



**Universiteit  
Leiden**  
The Netherlands

## **Evaluation of subclasses for T4-classified squamous cell carcinoma of the external auditory canal**

Nabuurs, C.H.; Kievit, W.; Leemans, C.R.; Smit, C.F.G.M.; Brekel, M.W.M. van den; Pauw, R.J.; ... ; Kunst, H.P.M.




### **Citation**

Nabuurs, C. H., Kievit, W., Leemans, C. R., Smit, C. F. G. M., Brekel, M. W. M. van den, Pauw, R. J., ... Kunst, H. P. M. (2022). Evaluation of subclasses for T4-classified squamous cell carcinoma of the external auditory canal. *Head And Neck*, 44(8), 1787-1798.  
doi:10.1002/hed.27082

Version: Publisher's Version  
License: [Creative Commons CC BY-NC-ND 4.0 license](#)  
Downloaded from: <https://hdl.handle.net/1887/3515816>

**Note:** To cite this publication please use the final published version (if applicable).

# Evaluation of subclasses for T4-classified squamous cell carcinoma of the external auditory canal

Cindy H. Nabuurs MD<sup>1,2</sup>  | Wietske Kievit PhD<sup>1,2,3</sup> |  
 C. René Leemans MD, PhD<sup>4</sup> | Conrad F. G. M. Smit MD, PhD<sup>4</sup> |  
 Michiel W. M. van den Brekel MD, PhD<sup>5</sup>  | Robert J. Pauw MD, PhD<sup>6</sup> |  
 Bernard F. A. M. van der Laan MD, PhD<sup>7,8</sup> | Jeroen C. Jansen MD, PhD<sup>9</sup> |  
 Martin Lacko MD, PhD<sup>10</sup> | Weibel W. Braunius MD<sup>11</sup> | Chunfu Dai MD, PhD<sup>12</sup> |  
 Xunbei Shi MD<sup>12</sup> | Giovanni Danesi MD, PhD<sup>13</sup> | Jan Bouček MD, PhD<sup>14</sup> |  
 Robert P. Takes MD, PhD<sup>1,2</sup>  | Henricus P. M. Kunst MD, PhD<sup>1,2,10</sup>

<sup>1</sup>Department of Otorhinolaryngology and Head and Neck Surgery – Academic Alliance Skull Base Pathology Radboudumc & MUMC+, Radboud University Medical Center, Nijmegen, the Netherlands

<sup>2</sup>Rare Cancers, Radboud Institute for Health Sciences, Nijmegen, the Netherlands

<sup>3</sup>Department of Health Evidence, Radboud University Medical Center, Nijmegen, the Netherlands

<sup>4</sup>Department of Otolaryngology and Head and Neck Surgery, Amsterdam University Medical Centers, VU University, Amsterdam, the Netherlands

<sup>5</sup>Department of Head and Neck Surgery, Netherlands Cancer Institute – Antoni van Leeuwenhoek, Amsterdam, the Netherlands

<sup>6</sup>Department of Otorhinolaryngology and Head and Neck Surgery, Erasmus Medical Center, Rotterdam, the Netherlands

<sup>7</sup>Department of Otorhinolaryngology and Head and Neck Surgery, University of Groningen, University Medical Center Groningen, Groningen, the Netherlands

<sup>8</sup>Department of Otorhinolaryngology and Head and Neck Surgery, Haaglanden Medical Center, The Hage, the Netherlands

<sup>9</sup>Department of Otorhinolaryngology and Head and Neck Surgery, Leiden University Medical Center, Leiden, the Netherlands

<sup>10</sup>Department of Otorhinolaryngology and Head and Neck Surgery – Academic Alliance Skull Base Pathology Radboudumc & MUMC+, Maastricht University Medical Center, Maastricht, the Netherlands

<sup>11</sup>Department of Head and Neck Surgical Oncology, University Medical Center/Utrecht Cancer Center, Utrecht, the Netherlands

<sup>12</sup>Department of Otolaryngology & Skull Base Surgery, Eye Ear Nose & Throat Hospital, Fudan University, Shanghai, China

<sup>13</sup>Department of Otorhinolaryngology and Skull Base Microsurgery-Neurosciences, Azienda Socio Sanitaria Territoriale Papa Giovanni XXIII, Bergamo, Italy

<sup>14</sup>Department of Otorhinolaryngology and Head and Neck Surgery, The First Faculty of Medicine, Charles University in Prague, University Hospital Motol, Prague, Czech Republic

## Correspondence

Cindy H. Nabuurs, Radboud University Medical Center, Department of Otorhinolaryngology and Head and Neck Surgery, Skull Base Center, P.O. Box 9191, 6500 HB Nijmegen, the Netherlands.  
 Email: [cindy.nabuurs@radboudumc.nl](mailto:cindy.nabuurs@radboudumc.nl)

## Abstract

**Background:** T4-classified squamous cell carcinoma (SCC) of external auditory canal (EAC) can potentially involve different anatomical structures, which could translate into different treatment strategies and survival outcomes within one classification. Our aim is to evaluate the clinical added value of T4-subclasses proposed by Lavieille and by Zanoletti.

This work represents an independent research supported by the Department of Otorhinolaryngology and Head and Neck Surgery, Radboud University Medical Center. Preliminary results were not presented previously.

This is an open access article under the terms of the [Creative Commons Attribution-NonCommercial-NoDerivs](https://creativecommons.org/licenses/by-nc-nd/4.0/) License, which permits use and distribution in any medium, provided the original work is properly cited, the use is non-commercial and no modifications or adaptations are made.

© 2022 The Authors. *Head & Neck* published by Wiley Periodicals LLC.

**Methods:** Retrospective data, including patients with primary operated cT4-classified EAC SCC, was obtained from 12 international hospitals. We subclassified according to the T4-subclasses. The treatment strategies, disease-free survival (DFS) and overall survival per subclass were calculated.

**Results:** A total of 130 T4-classified EAC SCC were included. We found commonly used treatment strategies per subclass according to Lavielle and the DFS seems also to differ per subclass. Subclass according to Zanoletti showed comparable treatment strategies and survival outcomes per subclass.

**Conclusion:** Our study suggests that the subclass according Lavielle might have added value in clinical practice to improve care of T4-classified EAC SCC.

#### KEYWORDS

disease-free survival, neoplasm staging, squamous cell carcinoma, temporal bone, treatment

## 1 | INTRODUCTION

Squamous cell carcinoma (SCC) of the external auditory canal (EAC) is a rare invasive tumor. Especially advanced EAC SCC is associated with a poor prognosis, despite current treatment strategies. The 5-year disease-free survival (DFS) of T4-classified tumors is between 35% and 84.4%.<sup>1-3</sup> Published studies describe various treatment strategies for advanced EAC SCC such as lateral, subtotal, or total temporal bone resection (LTBR, STBR, TTBR, respectively); with or without neck dissection; with or without (total) parotidectomy; and with or without (chemo-)radiotherapy.

In order to choose the optimal treatment, an adequate tumor classification is essential. The modified Pittsburgh classification is one of commonly used tumor classification systems for EAC SCC. This classification system consists of four T-classifications (T1–T4) based on the invasion of anatomical structures by the tumor. T4-classified tumors are tumors eroding the cochlea, petrous apex, medial wall of

the middle ear, carotid canal, jugular foramen, or dura, or with extensive soft tissue involvement (>0.5 cm), or involvement of temporomandibular joint or styloid process, or evidence of facial paresis.<sup>4</sup> Within this T4-class no differences are made based on the direction of the spread of the tumor. The involved anatomical structures, however, might affect the choice of the optimal surgical treatment, resulting in different treatment strategies and especially different surgical strategies for various T4-classified tumors.

The idea that a subclass of the T4-classified tumors could contribute to an improved treatment choice was already recognized by Lavielle et al.<sup>5</sup> in 1997 who proposed a subclass for T4-classified tumors taking into account the tumor extension (Table 1). A similar but simpler subclass was suggested by Zanoletti et al.<sup>6</sup> Their results showed that T4-classified tumors spreading anteriorly (parotid space and preauricular region) had a significantly better DFS compared to T4-classified tumors spreading nonanteriorly (87.5% and 8.3%, respectively).<sup>6</sup>

TABLE 1 T4-subclasses

T4-subclasses		
Lavielle et al.	According to Lavielle et al. <sup>5</sup>	Specified T4-subclasses
T4a	Extracranial: infratemporal fossa, skin, parotid	Tumor with extensive soft tissue involvement (>0.5 cm), such as involvement of TMJ, parotid gland, or styloid process
T4b	Intrapetrous bone and extradural extension	Tumor eroding the cochlea, medial wall of the middle ear, evidence of facial paralysis/erosion of facial nerve canal, defect of tegmen without intracranial growth, or erosion of bone on sigmoid sinus, eroding the petrous apex
T4c	Meningeal or intradural involvement	Tumor eroding carotid canal, jugular foramen, or dura/intracranial involvement
Zanoletti et al. <sup>6</sup>		
Anterior	Tumor spread to anterior	
Nonanterior	Tumor spread to posterior, superior, inferior, or medial	

The predictive performances of these two proposed subclasses have not yet been evaluated in an external study sample. We used an international database on EAC SCC to evaluate the DFS within the aforementioned T4-subclasses and the potential differences in treatment per T4-subclass. This might result in identification of potential room for improvement of prognosis.

In order to contribute to improved care of curable T4-classified EAC SCC, the primary aim of this retrospective multicenter study is to evaluate the T4-subclasses proposed by Lavieille et al. and by Zanoletti et al. in terms of analyzing the DFS outcome and overall survival (OS) outcome per subclass and in the context of the observed treatment strategies per subclass. Therefore, we focused on T4-classified EAC SCC that were treated surgically. T4-classified EAC SCC that were not operated are tumors that were irresectable or the patients were inoperable. These patients received palliative care.

## 2 | METHODS

### 2.1 | Database

First a nationwide cohort study was conducted including patients who were treated with curative intent for primary EAC SCC in one of the eight Dutch head and neck oncological centers between 1975 and 2017. The patients were identified using two nationwide systems (ICD-code, “International Statistical Classification of Diseases and Related Health Problems” and PALGA, “Pathologisch-Anatomisch Landelijk Geautomatiseerd Archief”: a nationwide pathology archive). Thereafter, the diagnosis was verified manually by checking the medical records. Approval was obtained from the medical ethics committee of Radboud University Medical Center (number 2017-3397); participating centers complied with their local medical ethics committee requirements.

This nationwide database was combined with retrospective data of patients who were treated for EAC SCC in Eye and ENT Hospital of Fudan University (Shanghai, China) between 2005 and 2018, Papa Giovanni XXIII hospital (Bergamo, Italy) between 2012 and 2019, Padova General Hospital (Padova, Italy) between 2014 and 2017 and Motol University Hospital (Prague, Czech Republic) between 2011 and 2020.

### 2.2 | Patient selection

For this study, only patients with clinical cT4-classified EAC SCC were included. Patients were excluded if the

site of the origin was not the EAC, temporal bone, or middle ear; the histologic subtype was not SCC; if the EAC SCC was not the primary tumor; if the EAC SCC was a residual or recurrence; if the medical records were too limited to stage or classify the tumor; patients were not treated surgically; or if they received palliative care for their primary EAC SCC. Patients were also excluded if they were treated by local resection in combination with local application of 5-fluorouracil, in order to improve the homogeneity of the data.

### 2.3 | T4-subclasses

The modified Pittsburgh classification was applied to classify tumors in this study.<sup>4</sup> The subclasses of T4-classified tumors was performed using Lavieille's<sup>5</sup> and Zanoletti's<sup>6</sup> subclass system (Table 1). The T4-subclass according to Lavieille et al. was specified by our research group in order to improve the clinical use of it. Moreover, the T4c-subclass additionally includes tumor spreading to carotid canal or jugular foramen, because these tumors seems clinically more difficult to treat and seems to have poorer prognosis compared to T4b-classified tumors.<sup>5</sup> The clinical TNM-classification was based on clinical examination and imaging findings. The pathological TNM-classification was adjusted if necessary based on surgical findings and pathological results. All tumors were classified based on the characteristics. The classification was performed by CN and HK for the EAC SCC treated in the Dutch centers, by CD and XS for the EAC SCC treated in the Fudan University in China, by GD and RB for the EAC SCC treated in the Azienda Socio Sanitaria Territoriale Papa Giovanni XXIII hospital in Italy, and JB and MT for the EAC SCC treated in the University hospital Motol in Czech Republic.

If tumors contained features of more subclasses, the tumor was classified with the suggested poorest prognosis. For the subclass according to Lavieille, tumors were classified to the highest T4-subclass. For the subclass according to Zanoletti et al., tumors classified as non-anteriorly growing tumor if they grew both anteriorly and nonanteriorly. The pathological information was unavailable in order to give a pathological subclass according to Zanoletti et al. In order to compare the pathological subclasses according to Lavieille et al. with the subclasses according Zanoletti et al., we excluded the patients with a pT1-, pT2-, or pT3-subclassified tumor and assumed that the pathological subclass according Zanoletti et al. remained the same as the clinical subclass according Zanoletti et al.

## 2.4 | Analyses

First, the frequencies of various treatment strategies and surgical techniques were calculated per subclass. Thereafter, the DFS and OS after initial treatment per cT4-subclass were analyzed using the Kaplan Meier survival analysis. The differences in 5-year DFS outcome between cT4-subclasses were analyzed using the cox regression analyses. Although our database is relatively large, the database is too small to perform other statistical analyses of subgroups or to correct the analyses for potential confounders affecting the outcomes, such as treatment strategies. All data analyses were performed in R version 3.4.3 (RStudio: Integrated Development for R. Boston, USA 2016). In all analyses, a probability ( $p$ ) value  $<0.05$  was considered statistically significant.

## 3 | RESULTS

### 3.1 | Total study population

In total 130 patients with cT4-classified tumor were included in this study, 19 had clinically suspected lymph node metastases (cN+) (Table 2), 118 patients had a pathological T4-classified tumor postoperatively, 68 had a residual or recurrent disease, and 64 died during follow-up (median follow-up 19.5 months; min–max 1–161 months).

The treatment strategies of T4-classified tumors consisted mainly of surgery in combination with radiotherapy (62.3%). The surgical technique mainly used was LTBR or STBR (48.5% and 33.8%, respectively) with parotidectomy (73.8%) and also a neck dissection in approximately half of the patients (51.5%).

### 3.2 | cT4-subclass according to Lavieille et al.

According to the T4-subclass of Lavieille et al., 48 tumors were classified as cT4a, 38 as cT4b, 37 as cT4c and 7 could not be classified in one of these three subclasses due to lack of information. Table 2 shows that 18.8% of the patients with cT4a-classified tumors, 13.2% with cT4b-classified tumors and 8.1% with cT4c-classified tumors have clinically suspected lymph nodes. The percentage of patients with pathologically proven lymph nodes were comparable between all subclasses (18.8%, 18.4%, and 16.2%, respectively, for cT4a-, cT4b-, and cT4c-classified tumors).

### 3.3 | Treatment strategies

Table 3 shows that all three subclasses were mainly treated with surgery combined with radiotherapy (64.6%, 71.1%, and 54.1%, respectively, for cT4a-, cT4b-, and cT4c-classified tumors). Of the cT4c-classified tumors, 24.3% was treated with additional chemotherapy (24.3%) compared to 8.3% and 15.8% for cT4a- and cT4b-classified tumors, respectively. The surgical technique for cT4a-classified tumors was mainly LTBR (72.9%), for cT4b-classified tumors LTBR (39.5%) or STBR (42.1%) and for cT4c-classified tumors STBR (43.2%). All tumors, regardless of the subclass, were mostly treated with additional parotidectomy. About 50% of all tumors, regardless of the subclass, were treated with additional neck dissections. Tumors with no clinically suspected lymph nodes were mostly treated with also an elective (partial/superficial/total) parotidectomy and about half of tumors with no clinically suspected lymph nodes were treated with an elective neck dissection (Table 4).

### 3.4 | Survival outcomes

The residue and recurrence rate of cT4b- and cT4c-classified tumors (55.3% of cT4b- and 56.8% of cT4c-classified tumors) were higher compared to cT4a-classified tumors (41.7%). The 5-year DFS-outcome of patients with cT4a-, cT4b-, and cT4c-classified tumors were 60.8%, 45.5%, and 39.1%, respectively (Figure 1A).

However, the Cox regression analyses showed that the hazard ratio (HR) for DFS outcomes was not statistically significant for patients with cT4b- (HR 1.638; 95% CI 0.841–3.193;  $p = 0.326$ ) and cT4c-classified tumors (HR 1.603; 95% CI 0.808–3.181;  $p = 0.177$ ) compared to cT4a-classified tumors. This was also seen for patients with cT4c-classified tumors (HR 1.141; 95% CI 0.586–2.219;  $p = 0.698$ ) compared to cT4b-classified tumors. The 5-year OS-outcome of patients with cT4a-, cT4b-, and cT4c-classified tumors were 57.3%, 41.9%, and 39.5%, respectively (Figure 1C).

The 5-year DFS-outcome of patients with pT4a-, pT4b-, and pT4c-classified tumors were 70%, 36.6%, and 27.8%, respectively (Figure 1B). The Cox regression analyses showed that the hazard ratio (HR) for DFS outcomes was statistically significant different for patients with cT4b- (HR 2.309; 95% CI 1.059–5.035;  $p = 0.035$ ) and for patients with cT4c-classified tumors (HR 2.747; 95% CI 1.236–6.102;  $p = 0.013$ ) compared to cT4a-classified tumors. However, the HR for patients with cT4c-classified tumors (HR 1.190; 95% CI 0.642–2.203;  $p = 0.581$ ) was not statistically significant different to cT4b-classified tumors.

TABLE 2 Patient characteristics

	Modified Pittsburgh classification			Clinical subclasses according to Lavieille et al. (N = 123)						Clinical subclasses according to Zanoletti et al. (N = 115)					
	cT4	cT4a		cT4b		cT4c		NA		cT4 anterior	cT4 nonanterior		NA		
		N = 130	%	N = 48	%	N = 38	%	N = 37	%		N = 7	N = 24	%	N = 91	%
Sex															
Male	73	56.2	26	54.2	22	57.9	21	56.8	4	11	45.8	55	60.4	7	
Female	57	43.8	22	45.8	16	42.1	16	43.2	3	13	54.2	36	39.6	8	
Age	63 (38–84)		65.5 (39–84)		62.5 (43–82)		61 (38–84)		73 (39–78)		64 (38–84)		63 (39–84)		63 (39–78)
Direction <sup>a</sup>															
Anterior	63	48.5	27	56.3	18	47.4	17	45.9	1	24	100.0	39	42.9	0	
Posterior	46	35.4	15	31.3	16	42.1	14	37.8	1	0	0.0	46	50.5	0	
Inferior	50	38.5	15	31.3	16	42.1	18	48.6	1	0	0.0	50	54.9	0	
Superior	33	25.4	5	10.4	11	28.9	16	43.2	1	0	0.0	33	36.3	0	
Facial nerve paresis	41	31.5	3	6.3	21	55.3	15	40.5	2	5	20.8	31	34.1	5	
cN															
None	111	85.4	39	81.3	33	86.8	34	91.9	5	22	91.7	76	83.5	13	
Suspected	19	14.6	9	18.8	5	13.2	3	8.1	2	2	8.3	15	16.5	2	
pT															
1	2	1.5	2	4.2	0	0.0	0	0.0	0	0	0.0	2	2.2	0	
2	3	2.3	2	4.2	1	2.6	0	0.0	0	0	0.0	3	3.3	0	
3	7	6.3	4	10.3	2	6.1	1	2.9	0	1	4.2	3	3.3	3	
4	118	90.8	40	83.3	35	92.1	36	97.3	7	23	95.8	83	91.2	12	
pT4-subclasses <sup>b</sup>															
4a	38	29.2	35	72.9	1	2.6	2	5.4	0	11	45.8	25	27.5	2	
4b	39	30.0	4	8.3	30	78.9	4	10.8	1	8	33.3	27	29.7	4	
4c	35	26.9	1	2.1	4	10.5	30	81.1	0	4	16.7	28	30.8	3	
NA	6	4.6	0	0	0	0	0	0	6	0	0	3	3.2	3	
pN															
None	107	82.3	39	81.3	31	81.6	31	83.8	6	18	75.0	74	81.3	15	
Yes	23	17.7	9	18.8	7	18.4	6	16.2	1	6	25.0	17	18.7	0	

Abbreviation: NA, not available.  
<sup>a</sup>One tumor could grow in more than one direction.  
<sup>b</sup>According to the subclassification of Lavieille et al.

TABLE 3 Treatment strategies per subclass

Treat	Clinical subclasses according to Lavieille et al. (N = 123)										Clinical subclasses according to Zanoletti et al. (N = 115)					
	cT4		cT4a		cT4b		cT4c		NA		cT4 anterior		cT4 nonanterior		NA	
	N = 130	%	N = 48	%	N = 38	%	N = 37	%	N = 7	%	N = 24	%	N = 91	%	N = 15	%
1 = Surg	17	13.1	8	16.7	3	7.9	4	10.8	2	10.8	5	20.8	10	11.0	2	
2 = Surg + RTx	81	62.3	31	64.6	27	71.1	20	54.1	3	54.1	13	54.2	58	63.7	10	
3 = Surg + CRT	21	16.2	4	8.3	6	15.8	9	24.3	2	24.3	4	16.7	15	16.5	2	
NA	11	8.5	5	10.4	2	5.3	4	10.8	0	10.8	2	8.3	8	8.8	1	
Surgical technique	7	5.4	2	4.2	1	2.6	2	5.4	2	5.4	1	4.2	2	2.2	4	
Local	63	48.5	35	72.9	15	39.5	10	27.0	3	27.0	16	66.7	44	48.4	3	
LTBR	44	33.8	10	20.8	16	42.1	16	43.2	2	43.2	7	29.2	33	36.3	4	
STBR	5	3.8	0	0.0	5	13.2	0	0.0	0	0.0	0	0.0	2	2.2	3	
TTBR	9	6.9	0	0.0	0	0.0	9	24.3	0	24.3	0	0.0	8	8.8	1	
Other	2	1.5	1	2.1	1	2.6	0	0.0	0	0.0	0	0.0	2	2.2	0	
NA	33	25.4	9	18.8	12	31.6	10	27.0	2	27.0	4	16.7	22	24.2	7	
Parotidectomy	96	73.8	38	79.2	26	68.4	27	73.0	5	73.0	20	83.3	68	74.7	8	
Yes	1	0.8	1	2.1	0	0.0	0	0.0	0	0.0	0	0.0	1	1.1	0	
NA	62	47.7	21	43.8	21	55.3	15	40.5	5	40.5	9	62.5	47	51.6	6	
Neck dissection	67	51.5	26	54.2	17	44.7	22	59.5	2	59.5	15	62.5	43	47.3	9	
Yes	1	0.8	1	2.1	0	0.0	0	0.0	0	0.0	0	0.0	1	1.1	0	
NA	92	70.8	39	81.3	21	55.3	28	75.7	4	75.7	18	75.0	66	72.5	8	
Facial nerve sacrifice	35	26.9	8	16.7	17	44.7	9	24.3	1	24.3	6	25.0	24	26.4	5	
Yes	3	2.3	1	2.1	0	0.0	0	0.0	2	0.0	0	0.0	1	1.1	2	
NA	72	55.4	27	56.3	17	44.7	25	67.6	3	67.6	15	62.5	51	56.0	6	
Margin	51	39.2	17	35.4	19	50.0	11	29.7	4	29.7	8	33.3	34	37.4	9	
Negative	7	5.4	4	8.3	2	5.3	1	2.7	0	2.7	1	4.2	6	6.6	0	
Positive	17	13.1	8	16.7	3	7.9	4	10.8	2	10.8	5	20.8	10	11.0	2	
NA	107	82.3	37	77.1	33	86.8	32	86.5	5	86.5	18	75.0	76	83.5	13	
Additional radiotherapy	6	4.6	3	6.3	2	5.3	1	2.7	0	2.7	1	4.2	5	5.5	0	
No	66 (40–74)		66 (48–70)		66 (40–74)		66 (60–74)		66 (60–66)		66.0 (48.0–70.0)		66.0 (40.0–74.0)		62 (40–74)	
Yes	85	65.4	33	68.8	28	73.7	20	54.1	4	54.1	14	58.3	59	64.8	12	
NA	21	16.2	4	8.3	6	15.8	9	24.3	2	24.3	4	16.7	15	16.5	2	
Dose median (min–max)	24	18.5	11	22.9	4	10.5	8	21.6	1	21.6	6	25.0	17	18.7	1	

Abbreviations: CRT, chemoradiotherapy; LTBR, lateral temporal bone resection; NA, not available; RTx, radiotherapy; STBR, subtotal temporal bone resection; TTBR, total temporal bone resection.

TABLE 4 Elective neck dissection and parotidectomy

		Neck dissection			Parotidectomy		
		Yes	No	NA	Yes	No	NA
cT4N0 (N = 111)	No. of patients	53	57	1	79	31	1
	% of patients	47.7	51.4	0.9	71.2	27.9	0.9
	5-year DFS (95% CI)	54.7 (41.3–72.5)	49.3 (37.1–65.4)		60.8 (50.0–73.9)	30.3 (16.9–54.3)	
cT4aN0 (N = 39)	No. of patients	19	19	6	30	8	6
	% of patients	48.7	48.7	15.4	76.9	20.5	15.4
	5-year DFS (95% CI)	62.5 (42.8–91.4)	66.7 (48.1–92.4)		68.8 (52.9–89.4)	50 (25–100)	
cT4bN0 (N = 33)	No. of patients	13	20	0	22	11	0
	% of patients	39.4	60.6	0	66.7	33.3	0
	5-year DFS (95% CI)	68.6 (44.5–100)	39.1 (21.6–70.6)		66.2 (47.4–92.4)	27.3 (10.4–71.6)	
cT4cN0 (N = 34)	No. of patients	21	13	0	24	10	0
	% of patients	61.8	38.2	0	70.6	29.4	0
	5-year DFS (95% CI)	40.1 (21.8–73.7)	45.4 (23.8–86.8)		46.5 (28.8–75.0)	28.6 (8.9–92.2)	
cT4 anterior N0 (N = 22)	No. of patients	14	8	0	18	4	0
	% of patients	63.6	36.4	0	81.8	18.2	0
	5-year DFS (95% CI)	58.3 (36.2–94.1)	42.9 (18.2–100)		53.3 (33.2–85.6)	50 (18.8–100)	
cT4 nonanterior N0 (N = 76)	No. of patients	32	43	1	55	20	0
	% of patients	42.1	56.6	1.3	72.4	26.3	0
	5-year DFS (95% CI)	47.1 (30.2–73.5)	57.7 (43.7–76.3)		61.8 (49.2–77.7)	31.4 (14.7–66.9)	

Abbreviations: CI, confidential interval; DFS, disease-free survival; NA, not available.

Table 4 shows that elective neck dissection does not improve 5-year DFS outcomes compared to no elective neck dissection. On the other hand, elective parotidectomy seems to improve the 5-year DFS outcome in the total group (cT4N0-classified EAC SCC) compared to no elective parotidectomy, 60.8% (95% CI of 50–74) versus 30.3% (95% CI of 17–54), respectively. The Cox regression analysis test shows a HR 0.5178 (95% CI of 0.289–0.930) and a *p*-value of 0.028. However, this difference in 5-year outcome for elective parotidectomy is not seen for each subclass of Lavieille et al.

### 3.5 | cT4-subclass according to Zanoletti et al.

Based on the subclass proposed by Zanoletti et al., 24 patients were classified as a cT4 anterior tumor, 91 as a cT4 nonanterior tumor and 15 could not be classified in one of these two subclasses due to lack of information. About 8.3% of the patients with cT4 anterior tumors and 16.5% with the cT4 nonanterior tumors have clinically suspected lymph nodes. The percentage of patients with pathologically proven lymph nodes were 25.0% and 18.7% for the cT4 anterior and cT4 nonanterior classified tumors.

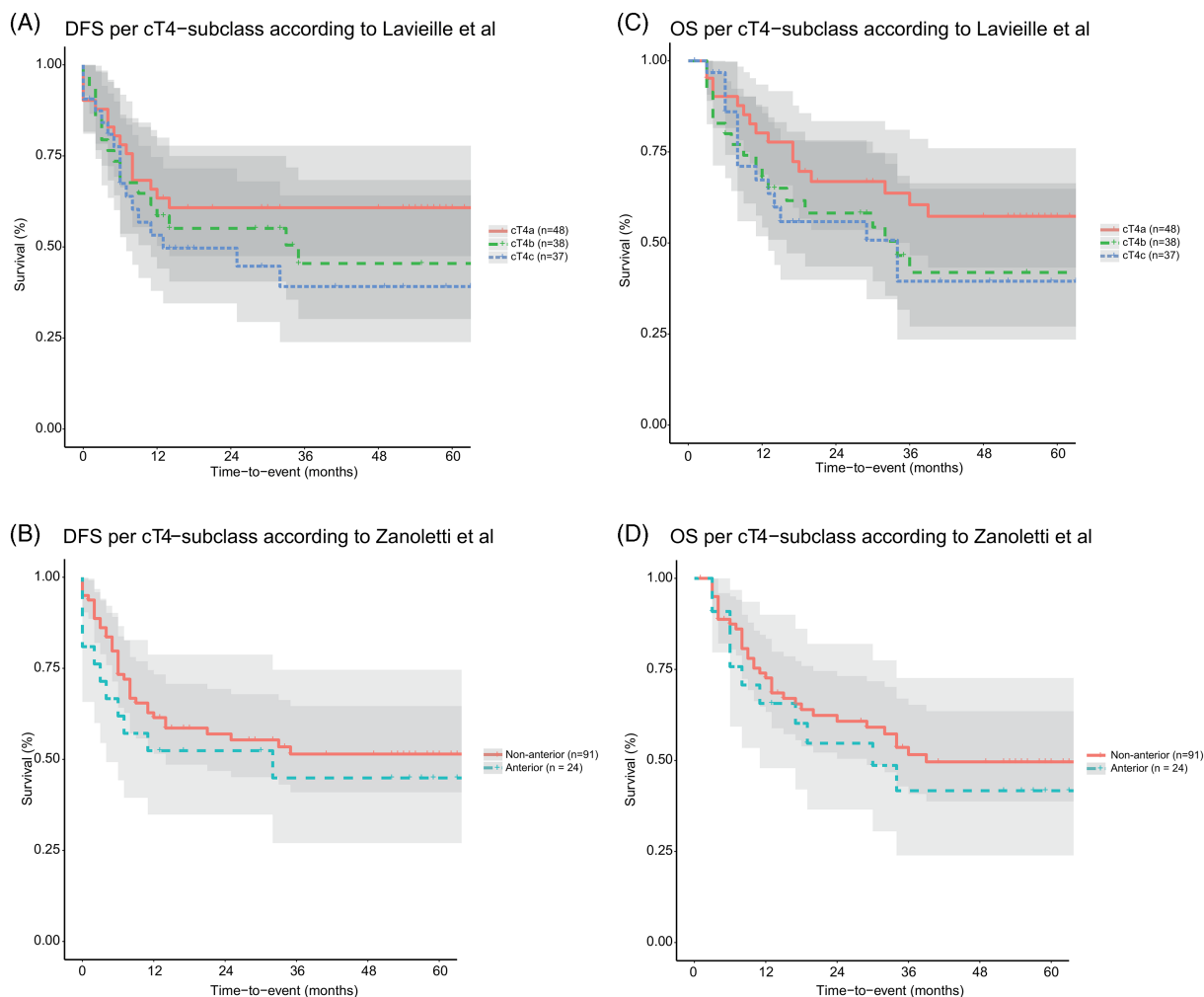
### 3.6 | Treatment strategies

Both cT4-subclassified tumors according to Zanoletti et al. were mainly treated with surgery in combination with radiotherapy (54.2% of cT4 anterior classified tumors and 63.7% of cT4 nonanterior classified tumors). The surgical technique for cT4 anterior classified tumors was mainly LTBR (66.7%) and for cT4 nonanterior classified tumors were LTBR (48.4%) or STBR (36.3%). In both subgroups additional parotidectomy was performed in about 75% of the cases. In about half of the cases a neck dissection or an elective neck dissection was performed, independently of the subclass (Table 4).

### 3.7 | Survival outcomes

The residue and recurrence rate of both subclassified T4 tumors were similar (cT4 anterior: 54.2% and cT4 nonanterior: 50.5%). The subgroups had similar 5-year DFS outcomes (44.9% and 51.5%, respectively, for cT4 anterior and nonanterior classified tumors, Figure 1D) and similar 5-year OS outcomes (51.7% and 49.6%, respectively, for cT4 anterior and nonanterior classified tumors, Figure 1F). The 5-year DFS outcomes for pT4 anterior





**FIGURE 1** Survival outcome per subclass according Lavielle et al. and Zanoletti et al. DFS, disease-free survival; OS, overall survival [Color figure can be viewed at [wileyonlinelibrary.com](https://onlinelibrary.wiley.com/doi/10.1002/hed.27082)]

(45.5%) was not statistically significant different from the 5-year DFS outcome of pT4 nonanterior (47.1%), with a  $p =$  value of 0.95 (Figure 1E). Table 4 shows also that elective neck dissection and elective parotidectomy do not improve the 5-year DFS outcomes compared to no elective neck dissection or elective parotidectomy.

## 4 | DISCUSSION

This study evaluated the T4-subclasses proposed by Lavielle et al. and by Zanoletti et al. in terms of the chosen treatment strategies per subclass and analyzing the DFS and OS outcomes of these subclasses. Our results show that the DFS-outcome of cT4b- and cT4c-subclassified tumors—according to the subclass of Lavielle et al.—seems to be poorer compared to cT4a-subclassified tumors. However, this difference is not statistically significant probably due to the small number of

patients per subclass. Our data also show that both T4-subclassified tumors proposed by Zanoletti et al. showed comparable treatment strategies and survival outcomes. This might indicate that using these subclasses does not have added value to determine a more specified treatment strategy per T4-subclassified tumor to improve survival outcome. Furthermore, our data show that there is a variation of treatment strategies for T4-classified tumors as a whole, but in practice there seems to be a treatment strategy in place per T4-subclass according to Lavielle et al.

### 4.1 | Surgical resection techniques

Surgery is the primary curative treatment of choice for advanced EAC SCC.<sup>7–9</sup> In general, there are four surgical techniques to remove the tumor: local resection, LTBR, STBR, and TTBR. There is no literature that supports

**TABLE 5** Summary of the suggested (surgical) treatment strategy for future research per T4-subclassified tumor

<b>T4-subclass according Lavieille et al.</b>	<b>Suggested (surgical) treatment strategy for future research</b>
T4a	LTBR If TMJ is invaded, additional (partial) removal of the temporomandibular joint + Elective partial superficial parotidectomy to safeguard oncological margin + Only if N+, then neck dissection and/or partial or total parotidectomy + Adjuvant radiation
T4b	LTBR. Unless there is erosion of medial wall of middle ear, then STBR is advocated If facial nerve invasion, additional facial nerve sacrifice with direct facial nerve reconstruction + Elective superficial parotidectomy to safeguard oncological margin + Only if N+, then neck dissection and/or total parotidectomy + Adjuvant radiation
T4c	STBR If facial nerve invasion, additional facial nerve sacrifice with direct facial nerve reconstruction If invasion of dura, additional dura resection with frozen section pathology for assessing the margin + Elective superficial parotidectomy to safeguard oncological margin + Only if N+, then neck dissection and/or total parotidectomy + Adjuvant radiation

Abbreviations: N+, clinical suspected lymph node metastasis; TMJ, temporomandibular joint.

local resection for advanced EAC SCC. In our database only seven T4-classified tumors were treated with local resection. Four of them were initially suspected of benign disease and three of them were surgically removed by creating a radical cavity and one of them by a retro- and infra-auricular approach. For one of these seven T4-classified tumors the surgeon chose on purpose for creating a radical cavity instead of en bloc resection, although the biopsy already showed SCC. The exact reason for this choice is unknown. The histopathologic examination of these five operations showed SCC leading to adjuvant radiotherapy. The reasons for why the two other tumors were treated by local resection are unknown. All seven patients had a residual disease or developed a recurrence within 2 years. In our data, cT4a-classified tumors were mainly removed by LTBR, cT4b-classified tumors by LTBR or STBR and cT4c-classified tumors by STBR. LTBR is recommended by Lassig et al. as primary intervention regardless the classification.<sup>7</sup> Mazzone et al. recommend LTBR if the T4-classified tumors expand only anteriorly.<sup>10</sup> Other studies recommend STBR as primary intervention for T4-classified tumors or if the T4-classified tumor do not expand anteriorly.<sup>3,5,8–13</sup> In general, TTBR is not recommended,

because it is related with high morbidity without survival improvement.<sup>5,11,14</sup> Lovin et al. recommends TTBR only if the tumor extends into or medial to the bony labyrinth.<sup>9</sup> Surgical resection of the dura is only recommended, if the dura is involved.<sup>11,15</sup> In case that the facial nerve is invaded by the tumor, the facial nerve needs to be sacrificed and directly reconstructed.<sup>8,15</sup> Although the evidence in previously mentioned literature and of our data is low, we would like to suggest LTBR for cT4a-classified tumors and if the temporomandibular joint (TMJ) is invaded by tumor with additional (partial) removal of the TMJ; LTBR for cT4b-classified tumors or STBR for cT4b-classified tumor with erosion of medial wall of middle ear with additional facial nerve sacrifice if the facial nerve is invaded; STBR for cT4c-classified tumors with additional dura resection with frozen section pathology for assessing the margin if dura is invaded by tumor (Table 5).

## 4.2 | Parotidectomy

The parotid gland can be invaded by the tumor through the fissures of Santorini or can contain intraparotid

lymph nodes with metastasis. Our data show that most cT4-subclassified tumors were treated with an additional parotidectomy or elective parotidectomy. However, it was not clear when there were no clinically suspected lymph nodes and a parotidectomy was performed whether it was done to safeguard oncological margin or it was done electively. We assumed it as elective parotidectomy.

Our results are in line with the literature. Most studies suggest performing at least an elective superficial parotidectomy in advanced EAC SCC even when there is no clinically suspected lymph node metastasis.<sup>7,8,12,16–20</sup> However, other studies recommend that cT4-classified tumors should additionally be treated with a total parotidectomy.<sup>21–24</sup> In contrast, two studies proposed no elective parotidectomy, but elective treatment of the parotid gland with radiotherapy<sup>1</sup> or to consider it only when a neck dissection is indicated.<sup>2</sup> Elective parotidectomy for EAC SCC was frequently performed in our data. Although the level of evidence of the literature and our data are limited, we suggest performing an elective partial superficial parotidectomy in all cT4N0-classified tumors to safeguard oncological margin, especially if the tumor expands anteriorly (Table 5).

### 4.3 | Neck dissection

In our database, about half of the patients received an elective neck dissection (54.7%) without significant improvement of the 5-year DFS outcome. These numbers are comparable for each cT4-subclassified tumor. Elective neck dissection for EAC SCC is still under debate. Some studies encourage elective neck dissections especially in advanced EAC SCC as a staging tool and for free flap reconstructions.<sup>18,21,22,24,25</sup>

Kiyokawa et al. suggest if an elective neck dissection is being considered, to remove the lymph nodes of level 1–3, because these levels are common levels for metastasis of EAC SCC.<sup>26</sup> Kunst et al. do not encourage standard elective neck dissection, because suspected lymph nodes can be diagnosed adequately preoperatively to prevent unnecessary morbidities related to neck dissections.<sup>8,27</sup> In order to prevent unnecessary neck dissections and its associated morbidity, it might be interesting to evaluate in the future what the DFS will be if neck dissections are only performed if the patient with a cT4-classified tumor has clinically suspected lymph nodes (Table 5).

### 4.4 | Radiotherapy

In our data, almost all cT4-subclassified tumors received radiotherapy, particularly cT4b- and cT4c-subclassified

tumors. The tumors that did not receive radiotherapy ( $n = 17$ ) were due to continuing growth of the tumor ( $n = 4$ ), death within 4 months after surgery ( $n = 3$ ) and for unknown reason ( $n = 10$ ). The literature also recommends adjuvant radiotherapy in T4-classified tumors, despite the surgical margins or tumor characteristics.<sup>8,15,21,24,25,28</sup>

### 4.5 | Chemoradiotherapy

Chemoradiotherapy is an upcoming additional treatment for EAC SCC. Nakagawa et al. showed in a small population with EAC SCC that neoadjuvant chemoradiation may improve the success of negative surgical margins for cT3- and cT4-classified tumors.<sup>1</sup> Takenaka et al. also showed in their meta-analysis that neoadjuvant chemoradiation may improve the OS.<sup>29</sup> Shiga et al. showed that T4-classified tumors were treated primary with chemoradiotherapy when the tumor involves the cochlear, jugular foramen, dura mater invasion, or brain invasion.<sup>30</sup> Results of other studies also presented beneficial effects of chemoradiotherapy on survival outcomes of EAC SCC, but all studies used different chemoradiation protocols and the sample sizes were too small for meaningful evaluation.<sup>31–38</sup>

### 4.6 | Alternative T4-subclassification

Shinomiya et al. suggested in 2021 another subclass for T4-classified EAC SCC consisting of T4a-subclass including T4-classified tumors without involving the brain, internal carotid artery, and internal jugular vein and of T4b-subclass including T4-classified tumors that involve one of these three previously mentioned structures.<sup>39</sup> Their T4a-class is comparable to the T4a-class and T4b-class of Lavielle et al. and their T4b-class is comparable to the T4c-class of Lavielle et al. It would be interesting to evaluate the DFS and OS of these two subclasses to evaluate and compare the clinical added value of both systems.

## 5 | STRENGTHS AND LIMITATIONS

Studies on EAC SCC are generally retrospective cohorts including our study, because EAC SCC are extremely rare. Retrospective studies have a high risk of confounding factors and their effects are hard to analyze especially in small sample sizes. For example, the exact reasons that various treatment strategies were chosen remain unknown, although this would be very

interesting to study for a future guideline on treatment strategies for EAC SCC. It would also be interesting to study in the future the interobserver variability of the classification systems for additional evaluation how the classification systems can be improved for clinical use. This may be an explanation why our results on the subclass of Zanoletti are in contrast with the results of Zanoletti et al. In addition, the subgroups were too small resulting in too little power to study the difference in DFS per subgroup. Consequently, we were unable to analyze the influence of the various treatment strategies on the outcomes. However, to our knowledge, our study involves one of the largest database of cT4-classified EAC SCC. We believe that sharing this data will contribute learning more about T4-classified EAC SCC, which could eventually improve the care for patients.

For future research, we recommend applying the subclass according to Lavieille et al. for T4-classified EAC SCC and to study the chosen treatment and the survival outcomes per T4-subclass, because our data show that the DFS-outcomes per T4-subclass according Lavieille seems to differ from each other and there is already a commonly used surgical strategy per T4-subclass in clinical practice.

## 6 | CONCLUSION

Our data show that if the T4-classified tumors are subclassified as proposed by Lavieille, the DFS-outcomes per T4-subclass seems to differ indeed and that there is already a commonly used treatment per T4-subclassified tumor in clinical practice. In contrast, if the T4-classified tumors are subclassified as proposed by Zanoletti, the DFS-outcomes and used treatment per subclass are comparable. Therefore, our study suggests that the subclass proposed by Lavieille et al. might have added value in clinical practice. For future research, we recommend to apply this subclass for T4-classified EAC SCC. Furthermore, we suggest to perform LTBR for cT4a-subclassified tumors; LTBR for cT4b and STBR for cT4b if the medial wall of the middle ear is eroded; STBR for cT4c-subclassified tumors. We also suggest to perform elective partial superficial parotidectomy to safeguard oncological margin and adjuvant radiotherapy for all cT4N0-subclassified tumors and only a neck dissection and/or superficial or total parotidectomy if there are clinically suspected lymph nodes.

## ACKNOWLEDGMENTS

We greatly appreciate and are thankful for the contribution of collecting data by Michaela Tesarova MD

(Department of Otorhinolaryngology, Head and Neck Surgery, The First Faculty of Medicine, Charles University in Prague, University Hospital Motol, Prague, Czech Republic) and by Rachele Bivona MD (Department of Otorhinolaryngology and Skull Base Microsurgery-Neurosciences, Azienda Socio Sanitaria Territoriale Papa Giovanni XXIII, Bergamo, Italy).


## CONFLICT OF INTEREST

The authors declare that there is no conflict of interest that could be perceived as prejudicing the impartiality of the research reported.

## DATA AVAILABILITY STATEMENT

The data that support the findings of this study are not openly available due to human data and are available from the corresponding author upon reasonable request

## ORCID

Cindy H. Nabuurs  <https://orcid.org/0000-0001-8894-4329>

Michiel W. M. van den Brekel  <https://orcid.org/0000-0002-6338-6743>

Robert P. Takes  <https://orcid.org/0000-0003-4784-0499>

## REFERENCES

- Nakagawa T, Kumamoto Y, Natori Y, et al. Squamous cell carcinoma of the external auditory canal and middle ear: an operation combined with preoperative chemoradiotherapy and a free surgical margin. *Otol Neurotol*. 2006;27(2):242-248. discussion 249.
- Ihler F, Koopmann M, Weiss BG, et al. Surgical margins and oncologic results after carcinoma of the external auditory canal. *Laryngoscope*. 2015;125(9):2107-2112.
- Bacciu A, Clemente IA, Piccirillo E, Ferrari S, Sanna M. Guidelines for treating temporal bone carcinoma based on long-term outcomes. *Otol Neurotol*. 2013;34(5):898-907.
- Moody SA, Hirsch BE, Myers EN. Squamous cell carcinoma of the external auditory canal: an evaluation of a staging system. *Am J Otol*. 2000;21(4):582-588.
- Lavieille J-P, Delande C, Kunst H, Devèze A, Magnan J, Schmerber S. Management of carcinoma of the temporal bone. *Mediterr J Otol*. 2005;2:1-9.
- Zanoletti E, Marioni G, Sritoni P, et al. Temporal bone squamous cell carcinoma: analyzing prognosis with univariate and multivariate models. *Laryngoscope*. 2014;124(5):1192-1198.
- Lassig AA, Spector ME, Soliman S, El-Kashlan HK. Squamous cell carcinoma involving the temporal bone: lateral temporal bone resection as primary intervention. *Otol Neurotol*. 2013; 34(1):141-150.
- Kunst H, Lavieille JP, Marres H. Squamous cell carcinoma of the temporal bone: results and management. *Otol Neurotol*. 2008;29(4):549-552.
- Lovin BD, Gidley PW. Squamous cell carcinoma of the temporal bone: a current review. *Laryngosc Investig Otolaryngol*. 2019;4(6):684-692.

10. Mazzoni A, Danesi G, Zanoletti E. Primary squamous cell carcinoma of the external auditory canal: surgical treatment and long-term outcomes. *Acta Otorhinolaryngol Ital.* 2014;34(2):129-137.
11. Prasad SC, D'Orazio F, Medina M, Bacciu A, Sanna M. State of the art in temporal bone malignancies. *Curr Opin Otolaryngol Head Neck Surg.* 2014;22(2):154-165.
12. Leong SC, Youssef A, Lesser TH. Squamous cell carcinoma of the temporal bone: outcomes of radical surgery and postoperative radiotherapy. *Laryngoscope.* 2013;123(10):2442-2448.
13. Hosokawa S, Mizuta K, Takahashi G, et al. Surgical approach for treatment of carcinoma of the anterior wall of the external auditory canal. *Otol Neurotol.* 2012;33(3):450-454.
14. Chi FL, Gu FM, Dai CF, Chen B, Li HW. Survival outcomes in surgical treatment of 72 cases of squamous cell carcinoma of the temporal bone. *Otol Neurotol.* 2011;32(4):665-669.
15. Gidley PW, DeMonte F. Temporal bone malignancies. *Neurosurg Clin N Am.* 2013;24(1):97-110.
16. Zanoletti E, Lovato A, Stritoni P, Martini A, Mazzoni A, Marioni G. A critical look at persistent problems in the diagnosis, staging and treatment of temporal bone carcinoma. *Cancer Treat Rev.* 2015;41(10):821-826.
17. Choi JY, Choi EC, Lee HK, Yoo JB, Kim SG, Lee WS. Mode of parotid involvement in external auditory canal carcinoma. *J Laryngol Otol.* 2003;117(12):951-954.
18. Morris LG, Mehra S, Shah JP, Bilsky MH, Selesnick SH, Kraus DH. Predictors of survival and recurrence after temporal bone resection for cancer. *Head Neck.* 2012;34(9):1231-1239.
19. Zhang T, Li W, Dai C, Chi F, Wang S, Wang Z. Evidence-based surgical management of T1 or T2 temporal bone malignancies. *Laryngoscope.* 2013;123(1):244-248.
20. Xie B, Zhang T, Dai C. Survival outcomes of patients with temporal bone squamous cell carcinoma with different invasion patterns. *Head Neck.* 2015;37(2):188-196.
21. Moffat DA, Wagstaff SA, Hardy DG. The outcome of radical surgery and postoperative radiotherapy for squamous carcinoma of the temporal bone. *Laryngoscope.* 2005;115(2):341-347.
22. Masterson L, Rouhani M, Donnelly NP, et al. Squamous cell carcinoma of the temporal bone: clinical outcomes from radical surgery and postoperative radiotherapy. *Otol Neurotol.* 2014;35(3):501-508.
23. Xie B, Wang M, Zhang S, Liu Y. Parotidectomy in the management of squamous cell carcinoma of the external auditory canal. *Eur Arch Otorhinolaryngol.* 2020;278(5):1355-1364.
24. Homer JJ, Lesser T, Moffat D, Slevin N, Price R, Blackburn T. Management of lateral skull base cancer: United Kingdom National Multidisciplinary Guidelines. *J Laryngol Otol.* 2016;130(S2):S119-S124.
25. Gidley PW, Roberts DB, Sturgis EM. Squamous cell carcinoma of the temporal bone. *Laryngoscope.* 2010;120(6):1144-1151.
26. Kiyokawa Y, Ariizumi Y, Ohno K, et al. Indications for and extent of elective neck dissection for lymph node metastasis from external auditory canal carcinoma. *Auris Nasus Larynx.* 2020;48(4):745-750.
27. Gillespie MB, Francis HW, Chee N, Eisele DW. Squamous cell carcinoma of the temporal bone: a radiographic-pathologic correlation. *Arch Otolaryngol Head Neck Surg.* 2001;127(7):803-807.
28. Woods RSR, Naude A, O'Sullivan JB, et al. Management of temporal bone malignancy in Ireland. *J Neurol Surg B Skull Base.* 2020;81(6):680-685.
29. Takenaka Y, Cho H, Nakahara S, Yamamoto Y, Yasui T, Inohara H. Chemoradiation therapy for squamous cell carcinoma of the external auditory canal: a meta-analysis. *Head Neck.* 2015;37(7):1073-1080.
30. Shiga K, Nibu KI, Fujimoto Y, et al. Sites of invasion of cancer of the external auditory canal predicting oncologic outcomes. *Head Neck.* 2021;43(10):3097-3105.
31. Shiga K, Ogawa T, Maki A, Amano M, Kobayashi T. Concomitant chemoradiotherapy as a standard treatment for squamous cell carcinoma of the temporal bone. *Skull Base.* 2011;21(3):153-158.
32. Shinomiya H, Hasegawa S, Yamashita D, et al. Concomitant chemoradiotherapy for advanced squamous cell carcinoma of the temporal bone. *Head Neck.* 2016;38(Suppl 1):E949-E953.
33. Kitani Y, Kubota A, Furukawa M, et al. Primary definitive radiotherapy with or without chemotherapy for squamous cell carcinoma of the temporal bone. *Eur Arch Otorhinolaryngol.* 2016;273(5):1293-1298.
34. Komune N, Noda T, Kogo R, et al. Primary advanced squamous cell carcinoma of the temporal bone: a single-center clinical study. *Laryngoscope.* 2021;131(2):E583-E589.
35. Yin M, Ishikawa K, Honda K, et al. Analysis of 95 cases of squamous cell carcinoma of the external and middle ear. *Auris Nasus Larynx.* 2006;33(3):251-257.
36. Fujiwara M, Yamamoto S, Doi H, et al. Arterial chemoradiotherapy for carcinomas of the external auditory canal and middle ear. *Laryngoscope.* 2015;125(3):685-689.
37. Nagano T, Yoshimura RI, Kojima M, Nakagawa K, Toda K. Outcomes of radiotherapy in advanced external auditory canal cancer. *J Radiat Res.* 2019;60(3):380-386.
38. Shiga K, Nibu KI, Fujimoto Y, et al. Multi-institutional survey of squamous cell carcinoma of the external auditory canal in Japan. *Laryngoscope.* 2021;131(3):E870-E874.
39. Shinomiya H, Uehara N, Fujita T, et al. New proposal to revise the classification for squamous cell carcinoma of the external auditory canal and middle ear. *J Laryngol Otol.* 2021;135(4):297-303.

**How to cite this article:** Nabuurs CH, Kievit W, Leemans CR, et al. Evaluation of subclasses for T4-classified squamous cell carcinoma of the external auditory canal. *Head & Neck.* 2022;44(8):1787-1798. doi:[10.1002/hed.27082](https://doi.org/10.1002/hed.27082)