



Universiteit
Leiden

The Netherlands

Characterization of vulvar diseases: novel imaging tools, models and molecular targets

Huisman, B.W.

Citation

Huisman, B. W. (2023, April 20). *Characterization of vulvar diseases: novel imaging tools, models and molecular targets*. Retrieved from <https://hdl.handle.net/1887/3594371>

Version: Publisher's Version

License: [Licence agreement concerning inclusion of doctoral thesis in the Institutional Repository of the University of Leiden](#)

Downloaded from: <https://hdl.handle.net/1887/3594371>

Note: To cite this publication please use the final published version (if applicable).

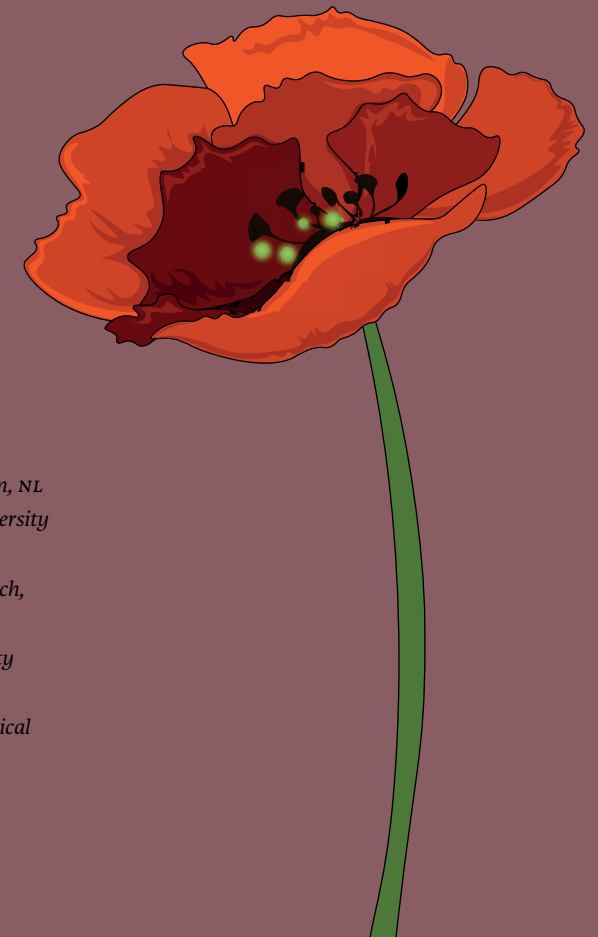SECTION III

MOLECULAR TARGET IDENTIFICATION OF VULVAR CARCINOMAS

CHAPTER 5

Potential targets for tumor-specific imaging of vulvar squamous cell carcinoma: a systematic review of candidate biomarkers.

B.W. Huisman^{a,b}, J. Burggraaf^{a,c,d}, A.L. Vahrmeijer^d, J.W. Schoones^e,
R.A. Rissmann^{a,c}, C.F.M. Sier^d, M.I.E. van Poelgeest^{a,b}



a Centre for Human Drug Research, Leiden, NL

b Department of Gynecology, Leiden University Medical Center, Leiden, NL

c Leiden Academic Center for Drug Research, Leiden University, Leiden, NL.

d Department of Surgery, Leiden University Medical Center, Leiden, NL

e Walaeus Library, Leiden University Medical Center, Leiden, NL

Abstract

INTRODUCTION Vulvar squamous cell carcinoma (vSCC) is a rare malignancy with an increasing incidence, especially in young women. Surgical treatment of vSCC is associated with significant morbidity and high recurrence rates, which is related to the limited ability to distinguish (pre)malignant from healthy tissue. There is a need for new tools for specific real-time detection of occult tumor lesions and localization of cancer margins in patients with vSCC. Several tumor-specific imaging techniques are developed to recognize malignant tissue by targeting tumor markers. We present a systematic review to identify, evaluate, and summarize potential markers for tumor-specific imaging of vSCC.

METHODS Relevant papers were identified by a systematic cross-database literature search developed with assistance of an experienced librarian. Data were extracted from eligible papers and reported based on the Preferred Reporting Items for Systematic reviews and Meta-Analyses (PRISMA) guidelines. vSCC-specific tumor markers were valued based on a weighted scoring system, in which each biomarker was granted points based on ranked eligibility criteria: I) percentage expression, II) sample size, and III) *in vivo* application.

RESULTS In total 627 papers were included of which 22 articles met the eligibility criteria. Twelve vSCC-specific tumor markers were identified and of these 7 biomarkers were considered most promising: EGFR, CD44V6, GLUT1, MRP1, MUC1, CXCR-4 and VEGF-A.

DISCUSSION This overview identified 7 potential biomarkers that can be used in the development of vSCC-specific tracers for real-time and precise localization of tumor tissue before, during, and after treatment. These biomarkers were identified in a small number of samples, without discriminating for vSCC-specific hallmarks such as HPV-status. Before clinical development, experimental studies should first aim at validation of these biomarkers using immunohistochemistry and cell line-based examination, discriminating for HPV-status and the expression rate in lymph nodes and precursor lesions.

Introduction

Vulvar carcinomas represent around 2-5% of all gynecological cancers and the incidence is rising, especially in young women.¹ Vulvar squamous cell carcinoma (vSCC) is the most common histopathological type and constitutes 80-90% of all vulvar cancers. There are two different pathophysiological pathways for vSCC: (I) a high-risk human papillomavirus (HPV) dependent type, accounting for 20% of all vSCC's, which is often associated with high grade squamous intraepithelial lesion (HSIL) and occurs mostly in younger women, and (II) an HPV-independent type associated with lichen sclerosis which is mostly observed in older women.²

Surgery with or without adjuvant (chemo)radiotherapy is the cornerstone of treatment of vSCC. Surgical treatment is frequently associated with significant morbidity, which is partly related to the limited ability to distinguish between healthy and malignant tissue, both before and during surgery. Positive surgical margins are associated with high local recurrence rates up to 40% and corresponding poor survival (5-year survival for recurrent vSCC is reported to be 25-50%).^{3,4} In addition, precursor lesions are often found adjacent to the tumor, which are sometimes difficult to identify clinically with current available imaging modalities. Consequently, incorrect identification results in re-excisions, local recurrences, regional metastases and associated worse prognosis. Moreover, when (pre)malignant lesions are located near the urethra, clitoris, or anus, surgery may be technically challenging with suboptimal results, ensuing in a decreased quality of life. This underlines the high unmet medical need for clinicians to more optimal discriminate tissue abnormalities of the vulva.

Currently there are no real-time techniques to distinguish (pre)malignant from healthy tissue during surgery, equivalent to the pathological assessment of hematoxylin/eosin stained vulvar tissue sections suspected of tumor invasion. Gynecologists rely on visual and tactile information, and experience for the identification of tumor tissue or distinction of tissue margins, before, during and after treatment. Treatment of patients can be improved upon the availability of safe and specific real-time detection of occult tumor lesions and localization of cancer margins. Such techniques will enhance personalized treatment decisions and minimize the risk of residual disease.

Molecular imaging integrates advanced imaging modalities with probes targeting molecular biomarkers of interest. This technique plays a signifi-

cant role in accurate diagnosis of several cancer types and is generally safe to apply. An imaging probe consists of a contrast label, such as radionuclides for nuclear based imaging, paramagnetic or electron opaque substances for radiological techniques, or bioluminescent or fluorescent molecules for optical imaging,⁵ which is conjugated to a molecular imaging agent with high affinity for a biomarker selectively expressed at the surface of tumor(-associated) cells (Figure 1). Small molecules, peptides, aptamers, antibodies, protein fragments and nanoparticles have been used as molecular imaging agents. After administration of an imaging probe, real-time images of the tissue of interest can be obtained by a suitable camera system that generates optical contrast between tumor and surrounding healthy tissue.⁶ This review will mainly focus on imaging agents applicable for optical imaging, as this modality benefits of its high-spatial resolution and real-time localization. An example of optical imaging coupled with image-guided surgery is Fluorescent Guided Surgery (FGS), which has been widely explored in the last decade.⁶ Particularly, the use of near-infrared (NIR) fluorescence dyes can most likely provide sufficient tissue penetration for vulvar carcinoma, though thus far, targeted imaging has not been used to detect VSCC.

The following characteristics define a potential protein marker for targeted imaging: extracellular biomarker localization, expression pattern, tumor-to-healthy tissue ratio, percentage and distribution of positive cells, and previous use of the biomarker for *in vivo* targeted imaging.^{7,8} Based on these criteria we rank the feasibility of different vulva-specific biomarkers, found through systematic analysis of the scientific literature using the PRISMA guidelines. The purpose of this review is to provide an overview of potential tumor specific targets for VSCC. These vulva-specific biomarkers could serve as targets for molecular imaging and help develop a structured approach of tumor-visualization.

Methods

This study was performed according to the PRISMA guidelines.⁹

SEARCH STRATEGY

Relevant scientific papers were identified by a systematic online cross-database search performed in July 2019, using PubMed, Embase, Web of Science, Cochrane Library and Academic Search Premier. Search strategies for all

databases were adapted from the PubMed strategy and developed with assistance of an experienced librarian of the Walaeus Library of the Leiden University Medical Center (JS). The search strategy consisted of the medical subject headings and text words related to the keywords 'vulvar carcinoma', 'target proteins' and abbreviations thereof. See Appendix I for the complete search strategies for each database.

ELIGIBILITY

Clinical trials (phase I, II, and III), and prospective or retrospective cohort studies were included. The following eligibility criteria were set: (1) Report of cell surface protein expression in more than 40% of the human VSCC tumor or tumor-associated cells, such as stromal cells, and (2) Evaluation of cell surface protein expression by immunohistochemistry. Results from flow cytometry analysis of cell lines were considered as advantageous but non-decisive. Animal studies, (systematic) reviews, not-English published abstracts and case reports were excluded.

TARGET SELECTION

Tumor-specific imaging is based on the distinction between malignant and healthy tissue. However, information about the expression of the target in non-malignant vulvar tissue and the pattern of expression is mostly lacking in the included studies. It was therefore chosen to leave these characteristics out of the target selection and refer to these if known in the descriptive text of the potential marker headings in the result section. To select potential tumor specific targets for optical imaging in VSCC, a weighted scoring system was used, adapted from the target selection criteria (tasc) scoring system.^{8,10} Biomarkers were granted points (0-2), based on three criteria (table 1). The criteria were prioritized to value certain criteria more important than others. The percentage expression score (criterion I) was chosen the most determinative factor and granted most weight, followed by the criteria *in vivo* application score (criterion II, based on the review of hertot et al.⁶), indicating previously use of the target for imaging of other cancer types. The least weight was assigned to the sample size score (criterion III). If more than one publication described the same target, the scoring system was applied to all articles. An average expression rate and a total sample size (n) was calculated for the particular target. Some publications described multiple potential targets.

Table 1 Target scoring system. Eligible biomarkers are granted points (0–2) based on three criteria: I) Percentage expression: percentage of vSCC samples expressing the target of interest; II) In vivo application: previously *in vivo* application of an imaging agent against the target of interest; III) Sample size: total number of vSCC samples tested within a study.

Target scoring system	0	1	2
I Percentage expression	50 – 65%	66 – 80%	>81%
II <i>In vivo</i> application	No		Yes
III Sample size	0 – 9	10 – 50	>50

Results

STUDY SELECTION

The literature searches yielded 1207 records: PubMed n=440; Embase n=439; Web of Science n=237; Cochrane Library n=9; Academic Search Premier n=82. After removal of duplicates, 627 records were available for screening. One investigator (BH) reviewed all titles and abstracts for eligibility based on the above-mentioned criteria, from which 151 full-text articles were obtained. Of the full-text articles, 129 did not meet the eligibility criteria: 76 articles described targets not expressed at the cell surface membrane, 29 articles reported a high expression of the target in healthy vulvar tissue and/or lower expression rates (<40%) of the target in vSCC, 8 articles were not about the expression in vSCC and for 8 articles no full-text was available. In case the investigator (BH) doubted the eligibility of an article, a second investigator (MVP) reviewed the paper and eligibility for inclusion in the review was based on consensus. In total, 22 scientific papers were included, describing 12 potential tumor targets for vSCC. See Figure 2 for the PRISMA flow diagram of the study selection.

CANDIDATE TARGETS

The 12 targets for tumor-specific imaging of vSCC evaluated in the selected 22 scientific papers were scored according to the target scoring system indicated in Table 1. Scores were summarized in Table 2. With an expression average of 65% or higher (score >0): EGFR,¹⁻²¹ CD44V6,²²⁻²⁵ GLUT,²⁶⁻²⁸ MRP1,^{12,13} MUC1²⁹ and CXCR-4³⁰ were considered potential candidates for tumor-specific imaging of vSCC. Although VEGF-A^{22,27,31} showed an average expression of 45% (score 0), it fulfilled both other criteria and therefore

this marker was included as well. The other evaluated targets were considered less potential, based on the granted scores (CD34,³² CA IX,²⁷ SPARC M,¹³ CCND1,¹⁵ BCRP¹²). The seven potential biomarkers for tumor-specific imaging in vSCC are described below. Description of the biomarkers is based on their physiological role, expression in tumor and healthy tissue and the availability of clinical tracers targeted against these biomarkers.

EGFR

Physiological role – Epidermal growth factor receptor (EGFR) is a transmembrane glycoprotein and one of the four members of the Human Epidermal growth factor Receptor (HER) family of tyrosine kinase receptors, consisting of EGFR/HER1, HER2/ERB2, HER3/ERBB3 and HER4/ERB4.³³ Epidermal growth factor binding to EGFR leads to cell proliferation. EGFR in normal epithelium of the skin is mainly expressed in proliferating keratinocytes.³⁴

Tumor upregulation/expression – Squamous carcinomas frequently over-express EGFR, which is thought to be characteristic for the loss of differentiation among keratinocytes and associated with a poor prognosis.^{12,18} Based on this literature search, 11 scientific papers described EGFR expression in vSCC with a total of 747 vSCC immunohistochemically stained samples. Of these samples an average of 67% stained positive (range 36-96%), with a median of 73%. One study observed positive staining for EGFR to be associated with good to moderate grade of differentiation (p=0.01).¹⁶ Another study found a progressive increase in EGFR expression from healthy vulvar tissue to primary malignant tissue to metastatic lesions within the same patient.¹⁸ EGFR expression was reported to be similar among vSCC samples with various FIGO stages.^{19,20} Two articles reported no difference in EGFR expression for HPV-dependent or HPV-independent samples.^{14,19} However, another article described stronger EGFR positivity for IHC mainly in HPV-independent vSCC samples and concluded that EGFR expression trends toward a negative correlation with P16 expression.¹⁵ EGFR expression in relation to lymph node metastases showed that increased expression in the primary vulvar malignancy was significantly associated with presence of lymph node metastases. Tissue of these lymph node metastases showed 88% EGFR expression.¹⁸

Expression in non-malignant vulvar tissue – One study reported EGFR expression in some basal cells in 40% of healthy vulvar tissue, in highly dysplastic cells in 40% of the VIN III and in many neoplastic cells in 80% of

vulvar condylomata acuminata.²¹ These data are consistent with another study wherein 26 out of 61 (43%) healthy vulvar tissue samples stained positive for EGFR.¹⁸ Identical to expression patterns in normal skin, receptor expression was confined to the basal and parabasal keratinocytes and was lost as the cells migrated upward toward the surface of the epithelium. No tumor to healthy ratios for EGFR have been described.

Clinical tracers – A variety of anti-EGFR drugs are currently FDA approved or tested in clinical trials. Moreover, humanized anti-EGFR monoclonal antibodies as panitumumab and cetuximab conjugated to a fluorophore (IRDye800CW) are being tested in several clinical studies for FGS purposes in e.g. head and neck squamous cell carcinomas (HNSCC) and oropharyngeal squamous cell carcinomas (OSCC). In a dose-escalation study with cetuximab labeled to near-infrared fluorophore (IRDye800CW) no adverse events higher than grade 2 were reported.³⁵

CD44V6

Physiological role – CD44 (HCAM, Pgp-1, Hermes antigen) is a cell-surface glycoprotein involved in cell-cell and cell-matrix adhesion and is widely expressed in a variety of human tissues. It interacts as a receptor with hyaluronic acid (HA) but can also bind with other ligands as collagens or matrix metalloproteinases (MMP's). These interactions trigger cell activation, motility and adhesion to other cells. Different isoforms of CD44 exist due to complex alternative splicing of transcripts of the CD44 gene. Various CD44 isoforms were broadly investigated in multiple tissue types and revealed CD44V6 expression to be mainly observed in normal human thyroid, breast, cervix, placenta and skin tissue.³⁶

Tumor expression – Aberrant expression of CD44 isoforms like CD44V6 in human tumors indicates a loss of splice control in malignant cells and has been associated with poor prognosis in human malignancies as breast and oropharyngeal cancer.^{23,37} The major role of isoform v6 involves cell migration and invasion and is thereby a metastatic determinant in aggressive stages of several human cancers, mainly in squamous cell carcinomas.³⁸ Patients expressing CD44V6 in vulvar cancer showed significantly poorer overall and relapse free survival compared with patients whose tumors lacked CD44V6 expression.^{24,25} In the 4 included scientific papers from this literature search, the average expression of CD44V6 on VSCC tissue was 59% (range 33-99%). Different staining patterns were used to score

CD44V6; even the same author used different cut-offs for the conducted studies.^{23,25} Two studies concluded CD44V6 expression not to be correlated to FIGO stage, tumor grade, PTNM classification, histologic grade or type of treatment.^{23,24} One study described CD44V6 staining patterns in primary tumors compared to lymph node metastases and found no obvious differences.²⁴ CD44V6 expression in relation to HPV status was not described in the included scientific papers.

Table 2 Potential targets for tumor-specific imaging of vscC. Tumor markers are shown, followed by the number of included papers relating to this target based on the literature search. Each extracted biomarker is granted points based on ranked criteria; I) percentage expression, II) sample size, and III) *in vivo* application. Solitary patient trials are scored in the *in vivo* application category. EGFR-Epidermal Growth Factor Receptor, CD44V6-CD44 variant 6, GLUT1-Glucose transporter 1, MRP1 -Multidrug resistance-associated protein, MUC1-Mucine 1, CXCR-4-C-X-C chemokine receptor type 4, VEGF-A-Vascular endothelial growth factor A, CA IX-Carbonic anhydrase IX, SPARC M-Secreted protein acidic and cysteine-rich M, CCND1-Cyclin D1, BCRP-Breast cancer resistance protein.

Tumor marker	Expression		In vivo application		Sample size		Included papers	
	average %	score	yes/no	score	(n)	score	(n)	Author, year
EGFR	70	1	yes	2	747	2	11	Fons 2009, Palisoul 2017, Koncar 2017, Lee 2007, Woelber 2012, Oonk 2007, Dong 2015, Johnson 1997, de Melo 2014, Brustmann 2007, Wu 2001
CD44V6	59*	1*	no	0	249	2	4	Fons 2007, Tempfer 1996, Hefler 2002, Tempfer 1998
GLUT1	68	1	no	0	166	2	3	Van de Nieuwenhof 2010, Li 2012, Mayer 2014
MRP1	78	1	no	0	79	2	2	Palisoul 2017, Koncar 2017
MUC1	81	1	no	0	30	1	1	Wu 2000
CXCR-4	68	1	no	0	22	1	1	Shiozaki 2013
VEGF-A	45	0	yes	2	100	1	3	Fons 2007, Li 2012, Obermair 1996
CD34	58	0	no	0	158	2	1	Dhokal 2013
CA IX	52	0	no	0	25	1	1	Li 2012
SPARC M	49	0	no	0	35	1	1	Koncar 2017
CCND1	47	0	no	0	131	1	1	Woelber 2012
BCRP	44	0	no	0	25	1	1	Palisoul 2017

* Borderline value, investigators decided to include this target based on the number of included papers and the total sample size

Expression in non-malignant vulvar tissue – None of the included articles has examined the expression of CD44V6 in healthy vulvar or dysplastic tissue.

Clinical tracers – Several peptides³⁹ and antibodies⁴⁰ have shown potency in CD44V6-targeting. For example, the humanized monoclonal anti-CD44V6 antibody bivatuzumab was shown to be safe in clinical trials and reliably visualized HNSCC lesions by nuclear imaging in humans.⁴¹ Thereafter, bivatuzumab was conjugated with both a near-infrared fluorescent dye (IRDye800CW) and a radioactive label (Indium-111) to perform dual-modality imaging in a HNSCC xenograft mice-model. Bivatuzumab accurately detected human HNSCC xenografts in mice and showed CD44V6 to be a suitable target *in vivo*.⁴²

GLUT1

Physiological role – Glucose transporter 1 (GLUT1, solute carrier family 2, facilitated glucose transporter member 1/SLC2A1) is encoded by the SLC2A1 gene. This uniporter protein is located in the cell membrane and facilitates the transport of glucose into the cell. It is widely expressed on placental tissue, red blood cells and normal capillaries of the brain, consistently with the high uptake of glucose in these cells.⁴³

Tumor expression – Increased glucose intake is also seen after malignant transformation of tissue triggered by hypoxia-induced gene expression.⁴⁴ VSCC is a solid tumor with such a glycolytic phenotype. GLUT1 expression was analyzed in 3 studies with a total sample size of 166 and was on average expressed in 68% (range 50-100%) of the VSCC samples. In general a diffuse staining of a large tumor area was observed, with a focally increased staining intensity, both cytoplasmic and membranous. Less differentiated tumors demonstrated lower GLUT1 expression levels. In several cases, GLUT1 expression was observed directly adjacent to a blood vessel/vascularized tumor stroma. However, the pattern of GLUT1 clearly indicated that a large part of its expression is presumably unrelated to hypoxia. One study investigating increased GLUT1 expression in relation to primary tumor characteristics as differentiation grade, FIGO stage or recurrences found no significant associations.²⁶ In the included scientific papers, GLUT1 expression in relation to HPV status and staining patterns in metastases was not described.

Expression in non-malignant vulvar tissue – Healthy vulvar tissue showed weak staining expressed in basal cells and prickle cells.^{27,28} One study described GLUT1 expression in dysplastic tissue to be comparable to the

observed low expression in healthy vulvar tissue,²⁸ while another study reported expression levels of dysplastic tissue to be more comparable to up-regulated expression as seen in VSCC tissue.²⁷

Clinical tracers – Up to now, no clinical studies have been performed with GLUT1 binding tracers. One pre-clinical study showed that a monoclonal GLUT1 antibody conjugated to iron oxide nanoparticles could effectively target GLUT1 positive tumor cells in infantile hemangioma using MRI.⁴⁵ But, being a glucose channel, GLUT1 targeting is more easily established by determining the accumulation of labelled glucose into tumor cells. Metabolic PET scanning with 18F-fluoro-deoxy-glucose (FDG) makes use of this principle and is widely used in the clinic for tumor imaging, including nodal staging in vulvar cancer.⁴⁶ A near-infrared version, IRDye800CW 2-DG, has been developed and showed specificity in several tumor models in mice, but these data are not yet confirmed in a clinical study.⁴⁷

MRP1

Physiological role – Multidrug resistance-associated protein 1, MRP1 (GS-X), is a protein that in humans is encoded by the ABCB1 gene. MRP1 is a member of the ATP-binding cassette transporters. This type of protein transports molecules across extra- and intracellular membranes. It has been speculated that MRP1 protects against carcinogens by preventing them from entering epithelial cells and is therefore ubiquitously expressed in almost all human tissues.⁴⁸ This transporter may therefore play a role in disrupting optimal cytotoxic agent efficacy by its capacity to mediate efflux of drugs.⁴⁹

Tumor expression – Overexpression of MRP1 is known to occur in cancers as neuroblastoma, breast, and prostate,⁵⁰ but little is known about the involvement in VSCC. MRP1 expression has been tested in two studies with a total of 79 VSCC samples included, showing 80% expression on average (range 77-82%). One study described expression of MRP1 in primary (26/34 samples, 77%) compared to metastatic alteration (22/28 samples, 79%), including metastatic lymph nodes and other distant metastases.¹² MRP1 expression in relation to other tumor characteristics such as FIGO stage or HPV-status have not been described.

Expression in non-malignant vulvar tissue – None of the included articles has examined the expression of MRP1 in healthy vulvar or dysplastic tissue.

Clinical tracers – To our knowledge, no clinical studies have been performed with MRP1 binding tracers. Pre-clinical research on inhibition of

MRP1-mediated transport to avoid multidrug resistance showed that mifepristone, doramapimod and celecoxib are potential inhibitors of MRP1 efflux.⁵⁰ Knowing that these small molecules show high specificity for MRP1, indicates their potential for tumor-specific tracer. Furthermore, a small recombinant scFv antibody directed to an extracellular epitope of the MRP1 in viable malignant cells was isolated. These small Fv-based recombinant antibodies possess superior tumor penetration capabilities and may possibly be used to selectively target drugs or tumor cells expressing MRP1.⁵¹ As for GLUT1, MRP1 targeting is more easily established by determining the cellular uptake of a non-binding tracer selectively passing MRP1 transporters into tumor cells. These tracers could be potential for imaging of MRP1 over-expressing tissues. MRP1 tracers are tested *in vitro* for different application, as for instance to study multidrug resistance.⁵²

MUC1

Physiological role – Mucine 1 (MUC1) is a membrane-bound protein belonging to the mucin family. This protein is O-glycosylated, plays a role in intracellular signaling and is critically important for the formation of a protective mucous barrier on epithelial surfaces. This protein is normally expressed on the apical surface of epithelial cells of mucosal surfaces as stomach and pancreas.⁵³

Tumor expression – Overexpression and changes in glycosylation are associated with carcinogenic development. The one study reporting on MUC1 expression in VSCC tested three monoclonal antibodies (MA695, CA15-3 and DF3) on vulvar tissues. These showed on average positive MUC1 expression of 81% (100%, 84% and 60% for Ma695, CA15-3 and DF3, respectively) in 30 VSCC samples tested. Increased MUC1 expression was related to the degree of differentiation of VSCC, prevalence of expression increased gradually from well through moderately to poorly differentiated VSCC. The prevalence and intensity of MUC1 expression was tested in 15 of the 30 VSCC samples by Ma695, and found to be higher in HPV-negative (48%, 13/15 samples) compared to HPV-positive tissues (8%, 2/15 samples). There were no significant associations between MUC1 expression and clinical stage or lymph node metastases in VSCC.²⁹

Expression in non-malignant vulvar tissue – MUC1 expression by Ma695 in VSCC was higher than the expression in VIN III, HPV-independent VIN III (4/5) and HPV-dependent VIN III (0/1). Both HPV-independent VIN I-II (n=4),

HPV-dependent VIN I-II (n=6), HPV-dependent vulvar condylomata acuminata (n=10) and healthy vulvar tissue (n=5) did not stain positive for MUC1 according to one study.²⁹

Clinical tracers – Due to its overexpression in several other cancers, MUC1 has emerged as a potential target for cancer therapy.⁵⁴ Monoclonal antibody development has historically been hampered by the abundant presence of aberrant glycosylation of MUC1 on tumor cells. The humanized IgG1 antibody (PankoMab-GEX) is directed against a glycol-epitope and has been shown to be safe, well tolerated, and promising for anti-tumor activity, suggesting a possible use as imaging tracer.⁵⁵ Mouse studies with another MUC1 antibody showed selectivity for ovarian cancer MR imaging.⁵⁶ Other, non-antibody based tracers like peptides and aptamers specifically binding MUC1 for imaging applications are under development. These ligands are relatively easy and cheaper to produce than antibodies, with low toxicity and immunoreactivity. A disadvantage for fluorescent based imaging might be the rapid systemic clearance resulting in a too short circulation half-life. It was shown that aptamers directed against the mucin 1 (MUC1) antigen, demonstrated high specificity and uniform penetration in tumor xenografts.⁵⁷

CXCR-4

Physiological role – C-X-C chemokine receptor type 4 (CXCR-4, fusin, CD184) is a specific receptor for stromal cell-derived factor-1. This factor is endowed with potent chemotactic activity for lymphocytes. CXCR-4 is located on the surface of the (tumor)cell membrane and acts with the CD4 protein to support HIV entering into cells.

Tumor expression – CXCR-4 is known to be overexpressed in at least 23 types of cancer, including breast cancer and prostate cancer.⁵⁸ The only study including CXCR-4 in VSCC showed 68% expression in 22 tested samples.³⁰ Expression was mainly seen at the invasive front, at the invading tumor clusters in deep stroma and in lymph node metastases. The expression rates of CXCR-4 in primary tumors were shown to be similar in node-negative and node-positive disease. But at metastatic sites, the expression rate of CXCR-4 in node positive diseases was very high. CXCR-4 expression tended to be increased for higher FIGO stages (III-IV) compared to lower stages (I-II) although this was not statistically significant (P=0.08). Furthermore, expression was associated with poor disease prognosis but

was not an independent prognostic factor. HPV-status in relation to CXCR-4 expression was not described.³⁰

Expression in non-malignant vulvar tissue – No information is available on expression in healthy tissue. None of the intraepithelial lesions (n=7) stained positive for CXCR-4.³⁰

Clinical tracers – Antibodies, aptamers and peptides against CXCR-4 are extensively evaluated for molecular imaging purposes, with promising results.⁵⁹ An anti-CXCR-4 peptide conjugated to a NIR-dye was tested *in vivo* at mice bearing human osteosarcoma xenografts. This showed high NIR signal intensity within the CXCR-4-positive tumor and within CXCR-4 receptor-positive organs.⁶⁰ The T140 peptide antagonist for CXCR-4 was synthesized, containing fluorescent rhenium and technetium for fluorescence or SPECT dual modality imaging.⁶¹ The diagnostic performance of ⁶⁸Ga-Pentixafor, a recently introduced CXCR-4-directed PET tracer in a small cohort of breast cancer patients, showed that tumor detection was feasible but performed less than a glucose based ¹⁸F-FDG tracer.⁶² As CXCR-4 is also natively expressed in immune-related cells, background staining in these tissues must be taken into consideration when evaluating *in vivo* imaging results.⁵⁹

VEGF-A

Physiological role – Vascular endothelial growth factor A (VEGF-A) is a heparin binding glycoprotein that mainly interacts with the VEGF-R1 and-R2 receptors present on endothelial cell membranes and some cancer cells. VEGF-A is important for angiogenesis by induction of proliferation and migration of vascular endothelial cells.

Tumor expression – The protein is encoded by the VEGF-A gene and known to be upregulated in many, especially hypoxic, tumors.⁶³ Abnormal blood vessel formation can form if VEGF-A expression is upregulated or disrupted, leading to pathological angiogenesis. The three included scientific papers show an average VEGF-A expression of 45% in VSCC samples (range 25-70%). It is important to notice that one author observed membranous expression of VEGF-A in tumor cells,²² whereas others described the expression to be dominantly in the cytoplasm of epidermal prickle cells and tumor cells associated with micro vessels.^{27,31} One author reported no clinically significant correlation between VEGF-A expression in relation to the distribution of FIGO stage (p=0.58), histopathological stage (p=0.69), and histological

grade (p=0.09).³¹ HPV-status in relation to VEGF-A expression was not mentioned in any of the included articles.^{22,27,31}

Expression in non-malignant vulvar tissue – One author observed strong VEGF-A staining in 17% (2/12 samples) of healthy tissue and 70% (7/10 samples) of VIN tissue.²⁷ Other included authors did not describe VEGF-A expression in non-malignant tissue.

Clinical tracers – VEGF-A is relatively well investigated in clinical trials for tumor imaging purposes in various cancer types. For instance, the therapeutic antibody bevacizumab (anti-VEGF) is being tested in various clinical feasibility trials (phase 1 and 2) for detection of tumors over-expressing VEGF-A.⁶ Fluorescence imaging with bevacizumab labelled to IRDye800CW enabled in-situ detection of additional malignant lesions in peritoneal carcinomatosis of colorectal origin.⁶⁴ Additional studies with fluorescently labeled bevacizumab are planned in for instance endometriosis (NCT02975219). In addition, ranibizumab is an FDA approved humanized monoclonal antibody with potential for targeting of VEGF-A as well, however more expensive compared to bevacizumab.

Discussion

In this systematic review, we provide an overview of tumor-specific biomarkers as potential candidates for tumor-specific imaging in VSCC patients. Seven potential targets were identified from the literature, including EGFR, CD44V6, GLUT1, MRP1, MUC1, CXCR-4 and VEGF-A.

EGFR was the most frequently evaluated biomarker in VSCC, and showed an expression in 70% of the 747 tested samples. Based on the availability of FDA approved anti-EGFR antibodies and the knowledge obtained from previously executed clinical trials, targeted imaging of VSCC with use of EGFR has high potential, although the relatively high expression found in healthy vulvar tissue is a major concern.²¹ The expression of VEGF-A was lower with 45% of the 100 samples tested, however, this target could also be easily used in a clinical setting because of the availability of FDA approved antibodies. Research in the field of CD44V6 is mainly performed in HNSCC, which has two different pathophysiological pathways, similar to VSCC (via a non-viral or an HPV-driven oncogenic pathway). Therefore, the concept tested on this target could easily be translated to application in VSCC. GLUT1 shows a relatively high expression in VSCC compared to healthy tissue. MRP1 seems to

have less potency as a tracer, since this protein is ubiquitously expressed in almost all healthy tissues. MUC1 and CXCR-4 expression were both evaluated in only one small study with 30 and 22 samples, respectively.

This review is based on the available literature with respect to the expression of tumor-specific targets in vSCC. Although the analysis pinpoints several potential imaging targets, it should be emphasized that the studies from which the data are generated were not specifically designed to prospectively evaluate imaging targets. For such a purpose, these studies should be supplemented with more details on marker expression in relation to HPV-status, expression in precursor lesions and metastatic lymph node tissue, and most ideally in comparison with other vSCC-specific targets. The importance of the understanding and incorporation of these vSCC-specific details on marker expression in further research, will be explained in the following sections.

HPV-independent and HPV-dependent vulvar cancers represent two distinct types of vSCC and have different precursor lesions and clinical outcomes.² HPV status has not been examined in relation to target expression in most studies, except for EGFR and MUC1. These targets showed a higher expression in HPV-independent tissue samples compared to HPV-dependent samples. HPV infected cells are known to express the oncoproteins E6 and E7, however these are expressed in the cell nucleus and therefore seem not targetable for optical imaging. An HPV status dependent proteomics study of vulvar samples could elicit potential proteins expressed exclusively at either type. Considering HPV status during target selection could result in a more accurate and precise identification in both HPV-dependent and HPV-independent (pre)malignant vulvar lesions.

This knowledge about HPV-related expression could also be valuable for detection of precursor lesions vulvar HSIL and dVIN, as these lesions may sometimes be difficult to identify clinically and can progress to invasive vulvar cancer if left untreated. Unfortunately, information on expression in precursor lesions is mostly lacking for the listed biomarkers.

Tumor-specific imaging of lymph node metastases could also be used in the treatment for patients with vSCC. Lymph node metastases are considered one of the most important prognostic factor affecting disease-free and overall survival for vSCC patients.⁶⁵ Patients with early stage vSCC have a 25% risk of lymph node metastases at the time of diagnosis. Sentinel lymph node mapping, a non-tumor specific imaging technique, is used for

the detection of lymph node metastases in these patients.⁶⁶ The detection of lymph node metastases by targeted optical imaging could result in a further reduction of surgery-related morbidity. Most of the included studies reported on differences in expression in the primary tumor based on presence or absence of lymph node metastases. However, some studies reported on target expression in lymph node tissue: in 14 patients with lymph node metastases mean EGFR expression was 88% versus 65% in the primary tumor,¹⁸ CXCR-4 expression was seen in 100% of the lymph node metastases (n=4)³⁰ and in all cases in which the primary tumor stained positive for CD44V6 (3/10) a positive CD44V6 staining in the respective lymph node metastases was ascertained. This data could be useful in targeted detection of these nodes.²⁴

Other candidates for tumor-specific imaging in vSCC could be tumor-specific targets that are identified in OSCC or HNSCC, such as UPAR. Boonstra et al described the applicability of an UPAR specific multimodal tracer in an oral cancer model, combining SPECT with intraoperative guidance.⁶⁷ In addition, the use of photodynamic therapy, with for instance 5-ALA, that showed great potential for both diagnosis and treatment of premalignant vulvar lesions.^{68,69} Proteomics or surfaceome studies could identify new and specific vSCC and precursor targets. Until now, these type of studies are lacking in vulvar (pre)cancers.

This review has several limitations. First, the set of potential biomarkers is based on general tumor marker expression, without discriminating for vSCC-specific hallmarks as HPV-status. Second, only 22 studies could be included verifying expression of a small number of vulvar samples. Furthermore, the evaluation of targets was performed using different scoring systems, yielding results that are difficult to compare with wide ranges of expression. In addition, no tumor-to-healthy cell ratio could be estimated for the selected biomarkers.

Future studies should include the immunohistochemical analysis of potential targets in vSCC and its precursors. Cohorts should at least include HPV-independent and HPV-dependent vSCC samples and precursor lesions, healthy vulvar tissue samples and preferably tissue of respective lymph node metastases. It is desirable that two antibodies targeting the same biomarker will be used to test differences in sensitivity. Afterwards, cell line-based research should be executed to validate a biomarkers potency as tumor-specific target for vSCC, whereafter an antibody or peptide

conjugated to a fluorophore could be tested in vitro and in a tumor mouse model. Eventually, these findings might have clinical implications in terms of the development of a vSCC-specific probe for the safe and specific real-time detection of occult tumor lesions.

Conclusions

Based on the current literature, we identified seven biomarkers as potential targets for vSCC-specific molecular imaging. This overview can be used as a first step towards the development of a structured approach of tumor-visualization in patients with vSCC, which could be used for pre-surgical diagnosis and real-time and precise localization of vulvar cancer.

Figure 1 Optical imaging using Fluorescent Guided Surgery (FGS). A) An example of an imaging probe used for optical imaging, which consists of a fluorophore (contrast label) conjugated to an antibody (imaging probe). B) Schematic illustration of a tumor cell and a healthy cell expressing different biomarkers (pink, orange or blue receptors/proteins). The imaging probe is able to bind to the overexpressed biomarker of interest on the tumor cell (pink receptor). The healthy cell does not express this particular biomarker and stays unstained. Using a proper imaging modality, the tumor cell expressing green fluorescence light can be distinguished from the healthy cell.

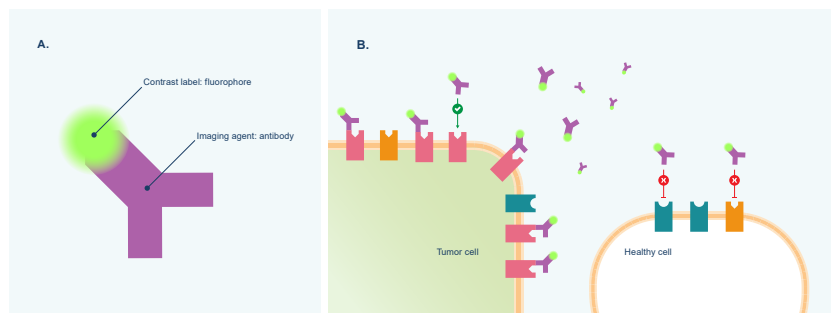
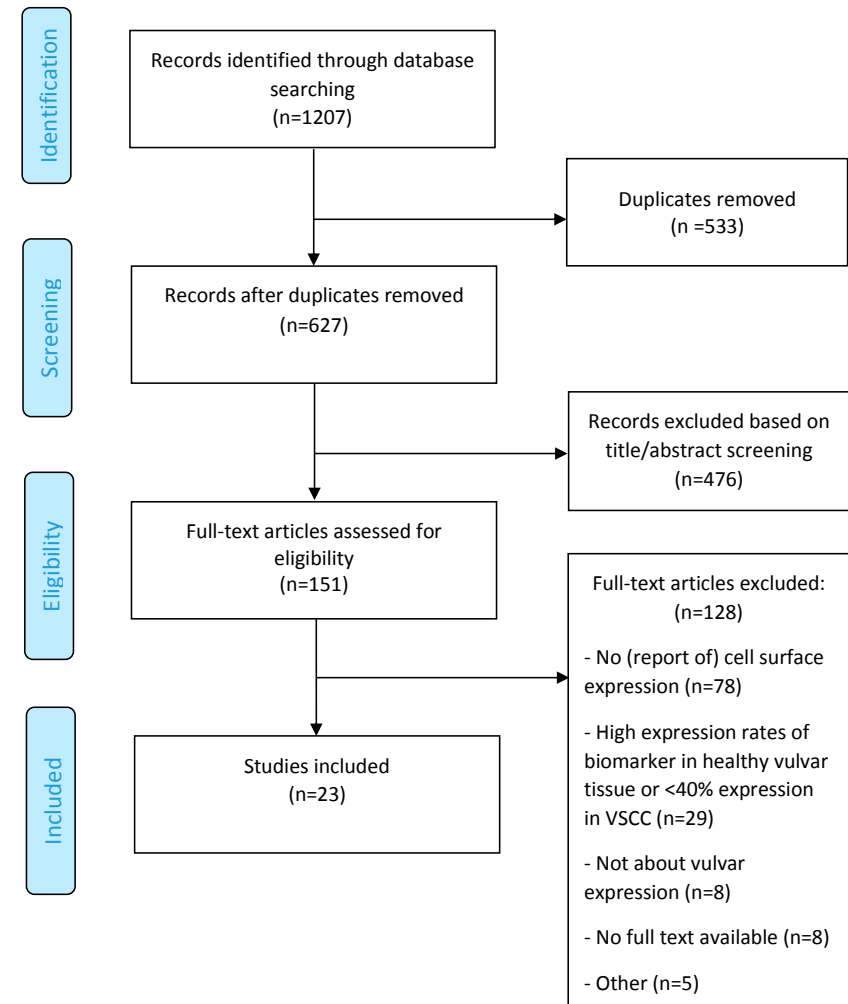


Figure 2 PRISMA flow diagram of literature search and selection process.



REFERENCES

- 1 Cancer Stat Facts: Vulvar Cancer, <https://seer.cancer.gov/statfacts/html/vulva.html>. 2019, assessed June 2019).
- 2 S. de Sanjose, L. Alemany, J. Ordi, S. Tous, M. Alejo, S.M. Bigby, E.A. Joura, P. Maldonado, J. Laco, et al., Worldwide human papillomavirus genotype attribution in over 2000 cases of intraepithelial and invasive lesions of the vulva, *Eur J Cancer* 49(16) (2013) 3450-61.
- 3 N.C. Te Grootenhuys, A.W. Pouwer, G.H. de Bock, H. Hollema, J. Bulten, A.G.J. van der Zee, J.A. de Hullu, M.H.M. Oonk, Prognostic factors for local recurrence of squamous cell carcinoma of the vulva: A systematic review, *Gynecol Oncol* 148(3) (2018) 622-31.
- 4 L.S. Nooij, F.A. Brand, K.N. Gaarenstroom, C.L. Creutzberg, J.A. de Hullu, M.I. van Poelgeest, Risk factors and treatment for recurrent vulvar squamous cell carcinoma, *Crit Rev Oncol Hematol* 106 (2016) 1-13.
- 5 C. Martelli, A. Lo Dico, C. Diceglie, G. Lucignani, L. Ottobri, Optical imaging probes in oncology, *Oncotarget* 7(30) (2016) 48753-87.
- 6 S. Hernot, L. van Manen, P. Debie, J.S.D. Mieog, A.L. Vahrmeijer, Latest developments in molecular tracers for fluorescence image-guided cancer surgery, *The Lancet Oncology* 20(7) (2019) e354-e367.
- 7 M.C. Boonstra, S.W. de Geus, H.A. Prevoo, L.J. Hawinkels, C.J. van de Velde, P.J. Kuppen, A.L. Vahrmeijer, C.F. Sier, Selecting Targets for Tumor Imaging: An Overview of Cancer-Associated Membrane Proteins, *Biomarkers in cancer* 8 (2016) 119-33.
- 8 M. van Oosten, L.M. Crane, J. Bart, F.W. van Leeuwen, G.M. van Dam, Selecting Potential Targetable Biomarkers for Imaging Purposes in Colorectal Cancer Using TArget Selection Criteria (TASC): A Novel Target Identification Tool, *Transl Oncol* 4(2) (2011) 71-82.
- 9 D. Moher, L. Shamseer, M. Clarke, D. Ghersi, A. Liberati, M. Petticrew, P. Shekelle, L.A. Stewart, Preferred reporting items for systematic review and meta-analysis protocols (PRISMA-P) 2015 statement, *Systematic reviews* 4 (2015) 1.
- 10 S.E. Bosma, P.B. van Driel, P.C. Hogendoorn, P.S. Dijkstra, C.F. Sier, Introducing fluorescence guided surgery into orthopedic oncology: A systematic review of candidate protein targets for Ewing sarcoma, *J Surg Oncol* 118(6) (2018) 906-14.
- 11 G. Fons, d. van, V. M. Burger, K.F. ten, Validation of tissue microarray technology in vulvar cancer, *Int J Gynecol Pathol* 28(1) (2009) 76-82.
- 12 M.L. Palisoul, M.M. Mullen, R. Feldman, P.H. Thaker, Identification of molecular targets in vulvar cancers, *Gynecol Oncol* 146(2) (2017) 305-13.
- 13 R.F. Koncar, R. Feldman, E.M. Bahassi, S.N. Hashemi, Comparative molecular profiling of HPV-induced squamous cell carcinomas, *Cancer Med* 6(7) (2017) 1673-85.
- 14 T.S. Lee, Y.T. Jeon, J.W. Kim, J.K. Won, N.H. Park, I.A. Park, Y.S. Juhn, S.B. Kang, H.P. Lee, Y.S. Song, Increased cyclooxygenase-2 expression associated with inflammatory cellular infiltration in elderly patients with vulvar cancer, *Ann N Y Acad Sci* 1095 (2007) 143-53.
- 15 L. Woelber, S. Hess, H. Bohlken, P. Tennstedt, C. Eulenburger, R. Simon, F. Giesecking, F. Jaenicke, S. Mahner, M. Choschzick EGFR gene copy number increase in vulvar carcinomas is linked with poor clinical outcome, *J Clin Pathol* 65(2) (2012) 133-9.
- 16 M.H. Oonk, G.H. de Bock, D.J. van der Veen, K.A. Ten Hoor, J.A. de Hullu, H. Hollema, A.G. van der Zee, EGFR expression is associated with groin node metastases in vulvar cancer, but does not improve their prediction, *Gynecol Oncol* 104(1) (2007) 109-13.
- 17 F. Dong, S. Kojiro, D.R. Borger, W.B. Growdon, E. Oliva, Squamous Cell Carcinoma of the Vulva: A Subclassification of 97 Cases by Clinicopathologic, Immunohistochemical, and Molecular Features (P16, P53 and EGFR), *Am J Surg Pathol* 39(8) (2015) 1045-53.
- 18 G.A. Johnson, R. Mannel, M. Khalifa, J.L. Walker, M. Wren, K.W. Min, D.M. Benbrook, Epidermal growth factor receptor in vulvar malignancies and its relationship to metastasis and patient survival, *Gynecol Oncol* 65(3) (1997) 425-9.
- 19 M.B. de Melo, A.M. Fontes, A.M. Lavorato-Rocha, I.S. Rodrigues, B.L. de, G. Baiocchi, M.M. Stiepcich, F.A. Soares, R.M. Rocha, EGFR expression in vulvar cancer: clinical implications and tumor heterogeneity, *Hum Pathol* 45(5) (2014) 917-25.
- 20 H. Brustmann, Epidermal growth factor receptor is involved in the development of an invasive phenotype in vulvar squamous lesions, but is not related to MIB-1 immunoreactivity, *Int J Gynecol Pathol* 26(4) (2007) 481-9.
- 21 X. Wu, Y. Xin, J. Yao, K. Hasui, S. Tsuyama, S. Yonezawa, F. Murata, Expression of epithelial growth factor receptor and its two ligands, transforming growth factor-alpha and epithelial growth factor, in normal and neoplastic squamous cells in the vulva: an immunohistochemical study, *Med Electron Microsc* 34(3) (2001) 179-84.
- 22 G. Fons, M.P. Burger, F.J. ten Kate, d. van, V, Identification of potential prognostic markers for vulvar cancer using immunohistochemical staining of tissue microarrays, *Int J Gynecol Pathol* 26(2) (2007) 188-93.
- 23 C. Tempfer, G. Gitsch, G. Haeusler, A. Reinthaller, H. Koelbl, C. Kainz, Prognostic value of immunohistochemically detected CD44 expression in patients with carcinoma of the vulva, *Cancer* 78(2) (1996) 273-7.
- 24 L.A. Hefler, N. Concin, D. Mincham, J. Thompson, N.B. Swarte, M.A. van Eijkeren, D.M. Sie-Go, I. Hammond, A.J. McCartney, C.B. Tempfer, P. Speiser, The prognostic value of immunohistochemically detected CD44v3 and CD44V6 expression in patients with surgically staged vulvar carcinoma: a multicenter study, *Cancer* 94(1) (2002) 125-30.
- 25 C. Tempfer, G. Sliutz, G. Haeusler, P. Speiser, A. Reinthaller, G. Breitenecker, N. Vavra, C. Kainz, CD44v3 and v6 variant isoform expression correlates with poor prognosis in early-stage vulvar cancer, *Br J Cancer* 78(8) (1998) 1091-4.
- 26 H.P. van de Nieuwenhof, J.A. de Hullu, J.H. Kaanders, J. Bulten, L.F. Massuger, L.C. van Kempen, Hemoglobin level predicts outcome for vulvar cancer patients independent of GLUT-1 and CA-1x expression in tumor tissue, *Virchows Arch* 457(6) (2010) 693-703.
- 27 Y.Z. Li, S.L. Li, X. Li, L.J. Wang, J.L. Wang, J.W. Xu, Z.H. Wu, L. Gong, X.D. Zhang, Expression of endogenous hypoxia markers in vulvar squamous cell carcinoma, *Asian Pac J Cancer Prev* 13(8) (2012) 3675-80.
- 28 A. Mayer, M. Schmidt, A. Seeger, A.F. Serras, P. Vaupel, H. Schmidberger, GLUT-1 expression is largely unrelated to both hypoxia and the Warburg phenotype in squamous cell carcinomas of the vulva, *BMC Cancer* 14 (2014) 760.
- 29 X. Wu, J.F. Yao, Y. Xin, S. Tsuyama, S. Yonezawa, F. Murata, Expression of mucin 1 (MUC1) in benign, premalignant and malignant vulvar tumors, *Acta Histochem Cytoc* 33(4) (2000) 267-73.
- 30 T. Shiozaki, T. Tabata, N. Ma, T. Yamawaki, T. Motohashi, E. Kondo, K. Tanida, T. Okugawa, T. Ikeda, Association of CXCL12 chemokine receptor type 4 expression and clinicopathologic features in human vulvar cancer, *Int J Gynecol Cancer* 23(6) (2013) 1111-7.
- 31 A. Obermair, P. Kohlberger, D. Bancher-Todesca, C. Tempfer, G. Sliutz, S. Leodolter, A. Reinthaller, C. Kainz, G. Breitenecker, G. Gitsch, Influence of microvessel density and vascular permeability factor/vascular endothelial growth factor expression on prognosis in vulvar cancer, *Gynecol Oncol* 63(2) (1996) 204-9.
- 32 H.P. Dhakal, J.M. Nesland, M. Forsund, C.G. Trope, R. Holm, Primary tumor vascularity, HIF-1alpha and VEGF expression in vulvar squamous cell carcinomas: their relationships with clinicopathological characteristics and prognostic impact, *BMC Cancer* 13 (2013) 506.
- 33 X. Liu, P. Wang, C. Zhang, Z. Ma, Epidermal growth factor receptor (EGFR): A rising star in the era of precision medicine of lung cancer, *Oncotarget* 8(30) (2017) 50209-20.
- 34 S. Pastore, F. Mascia, V. Mariani, G. Girolomoni, The epidermal growth factor receptor system in skin repair and inflammation, *J Invest Dermatol* 128(6) (2008) 1365-74.
- 35 W.J. Rosenthal EL, de Boer E, et al., Safety and Tumor Specificity of Cetuximab-IRDye800 for Surgical Navigation in Head and Neck Cancer., *Clin Cancer Res.* (21(16)):3658-66. doi:10.1158/1078-0432.CCR-14-3284 (2015).
- 36 S.B. Fox, J. Fawcett, D.G. Jackson, I. Collins, K.C. Gatter, A.L. Harris, A. Gearing, D.L. Simmons, Normal human tissues, in addition to some tumors, express multiple different CD44 isoforms, *Cancer Res* 54(16) (1994) 4539-46.
- 37 L. Chai, H. Liu, Z. Zhang, F. Wang, Q. Wang, S. Zhou, S. Wang, CD44 expression is predictive of poor prognosis in pharyngolaryngeal cancer: systematic review and meta-analysis, *Tohoku J Exp Med* 232(1) (2014) 9-19.
- 38 M. Todaro, M. Gaggiani, V. Catalano, A. Benfante, F. Iovino, M. Biffoni, T. Apuzzo, I. Sperduti, S. Volpe, G. Cocorullo, G. Gulotta, F. Dieli, R. De Maria, G. Stassi, CD44V6 is a marker of constitutive and reprogrammed cancer stem cells driving colon cancer metastasis, *Cell stem cell* 14(3) (2014) 342-56.
- 39 S.M.P. Vadevoo, S. Gurung, F. Khan, M.E. Haque, G.R. Gunassekaran, L. Chi, U. Permpoon, B. Lee, Peptide-based targeted therapeutics and apoptosis imaging probes for cancer therapy, *Arch Pharmacol Res* 42(2) (2019) 150-8.
- 40 D. Spiegelberg, J. Nilvebrant, CD44V6-Targeted Imaging of Head and Neck Squamous Cell Carcinoma: Antibody-Based Approaches, *Contrast media & molecular imaging* 2017 (2017) 2709547.
- 41 J.W. Stroemer, J.C. Roos, M. Sproll, J.J. Quak, K.H. Heider, B.J. Wilhelm, J.A. Castelijns, R. Meyer, M.O. Kwakkelstein, G.B. Snow, G.R. Adolf, G.A. van Dongen, Safety and biodistribution of 99mTechnetium-labeled anti-CD44V6 monoclonal antibody B1WA 1 in head and neck cancer patients, *Clin Cancer Res* 6(8) (2000) 3046-55.
- 42 J. Odenthal, M. Rijpkema, D. Bos, E. Wagena, H. Croes, R. Grenman, O. Boerman, R. Takes, P. Friedl, Targeting CD44V6 for fluorescence-guided surgery in head and neck squamous cell carcinoma, *Scientific reports* 8(1) (2018) 10467.
- 43 A. Carruthers, J. DeZutter, A. Ganguly, S.U. Devaskar, Will the original glucose transporter isoform please stand up! *Am J Physiol Endocrinol Metab* 297(4) (2009) E836-48.
- 44 J. Wang, C. Ye, C. Chen, H. Xiong, B. Xie, J. Zhou, Y. Chen, S. Zheng, L. Wang, Glucose transporter GLUT1 expression and clinical outcome in solid tumors: a systematic review and meta-analysis, *Oncotarget* 8(10) (2017) 16875-86.
- 45 C.H. Sohn, S.P. Park, S.H. Choi, S.H. Park, S. Kim, L. Xu, S.H. Kim, J.A. Hur, J. Choi, T.H. Choi. MR1 molecular imaging using GLUT1 antibody-Fe3O4 nanoparticles in the hemangioma animal model for differentiating infantile hemangioma from vascular malformation, *Nanomed-Nanotechnol* 11(1) (2015) 127-35.
- 46 C. Crivellaro, P. Guglielmo, E. De Ponti, F. Elisei, L. Guerra, S. Magni, M. La Manna, G. Di Martino, C. Landoni, A. Buda, 18F-FDG PET/CT in preoperative staging of vulvar cancer patients: is it really effective? *Medicine* 96(38) (2017) e7943.
- 47 J.L. Kovar, W. Volcheck, E. Sevcik-Muraca, M.A. Simpson, D.M. Olive, Characterization and performance of a near-infrared 2-deoxyglucose optical imaging agent for mouse cancer models, *Anal Biochem* 384(2) (2009) 254-62.
- 48 J. Yin, J. Zhang, Multidrug resistance-associated protein 1 (MRP1/ABCC1) polymorphism: from discovery to clinical application, *Zhong Nan Da Xue Xue Bao Yi Xue Ban* 36(10) (2011) 927-38.
- 49 M. Munoz, M. Henderson, M. Haber, M. Norris, Role of the MRP1/ABCC1 multidrug transporter protein in cancer, *IUBMB Life* 59(12) (2007) 752-7.
- 50 A. Sampson, B.G. Peterson, K.W. Tan, S.H. Iram, Doxorubicin as a fluorescent reporter identifies novel

- MRP1 (ABCC1) inhibitors missed by calcein-based high content screening of anticancer agents, *Biomed Pharmacother* 118 (2019) 109289.
- 51 L. Binyamin, Y.G. Assaraf, M. Haus-Cohen, M. Stark, Y. Reiter, Targeting an extracellular epitope of the human multidrug resistance protein 1 (MRP1) in malignant cells with a novel recombinant single chain Fv antibody, *Int J Cancer* 110(6) (2004) 882-90.
- 52 C. Vanpouille, N. Le Jeune, D. Kryza, A. Clotagatide, M. Janier, F. Dubois, N. Perek, Influence of multidrug resistance on (18)F-FCH cellular uptake in a glioblastoma model, *Eur J Nucl Med Mol Imaging* 36(8) (2009) 1256-64.
- 53 P.E. Constantinou, B.P. Danysh, N. Dharmaraj, D.D. Carson, Transmembrane mucins as novel therapeutic targets, Expert review of endocrinology & metabolism 6(6) (2011) 835-848.
- 54 S. Nath, P. Mukherjee, MUC1: a multifaceted oncoprotein with a key role in cancer progression, *Trends Mol Med* 20(6) (2014) 332-42.
- 55 W. Fiedler, S. DeDosso, S. Cresta, J. Weidmann, A. Tessari, M. Salzberg, B. Dietrich, H. Baumeister, S. Goletz, L. Gianni, C. Sessa, A phase I study of PankoMab-GEX, a humanised glyco-optimised monoclonal antibody to a novel tumour-specific MUC1 glycopeptide epitope in patients with advanced carcinomas, *Eur J Cancer* 63 (2016) 55-63.
- 56 D. Shahbazi-Gahruei, M. Abdolahi, Detection of MUC1-expressing ovarian cancer by C595 monoclonal antibody-conjugated SPIONs using MR imaging, *Sci World J* (2013) 609151.
- 57 A.C. Perkins, S. Missailidis, Radiolabelled aptamers for tumour imaging and therapy, *The quarterly journal of nuclear medicine and molecular imaging : official publication of the Italian Association of Nuclear Medicine (AIMN) [and] the International Association of Radiopharmacology (IAR), [and] Section of the Society* 51(4) (2007) 292-6.
- 58 A. Muller, B. Homey, H. Soto, N. Ge, D. Catron, M.E. Buchanan, T. McClanahan, E. Murphy, W. Yuan, S.N. Wagner, J.L. Barrera, A. Mohar, E. Verastegui, A. Zlotnik, Involvement of chemokine receptors in breast cancer metastasis, *Nature* 410(6824) (2001) 50-6.
- 59 J. Kuil, T. Buckle, F.W. van Leeuwen, Imaging agents for the chemokine receptor 4 (CXCR4), *Chem Soc Rev* 41(15) (2012) 5239-61.
- 60 Y. Lin, Y. Lin, X. Lin, X. Sun, K. Luo, Combination of PET and CXCR4-Targeted Peptide Molecule Agents for Noninvasive Tumor Monitoring, *Journal of Cancer* 10(15) (2019) 3420-6.
- 61 W.L. Turnbull, L. Yu, E. Murrell, M. Milne, C.L. Charron, L.G. Luyt, A dual modality (99m)Tc/Re(i)-labelled T140 analogue for imaging of CXCR4 expression, *Organic & biomolecular chemistry* 17(3) (2019) 598-608.
- 62 T. Vag, K. Steiger, A. Rossmann, U. Keller, A. Noske, P. Herhaus, J. Ettl, M. Niemeyer, H.J. Wester, M. Schwaiger, PET imaging of chemokine receptor CXCR4 in patients with primary and recurrent breast carcinoma, *EJNMMI research* 8(1) (2018) 90.
- 63 H.L. Goel, A.M. Mercurio, VEGF targets the tumour cell, *Nature reviews. Cancer* 13(12) (2013) 871-82.
- 64 N.J. Harlaar, M. Koller, S.J. de Jongh, B.L. van Leeuwen, P.H. Hemmer, S. Kruijff, R.J. van Ginkel, L.B. Been, J.S. de Jong, G. Kats-Ugurlu, M.D. Linssen, A. Jorritsma-Smit, M. van Oosten, W.B. Nagengast, V. Ntziachristos, G.M. van Dam, Molecular fluorescence-guided surgery of peritoneal carcinomatosis of colorectal origin: a single-centre feasibility study, *The Lancet. Gastroenterology & hepatology* 1(4) (2016) 283-90.
- 65 G. Bogani, A. Cromi, M. Serati, S. Uccella, V.D. Donato, J. Casarin, E.D. Naro, F. Ghezzi, Predictors and Patterns of Local, Regional, and Distant Failure in Squamous Cell Carcinoma of the Vulva, *Am J Clin Oncol* 40(3) (2017) 235-40.
- 66 M.H. Oonk, H. Hollema, A.G. van der Zee, Sentinel node biopsy in vulvar cancer: Implications for staging, *Best Pract Res Clin Obstet Gynaecol* 29(6) (2015) 812-21.
- 67 M.C. Boonstra, P. Van Driel, S. Keereweer, H. Prevo, M.A. Stammes, V.M. Baart, C. Lowik, A.P. Mazar, C.J.H. van de Velde, A.L. Vahrmeijer, C.F.M. Sier, Preclinical uPAR-targeted multimodal imaging of locoregional oral cancer, *Oral Oncol* 66 (2017) 1-8.
- 68 S. Booth, D. Poole, K. Moghissi, Initial experience of the use of photodynamic therapy (PDT) in recurrent malignant and pre-malignant lesions of the vulva, *Photodiagn Photodyn* 3(3) (2006) 156-61.
- 69 L. Leufflen, A. Francois, J. Salleron, C. Barlier, G. Dolivet, F. Marchal, L. Bezdetnaya, Photodynamic diagnosis with methyl-5-aminolevulinic acid in squamous intraepithelial lesions of the vulva: Experimental research, *Photodiagn Photodyn* 13(5) (2018) e0196753.