



Universiteit
Leiden

The Netherlands

Defining optimal oncolytic virus treatment and diagnostics in high risk melanoma patients

Stahlie, E.H.A.

Citation

Stahlie, E. H. A. (2023, April 19). *Defining optimal oncolytic virus treatment and diagnostics in high risk melanoma patients*. Retrieved from <https://hdl.handle.net/1887/3594222>

Version: Publisher's Version

License: [Licence agreement concerning inclusion of doctoral thesis in the Institutional Repository of the University of Leiden](#)

Downloaded from: <https://hdl.handle.net/1887/3594222>

Note: To cite this publication please use the final published version (if applicable).



CHAPTER 5

False positive FDG uptake in melanoma patients treated with talimogene laherparepvec (T-VEC)

Evalyn E. A. P. Mulder
Emma H. A. Stahlie
Daniëlle Verver
Clara Lemstra
Lukas B. Been
Antien L. Mooyaart
Tessa Brabander
Erik Vegt
Frederik A. Verburg
Astrid A. M. van der Veldt
Cornelis Verhoef
Alexander C. J. van Akkooi
Dirk J. Grünhagen

Surgical Oncology 2021;124:1161–1165.

ABSTRACT

Talimogene laherparepvec (T-VEC) is a genetically modified herpes simplex virus-1-based oncolytic immunotherapy and has been approved for the local treatment of unresectable (stage IIIB/C and IVM1a) cutaneous melanoma. During T-VEC treatment, tumor response is often evaluated using [18F]2-fluoro-2-deoxy-D-glucose(FDG) positron emission tomography/computed tomography (PET/CT). In a Dutch cohort (n=173), almost one-third of patients developed new onset FDG uptake in uninjected locoregional lymph nodes during T-VEC. In 36 out of 53 (68%) patients with new nodal FDG uptake, nuclear medicine physicians classified this FDG uptake as 'suspected metastases' without clinical or pathological confirmation in the majority of patients. These false positive results indicate that new-onset FDG uptake in locoregional lymph nodes during T-VEC treatment does not necessarily reflect progressive disease, but may be associated with immune infiltration. In current clinical practice, physicians should be aware of the high false positive rate of FDG uptake during treatment with T-VEC in patients with melanoma. Therefore, pathological examination of lymph node lesions with new FDG uptake is recommended to differentiate between progressive disease and immune infiltration after treatment with T-VEC.

INTRODUCTION

Talimogene laherparepvec (T-VEC) is an oncolytic immunotherapy and has been approved for local treatment of unresectable (stage IIIB/C and IVM1a) cutaneous melanoma.^{1,2} After intralesional injection in (sub)cutaneous and/or nodal lesions, the genetically modified herpes simplex virus-1 selectively replicates in tumor cells and produces granulocyte-macrophage colony-stimulating factor.^{3,4} T-VEC promotes lysis and cell death, thereby inducing an antitumor immune response, which is local but can also be systemic.^{5,6} Since the introduction of T-VEC in the clinic, durable tumor responses have been described,⁷ and best overall response rates have been reported up to 89%.⁸ In addition to T-VEC, immune checkpoint inhibitors and targeted therapy have proven efficacy and have been approved for the treatment of unresectable and metastatic melanoma.⁹⁻¹¹ To adequately select patients for T-VEC, [18F]2-fluoro-2-deoxy-D-glucose (FDG) positron emission tomography/computed tomography (PET/CT) is usually performed to identify patients without distant metastases. As patients with unresectable stage III and IVM1a melanoma are at high risk of distant metastases, adequate response evaluation is essential to switch to other treatments in case of progressive disease during T-VEC. Since FDG-PET/CT has a high sensitivity for advanced melanoma,^{12,13} it is often applied for early detection of (distant) metastasis during treatment with T-VEC.¹⁴ In addition, FDG-PET/CT can guide the discontinuation of T-VEC since the complete metabolic response on FDG-PET/CT is indicative of a complete pathological response during T-VEC.¹⁴ On the other hand, the development of new FDG avid lesions suggests progressive disease, requiring another treatment strategy. However, tumor responses during immunomodulatory treatments are associated with development of immune infiltrates, which can also cause increased FDG uptake.^{12,13} False positive FDG uptake during T-VEC may result in treatment discontinuation. To evaluate this diagnostic dilemma in clinical practice, a study was performed to evaluate the false positive FDG uptake in locoregional lymph nodes in patients treated with T-VEC in three dedicated melanoma centers in The Netherlands.

MATERIALS AND METHODS

Consecutive patients treated with T-VEC were retrospectively selected in one of the following three Dutch melanoma centers: Netherlands Cancer Institute – Antoni van Leeuwenhoek, Erasmus MC Cancer Institute, and University Medical Center Groningen. In these centers, FDG-PET with (low dose) CT is performed every 3 – 6 months according to clinical practice during treatment with T-VEC. To limit detection of FDG uptake in response to T-VEC, FDG-PET/CT is preferably scheduled at 1 – 2 weeks after the last administration of T-VEC. In addition, visible and/or palpable lesions are usually evaluated clinically every 2 weeks during

T-VEC treatment. For this analysis, patients without distant metastases on FDG-PET/CT before initiation of T-VEC treatment were included. At baseline and after T-VEC treatment, the clinical reports of FDG-PET/CT, routinely made by experienced nuclear medicine physicians, were reviewed for new-onset FDG uptake in uninjected locoregional lymph nodes and changes in nodal size (short axis, in mm). New-onset FDG uptake was described by the nuclear medicine physicians as either “suspected metastases,” “probably reactive,” or “equivocal” (malignant or reactive). Pathological examination was performed to confirm progressive disease in lymph nodes with new-onset FDG uptake. Tissue was obtained through (core needle) biopsy, fine needle aspiration, or surgical excision. When pathological examination was not feasible or inconclusive, true lesion status of new-onset FDG uptake in locoregional lymph nodes was determined by routine follow-up, including physical examination and FDG-PET/CT. Newonset FDG uptake in uninjected locoregional lymph nodes was classified as false positive if pathological examination did not demonstrate malignant cells and/or FDG uptake disappeared spontaneously during follow-up.

RESULTS

Between December 2016 and August 2020, 238 patients with melanoma were treated with T-VEC and 173 patients underwent FDG-PET/CT at baseline and during treatment with T-VEC. In these 173 included patients, the median number of injected lesions was 4 (interquartile range [IQR] = 2 – 10) with a median amount of 2 ml per T-VEC treatment (IQR = 1–2 ml). After 3–12 months of T-VEC treatment, 53 out of 173 (31%) patients had new FDG uptake in uninjected locoregional lymph nodes nearby T-VEC injected (sub) cutaneous lesions. In the majority of these patients (n = 42, 79%), FDG uptake was not associated with malignancy (Table 1), but with immune infiltration. For new-onset FDG uptake, median nodal size was comparable between malignant (8.2mm [IQR = 7.7 – 10.1 mm]) and nonmalignant (9.9 mm [IQR = 8.0–11.0 mm]) FDG avid lesions. In 36 out of 53 patients (68%) with new-onset FDG uptake in locoregional lymph nodes, lesions were classified as “suspected metastases,” which was not confirmed by pathological examination or routine follow-up (median 18 months [IQR = 11 – 25 months]) in the majority of patients (27 out of 36 patients, 75%). For illustrative purposes, three patients with false positive FDG uptake in locoregional lymph nodes are shown in Figure 1.

	Patients with new nodal FDG uptake n=53	Classification of new nodal FDG uptake		
		Suspected metastases (n = 36)	Probably reactive (n = 10)	Equivocal (n = 7)
True positive (malignant)	11 (24%)	9 (25%)	1 (10%)	1 (14%)
Pathology	7			
Follow-up	4			
False positive (non-malignant)	42 (76%)	27 (75%)	9 (90%)	6 (86%)
Pathology	24			
Follow-up	18			

Table 1. Correlation of new-onset FDG uptake in locoregional lymph nodes in melanoma patients treated with T-VEC. FDG-PET/CT evaluation was performed in 173 patients. After 3–12 months of T-VEC treatment, 53 (31%) patients had new FDG uptake in uninjected locoregional lymph nodes nearby T-VEC injected (sub)cutaneous lesions. Abbreviations: FDG, [18F]2-fluoro-2-deoxy-D-glucose positron emission tomography; PET/CT, positron emission tomography/computed tomography; TVEC, talimogene laherparepvec.

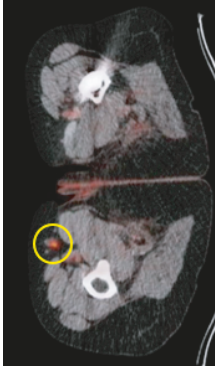
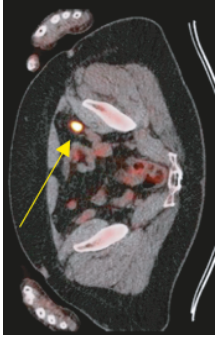

	Case 1	Case 2	Case 3
Age	65 years	71 years	76 years
Gender	Female	Female	Female
Disease stage (AJCC 7)	III	III	III
Site T-VEC treatment*	Right foot sole (acral melanoma, primary melanoma still in situ)	Left lower leg (subcutaneous)	Right upper leg (cutaneous)
Timing PET/CT** PET/CT images	6 months	3 months	3 months
			
Site FDG uptake	Inguinal lymph node (right)	Iliac lymph node (left)	Inguinal-iliac lymph nodes (right)
Classification	Suspected metastasis	Suspected metastasis	Suspected metastasis
Pathological examination & routine follow-up	FNA of inguinal lymph node: no malignant cells, only hyperplastic lymphoid cells (Melan A negative).	Follow-up: FDG uptake in lymph node was highly suspected for progressive disease and systemic treatment was considered. Prior to start of systemic treatment, CT was performed and showed a decrease in size of the lymph node. Local treatment with T-VEC (knee) was restarted until complete local pathological response was achieved, while FDG uptake in the lymph node disappeared after months.	FNA from lymph node with highest FDG uptake: no malignant cells, but reactive lymphoid cells, starry sky macrophages, and lymphoglandular bodies.
Outcome	Complete pathological response	Delayed pathological response	Complete pathological response
Follow-up (months)	8 months	10 months	3 months
	No evidence of disease	No evidence of disease	No evidence of disease

Figure 1. False positive FDG uptake in locoregional lymph nodes in three patients treated with T-VEC. Abbreviations: AJCC, American Joint Committee on Cancer; CT, Computed tomography; FDG-PET, [18F]2-fluoro-2-deoxy-D-glucose positron emission tomography; FNA, Fine needle aspiration; T-VEC, Talimogene laherparepvec.

*All three patients were only treated in (sub)cutaneous lesions, i.e., T-VEC was not injected into the (regional) lymph nodes.

** Months after first T-VEC treatment

DISCUSSION

This Dutch cohort shows that almost one-third of patients developed new-onset FDG uptake in uninjected locoregional lymph nodes during T-VEC, without pathological and/or clinical confirmation of progressive disease in the majority of patients. At pathological examination, false positive FDG uptake was associated with T-VEC-induced immune infiltration. In patients with advanced-stage melanoma, comparable observations have been described after isolated limb perfusion and treatment with immune checkpoint inhibitors.¹⁵⁻¹⁷ Immunomodulatory therapies, including T-VEC, boost the immune system to enhance an effective T-cell mediated antitumor response.¹⁸ Our findings indicate that new-onset FDG uptake in locoregional lymph nodes during T-VEC treatment occurs frequently and does not necessarily reflect progressive disease. According to the response evaluation criteria in solid tumors (RECIST) v1.1,¹⁹ lymph nodes < 10mm are considered benign. However, in our cohort, the vast majority of the FDG avid lymph nodes, both benign and malignant, were <10 mm. Therefore, RECIST cannot contribute to further characterization of FDG avid nodal lesions after T-VEC. Pathological examination of lymph node lesions with new FDG uptake is required to differentiate between progressive disease and immune infiltration before (dis)continuation of T-VEC and/or switch to other therapy. Prospective studies are needed to determine the diagnostic accuracy and clinical value of FDG-PET/CT for tumor response evaluation during treatment with T-VEC in melanoma patients.

CONCLUSION

In current clinical practice, physicians should be aware of the high rate of false positive FDG uptake in locoregional lymph nodes after treatment with T-VEC in patients with unresectable melanoma. To address this issue, it is recommended to obtain representative tissue.

REFERENCES

1. Andtbacka RH, Kaufman HL, Collichio F, et al. Talimogene Laherparepvec Improves Durable Response Rate in Patients With Advanced Melanoma. *J Clin Oncol* 2015;33:2780-8.
2. European Medicines Agency (EMA). CHMP summary of positive opinion for Imlygic. <http://www.ema.europa.eu>. Accessed: 1 Dec, 2020.
3. Senzer NN, Kafuman HL, Amatruda T, et al. Phase II clinical trial of a granulocyte-macrophage colony-stimulating factor-encoding, second-generation oncolytic herpesvirus in patients with unresectable metastatic melanoma. *J Clin Oncol* 2009;27:5763-71.
4. Hamid O, Hoffner B, Gasal E, et al. Oncolytic immunotherapy: unlocking the potential of viruses to help target cancer. *Cancer Immunol Immunother* 2017;66:1249-64.
5. Andtbacka RH, Ross M, Puzanov I, et al. Patterns of Clinical Response with Talimogene Laherparepvec (T-VEC) in Patients with Melanoma Treated in the OPTiM Phase III Clinical Trial. *Ann Surg Oncol* 2016;23:4169-77.
6. Thompson JF, Agarwala SS, Smithers BM, et al. Phase 2 Study of Intralesional PV-10 in Refractory Metastatic Melanoma. *Ann Surg Oncol* 2015;22:2135-42.
7. Andtbacka RH, Collichio F, Harrington KJ, et al. Final analyses of OPTiM: a randomized phase III trial of talimogene laherparepvec versus granulocyte-macrophage colony-stimulating factor in unresectable stage III-IV melanoma. *J Immunother Cancer* 2019;7:145.
8. Franke V, Berger DM, Klop WM, et al. High response rates for T-VEC in early metastatic melanoma (stage IIIB/C-IVM1a). *Int J Cancer* 2019;145:974-8.
9. Robert C, Grob JJ, Stroyakovskiy D, et al. Five-Year Outcomes with Dabrafenib plus Trametinib in Metastatic Melanoma. *N Engl J Med* 2019;381:626-36.
10. Hamid O, Robert C, Daud A, et al. Five-year survival outcomes for patients with advanced melanoma treated with pembrolizumab in KEYNOTE-001. *Ann Oncol* 2019;30:582-8.
11. Hodi FS, Chiarion-Sileni V, Gonzalez R, et al. Nivolumab plus ipilimumab or nivolumab alone versus ipilimumab alone in advanced melanoma (CheckMate 067): 4-year outcomes of a multicentre, randomised, phase 3 trial. *Lancet Oncol* 2018;19:1480-92.
12. Ayati N, Sadeghi R, Kiamanesh, et al. The value of (18)F-FDG PET/CT for predicting or monitoring immunotherapy response in patients with metastatic melanoma: a systematic review and meta-analysis. *Eur J Nucl Med Mol Imaging* 2020.
13. Reinhardt MJ, Joe AY, Jaeger U, et al. Diagnostic performance of whole body dual modality 18F-FDG PET/CT imaging for N- and M-staging of malignant melanoma: experience with 250 consecutive patients. *J Clin Oncol* 2006;24:1178-87.
14. Franke V, van der Hiel B, van de Wiel B, et al. Positron emission tomography/computed tomography evaluation of oncolytic virus therapy efficacy in melanoma. *Eur J Cancer* 2018;90:149-52.
15. Kong BY, Menzies AM, Saunders CA, et al. Residual FDG-PET metabolic activity in metastatic melanoma patients with prolonged response to anti-PD-1 therapy. *Pigment Cell Melanoma Res* 2016;29:572-7.
16. Somarouthu B, Lee SI, Urban T, et al. Immune-related tumour response assessment criteria: a comprehensive review. *Br J Radiol* 2018;91:20170457-.
17. Beasley GM, Parsons C, Broadwater G, et al. A multicenter prospective evaluation of the clinical utility of F-18 FDG-PET/CT in patients with AJCC stage IIIB or IIIC extremity melanoma. *Ann Surg* 2012;256:350-6.

18. Kwak JJ, Tirumani SH, van den Abbeele AD, et al. Cancer Immunotherapy: Imaging Assessment of Novel Treatment Response Patterns and Immune-related Adverse Events. *RadioGraphics* 2015;35:424-37.
19. Eisenhauer EA, Therasse P, Bogaerts J, et al. New response evaluation criteria in solid tumours: revised RECIST guideline (version 1.1). *Eur J Cancer* 2009, 45(2):228-247.