



Universiteit  
Leiden

The Netherlands

## **Fetal and neonatal alloimmune thrombocytopenia: the proof of the pudding is in the eating**

Vos, T.W. de

### **Citation**

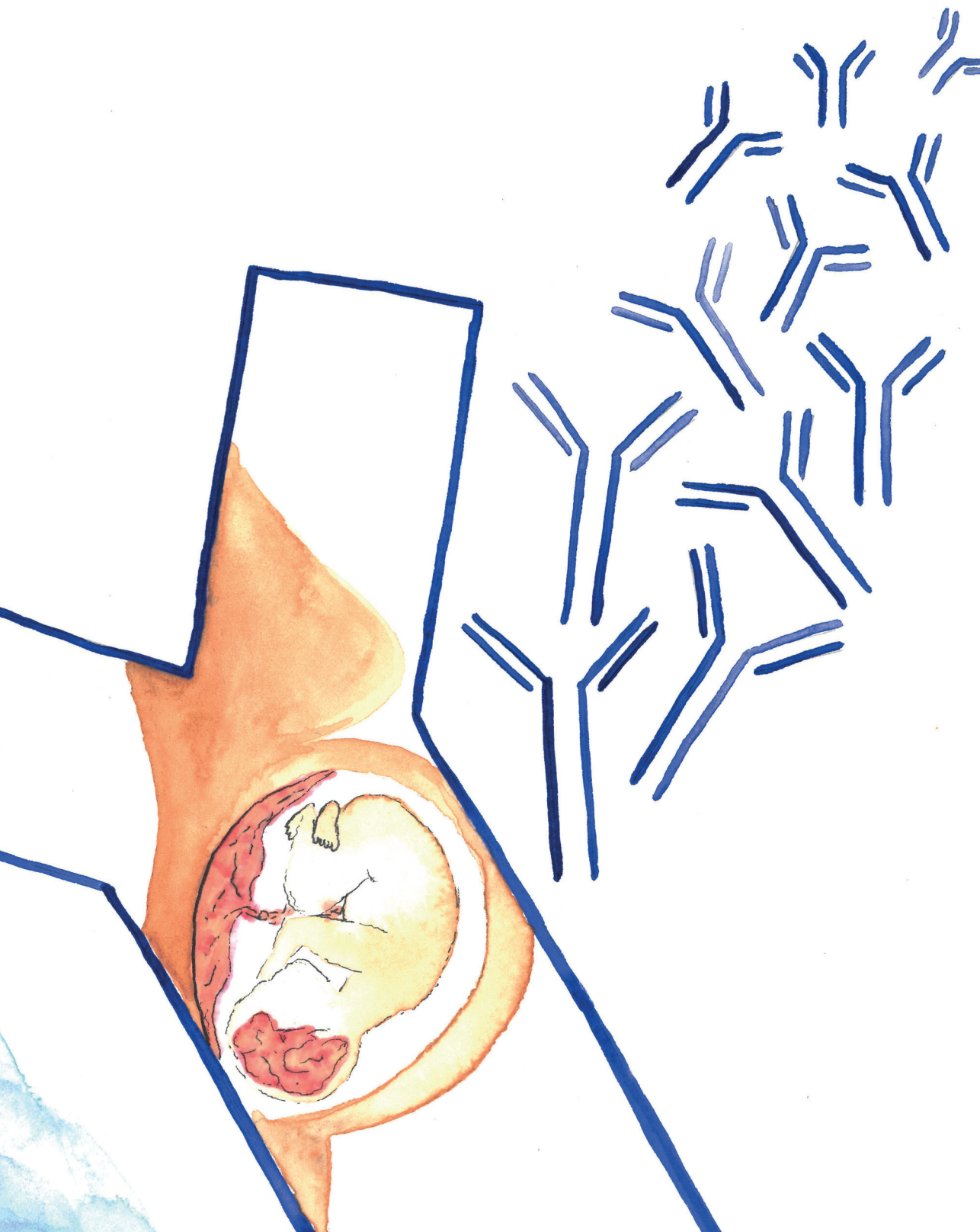
Vos, T. W. de. (2023, April 13). *Fetal and neonatal alloimmune thrombocytopenia: the proof of the pudding is in the eating*. Retrieved from <https://hdl.handle.net/1887/3593976>

Version: Publisher's Version

License: [Licence agreement concerning inclusion of doctoral thesis in the Institutional Repository of the University of Leiden](#)

Downloaded from: <https://hdl.handle.net/1887/3593976>

**Note:** To cite this publication please use the final published version (if applicable).



# CHAPTER 4

## **Placental complement activation in fetal and neonatal alloimmune thrombocytopenia: an observational study**

Thijs W. de Vos  
Dian Winkelhorst  
Hans J. Baelde  
Kyra L. Dijkstra  
Rianne D.M. van Bergen  
Lotte E. van der Meeren  
Peter G. K. Nikkels  
Leendert Porcelijn  
C. Ellen van der Schoot  
Gestur Vidarsson

Michael Eikmans  
Rick Kapur  
Carin van der Keur  
Leendert A. Trouw  
Dick Oepkes  
Enrico Lopriore  
Marie-Louise van der Hoorn  
Manon Bos  
Masja de Haas

## ABSTRACT

Fetal and neonatal alloimmune thrombocytopenia (FNAIT) is a disease that causes thrombocytopenia and a risk of bleeding in the (unborn) child that result from maternal alloantibodies directed against fetal, paternally inherited, human platelet antigens (HPA). It is hypothesized that these alloantibodies can also bind to the placenta, causing placental damage. This study aims to explore signs of antibody-mediated placental damage in FNAIT. We performed a retrospective study that included pregnant women, their newborns, and placentas. It comprised 23 FNAIT cases, of which nine were newly diagnosed (14 samples) and 14 were antenatally treated with intravenous immunoglobulin (IVIg) (21 samples), and 20 controls, of which 10 with anti-HLA-class I antibodies. Clinical information was collected from medical records. Placental samples were stained for complement activation (C1q, C4d, SC5b-9 and mannose-binding lectin) using immunohistochemistry. Histopathology was examined according to the Amsterdam criteria. A higher degree of C4d deposition was present in the newly diagnosed FNAIT cases (10/14 samples), as compared to the IVIg treated FNAIT cases (2/21 samples,  $P = 0.002$ ) and anti-HLA-negative controls (3/20 samples,  $P = 0.006$ ). A histopathological examination showed delayed maturation in four (44%) placentas in the newly diagnosed FNAIT cases, five (36%) in the IVIg treated FNAIT cases and one of the controls (NS). C4d deposition at the syncytiotrophoblast was present in combination with low-grade villitis of unknown etiology in three newly diagnosed FNAIT cases that were born SGA. We conclude that anti-HPA-1a antibodies bind to the placenta and that a higher degree of classical pathway-induced complement activation is present in placentas from pregnancies with untreated FNAIT. This may affect placental function and fetal growth.

## INTRODUCTION

Fetal and neonatal alloimmune thrombocytopenia (FNAIT) is the leading cause of thrombocytopenia and bleeding tendency in otherwise healthy and term-born infants. FNAIT is caused by maternal alloantibodies directed against paternally inherited human platelet antigens (HPA).<sup>1</sup> Immunoglobulin G (IgG) class alloantibodies cross the placenta and bind to fetal platelets, resulting in thrombocytopenia and risk of bleeding. Bleeding complications in FNAIT are often caused by HPA-1a specific alloantibodies and vary from minor skin bleedings to severe intracranial hemorrhages (ICH) leading to lifelong neurological impairment or death.<sup>2</sup> Administration of intravenous immune globulins (IVIg) to the mother during pregnancy can prevent the hemorrhagic complications due to FNAIT.<sup>3</sup> However, since FNAIT is predominantly diagnosed after birth, prenatal treatment can usually only be administered in subsequent pregnancies.

The HPA-1a/HPA-1b alloantigenic epitopes are formed due to a single nucleotide substitution (C29523T), resulting in a Leu33Pro amino acid polymorphism within the integrin  $\beta 3$  subunit. Platelets express high levels of HPA-1a at the integrin  $\beta 3$  on the fibrinogen receptor ( $\alpha 2\beta 3$ , glycoprotein IIb/IIIa, CD41/CD61) and at a much lower level on the vitronectin receptor ( $\alpha v\beta 3$ , CD51/CD61). Platelet-directed antibodies may lead to antibody-mediated destruction of sensitised cells, e.g. leading to thrombocytopenia, and also impair the function of these integrins.<sup>4-6</sup> Trophoblast cells and endothelial cells express high levels of the vitronectin receptor, and interference of HPA-1a antibodies with their cellular function is likely involved in the bleeding tendency.<sup>7</sup> In a Norwegian cohort study,<sup>8</sup> the presence of anti-HPA-1a in maternal serum was associated with a reduced birthweight in infants diagnosed with FNAIT, which was also reported in other cohorts.<sup>9, 10</sup> Furthermore, immune-induced placental dysfunction was observed in murine FNAIT models, in which the mice had high levels of anti- $\beta 3$  antibodies and showed fetal growth restriction (FGR) and miscarriages.<sup>11</sup> Yougbaré *et al.*<sup>12</sup> showed abnormal placental vascularisation and poor placental perfusion resulting in FGR in these mice.

Antibodies in pregnancies complicated by antiphospholipid syndrome or systemic lupus erythematosus (SLE) can also bind to trophoblast cells, which results in classical pathway complement activation.<sup>13</sup> In these pregnancies, complement activation is associated with adverse pregnancy outcomes, such as fetal loss and children born small for gestational age.<sup>14, 15</sup> On the basis of these observations, we hypothesized that placental classical route complement activation might also occur in FNAIT and could lead to placental dysfunction. The aim of this study was to explore the presence of classical route complement activation and histopathological abnormalities in placentas from FNAIT cases.

## MATERIALS AND METHODS

### STUDY COHORT AND PLACENTA COLLECTION

4 A total of 43 placentas were included in this study; they were categorized into four groups: newly diagnosed FNAIT cases (n = 9, Group 1), antenatally IVIg-treated FNAIT cases (n = 14, Group 2), and controls with and without anti-HLA class I antibodies (n = 10, Group 3 and n = 10 Group 4, respectively). Only FNAIT cases caused by anti-HPA-1a antibodies were included. Newly diagnosed FNAIT cases (Group 1) were identified upon diagnostic testing at Sanquin Diagnostics, Amsterdam, The Netherlands. Cases were selected from a cohort of 77 cases diagnosed between January 2006 and January 2017; 22% of the new-borns with newly diagnosed anti-HPA-1a mediated FNAIT were small for gestational age.<sup>9</sup> Pathology departments were contacted to request placenta material. All cases with available material were included. In total, nine placentas of newly diagnosed FNAIT cases were available and could be included in Group 1. These placentas had initially been evaluated for other clinical reasons: small for gestational age (SGA) (n = 3), fetal distress during delivery (n = 2), a previous mola pregnancy (n = 1), suspected abruptio placentae (n = 1), premature delivery (n = 1) and a suspected congenital infection (n = 1). Group 2 consisted of 14 placentas from pregnancies complicated by FNAIT of which mothers received IVIg treatment at the Leiden University Medical Center (LUMC). Cases were identified because they were included in a randomized trial comparing low dose IVIg (0.5 g/kg/week, n = 7, 10 samples) versus standard dose IVIg (1 g/kg/week, n = 7, 11 samples).<sup>16</sup>

Twenty controls were selected from a cohort of cases of uncomplicated pregnancies that resulted in the delivery of a healthy child at the obstetric department of the LUMC or in the affiliated hospitals in the region. Placentas were stored after informed consent for research purposes: furthermore storage of the placenta material, HLA typing, and HLA antibody screening took place for all these cases. Although the role of anti-HLA class I antibodies in FNAIT is the subject of scientific debate, anti-HLA class I reactive antibodies can bind to platelets, immune cells and endothelial cells in the placenta.<sup>17</sup> Ten controls were selected based on the presence of anti-HLA class I type antibodies and a new-born positive for the targeted antigens, these cases were categorized as Group 3. Ten controls were selected based on the absence of anti-HLA class I or II antibodies and placed in Group 4. All mothers in Group 3 and 4 were genotyped and were HPA-1a positive.

### CLINICAL DATA COLLECTION AND DEFINITIONS

Clinical data concerning obstetric and neonatal treatment were collected from the medical records. A low placental weight was defined as a weight below the 10th percentile.<sup>18</sup> Small for gestational age (SGA) was defined as a birthweight below the 10th percentile according to the Dutch reference curves for birthweight.<sup>19</sup> Clinical data collection was performed separately from laboratory experiments; data were de-identified and linked to a study number by an independent research nurse.

## ETHICS

Ethical approval was provided by the medical ethical committee Leiden-Delft-The Hague for cases by study protocol B18.033 and for the controls by protocol P13.084. Placentas and serum samples of control cases were collected after informed consent.

## HPA ANTIBODY DETECTION

FNAIT was diagnosed by the presence of fetal or neonatal thrombocytopenia and/or bleeding symptoms in presence of fetal-maternal HPA incompatibility and HPA alloantibodies. HPA incompatibility was confirmed by maternal, paternal and/or neonatal genotyping. HPA alloantibody screening was performed using PIFT (platelet immunofluorescence test) and MAIPA (monoclonal antibody immobilization of platelet antigens assay) as described by Porcelijn *et al.*<sup>20</sup>.

## HLA ANTIBODY DETECTION AND HLA TYPING

Maternal anti-HLA antibodies were detected and typed using the Luminex Single bead Antigen assay (Lifecodes, Immucor, Norcross, United States of America) for HLA class I and II at either the Department of Immunogenetics, Sanquin, Amsterdam (Group 1 and 2) or the Department of Immunology at the LUMC (Group 3 and 4). If HLA antibodies were present in the maternal serum, low-resolution genotyping was performed using PCR-SSP and sequence-based typing to determine whether or not the maternal HLA alloantibodies were child-specific.

## HISTOPATHOLOGY

Formalin-fixed paraffin-embedded (FFPE) tissues (one slide of the umbilical cord, one of the membranes, and at least two sections of normal placental parenchyma) were H&E stained according to standardized protocol.<sup>21</sup> Histopathology was reviewed according to the Amsterdam criteria by two experienced perinatal pathologists (PGKN and LEvdM). The pathologists were blinded to clinical information, except for gestational age.

## IMMUNOHISTOCHEMISTRY

The presence of complement proteins was investigated using immunohistochemistry for C1q, C4d, membrane attack complex (MAC, SC5b-9) and mannose-binding lectin (MBL). Detailed protocols are reported in Supplemental Table 2. In brief, sections were deparaffinized and antigen retrieval was performed. After blocking for endogenous peroxidase, the sections were incubated with the primary antibody. Binding of the primary antibody was visualized with the appropriate secondary antibody (Dako Envision+) and diaminobenzidine as a chromogen. Isotype specific controls were used as negative controls (Supplemental Table 2). Sections were counterstained with hematoxylin.

**QUANTIFICATION OF IMMUNOHISTOCHEMICAL STAINING**

The immunohistochemical staining was scored semi-quantitatively as either absent (<10%), focal (10% - 50%), or diffuse (>50%) by two blinded observers (TWdV and RDMvB). In case of discrepancy between the scores, consensus was reached in the presence of an independent blinded third researcher (MB). Examples for the semi-quantitative score can be found in Supplemental Figure 3.

**STATISTICAL ANALYSIS**

Data analysis was performed using IBM SPSS Statistics 25.0 (Chicago, IL, USA). Descriptive statistics were used to report clinical characteristics by proportions and medians with interquartile ranges. Quantitative clinical characteristics were compared by the Kruskal-Wallis analysis. Categorical parameters were compared by the Chi-square analysis or Fisher Exact Test as appropriate. An ordinal logistic regression model was used for the comparison of complement deposits in the placenta. This statistical model was chosen because in some FNAIT cases only one sample was available instead of two.



TABLE 1. Clinical characteristics

	Group 1 FNAIT cases Newly diagnosed n = 9	Group 2 FNAIT cases IVig-treated n = 14	Group 3 Controls anti-HLA I positive n = 10	Group 4 Controls anti-HLA I negative n = 10
<b>Maternal characteristics</b>				
Maternal age (years) – median (IQR)	31 (29 – 34)	33 (31 – 36)	33 (31 – 35)	33 (30 – 39)
Gravidity – median (IQR)	2 (1 – 2)	3 (2 – 4)	3 (2 – 3)	2 (1 – 4)
Parity – median (IQR)	0 (0 – 1)	1 (1 – 2)	1 (0 – 1)	1 (0 – 1)
Multiparous women – n (%)	6 (67%)	14 (100%)	9 (90%)	7 (70%)
Pre-eclampsia – n (%)	0	0	0	0
<b>Delivery</b>				
Spontaneous vaginal delivery – n (%)	1 (11%)	8 (57%)	4 (40%)	4 (40%)
CS fetal distress – n (%)	3 (33%)	1 (7%)	0	0
GA at delivery (weeks <sup>±days</sup> )** – median (IQR)	37 <sup>+1</sup> (33 <sup>+5</sup> – 40 <sup>+5</sup> )	38 <sup>+3</sup> (37 <sup>+2</sup> – 38 <sup>+6</sup> )	39 <sup>+1</sup> (39 <sup>+1</sup> – 40 <sup>+4</sup> )	37 <sup>+1</sup> (38 <sup>+4</sup> – 40 <sup>+2</sup> )
<b>Neonatal data</b>				
Sex (male) – n (%)	5 (56%)	7 (50%)	5 (50%)	5 (50%)
Birthweight (grams)** – median (IQR)	2405 (2099 – 3535)	3133 (2674 – 3493)	3700 (3319 – 3805)	3323 (3214 – 3814)
Small for gestational age* – n (%)	4 (44%)	1 (7%)	0	0
Skin bleeding only* – n (%)	4 (44%)	0	0	0
Intracranial hemorrhage* – n (%)	2 (22%)	1 (7%) <sup>‡</sup>	0	0
Perinatal asphyxia – n (%)	1 (11%)	0	0	0
Platelet count nadir (× 10 <sup>9</sup> /l)** – median (IQR)	17 (9 – 43)	64 (21 – 170)	NT	0
<b>HPA alloantibodies</b>				
Mother HPA-1a negative – n (%)	9 (100%)	14 (100%)	0	0
Fetus HPA-1a positive – n (%)	9 (100%)	14 (100%)	NT	NT
Antibodies directed against:			NT	NT
HPA-1a – n (%)	6 (67%)	14 (100%)		
HPA-1a and 3a – n (%)	1 (11%)			
HPA-1a and 5b – n (%)	2 (22%)			
Anti-HLA class I present fetus-specific † – n (%)	4 (57%), 2 missing	4 (44%), 5 missing	10 (100%)	0
<b>Placenta characteristics</b>				
Placenta weight (grams) – median (IQR)	460 (268 – 636)	500 (440 – 577)	572 (420 – 790)	610 (533 – 730)
Placenta weight < p10* – n (%)	4 (44%)	1 (7%)	0	0

\* Data show a statistically significant difference ( $P < 0.05$ ) when compared with the pooled controls by the Chi-Square test.

\*\* Data show a statically significant difference ( $P < 0.05$ ) when compared with the controls by Kruskal–Wallis analysis.

‡ Intracranial hemorrhage developed at 27 weeks' gestational age before administration of intravenous immune globulins to the mother was started.

† Assessed in 7/19/10 cases, missing values for 7 (16%) cases due to lack of serum/DNA.

¶ Assessed in 9/9/7/8 cases, missing values for 10 (23%) cases.

Abbreviations: FNAIT, fetal neonatal alloimmune thrombocytopenia; IVig, intravenous immune globulins; HLA, human leukocyte antigen; CS, caesarean section; GA, gestational age; l, liter; HPA, human platelet antigen p, percentile.

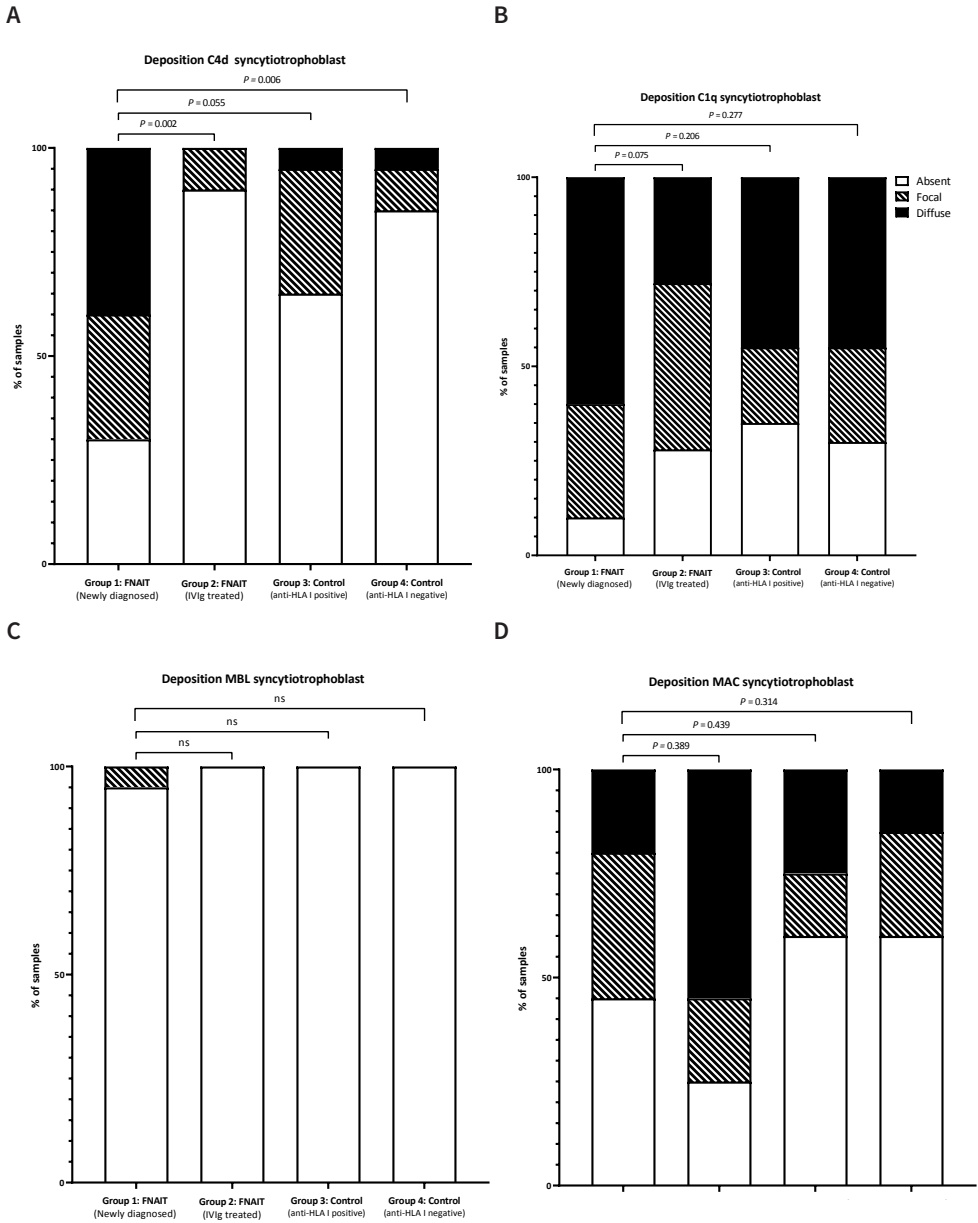
## RESULTS

### CLINICAL CHARACTERISTICS

Clinical characteristics are shown in Table 1. Newly detected FNAIT cases (Group 1) and IVIg treated FNAIT cases (Group 2) were comparable to controls in terms of maternal age, gravidity, parity, and presence of pre-eclampsia. Gestational age at delivery was lower in both the newly detected FNAIT cases (Group 1) and IVIg-treated FNAIT cases (Group 2); compared to controls. ICH was observed in one of the IVIg-treated FNAIT cases (Group 2); this ICH was detected by ultrasound at 27 weeks' gestational while the IVIg-treatment was planned to start at 28 weeks. Placental weight was below the 10th percentile in four (44%) newly diagnosed FNAIT cases, one (7%) FNAIT IVIg-treated case and none of the controls ( $P = 0.022$ ). Three of these four cases were SGA.

### C4D DEPOSITION ON SYNCYTIOTROPHBLAST IS INCREASED IN NEWLY DETECTED FNAIT CASES

Placental complement deposition was scored semi-quantitatively; representative examples are shown in Supplemental Figure 1. More C4d deposition was present at the syncytiotrophoblast in newly diagnosed FNAIT cases (Group 1; 10/14 samples), as compared to IVIg-treated FNAIT cases (Group 2; 2/21 samples;  $P = 0.002$ ) and controls without anti-HLA class I antibodies (Group 4; 3/20 samples;  $P = 0.006$ ; Figure 1A). C4d can be regarded as the footprint of complement activation, which may be either induced through the classical route (e.g. antibody-mediated) or lectin pathway activation. C1q deposition, a marker for the classical pathway of complement activation, was equally present in all study groups in either a focal (20-45%) or diffuse (20-57%) staining pattern (Figure 1B). In 11 (92%) of the samples from FNAIT cases (Group 1 and 2) with C4d deposition, C1q deposition was also present. Deposition of MBL, which indicates complement system activation via the lectin route, was observed only once (Figure 1C). The staining pattern for ongoing complement activation resulting in the formation of a membrane attack complex (MAC) did not differ between the study groups (Figure 1D). In 41% (5/12) of the samples from FNAIT cases (Group 1 and Group 2) with C4d deposition at the syncytiotrophoblast, MAC was also present. C4d deposition was present in all four placentas of newly detected FNAIT children born SGA and absent in the IVIg-treated FNAIT case born SGA. In the samples from FNAIT cases (Group 1 and 2), C4d deposition was equally present in placentas from term (6/6) and preterm (2/4) pregnancies (GA < 37 weeks). No relationship was observed between the mode of delivery and C4d deposition at the syncytiotrophoblast.



**FIGURE 1. Semi-quantitative scoring of complement deposition syncytiotrophoblast**

All complement depositions shown by immunohistochemistry at the syncytiotrophoblast were scored semi-quantitatively as absent (<10%), focal (10-50%) or diffuse (>50%). Figure **A** summarizes the scoring of C4d deposition at the syncytiotrophoblast. In Figure **B** scoring of C1q deposition, in Figure **C** scoring of MBL deposition and in Figure **D** scoring of MAC deposition are summarised. Ordinal logistic regression was used to compare complement deposition score between the groups.

Abbreviations: FNAIT, fetal neonatal alloimmune thrombocytopenia; IVIg, intravenous immune globulins; HLA, human leukocyte antigen; MBL, mannose-binding lectin; MAC, membrane attack complex.

The presence of complement depositions in the fetal vessels is shown in Supplemental Figure 3. The pattern of C4d deposition in the fetal vessels was only different between the newly diagnosed FNAIT cases (Group 1; 50% focal, 21% diffuse) as compared to the IVIg-treated FNAIT cases (Group 2; 62% focal, 10% diffuse;  $P = 0.012$ ). C4d deposition was observed to a similar extent, though with different distribution, in controls. C1q deposition in the fetal vessels was more often diffuse (25% focal, 75% diffuse) in the control group with anti-HLA class I antibodies (Group 3) as compared to the newly detected FNAIT cases (Group 1; 71% focal, 21% diffuse;  $P = 0.003$ ). We did not observe other significant differences.

### PLACENTA MATURATION WAS DELAYED IN NEWLY DIAGNOSED FNAIT CASES

Histopathological findings in the placental tissue are described in Table 2. In four placentas of newly diagnosed FNAIT cases (Group 1; 4/9 cases; 44%) and five of the IVIg-treated FNAIT cases (Group 2; 5/14 cases; 36%), a delayed placental maturation was observed whereas this was not observed in any of the controls ( $P = 0.118$ ). In three of the nine cases (Group 1 and 2; 3/9 cases; 33%) with delayed maturation, the presence of C4d at the syncytiotrophoblast was detected. In one placenta of the newly diagnosed FNAIT cases with delayed maturation the infant was born SGA. In both Group 1 and Group 2, three cases showed maternal vascular malperfusion ( $P = 0.156$ ). Low-grade villitis of unknown etiology was observed in all groups. In all three cases with low-grade villitis of unknown etiology in the group of newly diagnosed FNAIT cases (Group 1), C4d deposition at the syncytiotrophoblast was observed and these three infants were all born SGA. Mild signs of fetal hypoxia were seen in two of the newly diagnosed FNAIT cases (Group 1; 2/9 cases; 22%) and in one of the IVIg-treated FNAIT cases (Group 2, 1/14 cases; 7%;  $P = 0.475$ ). Decidual arteriopathy, chronic intervillitis and vascular necrosis were not seen in any of the cases nor in the controls. An overview of clinical characteristics, complement deposition and histopathological findings for all individual FNAIT cases is listed in Supplemental Table 2.

**TABLE 2. Placenta histopathology**

Pathology	Group 1 FNAIT cases Newly diagnosed n=9	Group 2 FNAIT cases IVIg-treated n=14	Group 3 Controls Anti-HLA I positive n=10	Group 4 Control Anti-HLA I negative n=10
<b>Maturation</b>				
Delayed	4 (44%)	5 (36%)	1 (10%)	0
Corresponding with GA	3 (33%)	9 (64%)	9 (90%)	10 (100%)
Accelerated	2 (22%)	0	0	0
<b>Maternal vascular malperfusion</b>	<b>3 (33%)</b>	<b>3 (21%)</b>	<b>0</b>	<b>0</b>
Retroplacental hematoma	1	0	0	0
Infarction	3	0	0	0
Ischemia	0	2	0	0
Distal villous hypoplasia	1	3	0	0
<b>Fetal vascular malperfusion</b>	<b>1 (11%)</b>	0	0	<b>3 (30%)</b>
Avascular villi	1	0	0	3

TABLE 2. Continued

Pathology	Group 1 FNAIT cases Newly diagnosed n=9	Group 2 FNAIT cases IVIg-treated n=14	Group 3 Controls Anti-HLA I positive n=10	Group 4 Control Anti-HLA I negative n=10
<b>Ascending intrauterine infection</b>	<b>2 (22%)</b>	<b>1 (7%)</b>	<b>1 (10%)</b>	<b>2 (20%)</b>
Stage 1	2	1	0	2
Fetal response	0	0	1	0
<b>Villitis of unknown etiology</b>	<b>3 (33%)</b>	<b>3 (21%)</b>	<b>2 (20%)</b>	<b>1 (10%)</b>
Low grade focal	3	3	1	1
Low grade multifocal	0	0	1	0
<b>Massive perivillous fibrin depositions</b>	<b>0</b>	<b>1 (7%)</b>	<b>0</b>	<b>0</b>
<b>Signs of fetal hypoxia</b>	<b>2 (22%)</b>	<b>1 (7%)</b>	<b>0</b>	<b>0</b>
Mild hypoxia	2	1	0	0
<b>Chorangiomas</b>	<b>0</b>	<b>0</b>	<b>2 (20%)</b>	<b>0</b>
<b>Meconium</b>	<b>1 (11%)</b>	<b>0</b>	<b>0</b>	<b>0</b>

Abbreviations: FNAIT, Fetal Neonatal Alloimmune Thrombocytopenia; IVIg, intravenous immune globulin; HLA, human leukocyte antigen; GA, gestational age.

## DISCUSSION

### MAIN FINDINGS

The aim of this study was to explore complement activation and histopathological anomalies in the placenta of FNAIT cases. We observed an increase in C4d deposition at the syncytiotrophoblast in newly diagnosed FNAIT cases (10/14 samples), as compared to antenatally IVIg treated FNAIT cases (2/21 samples) and healthy controls ( $P = 0.006$ ). C4d deposition was present at the syncytiotrophoblast in all infants born SGA with newly diagnosed FNAIT, but not in the SGA new-born from a pregnancy treated with IVIg. Histopathological examination revealed a delayed maturation of the placenta parenchyma in 44% of the newly diagnosed FNAIT cases, 36% of the IVIg-treated FNAIT cases, and only in one of the controls (10%) (NS). Both low-grade villitis of unknown etiology and C4d deposition at the syncytiotrophoblast were observed in three out of four newly diagnosed FNAIT cases that were born SGA.

### STRENGTHS AND LIMITATIONS

As a result of the retrospective nature of our study, we unfortunately had limited availability of placental tissue from newly diagnosed FNAIT cases. FNAIT is often diagnosed after delivery. The need for a clinical indication to send the placenta to pathology may have led to selection bias. This was not the case for the IVIg-treated FNAIT cases and our control cohort as these placentas were routinely stored for examination. Differences in the inclusion of our groups made it challenging to decipher whether alterations in complement deposits were due to less severe FNAIT or due to the effect of IVIg treatment. The inclusion of newly diagnosed FNAIT cases was based on the nationwide Dutch retrospective cohort study (2006-2017).<sup>9</sup> A strength of our study is that the pathology departments of all referring hospitals were

contacted to retrieve the maximum amount of placenta material available. We previously reported that 22% of the infants in the nationwide Dutch retrospective cohort were SGA;<sup>9</sup> therefore the number of SGA in this newly diagnosed FNAIT cohort (44%) does not appear to be an overrepresentation. Furthermore, Buurma *et al.*<sup>22</sup> found a comparable amount of C4d depositions in IUGR and control placentas. Thus, SGA was suggested to not be associated with C4d deposition in the placenta. A limitation of our study is that the baseline characteristics between groups were slightly different. FNAIT cases had a lower gestational age at birth, likely due to the routine near-term induction in this group. When comparing term and preterm cases, however, our main outcome measure of C4d deposition was found to be equally present in both groups. Similar to our study, Buurma *et al.*,<sup>22</sup> also did not report an association between placental complement activation and the mode of delivery.

## INTERPRETATION

In line with other antibody-mediated disorders, such as the antiphospholipid syndrome and SLE, we hypothesized that anti-HPA-1a binding could lead to classical pathway complement activation in the placenta during FNAIT pregnancies.<sup>13, 15</sup> The complement system is tightly regulated in the placenta. C1q is reported to be an important factor in physiological trophoblast migration.<sup>23</sup> The balance between an active role of C1q and prevention of ongoing complement activation is controlled by complement regulatory proteins, which inhibit the formation of MAC on the membrane surface.<sup>24</sup>

In the newly diagnosed FNAIT cases, a significantly higher degree of C4d deposition was observed at the maternal interface of the placenta of newly diagnosed FNAIT cases compared to IVIg treated FNAIT pregnancies ( $P = 0.002$ ) and anti-HLA antibody-negative controls ( $P = 0.006$ ). This may be related to the high IgG levels in the maternal circulation of the IVIg-treated women, which could have reduced anti-HPA-1a antibody levels.<sup>25</sup> We did not observe increased staining for MAC at the syncytiotrophoblast in the newly diagnosed FNAIT cases. This may be explained by the notion that the complement system is tightly regulated in the placenta by complement inhibitory proteins.<sup>24</sup> For instance, membrane cofactor protein (CD46), decay-accelerating protein (CD55), and MAC-inhibitory protein (CD59) inhibit the continuation of the complement cascade beyond C4b formation.<sup>26</sup> C4d is seen as a footprint of complement activation, whereas MAC deposition can be transient.<sup>13</sup> Moreover, C4d is an accepted biomarker in antibody-mediated transplant rejection and is also recognized to have a role in antibody-mediated pregnancy complications,<sup>13</sup> to which HPA-1a alloimmunization may be added based on our current results.

It is known that subtypes of HPA-1a-directed antibodies can bind to endothelial cells.<sup>4, 6</sup> In contrast to the differences in complement depositions between the groups at the syncytiotrophoblast no differences were observed in complement depositions between the fetal vessels of the FNAIT cases and the controls. Several factors may explain these

differences between the syncytiotrophoblast and fetal vessels, such as lower antibody levels in the fetus, lower availability of complement proteins on the fetal vessel side, or differences in the expression levels of complement regulatory proteins at the surface of endothelial cells and the syncytiotrophoblast.

Delayed placental maturation was found in 44% of the newly diagnosed cases, 36% of the IVIg-treated FNAIT cases and only once in the control group (10%). Delayed maturation may be caused by villitis due to the binding of alloantibodies to trophoblasts, which may lead to altered growth and maturation of the terminal villi. Delayed maturation is associated with fetal hypoxia<sup>27</sup> and was also found in the placentas of  $\beta$ 3-immunised mice.<sup>12</sup> C4d deposition and low-grade villitis of unknown etiology were present in three out of four newly diagnosed FNAIT cases born SGA. This finding suggests a possible correlation between complement deposition and villitis with fetal growth restriction in FNAIT.<sup>28</sup> Our sample size, however, was relatively small and low grade villitis of unknown etiology was also present in some of the control cases, indicating that this finding should be interpreted with caution. In other cohort studies that assessed placental histopathology in FNAIT, chronic villitis, chronic chorioamnionitis and chronic intervillitis were observed.<sup>29,30</sup> Aberrant histopathology was less pronounced in our FNAIT cases as compared to the findings of these studies, however, median gestational age at delivery was 34 weeks in the French study as compared to 37 weeks in our study which may explain the histopathological differences.<sup>30</sup>

### **FUTURE PERSPECTIVES**

In earlier studies, the expression of the  $\beta$ 3-integrin on the syncytiotrophoblast and extravillous trophoblasts was shown.<sup>12, 31</sup> In these studies an antibody directed against the  $\beta$ 3-integrin was used. Eksteen *et al.*<sup>32</sup> showed binding of the HPA-1a antibody to the  $\alpha$ v $\beta$ 3 receptor on isolated trophoblasts. To further support our hypothesis that binding of anti-HPA-1a can lead to placenta damage, future research should focus on demonstrating binding of anti-HPA-1a to the syncytiotrophoblast. On the basis of our observations of increased classical route complement activation in FNAIT placentas, in combination with the histopathological findings, it is imperative to perform additional investigations in the placentas of HPA-1a negative women with and without alloantibodies and in infants born SGA.

### **CONCLUSION**

Our findings support the hypothesis that HPA-1a antibodies affect placental function and may impair fetal growth. We demonstrated that increased classical pathway-mediated complement activation was present in placentas of pregnancies complicated by FNAIT. To what extent binding of HPA-1a antibodies to trophoblast lead to placenta dysfunction should be further explored.

## FOOTNOTES

### AUTHOR CONTRIBUTIONS

MdH, MB, HB and DW conceptualised and designed the research study; TV, KD, RB and MB performed experiments; TV, DW, LP, CK and MB performed clinical data collection; LM and PN performed histopathological examination, ME, CK and MvdH collected control samples; TV and MB analysed the data; TV drafted the manuscript; DW, HB, HB, LM, PG, LP, CS, GV, ME, RK, CK, LA, DO, EL, MvdH, MB and MdH critically revised the manuscript.

### FUNDING

Funded by Fonds Gezond Geboren (E50-03-LUMC) and Process and Product Development Diagnostic Services, Sanquin (SQI/00034).

### INSTITUTIONAL REVIEW BOARD STATEMENT

The study was conducted according to the guidelines of the Declaration of Helsinki, and approved by the Medical Ethical Committee Leiden-Delft-The Hague for cases by study protocol B18.033 (July 11th, 2018) and for the controls by protocol P13.084 (2013).

### INFORMED CONSENT STATEMENT

Patient consent was waived for cases with FNAIT, these cases and clinical data were anonymised by a trusted third party before inclusion. This was in compliance with the Code of Proper Use by the Federation of Medical Scientific Societies (Code Goed Gebruik door de Federatie Medisch Wetenschappelijke Verenigingen in Dutch) and approved by the Ethical Committee. Placentas and serum samples of control cases were collected after informed consent.

### DATA AVAILABILITY STATEMENT

Data available on request due to privacy/ethical restrictions. Outcomes of immunohistochemistry and histopathology assessment per case can be found in Supplemental Material Table 2.

### ACKNOWLEDGMENTS

We want to thank the laboratory of platelet and leukocyte serology at Sanquin, Amsterdam that collected the cohort of newly diagnosed FNAIT samples. Also we would like to thank the department of Department of Immunogenetics, Sanquin, Amsterdam and the Department of Immunology at the Leiden University Medical Center, Leiden for performing HLA antibody screening and HLA typing.

### CONFLICTS OF INTEREST

The authors declare no conflict of interest. The funders had no role in the design of the study; in the collection, analyses, or interpretation of data; in the writing of the manuscript, or in the decision to publish the results

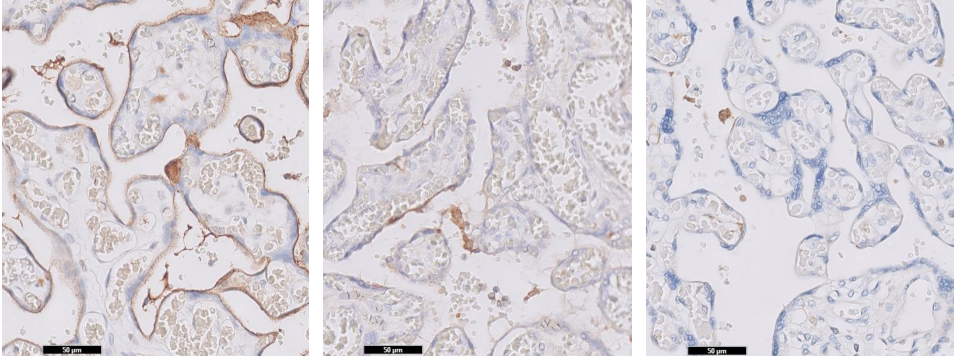


## REFERENCES

1. Dreyfus M, Kaplan C, Verdy E, Schlegel N, Durand-Zaleski I, Tchernia G. Frequency of immune thrombocytopenia in newborns: a prospective study. *Immune Thrombocytopenia Working Group. Blood.* 1997;89(12):4402-6.
2. Winkelhorst D, Kamphuis MM, Steggerda SJ, Rijken M, Oepkes D, Lopriore E, et al. Perinatal Outcome and Long-Term Neurodevelopment after Intracranial Haemorrhage due to Fetal and Neonatal Alloimmune Thrombocytopenia. *Fetal diagnosis and therapy.* 2019;45(3):184-91.
3. Winkelhorst D, Murphy MF, Greinacher A, Shehata N, Bakchoul T, Massey E, et al. Antenatal management in fetal and neonatal alloimmune thrombocytopenia: a systematic review. *Blood.* 2017;129(11):1538-47.
4. van Gils JM, Stutterheim J, van Duijn TJ, Zwaginga JJ, Porcelijn L, de Haas M, et al. HPA-1a alloantibodies reduce endothelial cell spreading and monolayer integrity. *Mol Immunol.* 2009;46(3):406-15.
5. Refsum E, Meinke S, Gryfelt G, Wikman A, Höglund P. Adding to the complexity of fetal and neonatal alloimmune thrombocytopenia: Reduced fibrinogen binding in the presence of anti-HPA-1a antibody and hypo-responsive neonatal platelets. *Thrombosis research.* 2018;162:69-76.
6. Santoso S, Wihadmadyatami H, Bakchoul T, Werth S, Al-Fakhri N, Bein G, et al. Antiendothelial  $\alpha\beta 3$  Antibodies Are a Major Cause of Intracranial Bleeding in Fetal/Neonatal Alloimmune Thrombocytopenia. *Arteriosclerosis, thrombosis, and vascular biology.* 2016;36(8):1517-24.
7. Yougbare I, Zdravic D, Ni H. Angiogenesis and bleeding disorders in FNAIT. *Oncotarget.* 2015;6(18):15724-5.
8. Tiller H, Killie MK, Husebekk A, Skogen B, Ni H, Kjeldsen-Kragh J, et al. Platelet antibodies and fetal growth: maternal antibodies against fetal platelet antigen 1a are strongly associated with reduced birthweight in boys. *Acta obstetrica et gynecologica Scandinavica.* 2012;91(1):79-86.
9. Winkelhorst D, Oostweegel M, Porcelijn L, Middelburg RA, Zwaginga JJ, Oepkes D, et al. Treatment and outcomes of fetal/neonatal alloimmune thrombocytopenia: a nationwide cohort study in newly detected cases. *British journal of haematology.* 2019;184(6):1026-9.
10. Tiller H, Kamphuis MM, Flodmark O, Papadogiannakis N, David AL, Sainio S, et al. Fetal intracranial haemorrhages caused by fetal and neonatal alloimmune thrombocytopenia: an observational cohort study of 43 cases from an international multicentre registry. *BMJ Open.* 2013;3(3).
11. Tiller H, Killie MK, Chen P, Eksteen M, Husebekk A, Skogen B, et al. Toward a prophylaxis against fetal and neonatal alloimmune thrombocytopenia: induction of antibody-mediated immune suppression and prevention of severe clinical complications in a murine model. *Transfusion.* 2012;52(7):1446-57.
12. Yougbare I, Tai WS, Zdravic D, Oswald BE, Lang S, Zhu G, et al. Activated NK cells cause placental dysfunction and miscarriages in fetal alloimmune thrombocytopenia. *Nature communications.* 2017;8(1):224.
13. Cohen D, Colvin RB, Daha MR, Drachenberg CB, Haas M, Nicleleit V, et al. Pros and cons for C4d as a biomarker. *Kidney Int.* 2012;81(7):628-39.
14. Kim MY, Buyon JP, Guerra MM, Rana S, Zhang D, Laskin CA, et al. Angiogenic factor imbalance early in pregnancy predicts adverse outcomes in patients with lupus and antiphospholipid antibodies: results of the PROMISSE study. *American journal of obstetrics and gynecology.* 2016;214(1):108 e1- e14.
15. Cohen D, Buurma A, Goemaere NN, Girardi G, le Cessie S, Scherjon S, et al. Classical complement activation as a footprint for murine and human antiphospholipid antibody-induced fetal loss. *J Pathol.* 2011;225(4):502-11.
16. Paridaans NP, Kamphuis MM, Taune Wikman A, Tiblad E, Van den Akker ES, Lopriore E, et al. Low-Dose versus Standard-Dose Intravenous Immunoglobulin to Prevent Fetal Intracranial Hemorrhage in Fetal and Neonatal Alloimmune Thrombocytopenia: A Randomized Trial. *Fetal diagnosis and therapy.* 2015;38(2):147-53.
17. Dahl J, Skogen B, Kjaer M, Husebekk A, Kjeldsen-Kragh J, Tiller H. A combined effect of anti-HPA-1a and anti-HLA Class I in pregnancy? *Transfusion.* 2020.
18. Pinar H, Sung CJ, Oyer CE, Singer DB. Reference values for singleton and twin placental weights. *Pediatr Pathol Lab Med.* 1996;16(6):901-7.
19. Hoftiezer L, Hukkelhoven CW, Hogeveen M, Straatman HM, van Lingen RA. Defining small-for-gestational-age: prescriptive versus descriptive birthweight standards. *European journal of pediatrics.* 2016;175(8):1047-57.
20. Porcelijn L, Huiskes E, de Haas M. Progress and development of platelet antibody detection. *Transfusion and apheresis science : official journal of the World Apheresis Association : official journal of the European Society for Haemapheresis.* 2020;59(1):102705.
21. Khong TY, Mooney EE, Ariel I, Balmus NC, Boyd TK, Brundler MA, et al. Sampling and Definitions of Placental

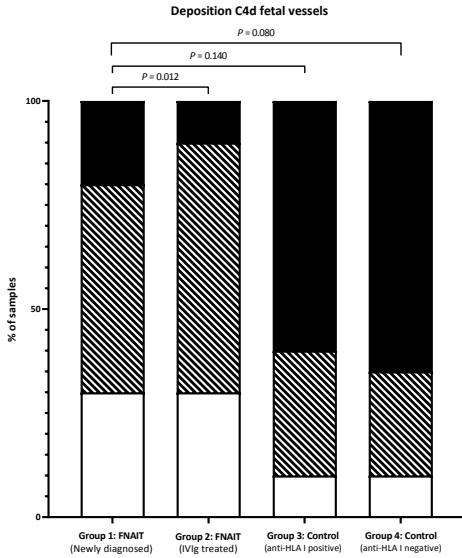
- Lesions: Amsterdam Placental Workshop Group Consensus Statement. *Archives of pathology & laboratory medicine*. 2016;140(7):698-713.
22. Buurma A, Cohen D, Veraar K, Schonkeren D, Claas FH, Bruijn JA, et al. Preeclampsia is characterized by placental complement dysregulation. *Hypertension*. 2012;60(5):1332-7.
  23. Agostinis C, Bulla R, Tripodo C, Gismondi A, Stabile H, Bossi F, et al. An alternative role of C1q in cell migration and tissue remodeling: contribution to trophoblast invasion and placental development. *Journal of immunology* (Baltimore, Md : 1950). 2010;185(7):4420-9.
  24. Girardi G. Complement activation, a threat to pregnancy. *Semin Immunopathol*. 2018;40(1):103-11.
  25. Wabnitz H, Khan R, Lazarus AH. The use of IVIg in fetal and neonatal alloimmune thrombocytopenia- Principles and mechanisms. *Transfusion and apheresis science : official journal of the World Apheresis Association : official journal of the European Society for Haemapheresis*. 2020;59(1):102710.
  26. Pierik E, Prins JR, van Goor H, Dekker GA, Daha MR, Seelen MAJ, et al. Dysregulation of Complement Activation and Placental Dysfunction: A Potential Target to Treat Preeclampsia? *Frontiers in immunology*. 2019;10:3098.
  27. Jaiman S, Romero R, Pacora P, Jung EJ, Kacerovsky M, Bhatti G, et al. Placental delayed villous maturation is associated with evidence of chronic fetal hypoxia. *Journal of perinatal medicine*. 2020;48(5):516-8.
  28. Kim CJ, Romero R, Chaemsaitong P, Kim JS. Chronic inflammation of the placenta: definition, classification, pathogenesis, and clinical significance. *American journal of obstetrics and gynecology*. 2015;213(4 Suppl):S53-69.
  29. Althaus J, Weir EG, Askin F, Kickler TS, Blakemore K. Chronic villitis in untreated neonatal alloimmune thrombocytopenia: an etiology for severe early intrauterine growth restriction and the effect of intravenous immunoglobulin therapy. *Am J Obstet Gynecol*. 2005;193(3 Pt 2):1100-4.
  30. Dubruc E, Lebreton F, Giannoli C, Rabilloud M, Huissoud C, Devouassoux-Shisheboran M, et al. Placental histological lesions in fetal and neonatal alloimmune thrombocytopenia: A retrospective cohort study of 21 cases. *Placenta*. 2016;48:104-9.
  31. Kumpel BM, Sibley K, Jackson DJ, White G, Soothill PW. Ultrastructural localization of glycoprotein IIIa (GPIIIa, beta 3 integrin) on placental syncytiotrophoblast microvilli: implications for platelet alloimmunization during pregnancy. *Transfusion*. 2008;48(10):2077-86.
  32. Eksteen M, Heide G, Tiller H, Zhou Y, Nedberg NH, Martinez-Zubiaurre I, et al. Anti-human platelet antigen (HPA)-1a antibodies may affect trophoblast functions crucial for placental development: a laboratory study using an in vitro model. *Reproductive biology and endocrinology : RB&E*. 2017;15(1):28.

## SUPPLEMENTAL MATERIALS

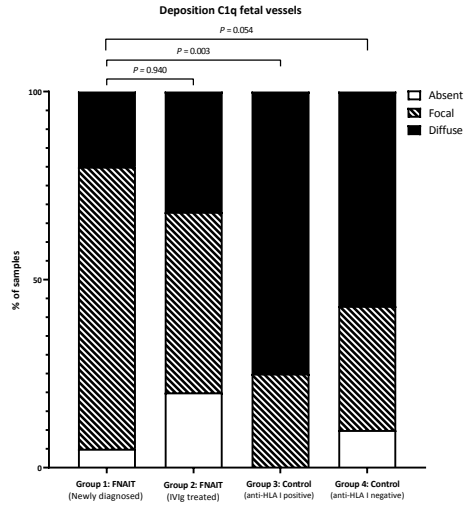
**SUPPLEMENTAL FIGURE 1. Semi quantitative scoring complement depositions**

Sections of placentas stained immunohistochemically for C4d, **A** shows diffuse deposition of C4d to the syncytiotrophoblast, in **B** focal binding to syncytiotrophoblast of C4d appreciated and **C** shows an example where C4d binding to syncytiotrophoblast was absent.

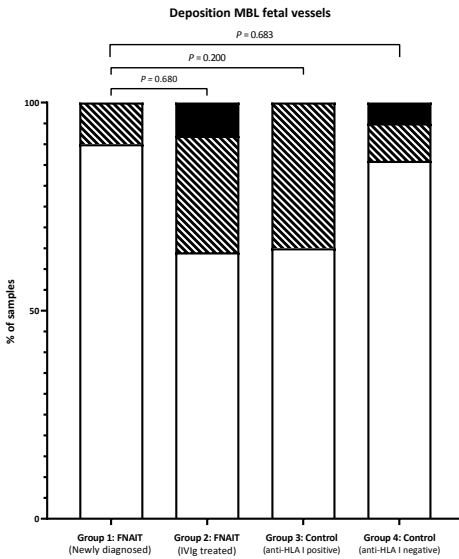
A



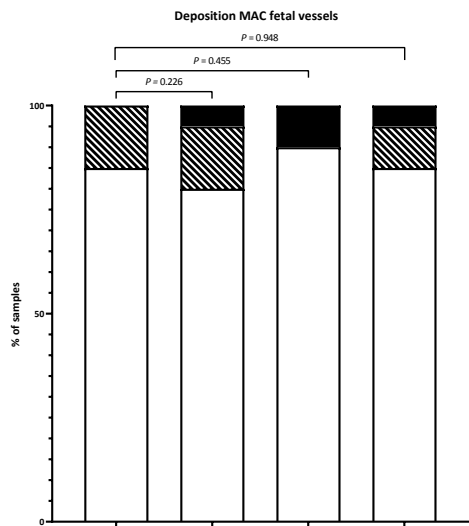
B



C



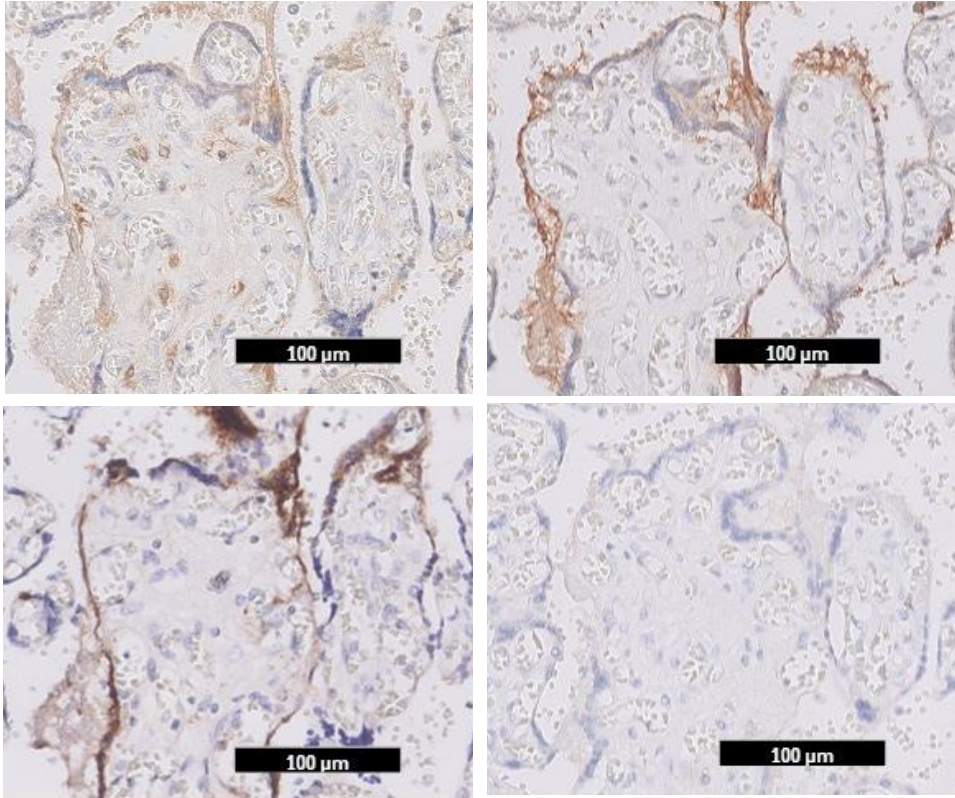
D



**SUPPLEMENTAL FIGURE 2. Semi quantitative scoring of complement deposition fetal vessels**

All complement depositions shown by immunohistochemistry in the fetal vessels were scored semi-quantitatively as absent (<10%), focal (10-50%) or diffuse (>50%). **Figure 2A** summarizes the scoring of C4d deposition at the fetal vessels, in **Figure 2B** scoring of C1q deposition, in **Figure 2C** scoring of MBL deposition and **Figure 2D** scoring of MAC deposition are summarized. Ordinal logistic regression was used to compare complement deposition score between the groups.

Abbreviations: FNAIT, fetal neonatal alloimmune thrombocytopenia; IVIg, intravenous immune globulins; HLA, human leukocyte antigen; MBL, mannose-binding lectin; MAC, membrane attack complex.

**SUPPLEMENTAL FIGURE 3. Complement deposition in the placenta**

Sequential sections of placentas stained immunohistochemically for components of the complement system. **A** shows diffuse deposition of C1q to the syncytiotrophoblast, in **B** diffuse binding of C4d to syncytiotrophoblast can be seen and **C** shows an example of binding of (MAC) SC5b-9. Figure **D** shows that the mannose-binding lectin (MBL) is absent.

SUPPLEMENTAL TABLE 1. Immunohistochemistry protocols

Material type	C1q	C4d	MAC (SC5b-9)	MBL
<b>Preparation/fixation</b>	Sections of paraffin embedded placenta			
<b>Antigen retrieval</b>	Deparaffinize			
	Heat antigen retrieval (Tris/EDTA, 10 mM, pH 9.0)	Heat antigen retrieval (Tris/EDTA, 10 mM, pH 9.0)	Enzym antigen retrieval, Prot 24 (XXIV) (SigmaAldrich, Saint Louis, Missouri, USA, P8038-50MG)	Heat antigen retrieval (Citric acid, 10mM, pH 6.0)
<b>Block endogenous peroxidase</b>	H2O2 (30%) was used 1:250 in distilled water (Merck, Kenilworth, New Jersey, United States of America, 1.07209.0250)			
<b>Block</b>	NGS 1:20 in PBS/1% BSA (Normal goat serum, DakoCytomation, Glostrup, Denmark, X0907)			
<b>Primary antibody</b>	anti-C1q, Rabbit, HRP conjugated, 1:2000 (DakoCytomation, Glostrup, Denmark, A0138)	anti-C4d, Rabbit, HRP conjugated, 1:75 (Biomedica, Vienna, Austria, BJ-RCD4D)	anti-SC5b-9 (neoantigen), Mouse, HRP conjugated, 1:1000 (Quidel Corporation, San Diego, California, USA, A239)	anti-MBL, Rabbit, HRP conjugated 1:500 (Sigma Aldrich, Saint Louis, Missouri, USA HP4002027)
<b>Incubation primary antibody</b>	60 minutes	60 minutes	Overnight	60 minutes
<b>Isotype specific control (negative control)</b>	Rabbit negative control fraction, (DakoCytomation, Glostrup, Denmark, X0936)	Rabbit negative control fraction, (DakoCytomation, Glostrup, Denmark, X0936)	Mouse negative control, IgG2b (DakoCytomation, Glostrup, Denmark, X0944)	Rabbit negative control fraction, (DakoCytomation, Glostrup, Denmark, X0936)
<b>Secondary antibody</b>	HRP anti-rabbit envision+ system (DakoCytomation, Glostrup, Denmark, K4003)	HRP anti-rabbit envision+ system (DakoCytomation, Glostrup, Denmark, K4003)	HRP anti-mouse envision+ system (DakoCytomation, Glostrup, Denmark, K4001)	HRP anti-rabbit envision+ system (DakoCytomation, Glostrup, Denmark, K4003)
<b>Tertiary antibody</b>	Not applicable			
<b>Visualisation staining</b>	DAB, diaminobenzidine (DakoCytomation, Glostrup, Denmark, K3468)			
<b>Counterstaining</b>	Hematoxylin			

Abbreviations: MBL, mannose-binding lectin; HPA, human platelet antigen; Tris, tris(hydroxymethyl)aminomethane; EDTA, ethylenediaminetetraacetic acid; PBS, phosphate buffered saline; BSA, bovine serum albumin; HRP, horseradish peroxidase.



SUPPLEMENTAL TABLE 2. Clinical data and immunohistopathology per case

Case	Age mother	G/P	GA	αHPA	αHLA	Sex	SGA	Bleed	Plt.	C1q syn	C4d syn.	MAC syn.	MBL syn.
1	34	G1P0	41+0	1a	No	F	No	Skin	44	D/F	F/D	A/F	A/F
2	35	G2P0	40+1	1a	Yes*	M	Yes	None	17	D/D	D/D	D/A	A/A
5	28	G2P1	37+1	1a+5b	Yes	M	Yes	Skin	5	D/D	D/D	A/A	A/A
7a	30	G3P1	32+2	1a	Yes	F	NT	ICH	11	D	A	D	A
11	33	G1P0	34+3	1a+3a	No	M	No	Skin	41	A	A	D	A
12	31	G2P1	38+3	1a	Yes	F	Yes	Skin	10	D	F	A	A
13	32	G1P0	35+1	1a	No	M	No	Skin	40	F/D	A/F	A/A	A/A
14	21	G2P0	41+4	1a	Yes*	M	No	ICH	8	F/F	A/F	F/F	A/A
15	29	G2P1	32+6	1a+5b	Yes	F	Yes	None	68	F	D	F	A
7b	32	G4P2	35+5	1a	Yes	F	No	None	22	F/D	A/A	F/F	A/A
8	31	G3P2	38+1	1a+3a	Yes	M	No	None	266	D	A	A	-
11	35	G3P1	37+2	1a	No	F	No	None	169	F	A	A	A
37	37	G2P1	38+0	1a	Yes	M	No	None	78	D	A	D	A
38	31	G5P1	39+2	1a	No	M	Yes	None	50	A	A	D	A
39	33	G2P1	38+5	1a	NT	M	No	None	30	D	F	A	A
40	33	G2P1	39+0	1a	No	M	No	None	85	F	A	D	A
41	31	G3P1	38+6	1a	No	M	No	None	18	F/F	A/A	A/F	A/-
42	30	G2P1	38+4	1a	Yes*	M	No	None	24	A/F	F/A	F/D	A/A
43	35	G5P2	38+5	1a	No	F	No	None	8	F	A	A	A
46	38	G3P2	37+6	1a	Yes*	F	No	None	271	A/F	A/A	D/D	A/A
47	30	G4P1	36+0	1a	Yes*	F	No	ICH	6	-/A	A/A	D/D	A/A
48	37	G4P2	39+2	1a	NT	F	No	None	172	A/A	A/A	D/D	A/A
50	26	G2P1	37+0	1a	Yes	F	No	None	164	A	A	A	A

Abbreviations: G, gravidity; P, parity; GA, gestational age; αHPA, anti-human platelet antigen directed antibodies; αHLA, anti-human leukocyte class I antibodies; SGA, small for gestational age; Bleed, bleeding symptoms; Plt, lowest platelet count; syn., syncytiotrophoblast; MAC, membrane attack complex; MBL, mannose binding lectin; f.v. fetal vessels; PW, placenta weight; MVM, maternal vascular malperfusion; FVM, fetal vascular malperfusion; VUE, villitis of unknown origin; F, focal; D, diffuse; A, absent; \*Specificity of antibodies could not be determined; Corresp. GA, corresponding with gestational age; NT, not tested; ICH, intracranial hemorrhage; AV, avascular villi; Low, low grade focal; DVH, distal villous hypoplasia, IS, ischemia.



C1q f.v.	C4d f.v.	MAC f.v.	MBL f.v.	BW p<10	Maturation	MVM	FVM	Infection	VUE	Fetal hypoxia
F/F	A/A	A/A	A/F	No	Delayed	Infarct	-	-	-	-
A/F	A/A	A/A	A/F	Yes	Corresp. GA	-	AV	-	Low	-
F/F	F/D	A/F	A/A	No	Corresp. GA	-	-	-	-	-
F	F	A	A	No	Delayed	-	-	-	-	-
F	F	F	A	Yes	Accelerated	Infarct abrupt	-	Stage 1	-	Mild
D	F	A	A	Yes	Delayed	-	-	-	Low	-
D/F	D/D	A/A	A/A	No	Corresp. GA	DVH	-	-	-	-
D/F	D/F	A/A	A/A	No	Delayed	-	-	Stage 1	-	-
F	F	A	A	Yes	Accelerated	Infarct	-	-	Low	Mild
F/D	F/F	A/F	A/A	No	Corresp. GA	-	-	-	-	-
D	D	A	-	No	Delayed	-	-	-	Low	-
F	A	F	A	Yes	Corresp. GA	-	-	-	-	-
A	F	A	A	NT	Corresp. GA	DVH	-	-	-	-
F	F	D	A	No	Corresp. GA	-	-	-	-	-
A	A	A	A	No	Corresp. GA	-	-	Stage 1	-	-
A	F	A	A	NT	Delayed	IS	-	-	Low	-
D/F	F/F	A/A	A/-	NT	Delayed	-	-	-	-	-
F/F	F/F	F/A	F/F	NT	Corresp. GA	-	-	-	-	-
F	F	A	A	NT	Delayed	-	-	-	Low	-
D/D	D/F	A/A	F/F	No	Corresp. GA	-	-	-	-	Mild
-/F	A/F	A/A	F/F	No	Delayed	DVH	-	-	-	-
A/F	A/F	A/A	A/F	No	Corresp. GA	DVH, IS	-	-	-	-
A	A	A	A	No	Corresp. GA	-	-	-	-	-