



Universiteit  
Leiden  
The Netherlands

## **Immunotherapy in advanced melanoma: crossing borders**

Kooij, M.K. van der

### **Citation**

Kooij, M. K. van der. (2023, March 30). *Immunotherapy in advanced melanoma: crossing borders*. Retrieved from <https://hdl.handle.net/1887/3589872>

Version: Publisher's Version

License: [Licence agreement concerning inclusion of doctoral thesis in the Institutional Repository of the University of Leiden](#)

Downloaded from: <https://hdl.handle.net/1887/3589872>

**Note:** To cite this publication please use the final published version (if applicable).

CHAPTER  
3.2

# Anti-PD-1 Treatment in Metastatic Uveal Melanoma in the Netherlands

*Acta Oncologica 2016; 56(1):101-103*

Monique K. van der Kooij, Arjen Jooisse, Frank M. Speetjens, Geke A.P. Hospers,  
Kees Bisschop, Jan Willem B. de Groot, Ruther Koornstra, Christian U. Blank,  
Ellen Kapiteijn

## To the Editor,

Uveal melanoma (UM) is a rare type of melanoma, with an incidence of 4.4 cases per million in Europe each year<sup>(1)</sup>. During recent years, different treatment approaches have been tested in patients with metastatic UM. Responses have been reported mainly with localized treatment in patients with a limited number of metastases in the liver<sup>(2-6)</sup>. When diffuse liver involvement and/or extrahepatic disease have developed, systemic therapies are warranted. So far, systemic therapies such as targeted therapy with selumetinib<sup>(7)</sup> or classic chemotherapy<sup>(8)</sup> have failed in metastasized UM.

During the past three years, the European Medicines Agency and the Food and Drug Administration (FDA) have approved three immune checkpoint inhibitors for the treatment of melanoma; ipilimumab (a monoclonal antibody targeting cytotoxic T-lymphocyte-associated protein 4, anti-CTLA-4), pembrolizumab and nivolumab (both programmed cell death protein 1 antibodies, anti-PD-1). Previous retrospective studies in metastatic UM with ipilimumab did not yield the same positive results as in cutaneous melanoma<sup>(9-11)</sup>.

Here, we present the clinical outcome of 17 metastasized UM patients treated with nivolumab or pembrolizumab in the Netherlands.

## Methods

### Patients

Some of the patients were treated in a named patient program (NPP) according to inclusion criteria. Other patients were treated outside this NPP, following clinical criteria of the treating physician. In all 17 patients this meant that they were  $\geq 18$  years of age, were diagnosed with unresectable metastatic UM, had a reasonable performance score (WHO performance status of 0-2) and adequate organ and bone marrow function. Patients did not require previous ipilimumab treatment. Patients with central nervous system metastases had to be clinically stable before enrollment.

### Treatment

Patients were treated with respectively 2 mg/kg pembrolizumab intravenously every three weeks or 3 mg/kg nivolumab intravenously every two weeks. Treatment beyond disease progression was allowed, provided that the patient had clinical benefit and no severe adverse effects. Before every administration the patients' blood was tested, as completed per clinical practice for at least lactate dehydrogenase, liver, kidney, bone marrow and thyroid function.

## Response and progression-free survival evaluation

Imaging was performed at baseline, and every 12 weeks and at the investigators' discretion. A computed tomography (CT) scan was made to evaluate the tumor response according to the radiological scoring system Response Evaluation Criteria In Solid Tumors (RECIST) version 1.1<sup>(12)</sup>. Estimates of overall (OS) and progression-free survival (PFS) were obtained using the Kaplan-Meier method.

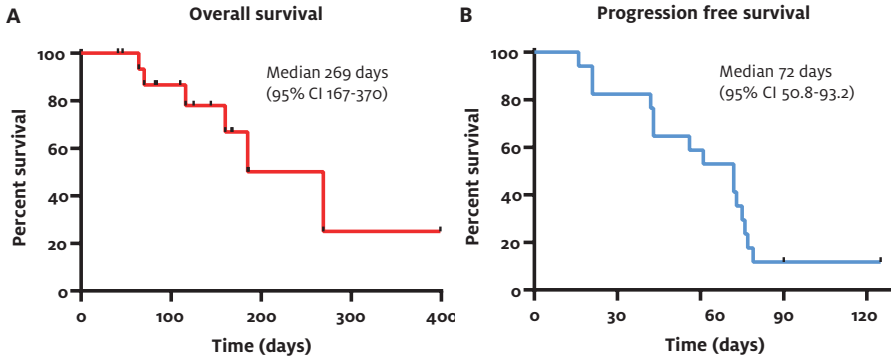
**TABLE 1** Patient characteristics

Age	Sex	WHO	Infusions	Lesion sites at start	Therapies*
51	Female	2	1	Lu, Ma, Cor, LN, Mu, Sp, Bo	3
68	Female	1	3	Li (multiple)	2
68	Female	1	1	Lu, Li, LN, Th, Pt, SC	4
40	Male	0	7	LN, Ad, Pt, Sp, SC	2
60	Female	0	6**	Lu, Li, Bo, SC	1
69	Male	0	6**	Li	1
45	Female	0	4	Li (multiple)	1
44	Female	0	3	Lu, Li	1
49	Female	0	4	Lu, Li, SC, LN	0
28	Male	0	2	Li (multiple)	0
72	Female	0	8 ongoing	Lu, Li	0
54	Male	0	2	Li, LN, Ad, Bo, Pl	0
73	Female	0	5	Li (multiple)	2
67	Female	0	6 ongoing	Li	0
68	Female	0	4 ongoing	Lu, Li	0
49	Female	0	4 ongoing	Lu, Ad, LN, Sp, Bo	0
63	Male	-	3	Lu, Li, LN, Bo, SC	0

\* Number of prior systemic therapies

\*\* Patients received nivolumab

Ad: adrenal; Bo: bone; B: brain; Li: liver; LN: lymph node; Lu: lung; Ma: mammae; Mu: muscle; Pl: pleurae; Pt: peritoneal; SC: subcutaneous; Sp: spleen; Th: thyroid.



**FIGURE 1** Progression-free (PFS) and overall survival (OS) of uveal melanoma patients treated with either pembrolizumab or nivolumab. OS is shown in (A), with 11 patients still alive at time of manuscript preparation. PFS is depicted in (B), with two patients having stable disease at time of manuscript preparation.

### Data analysis

Data were retrospectively collected from Dutch centers organized by the Dutch Immunotherapy Working Group (WIN-O). These data were collected into a predefined database, which was closed on 4 August 2016. Descriptive statistics were performed using SPSS (Version 23 for Windows, SPSS, Chicago, IL, USA).

### Results

Seventeen metastatic UM patients were treated with anti-PD-1 in five different medical centers in the Netherlands between June 2014 and July 2016. The characteristics of this cohort are described in Table 1. The median follow-up was four months. In 10 patients (58.8%) at least four infusions of anti-PD-1 were completed and a CT scan to evaluate tumor response was performed. In three patients a CT scan was performed after three courses of anti-PD-1 after which treatment was discontinued due to fast progressive disease. The remaining four patients (23.5%) deteriorated due to progressive disease too fast to be evaluated by CT scans (two patients after one course of anti-PD-1 and two patients after two courses).

Of the 17 patients who received at least one anti-PD-1 infusion, 15 had progressive disease either clinically or on CT scan (six of them died during or shortly after discontinuing treatment). No patient experienced grade 3 or 4 adverse events. One patient experienced grade 2 toxicodermia which was treated with topical steroids.

At the time of database closure, two of the 15 patients with progressive disease had clinical benefit in terms of symptom reduction and underwent further treatment

with anti-PD-1. Two patients (11.8%) were alive and on treatment with ongoing stable disease; with both patients having received four courses at the time of manuscript preparations. Figure 1(a) demonstrates OS (median 9.6 months) and PFS (median 2.3 months) of our 17 patients is shown in Figure 1(b).

## Discussion

In our study, 17 metastasized UM patients were treated with anti-PD-1 (either nivolumab or pembrolizumab). Four patients were continuing anti-PD-1 treatment at the time of manuscript preparations; two patients because of clinical benefit in terms of symptom reduction and two patients due to ongoing stable disease.

In another recent study by Kottschade et al., a total of 10 UM patients were treated with pembrolizumab. The median PFS was 18 weeks with four patients still ongoing treatment, which is high compared to the 10.3 weeks (2.3 months) in our cohort, indicating strong patient selection<sup>(13)</sup>. Our study differed from the research by Kottschade et al. because we included patients with WHO performance score of 2. Furthermore, we also included treatment-naive patients, whereas Kottschade et al. only included patients who were progressive on treatment with ipilimumab. Moreover, the number and location of metastases was not described by Kottschade et al.

In another recent study from Algazi et al., a total of 56 patients were treated with a PD-1 or PD-L1 antibody. The median PFS was 2.6 months and the median OS was 7.6 months, which is comparable to the median PFS in our study of 2.3 months and the median OS of 9.6 months<sup>(14)</sup>. Algazi et al. concluded that PD-1 and PD-L1 antibodies rarely confer durable remissions in patients with metastatic UM.

Forthcoming are the results from a phase II trial with pembrolizumab in patients with metastasized UM (NCT02359851) and two phase II studies investigating the combination of ipilimumab with nivolumab in treatment-naive UM patients (NCT02626962) or patients with any number of prior treatments (NCT01585194).

The OS data of our study should be interpreted with caution. Limitations of these data include the small sample size of 17 patients, the short follow-up period, differences in prior treatment and subsequent treatments received.

In conclusion, our retrospective analysis of 17 metastatic UM patients treated with anti-PD-1 in the Netherlands indicates limited clinical activity. Overall, this is in agreement with the recently published study by Algazi et al. and is in contrast with the more favorable response reported by Kottschade et al. More studies are needed to explore combination therapies of checkpoint inhibitors, targeted and immunotherapy,

or local therapies and checkpoint inhibitors for metastasized UM patients to improve prognosis in this patient group.

### **Conflicts of interest**

The authors report no conflicts of interest. The authors alone are responsible for the content and writing of this article.

## References

- 1 Mallone S, De Vries E, Guzzo M, et al. Descriptive epidemiology of malignant mucosal and uveal melanomas and adnexal skin carcinomas in Europe. *Eur J Cancer*. 2012;48:1167-1175.
- 2 Hughes MS, Zager J, Faries M, et al. Results of a randomized controlled multicenter phase III trial of percutaneous hepatic perfusion compared with best available care for patients with melanoma liver metastases. *Ann Surg Oncol*. 2016;23:1309-1319.
- 3 Stinauer MA, Kavanagh BD, Scheffter TE, et al. Stereotactic body radiation therapy for melanoma and renal cell carcinoma: impact of single fraction equivalent dose on local control. *Radiat Oncol*. 2011;6:34.
- 4 Shashank A, Shehata M, Morris DL, et al. Radiofrequency ablation in metastatic melanoma. *J Surg Oncol*. 2014;109:366-369.
- 5 Huppert PE, Fierlbeck G, Pereira P, et al. Transarterial chemoembolization of liver metastases in patients with uveal melanoma. *Eur J Radiol*. 2010;74:38-44.
- 6 Pawlik TM, Zorzi D, Abdalla EK, et al. Hepatic resection for metastatic melanoma: distinct patterns of recurrence and prognosis for ocular versus cutaneous disease. *Ann Surg Oncol*. 2006;13:712-720.
- 7 Carvajal RD, Sosman JA, Quevedo JF, et al. Effect of selumetinib vs chemotherapy on progression-free survival in uveal melanoma: a randomized clinical trial. *JAMA*. 2014;311:2397-2405.
- 8 Kivelä T, Suciü S, Hansson J, et al. Bleomycin, vincristine, lomustine and dacarbazine (BOLD) in combination with recombinant interferon alpha-2b for metastatic uveal melanoma. *Eur J Cancer*. 2003;39:1115-1120.
- 9 Kelderman S, van der Kooij MK, van den Eertwegh AJM, et al. Ipilimumab in pretreated metastatic uveal melanoma patients. Results of the Dutch Working group on Immunotherapy of Oncology (WIN-O). *Acta Oncol*. 2013;52:1786-1788.
- 10 Zimmer L, Vaubel J, Mohr P, et al. Phase II DeCOG-study of ipilimumab in pretreated and treatment-naive patients with metastatic uveal melanoma. *PLOS One*. 2015;10:e0118564.
- 11 Maio M, Danielli R, Chiarion-Sileni V, et al. Efficacy and safety of ipilimumab in patients with pre-treated, uveal melanoma. *Ann Oncol*. 2013;24:2911-2915.
- 12 Eisenhauer EA, Therasse P, Bogaerts J, et al. New response evaluation criteria in solid tumours: revised RECIST guideline (version 1.1). *Eur J Cancer*. 2009;45:228-247.
- 13 Kottschade LA, McWilliams RR, Markovic SN, et al. The use of pembrolizumab for the treatment of metastatic uveal melanoma. *Melanoma Res*. 2016;26:300-303.
- 14 Algazi AP, Tsai KK, Shoushtari AN, et al. Clinical outcomes in metastatic uveal melanoma treated with PD-1 and PD-L1 antibodies. *Cancer*. 2016;122:3344-3353.