Universiteit Leiden
The Netherlands

Elucidation of the migratory behaviour of the corneal endothelium

Miron, A.

Citation
Miron, A. (2023, March 9). *Elucidation of the migratory behaviour of the corneal endothelium*. Retrieved from https://hdl.handle.net/1887/3570514

Version:	Publisher's Version
License:	Licence agreement concerning inclusion of doctoral thesis in the Institutional Repository of the University of Leiden
Downloaded from:	https://hdl.handle.net/1887/3570514

Note: To cite this publication please use the final published version (if applicable).

Elucidation of the migratory behaviour of the corneal endothelium

Alina Miron

Elucidation of the migratory behaviour of corneal endothelium

Alina Miron
Leiden University Medical Center, Leiden, The Netherlands
Netherlands Institute for Innovative Ocular Surgery, Rotterdam, The Netherlands

Cover image and design by: Iulia Ghenea, IE Clothing

Cover: The cover image embraces the innovative mindset nourished by the traditional flame. Always in motion, curiosity leads to research and innovation. Instilled by folklore and traditional culture, it exudes a wealth of knowledge that will provide a major impulse to scientific research.

Scientific photography: Netherlands Institute for Innovative Ocular Surgery, Rotterdam, The Netherlands

Layout and printed by: ProefschriftMaken (www.proefschriftmaken.nl)

ISBN: 9789464692105

Copyright © 2023, Alina Miron
Copyright of the published material in chapters 2-7 and 9 lies with the publisher of the journal listed at the beginning of each chapter. All rights reserved. It is not permitted to reprint, reproduce or utilize (parts of) this thesis in any form by electronic, mechanical, or other means now known or hereafter invented, including photocopying and recording in any information storage or retrieval system without prior written consent of the author.

Financial support
Cover design and printing of this thesis was generously provided by: Rotterdamse Stichting Blindenbelangen, Stichting Leids Oogheelkundig Ondersteuningsfonds (LOOF)
Publication of this thesis was partially supported by: European Union's Horizon 2020 research and innovation programme (grant number 667400 – ARREST BLINDNESS Consortium);

Elucidation of the migratory behaviour of the corneal endothelium

Proefschrift

ter verkrijging van
de graad van doctor aan de Universiteit Leiden,
op gezag van rector magnificus prof.dr.ir. H. Bijl,
volgens besluit van het college voor promoties
te verdedigen op donderdag 9 maart 2023
klokke 15.00 uur

door

Alina Miron
geboren te Iași, România
in 1982

Promotor:

Prof. Dr. M.J. Jager

Co-promotors:

Dr. G.R.J. Melles, Netherlands Institute for Innovative Ocular Surgery, The Netherlands

Dr. S. Oellerich, Netherlands Institute for Innovative Ocular Surgery, The Netherlands

Leden Promotiecommissie

Prof. Dr. F.H.J. Claas

Dr. Y.Y. Cheng

Dr. N. Legali, Linköping University, Zweden

Prof. Dr. C. Cursiefen, Uniklinik Köln, Duitsland

For my Family

TABLE OF CONTENTS

Preface		9
Chapter 1	Introduction and outline of the thesis	13
Part 1	**DMEK Graft Analysis before and after Transplantation**	31
Chapter 2	*In vivo* endothelial cell density decline in the early postoperative phase after Descemet membrane endothelial keratoplasty (DMEK)	33
Chapter 3	Endothelial cell viability after DMEK graft preparation	43
Part 2	**Regenerative strategies for the treatment of Fuchs endothelial dystrophy**	59
Chapter 4	Corneal endothelial wound healing: understanding the regenerative capacity of the innermost layer of the cornea	61
Chapter 5	Asymmetrical endothelial cell migration from in vitro Quarter-Descemet membrane endothelial keratoplasty grafts	83
Chapter 6	Improving endothelial explant tissue culture by a novel thermoresponsive cell culture system	95
Chapter 7	In vitro endothelial cell migration from limbal edge-modified Quarter-DMEK grafts	105
Chapter 8	Early and late-onset cell migration from peripheral corneal endothelium	119
Chapter 9	Preclinical testing of small diameter Descemet membrane endothelial keratoplasty grafts to increase tissue availability	137
Chapter 10	Summary, Discussion, and Future Perspectives	151
Chapter 11	Nederlandse samenvatting (Dutch summary)	177
Appendices	List of publications	205
	Curriculum Vitae	
	Acknowledgements	

Preface

PREFACE

The human eye has millions of functional cells, and is considered the second most complex organ in the body after the brain. The eyes dominate emotional communication, governing interactions between the brain and the heart and capturing a lifetime of an individual's views. Although, we can interpret emotions (e.g., anger, disgust, fear, happy, sad, surprise, and to a lesser extent contempt, embarrassment, interest, pain, and shame) by analyzing the expression of the face and eyes, our view is modified by social learning and culture. The fine work of the renowned French photographer Rehahn illustrates ethnic culture, landscapes and portraits with emotions. His most praised works include a close-up shot of a 103-year-old Rengao woman who reveals - through her warm and sparkling eyes - satisfaction and happiness, attesting to a rich life story. Moreover, the eyes can offer a unique glimpse into the body's health and by regular monitoring, an eye doctor may be able to spot systemic medical conditions potentially leading to early diagnostic and treatments. The retinal blood flow and vessels can, for instance, signal a risk for stroke or high blood pressure, and a yellow sclera may be a sign of hepatitis.

The eye is protected from germs, dust, harmful objects, and to some extent, from the damaging ultraviolet wavelengths in sunlight by the eyelids and the cornea. The cornea also acts as the eye's outermost refractive surface focusing the light that will reach the brain as electrical signals which are then translated further into images. In order for a person to see well, all five main layers of the cornea must be free of any cloudy or opaque areas. The cornea can recover from minor injuries on its own, however, deep injuries will take longer to heal and might also cause pain, blurred vision, extreme sensitivity to light, and in some cases even corneal scarring. Also, corneal dystrophies can affect one or more parts of the cornea through accumulation of foreign material that will cause the cornea to lose its transparency, potentially leading to loss of vision. To restore vision in such cases, a cornea transplant (i.e., keratoplasty) is performed in which (a part of) the defective cornea is replaced with healthy corneal tissue from a deceased donor. In cases in which the inner most layer of the cornea (i.e., endothelium) is affected, it is mostly restored by performing a Descemet Membrane Endothelial Keratoplasty (DMEK) procedure. However, the global shortage of available corneal donor grafts and a rise in the ageing population cause a shortness in potential transplants. Thus, a considerable clinical interest exists for developing tissue-engineered constructs and new cell therapies using cultivated cells.

More than 9 years have passed since I became fascinated by this clear window of the eye. The story begins in Rotterdam where I was doing a six-month internship at the Netherlands Institute for Innovative Ocular Surgery (NIIOS) center located in the vicinity of the Erasmus Bridge. Before completing a 2-year program and being awarded the degree Professional Doctorate in engineering (PDEng) at the Delft University of Technology, I was referred to set up a protocol for culturing a cell type with a rare nesting behavior. But applying these results into clinical practice is another challenge and if you fast-forward the time, you will still find me trying to explain paradigms that show-up while digging for answers. For a successful implementation of regenerative therapies for the corneal endothelium, we need to understand the dynamic cellular changes that occur in vivo in both normal and diseased tissue. Only after this, can effective solutions be proposed to reduce the global shortage of donor corneas.

In this thesis, I will focus on the *in vivo* and *in vitro* behavior of corneal endothelial cells before and after endothelial keratoplasty. Regenerative strategies for the treatment of Fuchs endothelial corneal dystrophy, the most common corneal disorder requiring transplantation, will be tackled from a dual perspective, i.e., regeneration without allogeneic corneal endothelial cell transplantation and targeted activation of endogenous self-repair mechanisms.

CHAPTER 1

Introduction and outline of the thesis

Alina Miron

Netherlands Institute for Innovative Ocular Surgery, Rotterdam, The Netherlands

GENERAL INTRODUCTION

Posterior lamellar keratoplasty techniques have gained increasing acceptance over the past two decades to become the leading form of corneal transplantation. Initially described by Melles et al in 1998 , there have been multiple technical modifications, culminating in Descemet membrane endothelial keratoplasty (DMEK).[1,2] These technical refinements have allowed endothelial keratoplasty to gain not only widespread acceptance but to make it the treatment of choice for endothelial diseases.[3,4] The selective transplantation of the endothelium through a small incision allows for faster and more complete visual rehabilitation, with minimized interface haze and antigen load, less astigmatism and fewer suture-related complications.[5,6] Fuchs endothelial corneal dystrophy is the most common indication for corneal transplantation.[7,8] It is characterized by deterioration of endothelial cells, from the center towards the corneal periphery, and the development of characteristic basement membrane excrescences known as guttae. Interestingly, the diseased endothelial cells have demonstrated an increased migration speed compared to normal corneal endothelial cells, which may impact the healing response to surgical procedures under pathological conditions.[9]

The research presented in this thesis focusses on *in vivo* and *in vitro* corneal endothelial cell migration from shape-adapted corneal grafts for the treatment of corneal endothelial disorders. A greater understanding of the cell migration mechanisms from phenotypically distinct regions of the endothelium may assist in selecting the optimal donor tissue and predicting *in vivo* cell behavior. Understanding cell migration *in vivo* has clinical implications for corneal transplantation, for instance when pharmaceutical cell modulation may further improve the patient outcomes. In this introduction, we will discuss the corneal anatomy, the basic physiological function of the corneal endothelium, surgical approaches, and available treatment options for mitigating endothelial cell dysfunction.

THE HUMAN EYE

The eye consists of three basic structural layers, which enclose the optically clear aqueous humour, lens, and vitreous body. The outermost layer is a tough collagenous structure comprised of the cornea and the sclera. The middle layer is highly vascular and is known as the uvea. This layer contains the main blood supply to the eye and consists, from posterior to anterior, of the choroid, the ciliary body, and the iris. The innermost layer is the retina, which rests on the choroid and lines the inside of the posterior segment. The retina is one of the most metabolically active tissues in the body, receives most of its nourishment from the vessels within the choroid, and is responsible for the perception of images (Figure 1). To reach the retina, light must pass through and be refracted by the cornea which is responsible for two thirds of the refractive power of the eye.

The Cornea

The cornea is a transparent avascular tissue about 520 µm thick which acts as a primary barrier against infection and mechanical damage to the internal structure of the eye.[10] The role of the cornea in the refraction of light requires it to be both optically transparent and sufficiently curved to bend light rays with minimal light scattering. Normally, more than 90% of the incident light is transmitted through the cornea.[11] Maintaining corneal transparency is of prime importance for visual function. Since the cornea lacks blood vessels, the anterior surface receives nutrients via diffusion from the tear fluid, the periphery from scleral vessels while the posterior side is supplied by the aqueous humor. The cornea is also supplied by neurotrophins via the nerve fibers that innervate it. Its anatomic structure is relatively simple consisting of three cellular layers, namely the epithelium, the stroma and the endothelium which contain epithelial cells, keratocytes and endothelial cells, respectively. In addition, there are two important acellular interfaces: the Bowman layer between the

epithelium and the stroma, and the Descemet membrane (DM) between the stroma and endothelium (Figure 2).

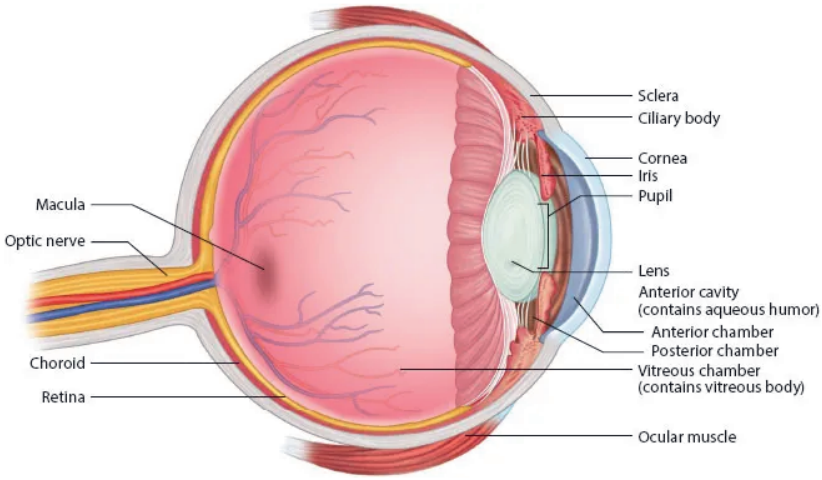

Figure 1| Anatomy of the eye – sagittal section.

Source: https://basicmedicalkey.com/ophthalmic-drug-delivery/

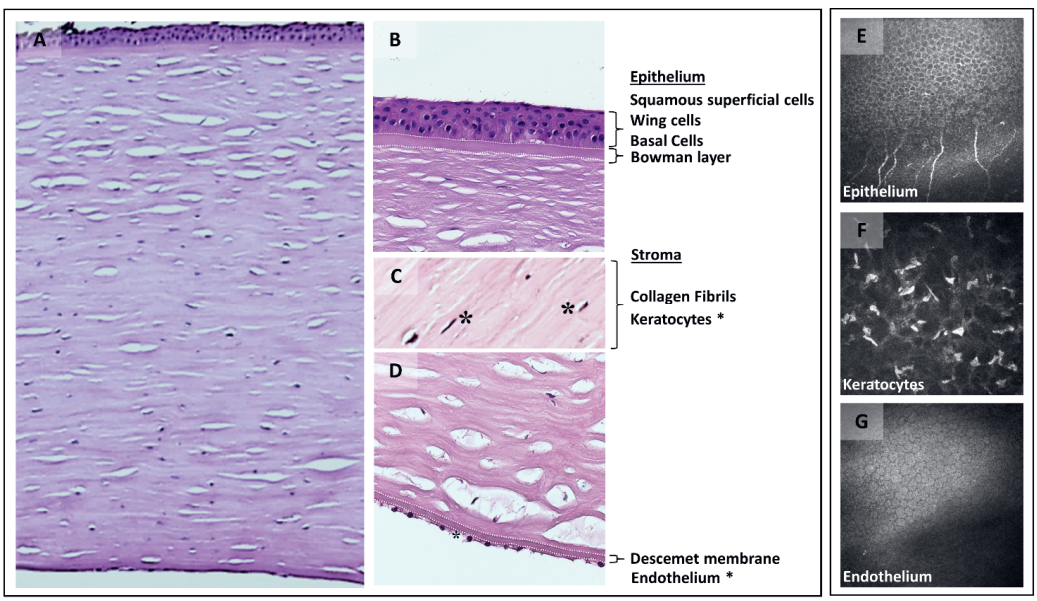

Figure 2| The human cornea. (A) Photomicrograph of a cornea stained with hematoxylin-eosin (H&E) with emphasis on (B) epithelium – formed by superficial squamous cells, wing cells and a single layer of inner columnar basal cells, Bowman layer – an acellular tough membrane situated between corneal epithelium and stroma, (C) stroma – the layer that gives the cornea strength and gives it its curved shape, (D) Descemet membrane – the innermost surface of the cornea that acts as a basement membrane for the inner endothelium – a monolayer of homogeneous, closely packed, hexagonal cells; original magnification: (A) 100 µm, (B-D) 400 µm. (E-G) confocal microscopy images of epithelial cells, stromal keratocytes and endothelial cells.

The epithelium

The epithelium is a five-to-seven layered cell sheet that serves a number of functions. It helps to keep the corneal surface optically smooth and provides a barrier to external biological agents and chemical damage.[12] It represents about 10% (~ 50 µm) of the total corneal thickness and it is constantly sloughed off and regenerated, which helps the eye to heal itself from mild trauma or abrasions. The epithelium consists of flat superficial differentiated cells, deeper winged cells (daughter cells of the basal layer which are pushed anteriorly), and an underlying monolayer of columnar basal cells. The differentiated squamous cells have surface microvilli and occupy the outer 1 – 3 cell layers of the epithelium (Figure 2, A, B, and E). The function of the microvilli is to increase the cell surface area allowing a close association with the tear film. The underlying basal cells have wing-like extensions, rarely undergo division and migrate superficially to differentiate into squamous cells. The innermost basal cell layer consists of a single layer of columnar cells with important functions including the generation of new wing cells and maintenance of the epithelial organization, and acting as a scaffold on which cells can migrate. The transparency of the normal epithelium is the result of the homogeneity of the refractive index of cells throughout this cellular layer.[13] When an excessive accumulation of fluid (edema) occurs, the epithelium loses its homogeneity and the corneal surface becomes irregular. Any surface irregularity can cause a reduction in vision along with symptoms of glare, photophobia, and halos around lights due to light scatter.

The Bowman layer

The Bowman layer forms the anterior boundary between the epithelium and the stroma and consists of randomly oriented collagen type I fibrils supported within a proteoglycan matrix. This interconnecting network of the anchoring fibrils in the anterior cornea confers considerable strength and resistance to trauma and helps the cornea to maintain its shape (Figure 2, A and B). However, once damaged, it cannot be regenerated.[14]

The stroma

The stroma is a structured lattice of collagens and proteoglycans deposited in sheets known as lamellae and maintained by specialized keratocytes (Figure 2, A, C, and F).[15] The keratocytes are scattered throughout the stroma and are linked to one another via dendritic processes.[16] Keratocytes are typically dormant in the quiescent stroma but can become active and then produce and turnover crystalline proteins to maintain corneal transparency.[17] The unique arrangement of evenly-spaced collagen fibrils provides structural strength, shape, stability, and transparency to the cornea.[18]

The Descemet membrane

The Descemet membrane (DM) is a thin acellular layer that acts as the basement membrane of the endothelial cells. It is continuously produced and deposited by the endothelial cells, resulting in a thickness increase throughout life at a rate of about 1 to 2 µm per decade reaching about 10 µm in older adults (Figure 2, A and D).[19,20] In adults, the DM consists of two ultrastructurally distinct layers: an anterior, highly organized banded layer of collagen lamellae and proteoglycans formed during gestation, and a posterior, more amorphous layer produced by the extracellular matrix deposition of the endothelial cells.[21] The gradual increase in thickness of the posterior layer suggests that either there is no degradation of its constituents or the rate of synthesis of constituents is higher than the degradation rate.[22] The wide-spaced collagen fibers found in the DM do not adhere strongly to the stroma, and so a surgical cleavage plane can be created allowing the DM to be peeled and dissected as a sheet.[23]

The endothelium

The endothelium is a thin monolayer of hexagonal cells covering the posterior surface of DM, lining the inner surface of the cornea, and maintained by nutrients from the aqueous humor (Figure 2, A, D, and G). Despite their simple hexagonal appearance, endothelial cells are quite complex in function. Adjacent cells communicate through intracellular junctions[24–27] that mediate electrical and chemical coupling between neighboring cells, whereas the basal cell margins adjacent to DM are ruffled, with tightly-joined interdigitating foot processes, some of which appear to insert into neighboring cells.[28,29] The whole assembly allows the endothelium to function as a "leaky" barrier, forming resistance to the permeability of solutes and fluid through paracellular transport routes,[27,30] but allowing the passage of nutrients from the aqueous humor to feed the avascular cornea.[31] The corneal endothelium (CE) counteracts the osmotic tendency of the corneal stroma to swell by removing excess stromal fluid via the activity of proton pumps, which are located mainly on the basolateral side of the membrane.[32,33] The dynamic balance between the barrier and active pump of the endothelium is essential for maintaining the relatively dehydrated state of the stroma required for transparency (i.e., stromal deturgescence).[34] Once the endothelial monolayer is compromised, the relative balance between the leak rate and metabolic pump rate is lost.

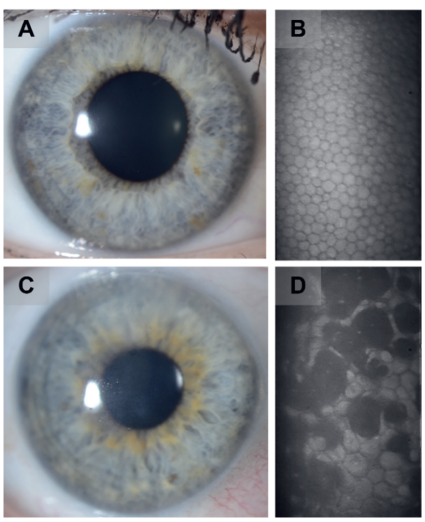

Figure 3| Slit-lamp photograph showing a transparent cornea (A, slit lamp image overview) optimally hydrated by a healthy endothelium (B, specular microscopy image showing an endothelium characterized by hexagonal cells with highly uniform polygonal morphology). Corneal endothelial decompensation (D, specular microscopy image showing empty spaces in the endothelial mosaic) leading to overhydration of the cornea (C, slit lamp image overview).

Endothelial cell density (ECD) begins at about 5000-6000 cells/mm^2 at birth, but as the cornea grows the cells spread out and the density declines to about 3500 cells/mm^2 in the young adult. From the second to the eighth decade, the cell density further decreases to about 2600 cells/mm^2 with an attrition rate of approximately 0.6% per year.[35–37] Human corneal endothelial cells (hCEC) are not thought to have a significant capacity for *in vivo* regeneration, thus making them unable to replace significant numbers of dead or damaged cells.[38] While the cells do not appear to have the capacity to proliferate, hCEC can respond to minor damage by stretching and centripetal migration into the injured area, to maintain proper structure and function.[26,35] The phenomenon of cell spreading can be associated with the variability in cell size (polymegathism) and cell shape

(pleomorphism) observed in older individuals. Given the importance of its function, damage to the endothelium is potentially more serious than that to the other corneal layers and can result in cell loss and loss of vision.[40] However, the age-associated decline of the CE does not usually affect the critical barrier and pump function.[41] In contrast, acute hCEC loss due to conditions such as endothelial dystrophies, chemical burn, or previous refractive or intraocular surgeries may lead to corneal decompensation.[42–48] When the hCEC density decreases below the critical threshold range of 500 to 1000 cells/mm^2 the pump function may be compromised, and the cornea can become edematous and cloudy (Figure 3).[49] In such cases, corneal transplantation is currently the only effective option to improve vision and reduce pain. The gold standard treatment is to replace the ineffective endothelium selectively with healthy, functional donor CE through a corneal transplant.

ADVANCES IN ENDOTHELIUM TRANSPLANTATION AND REGENERATION

Cornea transplantation is an operation used to remove all or only the damaged part of the cornea to replace it with healthy cornea tissue (the transplant) of a suitable deceased donor. Fuchs endothelial corneal dystrophy (FECD) is a common form of corneal endothelial dystrophy and the most common indication for cornea transplantation worldwide.[50] FECD dystrophy progresses slowly and is characterized by a progressive loss of central corneal endothelial cells, thickening of DM and deposition of basement membrane excrescences in the form of guttae (Figure 3, C and D).[51]

Before cornea transplantation can be performed, the donor tissue should be harvested, disinfected, assessed, prepared and stored, a highly regulated process most often performed by an eye bank. Since the first successful transplantation in 1905 by Zirm,[52] for many years, the procedure of choice to manage corneal disorders was penetrating keratoplasty (PK), i.e., a full-thickness graft in which all corneal layers are replaced (Figure 4, top). Although improvements in the visual acuity were achieved with PK, frequent complications were reported: (i) denervation, (ii) suture-related complications such as astigmatism, infection and increased risk of immune-mediated graft rejection, (ii) and a significant increase in the prevalence of glaucoma following transplantation.[53] Moreover, since visual acuity outcomes after PK were not predictable, the procedure was usually only performed after the patient's visual acuity level had dropped to levels below 0.3.[54,55] These drawbacks of PK led to the development of posterior lamellar keratoplasty techniques to replace PK with less invasive surgical interventions for the treatment of endothelium-related corneal diseases.[56–59]

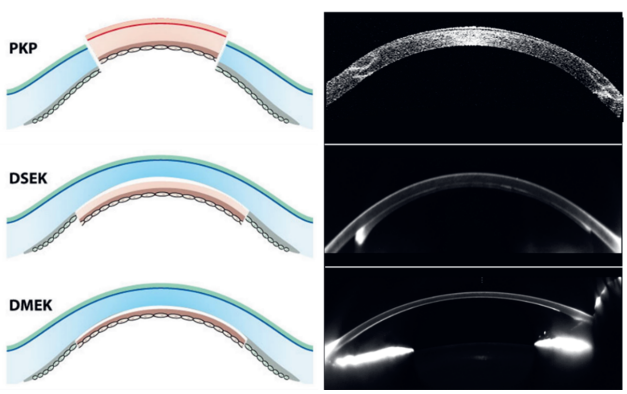

Figure 4| Fundamental developments in endothelial keratoplasty. Cartoon images of the PK, DS(A)EK, and DMEK principles (Left) and the post operative view of the cornea after the three procedures (Scheimpflug image – Pentacam), respectively (Right).[60-62]

One of the keystones of modern endothelial keratoplasty (EK) was laid by Melles et al.[63] in 1998, where he described the posterior lamellar keratoplasty (PLK), an initially mid-stromal approach to replace the posterior cornea. Since the removal of the diseased tissue for PLK was technically still challenging, in 2002, Melles introduced the 'descemetorhexis' procedure, during which the diseased host Descemet membrane with its endothelium is selectively removed ('stripping').[64] This enabled the introduction of Descemet stripping (automated) endothelial keratoplasty (DS(A)EK), a procedure that became adopted by corneal surgeons all over the world (Figure 4, middle).[65] Compared to PK, DS(A)EK resulted in a faster visual rehabilitation and more predictable refractive outcome, while suture and wound-related problems could be avoided. DS(A)EK allows the retention of a better structural integrity of the eye and allograft rejection rates were reduced.[66,67] However, thickness irregularities of the donor graft or stromal interface haze causing optical aberrations could sometimes result in variable visual acuity outcomes.[67] Following the widespread adoption of DS(A)EK, the Melles group further revised its approach and reported the results of a newer procedure that eliminated the variability of the stroma by producing a stroma-less graft in the form of Descemet Membrane Endothelial Keratoplasty (DMEK).[68–70] In DMEK, the normal corneal anatomy is restored by selective replacement of the diseased corneal layer only (Figure 4, bottom). Although initially challenging, recent developments have facilitated tissue handling in a "no-touch" manner. As a result, the procedure is designed with reproducible, standardized steps, that can be implemented by most corneal surgeons in any clinical settings and with relatively low costs.[71]

Compared to PK, lamellar keratoplasty procedures provide faster recovery, better visual results, with less scarring and fewer optical stromal aberrations. In addition, lower rates of post-operative endothelial cell loss have been reported in long-term outcome studies. [72]

Globally, the main barrier to patients receiving these treatments is the lack of suitable donor tissue. To cope with global shortage of donor corneas, the concept of using one donor cornea for the treatment of multiple patients was realized with the introduction of the 'Hemi-DMEK'[73–75] and 'Quarter-DMEK'.[76–79] These approaches use one donor cornea to prepare two semi-circular or four quadrant-shaped DMEK grafts with the potential to double or quadruple the availability of endothelial grafts. These techniques are surgically similar to standard DMEK and achieved comparable visual acuity outcomes, however, the initial case series showed higher rates of graft detachment and relatively low postoperative endothelial cell density.[80,81] Another limitation of these techniques, particularly for Quarter-DMEK, is that the surgical indication is mostly restricted to cases of Fuchs endothelial corneal dystrophy with central corneal guttata (Figure 5B) and without peripheral corneal edema on slit-lamp examination.

Clinical reports of patients who achieved corneal clearing despite failure of graft adhesion after endothelial keratoplasty[82,83] stimulated research into an entirely different concept – the possibility of cell free treatments. The initial cases with corneal clearance despite graft detachment were followed by reports of endothelial regeneration after Descemet's Stripping Only (DSO) procedures, also known as Descemetorhexis without endothelial keratoplasty (DWEK), that has emerged as a new tissue-free treatment option for patients with central FECD.[84–86] Like any surgical technique, DSO has also evolved over time. Currently, only a small area of diseased DM with a diameter of about 4–6mm, along with its endothelial cells and guttae in the visual axis, is removed. The bare area is then left to clear by the migration of peripheral endothelial cells. The presence of healthy peripheral cells is therefore a pre-requisite for successful DSO treatment but despite improvements in high resolution imaging technologies to determine the peripheral cell density reserve, some patients still do not clear after DSO.[87] The complexity of determining not only the density but the migration capacity and quality of the peripheral endothelial cell reserve in order to define the ideal candidate for DSO, may be the major limiting factor on the widespread use of this approach[88] which shows a 12-month failure rate of 8% - 18%.[89–94] Recently, studies have reported on the topical administration of Rho-kinase inhibitors (ROCK-inhibitors) in combination with DSO.[95–96] It has been shown that the use of ROCK-inhibitors promotes the

recovery of ECD, of visual quality, and supports the concept of peripheral endothelial cell proliferation and/or migration by decreasing peripheral ECD loss. Therefore, by combining DSO with ROCK inhibitors an important economical saving for society could take place as it does not require donor tissue nor expensive post-operative care.



Figure 5| *In vivo* confocal microscopy images: (A) healthy corneal endothelium (B) mild FECD: guttae appear rather scattered and appear in only a small portion of the endothelial area, and (C) severe FECD: confluent guttae visible across the entire endothelium.

DSO/DWEK is likely to only be an option for milder FECD cases and will not eliminate the demand for corneal tissue. With this in mind, other alternatives for donor graft material are being investigated. Several clinical trials are underway evaluating approaches to using corneal endothelial cell replacement therapy through the injection of cultivated cells from a donor in the presence of mitogens[97,98] or even loaded with magnetic nanoparticles.[99] Expanding cells in culture allows far more patients to be treated by a single corneal donor. The longest-running trial using cell injection delivery has enrolled more than 60 participants in Japan[100] and recently reported its 5-year follow-up of the first 11 patients.[101] The most recently reported clinical trial with cultured endothelial cells was conducted from November 2020 to May 2021 at the Quesada Clinic in San Salvador, El Salvador, and the investigators injected cultured cells of two donor corneas into 50 affected eyes with the goals of reducing corneal edema and restoring vision. Although official data is not yet available, the investigators have confidence in the procedure's efficiency.[102] Figure 6 summarizes the current and developing regenerative medicine therapies to treat corneal endothelial disease.

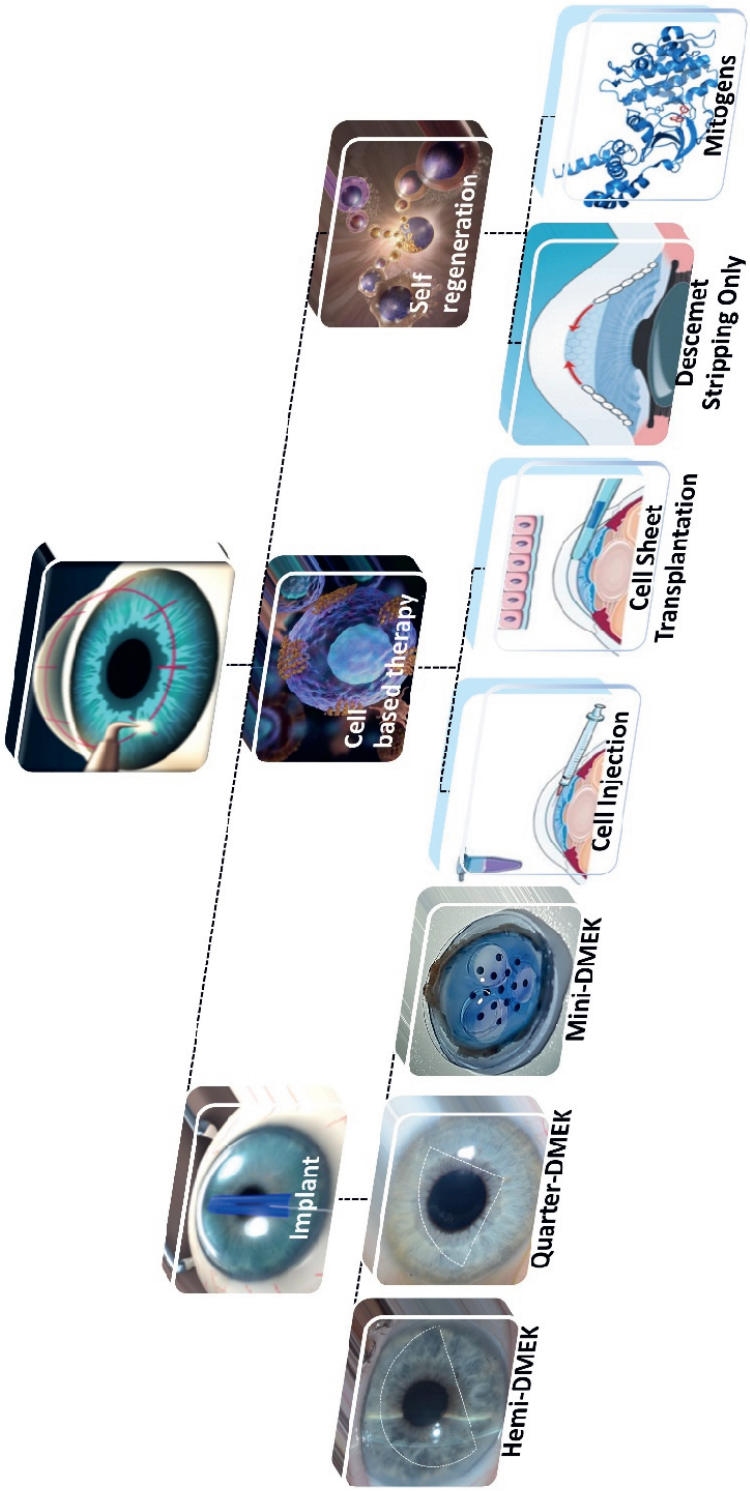

Figure 6|Strategies to counteract the global shortage of donor material. Implant approach: efficient use of donor cornea with Hemi-DMEK, Quarter-DMEK, Mini-DMEK. Cell based therapy: cell injection using cultured cells of mature differentiated cells or cell sheet transplantation. Self regeneration through Descemet stripping only in the presence or absence of mitogens.

AIM AND THESIS OUTLINE

The thesis focuses on the *in vivo* and *in vitro* behavior of corneal endothelial cells before and after endothelial keratoplasty. The first part of the project concentrates on the ECD decrease after DMEK and DMEK graft viability prior to transplantation. The second part focusses on regenerative strategies for the treatment of FECD by developing and applying *in vitro* cell migration assays. *In vitro* cell migration from DMEK grafts of various sizes and shapes are investigated in a 3D cell culture system aiming to identify critical parameters for the successful clinical application of corneal endothelial therapies.

The first two chapters focus on the pre- and postoperative ECD measurements of DMEK grafts. In **Chapter 2**, we analyse ECD decrease after DMEK and demonstrate that about half of the observed ECD decrease at 6 months after DMEK is an *in vivo* decline from 1 day to 6 months postoperatively. The remaining decrease between preoperative and 1 day postoperative ECD values may be attributed to measurement error in the eye bank. In **Chapter 3**, we further examine the high ECD drop in the early postoperative phase after DMEK by analyzing the effect of graft preparation and organ-culture storage on ECD and viability of DMEK grafts prior to their release for transplantation.

The next six chapters focus on obtaining a better understanding of the regenerative capacity of the corneal endothelium by collecting the latest updates on the corneal endothelial wound process and performing explant outgrowth assays using a novel 3D culture technique. In **Chapter 4**, we summarize what is currently known about the wound healing characteristics from a biochemical level in the lab to the regenerative features seen in the clinic. In **Chapter 5**, cell migration of shape-adapted DMEK (Quarter-DMEK) grafts is replicated in an *in vitro* culture system and possible reasons for the lack of endothelial cell migration from the peripheral round edge of Quarter-DMEK grafts are examined. In **Chapter 6**, a novel 3D culture technique for an improved studying *in vitro* cell migration from explant tissue is tested. The technical 'ins and outs' of the proposed culture system and the cell ability to remodel the artificial matrix during migration while the explant tissue is maintained and fixed on a rigid position are analysed. In **Chapter 7,** we use the 3D culture system to explain the migration capacity of the peripheral endothelium, to provide more effective graft modifications prior to clinical implementation. In **Chapter 8**, we determine the migration of peripheral corneal endothelial cells in the presence and absence of mitogens to better understand the cell migration mechanism from phenotypically-distinct regions of the endothelium. In **Chapter 9**, a new preparation process and surgical testing of small diameter DMEK grafts are investigated. Additionally, by engaging the 3D hydrogel system, the surgical effect on endothelial cell density, viability, and migration capacity is evaluated.

References

1. Melles GRJ, Ong TS, Ververs B, van der Wees J. Descemet membrane endothelial keratoplasty (DMEK). Cornea. 2006 Sep;25(8):987-90. https:// doi.org/10.1097/01.ico.0000248385.16896.34 PMID: 17102683

2. Melles GR, Dapena I. How to get started with standardized 'no-touch' Descemet endothelial keratoplasty (DMEK). Netherlands Institute for Innovative Ocular Surgery. 2014. ISBN: 978-90-8890-277-2

3. Flockerzi E, Maier P, Böhringer D, Reinshagen H, Kruse F, Cursiefen C, et al. Trends in corneal transplantation from 2001 to 2016 in Germany: a report of the DOG-section cornea and its keratoplasty registry. Am J Ophthalmol. 2018 Apr;188:91-98. https://doi.org/10.1016/j.ajo.2018.01.018 PMID: 29410297

4. Eye Bank Association of America. The 2021 Eye Banking Statistical Report includes data from all 56 U.S. and 11 international member eye banks, plus one EBAA-accredited entity for the calendar year 2021 and represents a complete picture of eye banking activity among eye banks. Available from: https://restoresight.org/members/publications/statistical-report/

5. Waldrop WH, Gillings MJ, Robertson DM, Petroll WM, Mootha VV. Lower corneal haze and aberrations in Descemet membrane endothelial keratoplasty versus Descemet stripping automated endothelial keratoplasty in fellow eyes for Fuchs endothelial corneal dystrophy. Cornea. 2020 Oct;39(10):1227-1234. https://doi.org/10.1097/ICO.0000000000002416 PMID:32639312

6. Woo JH, Ang M, Htoon HM, Tan D. Descemet membrane endothelial keratoplasty versus Descemet stripping automated endothelial keratoplasty and penetrating keratoplasty. Am J Ophthalmol. 2019 Nov;207:288-303. https://doi.org/10.1016/j.ajo.2019.06.012 PMID: 31228467

7. Sarnicola C, Farooq AV, Colby K. Fuchs Endothelial Corneal Dystrophy: Update on pathogenesis and future directions. Eye Contact Lens. 2019 Jan;45(1):1-10. https://doi.org/10.1097/ICL.0000000000000469 PMID: 30005051

8. Lin F, Zhang L, Wang Y, Fu D, Wang Y, Zhou X. A 20-year bibliometric analysis of Fuchs endothelial corneal dystrophy: from 2001 to 2020. BMC Ophthalmol. 2022 Jun 8;22(1):255. https://doi.org/10.1186/s12886-022-02468-x PMID: 35676652

9. Tone SO, Wylegala A, Böhm M, Melangath G, Deshpande N, Jurkunas UV. Increased corneal endothelial cell migration in Fuchs endothelial corneal dystrophy. Am J Ophthalmol. 2021 March1;1:100006 https://doi.org/10.1016/j.xops.2021.100006

10. Harayama K, Amemiya T, Nishimura H. Development of the cornea during fetal life: comparison of corneal and bulbar diameter. Anat Rec. 1980 Nov;198(3):531-5. https://doi.org/10.1002/ar.1091980313 PMID: 7457942

11. Mishima S, Hedbys BO. Physiology of the cornea. Int Ophthalmol Clin. 1968 Fall;8(3):527 PMID: 4243831

12. Kinoshita S, Adachi W, Sotozono C, Nishida K, Yokoi N, Quantock AJ, et al. Characteristics of the human ocular surface epithelium. Prog Retin Eye Res. 2001 Sep;20(5):639-73. https://doi.org/10.1016/s1350-9462(01)00007-6 PMID: 11470454

13. Dohlman CH. The function of the corneal epithelium in health and disease. The Jonas S. Friedenwald Memorial Lecture. Invest Ophthalmol. 1971 Jun;10(6):383-407. PMID: 4325305

14. Gipson IK, Spurr-Michaud SJ, Tisdale AS. Anchoring fibrils form a complex network in human and rabbit cornea. Invest Ophthalmol Vis Sci. 1987 Feb;28(2):212-20. PMID: 8591898

15. Hay ED, Linsenmayer TF, Trelstad RL, von der Mark K. Origin and distribution of collagens in the developing avian cornea. Curr Top Eye Res. 1979;1:1-35. PMID: 400678

16. Müller LJ, Pels L, Vrensen GF. Novel aspects of the ultrastructural organization of human corneal keratocytes. Invest Ophthalmol Vis Sci. 1995 Dec;36(13):2557-67. PMID: 7499078

17. Jester JV, Moller-Pedersen T, Huang J, Sax CM, Kays WT, Cavangh HD, et al. The cellular basis of corneal transparency: evidence for 'corneal crystallins'. J Cell Sci. 1999 Mar;112 (Pt 5):613-22. https://doi.org/10.1242/jcs.112.5.613 PMID: 9973596

18. Newsome DA, Gross J, Hassell JR. Human corneal stroma contains three distinct collagens. Invest Ophthalmol Vis Sci. 1982 Mar;22(3):376-81. PMID: 6277819

19. Johnson DH, Bourne WM, Campbell RJ. The ultrastructure of Descemet's membrane. I. Changes with age in normal corneas. Arch Ophthalmol. 1982 Dec;100(12):1942-7. https://doi.org/10.1001/archopht.1982.01030040922011 PMID: 7150061

20. Yee RW, Matsuda M, Schultz RO, Edelhauser HF. Changes in the normal corneal endothelial cellular pattern as a function of age. Curr Eye Res. 1985 Jun;4(6):671-8. https://doi.org/10.3109/02713688509017661 PMID: 4028790

21. Wulle KG, Lerche W. Electron microscopic observations of the early development of the human corneal endothelium and Descemet's membrane. Ophthalmologica. 1969;157(6):451-61. https://doi.org/10.1159/000305709 PMID: 5796012

22. Gilbert Smolin and Richard A. Thoft, The Cornea: Scientific Foundations and Clinical Practice. 4 ed, ed. C.S. Foster, D.T. Azar, and C.H. Dohlman. 2005, 530 Walnur Street, Philadelphia, PA 19106 USA: Lippincott Williams & Wilkins 1323

23. Johnson DH, Bourne WM, Campbell RJ. The ultrastructure of Descemet's membrane. I. Changes with age in normal corneas. Arch Ophthalmol. 1982 Dec;100(12):1942-7. https://doi.org/10.1001/archopht.1982.01030040922011 PMID: 7150061

24 Rae JL, Lewno AW, Cooper K, Gates P. Dye and electrical coupling between cells of the rabbit corneal endothelium. Curr Eye Res. 1989 Aug;8(8):859-69. https://doi.org/10.3109/02713688909000876 PMID: 2791630

25 Joyce NC, Harris DL, Zieske JD. Mitotic inhibition of corneal endothelium in neonatal rats. Invest Ophthalmol Vis Sci. 1998 Dec;39(13):2572-83. PMID: 9856767

26 Joyce NC. Proliferative capacity of corneal endothelial cells. Exp Eye Res. 2012 Feb;95(1):16-23. https://doi.org/10.1016/j.exer.2011.08.014 PMID: 21906590

27 Srinivas SA. Dynamic regulation of barrier integrity of the corneal endothelium. Optom Vis Sci. 2010 Apr;87(4):E239-54. https://doi.org/10.1097/OPX.0b013e3181d39464 PMID: 20142793

28 Sherrard ES, Ng YL. The other side of the corneal endothelium. Cornea. 1990 Jan;9(1):48-54. PMID: 2297995

29. He Z, Forest F, Gain P, Rageade D, Bernard A, Acquart S, et al. 3D map of the human corneal endothelial cell. Sci Rep. 2016 Jul 6;6:29047. https://doi.org/10.1038/srep29047 PMID: 27381832

30. Joyce NC. Proliferative capacity of corneal endothelium. Prog Retin Eye Res. 2003 May;22(3):359-89. https://doi.org/10.1016/s1350-9462(02)00065-4 PMID: 12852491

31. Bonanno JA. Identity and regulation of ion transport mechanisms in the corneal endothelium. Prog Retin Eye Res. 2003 Jan;22(1):69-94. https://doi.org/10.1016/s1350-9462(02)00059-9 PMID: 12597924

32. Tervo T, Palkama A. Electron microscopic localization of adenosine triphosphatase (NaK-ATPase) activity in the rat cornea. Exp Eye Res. 1975 Sep;21(3):269-79. https://doi.org/10.1016/0014-4835(75)90098-6 PMID: 126867

33. Mergler S, Pleyer U. The human corneal endothelium: new insights into electrophysiology and ion channels. Prog Retin Eye Res. 2007 Jul;26(4):359-78. https://doi.or/10.1016/j.preteyeres.2007.02.001 PMID: 17446115

34. Geroski DH, Matsuda M, Yee RW, Edelhauser HF. Pump function of the human corneal endothelium. Effects of age and cornea guttata. Ophthalmology. 1985 Jun;92(6):759-63. https://doi.org/10.1016/s0161-6420(85)33973-8 PMID: 2412197

35. Murphy C, Alvarado J, Juster R, Maglio M. Prenatal and postnatal cellularity of the human corneal endothelium. A quantitative histologic study. Invest Ophthalmol Vis Sci. 1984 Mar;25(3):312-22. PMID: 6698749

36. Bourne WM, Nelson LR, Hodge DO. Central corneal endothelial cell changes over a ten-year period. Invest Ophthalmol Vis Sci. 1997 Mar;38(3):779-82. PMID: 9071233

37. Williams KK, Noe RL, Grossniklaus HE, Drews-Botsch C, Edelhauser HF. Correlation of histologic corneal endothelial cell counts with specular microscopic cell density. Arch Ophthalmol. 1992 Aug;110(8):1146-9. https://doi.org/10.1001/archopht.1992.01080200126039 PMID: 1497530

38. Laule A, Cable MK, Hoffman CE, Hanna C. Endothelial cell population changes of human cornea during life. Arch Ophthalmol. 1978 Nov;96(11):2031-5. https://doi.org/10.1001/archopht.1978.03910060419003 PMID: 718491

39. Mehta D, Malik AB. Signaling mechanisms regulating endothelial permeability. Physiol Rev. 2006 Jan;86(1):279-367. https://doi.org/10.1152/physrev.00012.2005 PMID: 16371600

40. Laing RA, Sanstrom MM, Berrospi AR, Leibowitz HM. Changes in the corneal endothelium as a function of age. Exp Eye Res. 1976 Jun;22(6):587-94. https://doi.org/10.1016/0014-4835(76)90003-8 PMID: 776638

41. Laing RA, Sanstrom MM, Berrospi AR, Leibowitz HM. Changes in the corneal endothelium as a function of age. Exp Eye Res. 1976 Jun;22(6):587-94. https://doi.org/10.1016/0014-4835(76)90003-8 PMID: 776638

42. Hecht F. Letter: Partial trisomy 15 (dup15q) syndrome and the need for precision in clinical cytogenetics. J Pediatr. 1975 Nov;87(5):842-3. https://doi.org/10.1016/s0022-3476(75)80340-4 PMID: 1185371

43. Burns RR, Bourne WM, Brubaker RF. Endothelial function in patients with cornea guttata. Invest Ophthalmol Vis Sci. 1981 Jan;20(1):77-85. PMID: 6969713

44. Ventura AC, Wälti R, Böhnke M. Corneal thickness and endothelial density before and after cataract surgery. Br J Ophthalmol. 2001 Jan;85(1):18-20. https://doi.org/10.1136/bjo.85.1.18 PMID: 11133705

45. Erickson P, Doughty MJ, Comstock TL, Cullen AP. Endothelial cell density and contact lens-induced corneal swelling. Cornea. 1998 Mar;17(2):152-7. https://doi.org/10.1097/00003226-199803000-00006 PMID: 9520190

46. Amon M, Menapace R, Radax U, Papapanos P. Endothelial cell density and corneal pachymetry after no-stitch, small-incision cataract surgery. Doc Ophthalmol. 1992;81(3):301-7. https://doi.org/10.1007/BF00161768 PMID: 1483372

47. Olsen T. Corneal thickness and endothelial damage after intracapsular cataract extraction. Acta Ophthalmol (Copenh). 1980 Jun;58(3):424-33. https://doi.org/10.1111/j.1755-3768.1980.tb05743.x PMID: 7415829

48. Ravalico G, Tognetto D, Palomba MA, Lovisato A, Baccara F. Corneal endothelial function after extracapsular cataract extraction and phacoemulsification. J Cataract Refract Surg. 1997 Sep;23(7):1000-5. https://doi.org/10.1016/s0886-3350(97)80071-5 PMID: 9379368

49. Edelhauser HF. The balance between corneal transparency and edema: the Proctor Lecture. Invest Ophthalmol Vis Sci. 2006 May;47(5):1754-67. https://doi.org/10.1167/iovs.05-1139 PMID: 16638979

50. Gain P, Jullienne R, He Z, Aldossary M, Acquart S, Cognasse F, et al. Global Survey of Corneal Transplantation and Eye Banking. JAMA Ophthalmol. 2016 Feb;134(2):167-73. https://doi.org/10.1001/jamaophthalmol.2015.4776 PMID: 26633035

51. Moshirfar M, Somani AN, Vaidyanathan U, Patel BC. Fuchs Endothelial Dystrophy. StatPearls Publishing; 2022 Jan. 2022 May 24. PMID: 31424832

52. Moffatt SL, Cartwright VA, Stumpf TH. Centennial review of corneal transplantation. Clin Exp Ophthalmol. 2005 Dec;33(6):642-57. https://doi.org/10.1111/j.1442-9071.2005.01134.x PMID: 16402960

53. Power BJ, Power WJ (2022). Penetrating keratoplasty and complications management. In: Albert DM, Miller JW, Azar DT, Young LH (eds) Albert and Jakobiec's Principles and Practice of Ophthalmology. Springer, Cham. https://doi.org/10.1007/978-3-030-42634-7_220

54. Thompson RWJ, Price MO, Bowers PJ, Price FWJ. Long-term graft survival after penetrating keratoplasty. Ophthalmology. 2003 Jul;110(7):1396-402. https://doi.org/10.1016/S0161-6420(03)00463-9 PMID: 12867398

55. Patel SV. Graft survival after penetrating keratoplasty. Am J Ophthalmol. 2011 Mar;151(3):397-8. https://doi.org/10.1016/j.ajo.2010.10.006 PMID: 21335107

56. Melles GRJ. Posterior lamellar keratoplasty: DLEK to DSEK to DMEK. Cornea. 2006 Sep;25(8):879-81. https://doi.org/10.1097/01.ico.0000243962.60392.4f PMID: 17102659

57. Borderie VM, Boëlle PY, Touzeau O, Allouch C, Boutboul S, Laroche L. Predicted long-term outcome of corneal transplantation. Ophthalmology. 2009 Dec;116(12):2354-60. https://doi.org/10.1016/j.ophtha.2009.05.009 PMID: 19815285

58. Fernandez MM, Afshari NA. Endothelial keratoplasty: from DLEK to DMEK. Middle East Afr J Ophthalmol. 2010 Jan;17(1):5-8. https://doi.org/10.4103/0974-9233.61210 PMID: 20543930

59. Price MO, Feng MT, Price FWJ. Endothelial Keratoplasty Update 2020. Cornea. 2021 May 1;40(5):541-547. https://doi.org/10.1097/ICO.0000000000002565 PMID: 33252380

60. Farid M. Future Directions in Corneal Transplantation. A look at surgeries, donor tissue use, laser advances and more. Available from https://www.cornealphysician.com/issues/2020/april-2020/future-directions-in-corneal-transplantation (accessed on 3 August 2022)

61. Muijzer MB, van Luijk CM, van den Bogaerdt AJ, Kruit PJ, van Beek EG, Melles GRJ. Prospective evaluation of clinical outcomes between pre-cut corneal grafts prepared using a manual or automated technique: with one-year follow-up. Acta Ophthalmol. 2019 Nov;97(7):714-720. https://doi.org/10.1111/aos.14074 PMID: 30803143

62. Moutsouris K, Ham L, Dapena I, van der Wees J, Melles GRJ. Radial graft contraction may relate to subnormal visual acuity in Descemet stripping (automated) endothelial keratoplasty. Br J Ophthalmol. 2010 Jul;94(7):951-3. https://doi.org/10.1136/bjo.2009.167718 PMID: 20606030

63. Melles GR, Eggink FA, Lander F, Pels E, Rietveld FJ, Beekhuis WH, Binder PS. A surgical technique for posterior lamellar keratoplasty. Cornea. 1998 Nov;17(6):618-26. https://doi.org/10.1097/00003226-199811000-00010 PMID: 9820943

64. Melles GRJ, Wijdh RHJ, Nieuwendaal CP. A technique to excise the Descemet membrane from a recipient cornea (descemetorhexis). Cornea. 2004 Apr;23(3):286-8. https://doi.org/10.1097/00003226-200404000-00011 PMID: 15084862

65. Price FWJ, Price MO. Descemet's stripping with endothelial keratoplasty in 50 eyes: a refractive neutral corneal transplant. J Refract Surg. 2005 Jul-Aug;21(4):339-45. https://doi.org/10.3928/1081-597X-20050701-07 PMID: 16128330

66. Guilbert E, Bullet J, Sandali O, Basli EB, Laroche L, Borderie VM. Long-term rejection incidence and reversibility after penetrating and lamellar keratoplasty. Am J Ophthalmol. 2013 Mar;155(3):560-569.e2. https://doi.org/10.1016/j.ajo.2012.09.027 PMID: 23218931

67. Lee PWB, Jacobs DS, Musch DC, Kaufman SC, Reinhart WJ, Shtein RM. Descemet's stripping endothelial keratoplasty: safety and outcomes: a report by the American Academy of Ophthalmology. Ophthalmology. 2009 Sep;116(9):1818-30. https://doi.org/10.1016/j.ophtha.2009.06.021 PMID: 19643492

68. Melles GRJ, Lander F, Rietveld FJR. Transplantation of Descemet's membrane carrying viable endothelium through a small scleral incision. Cornea. 2002 May;21(4):415-8. https://doi.org/10.1097/00003226-200205000-00016 PMID: 11973393

69. Melles GRJ, Ong TS, Ververs B, van der Wees J. Descemet membrane endothelial keratoplasty (DMEK). Cornea. 2006 Sep;25(8):987-90. https://doi.org/10.1097/01.ico.0000248385.16896.34 PMID: 17102683

70. Melles GRJ, Ong TS, Ververs B, van der Wees J. Preliminary clinical results of Descemet membrane endothelial keratoplasty. Am J Ophthalmol. 2008 Feb;145(2):222-227. https://doi.org/10.1016/j.ajo.2007.09.021 PMID: 18061137

71. Dapena I, Moutsouris K, Droutsas K, Ham L, van Dijk K, Melles GRJ. Standardized "no-touch" technique for Descemet membrane endothelial keratoplasty. Arch Ophthalmol. 2011 Jan;129(1):88-94. https://doi.org/10.1001/archophthalmol.2010.334 PMID: 21220634

72. Maier, P., Reinhard, T. (2017). Long-term clear graft survival and chronic endothelial cell loss following posterior lamellar keratoplasty. In: Cursiefen, C., Jun, A. (eds) Current Treatment Options for Fuchs Endothelial Dystrophy. Springer, Cham. https://doi.org/10.1007/978-3-319-43021-8_14

73. Lam FK, Baydoun L, Dirisamer M, Lie J, Dapena I, Melles GRJ. Hemi-Descemet membrane endothelial keratoplasty transplantation: a potential method for increasing the pool of endothelial graft tissue. JAMA Ophthalmol. 2014 Dec;132(12):1469-73. https://doi.org/10.1001/jamaophthalmol.2014.3328 PMID: 25211529

74. Birbal RS, Hsien S, Zygoura V, Parker JS, Ham L, van Dijk K et al. Outcomes of Hemi-Descemet membrane endothelial keratoplasty for Fuchs endothelial corneal dystrophy. Cornea. 2018 Jul;37(7):854-858. https://doi.org/10.1097/ICO.0000000000001578 PMID: 29557816

75. Müller TM, Baydoun L, Melles GRJ. 3-Year update on the first case series of Hemi-Descemet membrane endothelial keratoplasty. Graefes Arch Clin Exp Ophthalmol. 2017 Jan;255(1):213-215. https://doi.org/10.1007/s00417-016-3517-5 PMID: 27783157

76. Baydoun L, Zygoura V, Hsien S, Birbal RS, Spinozzi D, Lie JT, et al. Clinical feasibility of using multiple grafts from a single donor for Quarter-DMEK. Acta Ophthalmol. 2018 Aug;96(5):e656-e658. https://doi.org/10.1111/aos.13720 PMID: 29498213

77. Zygoura V, Baydoun L, Ham L, Bourgonje VJA, van Dijk K, Lie JT et al. Quarter-Descemet membrane endothelial keratoplasty (Quarter-DMEK) for Fuchs endothelial corneal dystrophy: 6 months clinical outcome. Br J Ophthalmol. 2018 Oct;102(10):1425-1430. https://doi.org/10.1136/bjophthalmol-2017-311398 PMID: 29343529

78. Müller TM, Lavy I, Baydoun L, Lie JT, Dapena I, Melles GRJ. Case report of Quarter-Descemet membrane endothelial keratoplasty for Fuchs endothelial dystrophy. Cornea. 2017 Jan;36(1):104-107. https://doi.org/10.1097/ICO.0000000000001008 PMID: 27583798

79. Birbal RS, Ni Dhubhghaill S, Baydoun L, Ham L, Bourgonje VJA, Dapena I, et al. Quarter-Descemet membrane endothelial keratoplasty (Quarter-DMEK) for Fuchs endothelial corneal dystrophy: 6 months clinical outcome. Br J Ophthalmol. 2018 Oct;102(10):1425-1430. https://doi.org/10.1136/bjophthalmol-2017-311398 PMID: 31490274

80. Gerber-Hollbach N, Parker J, Baydoun L, Liarakos VS, Ham L, Dapena I et al. Preliminary outcome of hemi-Descemet membrane endothelial keratoplasty for Fuchs endothelial dystrophy. Br J Ophthalmol. 2016 Nov;100(11):1564-1568. https://doi.org/10.1136/bjophthalmol-2015-307783 PMID: 26837507

81. Birbal RS, Ni Dhubhghaill S, Baydoun L, Ham L, Bourgonje VJA, Dapena I et al. Quarter-Descemet membrane endothelial keratoplasty: one- to two-year clinical outcomes. Cornea. 2020 Mar;39(3):277-282. https://doi.org/10.1097/ICO.0000000000002127 PMID: 31490274

82. Dirisamer M, Yeh RY, van Dijk K, Ham L, Dapena I, Melles GRJ. Recipient endothelium may relate to corneal clearance in Descemet membrane endothelial transfer. Am J Ophthalmol. 2012 Aug;154(2):290-296.e1. https://doi.org/10.1016/j.ajo.2012.02.032 PMID: 22633346

83. Ziaei M, Barsam A, Mearza AA. Spontaneous corneal clearance despite graft removal in Descemet stripping endothelial keratoplasty in Fuchs endothelial dystrophy. Cornea. 2013 Jul;32(7):e164-6. https://doi.org/10.1097/ICO.0b013e31828b75a1 PMID: 23594769

84. Moloney G, Chan UT, Hamilton A, Zahidin AM, Grigg JR, Devasahayam RN. Descemetorhexis for Fuchs' dystrophy. Can J Ophthalmol. 2015 Feb;50(1):68-72. https://doi.org/10.1016/j.jcjo.2014.10.014 PMID: 25677286

85. Borkar DS, Veldman P, Colby KA. Treatment of Fuchs endothelial dystrophy by Descemet stripping without endothelial keratoplasty. Cornea. 2016 Oct;35(10):1267-73. https://doi.org/10.1097/ICO.0000000000000915 PMID: 27310885

86. Iovieno A, Neri A, Soldani AM, Adani C, Fontana L. Descemetorhexis without graft placement for the treatment of Fuchs endothelial dystrophy: preliminary results and review of the Literature. Cornea. 2017 Jun;36(6):637-641. https://doi.org/10.1097/ICO.0000000000001202 PMID: 28410355

87. Davies E, Jurkunas U, Pineda R. Predictive factors for corneal clearance after Descemetorhexis without endothelial keratoplasty. Cornea. 2018 Feb;37(2):137-140. https://doi.org/10.1097/ICO.0000000000001427 PMID: 29053562

88. Blitzer AL, Colby KA. Update on the Surgical management of Fuchs endothelial corneal dystrophy. Ophthalmol Ther. 2020 Dec;9(4):757-765. https://doi.org/10.1007/s40123-020-00293-3 PMID: 32840804

89. Davies E, Jurkunas U, Pineda R. Predictive factors for corneal clearance after Descemetorhexis without endothelial keratoplasty. Cornea. 2018 Feb;37(2):137-140. https://doi.org/10.1097/ICO.0000000000001427 PMID: 29053562

90. Moloney G, Petsoglou C, Ball M, Kerdraon Y, Höllhumer R, Spiteri N et al. Descemetorhexis without grafting for Fuchs endothelial dystrophy-supplementation with topical Ripasudil. Cornea. 2017 Jun;36(6):642-648. https://doi.org/10.1097/ICO.0000000000001209 PMID: 28476048

91. Huang MJ, Kane S, Dhaliwal DK. Descemetorhexis without endothelial keratoplasty versus DMEK for treatment of Fuchs endothelial corneal dystrophy. Cornea. 2018 Dec;37(12):1479-1483. https://doi.org/10.1097/ICO.0000000000001742 PMID: 30222714

92. Macsai MS, Shiloach M. Use of topical Rho Kinase inhibitors in the treatment of Fuchs dystrophy after Descemet stripping only. Cornea. 2019 May;38(5):529-534. https://doi.org/10.1097/ICO.0000000000001883 PMID: 30720541

93. Artaechevarria AJ, Wells M, Devasahayam RN, Moloney G. 5-Year outcomes of Descemet stripping only in Fuchs dystrophy. Cornea. 2020 Aug;39(8):1048-1051. https://doi.org/10.1097/ICO.0000000000002270 PMID: 31990847

94. Davies E, Jurkunas U, Pineda R. Pilot study of corneal clearance with the use of a Rho-kinase inhibitor after Descemetorhexis without endothelial keratoplasty for Fuchs endothelial corneal dystrophy. Cornea. 2021 Jul 1;40(7):899-902. https://doi.org/10.1097/ICO.0000000000002691 PMID: 33758139

95. Koizumi N, Okumura N, Ueno M, Nakagawa H, Hamuro J, Kinoshita S. Rho-associated kinase inhibitor eye drop treatment as a possible medical treatment for Fuchs corneal dystrophy. Cornea. 2013 Aug;32(8):1167-70. https://doi.org/10.1097/ICO.0b013e318285475d PMID: 23715376

96. Macsai MS, Shiloach M. Use of topical Rho kinase inhibitors in the treatment of Fuchs dystrophy after Descemet stripping only. Cornea. 2019 May;38(5):529-534. https://doi.org/10.1097/ICO.0000000000001883 PMID: 30720541

97. Ueno M, Toda M, Numa K, Tanaka H, Imai K, Bush J, et al. Superiority of mature differentiated cultured human corneal endothelial cell injection therapy for corneal endothelial failure. Am J Ophthalmol. 2022 May;237:267-277. https://doi.org/10.1016/j.ajo.2021.11.012 PMID: 34788595

98. Kinoshita S, Koizumi N, Ueno M, Okumura N, Imai K, Tanaka H, et al. Injection of cultured cells with a ROCK inhibitor for bullous keratopathy. N Engl J Med. 2018 Mar 15;378(11):995-1003. https://doi.org/10.1056/NEJMoa1712770 PMID: 29539291

99. Xia X, Atkins M, Dalal R, Kuzmenko O, Chang KC, Sun CB, et al. Magnetic human corneal endothelial cell transplant: delivery, retention, and short-term efficacy. Invest Ophthalmol Vis Sci. 2019 Jun 3;60(7):2438-2448. https://doi.org/10.1167/iovs.18-26001 PMID: 31158276

100. Dermot McGrath. Published: Thursday, December 3, 2020. Cell therapy for Fuchs' dystrophy. Published by EuroTimes for ESCRS. Accessed on August 5, 2022: https://www.escrs.org/eurotimes/cell-therapy-for-fuchs-dystrophy

101. Numa K, Imai K, Ueno M, Kitazawa K, Tanaka H, Bush JD, et al. Five-year follow-up of first 11 patients undergoing injection of cultured corneal endothelial cells for corneal endothelial failure. Ophthalmology. 2021 Apr;128(4):504-514. https://doi.org/10.1016/j.ophtha.2020.09.002 PMID: 32898516

102. CGTLive's Weekly Rewind – July 22, 2022. July 22, 2022 CGTLive Staff. Cell Therapy a Promising Option in Corneal Endothelial Disease. Accessed on August 5, 2022: Cell Therapy a Promising Option in Corneal Endothelial Disease (cgtlive.com)

Part I

DMEK graft analysis before and after transplantation

CHAPTER 2

In vivo endothelial cell density decline in the early postoperative phase after Descemet membrane endothelial keratoplasty (DMEK)

Cornea. 2018 Jun;37(6):673-677

Alina Miron, Marieke Bruinsma, Lisanne Ham, Sontje Schaal, Lamis Baydoun, Isabel Dapena, Silke Oellerich , Gerrit R.J. Melles

ABSTRACT

Purpose: To evaluate endothelial cell density (ECD) in the first 6 months after Descemet membrane endothelial keratoplasty (DMEK) by eliminating method error as a confounding variable.

Methods: From 24 DMEK eyes operated for Fuchs endothelial corneal dystrophy, from which specular microscopy images could be taken at 1 day and 6 months postoperatively, ECD values were compared between these 2 time points.

Results: Using the 1-day ECD measurement as baseline, mean ECD decreased from 1913 (±326) cells/mm^2 to 1524 (±393) cells/mm^2 at 6 months, a decline of -18 (±19)%. With the 1-week ECD as baseline [1658 (±395) cells/mm^2], the decline at 6 months was -6 (±19)% and when using preoperative ECD as baseline [2521 (±122) cells/mm^2], the decline was -39 (±16)% at 6 months.

Conclusions: After DMEK, ECD shows an *in vivo* decline of 18% from 1 day to 6 months postoperatively, with a sharp 13% drop in the first week, and a slower decrease thereafter. The remaining difference of 20% from preoperative ECD values may be attributed to a measurement error in the eye bank with an overestimation of the graft's viable endothelial cell population and/or intraoperative trauma to the graft.

INTRODUCTION

Descemet membrane endothelial keratoplasty (DMEK) is currently the most selective endothelial keratoplasty technique, by which only the diseased Descemet membrane (DM) and endothelium are replaced by a healthy donor.[1,2] With growing experience, DMEK may increasingly be preferred over Descemet stripping endothelial keratoplasty/ Descemet stripping automated endothelial keratoplasty owing to better visual outcomes,[3,4] a lower risk of interface haze, and a reduced chance of allograft rejection.[5,6]

Endothelial cell density (ECD) has been found to show a postoperative decrease comparable with earlier endothelial keratoplasty techniques, that is, 30% to 40% within the first 6 months after surgery followed by an annual decrease of 7% to 9% thereafter.[7–9] A postoperative ECD decrease for all endothelial keratoplasty techniques is usually reported for 6-month follow-up,[8,10,11] and it is therefore not known whether the perceived drop in ECD relates to the measurement error (light microscopy in the eye banks versus *in vivo* specular microscopy after surgery), intraoperative trauma to the graft, or a drop in central ECD in the first months after surgery.

Because DMEK often provides enough corneal deturgescence within the first 24 hours to enable specular microscopy, the purpose of our study was to use the 1-day ECD (instead of preoperative values) as baseline to evaluate the *in vivo* change in ECD within the early postoperative phase and to determine at which time points any change in *in vivo* ECD might occur.

METHODS

Of 46 consecutive DMEK surgeries performed for Fuchs endothelial corneal dystrophy, successful ECD images could be taken for 24 eyes of 24 patients on the first postoperative day, and these eyes were included in the study (**Figure 1**). For these 24 eyes, 13 patients (54%) were women and 11 were men with a mean age of 69 (±11) years (range 42–94 years). Six eyes (25%) were phakic and 18 (75%) pseudophakic (**Table 1**). All patients signed an institutional review board-approved informed consent form for research participation, and the study was conducted according to the Declaration of Helsinki.

Donor tissue protocol

The procedure for harvesting a DMEK graft has been previously described in detail.[12,13] Briefly, corneoscleral buttons were excised from donor globes obtained less than 36 hours postmortem and stored in organ culture medium at 15 to 31°C (CorneaMax, Eurobio, Courtaboeuf, France). After on average 1 week of culture, endothelial cell morphology and viability were evaluated again, and a 9.5 mm-diameter Descemet sheet with its endothelium was carefully stripped from the posterior stroma. Each “Descemet-roll” was then stored in organ culture medium until the time of transplantation (**Table 1**).[12] Preoperative donor ECD was assessed in vitro in the eye bank (Axiovert 40 inverted light microscope, Zeiss, Göttingen, Germany) after provoked swelling and staining with 0.04% trypan blue (Hippocratech, Rotterdam, The Netherlands)[12,13] and determined by manual counting according to the fixed-frame method.

Surgical protocol

All surgeries were performed according to the previously described DMEK technique.[2] After performing “descemetorhexis” under air,[14] a 3.0-mm tunnel incision was made for the insertion of the graft. The “Descemet-roll” was inserted endothelial side down (donor DM facing the recipient posterior stroma) into the recipient anterior chamber and then unfolded over the iris and positioned against the recipient posterior

stroma.[2] The anterior chamber was left completely filled with air for 60 minutes, followed by air-liquid exchange to pressurize the eye while leaving 30% to 50% air fill in the anterior chamber. Patients were instructed to remain supine for 48 to 72 hours after surgery. Postoperative medication included 0.5% chloramphenicol, 5 mg/mL ketorolac, and 0.1% dexamethasone eye drops for 4 weeks followed by a routine steroid tapering (fluorometholone) regimen over the course of a year.

Measurements and statistics

Routine follow-up examinations were performed at 1 day, 1 week, and at 1, 3, and 6 months after surgery. *In vivo* postoperative ECD was evaluated using noncontact specular microscopy (Topcon Medical Europe BV, Capelle a/d IJssel, The Netherlands). ECD analysis was performed by multiple trained technicians. For all endothelial images of the central corneal window, the automatically delineated cell borders (ImageNet software, Topcon Medical Europe BV) were carefully checked and in case they were not correctly assigned by the program, a "manual correction" was applied to reassign the cell borders. For every analysis, the largest possible part of the image was used, and measurements of 3 central images were averaged per follow-up time.

A paired t test was performed for ECD data comparison between preoperative and postoperative follow-up measurements. $P < .05$ was considered statistically significant.

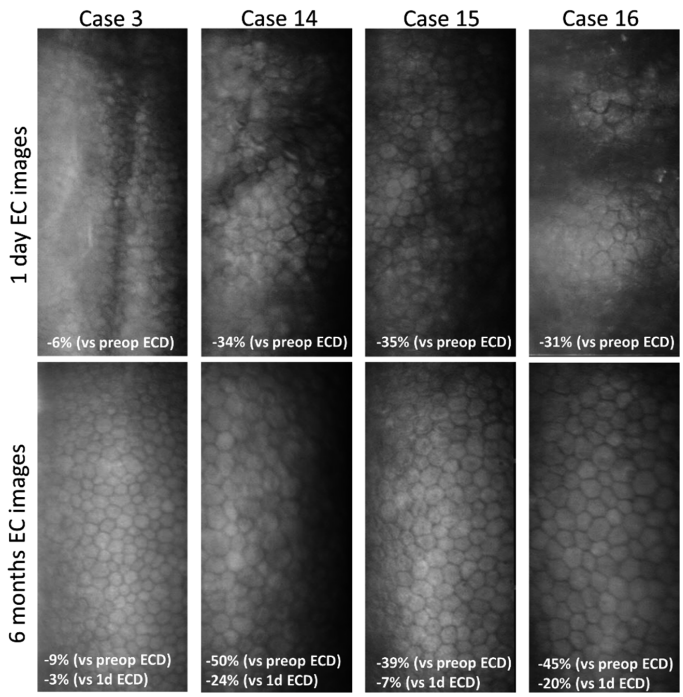

Figure 1| Specular microscopy images taken at 1 day and 6 months DMEK. One-day (upper row) and 6 months (bottom row) postoperative specular microscopy images are displayed for 4 cases. ECD decrease compared with preoperative donor ECD and with the 1 day ECD count are listed for each case.

Table 1. Demographics of DMEK Eyes

Patient and Donor Information	Group with successful 1d ECD count
Patient data	
No. of eyes (patients)	24 (24)
Gender	
Female	13 (54%)
Male	11 (46%)
Mean age (±SD) (range), yrs.	69 (±11), (42–94)
Preoperative lens status	
Pseudophakic	18 (75%)
Phakic	6 (25%)
Mean preoperative pachymetry (±SD), µm	661 (±56)
Donor data	
Gender	
Female	7 (29%)
Male	17 (71%)
Mean age (±SD) (range), yrs.	69 (±10), (46–82)
Mean storage time (±SD) (range), days	14 (±3), (8–20)
Mean time between last ECD evaluation and surgery (±SD) (range), days	9 (±3), (6–14)
Cause of death	
Cardio/Stroke	13 (54%)
Trauma	2 (8%)
Respiratory	5 (21%)
Cancer	2 (8%)
Other	2 (8%)
Mean donor ECD (±SD), cells/mm^2	2521 (±122)

RESULTS

Average central ECD decreased from 2521 (±122) cells/mm^2 preoperatively to 1913 (±326) cells/mm^2 at 1 day, to 1658 (±395) cells/mm^2 at 1 week, to 1629 (±367) cells/mm^2 at 1 month, to 1592 (±369) cells/mm^2 at 3 months, and to 1524 (±393) cells/mm^2 at 6 months. This corresponded to an ECD decrease of -39 (±16)% at 6 months compared with the preoperative value (**Table 2**, **Figure 2**).

When using the 1-day ECD measurement as a baseline value, mean ECD decreased by -13 (±14)% at 1 week, by -14 (±17)% at 1 month, by -15 (±19)% at 3 months, and by -18 (±19)% at 6 months. Using the 1-week ECD value as baseline, the ECD decrease was 0 (±16)% at 1 month, -3 (±19)% at 3 months, and -6 (±19)% at 6 months.

When comparing the average ECD between the consecutive follow-up time points, the initial decline between preoperative/1 day was -24 (±12)%, between 1 day/1 week -13 (±14%), between 1 week/1 month 0 (±16)%, between 1 month/3 months -3 (±10)%, and between 3 months/6 months -3 (±5)% ($P > 0.05$ for all paired time point comparisons after 1 week).

Although the average ECD decrease between 1 day/6 months was -18% (median 15%) within the study group, there was a large variation in the ECD decrease for this time interval ranging from +7% to -78% (**Table 2**).

Table 2. ECD and ECD decrease (ΔECD) after DMEK

Patient data			ECD, cells/mm^2				ΔECD		
Case	Age, yrs.	Lens Status	Preop.	1 d FU	1 w FU	6 mo FU	6 mo FU vs. Preop., %	6 mo FU vs. 1 d FU, %	6 mo FU vs. 1 w FU, %
1	94	Pseudophakic	2400	1768	NA	1432	-40%	-19%	NA
2	70	Pseudophakic	2700	2293	1734	1889	-30%	-18%	+9%
3	73	Pseudophakic	2600	2438	2440	2355	-9%	-3%	-3%
4	87	Pseudophakic	2600	2065	2327	1911	-26%	-7%	-18%
5	62	Pseudophakic	2700	2396	1457	536	-80%	-78%	-63%
6	79	Pseudophakic	2300	1870	1010	881	-62%	-53%	-13%
7	72	Pseudophakic	2600	1957	1413	1089	-58%	-44%	-23%
8	80	Pseudophakic	2400	2003	1852	2143	-11%	+7%	+16%
9	68	Phakic	2400	2120	1945	1789	-25%	-16%	-8%
10	68	Pseudophakic	2400	1265	942	1395	-42%	+10%	+48%
11	49	Phakic	2500	1956	1333	1220	-51%	-38%	-8%
12	71	Pseudophakic	2500	1237	1242	1222	-51%	-1%	-2%
13	42	Phakic	2600	1799	1882	1638	-37%	-9%	-13%
14	54	Pseudophakic	2500	1645	1409	1253	-50%	-24%	-10%
15	73	Pseudophakic	2500	1630	1629	1518	-39%	-7%	-7%
16	74	Pseudophakic	2300	1588	1410	1267	-45%	-20%	-10%
17	63	Pseudophakic	2400	2206	2097	1633	-32%	-26%	-22%
18	67	Pseudophakic	2800	2380	2225	2020	-28%	-15%	-9%
19	51	Phakic	2600	2163	1768	1821	-30%	-16%	+3%
20	76	Pseudophakic	2500	1822	1355	1182	-53%	-35%	-13%
21	69	Phakic	2500	1607	1452	1396	-44%	-13%	-4%
22	66	Phakic	2600	1828	1793	1846	-29%	+1%	+3%
23	78	Pseudophakic	2600	1644	1369	1515	-42%	-8%	+11%
24	67	Pseudophakic	2500	2240	2059	1978	-21%	-12%	-4%
Average			2521	1913	1658	1524	-39%	-18%	-6%
Standard Deviation			122	326	395	393	±16%	±19%	±19%
Median			2500	1913	1629	1516	-40%	-15%	-8%

ECD, endothelial cell density; FU, Follow-up; NA, not available; Preop, preoperative; ΔECD, ECD decrease.

DISCUSSION

Commonly, ECD decrease is considered one of the main outcome parameters in the evaluation of corneal transplantation procedures, both as a measure of efficacy and for predicting long-term graft survival.[15–17] For both Descemet stripping endothelial keratoplasty/Descemet stripping automated endothelial keratoplasty and DMEK, multiple studies have described an approximate 30% to 40% drop in ECD at 6 months after surgery, compared with preoperative values. So far, it has been unknown whether the ECD at 6 months reflects solely surgical trauma to the graft[3,17,18] or *in vivo* cell loss or redistribution. Also, it has been unknown at what time point any *in vivo* decrease in ECD might occur, and whether it reflects a gradual decrease or a sudden drop. In a small case series, we previously found a significant decrease in ECD within the first month after DMEK.[8] This finding triggered the current study that aimed to overcome the lack of reliable measurements in the early postoperative phase, using 1-day postoperative specular microscopy readings as baseline for *in vivo* ECD analysis.

Interestingly, our study showed that a -18% *in vivo* drop in ECD after DMEK occurred within the first 6 months after surgery and particularly within the first week after surgery. This finding may shed a different light on various causes that are hypothesized for the drop in ECD after DMEK, including endothelial cell migration and/or redistribution, after surgical inflammation or a subclinical immunological response and would indicate that approximately half of the apparent drop in ECD at 6 months occurs *in vivo*, that is, after transplantation.

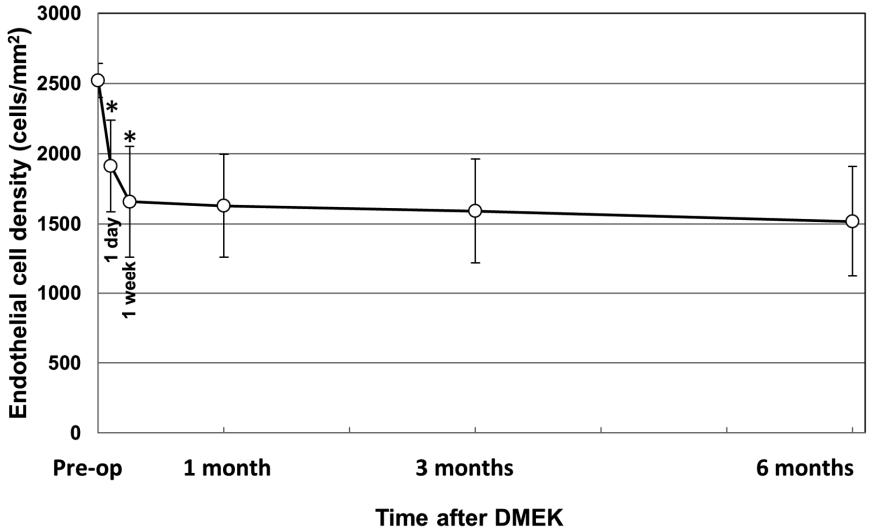

Figure 2| Preoperative and postoperative ECD after DMEK. ECD was measured preoperatively, and at 1 day, 1 week , 1 month, 3 months, and 6 months postoperatively. The highest ECD drop was observed at 1 day after surgery. Error bars represent SD. The t test was used for paired consecutive follow-up time points: *: $P \leq .05$.

On average, *in vivo* ECD dropped from day 1 to 1 week postoperatively by -13%, whereas the decrease between 1 week and 6 months was only -6%, indicating that different mechanisms may cause the *in vivo* ECD decrease. Endothelial cell migration and/or redistribution may contribute to the ECD drop within the first postoperative week, whereas the lower ECD decrease after 1 week may be caused by a subclinical immune reaction that had also been suggested to cause an ECD decrease in the longer term.[11,15,19,20] However, application of higher-dose steroids in the first postoperative week does not seem to influence postoperative ECD as shown in a recent study by Hoerster et al.[21]

When approximately half of the observed ECD decrease at 6 months occurs *in vivo*, the remaining decline in ECD as observed at 1 day postoperatively may be attributed to intraoperative trauma to the graft and/or a measurement error in the eye bank with an overestimation of the graft's viable endothelial cell population.[22–25] The latter has been addressed in a study by Pipparelli et al., which showed for endothelial grafts pre-dissected by eye banks that the actual pool of viable endothelial cells on the graft is commonly overestimated.[22] The same group showed in another study with paired organ cultured donor corneas, in which 1 cornea was used for penetrating keratoplasty (PK) and the contralateral cornea was used to determine the number of viable endothelial cells *in vitro*, that the number of viable cells counted in vitro was virtually similar to the ECD measured 5 days after PK.[23] Assuming that the number of viable cells is similar between eyes of the same pair, this suggests that the observed -30% drop in ECD at 5 days after PK was caused by a substantial overestimation of the number of viable endothelial cells on the graft. This is further substantiated by a recent study by Bhogal et al. in which global endothelial cell viability of DMEK grafts was assessed after preparation, and it was concluded that an early postoperative ECD reduction of up to -25% may be expected from tissue preparation alone.[25]

In conclusion, our study demonstrated that approximately half of the observed ECD decrease at 6 months after DMEK is an *in vivo* decline from 1 day to 6 months postoperatively, with a sharp -13% drop in the first week, and a slower decrease thereafter. The remaining decrease between preoperative and 1 day postoperative ECD values may be attributed to a measurement error in the eye bank with an overestimation of the graft's viable endothelial cell population and/or intraoperative trauma to the graft.

REFERENCES

1. Melles GR, Ong TS, Ververs B, van der Wees J. Descemet membrane endothelial keratoplasty (DMEK). Cornea. 2006 Sep;25(8):987-90. https://doi.org/10.1097/01.ico.0000248385.16896.34 PMID: 17102683
2. Dapena I, Moutsouris K, Droutsas K, Ham L, van Dijk K, Melles GR. Standardized "no-touch" technique for Descemet membrane endothelial keratoplasty. Arch Ophthalmol. 2011 Jan;129(1):88-94. https://doi.org/10.1001/archophthalmol.2010.334 PMID: 21220634
3. Rodríguez-Calvo-de-Mora M, Quilendrino R, Ham L, Liarakos VS, van Dijk K, Baydoun L, et al. Clinical outcome of 500 consecutive cases undergoing Descemet's membrane endothelial keratoplasty. Ophthalmology. 2015 Mar;122(3):464-70. https://doi.org/10.1016/j.ophtha.2014.09.004 PMID: 25439596
4. Guerra FP, Anshu A, Price MO, Price FW. Endothelial keratoplasty: fellow eyes comparison of Descemet stripping automated endothelial keratoplasty and Descemet membrane endothelial keratoplasty. Cornea. 2011 Dec;30(12):1382-6. https://doi.org/10.1097/ICO.0b013e31821ddd25 PMID: 21993468
5. Dapena I, Ham L, Netuková M, van der Wees J, Melles GR. Incidence of early allograft rejection after Descemet membrane endothelial keratoplasty. Cornea. 2011 Dec;30(12):1341-5. https://doi.org/10.1097/ICO.0b013e31820d8540 PMID: 21955628
6. Anshu A, Price MO, Price FW Jr. Risk of corneal transplant rejection significantly reduced with Descemet's membrane endothelial keratoplasty. Ophthalmology. 2012 Mar;119(3):536-40. https://doi.org/10.1016/j.ophtha.2011.09.019 PMID: 22218143
7. Baydoun L, Tong CM, Tse WW, Chi H, Parker J, Ham L, et al. Endothelial cell density after Descemet membrane endothelial keratoplasty: 1 to 5-year follow-up. Am J Ophthalmol. 2012 Oct;154(4):762-3. https://doi.org/10.1016/j.ajo.2012.06.025 PMID: 22995566
8. Quilendrino R, Höhn H, Tse WH, Chi H, Dapena I, Ham L, et al. Do we overestimate the endothelial cell "loss" after Descemet membrane endothelial keratoplasty? Curr Eye Res. 2013 Feb;38(2):260-5. https://doi.org/10.3109/02713683.2012.753095 PMID: 23294140
9. Feng MT, Price MO, Miller JM, Price FW Jr. Air reinjection and endothelial cell density in Descemet membrane endothelial keratoplasty: five-year follow-up. J Cataract Refract Surg. 2014 Jul;40(7):1116-21. https://doi.org/10.1016/j.jcrs.2014.04.023 PMID: 24957432
10. Schaub F, Enders P, Snijders K, Schrittenlocher S, Siebelmann S, Heindl LM, et al. One-year outcome after Descemet membrane endothelial keratoplasty (DMEK) comparing sulfur hexafluoride (SF6) 20% versus 100% air for anterior chamber tamponade. Br J Ophthalmol. 2017 Jul;101(7):902-908. https://doi.org/10.1136/bjophthalmol-2016-309653 PMID: 27836829
11. Schlögl A, Tourtas T, Kruse FE, Weller JM. Long-term clinical outcome after Descemet membrane endothelial keratoplasty. Am J Ophthalmol. 2016 Sep;169:218-226. https://doi.org/10.1016/j.ajo.2016.07.002 PMID: 27423793
12. Lie JT, Birbal R, Ham L, van der Wees J, Melles GR. Donor tissue preparation for Descemet membrane endothelial keratoplasty. J Cataract Refract Surg. 2008 Sep;34(9):1578-83. https://doi.org/10.1016/j.jcrs.2008.05.036 PMID: 18721723
13. Groeneveld-van Beek EA, Lie JT, van der Wees J, Bruinsma M, Melles GR. Standardized 'no-touch' donor tissue preparation for DALK and DMEK: harvesting undamaged anterior and posterior transplants from the same donor cornea. Acta Ophthalmol. 2013 Mar;91(2):145-50. https://doi.org/10.1111/j.1755-3768.2012.02462.x PMID: 22672202
14. Melles GR, Wijdh RH, Nieuwendaal CP. A technique to excise the Descemet membrane from a recipient cornea (descemetorhexis). Cornea. 2004 Apr;23(3):286-8. https://doi.org/10.1097/00003226-200404000-00011 PMID: 15084862
15. Baydoun L, Ham L, Borderie V, Dapena I, Hou J, Frank LE, et al. Endothelial survival after Descemet membrane endothelial keratoplasty: effect of surgical indication and graft adherence status. JAMA Ophthalmol. 2015 Nov;133(11):1277-85. https://doi.org/10.1001/jamaophthalmol.2015.3064 PMID: 26355238
16. Patel SV. Graft survival and endothelial outcomes in the new era of endothelial keratoplasty. Exp Eye Res. 2012 Feb;95(1):40-7. https://doi.org/10.1016/j.exer.2011.05.013 PMID: 21689649
17. Guerra FP, Anshu A, Price MO, Giebel AW, Price FW. Descemet's membrane endothelial keratoplasty: prospective study of 1-year visual outcomes, graft survival, and endothelial cell loss. Ophthalmology. 2011 Dec;118(12):2368-73. https://doi.org/10.1016/j.ophtha.2011.06.002 PMID: 21872938

18. Price MO, Price FW Jr. Endothelial cell loss after Descemet stripping with endothelial keratoplasty influencing factors and 2-year trend. Ophthalmology. 2008 May;115(5):857-65. https://doi.org/10.1016/j.ophtha.2007.06.033 PMID: 17868873
19. Ham L, Dapena I, Liarakos VS, Baydoun L, van Dijk K, Ilyas A, et al. Midterm results of Descemet membrane endothelial keratoplasty: 4 to 7 years clinical outcome. Am J Ophthalmol. 2016 Nov;171:113-121. https://doi.org/10.1016/j.ajo.2016.08.038 PMID: 27609712
20. Gerber-Hollbach N, Parker J, Baydoun L, Liarakos VS, Ham L, Dapena I, et al. Preliminary outcome of hemi-Descemet membrane endothelial keratoplasty for Fuchs endothelial dystrophy. Br J Ophthalmol. 2016 Nov;100(11):1564-1568. https://doi.org/10.1136/bjophthalmol-2015-307783 PMID: 26837507
21. Hoerster R, Stanzel TP, Bachmann BO, Siebelmann S, Cursiefen C. Intensified early postoperative topical steroids do not influence endothelial cell density after Descemet membrane endothelial keratoplasty combined with cataract surgery (Triple-DMEK). Cornea. 2016 Nov;35(11):1396-1400. https://doi.org/10.1097/ICO.0000000000000981 PMID: 27538194
22. Pipparelli A, Thuret G, Toubeau D, He Z, Piselli S, Lefèvre S, et al. Pan-corneal endothelial viability assessment: application to endothelial grafts predissected by eye banks. Invest Ophthalmol Vis Sci. 2011 Jul 29;52(8):6018-25. https://doi.org/10.1167/iovs.10-6641 PMID: 21666243
23. Gauthier AS, Garcin T, Thuret G, He Z, Jullienne R, Trone MC, et al. Very early endothelial cell loss after penetrating keratoplasty with organ-cultured corneas. Br J Ophthalmol. 2017 Aug;101(8):1113-1118. https://doi.org/10.1136/bjophthalmol-2016-309615 PMID: 27965261
24. Campolmi N, Trone MC, Nefzaoui C, Aldossary M, He Z, Acquart S, et al. Very early endothelial cell loss after simultaneous corneal autograft and allograft. Cornea. 2014 Feb;33(2):201-6. https://doi.org/10.1097/ICO.0000000000000030 PMID: 24342888
25. Bhogal M, Balda MS, Matter K, Allan BD. Global cell-by-cell evaluation of endothelial viability after two methods of graft preparation in Descemet membrane endothelial keratoplasty. Br J Ophthalmol. 2016 Apr;100(4):572-8. https://doi.org/10.1136/bjophthalmol-2015-307534 PMID: 26740609

CHAPTER 3

Endothelial cell viability after DMEK graft preparation

Curr Eye Res. 2021 Nov;46(11):1621-1630

Alina Miron, Anita Sajet, Esther A Groeneveld – van Beek, Jet Kok, Mehtap Dedeci, Maloeke de Jong, Vicky Amo-Addae, Gerrit R.J. Melles, Silke Oellerich, Jacqueline van der Wees

ABSTRACT

Aim: To evaluate the effect of graft preparation and organ-culture storage on endothelial cell density (ECD) and viability of Descemet membrane endothelial keratoplasty (DMEK) grafts.

Materials and methods: DMEK grafts (n = 27) were prepared at Amnitrans EyeBank Rotterdam from 27 corneas (15 donors) that were eligible for transplantation but could not be allocated due to the Covid-19-related cancellation of elective surgeries. Cell viability (by Calcein-AM staining) and ECD of five grafts originally scheduled for transplantation were evaluated on the originally planned surgery day, whereas 22 grafts from paired donor corneas were evaluated either directly post-preparation or after 3–7 days of storage. ECD was analyzed by light microscopy (LM ECD) and Calcein-AM staining (Calcein-ECD).

Results: Light microscopy (LM) evaluation of all grafts showed an unremarkable endothelial cell monolayer directly after preparation. However, median Calcein-ECD for the five grafts initially allocated for transplantation was 18% (range 9–73%) lower than median LM ECD. For the paired DMEK grafts, Calcein-ECD determined by Calcein-AM staining on the day of graft preparation and after 3–7 days of graft storage showed a median decrease of 1% and 2%, respectively. Median percentage of central graft area populated by viable cells after preparation and after 3–7 days of graft storage was 88% and 92%, respectively.

Conclusion: Cell viability of most of the grafts will not be affected by preparation and storage. Endothelial cell damage may be observed for some grafts within hours after preparation, with insignificant additional ECD changes during 3–7 days of graft storage. Implementing an additional post-preparation step in the eye bank to evaluate cell density before graft release for transplantation may help to reduce postoperative DMEK complications

INTRODUCTION

Descemet membrane endothelial keratoplasty (DMEK) is an increasingly popular treatment option for patients with corneal endothelial dysfunction, optimizing visual out- comes, recovery time, and rejection risk relative to previous generation of corneal transplantation, such as penetrating keratoplasty (PK) and Descemet stripping (automated) endothelial keratoplasty (DSAEK). Typical endothelial cell loss rates within the first 6 months after DMEK are reported to be 25–40%, followed by a slower decrease thereafter.[1–5] The majority of the observed cell loss after DMEK, however, actually occurs within the first week after DMEK.[6] At the same time, it was shown that endothelial cell loss after DMEK showed a high degree of variability between patients. Several studies tried to identify donor, recipient and surgery-related risk factors for endothelial cell loss after DMEK, with no consistent results so far.[5,7–10]

Next to focusing on the postoperative DMEK outcomes regarding endothelial cell loss, other studies aimed at validating graft preparation techniques. Some studies compared different graft preparation techniques[11,12] in terms of efficiency and observed endothelial cell loss. It was also evaluated whether, e.g., the speed of stripping,[13] type of graft storage,[14,15] other eye bank[16,17] or surgeon-related graft manipulations,[18,19] or the use of pre-loaded systems[20–23] would be associated with a reduction in endothelial cell density.

In a recent study,[6] we speculated that overestimation of endothelial cell viability on the DMEK graft may play a role and may result in an unrealistically high ECD drop in the early postoperative phase after DMEK. However, there is currently no possibility for eye banks to evaluate the endothelial cell viability of grafts allocated for transplantation. Typical graft evaluation in the eye bank is performed by trypan blue staining that fails to recognize apoptotic cells[24–26] and stained nuclei in a non-continuous area will not be discerned macroscopically.[27] Although in vitro analysis of endothelial integrity, including the analysis of sample subpopulations (apoptotic and necrotic), by using Calcein-AM staining was reported to be safe for pre-stained, pre-stripped, or pre-loaded DMEK grafts,[16,20–23] this protocol has not yet been approved for eye bank use.

While in vitro studies indicated that the endothelial cell counts provided by eye banks seem to overestimate the actual number of viable endothelial cells on a graft,[12,28] the use of research-grade tissue, i.e., corneas not eligible for transplantation, may not be directly comparable to surgery-grade tissue as the endothelial quality may often be lower to start with.

As a consequence of the COVID-19-related cancellation of elective surgeries in the Netherlands, we were able to analyze the endothelial cell density and viability of DMEK grafts on the day of the planned surgeries and additionally evaluated the effect of organ-culture storage on the endothelial cell density and viability of surgery-grade DMEK grafts.

MATERIALS AND METHODS

Corneas

Twenty-seven human corneas were obtained from 15 donors (mean age 70 (±8) years; range 59–85 years), for a total of 27 DMEK grafts. Prior to graft preparation, the average storage time was 21 (±6) days (range 9–29 days) and average ECD was 2588 (±139) cells/mm^2 (range 2300–2800 cells/mm^2) (**Table 1**). All corneas would have been eligible for transplantation but could either not be sent out after allocation (corneas #1–5) or could not be allocated (corneas #6–27) due to the COVID-19 related cancellation of elective surgeries. In all cases, the donors had stated to have no objection against transplant-related research and the study adhered to the tenets of the Declaration of Helsinki and the Barcelona Principles.[29] No institutional review board approval was obtained as under national regulation no approval is required for this research if no extra procedure was

performed to obtain the samples and donors had consented to having the samples used for research purposes (https://www.ccmo.nl/onderzoekers/aanvullende-informatie-over-bepaalde-soorten-onderzoek/niet-wmo-onderzoek/onderzoek-met-lichaamsmateriaal).

DMEK graft preparation techniques

All DMEK-grafts were prepared at Amnitrans EyeBank Rotterdam by means of hydrodissection[30] and/or no-touch DMEK graft preparation.[31,32] Briefly, to prepare the DMEK grafts, corneo-scleral rims were placed endothelial-side-up on a custom-made holder with a suction cup. The endothelium was then stained with 0.04% hypotonic trypan blue solution (Hippocratech, Rotterdam, The Netherlands) for 10 seconds for visualization. A 30-gauge needle mounted on a 2.5 mL syringe filled with 0.9% NaCl was inserted superficially through the tissue just peripheral to the pigmented trabecular meshwork and advanced until the entire bevel was in the cornea just past Schwalbe's line. NaCl was injected slowly until a peripheral separation "bubble" between the stroma and the Descemet membrane (DM) appeared, after which the needle was inserted in the bubble to enlarge the bubble until complete separation of the DM. In case of unsuccessful bubble formation, the same process was attempted at another site. After complete bubble formation, the peripheral DM was pierced with a 30-gauge needle and liquid was drawn from the bubble before an 8.5 mm trephination was performed directly on the cornea to complete the DMEK graft preparation.

In cases that no bubble could be formed, the "no-touch" DMEK graft preparation method was applied.[31,32] First, trabecular meshwork was loosened over 360° by pushing a hockey stick blade from the trabecular meshwork towards the corneal center. Then, by holding the trabecular meshwork with McPherson forceps and making gentle centripetal movements, the DM was carefully peeled from the posterior stroma before trephination with an 8.5 mm trephine.

Endothelial cell density of the corneas used for graft preparation was assessed in the eye bank with an inverted light microscope (Zeiss Axiovert 40C, Carl Zeiss International, Zaventem, Belgium) using the fixed frame method.[32] Endothelial cell density (ECD) of the DMEK rolls directly after preparation was determined on light microscopy (LM) images by averaging the counts performed manually on three fixed frames of 0.01 mm^2 per graft (reported as LM ECD). Grafts were considered eligible for transplantation if outcome of visual inspection after graft preparation was unremarkable (i.e., absence of bare DM areas or other irregularities), an ECD ≥ 2000 cells/mm^2 and negative microbiological testing to exclude possible contamination. For further analysis, grafts were transferred into a glass vial for storage in dextran-free organ-culture medium (CorneaMax, Eurobio, Cortaboeuf, France) at 31°C until the time of evaluation.

Light microscopy imaging and cell viability assay

For further analysis, grafts were carefully unfolded endothelial-side-up on a silane-precoated glass (Sigma–Aldrich Chemistry BV, Zwijndrecht, The Netherlands) by transferring the graft with a glass pipette from the storage vial to the glass support, and gently dropping organ-culture medium onto the graft until complete graft unfolding (**Figure 1a**). During the procedure, cellulose sponges were used to guide the movement of the liquid in such way that it would force the graft edges to flatten over the glass support. Next, DMEK grafts were stained with hypotonic trypan blue 0.04% solution to better visualize the tissue on the glass slide and then photographed with an AxioVert.A1 microscope with AxioCam 305 color camera (Zeiss, Oberkochen, Germany) (**Figure 1b,c**).

After light microscopy imaging, grafts were subjected to cell viability analysis. Each sample was covered with 100–150 µl of Dulbecco's phosphate-buffered saline (PBS) (Sigma–Aldrich Chemistry BV, Zwijndrecht, The Netherlands) containing Calcein-AM (4 µM) (Sigma–Aldrich Chemistry BV, Zwijndrecht, The Netherlands) and

incubated at room temperature (RT) for 45 min. After incubation, samples were washed with PBS and then imaged using an inverted fluorescence microscope. Multiple image tiles taken with a 50x magnification were combined and stitched together to create the graft panorama using Microsoft PowerPoint program.

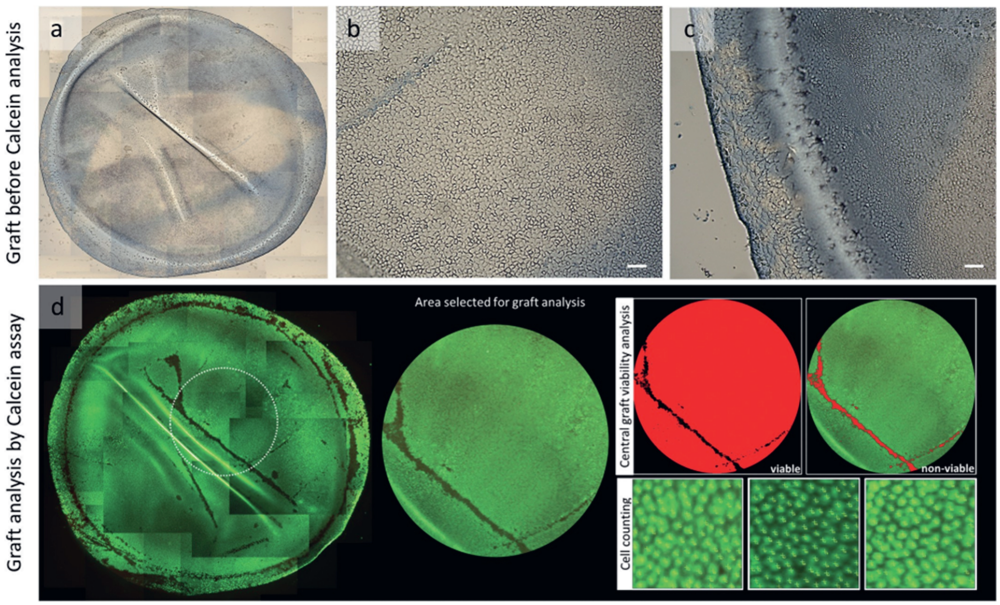

Figure 1| Representative images for the graft analysis before and after Calcein-AM staining. (a) Collage of light microscopy images (×50) to create the graft overview before cell viability investigation. (b) and (c) represent higher magnification areas (×100) of the graft displayed in (a), showing the endothelium at the central (b) and peripheral (c) regions. (d) Graft viability analysis process includes composite photos (×50) stitched together to create an image panorama of the graft stained with Calcein-AM (left). The central graft area (white dashed area in graft overview image) is then selected for cell viability analysis and endothelial cell density counting. The central graft viability analysis panel shows image segmentation and thresholding, with the viable and non-viable cell areas displayed in red. The cell counting panel displays three different frames (200 × 200 µm), selected in the white dashed area, wherein cell counting was performed using the multi-point function in ImageJ. Images are from graft #1 (**Table 1**). Scale bars = 100 µm.

Image analysis

Composite images were imported into FIJI open software for processing and analysis (https://imagej.net/Welcome). For each Calcein-AM-labeled DMEK graft, the graft area was manually defined, the background noise was removed, and the image underwent thresholding at different levels of image intensity and saturation. The presence of hyperfluorescent folds on some grafts caused some areas populated by viable cells to appear hypofluorescent rendering a low viability signal and, thus, underestimating graft viability. For this reason, next to analyzing the entire graft surface, also a circular area was selected centrally on the graft and with a diameter equal to one third of the entire graft diameter (**Figure 1d**, white-dashed line area). For both the entire graft and the selected central graft area, we were able to estimate the percentage of the area of the graft covered by viable cells (=viable cell area/total graft area) and the percentage of the non-viable graft area (=apoptotic and/or denuded graft area/total graft area). ECD on Calcein-stained grafts, reported as Calcein-ECD, was determined centrally on the graft by using the fixed-frame method like for the LM images taken directly after graft preparation. For Calcein-ECD, counting was performed in fixed frames of 0.04 mm^2 using the multi-

point tool to mark all cell centers and counts from three frames per graft were averaged. A half-cell was marked only if it could be paired with another unlabeled half- cell (**Figure 1d**, Cell counting panel). ECD differences were reported between the Calcein-AM-labeled DMEK graft (Calcein-ECD) and LM imaged DMEK rolls (LM ECD).

Statistical Analysis

Paired t-tests were performed to identify significant differences in outcomes between data (ECD and cell viability) collected at graft preparation time (day 0) and post-storage time (3 and 7 days). $P < .05$ was considered significant.

RESULTS

Cell density and viability analysis of DMEK grafts allocated for surgery

Due to the Covid-19 related cancellation of elective surgeries in the Netherlands in March 2020, 5 DMEK grafts from 4 donors that had been allocated and prepared for transplantation became available for research (**Table 1**, corneas #1-5). Endothelial cell density and viability of these grafts were evaluated on the days of the scheduled surgeries. Graft preparation by hydrodissection had been uneventful, except for one graft for which bubble formation was not successful and the graft had to be harvested using the "no-touch" peeling technique. Directly after preparation, standard visual inspection of the DMEK rolls by light microscopy (LM) had shown an unremarkable endothelial cell monolayer with a median LM ECD of 2600 cells/mm^2 and 2617 cells/mm^2 before and after preparation, respectively (mean LM ECD 2600 (±122) cells/mm^2 before and 2575 (±112) cells/mm^2 after preparation; P = .687). After 6 days of organ-culture storage, i.e., at the time of the scheduled surgery, median Calcein-ECD based on analysis of the Calcein-AM images had decreased to 2025 cells/mm^2 (mean ECD 1678 (±687) cells/mm^2; P=.058). Analysis of Calcein-AM images revealed that the percentage of central surface area covered by viable cells ranged from 57% to 97% (median 85%, mean 84 (±16)%) and for the entire graft surface area this ranged from 59% to 92% (median 80%, mean 78 (±13)%) (**Table 1** and **Figure 2**).

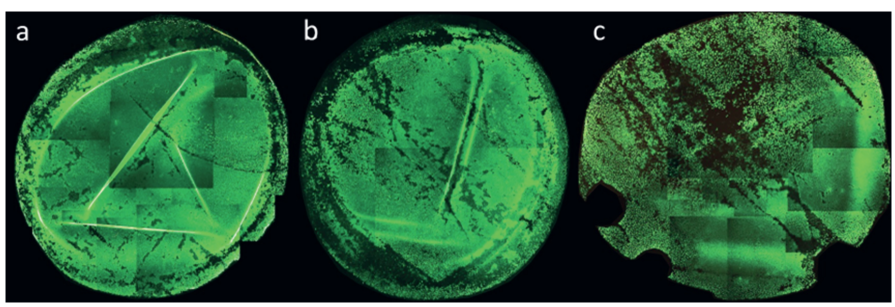

Figure 2| Example images representing Calcein-AM-stained DMEK grafts that had been allocated for transplantation. (a) Graft with a well maintained endothelial cell viability after 6 days in organ culture medium; (b) graft displaying mainly peripheral edge damage, probably induced during the trephination step in the graft preparation procedure; Calcein-AM-labeled cells showing a low level of fluorescence; (c) marked graft showing cell loss of about half of the surface area. Grafts were imaged on the planned day of the cancelled surgeries. Displayed grafts are (a) graft #2, (b) graft #4, and (c) graft #5.

Table 1. Basic donor demographics of corneas used for DMEK graft preparation.

# Cornea (Donor)	Donor age (y)	Gender	Cause of death	Diabetic status	Sepsis status	IOL scars	Preserv. time before graft prep. (days)	Preserv. time between graft prep. and cell viability analysis (days)	Graft prep. technique	ECD (cells/mm²) At cornea preserv. based on LM images	ECD (cells/mm²) Directly after DM stripping based on LM images	ECD (cells/mm²) Based on Ca-AM images (viable cells)	ECD difference between Ca-AM and LM images after DM stripping (%)	Central surface area covered by viable cells (%)	Graft area covered by viable cells (%)
Grafts initially allocated for transplantation, but surgery was cancelled due Covid-19-related cancellation of elective surgeries															
1 (1 R)	74	M	Circulatory syst.	No	Yes	No	9	6	Hydrod.	2600	2558	2317	9	97	92
2 (2 R)	78	M	Respiratory syst.	No	No	No	16	6	Hydrod.	2500	2392	2025	15	96	87
3 (2 L)	78	M	Respiratory syst.	No	No	No	16	6	Hydrod.	2500	2625	1175	55	85	80
4 (3 L)	71	F	Respiratory syst.	No	No	No	15	6	Hydrod.	2800	2617	2142	18	83	70
5 (4 L)	73	M	Circulatory syst.	No	No	No	12	6	Hydrod./NT	2600	2683	733	73	57	59
Median	74						15			2600	2617	2025	18	85	80
Mean (±SD)	75 (±5)						14 (±3)			2600 (±122)	2575 (±112)	1678 (±687)	34 (±28)	84 (±16)	78 (±13)
Paired grafts considered eligible for transplantation (but no allocation due to Covid-19 related cancellation of elective surgeries)															
6 (5 R)	70	M	Respiratory syst	No	Yes	No	29	0	Hydrod.	n.p.	2617	2583	1	83	71
7 (5 L)	70	M	Respiratory syst	No	Yes	No	29	3	Hydrod.	n.p.	2483	2592	-4	92	92
8 (6 R)	85	M	Other	Yes	Yes	No	28	0	Hydrod./NT	2400	2192	2283	-4	94	83
9 (6 L)	85	M	Other	Yes	Yes	No	28	3	Hydrod./NT	2300	2233	2367	-6	92	87
10 (7 R)	73	M	Circulatory syst.	No	No	No	21	0	Hydrod./NT	2800	2950	2750	7	85	81
11 (7 L)	73	M	Circulatory syst.	No	No	No	21	7	Hydrod./NT	2800	2850	2000	30	83	66
12 (8 R)	67	M	Circulatory syst.	No	Yes	Yes	19	0	Hydrod.	2700	2308	1625	30	38	44
13 (8 L)	67	M	Circulatory syst.	No	Yes	No	19	7	Hydrod.	2500	2533	333	87	60	27
14 (9 R)	73	M	Digestive syst	No	Yes	No	24	0	Hydrod.	2800	2650	2642	0	90	75
15 (9 L)	73	M	Digestive syst	No	Yes	No	24	7	Hydrod.	2700	2300	2317	-1	97	81
16 (10 R)	63	M	Circulatory syst.	No	No	No	23	0	Hydrod.	2500	2383	2350	1	95	83
17 (10 L)	63	M	Circulatory syst.	No	No	No	23	7	Hydrod.	2800	2449	2408	2	96	79
18 (11 R)	61	M	Other	No	No	No	22	0	Hydrod.	2500	2433	2417	1	88	91
19 (11 L)	61	M	Other	No	No	No	22	7	Hydrod./NT	2500	2500	2392	4	99	93
20 (12 R)	59	M	Respiratory syst	Yes	Yes	No	14	0	Hydrod.	2500	2300	2333	-1	89	82
21 (12 L)	59	M	Respiratory syst	Yes	Yes	No	14	0	Hydrod.	2500	2342	2317	1	91	77
22 (13 R)	77	M	Malign. neoplasms	No	Yes	No	29	0	Hydrod./NT	2500	2300	2017	12	47	53
23 (13 L)	77	M	Malign. neoplasms	No	Yes	No	29	0	NT	2600	2250	2175	3	88	75
24 (14 R)	60	M	Circulatory syst.	Yes	Yes	No	18	3	Hydrod.	2500	2475	2258	9	68	55
25 (14 L)	60	M	Circulatory syst.	Yes	Yes	No	18	3	Hydrod.	2500	2313	2125	8	81	68
26 (15 R)	75	F	Malign. neoplasms	No	Yes	No	18	3	Hydrod.	2600	2642	1558	41	73	62
27 (15 L)	75	F	Malign. neoplasms	No	Yes	No	18	3	Hydrod.	2700	2967	2683	10	90	79
Median	70						22			2500	2441	2325	3	89	78
Mean (±SD)	69 (±8)						22 (±5)			2585 (±146)	2476 (±224)	2206 (±515)	10 (±21)	83 (±16)	73 (±16)
All Grafts (n=27)															
Median	73						21			2500	2475	2317	7	88	79
Mean (±SD)	70 (±8)						21 (±6)			2588 (±139)	2494 (±210)	2108 (±575)	15 (±24)	83 (±16)	74 (±16)

Ca-AM: Calcein-AM staining; DM: Descemet membrane; ECD: endothelial cell density; F: female; Hydrod.: hydrodissection technique; IOL: intraocular lens; L: left donor cornea; LM: Light microscopy; M: male; Malign.: malignant; n.p.: not possible; NT: No-touch DMEK-graft preparation technique; Prep.: preparation; Preserv.: preservation; R: right donor cornea; SD: standard deviation; syst.: system

Table 2. Endothelial cell density and viability for grafts from paired donor corneas (corneas #6-27)

Statistical Parameters	ECD (cells/mm²) At cornea preservation based on LM images	ECD (cells/mm²) Directly after DM Stripping based on LM images	ECD (cells/mm²) Based on Ca-AM images	ECD difference between Ca-AM and LM images after DM stripping (%) [range]	Central surface area covered by viable cells (%) [range]	Graft surface area covered by viable cells (%) [range]
Evaluating effect of organ culture storage time (n=14)						
Evaluated directly after preparation (n=7)						
Median [range]	2600 [2400-2800]	2433 [2192-2950]	2417 [1625-2750]	1 [-4-30]	88 [38-95]	81 [44- 91]
Mean (±SD)	2617(±172)	2505 (±254)	2379 (±372)	5 (±11)	82 (±20)	75 (±15)
Evaluated after 3-7 days storage (n=7)						
Median [range]	2600 [2300-2800]	2483 [2233-2850]	2367 [333-2592]	2 [-6-87]	92 [60-99]	81 [27- 93]
Mean (±SD)	2600 (±200)	2478 (±198)	2058 (±781)	16 (±33)	88 (±14)	75 (±23)
All grafts (n=14)						
Median [range]	2600 [2300-2800]	2466 [2192-2950]	2380 [333-2750]	1 [-6-87]	91 [38-99]	81 [27-93]
Mean (±SD)	2608 (±178)	2492 (±219)	2219 (±611)	11 (±25)	85 (±17)	75 (±19)
Evaluating intra-donor variability (n=8)						
Grafts from right donor cornea (n=4)						
Median [range]	2500 [2500-2600]	2388 [2300-2642]	2138 [1558-2333]	11 [0-41]	71 [47-89]	59 [53-82]
Mean (±SD)	2525 (±50)	2429 (164)	2042 (±349)	15 (±18)	69 (±17)	63 (±13)
Grafts from left donor cornea (n=4)						
Median [range]	2550 [2500-2700]	2328 [2250-2967]	2246 [2125-2683]	6 [1-10]	89 [81-91]	76 [68-79]
Mean (±SD)	2575 (±96)	2468 (±335)	2325 (±252)	6 (±4)	88 (±5)	75 (±5)
All grafts (n=8)						
Median [range]	2500 [2500-2700]	2328 [2250-2967]	2217 [1558-2683]	8 [0-41]	85 [47-91]	72 [53-82]
Mean (±SD)	2550 (±76)	2449 (±245)	2183 (±320)	10 (±13)	78 (±15)	69 (±11)

Ca-AM: Calcein-AM staining; DM: Descemet membrane; ECD: endothelial cell density; LM: Light microscopy; Preserv.: preservation; SD: standard deviation

Effect of organ-culture storage on cell density and viability analysis of paired DMEK grafts

Based on the wide range of cell viability observed for the five grafts initially allocated for transplantation, additional tests with 14 DMEK grafts from paired donor corneas (**Table 1**, corneas #6–19) were performed to assess whether freshly prepared grafts would show less variability than grafts after organ-culture storage.

Median ECD assessed by light microscopy directly after DMEK graft preparation was 2466 cells/mm^2 (mean LM ECD 2492 (±219) cells/mm^2) (n = 14) as compared to 2600 cells/mm^2 (mean LM ECD 2608 (±178) cells/mm^2; P = .138) (n = 12) (Table 2) before preparation, with pre-preparation LM ECD calculated centrally on the donor cornea at the time of cornea preservation.

For grafts subjected to Calcein-AM staining on the day of the graft preparation (n = 7), median Calcein-ECD was 2417 cells/mm^2 (mean Calcein-ECD 2379 (±372) cells/mm^2) as compared to median LM-ECD of 2433 cells/mm^2 (mean LM ECD 2505 (±254) cells/mm^2; P = .247) determined directly after preparation. This corresponds to an average ECD difference between LM ECD and Calcein-ECD of 5 (±11)% (median decrease of 1%). Cell viability analysis performed on the day of graft preparation showed that, on average, 82 (±20)% (median 88%) (n = 7) of the central graft surface area and 75 (±15)% (median 81%) of the entire graft surface area was covered by viable cells (**Table 2**).

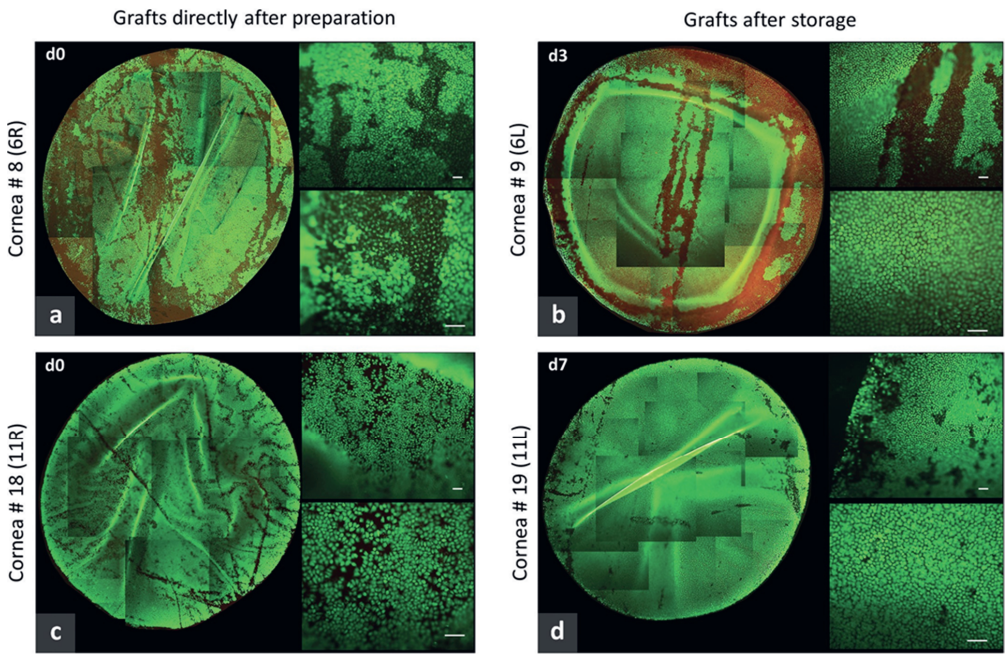

Figure 3| Representative images of paired grafts immediately after preparation and organ culture storage. Top row: Paired grafts #8 and 9 were imaged at d0 (day of preparation, (a) and after 3 days of organ culture storage (b). Bottom row: Paired grafts #18 and 19 were imaged at d0 (c) and after 7 days of organ culture storage (d). Every graft overview image is a collage of 50× image tiles stitched together, and two higher magnification images were included for a better visualization of endothelium integrity. Dark areas on the graft indicate apoptotic cells (a) or bare areas of DM (c). Scale bars = 100 µm.

Median Calcein-ECD of DMEK grafts analyzed after 3 to 7 days of graft storage in organ-culture medium (n = 7) was 2367 cells/mm^2 (mean Calcein-ECD 2058 (±781) cells/mm^2) as compared to 2417 cells/mm^2 (P = .155)

measured directly after preparation of grafts prepared from the contralateral corneas (n = 7) (**Table 2**). Assessment of cell viability following graft storage for 3–7 days showed that the median % central surface area populated by viable cells on the grafts was 92% (mean 88 (±14)%) (n = 7) compared to 88% (P = .0.089) measured directly after preparation of grafts prepared from the contralateral corneas and for the entire graft surface area the median remained at 81% (mean 75 (±23)%) (**Table 2** and **Figure 3**).

Noteworthy, the graft pair with the lowest area covered by viable cells (**Table 1**, corneas # 12 and 13), showed unremarkable endothelial cells upon LM inspection in the eye bank directly after preparation (**Figure 4a,f**) and both grafts were considered eligible for transplantation. However, about 3 hours later, LM inspection in the lab before Calcein-AM staining already showed cells with large nuclei (**Figure 4b**) and Calcein-AM staining revealed large areas of the graft devoid of viable cells (**Figure 4c–e**). Light microscopy and fluorescence imaging of the contralateral graft after 7 days of organ-culture storage showed sparsely distributed elongated endothelial cells (**Figure 4g–i**) that were not contact-inhibited.

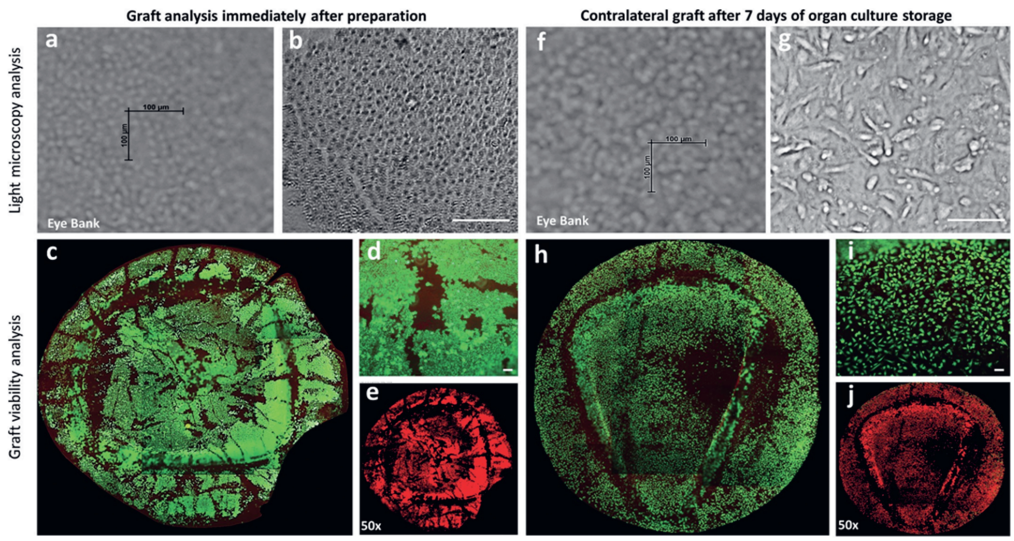

Figure 4| Paired donor graft analysis before and after Calcein-AM staining. (a–e): Analysis of graft #12 at day 0 after preparation in the eye bank; (f–j): Analysis of the contralateral graft (#13) after 7 days of organ culture storage. Displayed are representative brightfield images of the graft taken directly after preparation in the eye bank (a, f), taken about 3 hours after the preparation in the lab mounted on a glass cover slide (b, g), and fluorescence composite images after staining with Calcein-AM (c, h). (d) and (i) represent higher magnification images of the graft endothelium shown in (c) and (h), respectively. Especially in (d), the difference in fluorescence intensity between viable cells (higher fluorescence signal) and dying cells (low fluorescence signal) is evident. (e) and (j) represent the FIJI segmented images of the viable areas on the graft in (c) and (h), respectively. Scale bars = 100 µm.

Intra-donor variability of endothelial cell density and viability

Of four graft pairs (Table 1, corneas #20-27), grafts of two pairs were assessed directly after preparation and grafts of the other two pairs after 3 days of organ-culture storage. Overall, there was no significant difference between contralateral grafts in terms of average Calcein-ECD based on fluorescence images (mean Calcein-ECD 2042 (±349) cells/mm^2 vs. 2325 (±252) cells/mm^2; median Calcein-ECD 2138 cells/mm^2 vs. 2246 cells/mm^2) and central surface area covered by viable cells (mean 69 (±17)% vs. 88 (±5)%) (P = .396 and P =

.113, respectively) (**Table 2**). However, one pair (**Table 1**; corneas #26 and 27) had comparable LM ECD before and directly after preparation, but lower Calcein-ECD and central graft viability for one of the grafts after 3 days of graft storage (1558 cells/mm^2 vs. 2683 cells/mm^2 and 73% vs. 90%, respectively).

DISCUSSION

In this study, we have shown that vital dye staining of surgery-grade DMEK grafts revealed a high degree of variability in endothelial cell loss and in surface area covered by viable cells.

Overall, LM ECD determined centrally on the donor cornea at the time of cornea preservation and directly after DMEK graft preparation by counting in fixed-frames of 0.01 mm^2 with trypan blue staining in the eye bank, was almost similar in our study. All grafts were considered eligible for transplantation based on post-preparation LM ECD and light microscopy inspection of the endothelial cell layer. Mean Calcein-ECD determined centrally on the graft based on Calcein-AM analysis performed on the day of graft preparation was comparable to LM-ECD within the error margin of the fixed-frame method[33] for the majority of the grafts (8/11 grafts (73%)), while 2/11 grafts (18%) showed a slightly lower Calcein-ECD and one graft (9%) had a 30% lower Calcein-ECD. Overall, there was no significant difference in median Calcein-ECD depending on storage time, but the highest losses in Calcein-ECD were observed for grafts stored for 6 or 7 days, respectively.

Since the difference in LM-ECD and Calcein-ECD was within the error margin of the counting technique for most of the grafts, it is unlikely that the observed difference in eye bank determined LM ECD and Calcein-ECD based on Calcein-AM staining is due to cell damage induced by the graft handling for the Calcein-AM staining. Most likely the observed difference is due to the presence of apoptotic cells on the graft after preparation, which cannot be detected by trypan blue staining[34] and will be counted as viable endothelial cells in the eye bank. The presence of apoptotic cells on the grafts may not necessarily only be related to mechanical strain injury during graft preparation but also to stress-induced damage associated with donor death or even cornea procurement.[35] An already vulnerable endothelium before graft harvesting may not be able to maintain a proper cell repair mechanism after DM stripping, with some cells turning apoptotic and dropping off the DM. Another important parameter that could potentially affect the endothelial viability would be the ultrastructure of the DM. A DM may show resistance during cornea swelling in organ culture, forming folds that will deepen as swelling progresses, thereby compromising the surrounding cells.[36,37] Thus, after graft preparation, cells that had surrounded the folds could be shed off allowing the endothelium to heal but clearly resulting in a lower ECD compared to pre-preparation ECD.

Our data showed a median difference of about 2% between Calcein-ECD evaluated on the day of graft preparation (2417 cells/mm^2) and after 3–7 days of storage (2367 cells/mm^2) and suggest that in general the apoptotic cell population observed after graft preparation may not increase during graft storage as this would in time translate to a loss of Calcein-ECD. This finding is in line with a recent study showing an 11% ECD loss caused by the preparation with no further statistically significant Calcein-ECD loss occurring during 5 days of culture storage.[38] A series of recent studies, focusing on the effect of short-term storage time on cell viability showed that organ-cultured DMEK grafts[16,39] or grafts preloaded and then stored for up to 3 days in cold-storage[20,21,23,40] did not show a consistent or significant difference in ECD or cell viability when compared to uncultured grafts. However, in some cases of grafts with pronounced endothelial cell damage developed during the preparation, a further reduction in ECD during storage seems to occur as shown in our study, which can probably be caused by the redistribution of viable endothelial cells by migration to the areas where the cells were dead and detached. This may then result in a reported reduction of graft surface area covered by viable cells of on average 40%.[40] Larger studies with high-quality grafts, however, may be needed to shed more light on the overall effect of storage time on endothelial cells as this effect may not only be directly reflected by an

ECD loss but could also be more subtle and resulting in an elevated cellular stress level. The latter could lead to cells being more susceptible to damage caused by surgical manipulation.[41]

The large variability in the observed loss of Calcein-ECD after graft preparation may explain the clinical observation of a large variability in early endothelial cell loss after DMEK with an ECD decrease of up to 50% in some eyes as early as 1 day postoperatively.[6] This variability in postoperative ECD has been shown to persist also at longer follow-up times[5,42] and DMEK grafts with a low ECD at 6-month postoperatively have a significantly lower graft survival probability at 5-year postoperatively.[43]

This underlines the clinical importance of developing a better method for post-preparation graft screening in the eye bank to avoid transplanting grafts with a low density of viable endothelial cells. Therefore, the use of a florescent vital dye, such as Calcein-AM, to clearly visualize live and ideally also apoptotic cells could possibly assist eye bankers in the early detection of DMEK tissue of poor quality. Though Bhogal et al.[18,44] demonstrated the efficiency and safety of using Calcein-AM for cell evaluation across the entire surface of a corneal transplant in vitro, regulatory and safety concerns as well as economic considerations may prevent eye banks from implementing such a step in their current protocol. Another less invasive and less time-consuming alternative may be an additional graft evaluation by light microscopy within 1 day after graft preparation. Any loss in cell density and integrity of the endothelial cell layer could already be recognizable at this time and may allow to detect low-quality grafts before sending them out for transplantation.

One limitation of our analysis is the small number of grafts tested in every group from graft preparation through storage in organ-culture, limiting the accuracy of the cell viability analysis. On the other hand, these grafts were prepared from surgical-grade corneas that arrived in our eye bank before the cancellation of elective surgeries due to the COVID-19 pandemic and would have never been made available for research outside the nationwide lockdown context. In addition, our single dye method cannot ascertain whether non-stained areas contain dead cells or no cells. However, Calcein-AM is known to recognize cells in both early and late stages of cells death[45] and these areas will be accurately identified by the image segmentation software and rendered “non-viable” in the analysis.

CONCLUSION

In conclusion, our findings show that endothelial cell damage may be observed within hours after DMEK graft preparation with insignificant additional changes in ECD during 3–7 days of organ-culture storage before use in DMEK surgery. Implementing an additional step for checking tissue quality in the eye bank after preparation may improve the quality of DMEK grafts released for transplantation and thereby contribute to further reducing post-operative DMEK complications.

REFERENCES

1. Birbal RS, Baydoun L, Ham L, Miron A, van Dijk K, Dapena I, et al. Effect of surgical indication and preoperative lens status on Descemet membrane endothelial keratoplasty outcomes. Am J Ophthalmol. 2020 Apr;212:79-87. https://doi.org/10.1016/j.ajo.2019.12.011 PMID: 31863726
2. Schrittenlocher S, Schaub F, Hos D, Siebelmann S, Cursiefen C, Bachmann B. Evolution of consecutive Descemet membrane endothelial keratoplasty outcomes throughout a 5-year period performed by two experienced surgeons. Am J Ophthalmol. 2018 Jun;190:171-178. https://doi.org/10.1016/j.ajo.2018.03.036 PMID: 29621512
3. Hamzaoglu EC, Straiko MD, Mayko ZM, Sáles CS, Terry MA. The First 100 eyes of standardized Descemet stripping automated endothelial keratoplasty versus standardized Descemet membrane endothelial keratoplasty. Ophthalmology. 2015 Nov;122(11):2193-9. https://doi.org/10.1016/j.ophtha.2015.07.003 PMID: 26271841
4. Deng SX, Lee WB, Hammersmith KM, Kuo AN, Li JY, Shen JF, et al. Descemet membrane endothelial keratoplasty: safety and outcomes: a report by the American Academy of Ophthalmology. Ophthalmology. 2018 Feb;125(2):295-310. https://doi.org/10.1016/j.ophtha.2017.08.015 PMID: 28923499
5. Oellerich S, Ham L, Frank LE, Gorges S, Bourgonje VJA, Baydoun L, et al. Parameters associated with endothelial cell density variability after Descemet membrane endothelial keratoplasty. Am J Ophthalmol. 2020 Mar;211:22-30. https://doi.org/10.1016/j.ajo.2019.10.017 PMID: 31647928
6. Miron A, Bruinsma M, Ham L, Schaal SC, Baydoun L, Dapena I, et al. %endothelial cell density decline in the early postoperative phase after Descemet membrane endothelial keratoplasty. Cornea. 2018 Jun;37(6):673-677. https://doi.org/10.1097/ICO.0000000000001484 PMID: 29737973
7. Hayashi T, Schrittenlocher S, Siebelmann S, Le VNH, Matthaei M, Franklin J, et al. Risk factors for endothelial cell loss after Descemet membrane endothelial keratoplasty (DMEK). Sci Rep. 2020 Jul 6;10(1):11086. https://doi.org/10.1038/s41598-020-68023-0 PMID: 32632151
8. Peraza-Nieves J, Baydoun L, Dapena I, Ilyas A, Frank LE, Luceri S, et al. Two-year clinical outcome of 500 consecutive cases undergoing Descemet membrane endothelial keratoplasty. Cornea. 2017 Jun;36(6):655-660. https://doi.org/10.1097/ICO.0000000000001176 PMID: 28410548
9. Brockmann T, Pilger D, Brockmann C, Maier AB, Bertelmann E, Torun N. Predictive factors for clinical outcomes after primary Descemet's membrane endothelial keratoplasty for Fuchs' endothelial dystrophy. Curr Eye Res. 2019 Feb;44(2):147-153. https://doi.org/10.1080/02713683.2018.1538459 PMID: 30339062
10. Price MO, Lisek M, Feng MT, Price FW Jr. Effect of donor and recipient diabetes status on Descemet membrane endothelial keratoplasty adherence and survival. Cornea. 2017 Oct;36(10):1184-1188. https://doi.org/10.1097/ICO.0000000000001305 PMID: 28749899.
11. Parekh M, Borroni D, Ruzza A, Levis HJ, Ferrari S, Ponzin D, et al. A comparative study on different Descemet membrane endothelial keratoplasty graft preparation techniques. Acta Ophthalmol. 2018 Sep;96(6):e718-e726. https://doi.org/10.1111/aos.13746 PMID: 29520992
12. Bhogal M, Balda MS, Matter K, Allan BD. Global cell-by-cell evaluation of endothelial viability after two methods of graft preparation in Descemet membrane endothelial keratoplasty. Br J Ophthalmol. 2016 Apr;100(4):572-8. https://doi.org/10.1136/bjophthalmol-2015-307534 PMID: 26740609
13. Borroni D, Gadhvi K, Wojcik G, Pennisi F, Vallabh NA, Galeone A, et al. The influence of speed during stripping in Descemet membrane endothelial keratoplasty tissue preparation. Cornea. 2020 Sep;39(9):1086-1090. https://doi.org/10.1097/ICO.0000000000002338 PMID: 32301812
14. Garcin T, Gauthier AS, Crouzet E, He Z, Herbepin P, Perrache C, et al. Three-month storage of human corneas in an active storage machine. Transplantation. 2020 Jun;104(6):1159-1165. https://doi.org/10.1097/TP.0000000000003109 PMID: 31895867
15. Romano V, Parekh M, Ruzza A, Willoughby CE, Ferrari S, Ponzin D, et al. Comparison of preservation and transportation protocols for preloaded Descemet membrane endothelial keratoplasty. Br J Ophthalmol. 2018 Apr;102(4):549-555. https://doi.org/10.1136/bjophthalmol-2017-310906 PMID: 29133296
16. He Z, Gueudry J, Toubeau D, Gain P, Thuret G, Muraine M. Endothelial quality of eye bank-prestripped DMEK prepared form organ-cultured corneas with the Muraine technique. Cell Tissue Bank. 2018 Dec;19(4):705-716. https://doi.org/10.1007/s10561-018-9723-0 PMID: 30171415
17. Mayko ZM, Benetz BA, Menegay H, Donovan CP, Stoeger CG, Terry MA, et al. Donor endothelial cell density measurements do not change immediately after DMEK preparation. Cornea. 2016 Dec;35(12):1556-1561. https://doi.org/10.1097/ICO.0000000000001044 PMID: 27741015

18. Bhogal M, Lwin CN, Seah XY, Murugan E, Adnan K, Lin SJ, et al. Real-time assessment of corneal endothelial cell damage following graft preparation and donor insertion for DMEK. PLoS One. 2017 Oct 4;12(10):e0184824. https://doi.org/10.1371/journal.pone.0184824 PMID: 28977017
19. Tran KD, Alabi RO, Odell K, Dye PK, Downes K, Sales CS. Measuring endothelial cell loss on DMEK grafts after transplantation in human cadaveric whole eyes: description of the technique and pilot study. Cornea. 2018 Aug;37(8):1075-1080. https://doi.org/10.1097/ICO.0000000000001602 PMID: 29634671
20. Barnes K, Chiang E, Chen C, Lohmeier J, Christy J, Chaurasia A, et al. Comparison of tri-folded and scroll-based graft viability in preloaded Descemet membrane endothelial keratoplasty. Cornea. 2019 Mar;38(3):392-396. https://doi.org/10.1097/ICO.0000000000001831 PMID: 30550395
21. Wolle MA, DeMill DL, Johnson L, Lentz SI, Woodward MA, Mian SI. Quantitative analysis of endothelial cell loss in preloaded Descemet membrane endothelial keratoplasty grafts. Cornea. 2017 Nov;36(11):1295-1301. https://doi.org/10.1097/ICO.0000000000001301 PMID: 28991851
22. Tran KD, Dye PK, Odell K, Galloway J, Stoeger CG, Straiko MD, et al. Evaluation and quality assessment of prestripped, preloaded Descemet membrane endothelial keratoplasty grafts. Cornea. 2017 Apr;36(4):484-490. https://doi.org/10.1097/ICO.0000000000001150 PMID: 28129302
23. Zeidenweber DA, Tran KD, Sales CS, Wehrer SW, Straiko MD, Terry MA. Prestained and preloaded DMEK Grafts: an evaluation of tissue quality and stain retention. Cornea. 2017 Nov;36(11):1402-1407. https://doi.org/10.1097/ICO.0000000000001329 PMID: 28837527
24. Sgonc R, Gruber J. Apoptosis detection: an overview. Exp Gerontol. 1998 Sep;33(6):525-33. https://doi.org/10.1016/s0531-5565(98)00031-x. PMID: 9789730
25. Fischer S, Maclean AA, Liu M, Cardella JA, Slutsky AS, Suga M, et al. Dynamic changes in apoptotic and necrotic cell death correlate with severity of ischemia-reperfusion injury in lung transplantation. Am J Respir Crit Care Med. 2000 Nov;162(5):1932-9. https://doi.org/10.1164/ajrccm.162.5.9910064 PMID: 11069837
26. Gain P, Thuret G, Chiquet C, Dumollard JM, Mosnier JF, Burillon C, et al. Value of two mortality assessment techniques for organ cultured corneal endothelium: trypan blue versus TUNEL technique. Br J Ophthalmol. 2002 Mar;86(3):306-10. https://doi.org/10.1136/bjo.86.3.306 PMID: 11864889
27. Sperling S. Early morphological changes in organ cultured human corneal endothelium. Acta Ophthalmol (Copenh). 1978 Oct;56(5):785-92. https://doi.org/10.1111/j.1755-3768.1978.tb06643.x PMID: 80914
28. Pipparelli A, Thuret G, Toubeau D, He Z, Piselli S, Lefèvre S, et al. Pan-corneal endothelial viability assessment: application to endothelial grafts predissected by eye banks. Invest Ophthalmol Vis Sci. 2011 Jul 29;52(8):6018-25. https://doi.org/10.1167/iovs.10-6641 PMID: 21666243
29. The Barcelona Principles: An agreement on the use of human donated tissue for ocular transplantation, research, and future technologies©. Cornea. 2018 Oct;37(10):1213-1217. https://doi.org/10.1097/ICO.0000000000001675 PMID: 30198942
30. Szurman P, Januschowski K, Rickmann A, Damm LJ, Boden KT, Opitz N. Novel liquid bubble dissection technique for DMEK lenticule preparation. Graefes Arch Clin Exp Ophthalmol. 2016 Sep;254(9):1819-23. https://doi.org/10.1007/s00417-016-3377-z PMID: 27207467
31. Lie JT, Birbal R, Ham L, van der Wees J, Melles GR. Donor tissue preparation for Descemet membrane endothelial keratoplasty. J Cataract Refract Surg. 2008 Sep;34(9):1578-83. https://doi.org/10.1016/j.jcrs.2008.05.036 PMID: 18721723
32. Groeneveld-van Beek EA, Lie JT, van der Wees J, Bruinsma M, Melles GR. Standardized 'no-touch' donor tissue preparation for DALK and DMEK: harvesting undamaged anterior and posterior transplants from the same donor cornea. Acta Ophthalmol. 2013 Mar;91(2):145-50. https://doi.org/10.1111/j.1755-3768.2012.02462.x PMID: 22672202
33. Campolmi N, Acquart S, He Z, Gavet Y, Jullienne R, Naigeon N, et al. Inherent errors of the fixed-frame counting method for corneal endothelial cell density in eye banks. Cell Tissue Bank. 2014 Sep;15(3):451-9. https://doi.org/10.1007/s10561-013-9411-z PMID: 24292237
34. Leite M, Quinta-Costa M, Leite PS, Guimarães JE. Critical evaluation of techniques to detect and measure cell death--study in a model of UV radiation of the leukaemic cell line HL60. Anal Cell Pathol. 1999;19(3-4):139-51. https://doi.org/10.1155/1999/176515 PMID: 10866276
35. Doughman DJ. Prolonged donor cornea preservation in organ culture: long-term clinical evaluation. Trans Am Ophthalmol Soc. 1980;78:567-628. PMID: 7020215

36. Albon J, Tullo AB, Aktar S, Boulton ME. Apoptosis in the endothelium of human corneas for transplantation. Invest Ophthalmol Vis Sci. 2000 Sep;41(10):2887-93. PMID: 10967041
37. Nejepinska J, Juklova K, Jirsova K. Organ culture, but not hypothermic storage, facilitates the repair of the corneal endothelium following mechanical damage. Acta Ophthalmol. 2010 Jun;88(4):413-9. https://doi.org/10.1111/j.1755-3768.2008.01490.x PMID: 19604163
38. Safi T, Seitz B, Berg K, Schulz K, Langenbucher A, Daas L. Reproducibility of non-invasive endothelial cell loss assessment of the prestripped DMEK roll after preparation and storage. Am J Ophthalmol. 2021 Jan;221:17-26. https://doi.org/10.1016/j.ajo.2020.08.001 PMID: 32795433
39. GamalElDin SA, Salama MM, ElShazly MI. Seven-day storage of pneumatically dissected Descemet's endothelial grafts with and without Dua's layer. Acta Ophthalmol. 2016 Mar;94(2):e130-4. https://doi.org/10.1111/aos.12823 PMID: 26310820
40. Català P, Vermeulen W, Rademakers T, van den Bogaerdt A, Kruijt PJ, Nuijts RMMA, et al. Transport and preservation comparison of preloaded and prestripped-only DMEK grafts. Cornea. 2020 Nov;39(11):1407-1414. https://doi.org/10.1097/ICO.0000000000002391 PMID: 32467448
41. Patel SV, Lass JH, Benetz BA, Szczotka-Flynn LB, Cohen NJ, Ayala AR, et al. Postoperative endothelial cell density is associated with late endothelial graft failure after Descemet stripping automated endothelial keratoplasty. Ophthalmology. 2019 Aug;126(8):1076-1083. https://doi.org/10.1016/j.ophtha.2019.02.011 PMID: 30790587
42. Musayeva A, Livny E, Dragnea DC, Ham L, Vasiliauskaitė I, Ní Dhubhghaill S, et al. Endothelial cell density changes in the corneal center versus paracentral areas after Descemet membrane endothelial keratoplasty. Cornea. 2020 Sep;39(9):1091-1095. https://doi.org/10.1097/ICO.0000000000002326 PMID: 32282357
43. Vasiliauskaitė I, Quilendrino R, Baydoun L, van Dijk K, Melles GRJ, Oellerich S. Effect of six-month postoperative endothelial cell density on graft survival after Descemet membrane endothelial keratoplasty. Ophthalmology. 2021 Dec;128(12):1689-1698. https://doi.org/10.1016/j.ophtha.2021.05.022 PMID: 34033824
44. Bhogal M, Matter K, Balda MS, Allan BD. Organ culture storage of pre-prepared corneal donor material for Descemet's membrane endothelial keratoplasty. Br J Ophthalmol. 2016 Nov;100(11):1576-1583. https://doi.org/10.1136/bjophthalmol-2016-308855 PMID: 27543290
45. Méry B, Guy JB, Vallard A, Espenel S, Ardail D, Rodriguez-Lafrasse C, et al. *In vitro* cell death determination for drug discovery: a landscape review of real issues. J Cell Death. 2017 Feb 24;10:1179670717691251. https://doi.org/10.1177/1179670717691251 PMID: 28469473

Part II

Regenerative strategies for the treatment of Fuchs endothelial dystrophy

CHAPTER 4

Corneal endothelial wound healing: understanding the regenerative capacity of the innermost layer of the cornea

Transl Res. 2022 May 21;S1931-5244(22)00114-1

Hendrik Vercammen, Alina Miron, Silke Oellerich, Gerrit R.J. Melles, Sorcha Ní Dhubhghaill, Carina Koppen, and Bert Vandenbogerd

Abstract

Currently, there are very few well-established treatments to stimulate corneal endothelial cell regeneration *in vivo* as a cure for corneal endothelial dysfunctions. The most frequently performed intervention for a damaged or dysfunctional corneal endothelium nowadays is corneal endothelial keratoplasty, also known as lamellar corneal transplantation surgery. Newer medical therapies are emerging and are targeting the regeneration of the corneal endothelium, helping the patients regain their vision without the need for donor tissue. Alternatives to donor tissues are needed as the aging population requiring transplants, has further exacerbated the pressure on the corneal eye banking system. Significant ongoing research efforts in the field of corneal regenerative medicine have been made to elucidate the underlying pathways and effector proteins involved in corneal endothelial regeneration. However, the literature offers little guidance and selective attention to the question of how to fully exploit these pathways. The purpose of this paper is to provide an overview of wound healing characteristics from a biochemical level in the lab to the regenerative features seen in the clinic. Studying the pathways involved in corneal wound healing together with their key effector proteins, can help explain the effect on the proliferation and migration capacity of the corneal endothelial cells.

Introduction

The corneal endothelium forms the innermost layer of the cornea and fulfills a key function in maintaining a relative state of dehydration, making it transparent.[1,2] This monolayer regulates corneal hydration through a well- established "pump-and-leak" mechanism. The dynamic balance between the passive barrier and active fluid pump of the endothelium is essential for maintaining the relatively dehydrated state of the stroma along with the correct alignment of stromal collagen.[3] When the corneal endothelium (CE) is compromised the leak/pump rate becomes unbalanced and the cornea becomes thick and cloudy. This swelling is known as corneal edema. The CE forms resistance to solutes and fluid permeability through paracellular transport routes, but allows the pas- sage of nutrients from the aqueous humor into the avascular cornea.[4,5] The "leaky" barrier is formed by junction proteins such as zonula occludens (ZO-1) and connexin-43, and the adhesion junction complex represented by cadherin isoforms.[5–7] The osmotic drive of the corneal stroma to swell is counteracted by removing excess stromal fluid. This fluid is removed by the activity of sodium-potassium adenosine triphosphatase (Na^+/K^+-ATPase) pumps and bicarbonate-dependent Mg^{2+}-ATPase ionic pumps located mainly at the basolateral site of the cellular membrane.[5,8–12]

Traditionally, corneal endothelial cells (CEnCs) are not thought to have a significant capacity for *in vivo* regeneration.[13] They are highly differentiated and considered post mitotic and, in healthy individuals, show a gradual drop in endothelial cell density throughout life with an average cell loss of approximately 0.6% per year.[14] CEnCs are arrested in the G1 phase of mitosis and as a increased cell spreading with cells showing high polymorphism.[7,15,16] Age-related decline of the CE does not usually affect the critical barrier and pump function. In contrast, CEnC loss due to a pathology such as endothelial dystrophies, contact lens wear, previous refractive or intraocular surgeries, may lead to corneal decompensation.[17–20] When the CEnC density falls below a functional threshold (usually about 500 cells/mm^2), the pump and leak mechanism fails and the cornea swells.[21,22] In such cases, the gold standard treatment is to replace the ineffective endothelium with healthy, functional corneal endothelium by means of a corneal transplant.[15,23,24]

Over the past 2 decades, the procedure of choice to manage corneal disorders has shifted from penetrating keratoplasty (PK) to the more selective endothelial keratoplasty (EK).[25] The most selective form of EK is currently Descemet membrane endothelial keratoplasty (DMEK), where the endothelium is replaced with a single layer of donor cells.[26] Surgical outcomes are excellent, but the global donor shortage remains the major limitation for treatment.[27–32] This has led to the development of new therapeutic options.[33–36] New therapies aim to regenerate the corneal endothelium by inducing corneal endothelial wound healing which is known to occur through cell enlargement and migration rather than by cell proliferation.[37,38]

The mechanisms governing corneal endothelial cell migration pertain to the cytoskeleton and, in particular, to actin-based motility.[39] Corneal endothelium wound repair is accompanied by the appearance of actin which is involved in a dynamic process during cell movement. These actin filaments are involved in the formation of filopodia and lamellipodia, which will affect leading edge cell dynamics.[40,41] During wound healing, CEnC deposit fibronectin and laminin along the basement membrane.[42] These extracellular matrix molecules will act as guidance cues promoting signals associated with directed cell migration, including cytoskeletal reorganization.[43] Healthy remaining CEnC undergo cytoskeletal changes during the wound healing process. These changes consist of actin reorganization and cellular enlargement to form a polygonal cell shape to cover the damaged zone thereby rapidly restoring the barrier function. The process of these phenotypical changes during wound healing is known as endothelial-to-mesenchymal transition (EnMT). This process results in a disruption of the cellular monolayer and loss of cell-cell contact inhibition.[44] During EnMT the remaining cells lose their own function and shape and are converted to a fibroblast-like phenotype. The cells will break free of their neighboring cells and migrate individually along the Descemet membrane (DM) into the defected area resulting in a fast wound closure.[45–50] A hallmark of the EnMT is downregulation of the junctional protein E-cadherin and upregulation of cytoskeletal proteins such as fibronectin and vimentin concomitant with increased

expression of collagen type I genes (COL1A1 and COL1A2).[51] Also, mesenchymal transition marker genes such as snail family transcriptional repressor 1 (SNAI1), SNAI2, zinc finger E-box-binding homeobox 1 (ZEB1), and ZEB2 are known to regulate the expression of collagen type 1 and suppression of E-cadherins.47 Secretion of type I collagen can lead to retrocorneal membrane formation and corneal blindness.[52]

When CEnC receive a mitogenic cue, they activate cyclin proteins and cyclin dependent kinases (CDK). Both form cyclin/CDK complexes, which interact with the retinoblastoma protein known for its pivotal function in cell cycle progression.[8] The induction of cyclin D and E in combination with an inhibition of CDK-inhibitor cyclin-dependent kinase inhibitor 1B (p27kip1) are of particular importance in transitioning from the G1 phase to the S-phase of the cell cycle.[53]

Unraveling the processes involved in wound healing could lead to better insights in restoring the corneal endothelium. The goal of this review therefore is to compile what is currently known about the corneal endothelial wound healing process with special emphasis on involved pathways, biological modulators, and clinical implications.

Methods

The research strategy used for the pathway selection in the result section covered all relevant English papers concerning the corneal endothelial wound healing process. Research articles were selected in first line by title and abstract of the past decade (2011–2022). A total of 125 papers were found by using the query “Corneal endotheli*” AND Wound healing” OR “Repair” in PubMed. This selection was further refined manually through means of a screening table which was made to only select the most relevant papers in this field. This table was based on the activated pathway during corneal endothelial wound healing, the effector protein(s) involved in these processes and specific “marker” proteins involved in proliferation, migration, and endothelial-to-mesenchymal transition. We obtained 42 relevant papers concerning corneal endothelial wound healing. Following the literature study, the upstream and downstream proteins involved in corneal endothelial wound healing were connected into signaling cascades by using 2 online databases: Kyoto Encyclopedia of Genes and Genomes (KEGG) and Consensus Path Database (CPDB). For the clinical implication part in the result section, the following query in Pubmed was used: cornea and cell migration and endotheli*, endotheli* cell therapies. A total of 28 papers were selected between 2000 and 2021 based on their clinical relevance concerning wound healing aspects.

RESULTS

Main pathways involved in wound healing processes

In this section, we will summarize the key signaling pathways reported to date that are involved in corneal endothelial wound healing. These pathways are organized by various connections of specific effector proteins that typically form multi-tiered signaling cascades.

Rho/ROCK pathway

The most widely studied pathway involved in corneal endothelial wound healing is the Rho/Rho-associated coiled-coil containing kinase (Rho/ROCK) pathway (**Figure 1**).[54,55] Rho/ROCK pathway starting points are difficult to define, since different hormones, cytokines and growth factors can affect this cascade by regulating the upstream proteins.[56] Two important upstream regulators linked to corneal endothelial wound healing are guanine nucleotide exchange factors (GEFs) and GTPase-activating proteins (GAPs), both of which are involved

in the activation of small G-proteins.[15,33,57–59] GEFs act as signal activators by catalyzing the exchange of small G protein-bound GDP to GTP. In contrast, GAPs will act as signaling suppressors by means of GTP hydrolysis.[60]

The most characterized small G protein is the Ras homolog family member A (RhoA).[61] This class of proteins act as molecular switches of downstream signaling pathways and hydrolyze guanosine triphosphate (GTP) to become active.[56,62] Phosphorylated RhoA will affect ROCK, which is a target molecule for cellular therapy and regenerative medicine.[63] ROCK signaling pathway is involved in many biological processes ranging from cell adhesion, migration and stress fiber formation to even the regulation of cell proliferation and apoptosis.[33,34,62,64]

The activation of ROCK sustains the activation of myosin light chain phosphatase (MLCP) and myosin light chain kinase (MLCK), which in turn activate the phosphorylation of myosin light chain (MLC).[64] Active ROCK causes MLCP inactivation so that the MLCK activity will outweigh the physiological balance of these 2 MLC regulators.[57] Phosphorylated MLC will cause actin polymerization and stress fiber formation in the cytoskeleton of CEnCs. Alternatively, the phosphorylation of LIM kinase (LIMK) by ROCK leads to an increase in phosphorylated cofilin. This actin binding protein will be inhibited upon phosphorylation, which results in a decrease of actin-depolymerizing activity. Consequently, a higher level of actin filament stabilization results in a higher contractile state during the wound healing process.[54,57,65] Consequently, the latter causes a higher level of actin filament stabilization which results in a higher contractile state during the wound healing process.

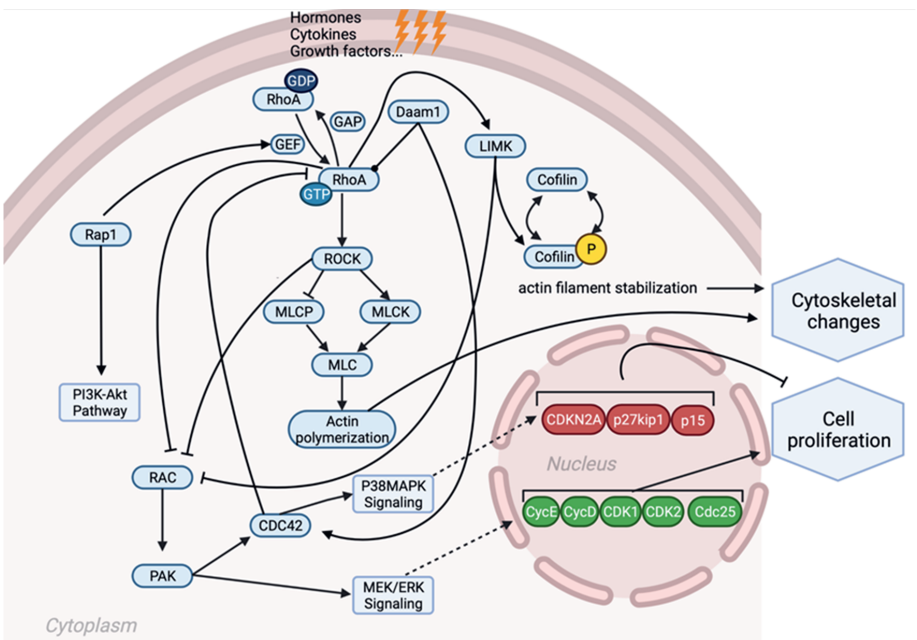

Figure 1| Rho/ROCK signaling pathway in a CEnC. Full lines represent either downstream stimulation (arrow) or inhibition (flathead). A rounded end line Indicates that it will form a complex. Dashed lines target the effector proteins without all the intermediate involved proteins.

Furthermore, LIMK, RhoA and ROCK can also block early G1-phase induction through inhibition of Ras-related C3 botulinum toxin substrate 1 (Rac) and cell division control protein 42 homolog (cdc42) resulting in low cyclin

D levels.[63,66,67] Rac and cdc42 are small GTPases which are key regulators of the p38 mitogen-activated protein kinases (p38MAPK) and mitogen activated ERK kinase-extracellular signal-regulated kinase (MEK-ERK) signaling pathways. Both pathways are known to regulate cell cycle progression.[57,61] Okumura et al. also showed the involvement of the phosphoinositol-3-kinase (PI3K) and protein kinase b (Akt) pathway when ROCK was not activated indicating the complex signaling route of this wound healing cascade.[57,68]

Furthermore, disheveled-associated activator of morphogenesis (Daam1) which is part of the winglessinkt (Wnt) pathway can form a complex with RhoA and directly stimulate its activity. Indirectly, Daam1 inhibits RhoA activity by cdc42 activation which creates a negative feedback loop. The cytoskeletal rearrangement together with decreased cyclin-cyclin kinase levels and increased cyclin kinase inhibition promote migration. Proliferation is therefore negatively affected upon activation of Rho/ROCK signaling thereby lowering the wound healing ability.[54,61,68]

Phosphoinositol-3-kinase (PI3K) and protein kinase b (Akt) pathway

The PI3K/Akt pathway is based on 2 key signaling proteins namely: phosphoinositol-3-kinase (PI3K) and protein kinase b (Akt) (**Figure 2**).[69] PI3K can be activated directly by small GTPase effector Ras-proximate-1 (Rap1), which acts as a cytosolic signaling transducer.[70] Rap1 can be activated by the binding of exchange protein directly activated by cAMP (EPAC) to the cytosolic cAMP that is released intracellularly. The release of cAMP occurs after the binding of pituitary adenylate cyclase activating polypeptide (PACAP) to their pituitary adenylate cyclase (PAC1) receptor.[15,71] Alternatively, PI3K can also be activated by focal adhesion kinase (Fak) that functions as an early mediator in integrin activation and the time-dependent generation of cell-ECM forces. During wound healing, the engagement of the integrin subunits activates protein kinase c (PKC).[33] This serine-threonine kinase is known to be upregulated in CEnCs at the wound edge thereby affecting the activity of Fak.[70–72]

PI3K phosphorylates phosphatidylinositol bisphosphate (PIP2) to generate the second messenger, phosphatidylinositol trisphosphate (PIP3) which signals to downstream effector Akt, a serine/threonine kinase implicated in the regulation of cell cycle progression and cell death.[68,73,74] The activation of Akt signaling by the transcription factor sex-determining region Ybox 2 (SOX2) alters the phosphorylation level of GSK-3ß targeting the b-catenin for ubiquitination and proteasome mediated degradation.[45] In confluent corneal endothelial monolayers, ß-catenin is bound to the cell

membrane while in a lower confluency degree more freely available cytosolic ß-catenin is present.[44,46] If there is no stabilization signal to suppress glycogen synthase kinase 3 beta (GSK-3ß) activity, the cytosolic ß-catenin is targeted for degradation by GSK-3b phosphorylation.[44,75] In this case, there is no internalization of ß-catenin into the nucleus to activate transcription factor 4 (TCF4) which can enhance cyclin D, E, cyclin dependent kinase 1 (CDK1) and breakdown p27kip1 and Cyclin Dependent Kinase Inhibitor 2A (CDKN2A).[45,46,70] As a result, there is no net effect on the cell cycle progression. SOX2 can also affect the GSK-3ß/ß-catenin system by interfering with the TCF4 binding site to promote cell proliferation.[45] SOX2 has an inhibitory effect on GSK-3ß thereby releasing ß-catenin to the cytosol which also promotes cell proliferation. Remarkably, ß-catenin induces morphogenic changes by enhancing EnMT related genes such as SNAI, SLUG, ACTA2 and ZEB1 contributing to aberrant ECM deposition and fibrosis.[44,47]

Akt activation also leads to forkhead box transcription factor FOXO3A (Fkhlr1) suppression which promotes cell survival over apoptosis (FOXO signaling pathway).[45] Additionally, activated Akt promotes the phosphorylation of cytosolic proline rich Akt substrate of 40 kDa (PRAS40) concomitant with unlocking the inhibition of tuberous sclerosis proteins 1 (TSC1) which results in the activation of mammalian target of rapamycin (mTOR) pathway.[76] Activated PRAS40 binds with rapamycin complex 1 (mTORC1) to stimulate ribosomal protein S6 kinase (S6K) which stimulates protein synthesis to become more metabolically active during wound closure. At

the same time activated PRAS40 as well as TSC will stimulate the mothers against decapentaplegic homolog 4 (SMAD4) transcription factor. The latter is known to activated EnMT related genes such as SNAI, SLUG, ACTA2 and ZEB1 causing enhanced motility and aberrant ECM deposition.[47,74]

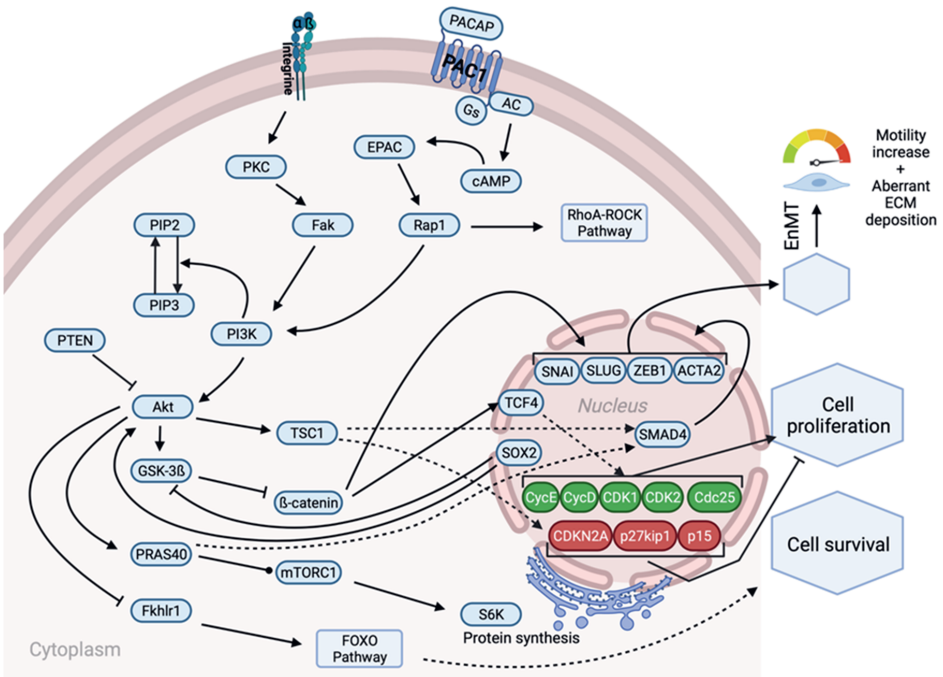

Figure 2| PI3K/Akt signaling pathway in a CEnC. Full lines represent either downstream stimulation (arrow) or inhibition (flathead). A rounded end line Indicates that it will form a complex. Dashed lines target the effector proteins and pathway without all the intermediate involved proteins.

Nuclear accumulation of p27kip1 is caused by the phosphatase and tensin homolog (PTEN) protein-induced inhibition of AKT phosphorylation.[77] Zhang et al. showed that inhibition of PTEN results in a stimulation of cell cycle progression as well as an increased migration behavior of CEnCs which emphasize the effect on wound healing.[77]

In general, PI3K and Akt modulate cell cycle progression, enhance cell survival, but may also cause EnMT induction with concomitant increase in motility together with aberrant ECM secretion. These different processes could be seen as characteristics for corneal endothelial wound healing.

Wingless-Inkt pathway

The Wnt pathway and can be subdivided in a canonical and noncanonical signaling cascade[44] (**Figure 3**). The canonical cascade passes signals in CEnCs through the activation of an atypic cell surface G-coupled receptor complex called Frizzled-Low density lipoprotein receptor related protein 5-6 (FzdLRP5/6).[59] This receptor complex inhibits GSK-3ß and leads to cytoplasmatic stabilization and nuclear transport of ß-catenin which enhances cellular proliferation abilities.[45,75]

The noncanonical Wnt pathway consists of different frizzled family receptor members such as Fzd5 and can be activated by Wnt5a ligand.[47,59] This protein will stimulate the cytoplasmatic protein Daam1 which form a complex with RhoA (Daam1-RhoA complex) to regulate cytoskeleton organization and cell migration through GTPases of the Rho-family, such as RhoA and Cdc42.[44,59] Activation of Cdc42 inhibits RhoA which, in turn, enhances cell migration through regulation of cofilin.[57] A higher level of dephosphorylated cofilin causes a faster modulation in actin turnover in cytoskeleton assembly resulting in a higher migratory state.[65]

In general, the Wnt pathway can alter cell proliferation and migration abilities by means of GSK-3ß regulation and Daam1 modulation respectively. Therefore, it is an important signaling cascade involved in corneal endothelial wound healing.

Transforming growth factor beta (TGF-) pathway

TGF-ß signaling pathway has been shown to regulate many cellular processes such as cell proliferation, differentiation, motility, adhesion, and programmed cell death (**Figure 3**). Earlier reports indicated the presence of 3 types of TGF-ß receptors in human corneal endothelium.[78] Moreover, Joyce et al. stated that those receptors were continuously exposed to latent TGF-ß2 that is found in aqueous humor, thereby preventing CEnCs to enter the G1-to-S transition phase of the cell cycle.[37,79] TGF-ß2 blocks the phosphorylation of p27kip1 which is a prerequisite for nuclear export of the inhibitor molecule for degradation.[77] Consequently, accumulation of p27kip1 molecules in the nucleus negatively regulate the CDK complexes that are necessary for cell cycle progression.[70] TGF-ß pathway activation together with contact inhibition are thought to be one of the main reasons which prohibit CEnC proliferation *in vivo*.[77] Additionally, the TGF-ß receptor can directly activate the downstream signaling Akt protein leading to loss of tight junctions and EnMT activation.

Joko et al. discovered that TGF-ß signaling caused an upregulation of the TGF-b-stimulated clone 22 (TSC-22) gene, encoding for a transcription factor that has cell proliferation suppressor properties.[76] TSC-22 binds to and modulates the transcriptional activity of Smad4 causing either an upregulation of cyclin-dependent kinase inhibitor 2B (p15) and thus inhibiting cell proliferation or enhances the expression of specific sets of target genes such as SNAI, ACTA2 and SLUG which trigger EnMT.[58,78,80]

Interestingly, TGF-β2 has been reported to induce wound healing by promoting CEnC migration through activation of p38MAPK rather than by stimulating cell proliferation because p38MAPK has shown to upregulate p27kip1 expression which promotes the G1 cell cycle arrest.[76] TGF-ß2 enhances CEnC migratory properties through mitogen-activated protein kinase 1 (MAPK1) activation.[37] This kinase affects the more downstream mitogen-activated protein kinase 3 and 6 (MAPK3/6) which modulates the phosphorylation of p38MAPK and promotes its translocation to the nucleus.[37,76]

In conclusion, TGF-ß can stimulate CEnC wound healing by enhanced migratory activities regulated through activation of p38MAPK.[76] However, TGF-ß signaling may force the CEnCs to adopt a fibroblastic like morphology causing aberrant collagen 1 and fibronectin deposition.[47,78] The presence of such changes in ECM production hampers the success of transplantation of cultivated cells *in vitro* due to this highly undesirable phenotype.[70,78]

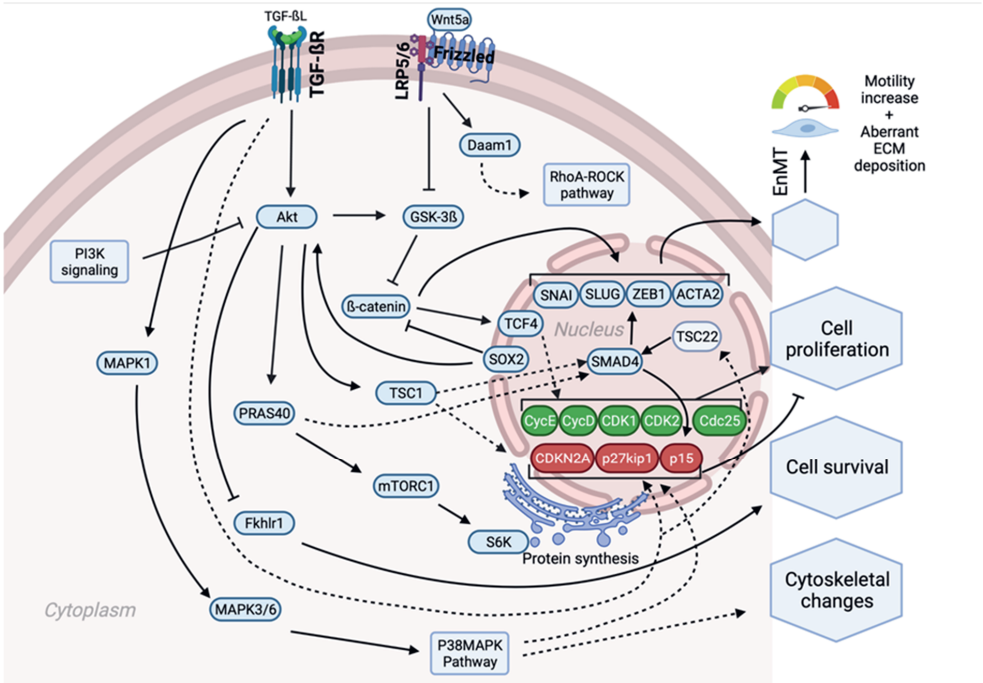

Figure 3| TGF-ß/Wnt signaling cascade in a CEnC. Full lines represent either downstream stimulation (arrow) or inhibition (flathead. Dashed lines target the effector proteins and pathway without all the intermediate involved proteins.

Clinical implications

Clinical scenarios that require corneal endothelial cell migration. Corneal opacification represents one of the prevalent causes of blindness, accounting for 4.2 million visual impaired patients of the worldwide blind population in 2019.[81–83] Corneal blindness may be caused by diseases such as Fuchs endothelial corneal dystrophy (FECD), (pseudophakic) bullous keratopathy, posterior polymorphous dystrophy, congenital hereditary endothelial dystrophy, or iridocorneal endothelial syndrome.[23] FECD is the most common form of corneal endothelial dystrophy with a regional prevalence that varies from 3.8% to 11% in individuals in the fifth or sixth decade of life. Moreover, it is the top indication for cornea transplantation worldwide.[30] FECD is a bilateral, sporadic, or autosomal dominant (inherited in some cases) dystrophy that progresses slowly and is characterized by deterioration of endothelial cells and development of basement membrane excrescences known as guttae.[84] Endothelial cell loss from FECD damages barrier function and if left untreated, central corneal edema will expand into the periphery leading to diffuse edema, bullous keratopathy, and eventually to subepithelial scarring.[85,86] However, corneal decompensation and bullous keratopathy can also result from corneal injury, iatrogenic damage by cataract surgery or other surgical procedures, or medication toxicity.[87–92] Corneal blindness from these cases is primarily treated by performing a corneal transplant.

For about ten decades, full thickness transplantation of the cornea was the gold standard for treating corneal disorders, while nowadays, EK has become the technique of choice. The 2 most successful endothelial keratoplasty techniques are Descemet stripping (automated) endothelial keratoplasty (DS(A)EK) and DMEK (Descemet membrane endothelial keratoplasty). The main difference between DMEK and DS (A)EK is the stroma-less graft in DMEK, which results in improved postoperative best-corrected visual acuity (BCVA) outcomes and a faster visual recovery.[93,94] Despite technique improvements and efforts to standardize

DMEK, postoperative complications have been reported including significant decline in endothelial cell density (ECD), especially during the early postoperative period, as well as graft detachment.[95–97]

Clinically, an important consideration is whether the host and/or recipient endothelial cells are capable of migrating to cover bare recipient stroma in the areas not covered by graft tissue. *In vivo* endothelial cell migration has been described in eyes with partially detached grafts resulting in corneal clearing, despite varying degrees of incomplete graft attachment[98,99] (**Figure 4**). Visual recovery was explained by endothelial cell migration or regeneration from either the donor or remaining recipient endothelial cells. Endothelial cell migration was also reported for grafts decentered in recipient eyes after DMEK or in patients who developed immune reaction episodes with endothelial precipitates detectable on the graft and on the bare stroma not covered by the DMEK graft.[100,101]

New insights in endothelial cell migration were also obtained after Quarter-DMEK surgery, that is, a modified DMEK-technique in which an untrephined full-sized DMEK graft is equally divided in quarters in order to treat 4 eyes with 1 donor cornea. In a first Quarter-DMEK cohort of 19 eyes, the central cornea underlying the graft cleared rapidly, while the peripheral bare stromal regions slowly improved over several months.[102–104] This suggested that donor endothelial cells migrated from the radial cut graft edges and induced corneal clearance in those areas. Cell migration from the round graft edge, on the other hand, was inhibited, possibly due to the arrangement of fibrillary bands of collagen in the graft periphery acting as a barrier for cell migration.[104] The lack of cell migration from the round graft edge resulted in localized longer standing corneal edema along the round graft edge.[102] Widespread cell migration from the cut graft edges may be responsible for the initially rapid decline in ECD observed after Quarter-DMEK surgery.[105] A follow up *in vitro* study carried out by the same group showed that alterations in the far peripheral area of Quarter-DMEK grafts were insufficient to trigger cell migration from the limbal graft edge.[106] This was attributed to progenitor cells located beneath the Schwalbe's line and which lack cytokinetic directional cues despite their exposure to free surface.[107]

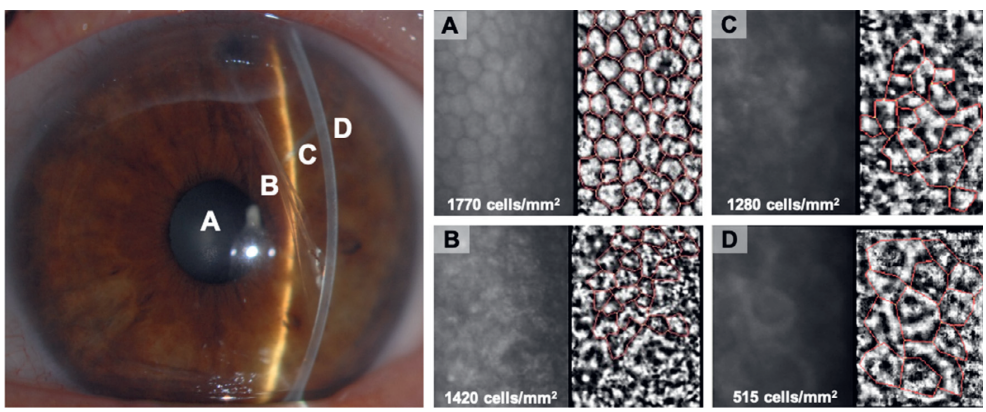

Figure 4| Slit-lamp and specular microscopy images of a DMEK graft at 8 months of follow-up. Although centrally the graft appeared detached, the area was visibly clear. Specular microscopy images taken at the indicated positions in the left image showed an endothelial cell density of 1770 cells/mm^2 in the corneal center (A), 1420 cells/mm^2 paracentrally (B), 1280 cells/mm^2 in the periphery (C), and 515 cells/mm^2 in the far periphery (D). Adapted from: "Descemet membrane endothelial transfer: "free-floating" donor Descemet implantation as a potential alternative to "keratoplasty". Dirisamer, M., Cornea, 2012.

Recently, another study reported complete recovery of corneal clarity and visual acuity when using cryopreserved full-thickness endothelial-free grafts for therapeutic PK.[108] Of the 18 out of 195 grafts showed

recovery of the corneal graft clarity within 1 year after graft transplantation. When corneal clarity was recovered, average ECD was 991 cells/mm^2 (range, 782-1531 cells/mm^2) and remained stable up to 2 years after surgery. The authors suggested that the endothelium may have regenerated by cell proliferation rather than cell migration and that cells originated from peripheral host.[108]

Experimental alternatives to transplantation techniques

Cell regeneration

In ophthalmology, ROCK-inhibitors play a role in the regulation of aqueous humor outflow by inducing relaxation of both the ciliary muscle and the actin cytoskeleton in the trabecular meshwork.109 Currently, Ripasudil (0.4% ROCK inhibitor) has market authorization in Japan for treating glaucoma or ocular hypertension.110 More recently, Netarsudil ophthalmic solution 0.02% was approved in the United States and the European Union for lowering elevated intraocular pressure (IOP).[34,111,112]

The first clinical study suggesting that *in vivo* proliferation of corneal endothelium could be stimulated by pharmaceutical treatment described the possibility of using ROCK-inhibitor eye drops subsequent to transcorneal freezing as an alternative to graft surgery in patients with corneal endothelial dysfunction.[113] Specular microscopy examination 18 months after the treatment showed small CEnCs present at a high cell density in the central part of the cornea. Two suggestions were made regarding the mechanism of action, namely the spontaneous cell remodeling and presence of endothelial progenitors in the peripheral cornea. In that experiment, it was not possible to conclude whether the endothelium improved due to the ROCK-inhibition application or whether the removal of the diseased cells was sufficient to induce wound healing.[113] Other case reports described that ROCK-inhibitors prevent the progression of bullous keratopathy in patients whose corneal endothelium was severely damaged by cataract surgery or rescue PK grafts from failure after an acute rejection episode.[63,114]

Surgical Techniques that require endothelial migration

Descemet stripping only (DSO) or Descemetorhexis without endothelial keratoplasty (DWEK) and acellular DM transplantation are experimental surgical strategies for treating central FECD that depend on the patient's own endothelial cells to grow and reform the barrier.[115–118] The surgery involves removal of the central 4-6 mm diseased endothelium and DM, that is, removal of central non-confluent guttae, to allow the centripetal migration and redistribution of the remaining healthy peripheral endothelial cells to cover either the bare stroma generated by DWEK/DSO or to re-populate the transplanted devitalized DM.[116,119] Transplanting a devitalized DM or trying to leave Descemet membrane's anterior banded layer intact during descemetorhexis may be beneficial for cell migration as this extracellular matrix contains important proteins and growth factors that are required for cellular process such as migration or proliferation [132].

Clinical case series evaluating DWEK/DSO for FECD have reported inconsistent results from total failure to complete recovery with central ECD in the range of 428-864 cells/mm^2 at the last reported follow-up visit (range: 6–24 months).[119–121] Observed corneal clearance time in successful DSO cases, which can most likely be linked to the speed to cell migration, varied between patients and was thought to be influenced by both surgical and patient factors. Overall, repopulation of the bare stroma and inducing corneal clearance can occur between 3 and 6 months postoperatively. This gives a timeframe for *in vivo* CEnC wound healing to happen.[119,121] (**Figure 5**).

When a topical ROCK-inhibitor such as Ripasudil or Netarsudil was administrated after DWEK/DSO, decreased clearance time together with an improved central ECD and an overall better cell architecture were found in eyes that received ROCK-inhibitor immediately after surgery.[66,122] Moreover, less loss of peripheral ECD was observed when ROCK-inhibitor was administrated immediately after surgery rather than waiting until later in

the healing course.[66] Hence, this may support the concept of endothelial cell proliferation in the ROCK-inhibitor treated group, as opposed to pure endothelial cell migration in the DWEK/DSO group. However, overall peripheral ECD decreased after DWEK/DSO regardless of whether ROCK-inhibitor had been administered. The repopulation of central bare stroma therefore most likely involved a combination of proliferation and migration of cells from the peripheral endothelium.[122]

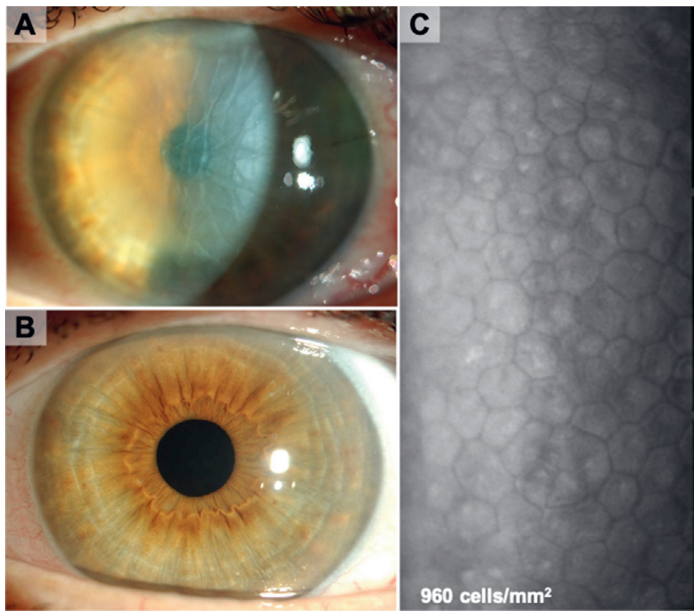

Figure 5| Slit-lamp and specular microscopy images of a cornea at 6 y post DSO. Although the posterior cornea appeared irregular (A) following 8 mm surgical descemetorhexis, the cornea clarity was restored within 12 weeks and maintained thereafter (B) with a central ECD of 960 cells/mm^2 (C).

The inability of the corneal endothelium to regenerate *in vivo* has been mainly attributed to strong contact inhibition cell behavior that in turn upregulates the p27Kip1 and prevents transition to the S-phase. Thus, corneal endothelial cells are not terminally differentiated but do possess proliferative potential. *In vitro* studies on corneal endothelium wound healing with ROCK-inhibitor showed that cell cycle progression is enhanced closer to the wound edge and stops once the wound is healed.[63,67,94] Studies of ROCK-inhibitor in human patients reported “pseudoguttae” visible on specular microscopy.[123] These ‘dark bodies’ were arising in the population of cells migrating to cover the descemetorhexis area but disappeared later, when the endothelium integrity was restored.[85,118] This led to the assumption that ROCK-inhibitor might have affected the distribution of actin microfilaments concomitant with inhibition of focal adhesion formation. Another important observation was the intercellular localization of the dark bodies rather than within the cell cytoplasm.[118] These clinical observations corroborate well with the in vitro findings that ROCK-inhibitor reduces cell adhesion through a loss of focal adhesion complexes and reduced expression of intracellular adhesion molecules.[112,124] Although there is little information about the success of DWEKDSO procedure in relation to patient factors, surgical factors such as avoiding constant pressure during DM scoring or stromal contact by overlaying an acellular DM to facilitate central cell migration and prevent posterior stromal scarring are better characterized.[116,117,125]

Because DWEK/DSO was shown to be more successful among patients suffering from FECD due to the presence of a larger cell reservoir to the periphery, transplanting a denuded DM together with the use of a topical ROCK-inhibitor might increase the success rate of DWEK/DSO.[117]

Cell- based therapies

Kinoshita et al. were the first to report on CEnC injection therapy in 11 patients (7 were FECD, 4 were BK) with a 5-year follow-up.[126] After removing the abnormal extracellular matrix and the degenerated CEnCs on the patient DM either by mechanical scraping or a 5 mm descemetorhexis, cultured human CEnCs were injected in combination with ROCK-inhibitor into the anterior chamber of the eye. ROCK-inhibitor was required as a supplement for the cell suspension to promote CEnC adhesion.[33,35] Since the number of injected cells was 106 in most treated eyes, proliferation is unlikely to occur despite the presence of ROCK-inhibitor, but it can be speculated that cell migration might have occurred in case of an initially uneven cell adherence on the posterior surface. Five years after the procedure, 10 out of 11 patients showed a restoration of the corneal function with a central ECD of 1257 ± 467 cells/mm^2 and no major adverse reactions directly related to the human CEnC injection therapy.[126] This promising preliminary study that merged an adjunct drug in cell-based therapies has offered a new perspective in the treatment of endothelial dysfunction.[126]

DISCUSSION

Currently, newly emerging alternatives to conventional EK are being investigated to compensate for the shortfall in global corneal graft tissue.[27–32] Within the field of regenerative medicine, new therapeutic strategies aim to regenerate the corneal endothelium through means of corneal endothelial wound healing and potentially pharmacologically stimulating this process.[61,62,77] Over the past decade, advances in our understanding of the biochemical and mechanical cues have help us better exploit the underlying wound healing process.

The main signaling pathways that govern normal corneal endothelial wound healing include the RhoA/ROCK, PI3K/Akt, Wnt, and TGF-ß pathways. These cascades carry on information of upstream/downstream relationships between interacting proteins. For example, Rap1 is a molecular switch that cycles between an active GTP-bound and inactive GDP-bound form and regulates the RhoA/ROCK and PI3K/Akt pathway. Because ROCK mediates various important cellular functions, inhibition of ROCK may affect multiple signaling pathways and will outweigh signaling cascades which act through the same effector proteins.[34] This crosstalk hypothesis may explain why ROCK-inhibition can have multiple biological effects such as enhanced proliferation or anti-apoptotic effects and why it is not only limited to cytoskeletal changes within the wound healing process.[62,66] The crosstalk of the Rho/ROCK pathway with other signaling cascades makes it challenging to unravel all involved processes in endothelial wound healing and more research is required to fully exploit the underlying biochemical processes for clinical applications.

Transcription factor SMAD4, which also is an indirect target of Akt, plays an important role in inducing EnMT thereby creating cytoskeletal changes, an increased motility and aberrant CEnC ECM deposition. However, strategies to overcome EnMT must not be accompanied by the impairment of cell migration during wound healing.[47] Sumioka et al. investigated the role of TGF-ß related signaling during corneal endothelial wound healing by avoiding the disruption of migration signals while blocking an unfavorable EnMT phenotype. This study indicates that it is possible to increase wound healing without inducing EnMT.[80]

Cyclins, cyclin-kinases and cyclin kinase inhibitors are the end staged effector proteins that regulate cell cycle progression and proliferation in CEnCs during wound healing. Enhancing these end-staged proteins can lead to a selective regulation of the proliferation rate instead of activating other upstream proteins that could adversely affect the normal CEnC phenotype.[13,38,53]

Endothelial wounds may trigger cells adjacent to the wound to lose their pericellular actin band pattern and later well-defined stress fibers fill their cytoplasm and persist until the wound is closed.[69] However, it was also reported that endothelial cells undergo directional migration into the wounded zone in the absence of an organized actin cytoskeleton and without stress fiber formation.[127,128]

Progenitor cells that are located in specific niches in the corneal far periphery may constitute an interesting target for regenerative therapies as they were shown to possess enhanced regenerative capacities.[107,129] However, knowledge about these cells and the involved processes is still limited.

This review provides an extensive overview over the signaling pathways involved in CEnC proliferation and migration. Knowledge about these pathways paves the way for pharmacological stimulation to effectively target these fundamental cell processes. This could lead to an effective topical treatment of corneal endothelial dysfunction either as a stand-alone treatment or in combination with surgical removal of diseased tissue. To conclude, basic research involved in corneal endothelial cell biology will act as a central anchor point for new therapies to treat corneal endothelial dysfunctions.

REFERENCES

1. DelMonte DW, Kim T. Anatomy and physiology of the cornea. J Cataract Refract Surg. 2011 Mar;37(3):588-98.https://doi.org/10.1016/j.jcrs.2010.12.037 PMID:21333881
2. Yam GH, Seah X, Yusoff NZBM, Setiawan M, Wahlig S, Htoon HM, et al. Characterization of human transition zone reveals a putative progenitor-enriched niche of corneal endothelium. Cells. 2019 Oct 12;8(10):1244. https://doi.org/10.3390/cells8101244 PMID: 31614883
3. Kivanany PB, Grose KC, Yonet-Tanyeri N, Manohar S, Sunkara Y, Lam KH, et al. An *in vitro* model for assessing corneal keratocyte spreading and migration on aligned fibrillar collagen. J Funct Biomater. 2018 Sep 21;9(4):54. https://doi.org/10.3390/jfb9040054 PMID: 30248890
4. Klyce SD. 12. Endothelial pump and barrier function. Exp Eye Res. 2020 Sep;198:108068. https://doi.org/10.1016/j.exer.2020.108068 PMID: 32663497
5. Bonanno JA. Molecular mechanisms underlying the corneal endothelial pump. Exp Eye Res. 2012 Feb;95(1):2-7. https://doi.org/10.1016/j.exer.2011.06.004 PMID:21693119
6. Theriault M, Roy O, Brunette I, Proulx S. Physiological pressure enhances the formation of tight junctions in engineered and native corneal endothelium. Exp Eye Res. 2019 Feb;179:102-105. https://doi.org/10.1016/j.exer.2018.11.004 PMID: 30414972
7. Kampik D, Basche M, Georgiadis A, Luhmann UFO, Larkin DF, Smith AJ, et al. Modulation of contact inhibition by ZO-1/ZONAB gene transfer-a new strategy to increase the endothelial cell density of corneal grafts. Invest Ophthalmol Vis Sci. 2019 Jul 1;60(8):3170-3177. https://doi.org/10.1167/iovs.18-26260 PMID: 31335954
8. Joyce NC. Proliferative capacity of corneal endothelial cells. Exp Eye Res. 2012 Feb;95(1):16-23. https://doi.org/10.1016/j.exer.2011.08.014 PMID: 21906590
9. Van den Bogerd B, Zakaria N, Adam B, Matthyssen S, Koppen C, Ní Dhubhghaill S. Corneal endothelial cells over the past decade: are we missing the mark(er)? Transl Vis Sci Technol. 2019 Nov 15;8(6):13. https://doi.org/10.1167/tvst.8.6.13 PMID: 31772824
10. Eghrari AO, Riazuddin SA, Gottsch JD. Overview of the cornea: structure, function, and development. Prog Mol Biol Transl Sci. 2015;134:7-23. https://doi.org/10.1016/bs.pmbts.2015.04.001 PMID: 26310146
11. Hertsenberg AJ, Funderburgh JL. Stem cells in the cornea. Prog Mol Biol Transl Sci. 2015;134:25-41. https://doi.org/10.1016/bs.pmbts.2015.04.002 PMID: 26310147
12. Amador-Munoz D, Gutierrez AM, Payan-Gomez C, Matheus LM. In silico and *in vitro* analysis of cation-activated potassium channels in human corneal endothelial cells. Exp Eye Res. 2020 Aug;197:108114. https://doi.org/10.1016/j.exer.2020.108114 PMID: 32561484
13. Joyce NC. Proliferative capacity of the corneal endothelium. Prog Retin Eye Res. 2003 May;22(3):359-89. https://doi.org/10.1016/s1350-9462(02)00065-4 PMID: 12852491
14. Gambato C, Longhin E, Catania AG, Lazzarini D, Parrozzani R, Midena E. Aging and corneal layers: an *in vivo* corneal confocal microscopy study. Graefes Arch Clin Exp Ophthalmol. 2015 Feb;253(2):267-75. https://doi.org/10.1007/s00417-014-2812-2 PMID: 25311652
15. Maugeri G, Longo A, D'Amico AG, Rasà DM, Reibaldi M, Russo A, et al. Trophic effect of PACAP on human corneal endothelium. Peptides. 2018 Jan;99:20-26. https://doi.org/10.1016/j.peptides.2017.11.003 PMID: 29126993
16. Zavala J, Lopez Jaime GR, Rodriguez Barrientos CA, Valdez-Garcia J. Corneal endothelium: developmental strategies for regeneration. Eye (Lond). 2013 May;27(5):579-88. https://doi.org/10.1038/eye.2013.15 PMID: 23470788
17. Chang SW, Hu FR, Lin LL. Effects of contact lenses on corneal endothelium - a morphological and functional study. Ophthalmologica. 2001 May-Jun;215(3):197-203. https://doi.org/10.1159/000050858 PMID: 11340391
18. Hwang HB, Lyu B, Yim HB, Lee NY. Endothelial cell loss after phacoemulsification according to different anterior chamber depths. J Ophthalmol. 2015;2015:210716. https://doi.org/10.1155/2015/210716 PMID: 26417452
19. Hasegawa Y, Nejima R, Mori Y, Sakisaka T, Minami K, Miyata K, et al. Risk factors for corneal endothelial cell loss by cataract surgery in eyes with pseudoexfoliation syndrome. Clin Ophthalmol. 2016 Aug 30;10:1685-9. https://doi.org/10.2147/OPTH.S106661 PMID: 27621588
20. Edelhauser HF. The resiliency of the corneal endothelium to refractive and intraocular surgery. 2000 May;19(3):263-73. https://doi.org/10.1097/00003226-200005000-00002 PMID: 10832681
21. Ong Tone S, Jurkunas U. Imaging the corneal endothelium in Fuchs corneal endothelial dystrophy. Semin Ophthalmol. 2019;34(4):340-346. https://doi.org/10.1080/08820538.2019.1632355 PMID: 31215821

22. Vedana G, Villarreal G Jr., Jun AS. Fuchs endothelial corneal dystrophy: current perspectives. Clin Ophthalmol. 2016 Feb 18;10:321-30. https://doi.org/10.2147/OPTH.S83467 PMID: 26937169
23. Galgauskas S, Norvydaite D, Krasauskaite D, Stech S, Asoklis RS. Age-related changes in corneal thickness and endothelial characteristics. Clin Interv Aging. 2013;8:1445-50. https://doi.org/10.2147/CIA.S51693 PMID: 24187493
24. Van den Bogerd B, Dhubhghaill SN, Koppen C, Tassignon MJ, Zakaria N. A review of the evidence for *in vivo* corneal endothelial regeneration. Surv Ophthalmol. 2018 Mar-Apr;63(2):149-165. https://doi.org/10.1016/j.survophthal.2017.07.004 PMID: 28782549
25. Birbal RS, Ni Dhubhghaill S, Bourgonje VJA, Hanko J, Ham L, Jager MJ, et al. Five-year graft survival and clinical outcomes of 500 consecutive cases after Descemet membrane endothelial keratoplasty. Cornea. 2020 Mar;39(3):290-297. https://doi.org/10.1097/ICO.0000000000002120 PMID: 31478948
26. Musayeva A, Livny E, Dragnea DC, Ham L, Vasiliauskaitė I, Ní Dhubhghaill S, et al. Endothelial cell density changes in the corneal center versus paracentral areas after Descemet membrane endothelial keratoplasty. Cornea. 2020 Sep;39(9):1091-1095. https://doi.org/10.1097/ICO.0000000000002326 PMID: 32282357
27. Jewitt-Harris J. Anything but the Eyes; An art-based investigation into why people won't donate their corneas after death. Ophthalmologist 2022:Epub 08/03/2020 Available from: https://theophthalmologist.com/subspecialties/anything-butthe-eyes
28. Lawlor M, Kerridge I. Anything but the eyes: culture, identity,and the selective refusal of corneal donation. Transplantation. 2011 Dec 15;92(11):1188-90. https://doi.org/10.1097/TP.0b013e318235c81 PMID: 22011764
29. Lawlor M, Kerridge I, Ankeny R, Dobbins TA, Billson F. Specific unwillingness to donate eyes: the impact of disfigurement, knowledge and procurement on corneal donation. Transplant. 2010 Mar;10(3):657-63. https://doi.org/10.1111/j.1600-6143.2009.02986.x PMID: 20121739
30. Gain P, Jullienne R, He Z, et al. Global survey of corneal transplantation and eye banking. JAMA Ophthalmol. 2016 Feb;134(2):167-73. https://doi.org/10.1001/jamaophthalmol.2015.4776 PMID: 26633035
31. Ang M, Moriyama A, Colby K, et al. Corneal transplantation in the aftermath of the COVID-19 pandemic: an international perspective. Br J Ophthalmol. 2020 Nov;104(11):1477-1481. https://doi.org/10.1136/bjophthalmol-2020-317013 PMID: 32732343
32. Toro M, Choragiewicz T, Posarelli C, Figus M, Rejdak R, European C-CG. Early impact of COVID-19 outbreak on the availability of cornea donors: warnings and recommendations Clin Ophthalmol. 2020 Sep 25;14:2879-2882. https://doi.org/10.2147/OPTH.S260960 PMID: 33061273
33. Schlotzer-Schrehardt U, Zenkel M, Strunz M, et al. Potential functional restoration of corneal endothelial cells in Fuchs endothelial corneal dystrophy by rock inhibitor (Ripasudil). Am J Ophthalmol. 2021 Apr;224:185-199. https://doi.org/10.1016/j.ajo.2020.12.006 PMID: 33316261
34. Ploysangam P, Patel SP. A case report illustrating the postoperative course of descemetorhexis without endothelial keratoplasty with topical netarsudil therapy. Case Rep Ophthalmol Med. 2019 Oct 13;2019:6139026. https://doi.org/10.1155/2019/6139026 PMID: 31737390
35. Kinoshita S, Koizumi N, Ueno M, Okumura N, Imai K, Tanaka H, et al. Injection of cultured cells with a ROCK inhibitor for bullous keratopathy N Engl J Med. 2018 Mar 15;378(11):995-1003. https://doi.org/10.1056/NEJMoa1712770 PMID: 29539291
36. Koizumi N, Okumura N, Ueno M, Kinoshita S. New therapeutic modality for corneal endothelial disease using Rho-associated kinase inhibitor eye drops. Cornea. 2014 Nov;33 Suppl 11:S25-31. https://doi.org/10.1097/ICO.0000000000000240 PMID: 25289721
37. Joko T, Shiraishi A, Akune Y, Tokumaru S, Kobayashi T, Miyata K, et al. Involvement of P38MAPK in human corneal endothelial cell migration induced by TGFbeta(2). Exp Eye Res. 2013 Mar;108:23-32. https://doi.org/10.1016/j.exer.2012.11.018 PMID: 23257207
38. Joyce NC. Cell cycle status in human corneal endothelium Exp Eye Res. 2005 Dec;81(6):629-38. https://doi.org/10.1016/j.exer.2005.06.012 PMID: 16054624
39. Hall A. Rho family GTPases. Biochem Soc Trans. 2012 Dec 1;40(6):1378-82. https://doi.org/10.1042/BST20120103 PMID: 23176484
40. Gordon SR, Staley CA. Role of the cytoskeleton during injury induced cell migration in corneal endothelium. Cell Motil Cytoskeleton. 1990;16(1):47-57. https://doi.org/10.1002/cm.970160107 PMID: 2354526
41. Gordon SR, Buxar RM. Inhibition of cytoskeletal reorganization stimulates actin and tubulin syntheses during injury-induced cell migration in the corneal endothelium J Cell Biochem. 1997 Dec 1;67(3):409-21. PMID: 9361195

42. Sabet MD, Gordon SR. Ultrastructural immunocytochemical localization of fibronectin deposition during corneal endothelial wound repair. Evidence for cytoskeletal involvement. Biol Cell. 1989;65(2):171-9. PMID: 2736331
43. Berzat A, Hall A. Cellular responses to extracellular guidance cues. EMBO J. 2010 Aug 18;29(16):2734-45. https://doi.org/10.1038/emboj.2010.170 PMID: 20717143
44. Liu J, Wen Y, Luo W, Liu Y, Sha X. Human amniotic epithelial cells promote the proliferation of human corneal endothelial cells by regulating telomerase activity via the Wnt/beta-catenin pathway. Curr Eye Res. 2021 Feb;46(2):159-167. https://doi.org/10.1080/02713683.2020.1792508 PMID: 32631162
45. Chang YK, Hwang JS, Chung TY, Shin YJ. SOX2 activation using CRISPR/dCas9 promotes wound healing in corneal endothelial cells. Stem Cells. 2018 Dec;36(12):1851-1862. https://doi.org/10.1002/stem.2915 PMID: 30270540
46. Hwang JS, Yi HC, Shin YJ. Effect of SOX2 repression on corneal endothelial cells. Int J Mol Sci. 2020 Jun 20;21(12):4397. https://doi.org/10.3390/ijms21124397 PMID: 32575737
47. Lee JG, Jung E, Heur M. Fibroblast growth factor 2 induces proliferation and fibrosis via SNAI1-mediated activation of CDK2 and ZEB1 in corneal endothelium. J Biol Chem. 2018 Mar 9;293(10):3758-3769. https://doi.org/10.1074/jbc.RA117.000295 PMID: 29363574
48. Li C, Dong F, Jia Y, Du H, Dong N, Xu Y, et al. Notch signal regulates corneal endothelial-to-mesenchymal transition. Am J Pathol. 2013 Sep;183(3):786-95. https://doi.org/10.1016/j.ajpath.2013.05.025 PMID: 23850080
49. Petroll WM, Barry-Lane PA, Cavanagh HD, Jester JV. ZO-1 reorganization and myofibroblast transformation of corneal endothelial cells after freeze injury in the cat. Exp Eye Res. 1997 Feb;64(2):257-67. https://doi.org/10.1006/exer.1996.0211 PMID: 9176060
50. Ong Tone S, Wylegala A, Bohm M, Melangath G, Deshpande N, Jurkunas UV. Increased corneal endothelial cell migration in Fuchs endothelial corneal dystrophy: a live cell imaging study. Ophthalmol Sci 2021;1:100006. https://doi.org/10.1016/j.xops.2021.100006
51. Lamouille S, Xu J, Derynck R. Molecular mechanisms of epithelial-mesenchymal transition. Nat Rev Mol Cell Biol. 2014 Mar;15(3):178-96. https://doi.org/10.1038/nrm3758 PMID: 24556840
52. Mihail Z, Alina-Cristina S, Speranta S. Retrocorneal membranes after penetrating keratoplasty. Rom J Ophthalmol. 2015 Oct-Dec;59(4):230-234. PMID: 29450312
53. Yoshida K, Kase S, Nakayama K, Nagahama H, Harada T, Ikeda H, et al. Involvement of p27KIP1 in the proliferation of the developing corneal endothelium. Invest Ophthalmol Vis Sci. 2004 Jul;45(7):2163-7. https://doi.org/10.1167/iovs.03-1238 PMID: 15223790
54. Meekins LC, Rosado-Adames N, Maddala R, Zhao JJ, Rao PV, Afshari NA. Corneal endothelial cell migration and proliferation enhanced by Rho kinase (ROCK) inhibitors in *in vitro* and *in vivo* Models. Invest Ophthalmol Vis Sci. 2016 Dec 1;57(15):6731-6738. https://doi.org/10.1167/iovs.16-20414 PMID: 2795159
55. Okumura N, Koizumi N, Ueno M, Sakamoto Y, Takahashi H, Hirata K, et al. Enhancement of corneal endothelium wound healing by Rho-associated kinase (ROCK) inhibitor eye drops. Br J Ophthalmol. 2011 Jul;95(7):1006-9. https://doi.org/10.1136/bjo.2010.194571 PMID: 21398412
56. Zhang W, Shao C, Yu F, Chen J, Fu Y, Fan X. Y-27632 promotes the repair effect of umbilical cord blood-derived endothelial progenitor cells on corneal endothelial wound healing. Cornea 2021;40:203–14 https://doi.org/10.1097/ICO.0000000000002560 PMID: 33086282
57. Pipparelli A, Arsenijevic Y, Thuret G, Gain P, Nicolas M, Majo F. ROCK inhibitor enhances adhesion and wound healing of human corneal endothelial cells. PLoS One. 2013 Apr 23;8(4):e62095. https://doi.org/10.1371/journal.pone.0062095 PMID: 23626771
58. Wang X, Zhou Q, Zhao C, Duan H, Li W, Dong C, Gong Y, Li Z, Shi W. Multiple roles of FGF10 in the regulation of corneal endothelial wound healing. Exp Eye Res. 2021 Apr;205:108517. https://doi.org/10.1016/j.exer.2021.108517 PMID: 33617851
59. Lee JG, Heur M. Interleukin-1β-induced Wnt5a enhances human corneal endothelial cell migration through regulation of Cdc42 and RhoA. Mol Cell Biol. 2014 Sep 15;34(18):3535-45. https://doi.org/10.1128/MCB.01572-13 PMID: 25022753
60. Homma Y, Hiragi S, Fukuda M. Rab family of small GTPases: an updated view on their regulation and functions. FEBS J. 2021 Jan;288(1):36-55. https://doi.org/10.1111/febs.15453 PMID: 32542850
61. Okumura N, Okazaki Y, Inoue R, Kakutani K, Nakano S, Kinoshita S, et al. Effect of the Rho-associated kinase inhibitor eye drop (Ripasudil) on corneal endothelial wound healing. Invest Ophthalmol Vis Sci. 2016 Mar;57(3):1284-92. https://doi.org/10.1167/iovs.15-18586 PMID: 26998714

62. Miyagi H, Kim S, Li J, Murphy CJ, Thomasy SM. Topical Rho-associated kinase inhibitor, Y27632, accelerates corneal endothelial regeneration in a canine cryoinjury model. Cornea. 2019 Mar;38(3):352-359. https://doi.org/10.1097/ICO.0000000000001823 PMID: 30516555
63. Okumura N, Inoue R, Okazaki Y, Nakano S, Nakagawa H, Kinoshita S, et al. Effect of the Rho kinase inhibitor Y-27632 on corneal endothelial wound healing. Invest Ophthalmol Vis Sci. 2015 Sep;56(10):6067-74. https://doi.org/10.1167/iovs.15-17595 PMID: 26393474
64. Hsu CC, Peng CH, Hung KH, Lee YY, Lin TC, Jang SF, et al. Stem cell therapy for corneal regeneration medicine and contemporary nanomedicine for corneal disorders. Cell Transplant. 2015;24(10):1915-30. https://doi.org/10.3727/096368914X685744 PMID: 25506885
65. Ho WT, Chang JS, Chou SF, Hwang WL, Shih PJ, Chang SW, et al. Targeting non-muscle myosin II promotes corneal endothelial migration through regulating lamellipodial dynamics. J Mol Med (Berl). 2019 Sep;97(9):1345-1357. https://doi.org/10.1007/s00109-019-01818-5 PMID: 31302714
66. Macsai MS, Shiloach M. Use of topical Rho kinase inhibitors in the treatment of Fuchs dystrophy after Descemet stripping only. Cornea. 2019 May;38(5):529-534. https://doi.org/10.1097/ICO.0000000000001883 PMID: 30720541
67. Okumura N, Koizumi N, Kay EP, Ueno M, Sakamoto Y, Nakamura S, et al. The ROCK inhibitor eye drop accelerates corneal endothelium wound healing. Invest Ophthalmol Vis Sci. 2013 Apr 3;54(4):2493-502. https://doi.org/10.1167/iovs.12-11320 PMID: 23462749
68. Okumura N, Nakano S, Kay EP, Numata R, Ota A, Sowa Y, et al. Involvement of cyclin D and p27 in cell proliferation mediated by ROCK inhibitors Y-27632 and Y-39983 during corneal endothelium wound healing. Invest Ophthalmol Vis Sci. 2014 Jan 15;55(1):318-29. https://doi.org/10.1167/iovs.13-12225 PMID: 24106120
69. Gordon SR, Gordon GH, Dimovski S. Rat corneal endothelial cell migration during wound repair on the basement membrane depends more on the PI-3K pathway than the cdc-42 pathway or actin stress fibers. Cell Tissue Res. 2020 Nov;382(2):351-366. https://doi.org/10.1007/s00441-020-03229-2 PMID: 32566981
70. Lee JG, Heur M. Interleukin-1β enhances cell migration through AP-1 and NF-κB pathway-dependent FGF2 expression in human corneal endothelial cells. Biol Cell. 2013 Apr;105(4):175-89. https://doi.org/10.1111/boc.201200077 PMID: 23331079
71. Ljubimov AV, Saghizadeh M. Progress in corneal wound healing. Prog Retin Eye Res. 2015 Nov;49:17-45. https://doi.org/10.1016/j.preteyeres.2015.07.002 PMID: 26197361
72. Rieck PW, Cholidis S, Hartmann C. Intracellular signaling pathway of FGF-2-modulated corneal endothelial cell migration during wound healing in vitro. Exp Eye Res. 2001 Nov;73(5):639-50. https://doi.org/10.1006/exer.2001.1067 PMID: 11747364
73. Kim KW, Park SH, Lee SJ, Kim JC. Ribonuclease 5 facilitates corneal endothelial wound healing via activation of PI3-kinase/Akt pathway. Sci Rep. 2016 Aug 16;6:31162. https://doi.org/10.1038/srep31162 PMID: 27526633
74. Hwang JS, Ma DJ, Choi J, Shin YJ. COL8A2 Regulates the fate of corneal endothelial cells. Invest Ophthalmol Vis Sci. 2020 Sep 1;61(11):26. https://doi.org/10.1167/iovs.61.11.26 PMID: 32931574
75. Hwang JS, Yoon CK, Hyon JY, Chung TY, Shin YJ. Transcription factor 4 regulates the regeneration of corneal endothelial cells. Invest Ophthalmol Vis Sci. 2020 Apr 9;61(4):21. https://doi.org/10.1167/iovs.61.4.21. Retraction in: Invest Ophthalmol Vis Sci. 2020 Sep 1;61(11):6. PMID: 32301972
76. Joko T, Shiraishi A, Kobayashi T, Ohashi Y, Higashiyama S. Mechanism of proliferation of cultured human corneal endothelial cells. Cornea. 2017 Nov;36 Suppl 1:S41-S45. https://doi.org/10.1097/ICO.0000000000001337 PMID: 28902018
77. Zhang W, Yu F, Yan C, Shao C, Gu P, Fu Y, et al. PTEN inhibition accelerates corneal endothelial wound healing through increased endothelial cell division and migration. Invest Ophthalmol Vis Sci. 2020 Jul 1;61(8):19. https://doi.org/10.1167/iovs.61.8.19 PMID: 32667999
78. Okumura N, Kay EP, Nakahara M, Hamuro J, Kinoshita S, Koizumi N. Inhibition of TGF-β signaling enables human corneal endothelial cell expansion *in vitro* for use in regenerative medicine. PLoS One. 2013;8(2):e58000. https://doi.org/10.1371/journal.pone.0058000 PMID: 23451286
79. Joyce NC, Harris DL, Mello DM. Mechanisms of mitotic inhibition in corneal endothelium: contact inhibition and TGF-beta2. Invest Ophthalmol Vis Sci. 2002 Jul;43(7):2152-9. PMID: 12091410
80. Sumioka T, Ikeda K, Okada Y, Yamanaka O, Kitano A, Saika S. Inhibitory effect of blocking TGF-beta/Smad signal on injury-induced fibrosis of corneal endothelium. Mol Vis 2008;14:2272–81. PMID: 19081766
81. Robaei D, Watson S. Corneal blindness: a global problem. Clin Exp Ophthalmol. 2014 Apr;42(3):213-4. https://doi.org/10.1111/ceo.12330 PMID: 24734984

82. Pascolini D, Mariotti SP. Global estimates of visual impairment: 2010. Br J Ophthalmol. 2012 May;96(5):614-8. https://doi.org/10.1136/bjophthalmol-2011-300539 PMID: 22133988
83. World Health O. World report on vision. Geneva: World Health Organization; 2019
84. Moshirfar M, Somani AN, Vaidyanathan U, Patel BC. Fuchs endothelial dystrophy. Treasure IslandFL: StatPearls; 2021
85. Bajaj RP, Fliotsos MJ, Pradeep T, Eghrari AO. Peripheral-to-central ratio of Guttae: validity and reliability of an objective method to characterize severity of Fuchs endothelial corneal dystrophy. Graefes Arch Clin Exp Ophthalmol. 2021 Mar;259(3):685-690. https://doi.org/10.1007/s00417-020-04985-1 PMID: 33128674
86. Shaheen BS, Bakir M, Jain S. Corneal nerves in health and disease. Surv Ophthalmol. 2014 May-Jun;59(3):263-85. https://doi.org/10.1016/j.survophthal.2013.09.002 PMID: 24461367
87. Shin YJ, Hyon JY, Choi WS, Yi K, Chung ES, Chung TY, et al. Chemical injury-induced corneal opacity and neovascularization reduced by rapamycin via TGF-β1/ERK pathways regulation. Invest Ophthalmol Vis Sci. 2013 Jul 2;54(7):4452-8. https://doi.org/10.1167/iovs.13-11684 PMID: 23716625
88. Feizi S. Corneal endothelial cell dysfunction: etiologies and management. Ther Adv Ophthalmol. 2018 Dec 7;10:2515841418815802. https://doi.org/10.1177/2515841418815802 PMID: 30560230
89. Van Looveren J, Vael A, Ideler N, Sillen H, Mathysen D, Tassignon MJ. Influence of the vitreolenticular interface in pediatric cataract surgery. J Cataract Refract Surg. 2018 Oct;44(10):1203-1210. https://doi.org/10.1016/j.jcrs.2018.06.052 PMID: 30172568
90. Tassignon MJ, Gobin L, Mathysen D, Van Looveren J, De Groot V. Clinical outcomes of cataract surgery after bag-in-the-lens intraocular lens implantation following ISO standard 11979-7:2006. J Cataract Refract Surg. 2011 Dec;37(12):2120-9. https://doi.org/10.1016/j.jcrs.2011.06.025 PMID: 22108108
91. Kloeck D, Koppen C, Kreps EO. Clinical Outcome of Hybrid Contact Lenses in Keratoconus. Eye Contact Lens. 2021 May 1;47(5):283-287. https://doi.org/10.1097/ICL.0000000000000738 PMID: 33009254
92. Madreperla SA, Johnson M, O'Brien TP. Corneal endothelial dysfunction in digoxin toxicity. Am J Ophthalmol. 1992 Feb 15;113(2):211-2. https://doi.org/10.1016/s0002-9394(14)71541-7 PMID: 1550195
93. Vasiliauskaitė I, Oellerich S, Ham L, Dapena I, Baydoun L, van Dijk K, et al. Descemet membrane endothelial keratoplasty: ten-year graft survival and clinical outcomes. Am J Ophthalmol. 2020 Sep;217:114-120. https://doi.org/10.1016/j.ajo.2020.04.005 PMID: 32283096
94. Anshu A, Price MO, Tan DT, Price FW Jr. Endothelial keratoplasty: a revolution in evolution. Surv Ophthalmol. 2012 May-Jun;57(3):236-52. https://doi.org/10.1016/j.survophthal.2011.10.005 PMID: 22516537
95. Dapena I, Moutsouris K, Droutsas K, Ham L, van Dijk K, Melles GR. Standardized "no-touch" technique for Descemet membrane endothelial keratoplasty. Arch Ophthalmol. 2011 Jan;129(1):88-94. https://doi.org/10.1001/archophthalmol.2010.334 PMID: 21220634
96. Miron A, Bruinsma M, Ham L, Schaal SC, Baydoun L, Dapena I, et al. *In vivo* endothelial cell density decline in the early postoperative phase after Descemet membrane endothelial keratoplasty. Cornea. 2018 Jun;37(6):673-677. https://doi.org/10.1097/ICO.0000000000001484 PMID: 29737973
97. Kruse FE, Laaser K, Cursiefen C, Heindl LM, Schlötzer-Schrehardt U, Riss S, et al. A stepwise approach to donor preparation and insertion increases safety and outcome of Descemet membrane endothelial keratoplasty. Cornea. 2011 May;30(5):580-7. https://doi.org/10.1097/ico.0b013e3182000e2e PMID: 21598430
98. Bachmann BO, Laaser K, Cursiefen C, Kruse FE. A method to confirm correct orientation of Descemet membrane during Descemet membrane endothelial keratoplasty. Am J Ophthalmol. 2010 Jun;149(6):922-925.e2. https://doi.org/10.1016/j.ajo.2010.01.005 PMID: 20346440
99. Balachandran C, Ham L, Verschoor CA, Ong TS, van der Wees J, Melles GR. Spontaneous corneal clearance despite graft detachment in Descemet membrane endothelial keratoplasty. Am J Ophthalmol. 2009 Aug;148(2):227-234.e1. https://doi.org/10.1016/j.ajo.2009.02.033 PMID: 19442962
100. Jacobi C, Zhivov A, Korbmacher J, Falke K, Guthoff R, Schlötzer-Schrehardt U, et al. Evidence of endothelial cell migration after Descemet membrane endothelial keratoplasty. Am J Ophthalmol. 2011 Oct;152(4):537-542.e2. https://doi.org/10.1016/j.ajo.2011.04.005 PMID: 21726845
101. Hos D, Heindl LM, Bucher F, Cursiefen C. Evidence of donor corneal endothelial cell migration from immune reactions occurring after Descemet membrane endothelial keratoplasty. Cornea. 2014 Apr;33(4):331-4. https://doi.org/10.1097/ICO.0000000000000054 PMID: 24488131
102. Müller TM, Lavy I, Baydoun L, Lie JT, Dapena I, Melles GR. Case report of Quarter-Descemet membrane endothelial keratoplasty for Fuchs endothelial dystrophy. Cornea. 2017 Jan;36(1):104-107. https://doi.org/10.1097/ICO.0000000000001008 PMID: 27583798

103. Zygoura V, Baydoun L, Ham L, Bourgonje VJA, van Dijk K, Lie JT, et al. Quarter-Descemet membrane endothelial keratoplasty (Quarter-DMEK) for Fuchs endothelial corneal dystrophy: 6 months clinical outcome. Br J Ophthalmol. 2018 Oct;102(10):1425-1430. https://doi.og/10.1136/bjophthalmol-2017-311398 PMID: 29343529
104. Birbal RS, Ni Dhubhghaill S, Baydoun L, Ham L, Bourgonje VJA, Dapena I, et al. Quarter-Descemet membrane endothelial keratoplasty: one- to two-Year clinical outcomes. Cornea. 2020 Mar;39(3):277-282. https://doi.org/10.1097/ICO.0000000000002127 PMID: 31490274
105. Miron A, Spinozzi D, Bruinsma M, Lie JT, Birbal RS, Baydoun L, et al. Asymmetrical endothelial cell migration from *in vitro* Quarter-Descemet membrane endothelial keratoplasty grafts. Acta Ophthalmol. 2018 Dec;96(8):828-833. https://doi.org/10.1111/aos.13841 PMID: 30171674
106. Schlumpf M, Gähwiler M, Ribary U, Lichtensteiger W. A new device for monitoring early motor development: prenatal nicotine-induced changes. Pharmacol Biochem Behav. 1988 May;30(1):199-203. https://doi.org/10.1016/0091-3057(88)90444-3 PMID: 3174744
107. Sie NM, Yam GH, Soh YQ, Lovatt M, Dhaliwal D, Kocaba V, et al. Regenerative capacity of the corneal transition zone for endothelial cell therapy. Stem Cell Res Ther. 2020 Dec 4;11(1):523. https://doi.org/10.1186/s13287-020-02046-2 PMID: 33276809
108. Ying LY, Qiu WY, Wang BH, Zhou P, Zhang B, Yao YF. Corneal endothelial regeneration in human eyes using endothelium-free grafts. BMC Ophthalmol. 2022 Jan 21;22(1):32. https://doi.org/10.1186/s12886-022-02260-x PMID: 35062892
109. Rao VP, Epstein DL. Rho GTPase/Rho kinase inhibition as a novel target for the treatment of glaucoma. BioDrugs. 2007;21(3):167-77. https://doi.org/10.2165/00063030-200721030-00004 PMID: 17516712
110. Kassumeh S, von Studnitz A, Priglinger SG, Fuchshofer R, Luft N, Moloney G, et al. *Ex vivo* excimer laser ablation of cornea guttata and ROCK inhibitor-aided endothelial recolonization of ablated central cornea. Acta Ophthalmol. 2020 Sep;98(6):e773-e780. https://doi.org/10.1111/aos.14366 PMID: 32017400
111. Kopczynski CC, Heah T. Netarsudil ophthalmic solution 0.02% for the treatment of patients with open-angle glaucoma or ocular hypertension. Drugs Today (Barc). 2018 Aug;54(8):467-478. https://doi.org/10.1358/dot.2018.54.8.2849627 PMID: 30209441
112. Kaneko Y, Ohta M, Inoue T, Mizuno K, Isobe T, Tanabe S, et al. Effects of K-115 (Ripasudil), a novel ROCK inhibitor, on trabecular meshwork and Schlemm's canal endothelial cells. Sci Rep. 2016 Jan 19;6:19640. https://doi.org/10.1038/srep19640 PMID: 26782355
113. Koizumi N, Okumura N, Ueno M, Nakagawa H, Hamuro J, Kinoshita S. Rho-associated kinase inhibitor eye drop treatment as a possible medical treatment for Fuchs corneal dystrophy. Cornea. 2013 Aug;32(8):1167-70. https://doi.org/10.1097/ICO.0b013e318285475d PMID: 23715376
114. Davies E. Case Series: Novel Utilization of Rho-Kinase Inhibitor for the Treatment of Corneal Edema. Cornea. 2021 Jan;40(1):116-120. https://doi.org/10.1097/ICO.0000000000002421 PMID: 33269892
115. Gorovoy MS. Descemet-stripping automated endothelial keratoplasty. Cornea. 2006 Sep;25(8):886-9. https://doi.org/10.1097/01.ico.0000214224.90743.01 PMID: 17102661
116. Soh YQ, Peh G, George BL, Seah XY, Primalani NK, Adnan K, et al. Predicative factors for corneal endothelial cell migration. Invest Ophthalmol Vis Sci. 2016 Feb;57(2):338-48. https://doi.org/10.1167/iovs.15-18300 PMID: 26842752
117. Bhogal M, Lwin CN, Seah XY, Peh G, Mehta JS. Allogeneic Descemet's membrane transplantation enhances corneal endothelial monolayer formation and restores functional integrity following Descemet's stripping. Invest Ophthalmol Vis Sci. 2017 Aug 1;58(10):4249-4260. https://doi.org/10.1167/iovs.17-22106 PMID: 28850636
118. Garcerant D, Hirnschall N, Toalster N, Zhu M, Wen L, Moloney G. Descemet's stripping without endothelial keratoplasty. Curr Opin Ophthalmol. 2019 Jul;30(4):275-285. https://doi.org/10.1097/ICU.0000000000000579 PMID: 31033737
119. Iovieno A, Neri A, Soldani AM, Adani C, Fontana L. Descemetorhexis without graft placement for the treatment of Fuchs endothelial dystrophy: preliminary results and review of the literature. Cornea. 2017 Jun;36(6):637-641. https://doi.org/10.1097/ICO.0000000000001202 PMID: 28410355
120. Artaechevarria Artieda J, Wells M, Devasahayam RN, Moloney G. 5-year outcomes of Descemet stripping only in Fuchs dystrophy. Cornea. 2020 Aug;39(8):1048-1051. https://doi.org/10.1097/ICO.0000000000002270 PMID: 31990847

121. Borkar DS, Veldman P, Colby KA. Treatment of Fuchs endothelial dystrophy by Descemet stripping without endothelial keratoplasty. Cornea. 2016 Oct;35(10):1267-73. https://doi.org/10.1097/ICO.0000000000000915 PMID: 27310885
122. Davies E, Jurkunas U, Pineda R 2nd. Pilot study of corneal clearance with the use of a Rho-kinase inhibitor after descemetorhexis without endothelial keratoplasty for Fuchs endothelial corneal dystrophy. Cornea. 2021 Jul 1;40(7):899-902. https://doi.org/10.1097/ICO.0000000000002691 PMID: 33758139
123. Nakagawa H, Koizumi N, Okumura N, Suganami H, Kinoshita S. Morphological changes of human corneal endothelial cells after Rho-associated kinase inhibitor eye drop (Ripasudil) administration: A Prospective Open-Label Clinical Study. PLoS One. 2015 Sep 14;10(9):e0136802. https://doi.org/10.1371/journal.pone.0136802 PMID: 26367375
124. Lu Y, Li H, Jian W, Zhuang J, Wang K, Peng W, et al. The Rho/Rho-associated protein kinase inhibitor Fasudil in the protection of endothelial cells against advanced glycation end products through the nuclear factor κB pathway. Exp Ther Med. 2013 Aug;6(2):310-316. https://doi.org/10.3892/etm.2013.1125 PMID: 24137180
125. Davies E, Jurkunas U, Pineda R 2nd. Predictive factors for corneal clearance after descemetorhexis without endothelial keratoplasty. Cornea. 2018 Feb;37(2):137-140. https://doi.org/10.1097/ICO.0000000000001427 PMID: 29053562
126. Numa K, Imai K, Ueno M, Kitazawa K, Tanaka H, Bush JD, et al. Five-year follow-up of first 11 patients undergoing injection of cultured corneal endothelial cells for corneal endothelial failure. Ophthalmology. 2021 Apr;128(4):504-514. https://doi.org/10.1016/j.ophtha.2020.09.002 PMID: 32898516
127. Le Clainche C, Carlier MF. Regulation of actin assembly associated with protrusion and adhesion in cell migration. Physiol Rev. 2008 Apr;88(2):489-513. https://doi.org/10.1152/physrev.00021.2007 PMID: 18391171
128. Ichijima H, Petroll WM, Barry PA, Andrews PM, Dai M, Cavanagh HD, et al. Actin filament organization during endothelial wound healing in the rabbit cornea: comparison between transcorneal freeze and mechanical scrape injuries. Invest Ophthalmol Vis Sci. 1993 Aug;34(9):2803-12. PMID: 8344802
129. He Z, Campolmi N, Gain P, Ha Thi BM, Dumollard JM, Duband S, et al. Revisited microanatomy of the corneal endothelial periphery: new evidence for continuous centripetal migration of endothelial cells in humans. Stem Cells. 2012 Nov;30(11):2523-34. https://doi.org/10.1002/stem.1212 PMID: 22949402

CHAPTER 5

Asymmetrical endothelial cell migration from *in vitro* Quarter-Descemet membrane endothelial keratoplasty grafts

Acta Ophthalmol. 2018 Dec;96(8):828-833

Alina Miron, Daniele Spinozzi, Marieke Bruinsma, Jessica T. Lie, Rénuka S. Birbal, Lamis Baydoun, Silke Oellerich, Gerrit R.J. Melles

ABSTRACT

Purpose: To investigate *in vitro* central and peripheral corneal endothelial cell (EC) migration from Quarter–Descemet membrane endothelial keratoplasty (Quarter-DMEK) grafts.

Methods: Quarter-DMEK grafts were obtained from 10 corneas ineligible for transplantation but with intact and viable ECs. Ten Quarter-DMEK grafts were 'sandwiched' between two glass slides and cultured over 1 week in a humidified atmosphere at 37°C and 5% CO_2. Cell migration was evaluated by light microscopy at standardized time intervals. In addition, immunohistochemistry analyses were performed to assess the detailed structural organization of ECs in the corneal centre and far periphery.

Results: Endothelial cell (EC) migration occurred from the radial cut graft edges, but not from the far peripheral area. Cell migration followed three different migration patterns: (1) individual cell migration, (2) uncoordinated cell migration of cell clusters and (3) collective migration in which ECs moved as a sheet. Immunostaining showed the presence of ECs up to the far periphery but with different expression patterns of phenotypical markers ZO-1, Na^+/K^+ –ATPase and vimentin compared to central ECs.

Conclusion: *In vitro* EC migration from Quarter-DMEK grafts occurs along the radial cut edges with a decrease in migration activity towards the corneal far periphery. No migration occurred along the outer peripheral corneal edge possibly due to a different anatomical matrix in the far periphery. Hence, ECs from the far periphery may not contribute to corneal clearance of the adjacent bare area after Quarter-DMEK surgery, but these cells may constitute a valuable cellular reserve on the graft.

Introduction

Recently, we have introduced several modifications of Descemet membrane endothelial keratoplasty (DMEK) including Quarter-DMEK, a technique that potentially allows to retrieve four quadrants from a full-size Descemet membrane (DM) and therefore to utilize four endothelial grafts from a single donor cornea.[1–4] In a first series, Quarter- DMEK eyes showed visual outcomes similar to conventional (circular) DMEK.[4] At the slit lamp, however, Quarter-DMEKeyes typically showed a different corneal clearance pattern with clearing primarily occurring adjacent to the radial cut graft edges but not along the 'limbal' round edge of the Quarter-DMEK grafts. This finding would suggest that donor endothelial cell (EC) migration varies over these grafts, with an almost complete absence of migration in the farperipheral anatomical area of DM.

The aim of this study was to further evaluate how EC migration may vary over different anatomical corneal areas,by studying *in vitro* EC migration fromorgan-cultured Quarter-DMEK grafts,and to determine how Quarter-DMEK grafts may be positioned best onto the posterior recipient corneal surface during surgery in order to obtain a homogenous redistribution of donor ECs postoperatively.

Materials and Methods

Corneas

Ten human corneas ineligible for transplantation but with an intact and viable EC layer were obtained from seven donors (mean age 72 (±13) years; range 51–84 years; **Table 1**). All donors had stated to have no objection against transplanted-related research.

Quarter–Descemet membrane endothelial keratoplasty graft preparation

Quarter-DMEK grafts for these experiments were prepared at Amnitrans EyeBank Rotterdam as previously described.[4] Briefly, after decontamination of the globes, corneo-scleral rims were excised within 36 hours post-mortem. After EC morphology and viability were evaluated and digital photographs were made with inverted light microscopy (Zeiss Axiovert 40C; Carl Zeiss International, Zaventem, Belgium), the excised corneo-scleral rims were stored in organ culture medium (CorneaMax; Eurobio, Courtaboeuf, France) at 30°C until further processing. To peel the Quarter-DMEK grafts, corneo-scleral rims were placed endothelial-side-up on a custom made holder with a suction cup. The endothelium was then stained for visualization with 0.04% hypotonic trypan blue solution (Hippocratech, Rotterdam, the Netherlands) for 10 second. Next, the DM-EC sheet including trabecular meshwork (TM) was loosened over 360° from the scleral spur towards the corneal centre and the corneo-scleral button was divided into four equally sized parts with a surgical blade (no. 24 knife; Swann-Morton, Sheffield, UK). The DM was then centripetally stripped from the posterior stroma by grasping the TM with McPherson forceps (Moria, Medical Workshop, Groningen, the Netherlands), thereby obtaining four Quarter-DMEK grafts. After stripping, four rolls formed spontaneously with the endothelium on the outer side and the TM still attached to facilitate later graft handling. Endothelial cell morphology and viability were again assessed, and images of each Quarter-DMEK graft were evaluated using the fixed frame method. For all ten corneas, the endothelial cell density (ECD) determined in the eye bank after DMEK graft preparation was on average 2743 (±185) cells/mm^2, with no significant ECD difference between the four quarters ($P > .05$) deriving from the same cornea. Each Quarter-DMEK graft was then stored separately in organ culture medium (CorneaMax; Eurobio) before being evaluated for chemotactic cell ability or immunohistochemistry analysis.

Table 1. Donor demographics.

Donor Information	Indicators
Donor data	
Gender	
Female	4
Male	3
Mean age (±SD), yrs. (range)	72 (±13), (51–84)
Mean storage time (±SD), days (range)	11 (±5), (3–16)
Cause of death	
Cardio/Stroke	2
Respiratory	5

*Mean storage time = time between death and culture of first isolated DM-EC tissue; SD = standard deviation; yrs. = years

Cell migration study

To analyse cell migration patterns of the corneal endothelium on a Quarter-DMEK graft, 10 individual Quarter-DMEK rolls with the TM attached, obtained from 10 different corneas, were unfolded endothelial-side-up on a FNC-coated (fibronectin, collagen and albumin coating mix; Athena ESTM Baltimore, MD, USA) glass coverslip and evaluated *in vitro*. Unfolding for all grafts was performed in a 'no-touch' manner by grabbing the graft only at the TM site with a McPherson forceps and dropping organ culture medium onto the graft while the glass coverslip was kept tilted under a small angle. Next, the TM was carefully removed from the Quarter-DMEK grafts, and the endothelium was submerged in serum containing culture medium to ensure cell viability during the experiments. Serum containing culture medium consisted of 15% fetal bovine serum in Dulbecco's modified Eagle's medium supplemented with 2 mM L-Glutamine, 2 ng/ml fibroblast growth factor (bFGF), 0.3 mM L-ascorbic acid 2-phosphate (all from Sigma-Aldrich, Zwijndrecht, the Netherlands) and 10 000 U-ml Pen/ Strep (Carl Roth GmbH + Co. KG, Karlsruhe, Germany). A second FNC-coated glass coverslip that was spatially separated from the flattened Quarter-DMEK graft by a suture wire (Supramid TS194-0, non-absorbable, Hueber Medica) was then carefully placed on top. The Quarter-DMEK graft, now 'sandwiched' between the two glass slides, was then transferred to a 24-well plate, and kept over 9 days in a humidified atmosphere at 37°C and 5% CO_2. For routine maintenance, medium was replaced with fresh culture medium every 2–3 days. To assess cell morphology and the degree of cell migration, the Quarter-DMEK grafts were photographed daily with an AxioVert.A1 microscope with AxioCam 305 color camera (Zeiss, Oberkochen, Germany).

Immunohistochemistry

To evaluate the expression of continuous zonula occludens-1 (ZO-1) at the cell–cell borders, thin cortical vimentin cytoskeleton and pump function through Na^+/K^+ –ATPase, immunohistochemistry analysis was performed at room temperature on Quarter-DMEK grafts obtained from the same corneas as the grafts used for the cell migration experiments. Quarter-DMEK grafts were unfolded and flattened on silane-precoated glass slides (Sigma Aldrich) before fixation in 4% paraformaldehyde (Sigma-Aldrich) for 30 min. Following fixation, the

grafts were first washed with phosphate buffered saline (PBS), then permeabilized using permeabilization buffer (0.1% Triton X-100 in PBS; Sigma Aldrich) and finally incubated with blocking buffer (5% bovine serum albumin in PBS; Sigma-Aldrich) for 1 hour to prevent non-specific staining. Blocking buffer was also used for primary and secondary antibody (Life Technology, Bleiswijk, the Netherlands) dilutions. Incubation with primary antibodies anti-ZO-1 tight junction protein (anti-ZO-1/TJP1; dilution 1:100), anti-vimentin filamentous protein (anti-vimentin, dilution 1:100) and anti-sodium/potassium-ATPase (anti-Na^+/K^+ –ATPase, dilution 1:100) was performed for 1 hour and was followed by several PBS washing steps. Samples were then incubated with secondary antibodies (dilution 1:200) for 1 hr. As control, an antibody to smooth muscle actin (anti-α-SMA, dilution 1:100) was included as a marker for smooth muscle cells and myofibroblasts. After washing with PBS, the samples were stained with 40,6-diamidino-2-phenylindole (DAPI; Sigma-Aldrich) to visualize the nuclear DNA and then imaged using an inverted fluorescence microscope connected to a camera (Axiovert; Zeiss).

Results

Structural analysis of endothelial cell distribution on Quarter-DMEK grafts

With light microscopy, all Quarter-DMEK grafts showed an intact endothelium up to the radial cut edges (**Figure 1A**).

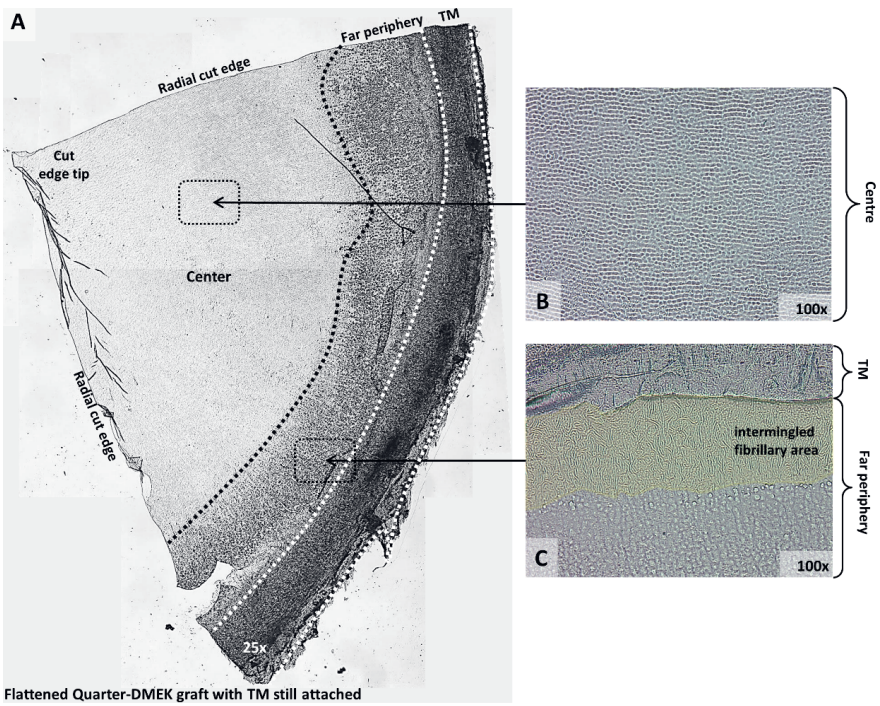

Figure 1| General view of a Quarter-Descemet membrane endothelial keratoplasty (DMEK) graft flattened on a glass support. (A) Overview of a flattened Quarter-DMEK graft with the trabecular meshwork (TM) still attached. Corneal centre (B) and far periphery (C) show structural differences, which become more distinct when displayed at higher magnifications (x100). (B) Corneal centre with closely packed hexagonal endothelial cells. (C) Far peripheral area is dominated by a fibrillary area adjacent to the TM.

From the central to far peripheral corneal areas, the ECs showed a different morphology, with a relatively homogenous cell distribution in the corneal centre and less densely packed cells with a more heterogeneous morphology towards the periphery (**Figure 1A–C**). In the area directly adjacent to the TM, collagen fibres intermingled with the ECs in a spiral-like pattern (**Figure 1C**).

Cell migration study

All grafts showed substantial cell migration from day 4 up to day 6 with EC migration along the radial cut edges up to the central tip of the graft **(Figures 2** and **3**). The degree of migration decreased towards the peripheral graft area. Over the far periphery, that is the intermingled fibrillary area, no cell migration was observed, that is no cells crossed the rounded graft edge at any time-point (**Figures 2B** and **3A–C**).

At the radial cut edges, three types of cell migration patterns could be observed: (1) individual cell migration in an exploratory manner lacking a directional stimulation (i.e. random cell migration) was present in five of 10 grafts (**Figure 2C**), (2) migration of cell clusters, with cells coexisting at the leading migratory edge, not forming a continuous monolayer (i.e. uncoordinated cell migration) was observed in four of 10 grafts (**Figure 2D–G**) and (3) migration of interconnected cells that collectively departed the DM with a leading 'cell group' at the front edge (i.e. collective cell migration) was observed in one of 10 graft (**Figure 3D–I**).

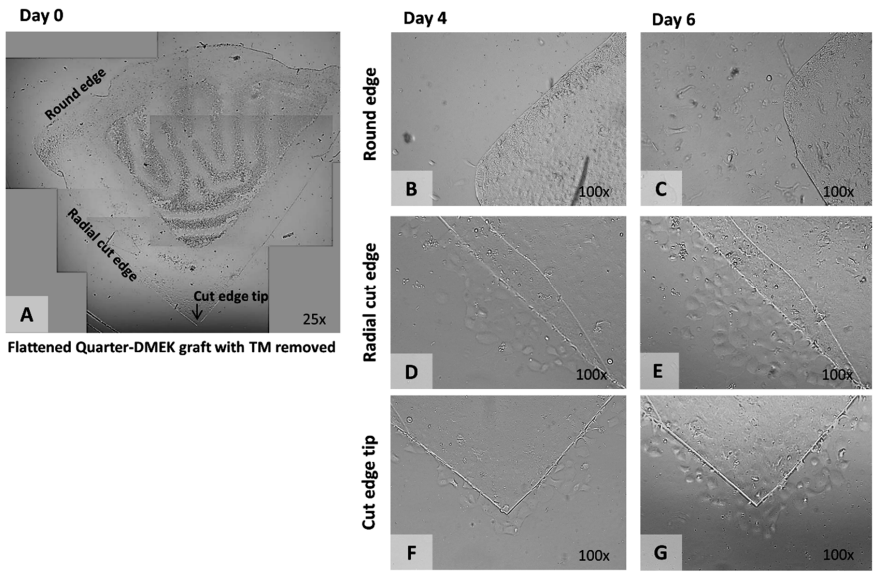

Figure 2| Example of individual and uncoordinated *in vitro* endothelial cell (EC) migration. (A) Collage of light microscopy images (x25 magnification) to create an overview of a flattened Quarter-Descemet membrane endothelial keratoplasty (DMEK) graft without trabecular meshwork attached, at the start of the cell migration experiment (Day 0). (B–G) Light microscopy images of the round edge (B,C), the radial cut edge (D,E) and the cut edge tip (F,G) of the Quarter-DMEK graft taken at Day 4 (left) and Day 6 (right) with x100 magnification. (B) In the area of the round edge of the Quarter-DMEK graft, no apparent cell migration is observed across the round graft edge with (C) only individual cells migrating across the far peripheral cut edge of the graft. (D,E) Along the radial cut edge of the Quarter-DMEK graft, single bleb-like ECs migrating onto the glass coverslip are observed. (F,G) At the cut edge tip of the Quarter-DMEK graft, individual cells migrate onto the glass coverslip.

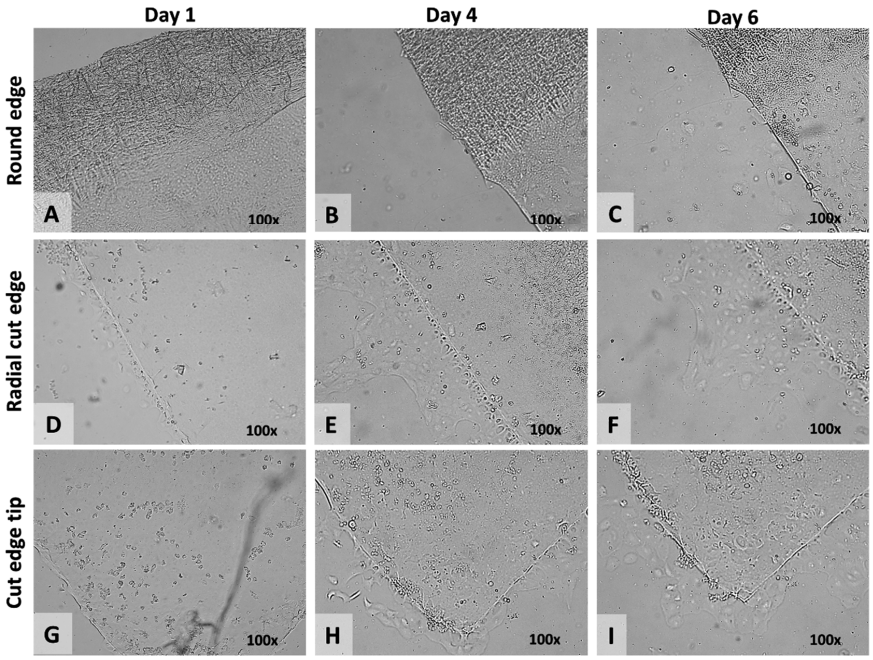

Figure 3| Example of collective *in vitro* endothelial cell (EC) migration. (A–I) Light microscopy images of the round edge (A–C), the radial cut edge (D–F) and the cut edge tip (G–I) of the Quarter-Descemet membrane endothelial keratoplasty (DMEK) graft taken at Day 1 (left), Day 4 (middle) and Day 6 (right) with x100 magnification. (A–C) In the area of the round edge and far periphery of the Quarter-DMEK graft, no EC migration onto the glass slide was observed up to Day 6. (D–F) Along the radial cut edges of the Quarter-DMEK graft, collective EC migration in a form of a monolayer was observed; leader cells at the front edge of the advancing cell sheet are identifiable. (G–I) Around the cut edge tip of the Quarter-DMEK graft, the collective migration pattern was most evident at Day 6.

Immunohistochemistry

Immunohistochemistry analysis confirmed the presence of ECs up to the far peripheral area of the Quarter-DMEK grafts, that is up to the round edge of the graft (**Figure 4**). However, ECs in the centre and far periphery revealed different expression patterns of the typical endothelial markers ZO-1, vimentin, and Na^+/K^+ –ATPase (**Figure 4**). While ZO-1 expression at the apical junctions in the central graft area showed the typical hexagonal cell borders, the distribution of ZO-1 towards the intermingled fibrillary area in the far periphery was more discontinuous and revealed larger cells than in the central area (**Figure 4A,B**). Differences in cell size and shape between ECs in the centre and far periphery were also shown by the expression of vimentin that showed a mat of filaments within the EC cytoplasm in the far periphery (**Figure 4C,D**). Towards the far periphery, also Na^+/K^+ –ATPase pumps were expressed more irregularly (**Figure 4E,F**). The absence of α-SMA-positive cells in both central and peripheral regions of the Quarter-DMEK graft verified the absence of any transformed ECs (**Figure 4G,H**).

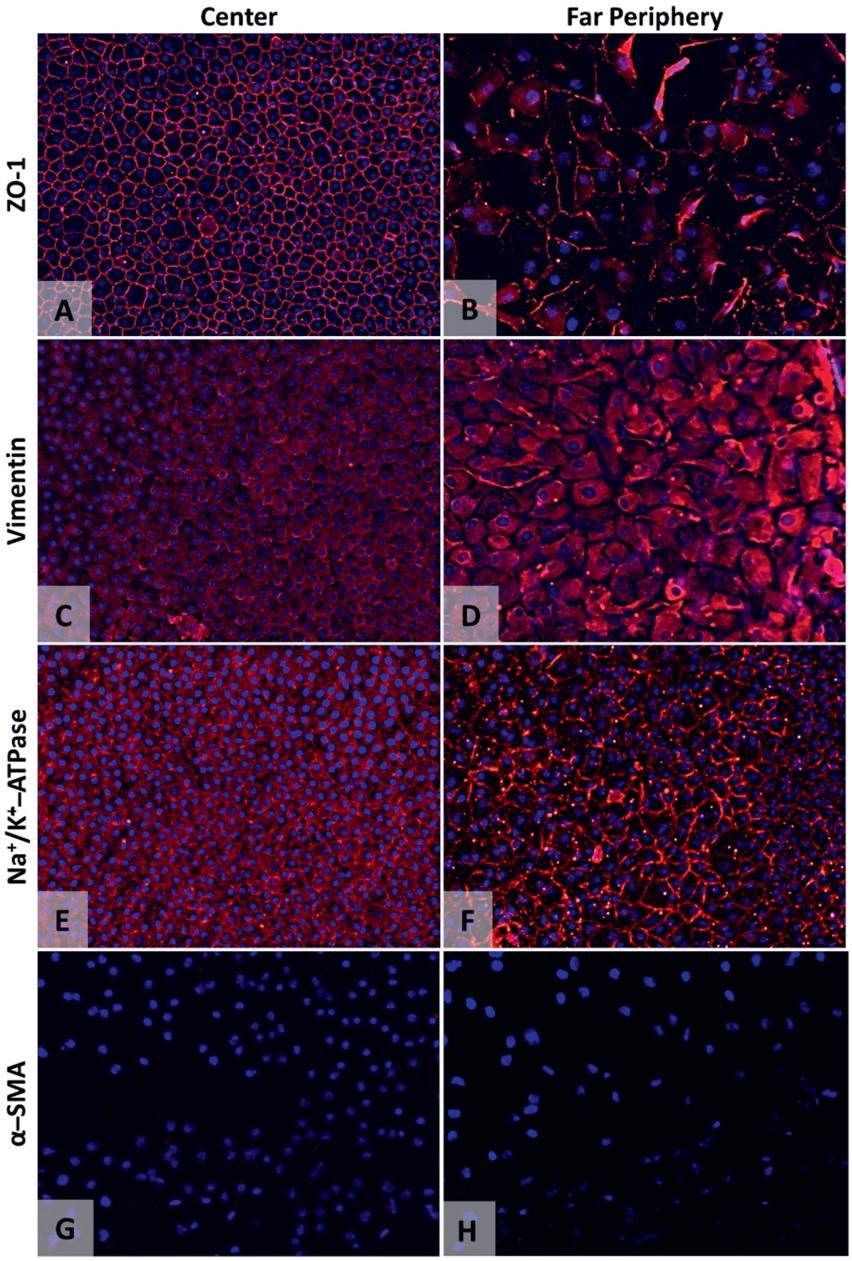

Figure 4| Immunofluorescence staining of the Quarter-Descemet membrane endothelial keratoplasty (DMEK) graft in the centre compared to the far periphery. Expression of ZO-1 (A,B), vimentin (C,D), Na^+/K^+ –ATPase (E,F) and α-smooth muscle actin (α-SMA; G,H) was analysed. The central endothelium showed characteristic expressions for the tight junction protein ZO-1 (A, red), structural protein vimentin (C, red) and functional protein Na^+/K^+ –ATPase (E, red) counter- stained with DAPI (blue). The presence of markers in the far peripheral area (B,D,F) verified the presence of endothelial cells (ECs) up to the round edge of the Quarter-DMEK graft. However, the cells in the far periphery showed a different expression pattern for these endothelial markers (B,D,F red) as compared to the central area. α-SMA, used as a negative control for the ECs, was absent in the centre and in the far periphery of the endothelium (G,H). x200 magnification.

Discussion

In this study, we evaluated how EC migration may vary over different anatomical corneal areas, by studying *in vitro* EC migration from organ cultured Quarter-DMEK grafts.

Our results showed that corneal ECs migrate from the radial cut edges but not from the round edge of a Quarter-DMEK graft, that is the far, 'limbal' periphery of DM. The lack of EC migration from the peripheral round edge may be explained by the structural organization of the peripheral DM. Immunolocalization showed expression of the structural (ZO-1 and vimentin) and functional (Na^+/K^+ –ATPase) markers up to the far periphery, however, although ECs in the far periphery formed a cellular monolayer, these cells did not show the typical hexagonal cell structure.

He et al. (2012) showed that in the corneal far periphery, ECs were organized in small radial rows induced by the furrow-like distribution of the underlying collagen fibres. It was suggested that this anatomical organization is to direct the migration of ECs from specific niches in the far periphery towards the centre of the cornea throughout life, limiting the migration in the other direction. Hence, if migration would not occur or is limited from the limbal edge of a Quarter-DMEK graft, it may be important to position the graft eccentrically, with its radial cut edges near the pupillary area while the peripheral round edge is positioned peripherally, to avoid slowly resolving corneal oedema in the visual axis.[5] Further, it may be beneficial for the smaller Quarter-DMEK graft – compared to a circular conventional graft – that not all cells are able to 'leave' the graft. This could possibly enable early stabilization of the EC density over time.

Although detailed knowledge about the movement of corneal ECs is lacking, migration of other cell sheets has been studied more extensively, especially *in vitro*.[6–10] Under normal conditions, cells maintain strong adhesions with neighboring cells. When a wound is created, the released transient chemical signals enhance cellular motility near the edge of the wound and cells at the wound edge extend large polarized lamellipodia towards the free surface producing an overall traction force that is directed towards the wound.[8–10] Another important denominator of cell migration is growth factor signaling, which is necessary for directional migration.[6] For instance, *in vitro*, fibroblast growth factor 2 (FGF-2, bFGF), has been shown to induce human umbilical vein ECs near the boundary of a sheet to move into open space, whereas in the absence of bFGF, cells migrated with normal speed but failed to sense open space or to respond with directed movement.[6]

While collective migration patterns were observed for other cell types, in our study, uncoordinated or individual migration patterns were more prevalent, which might be partly explained by the experimental set-up that might induce a limited number of viable neighboring cells, for example due to cell damage during tissue handling. However, differences in cell migration from the radial cut edges and from the peripheral round edge were clearly distinguishable.

Recent studies on the effect of Rho associated kinase (ROCK) inhibitors showed that topical administration of ROCK-inhibitors after induced surgical injury of rabbit corneal endothelium triggered cell adhesive changes which contributed to enhanced proliferation and migration.[11] A similar observation was made after cases of surgical 'Descemetorhexis only' procedures, that is stripping of a diseased DM–endothelium layer without subsequent corneal graft transplantation, followed by topical administration of ROCK-inhibitors (Moloney et al. 2017). Although, corneas after Quarter-DMEK may show sufficient clearance (Zygoura et al. 2018), ROCK-inhibitors may potentially enhance EC migration and corneal clearance. However, as ROCK-inhibitors were not administered after *in vivo* Quarter-DMEK surgery, they were also not added as an agent to the serum-containing growth media in our experiments to ensure better comparability of *in vitro* and *in vivo* EC migration patterns.

In conclusion, asymmetrical EC migration of Quarter-DMEK grafts may explain the corneal clearance pattern after Quarter-DMEK surgery, with cell migration predominantly from the radial cut edges, but not the rounded, limbal edge. While the ECs from the graft's far periphery may not contribute to corneal clearance after Quarter-DMEK surgery, these cells may constitute a valuable cellular reserve on the graft.

References

1. Gerber-Hollbach N, Parker J, Baydoun L, Liarakos VS, Ham L, Dapena I, et al. Preliminary outcome of hemi-Descemet membrane endothelial keratoplasty for Fuchs endothelial dystrophy. Br J Ophthalmol. 2016 Nov;100(11):1564-1568. https://doi.org/10.1136/bjophthalmol-2015-307783 PMID: 26837507
2. Lie JT, Lam FC, Groeneveld-van Beek EA, van der Wees J, Melles GR. Graft preparation for hemi-Descemet membrane endothelial keratoplasty (hemi-DMEK). Br J Ophthalmol. 2016 Mar;100(3):420-4. https://doi.org/10.1136/bjophthalmol-2015-307335 PMID: 26508780
3. Müller TM, Baydoun L, Melles GR. 3-Year update on the first case series of hemi-Descemet membrane endothelial keratoplasty. Graefes Arch Clin Exp Ophthalmol. 2017 Jan;255(1):213-215. https://doi.org/10.1007/s00417-016-3517-5 PMID: 27783157
4. Müller TM, Lavy I, Baydoun L, Lie JT, Dapena I, Melles GR. Case report of Quarter-Descemet membrane endothelial keratoplasty for Fuchs endothelial dystrophy. Cornea. 2017 Jan;36(1):104-107. https://doi.org/10.1097/ICO.0000000000001008 PMID: 27583798
5. Zygoura V, Baydoun L, Ham L, Bourgonje VJA, van Dijk K, Lie JT, et al. Quarter-Descemet membrane endothelial keratoplasty (Quarter-DMEK) for Fuchs endothelial corneal dystrophy: 6 months clinical outcome. Br J Ophthalmol. 2018 Oct;102(10):1425-1430. https://doi.org/10.1136/bjophthalmol-2017-311398 PMID: 29343529
6. Vitorino P, Meyer T. Modular control of endothelial sheet migration. Genes Dev. 2008 Dec 1;22(23):3268-81. https://doi.org/10.1101/gad.1725808 PMID: 19056882
7. Mayor R, Carmona-Fontaine C. Keeping in touch with contact inhibition of locomotion. Trends Cell Biol. 2010 Jun;20(6):319-28. https://doi.org/10.1016/j.tcb.2010.03.005 PMID: 20399659
8. Gov N. Cell mechanics: moving under peer pressure. Nat Mater. 2011 Jun;10(6):412-4. https://doi.org/10.1038/nmat3036 PMID: 21602874
9. Tambe DT, Hardin CC, Angelini TE, Rajendran K, Park CY, Serra-Picamal X, et al. Collective cell guidance by cooperative intercellular forces. Nat Mater. 2011 Jun;10(6):469-75. https://doi.org/10.1038/nmat3025 PMID: 21602808
10. Trepat X, Fredberg JJ. Plithotaxis and emergent dynamics in collective cellular migration. Trends Cell Biol. 2011 Nov;21(11):638-46. https://doi.org/10.1016/j.tcb.2011.06.006 PMID: 21784638
11. Meekins LC, Rosado-Adames N, Maddala R, Zhao JJ, Rao PV, Afshari NA. Corneal Endothelial Cell Migration and Proliferation Enhanced by Rho Kinase (ROCK) Inhibitors in *In Vitro* and *In Vivo* Models. Invest Ophthalmol Vis Sci. 2016 Dec 1;57(15):6731-6738. https://doi.org/10.1167/iovs.16-20414 PMID: 27951595

CHAPTER 6

Improving endothelial explant tissue culture by novel thermoresponsive cell culture system

Curr Eye Res. 2021 Mar;46(3):290-293

Alina Miron, Daniele Spinozzi, Jessica Lie, Gerrit RJ Melles, Silke Oellerich, Sorcha Ní Dhubhghaill

ABSTRACT

Aim: Studying cell migration of corneal endothelial cells *in vitro* is challenging because the capacity for cell migration needs to be maintained while at the same time the tissue must remain fixed on a rigid substrate. In this study, we report a thermoresponsive culture technique designed to maintain cellular viability, and to reduce tissue handling in order to analyze *in vitro* endothelial cell migration from corneal grafts.

Materials and Methods: As a test tissue, fifteen Quarter-Descemet membrane endothelial keratoplasty (Q-DMEK) grafts were used that were embedded in a three-dimensional culture system using a temperature-reversible hydrogel and cultured over 2–3 weeks in a humidified atmosphere at 37°C and 5% CO_2.

Results: All grafts could be successfully cultured inside the thermoresponsive polymer solution for periods of up to 21 days. Using this system, cell migration could be assessed by light microscopy at fixed time intervals. At the end of the culture period, the gel could be removed from all grafts and immunohistochemistry analysis showed that endothelial cells were able to maintain confluence, viability, and junctional integrity. Some problems were encountered when using the thermoresponsive cell culture system. These were mostly structural inconsistencies during the sol-to-gel transition phase that resulted in the formation of tiny bubbles in the matrix. Additionally, areas with different viscosity resulted in optical distortions showing up as folds throughout the matrix which can persist even after several cycles of culture medium exchange. These effects had impact on the imaging quality but did not affect the viability of the explant tissue.

Conclusion: This study proves that temperature-reversible hydrogel is a very useful matrix for studying *in vitro* corneal endothelial cell migration from explant grafts and allows for subsequent biological investigation after gel removal.

Introduction

Human corneal endothelial cells form a post-mitotic layer that is not thought to proliferate *in vivo* and are known to be difficult to culture.[1–3] The cells do however retain the capacity to spread and migrate to restore a defect in the endothelium as a wound healing response. This restorative capacity is already being applied in clinical practice by new surgical techniques and the rate of cells migration is directly related to the speed of corneal clearance and postoperative recovery.[4–7]

Study endothelial cell migration *in vitro* is challenging since simply placing the explants on glass, even when coated with extracellular matrix proteins, tends to result in poor adhesion, outgrowth, and grafts lifting off the slide.[5] Corneal endothelium on Descemet membrane, once peeled off the cornea, has a well-known rolling property in fluid rendering explant culture very difficult.[8] We therefore developed a new approach by embedding the explant in a thermoresponsive gel matrix for studying endothelial cell migration from shape-adapted endothelial grafts.[9] In this paper, we describe the technical 'ins and outs' of the proposed culture system that demonstrates the ability to be remodeled by cells during migration, permeability to oxygen and nutrient growth factors, and maintaining the tissue fixed on a rigid surface.

Materials and methods

Materials

Dulbecco's phosphate-buffered saline (PBS), fetal bovine serum (FBS), L-Glutamine, ascorbic acid 2-phosphate (Asc-2P), basic fibroblast growth factor (bFGF), Dulbecco's Modified Eagle's medium (DMEM), and Calcein-AM were purchased from Sigma-Aldrich Chemistry BV (Zwijndrecht, The Netherlands). Fibronectin, collagen, and albumin (FNC) coating mix was purchased from Athena ESTM (Baltimore, MD, USA), Pen/Strep Pre-Mix from Carl Roth GmbH + Co. KG (Karlsruhe, Germany), and Mebiol® Gel (Cosmo Bio, Carlsbad, CA, USA) from Bio-Connect B.V. (Huissen, The Netherlands).

Methods

Corneas

Human postmortem corneas, ineligible for transplantation, but with an intact and viable endothelial cell layer were obtained from Amnitrans EyeBank Rotterdam. There being no objection by the donors to transplant-related research, the study adhered to the tenets of the Declaration of Helsinki and the Barcelona Principles.[10]

Tissue preparation

Fifteen Quarter-Descemet membrane endothelial keratoplasty (Quarter-DMEK) grafts were prepared as described previously.[11] Quarter-DMEK-grafts was then stored separately in organ-culture medium (CorneaMax, Eurobio) for fewer than 24 hours before chemotactic cell ability evaluation.

Preparation of Mebiol® Gel culture medium and tissue embedding process

The lyophilized thermoresponsive hydrogel is liquid at lower temperatures (4–8°C) and becomes a firmer and more gel-like matrix at the culture temperature (37°C). The gel is prepared by dissolving in 50 ml DMEM supplemented with 15% FBS, 2 mM L-Glutamine, 2 ng/ml bFGF, 0.3 mM Asc-2P, and 10,000 U-ml Pen/Strep,

refrigerated at 4°C for three hours to create a viscous solution, then carefully aliquoted to avoid air bubbles, and stored at −20°C.

For gel embedding, tissue was placed endothelial-side-up on FNC-coated glass coverslips and transferred to a 24-well plate. After embedding, Quarter-DMEK grafts were photographed daily with an AxioVert.A1 microscope with AxioCam 305 color camera (Zeiss, Oberkochen, Germany).

Immunohistochemistry

After gel removal, different structural and functional markers such as ZO-1 (tight junction protein 1 (TJP1)/ zonula occludens-1) , vimentin, and sodium–potassium pump (Na^+/K^+ –ATPase) were used to prove the feasibility of immunohistochemistry characterization after gel removal and to show the structural and functional integrity of the cells. In addition, Calcein-AM staining was performed to verify cell viability after gel removal. The staining protocols have been described previously.[5,12]

Results

Tissue embedding

For embedding the explant tissue in the gel matrix, Quarter-DMEK grafts were placed endothelial side-up on the FNC coated substrate and the thermoresponsive medium mix was added slowly, drop by drop over the center of the graft, to prevent shifting. After the graft was covered by a thin layer, it was incubated at 37°C for about 5 minutes to solidify the layer. Once firm, more medium mix was added up to a volume of approximately 700 µl. Subsequent incubation at 37°C for about 10 minutes led to a solidified gel matrix uniformly distributed over the grafts. Growth factors and nutrients were replenished by keeping the gel surface moist with 300 µl of culture medium[13] every 2–3 days.

Gel removal

All Quarter-DMEK grafts could successfully be recovered from the gel matrix by cooling the gel below the sol-gel transition temperature (<20°C). Firstly, the warm culture medium was replaced by cold fluid (PBS or DMEM) and gently aspirated 5 minutes later, removing the uppermost liquefied layer of the gel. This was performed several times until the gel was removed completely. No fixating of the graft was required before gel removal to keep it in place.

Cell migration and comparison with previous approach

Gel embedding was successful for all grafts and allowed for observation of cell migration for up to 21 days during which, cells appeared viable and continued to migrate. After 21 days, cells had not shown any change in viability and the rate outgrowth had not abated. Longer culture times may therefore be possible in contrast to our previous approach, serving as a negative control, in which the grafts were “sandwiched” between two glass slides separated by a suture wire to prevent direct compression.[5]

Immunohistochemistry

After successful gel removal, tissue could be evaluated further by immunohistochemistry and the migrated cell layer (**Figure 1A**) remained attached to the glass support in all cases. Cells showed expression of the structural

and functional markers in the confluent layer of migrating cells and on the graft itself (**Figure 1B, C, E**) after gel removal. Calcein-AM staining confirmed cell viability after gel removal (**Figure 1D**). The dashed white line outlines in (**Figure 1A**) the cell migration edge and in (**Figure 1B-E**) the Quarter-DMEK graft edge.

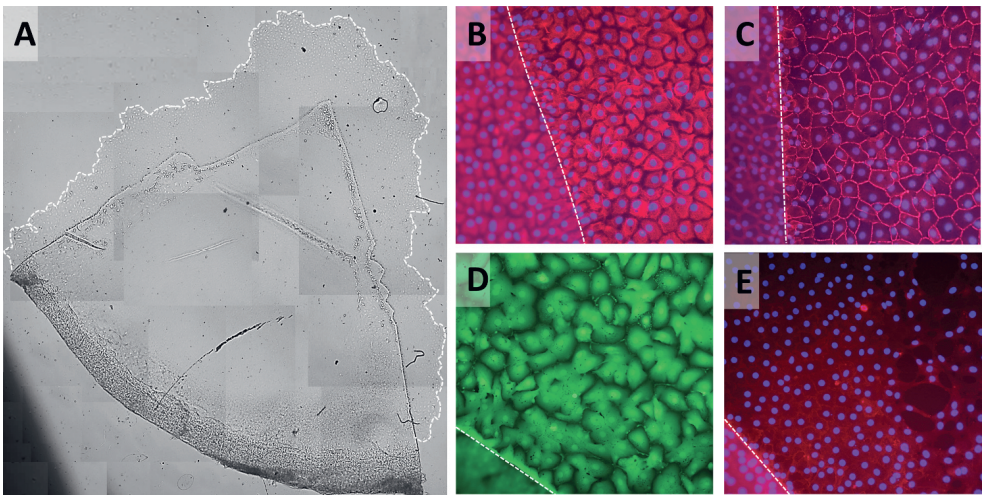

Figure 1| Example of biological research after gel removal. (A) Collage of light microscopy images (x50 magnification) to create an overview of a flattened Quarter-DMEK graft at the end of the cell migration experiment, after removing the liquefied gel at temperatures below 20°C. Expression of vimentin (B), ZO-1 (C), Calcein-AM (D), and Na^+/K^+ –ATPase (E) determined by immunohistochemistry in the confluence monolayer of cultured cells. x200 magnification.

Thermoresponsive hydrogel matrix – possible complications

Some problems were encountered when using the thermoresponsive cell culture system that can be avoided or managed. The most frequent was the formation of air bubbles inside the matrix that appeared to variable degrees for all embedded samples (**Figure 2**). Additionally, areas with different viscosity result in optical distortions showing up as folds throughout the matrix which can appear even after several cycles of culture medium exchange (**Figure 2**). These had an impact on the imaging quality but did not affect the explant tissue itself. In case of air bubble formation close to the graft, it was found that cooling the gel down to 15°C, gently aspirating the fluid and restarting the sample embedding process, could minimize the bubble. Air bubbles that formed more superficially in the gel matrix, were observed to decrease in size and shape during culture. In case of optical folds due to inhomogeneous viscosity distribution in the gel matrix, these may become more uniform in structure after few warm-RT cycles of culture medium exchange.

In 2/15 grafts, we observed graft shifting during gel removal (**Figure 2**) which resulted in a disruption of the newly formed monolayer. This tissue gliding over the solid support during gel removal can be minimized by taking care to aspirate the liquified gel as slowly as possible.

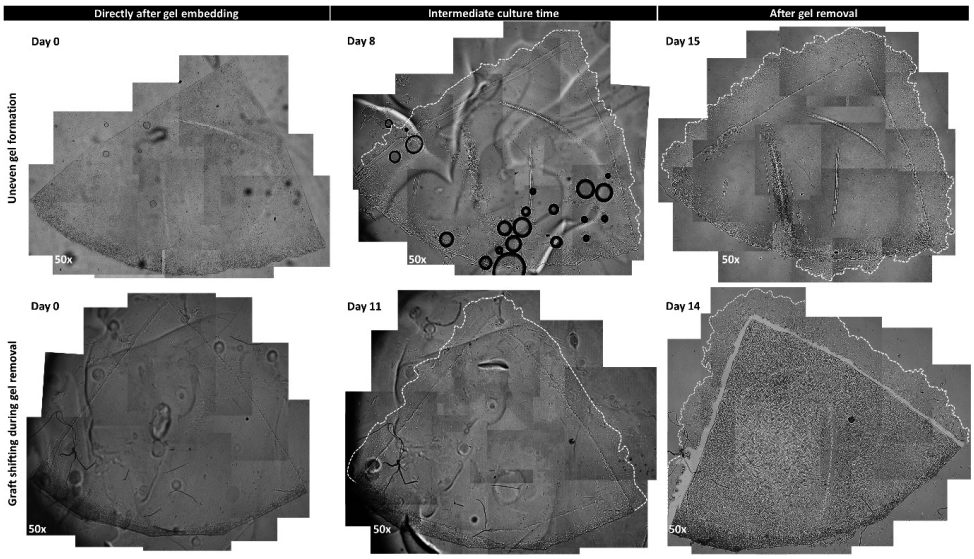

Figure 2| Complications of the thermoresponsive-hydrogel technique. The top panel displays a case of uneven gel formation: after placing the graft endothelial-side-up on FNC-coated glass coverslip (day 0, before culture) the addition of stocking gel led to small air bubble formation (day 8). In addition, minor folds throughout the matrix could be seen (day 8). Both the air bubble and folds had no impact on the graft viability during culture (day 15, after gel removal). The bottom panel shows a case of graft shifting (day 14: yellow outlined area) from its original positions (day 0) during the gel removal step. Throughout the culture time, the graft did not change its position and showed substantial endothelial cell migration (day 11) along the radial cut graft edges as outlined by the dotted white line. x50 magnification.

Discussion

With this adapted explant culture protocol based on a thermoresponsive hydrogel for *in vitro* studies on corneal grafts, we saw improved cell viability and collective cell migration which continued far longer than with the prior[5] culture system.

Grafts were kept up to 3 weeks in the hydrogel matrix and when the gel reaction was reversed, immunohistochemistry demonstrated the presence of viable cells with tightly packed morphologies. It is important to mention that on the day when grafts were recovered from the gel, cells had not shown any change in the rate of outgrowth or cell viability, therefore longer culturing times could have also been possible.

This culture system has been useful in several ways. Firstly, the consistent migration pattern observed *in vitro* helps explain the corneal clearance after corneal transplantation.[5,6,9,11]

Secondly, this method may help optimizing graft preparation to try to promote cell migration,[9] but can also be used for other purposes. This thermoresponsive cell culture system supports morphological and physiological cell changes through specific scaffold geometry and composition.[14,15] Although, other cell culture matrices provide good cell adhesion, they could in the same time make cell retrieval more difficult.[16] The temperature-reversible properties of the hydrogel presented here, on the other hand, permit cell retrieval without enzymatic treatment, which is difficult using hyaluronic acid hydrogel matrices.[17]

The question of maintaining cell polarity during cell migration in gel culture may be an issue. However, we previously demonstrated the monolayer dynamics during migration, emphasizing the difference in marker

expression between front and rear edge of the cell monolayer,[9] inferring that after migration, normal polarity can return as seen *in vivo*.

While the presented approach allows to keep the explant tissue flattened in a fixed position on the substrate, provides sufficient nutrient supply, and enables tissue retrieval at the end of the culture period, some technical challenges may occur during tissue embedding and retrieval. Occasionally, air bubbles get trapped in the matrix while adding stocking gel over the graft and inhomogeneous viscosity distribution may induce optical folds that should not be confused with folds of the tissue itself to avoid unnecessary tissue handling due to attempted repositioning.

Conclusion

In conclusion, this culturing technique based on temperature reversible hydrogel proves to be a very useful matrix for studying *in vitro* cell migration from explant tissue and allows for subsequent fundamental biological research after gel removal.

References

1. Peh GS, Toh KP, Ang HP, Seah XY, George BL, Mehta JS. Optimization of human corneal endothelial cell culture: density dependency of successful cultures *in vitro*. BMC Res Notes. 2013 May 3;6:176. https://doi.org/10.1186/1756-0500-6-176 PMID: 23641909
2. Peh GS, Beuerman RW, Colman A, Tan DT, Mehta JS. Human corneal endothelial cell expansion for corneal endothelium transplantation: an overview. Transplantation. 2011 Apr 27;91(8):811-9. https://doi.org/10.1097/TP.0b013e3182111f01 PMID: 21358368
3. Peh GS, Chng Z, Ang HP, Cheng TY, Adnan K, Seah XY, et al. Propagation of human corneal endothelial cells: a novel dual media approach. Cell Transplant. 2015;24(2):287-304. https://doi.org/10.3727/096368913X675719 PMID: 24268186
4. Van den Bogerd B, Dhubhghaill SN, Koppen C, Tassignon MJ, Zakaria N. A review of the evidence for in vivo corneal endothelial regeneration. Surv Ophthalmol. 2018 Mar-Apr;63(2):149-165. https://doi.org/10.1016/j.survophthal.2017.07.004 PMID: 28782549
5. Miron A, Spinozzi D, Bruinsma M, Lie JT, Birbal RS, Baydoun L, et al. Asymmetrical endothelial cell migration from *in vitro* Quarter-Descemet membrane endothelial keratoplasty grafts. Acta Ophthalmol. 2018 Dec;96(8):828-833. https://doi.org/10.1111/aos.13841 PMID: 30171674
6. Birbal RS, Ni Dhubhghaill S, Baydoun L, Ham L, Bourgonje VJA, Dapena I, et al. Quarter-Descemet membrane endothelial keratoplasty: one- to two-year clinical outcomes. Cornea. 2020 Mar;39(3):277-282. https://doi.org/10.1097/ICO.0000000000002127 PMID: 31490274
7. Zygoura V, Baydoun L, Ham L, Bourgonje VJA, van Dijk K, Lie JT, et al. Quarter-Descemet membrane endothelial keratoplasty (Quarter-DMEK) for Fuchs endothelial corneal dystrophy: 6 months clinical outcome. Br J Ophthalmol. 2018 Oct;102(10):1425-1430. https://doi.org/10.1136/bjophthalmol-2017-311398 PMID: 29343529
8. Groeneveld-van Beek EA, Lie JT, van der Wees J, Bruinsma M, Melles GR. Standardized 'no-touch' donor tissue preparation for DALK and DMEK: harvesting undamaged anterior and posterior transplants from the same donor cornea. Acta Ophthalmol. 2013 Mar;91(2):145-50. https://doi.org/10.1111/j.1755-3768.2012.02462.x PMID: 22672202
9. Miron A, Spinozzi D, Ní Dhubhghaill S, Lie JT, Oellerich S, Melles GRJ. In vitro endothelial cell migration from limbal edge-modified Quarter-DMEK grafts. PLoS One. 2019 Nov 20;14(11):e0225462. https://doi.org/10.1371/journal.pone.0225462 PMID: 31747441
10. The Barcelona Principles: An agreement on the use of human donated tissue for ocular transplantation, research, and future technologies©. Cornea. 2018 Oct;37(10):1213-1217. https://doi.org/10.1097/ICO.0000000000001675 PMID: 30198942
11. Müller TM, Lavy I, Baydoun L, Lie JT, Dapena I, Melles GR. Case report of Quarter-Descemet membrane endothelial keratoplasty for Fuchs endothelial dystrophy. Cornea. 2017 Jan;36(1):104-107. https://doi.org/10.1097/ICO.0000000000001008 PMID: 27583798
12. Spinozzi D, Miron A, Bruinsma M, Dapena I, Lavy I, Binder PS, et al. Evaluation of the suitability of biocompatible carriers as artificial transplants using cultured porcine corneal endothelial cells. Curr Eye Res. 2019 Mar;44(3):243-249. https://doi.org/10.1080/02713683.2018.1536215 PMID: 30339045
13. Spinozzi D, Miron A, Bruinsma M, Lie JT, Dapena I, Oellerich S, et al. Improving the success rate of human corneal endothelial cell cultures from single donor corneas with stabilization medium. Cell Tissue Bank. 2018 Mar;19(1):9-17. https://doi.org/10.1007/s10561-017-9665-y PMID: 29043524
14. Spinozzi D, Miron A, Bruinsma M, Lie JT, Dapena I, Oellerich S, et al. Improving the success rate of human corneal endothelial cell cultures from single donor corneas with stabilization medium. Cell Tissue Bank. 2018 Mar;19(1):9-17. https://doi.org/10.1007/s10561-017-9665-y PMID: 29043524
15. Maltman DJ, Przyborski SA. Developments in three-dimensional cell culture technology aimed at improving the accuracy of *in vitro* analyses. Biochem Soc Trans. 2010 Aug;38(4):1072-5. https://doi.org/10.1042/BST0381072 PMID: 20659006
16. Duval K, Grover H, Han LH, Mou Y, Pegoraro AF, Fredberg J, et al. Modeling physiological events in 2D vs. 3D cell culture. Physiology (Bethesda). 2017 Jul;32(4):266-277. https://doi.org/10.1152/physiol.00036.2016 PMID: 28615311
17. Jooybar E, Abdekhodaie MJ, Alvi M, Mousavi A, Karperien M, Dijkstra PJ. An injectable platelet lysate-hyaluronic acid hydrogel supports cellular activities and induces chondrogenesis of encapsulated mesenchymal stem cells. Acta Biomater. 2019 Jan 1;83:233-244. https://doi.org/10.1016/j.actbio.2018.10.031 PMID: 30366137

CHAPTER 7

In vitro endothelial cell migration from limbal edge-modified Quarter-DMEK grafts

PLoS One. 2019 Nov 20;14(11):e0225462

Alina Miron, Daniele Spinozzi, Sorcha Ní Dhubhghaill, Jessica T. Lie, Silke Oellerich, Gerrit R. J. Melles

Abstract

Endothelial cell migration plays a crucial role in achieving corneal clearance after corneal transplantation when using smaller-sized endothelial grafts to increase the donor pool. In this study we investigated how different strategies of Quarter-Descemet Membrane Endothelial Keratoplasty (Quarter-DMEK) limbal graft edge modification influence peripheral endothelial cell migration in an *in vitro* culture environment. For this study, 15 Quarter-DMEK grafts, prepared from 7 corneas deemed ineligible for transplantation but with intact and viable endothelial cells, were embedded in a cooled biocompatible, thermoresponsive matrix for culture. The limbal edge of ten Quarter-DMEK grafts were modified, either by using a small diameter punch or by peripheral radial cuts. All Quarter-DMEK grafts showed substantial collective endothelial cell migration from the radial cut graft edges, as observed by light microscopy at standardized time intervals. Grafts were retrieved from the polymer matrix after the two-week culture for immunohistochemistry analyses of the newly formed cell monolayers; this demonstrated the presence of tightly packed and viable cells that showed higher migratory ability at the leading edge. Peripheral endothelial cell migration, however, was not triggered by increasing cell exposure to free space through surgical modifications of the far periphery. Our data suggest that alterations in the far peripheral area of Quarter-DMEK grafts were insufficient to triggering cell migration from the limbal graft edge. This may be due to transient-amplifying cells that reside in the far periphery and which lack cytokinetic directional cues. Understanding the migration capacity of the peripheral endothelium could unlock cells' therapeutic potential which are, at present, routinely discarded from transplantation. Encouraging peripheral cell migration may also improve clinical outcomes from Quarter-DMEK, but a more effective solution is required prior to clinical implementation of modified grafts.

Introduction

We have recently introduced several modifications to Descemet membrane endothelial keratoplasty (DMEK), including Quarter-DMEK, as a means to potentially quadruple the availability of usable grafts from a single donor cornea.[1–3] The clinical outcomes are encouraging, use less tissue and the first series of Quarter-DMEK eyes achieved visual outcomes comparable to conventional DMEK.[1,2] At the slit-lamp, however, Quarter-DMEK-eyes typically showed a different corneal edema clearance pattern, due to the mismatch between the patient's round descemetorhexis and the quadrant shape of the graft. This mismatch results in areas of bare stroma that must be cleared by migrating endothelial cells (EC). Clinically, clearing occurs most efficiently in the area adjacent to the radial cut graft edges, but tends to be slow and stagnant along the "limbal" round edge of the Quarter-DMEK-grafts.

We have replicated the cell migration of the Quarter-DMEK grafts in an *in vitro* culture system in our previous experiment.[4] The results confirmed that endothelial cell migration readily occurred along the radial cut edges of the grafts, but that migration from the peripheral limbal edge was not observed. This finding prompted us to question the role played by the peripheral endothelium as a cell source in the restoration of corneal clearance. We hypothesized that the arrangement of fibrillary bands of collagen in the periphery could act a as a barrier or "fence", thereby preventing migration.

This study's purpose was to evaluate whether peripheral edge modification could break down the physical barrier that inhibits cell migration from the limbal edge of the graft, thereby promoting cell migration in a manner similar to the radial edges.

Materials and methods

Corneas

Seven human postmortem corneas, which were ineligible for transplantation but which had an intact and viable endothelial cell layer (from five donors (mean age 69 (±4) years; range 61–73 years)) (**Table 1**), were obtained from Amnitrans EyeBank Rotterdam. All donors stated that they had no objection to transplant-related research and the study adhered to the tenets of the Declaration of Helsinki. No institutional review board approval was obtained, given that no approval is required for this kind of research if no extra procedure was performed to obtain the samples and if donors had consented to having the samples used for research purposes, according to a national regulation (https://www.ccmo.nl/onderzoekers/aanvullende-informatie-over-bepaalde-soorten-onderzoek/niet-wmo-onderzoek/onderzoek-met-lichaamsmateriaal).

Quarter-Descemet membrane endothelial keratoplasty graft preparation

The Quarter-DMEK grafts were prepared at Amnitrans EyeBank Rotterdam, as described previously,[3] by a single eye bank technician (JTL) with extensive experience in DMEK and modified DMEK techniques.[5] For every cornea, two of the four Quarter-DMEK grafts were modified, by either using a 1 mm diameter biopsy punch (Kai Europe GmbH, Solingen, Germany) to create two cuts in the periphery or by using an ophthalmic keratome (MANI, INC. Tochigi, Japan) to create 3 peripheral radial cuts. One Quarter-DMEK graft was used as a backup in case of failed preparation of modified grafts, and one unmodified Quarter-DMEK graft was used as a negative control. A positive control was created by cutting the peripheral edge off from a Quarter-DMEK graft, thereby creating a triangle-shaped endothelial graft. The endothelial cell density (ECD) determined in the eye bank after DMEK graft preparation was on average 2514 (±267) cells/mm^2 for all seven corneas. Each Quarter-DMEK graft was then stored separately in organ culture medium (CorneaMax, Eurobio) for fewer than 24 hours before being evaluated for chemotactic cell ability.

Table 1. Donor demographics.

Donor Information	Indicators
Number of corneas/donors	7/5
Gender	
Female	2
Male	3
Mean age (±SD), yrs. (range)	69 (±4), (61–73)
Mean storage time* (±SD), days (range)	6 (±3), (2–12)
Cause of death	
Cardio/Stroke	2
Respiratory	2
Malignant neoplasm	1

*Mean storage time = time between death and culture of isolated DM-EC tissue; SD = standard deviation; yrs. = years

Preparation of Mebiol1 Gel culture medium

Mebiol1 Gel was obtained in a lyophilized and sterilized flask from Bio-Connect B.V. (Huissen, The Netherlands). The gel was reconstituted in 50 ml of culture medium, consisting of Dulbecco's modified eagle medium (DMEM) supplemented with 15% fetal bovine serum (FBS), 2 mM L-Glutamine, 2 ng/ml fibroblast growth factor (bFGF), 0.3 mM L-ascorbic acid 2-phosphate (all from Sigma-Aldrich, Zwijndrecht, The Netherlands), and 10,000U-ml Pen/Strep (Carl Roth GmbH + Co. KG, Karlsruhe, Germany). The culture-flask was then refrigerated at 4˚C for about three hours yielding a viscous transparent Mebiol1 Gel-culture medium mixture. The uniform liquid sol was then carefully aliquoted, to avoid air bubbles, at desired volumes (1.5–4 ml) and was stored at -20˚C for later use.

Cell migration study

15 individual Quarter-DMEK rolls with the trabecular membrane (TM) attached, obtained from 7 different corneas, were unfolded endothelial-side-up on FNC-coated (fibronectin, collagen, and albumin coating mix, Athena ESTM Baltimore, MD, USA) glass coverslip and evaluated *in vitro* in order to examine whether peripheral edge modifications of a Quarter-DMEK graft could trigger cell migration. Unfolding of all grafts was performed in a "minimal touch" manner by grabbing the graft only at the TM site with a McPherson forceps and dropping organ-culture medium onto the graft while the glass coverslip was kept tilted at a small angle.

The TM was then carefully removed from the Quarter-DMEK grafts, and the endothelium was submerged in serum-containing culture medium in order to ensure cell viability during the experiments. Each glass coverslip, which supported one Quarter-DMEK graft, was transferred to a 24 well plate and a drop of liquefied gel-culture medium mixture (temp 4–8˚C) was placed at the center of the well. The gel became more solid when kept at 37˚C for about 5 minutes. Once the gel became firmer, the well was then completely filled with cooler liquid drops of the gel-culture medium mixture (≈500 µl end volume), thereby preventing Quarter-DMEK grafts gliding over the solid support. Subsequent incubation at 37˚C for about 10 minutes led to a solidified gel matrix that was uniformly distributed over the Quarter-DMEK grafts. Growth factors and nutrients were provided by keeping the gel surface moist using 300 µl of culture medium. Grafts were cultured over 2 weeks in a humidified atmosphere at 37˚C with 5% CO_2. Medium was refreshed every 2–3 days. Quarter-DMEK grafts were

photographed daily with an AxioVert.A1 microscope with AxioCam 305 color camera (Zeiss, Oberkochen, Germany) to examine cell morphology and the degree of cell migration.

The recovery of the Quarter-DMEK grafts after cultivation was performed by cooling the gel below the sol-gel transition temperature (<20°C). Firstly, the warm culture medium was replaced by cold fluid (PBS or DMEM) and gently aspirated 5 minutes later, removing the uppermost liquefied layer of the gel in the process. This was performed several times until the gel was removed completely, without disturbing the graft position in the well.

Immunohistochemistry

Quarter-DMEK samples, reclaimed from gel culture for immunohistochemistry analysis, were first fixed in 4% paraformaldehyde (Sigma Aldrich, The Netherlands) for 15 minutes. Following fixation, the grafts were then washed with phosphate-buffered saline (PBS), permeabilized using permeabilization buffer (0.1% Triton X-100 in PBS, Sigma Aldrich, The Netherlands) and finally incubated with blocking buffer (5% bovine serum albumin in PBS, Sigma Aldrich, The Netherlands) for 30 minutes in order to prevent non-specific staining. Blocking buffer was also used for both primary and secondary antibody (Life Technology, The Netherlands) dilutions.

Samples were stained for the expression of zonula occludens-1 (ZO-1), vimentin and Na^+/K^+ –ATPase to establish the baseline endothelial morphology and CD73 for potential cell migration. Incubation with primary antibodies was performed at the following dilutions: anti-ZO-1 tight junction protein (anti ZO-1/TJP1, dilution 1:100), anti-vimentin filamentous protein (anti-vimentin, dilution 1:100), anti-sodium/potassium–ATPase (anti-Na^+/K^+ –ATPase, dilution 1:100) and anti-lymphocyte differentiation antigen CD73 (anti-CD73, single purchase from Abcam, Cambridge, United Kingdom, dilution 1:100). Incubations were performed for 1 hour and were then followed by several PBS washing steps. Samples were then incubated with fluorescent secondary antibodies that had been conjugated to Alexa Fluor® (dilution 1:200) for 45 minutes. After washing with PBS, the samples were stained with 4',6-diamidino-2-phenylindole (DAPI, Sigma-Aldrich, The Netherlands) to visualize the nuclear DNA, and were then imaged using an inverted fluorescence microscope connected to a camera (Axiovert, Zeiss).

Cell viability assay

The membrane-permeable dye Calcein-AM (Sigma-Aldrich Chemistry BV, Zwijndrecht, The Netherlands) was received as stock solution of 4 mM in dimethylsulfoxide at -20˚C, prepared as a working solution of 400 µM in PBS and added directly to grafts in order to examine the cell viability of Quarter-DMEK grafts after the culture period. A 45-minute incubation period at room temperature allowed for the nonfluorescent Calcein-AM to be hydrolysed by intercellular esterases into the highly negatively charged green fluorescent Calcein, which is retained in the cell cytoplasm. After one more PBS washing step, grafts were ready for imaging by microscopy.

Results

Cell migration study

All grafts placed in culture showed cell migration along the radial cut edges up to the tip of the graft (**Figure 1**). The degree of migration decreased towards the peripheral graft area in both the limbal edge-modified and unmodified Quarter-DMEK grafts (negative control) in which the dense fibrillary area was exposed to the open space (**Figure 1A–C**). The peripheral edge modification of the graft in order to cut through the dense fibrillary area either with the biopsy punch or radial cuts, did not sufficiently stimulate cell migration to populate the limbal round edge of the graft (**Figure 1B and C**). Greater cell migration was seen when the cuts were very deep

and protruding into the paracentral zone of the endothelium (**Figure 1C**). The positive control graft, where the fibrillary area was completely removed, showed a uniform cell migration pattern all around the cut edges (**Figure 1D**).

All grafts showed substantial cell migration from day 4 up to day 15 (**Figure 2**) which was when the graft was retrieved for immunohistochemistry evaluation. Cells migrated in interconnected groups (i.e., collective cell migration) with a "leading" cell group seen at the front edge in all grafts (15/15).



Figure 1| Representative images of each type of Quarter-DMEK graft modification and Quarter-DMEK graft controls after two weeks *in vitro* gel culture. Collage of light microscopy images (x25 magnification) to create an overview of the (A) Quarter-DMEK graft with intact far periphery showing lack of cell migration along the limbal round edge (negative control), (B) fence-broken Quarter-DMEK graft for which the periphery was punched with a 1 mm diameter biopsy punch twice, showing no stimulation of cell migration, (C) Quarter-DMEK graft for which the periphery was radially cut three times with an ophthalmic knife showing cell migration initiated only from those deep cuts (red marks) bypassing the intermingled fibrillary area and opening the endothelium's periphery, (D) Quarter-DMEK graft with a cut off periphery showing uniform cell migration from all cut edge sites (positive control). The dashed line outlines the cell monolayer migration edge.

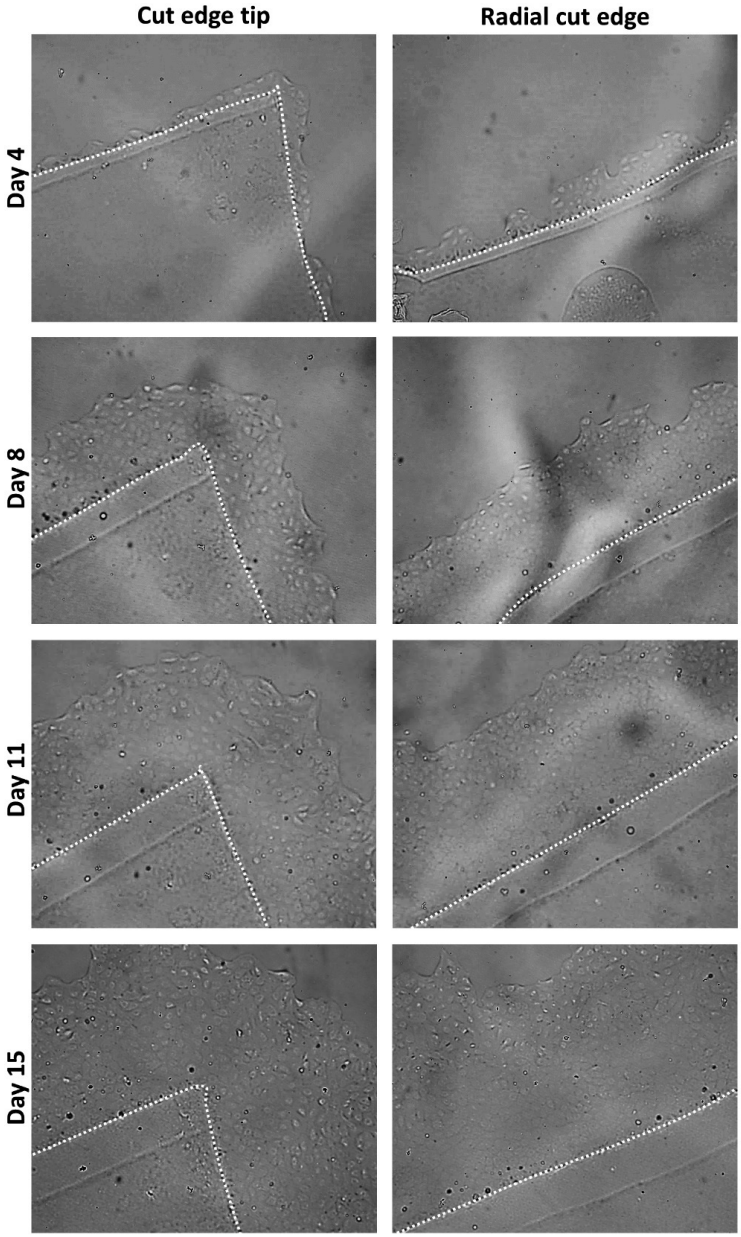

Figure 2| Example of collective *in vitro* endothelial cell migration from gel-cultured Quarter-DMEK grafts. Light microscopy images of the cut edge tip (Left) and the radial cut edge (Right) of a Quarter-DMEK graft taken at Day 4, Day 8, Day 11, and Day 15 (Top to Bottom view) with 100x magnification. Around the cut edge tip and along the radial cut edges of the Quarter-DMEK graft collective endothelial cell migration in a form of a monolayer was observed; leader cells at the front edge of the advancing cell sheet are identifiable; collective migration pattern was most evident at Day 8. The latter appear out of focus and hazy due to the difference in focal plane between the migrated cells and the cells on the graft itself (height difference due to Descemet membrane). In each of the photos, the dashed line outlines the edge of the Quarter-DMEK graft. The double-lined cut edge of the graft in all images is an optical aberration caused by the gel matrix.

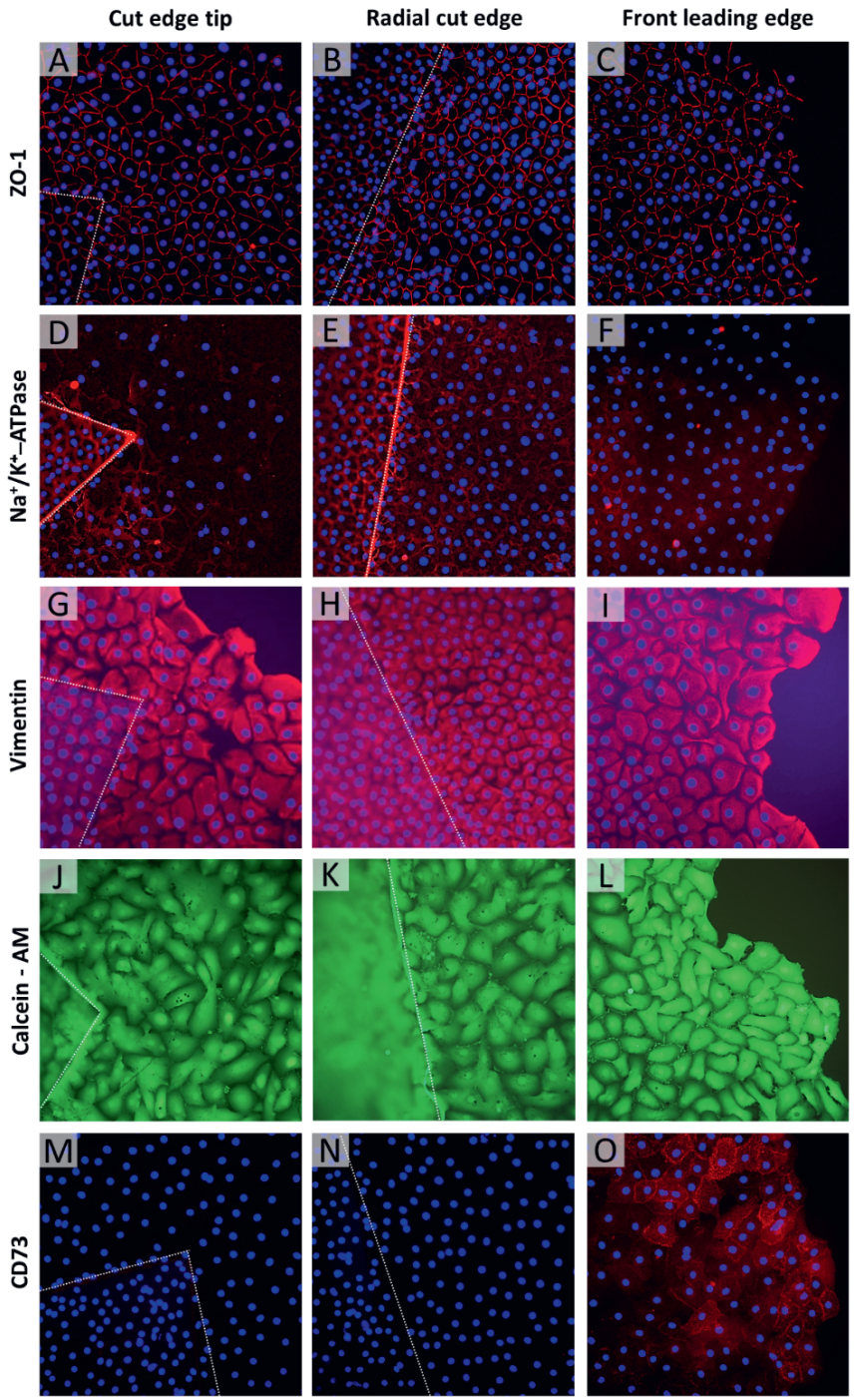

Figure 3| Immunofluorescence staining of the newly formed cell monolayer. Expression of ZO-1 (A-C), Na^+/K^+ –ATPase (D-F) vimentin (G-I), Calcein-AM (J-L) and CD73 (M-O) was analyzed around the cut edge tip (Left), along the radial cut edge (Middle) of the Quarter-DMEK graft, and at the monolayer's front leading edge contour (Right) after 17(±3) days in gel

culture and subsequent gel removal. Characteristic expressions for the tight junction protein ZO-1 (A, B red) and functional protein Na^+/K –ATPase (D, E red) were uniformly observed along lateral cell borders across the monolayer (A, B red); however, cells at the front leading edge of the monolayer showed a discontinuous distribution of ZO-1 (C, red) and Na^+/K^+ –ATPase (F, red). Strong expression of vimentin intermediate filaments was detected throughout the monolayer (G, H, I red) and in cells at the font leading edge more specifically, which demonstrate increased motility (I red). Cell viability evaluated by expression of Calcein-AM showed strong fluorescence intensity in the confluence monolayer of cultured cells (J, K, L green). CD73 expression marker was uniquely associated with cells near the leading edge (O red) indicating involvement in the process of cell migration; a lack of CD73 expression in the confluent monolayer indicates poor ability for cell migration and growth at the rear of the leading edge (M, N red). Due to the difference in focal plane between the migrated cells and the cells on the graft itself (height difference due to Descemet membrane), the latter appear out of focus and hazy. In each of the photos, the dashed line outlines the edge of the Quarter-DMEK graft, 200x magnification.

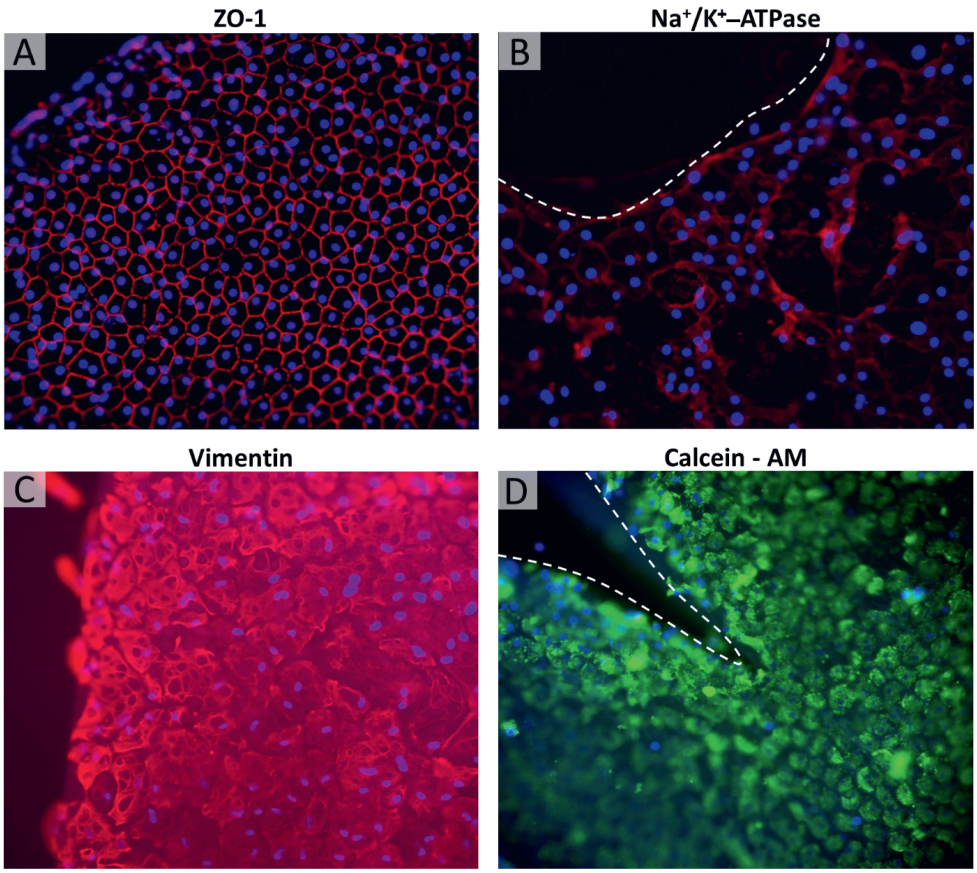

Figure 4| Immunofluorescence staining of the Quarter-DMEK graft with focus on far periphery. Expressions for the tight junction protein ZO-1 (A: control graft, red), functional protein Na^+/K^+ –ATPase (B: graft with trephined periphery, red), and structural protein vimentin (C: control graft, red) counterstained with DAPI (blue) showed sparsely distributed cells with irregular morphology and altered pump function activities in the far periphery. The round limbal edge the Quarter-DMEK graft was populated by viable cells as indicated by Calcein-AM expressions (D: graft with radially cut through periphery, green). Grafts were imaged after 17(±3) days in gel culture and subsequent gel removal 200x magnification.

Immunohistochemistry

Immunohistochemistry analysis confirmed the formation of a continuous functional monolayer created by direct cell migration into the free space available, apart from at the round edge of the graft (**Figures 3 and 4**). Typical expression profile was found for endothelial marker ZO-1 and Na^+/K^+ –ATPase (**Figure 3A,B,D** and **E** red) in EC that depart from the radial graft cut edge up to the rear of the leading edge. Resistance barrier and the pump function protein showed a discontinuous expression over the front leading cell edge, the (**Figure 3C** and **F,** red) which is concomitant with strong polymerization of vimentin intermediate filaments (**Figure 3G**,**H** and **I**, red) and the expression of regulatory molecule CD73 which is involved in cell migration (**Figure 3M**,**N** and **O**, red). Cell viability, evaluated by expression of Calcein-AM, showed strong fluorescence intensity in the confluence monolayer of cultured cells (**Figure 3J**,**K** and **L,** green). Although migration was not observed over the round, limbal edge of the Quarter-DMEK graft, the Calcein-AM expression (**Figure 4D**, green) confirmed the presence of viable endothelial cells. Expressions for the tight junction protein ZO-1 (**Figure 4A**, red), functional protein Na^+/K^+ –ATPase (**Figure 4B**, red), and structural protein vimentin (**Figure 4C**, red) showed sparsely distributed cells with irregular morphology and altered pump function activities.

Discussion

We know, both from clinical experience[1–3] and from our previous *in vitro* work,[4] that EC from the cut edges of a quarter DMEK graft have the capacity to migrate and spread throughout regions of bare stroma in recipient eyes. However, poor corneal clearance along the round graft edge[2] suggested that EC migration was almost absent in the far periphery, which was also confirmed *in vitro*.[4] Previously, He et al. suggested that the furrow-like distribution of the underlying collagen fibers in the corneal far periphery directs the migration of EC towards the center of the cornea throughout a person's life, thereby limiting migration in the other direction.[6] We suspected that the lack of migration from the periphery was, therefore, due to this obstructive barrier, or "fence" and that, by breaking through it, cells with migratory potential could be unlocked.

Our results showed that EC migrated collectively from all Quarter-DMEK grafts' radial cut edges. As they migrated through the gel matrix, the cells first displayed "mesenchymal collective migration" where individual satellite cells separate out from the group, elongate, and independently stretch and branch into the free space. After a few days, this pattern changed to one of "direct protrusion formation", that is that an area in which a sheet of cells coalesces behind the leading edge, and march together.[7] The leading edge protrusions were dynamic vimentin-containing structures with plasma membrane blebs polarized in the direction of the open space and regulated by activation of CD73.[8,9] Interestingly, at the leading edge of migrating cells, Na^+/K^+ –ATPase pumps and ZO-1 expression were more irregular, suggesting that these leader ECs were reducing their pump function specialization in favour of migration, while the followers retain more of their EC properties.[10,11] Thus, the rear end of EC maintained cell-cell adhesions and displayed homogenous endothelial cell expression for structural (ZO-1) and functional (Na^+/K^+–ATPase) markers.

Attempts to break the barrier by trephination or radial cuts, however, did not result in cell migration from the limbal round edge of a Quarter-DMEK graft within the study period of 2.5 weeks regardless the peripheral edge modifications. This suggests that the lack of migration from the periphery is due to a process that is more complex than a simple collagen barrier. It was also not due to the absence of viable of cells, since immunolocalization showed cells with expression of the structural (ZO-1 and vimentin) and functional markers (Na^+/K^+ –ATPase). The morphology was also different in this area with fewer cells displaying the typical endothelial hexagonal shape. This suggests that the cell-cell and cell-extracellular matrix (ECM) interactions are different to the central cornea and may prohibit migration. A stimulus greater than eliminating contact inhibition seems to be required in order to prompt these cells to move. It is possible that either the integrin-dependent adhesion between cells and underlining ECM is less expressed, thereby affecting cell tension and

morphology, or that the level of GTPases, responsible for cell contractility and protrusion mediation at the leading edge, is reduced.[12]

Clinically, the failure of far peripheral EC to migrate, in spite of modification, remains a limitation of the current quarter DMEK approach. However, cells located beneath the Schwalbe's line have been found to have progenitor cell-like properties[13] and might play a critical role in the stabilization of the endothelial cell density after transplantation. Thus, understanding the nature of these peripheral endothelial cells, how they differ from the central cells, and how to encourage them to migrate would greatly improve the pool of donor tissue available for patients in need.

Supporting information

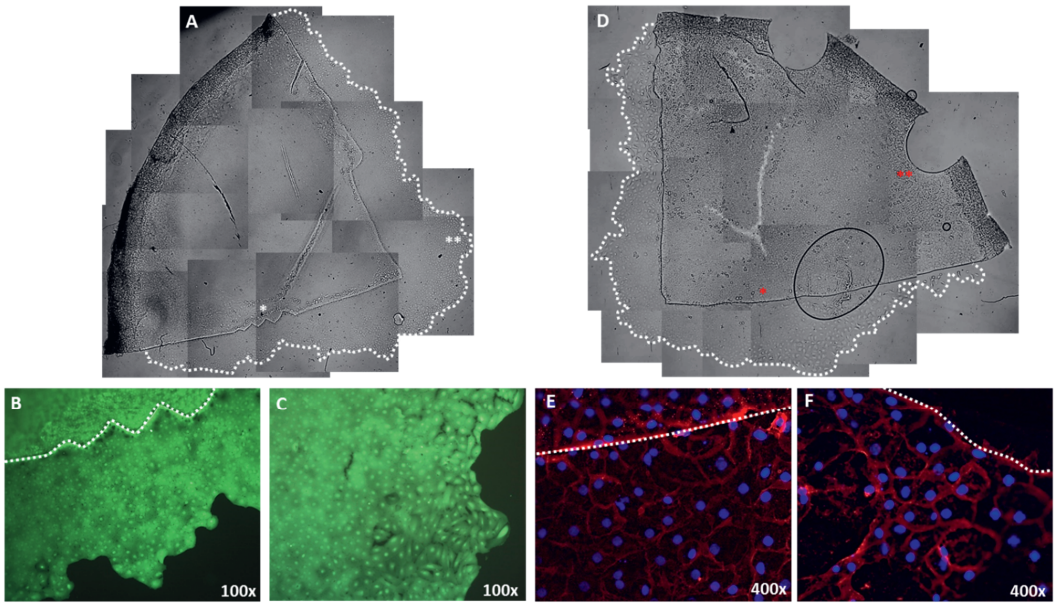

Supplementary Figure 1| Additional light microscopy and immunohistochemistry images of flattened grafts with and without modification of the limbal graft edge. Collage of light microscopy images (x25 magnification) to create an overview of (A) a Quarter-DMEK graft with intact far periphery and (D) a Quarter-DMEK graft with modification of the limbal graft edge; both after 2 weeks of *in vitro* gel culture. Both grafts show extensive cell migration along the radial cut graft edges as outlined by the dotted white line, but not along the limbal graft edge. (B, C) Cell viability evaluated by expression of Calcein-AM showed strong fluorescence intensity in the confluent monolayer of cultured cells at different positions of the migrated cell layer; Images shown in (B) and (C) correspond to the areas marked with one and two white asterisks in image (A), respectively. (E, F) Characteristic expression for the functional protein marker Na^+/K^+ –ATPase observed across the monolayer. Images shown in (E) and (F) correspond to the areas marked with one and two red asterisks in image (D), respectively. (F) Cells close to the modified limbal edge showed discontinuous expression of Na^+/K^+ –ATPase corroborating the finding that endothelial cells along the limbal edge differ morphologically from endothelial cells in the corneal center.

References

1. Baydoun L, Zygoura V, Hsien S, Birbal RS, Spinozzi D, Lie JT, et al. Clinical feasibility of using multiple grafts from a single donor for Quarter-DMEK. Acta Ophthalmol. 2018 Aug; 96(5):e656–658. https://doi.org/10.1111/aos.13720 PMID: 29498213
2. Zygoura V, Baydoun L, Ham L, Bourgonje VJA, van Dijk K, Lie JT, et al. Quarter-Descemet membrane endothelial keratoplasty (Quarter-DMEK) for Fuchs endothelial corneal dystrophy: 6 months clinical outcome. Br J Ophthalmol. 2018 Oct; 102(10):1425–1430. https://doi.org/10.1136/bjophthalmol-2017-311398 PMID: 29343529
3. Muller TM, Lavy I, Baydoun L, Lie JT, Dapena I, Melles GR. Case report of Quarter-Descemet membrane endothelial keratoplasty for Fuchs endothelial dystrophy. Cornea. 2017 Jan; 36(1):104–107. https://doi.org/10.1097/ICO.0000000000001008 PMID: 27583798
4. Miron A, Spinozzi D, Bruinsma M, Lie JT, Birbal RS, Baydoun L, et al. Asymmetrical endothelial cell migration from *in vitro* Quarter-Descemet membrane endothelial keratoplasty grafts. Acta Ophthalmol. 2018 Dec; 96(8):828–833. https://doi.org/10.1111/aos.13841 PMID: 30171674
5. Lie JT, Lam FC, Groeneveld-van Beek EA, van der Wees J, Melles GR. Graft preparation for hemi-Descemet membrane endothelial keratoplasty (hemi-DMEK). Br J Ophthalmol. 2016 Mar; 100(3):420–424. https://doi.org/10.1136/bjophthalmol-2015-307335 PMID: 26508780
6. He Z, Campolmi N, Gain P, Ha Thi BM, Dumollard JM, Duband S, et al. Revisited microanatomy of the corneal endothelial periphery: new evidence for continuous centripetal migration of endothelial cells in humans. Stem Cells. 2012 Nov; 30911):2523–2534. https://doi.org/10.1002/stem.1212 PMID: 22949402
7. Scarpa E, Mayor R. Collective cell migration in development. J Cell Biol. 2016 Jan; 212(2):143–155. https://doi.org/10.1083/jcb.201508047 PMID: 26783298
8. Curchoe CL, Maurer J, McKeown SJ, Cattarossi G, Cimadamore F, Nilbratt M, et al. Early acquisition of neural crest competence during hESCs neuralization. PLoS One. 2010 Nov; 5(11):e13890. https://doi.org/10.1371/journal.pone.0013890 PMID: 21085480
9. Adzic M, Nedeljkovic N. Unveiling the role of Ecto-5'-Nucleotidase/CD73 in astrocyte migration by using pharmacological tools. Front Pharmacol. 2018 Mar; 9:153. https://doi.org/10.3389/fphar.2018.00153 PMID: 29545748
10. Du D, Xu F, Yu L, Zhang C, Lu X, Yuan H, et al. The tight junction protein, occludin, regulates the directional migration of epithelial cells. Dev Cell. 2010 Jan; 18(1):52–63. https://doi.org/10.1016/j.devcel.2009.12.008 PMID: 20152177
11. Schwab A, Fabian A, Hanley PJ, Stock C. Role of ion channels and transporters in cell migration. Physiol Rev. 2012 Oct; 92(4):1865–1913. https://doi.org/10.1152/physrev.00018.2011 PMID: 23073633
12. Trepat X, Chen Z, Jacobson K. Cell migration. Compr Physiol. 2012 Oct; 2(4):2369–2392. https://doi.org/10.1002/cphy.c110012 PMID: 23720251
13. Liu Y, Sun H, Guo P, Hu M, Zhang Y, Tighe S, et al. Characterization and prospective of human corneal endothelial progenitors. Int J Med Sci. 2017 Jun; 14(8):705–710. https://doi.org/10.7150/ijms.19018 PMID:28824304

CHAPTER 8

Early and late-onset cell migration from peripheral corneal endothelium

Article submitted to PLoS One

Alina Miron, Sorcha Ní Dhubhghaill, Viridiana Kocaba, M.J. Jager, Gerrit Melles, Silke Oellerich

ABSTRACT

Aim: To study peripheral corneal endothelial cell migration *in vitro* in the absence and presence of a ROCK-inhibitor.

Materials and Methods: Twenty-one corneal endothelial graft rims, with attached trabecular meshwork (TM), were prepared from Descemet membrane-endothelial cell (DM-EC) sheets by 6.5 mm trepanation. For the initial proof-of-concept, 7 outer graft rims were cultured in a 3D thermo-reversible hydrogel matrix for up to 45 days. To assess the effect of a ROCK-inhibitor, 14 paired outer rims were cultured either with or without ROCK-inhibitor. At the end of culture, tissue was retrieved from the hydrogel matrix and examined for cell viability and expression markers (ZO-1, Na^+/K^+ –ATPase, NCAM, glypican-4, and vimentin).

Results: All cultured rims remained viable and displayed either single regions (n=5/21) or collective areas (n=16/21) of cell migration, regardless of the presence or absence of ROCK-inhibition. Migration started, after 4±2 days and continued for at least 29 days. Migrated cells showed a more regular cell morphology when cultured in the presence of a ROCK-inhibitor. In addition, 7 outer rims demonstrated a phenotypically distinct late-onset, but fast-growing cell population emerging from the area close to the limbus. These cells emerged after 3 weeks of culture and appeared less differentiated compared to the other areas of migration. Immunostaining showed that migrated EC maintained the expression patterns of endothelial cell markers.

Conclusion: Using a 3D-culture system, we observed migration of two morphologically distinct cell populations. The first type was triggered by a broken physical barrier, consistent with disruption of contact inhibition. The second, late-onset type showed a higher proliferative capacity though appearing less differentiated. This cell subpopulation appeared to be mediated by stimuli other than the loss of contact inhibition and the presence of ROCK-inhibitor. Further exploration of the differences between these cell types may assist in optimizing regenerative treatment options for endothelial diseases.

INTRODUCTION

The treatment of corneal endothelial failure and dysfunction is transitioning from corneal transplantation towards regenerative therapy.[1–3] Since central corneal endothelial cells are considered terminally differentiated and non-replicative *in vivo*,[4] new therapies that rely on the presence of healthy peripheral endothelial cells, such as Descemet stripping only (DSO), require endothelial migration from the periphery to cover the central area and endothelial cell mitosis through the administration of mitogens.[5–9] During this wound healing process, endothelial cells deposit fibronectin and laminin on the Descemet membrane which supports the required signaling for directed cell migration. Cells undergo cytoskeletal changes during the migration process reflected by cellular enlargement and polymorphism. Since the endothelial cells usually do not replicate *in vivo*, cellular enlargement is needed to cover the wounded areas. It has been suggested, however, that cells from the peripheral corneal endothelium may have proliferative capacity and act as a cell resource for the recovery of corneal endothelium in endothelial injury.[10] When immunostained, peripheral endothelial cells exhibit less differentiation markers than central endothelial cells but express stem cell markers and, sometimes, proliferation markers.[11] Furthermore, these cells were found between the corneal endothelium and the trabecular meshwork (TM) and showed a bipolar, spindle-shaped morphology similar to that of neural crest cells.[12] Recently, progenitor-like cells were discovered to reside within a thin strip of tissue, the transition zone (TZ), initially believed to be a zone depleted of cells.[13,14] These stem cells sequestered in specific niches inside the TZ may respond to corneal wounding to initiate endothelial repair and also contribute to a normal, slow replacement of corneal endothelial cells.

Endothelial cell proliferation and endothelial cell migration can be supported by topical administration of a ROCK-inhibitor, which resulted in improved clinical outcomes after DSO.[15–20]

The purpose of this study is to evaluate *in vitro* peripheral endothelial cell migration from outer corneal graft rims using a thermo-reversible temperature-responsive polymer culture technique both in the absence and presence of a ROCK-inhibitor to gain a better understanding of the process *in vivo*.

MATERIALS AND METHODS

Corneas

Twenty-one human postmortem corneas, which were ineligible for transplantation, but had an intact and viable endothelial cell layer with an average endothelial cell density of 2371 (±313) cells/mm^2 (from twelve donors (mean age 76 (±5) years; range 68–84 years)) (**Table 1**), were obtained from Amnitrans EyeBank Rotterdam. All donors had previously stated that they had no objection to transplant-related research and the study adhered to the tenets of the Declaration of Helsinki. No specific institutional review board approval was required as under national regulation no approval is required for this research if donors had consented to having the samples used for research purposes (https://www.ccmo.nl/onderzoekers/aanvullendeeisen-voor-bepaalde-soorten-onderzoek/niet-wmo-onder zoek/onderzoek-met-lichaamsmateriaal).

Table 1. Demographics of donor corneas.

# Cornea (Donor)	Donor age (years)	Gender	Cause of death	Diabetic status	Sepsis status	Preserv. time before DM-EC sheet prep. (T_1) (days)	Preserv. time between T_1 and tissue embedding (days)	ECD (cells/mm^2) at cornea preserv.	Rejection reason	DM-EC sheet Cell migration		
										4 mm circular graft	Outer rim graft	
Proof-of-concept cell migration study												
1 (1 R)	81	M	Circulatory syst.	No	No	14	6	2200	PEQ	CM	SCM	
2 (2 L)	80	M	Circulatory syst.	Yes	No	12	2	2700	Other	CM	SCM	
3 (3 R)	74	M	Circulatory syst.	No	No	16	7	2500	PEQ	n.v.	CM	
4 (4 R)	81	F	Circulatory syst.	No	No	1	2	2500	Virology	n.v.	CM	
5 (4 L)	81	F	Circulatory syst.	No	No	1	2	2500	Virology	CM	CM	
6 (5R)	71	M	Circulatory syst.	No	Yes	12	2	2600	Screening tests	n.v.	CM	
7 (5L)	71	M	Circulatory syst.	No	Yes	12	2	2600	Screening tests	CM	CM	
Mean (±SD)	**77 (±5)**					**11 (±6)**	**4 (±2)**	**2514 (±157)**				
Paired outer graft rims cell migration study												
										ROCK inhibitor	**Cell migration**	**Late-onset cells**
8 (6 R)	84	M	Respiratory sys.	No	Yes	21	2	2300	Other	No	SCM	No
9 (6 L)	84	M	Respiratory sys.	No	Yes	21	2	2300	Other	Yes	CM	No
10 (7 R)	80	M	Respiratory sys.	Yes	No	22	2	2400	PEQ	Yes	CM	Yes
11 (7 L)	80	M	Respiratory sys.	Yes	No	22	2	2400	PEQ	No	CM	No
12 (8 R)	77	M	Other	Yes	Yes	24	2	2200	Virology	No	CM	Yes
13 (8 L)	77	M	Other	Yes	Yes	24	2	2100	Virology	Yes	SCM	No
14 (9 R)	78	M	Malign.	No	No	4	4	1800	PEQ	No	CM	Yes
15 (9 L)	78	M	Malign	No	No	4	4	1800	PEQ	Yes	CM	Yes
16 (10 R)	68	M	Circulatory syst.	Yes	No	10	3	3000	Virology	Yes	CM	No
17 (10 L)	68	M	Circulatory syst.	Yes	No	10	3	2900	Virology	No	CM	No
18 (11 R)	68	M	Digestive syst.	No	No	15	2	2400	Virology	Yes	CM	Yes
19 (11 L)	68	M	Digestive syst.	No	No	15	2	2400	Virology	No	CM	No
20 (12 R)	75	M	Malign.	No	No	24	2	2300	PEQ	No	CM	Yes
21 (12 L)	75	M	Malign	No	No	24	2	1900	PEQ	Yes	CM	Yes
Mean (±SD)	**76 (±6)**					**17 (±8)**	**2 (±1)**	**2320 (±347)**				
Mean all grafts (±SD)	**76 (±5)**					**13 (±7)**	**3(±2)**	**2371 (±313)**				

CM: collective migration; DM: Descemet membrane; EC: endothelial cells; ECD: endothelial cell density; F: female; L: left donor cornea; M: male; Malign.: malignant; n.v.: not viable; PEQ: Poor Endothelium Quality; Prep.: preparation; Preserv.: preservation; R: right donor cornea; SCM: single cell migration; Screening test: inconclusive blood test; SD: standard deviation; syst.: system; Virology: Hepatitis B positive.

Table 2. Composition of the culture media used in this study.

Culture medium	Growth factors and supplements
Growth factor-depleted DMEM-based medium (M1)	DMEM
	15% fetal bovine serum (FBS)
	2 mM L-Glutamine (L-Glu)
DMEM based culture medium (M2):	15% fetal bovine serum (FBS)
	2 mM L-Glutamine (L-Glu)
	2 ng/ml basic fibroblast growth factor (bFGF)
	0.3 mM L-Ascorbic acid 2-phosphate (Asc-2P)
	10,000 U-ml Penicillin-Streptomycin (Pen/Strep)
ROCK-inhibitor enriched medium (M3):	M2 + 10 µM ROCK-inhibitor

FBS and bFGF were purchase from ThermoFisher Scientific Europe BV, The Netherlands; DMEM, ROCK-inhibitor, L-Glu and Asc-2P were obtained from Sigma-Aldrich Chemie NV, The Netherlands; Pen/Strep was bought from Carl Roth GmbH, Karlsruhe, Germany

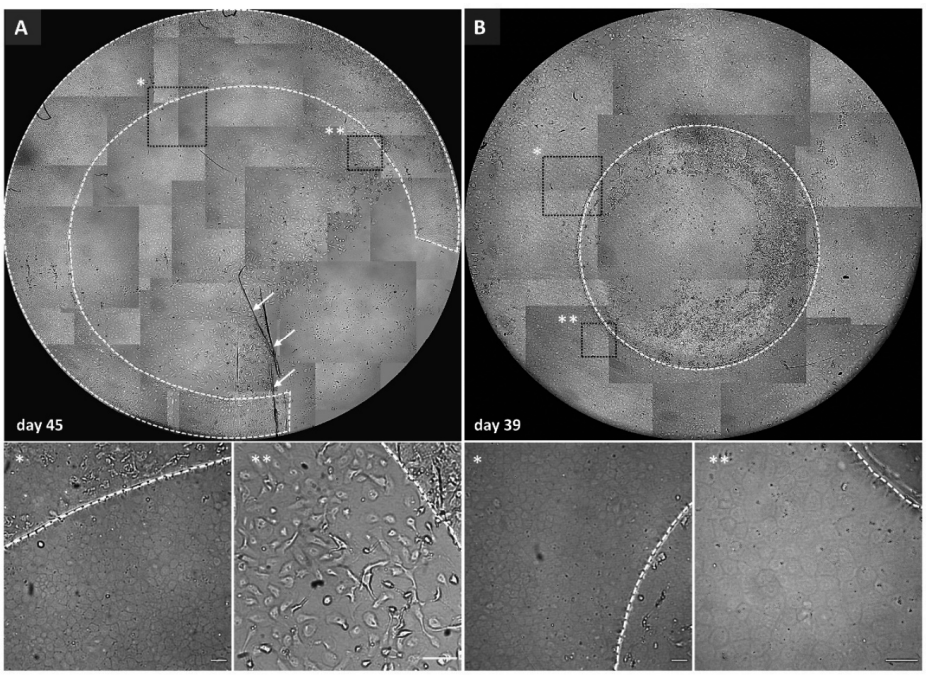

Figure 1| Outer rim and a central graft representation of the proof-of-concept migration study. Collage of light microscopy images (x50) to create an overview of the (A) outer rim cell migration after 45 days in gel culture for which the ring opening was performed in the well using a surgical blade (note the imprints highlighted by the white arrows); the squared areas marked in the overview image display the formations of a cell monolayer free from the DM substrate as a results of collective cellular migration (*) and migration of individual cells (**) (B) 4 mm control graft after 39 days in gel culture showing uniform cell migration from all around the round edges; two higher magnification images marked by * and ** in the graft overview show the cell monolayer formed by the collective spreading of cell cohorts. The dotted line outlines the outer rim (A), control graft (B), and cell monolayer migration edge in the higher magnified images. Scale bar: 100 µm.

Outer graft rim preparation

Corneoscleral buttons were excised from whole donor globes obtained less than 24 hours postmortem and stored in organ culture medium at 31°C (CorneaMax, Eurobio, Courtaboeuf, France) until graft preparation. The Descemet membrane-endothelial cell (DM-EC) sheets were separated from the stroma by using the standardized "no-touch" peeling technique, as described previously.[21,22] After placing the isolated DM-EC sheets with the trabecular meshwork (TM) still attached on a soft contact lens, the DM-EC sheets were centrally trephined with a 4 mm biopsy punch followed by a second concentric 6.5 mm trepanation to obtain the outer rims. Attachment of the TM prevented the outer rims from scrolling and facilitated further handling. Outer graft rims and 4 mm circular DM-EC sheets were stored separately in growth factor-depleted DMEM-based medium (**Table 2**, M1) for 2 to 7 days before culture in the thermo-reversible hydrogel matrix (Mebiol Gel, Cosmo Bio, USA).

A thermo-reversible cell culture system not only allows for studying endothelial cell migration but also facilitates tissue retrieval, without enzymatic treatment, by cooling the gel below the sol-gel transition temperature.[23] The preparation of the thermo-reversible hydrogel matrix and embedding protocol have been described in detail in previous publications from our group.[23,24] When embedding the tissue in the hydrogel matrix, the 4 mm circular DM-EC sheets were placed, endothelial-side-up, on glass coverslips and transferred to a 48-well plate.[25] The outer graft rims were transferred to a 24-well plate containing 100 µl Dulbecco's phosphate-buffered saline (PBS, Sigma-Aldrich Chemie NV, The Netherlands) and positioned endothelial-side-up by grasping the TM with a forceps. The surface was then carefully dried out with cellulose vitreous sponges and the graft rim was carefully cut radially with a surgical blade (Swann-Morton, Sheffield, England) to ensure that the graft rims were mounted completely flat on the surface. Hypotonic trypan blue solution 0.04% (Hippocratech, Rotterdam, The Netherlands) was used to ensure the visibility of both the rims and circular grafts during preparation and unfolding on the solid support. For the initial proof-of-concept experiments, 7 outer graft rims and the corresponding 4 mm circular grafts were embedded separately inside the thermo-reversible polymer solution and evaluated for chemotactic cell ability (**Figure 1**). The circular grafts acted as the control for cell migration.[23] Following the proof-of-concept, 7 paired outer rims were cultured in the presence or absence of ROCK-inhibitor to assess the effect of ROCK-inhibitor (Y-27632, Sigma-Aldrich Chemie NV, The Netherlands) on the *in vitro* cell migration. The tissue was cultured up to 47 days in a humidified atmosphere at 37°C with 5% CO_2. Medium (**Table 2,** M2, M3) was refreshed every 2-3 days. Cell morphology and cell migration were examined with an AxioVert.A1 microscope AxioVert.A1 microscope with AxioCam 305 color camera (Zeiss, Oberkochen, Germany). The recovery of the tissue from the hydrogel matrix at the end of the culture period was performed by gradually cooling the gel below the sol-gel transition temperature (<20°C) using low-temperature PBS in the manner previously described.[23]

Immunohistochemistry and cell viability analysis

After the removal of the hydrogel, routine markers such as tight junction protein zonula occludens-1 (ZO-1), vimentin, neural cell adhesion molecule (NCAM), glypican-4 (GPC-4), and sodium-potassium pump (Na^+/K^+ –ATPase) were examined for cell characterization. Primary antibodies against vimentin and GPC-4 were obtained from Abcam (Cambridge, United Kingdom) and for Na^+/K^+ –ATPase from Sigma-Aldrich Chemie NV (Zwijndrecht, The Netherlands). ZO-1 primary antibody and secondary antibodies were purchased from ThermoFisher Scientific Europe BV (Bleiswijk, The Netherlands). In addition, Calcein-AM (Sigma-Aldrich Chemie NV, The Netherlands) staining was performed to verify cell viability after hydrogel removal. Nuclear cell staining was performed with DNA-specific blue-fluorescent dyes DAPI (Sigma-Aldrich Chemie NV, The Netherlands) and Hoechst (ThermoFisher Scientific Europe BV, The Netherlands). Details of the staining protocols has been described previously.[25]

RESULTS

Cell migration

Proof-of-concept extended culture study

Hydrogel embedding was successful for all 7 outer graft rims and allowed for observation of *in vitro* cell migration from day 2 up to day 47 during which cells migrated either only individually (2/7) or collectively (5/7) (**Figure 1**). For the two graft rings that showed only migration of individual cells, the corresponding 4 mm circular grafts showed collective cell migration (**Supplementary Figure 1A**). Graft ring viability determined by Calcein-AM staining at the end of the culture period showed an overall compromised endothelial cell monolayer integrity with areas almost depleted of cells (**Supplementary Figure 1B**).

ROCK-inhibitor effect on *in vitro* cell migration

Of seven outer graft rim pairs used to test the effect of the ROCK-inhibitor, 5 pairs formed a continuous functional monolayer, as shown by the Calcein-AM and Hoechst staining (**Figure 2**). Mixed cell migration behaviour was observed for the other two pairs. While one graft rim showed collective migration, the contralateral graft rim only displayed single cell migration. For one outer graft rim pair with collective migration initially, cells displayed a coordinated movement that turned into individual cell migration after approximately 17 days of culture. Moreover, cell migration was initiated from edges displaying low viability, whereas it was absent from edges displaying well detected Calcein-AM signal (**Supplement Figure 2A**). A similar migration pattern initiated from mechanically damaged areas was also observed for one outer graft rim cultured in the absence of ROCK-inhibitor (**Supplement Figure 2B**) whereas the contralateral graft rim showed a more uniform distributed migration along the open edges.

Overall, for pairs with collective migration in both graft rims, there was no remarkable difference in terms of the moment when the cell migration started (4±2 days), or the duration, to maintain the direction of motion (44±2 days). The presence of ROCK-inhibitor in the culture medium contributed to a more regular cell morphology of the migrating cells and a migrating cell monolayer without significant formation of any gaps between cells (**Figure 2A, ME** vs. **2B, ME**).

Another finding, however, was that seven outer graft rims displayed a phenotypically distinct late-onset (but fast-growing) cell population emerging from the far periphery of the endothelium (**Figure 3**). The late onset migration was seen with both graft rings of 2 pairs, as well as with 3 unpaired graft rings (2 grafts in the presence and 1 in the absence of ROCK-inhibitor), while 2 other pairs did not show the late-onset cells at all. These late-onset cells started to migrate after 3–5 weeks of culture. Presence of ROCK-inhibitor in the growth medium did neither result in a higher percentage of graft rims displaying the late-onset cell population nor did it decrease the time-point when the migration capacity was unlocked (29±8 days with ROCK-inhibitor (n=4) vs. 27±3 days without ROCK-inhibitor (n=3)). The cells emerged from the intermingled fibrillary area and acquired a more endothelial-like morphology when cultured in the absence of ROCK-inhibitor (**Figure 3D–F**, **Figure 4A**). These cells became contact inhibited and formed a monolayer of hexagonal cells within 10±4 days (in 4 of 7 cases) and 7±4 days (in 3 of 7 cases) of gel culture in the presence or absence of ROCK-inhibitor, respectively (**Figure 3C, F** and **Figure 4B**).

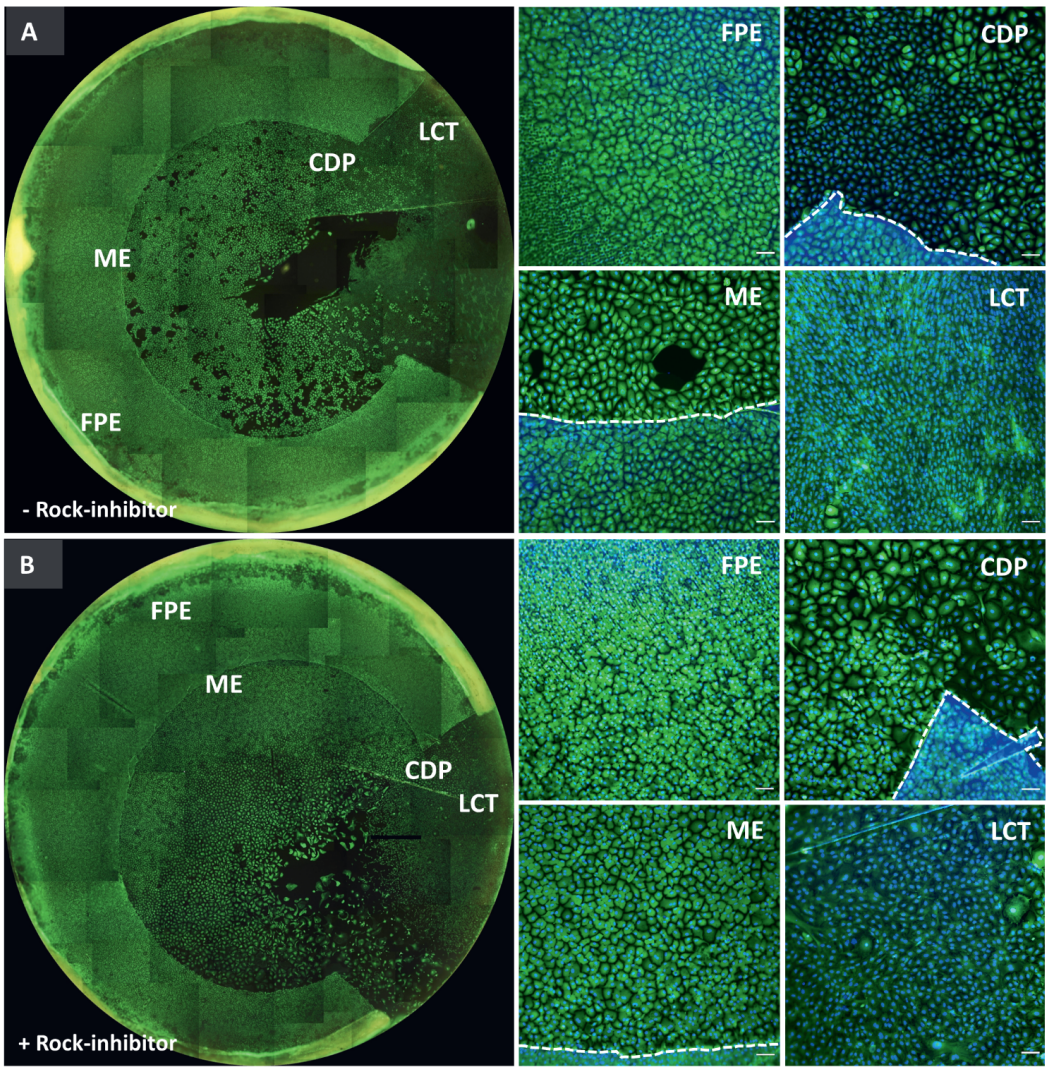

Figure 2| Calcein-AM and Hoechst staining of representative images of paired outer graft rims cultured in the (A) absence or (B) presence of ROCK-inhibitor. Displayed per culture condition are fluorescence overlay images of Calcein-AM and Hoechst channels representative of far periphery endothelium (FPE), cell monolayer migration edge (ME), cells of different phenotype (CDP) growing around the outer rim opening, and late-onset cell type (LCT) with high proliferative capacity. The dashed lines outline the cell monolayer migration edges. Scale bar: 100 µm.

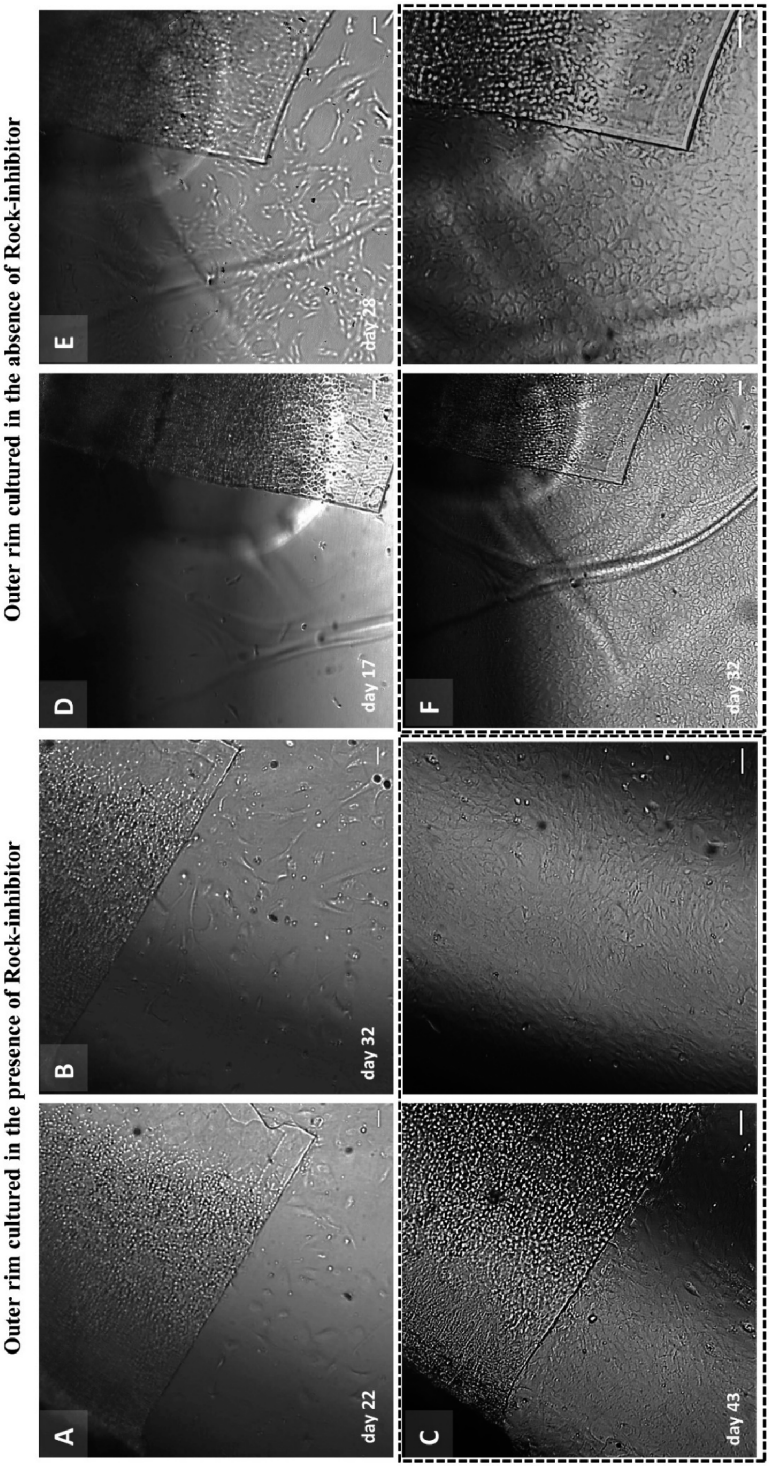

Figure 3 | Representative images of two unpaired outer rims that displayed the late-onset cell type with high proliferative capacity. (A–C) Outer rim cultured in the presence of ROCK-inhibitor and the fast-growing cell type initiated after 32 days of culture but evident only at day 43. (D–F) Outer rim cultured without ROCK-inhibitor and the fast-growing cell type already visible after 28 days of gel culture. Scale bar: 100 µm.



Figure 4| Example images of an outer rim displaying the late-onset cell population without actively targeting the Rho-kinase pathway. (A) cell outgrowth in the far periphery of the endothelium visible after 28 days of gel culture. Note, (i) the different gel embedding plane of the TM that was not physically connected to the endothelium and (ii) the absence of cell migration from the radial cut edge of the outer rim. (B) After 35 days of gel culture, a new cell monolayer of optimal morphology formed around the rim's cut edge. Scale bar: 100 µm.

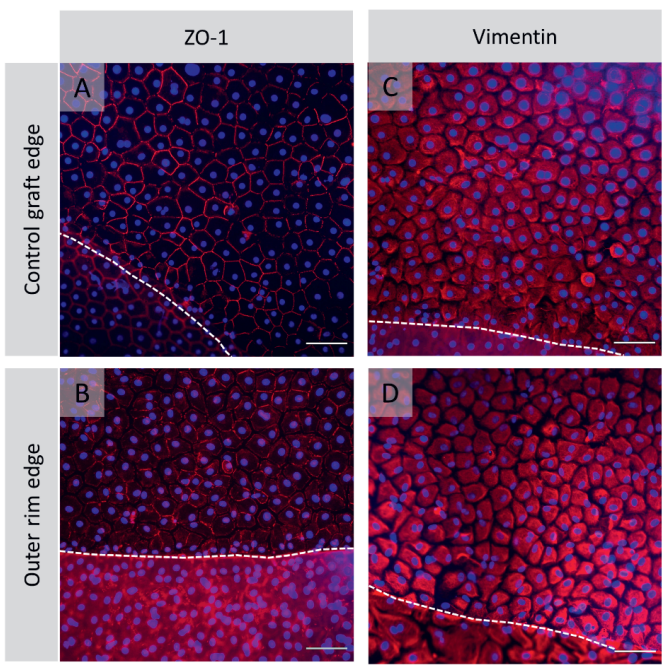

Figure 5| Representative images of structural proteins detected in the cell monolayer with focus on migration edge. Fluorescence microscopy images showing expression of ZO-1 (A, B: red signal) and Vimentin (C, D: red signal)

counterstained with DAPI (blue signal) in the confluent layer of migrating cells: control tissue (4 mm circular graft) (A and C) vs. outer graft rim (B and D). Scale bar: 100 µm.

Immunohistochemistry

After gel removal, immunohistochemistry analysis showed the typical expression profiles for the endothelial cell markers ZO-1 (**Figure 5A, B**) and Vimentin (**Figure 5C, D**) in the migrated cell monolayer. A weak signal was recorded for the functional marker Na^+/K^+ – ATPase, adhesion marker NCAM, and cell surface marker GPC-4 in the cell monolayer formed from the outer graft rim's edge and tissue itself regardless of the culture medium composition (**Table 2,** M2, M3), while the 4 mm circular grafts revealed the formation of a continuous functional monolayer with tightly interconnected cells (**Figure 6**). No visual differences in the immunofluorescent expression patterns were detected between cultured monolayers formed by cell outgrowth from the 4 mm circular grafts with or without ROCK inhibition. Interestingly, cell viability evaluation of the seven outer graft rims with the late-onset cell population showed a heterogenous Calcein-AM signal intensity wherein the lowest signal detection corresponded to the cell population emerged from the far periphery of the endothelium.

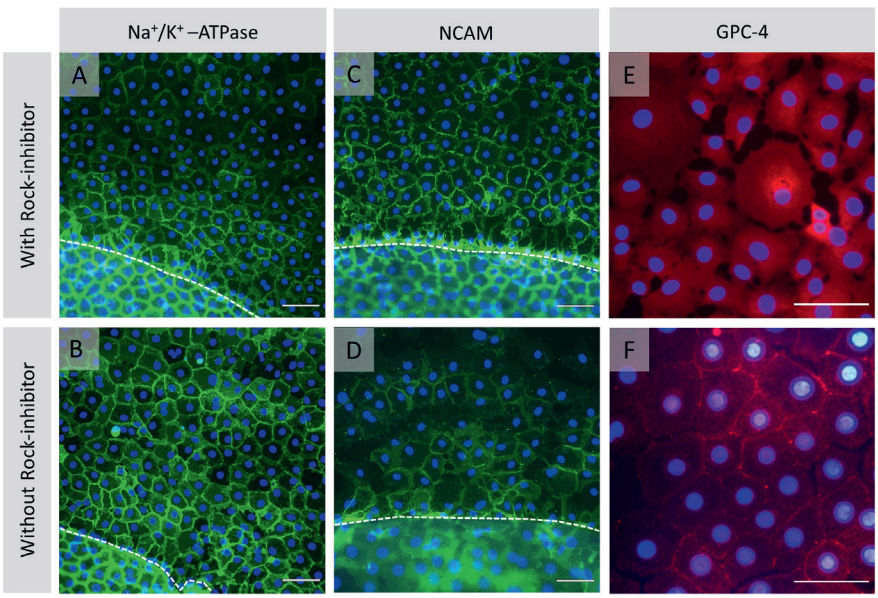

Figure 6| Immunofluorescence staining of the migrated monolayer from unpaired control grafts. Grafts were cultured with (top line: A, C, E) or without (bottom line: B, D, F) ROCK-inhibitor. Considerable expression of the functional cell marker Na^+/K^+ –ATPase (A, B: green signal), neural cell adhesion molecule NCAM (C, D: green signal), and cell surface proteoglycan GPC-4 (E, F: green signal) was detected in all cultured monolayers irrespective of the culture media composition. Nuclei were stained blue by DAPI. Scale bar: 100 µm

DISCUSSION

Corneal endothelial explant culture is technically challenging due to the inherent scrolling properties of the tissue, however, using a thermo-reversible hydrogel it is possible to selectively study *in vitro* EC migration from the outer regions of the monolayer with a central opening. Using this approach, we showed that EC migrate

collectively in the majority of outer graft rims with an intact endothelial monolayer. We observed early- and late-onset migration of two morphologically distinct corneal endothelial cell populations. The late-onset type showed a higher proliferative capacity though it appeared to be less differentiated. This cell subpopulation appeared to be mediated by stimuli other than the loss of contact inhibition and ROCK-inhibitor.

When both early- and late- onset migration ceased – on average, 6 weeks vs. 1 week with a lag time of 3–5 weeks, respectively, the cell monolayer became contact inhibited and immunohistochemistry demonstrated the presence of viable cells with tightly packed morphologies. In some other areas, we also noted single cell migration with individual satellite cells branching into the free space, though these were most often seen from areas with mechanical damage. We suspect that the lack of collective migration from the neighboring undamaged endothelial areas may be partly due to inconsistency in flattening the tissue fixed on the support, trapping some regions in the gel during the solidified matrix formation.

Cultures of seven outer rims showed migration of a morphologically distinct, late-onset cell type which appears after 3–5 weeks in culture. These cells arose from the intermingled fibrillary area between the peripheral endothelium and TM. The late-onset cells first adopted a quickly migrating, fibroblast-like morphology (**Figure 3B, E**). Within 10 days of culture, however, the cell migration pattern became more coordinated in which cells acquired an endothelial cell phenotype with a regular morphology (**Figure 3C, F** and **Figure 4B**). Interestingly, cell viability evaluation of outer graft rims with a late-onset cell population showed a heterogenous Calcein-AM signal intensity (**Figure 2A: ME** vs. **LCT**, **B: ME** vs. **LCT**) where late-onset cells displayed a lower fluorescence signal intensity than the cells that had started earlier with the migration.

The late-onset cells appear to originate from the far peripheral area of the endothelium, a region that has been referred to as a progenitor enriched region (TZ) with the potential to generate mature human corneal EC.[26,27] For the far peripheral endothelium a high mitogenic activity has been reported due to their propensity to sphere formation when cultured on low adhesion surfaces.[28] When spheres were injected into the anterior chamber of rabbit eyes with corneal deficiency, they formed a functional endothelium.[29,30] Zhang et al. demonstrated that TZ cells can proliferate and differentiate into CEC by culturing TZ cells from donor corneal rims.[31] The TZ cells grew from the explant after 20 days of culture, exhibiting initially a rounder polygonal morphology, that become gradually more elongated and fibroblastic during passaging and finally polygonal 2 to 3 passages before senescence. As a general observation, terminal differentiation was identified when the TZ cells spontaneously acquired round and polygonal morphology. While we cannot definitively state that the late onset growth represents TZ cell growth, the timing and end morphology of the cells is highly suggestive.

In our study, the observation of this late-onset cell population was only possible because the outer graft rims had been cut in order to flatten them on the substrate, however, the question is how these cells could be activated *in vivo*. While He et al. hypothesized that cells from the far periphery may have the ability to migrate towards the corneal center along DM grooves,[11] it is yet still unknown whether the TZ/late-onset cells play an active functional role or can be stimulated to be functionally active *in vivo*.

Although endothelial-to-mesenchymal transition (EMT) has been described to occur when CEC are cultured over multiple passages and cells adopted a more elongated morphology,[32] highly proliferative TZ cells first adopt a fibroblast-like morphology and later transform to a polygonal morphology.[31] Previous studies also reported that there is no association of the TZ dimension or proliferative characteristics with donor age, ethnicity, or cell density which is in agreement with our findings that the outer rims showing the late-onset cells were isolated from old donors (68–80 years old) with variable ECD (1800 – 2400 cells/mm^2), and preservation time before culture (8–26 days).[26]

Interestingly, the presence of ROCK-inhibitor in the culture medium did not alter the cell outgrowth from the outer graft rims. While it did appear beneficial for maintaining the cell shape and cell-cell adhesion contacts during collective migration, no differences in fluorescence intensity and expression patterns were observed for

the functional protein marker Na^+/K^+–ATPase and surface glycoproteins NCAM and GPC-4. Similar observations have been reported in other studies where the authors concluded that ROCK-inhibitors did not induce proliferation or alter the apoptosis of human corneal EC in culture but modulated the cell adhesion properties, cell morphology, and cell junctions by regulating the dynamic rearrangements of the actin cytoskeleton.[33,34] It is possible that the growth factors present in the serum and routinely added to these explant cell cultures already promote cell growth to the point that the effect of a ROCK-inhibitor cannot be detected.

One limitation of our analysis is the small number of outer graft rims used to test whether the ROCK-inhibitor influences the migratory ability of corneal endothelial cells *in vitro* and larger studies are needed to obtain more conclusive results under which conditions ROCK-inhibitor is most effective in stimulating cell migration. A technical limitation was the challenging observation of the late-onset cells, that were located close to the borders of the well-plate, due to an uneven illumination caused by liquid meniscus.

CONCLUSION

In conclusion, we present the findings of selectively studying EC migration from the peripheral cornea by using outer graft rims embedded into a thermo-reversible polymer matrix. In this study, we observed the migration of two morphologically distinct cell populations. The first type was triggered by a broken physical barrier, while the second, late-onset type appeared less differentiated but showed a higher proliferative capacity. It is possible that the activation of the later cell population that displays characteristics of the TZ cells is governed by stimuli other than the loss of contact inhibition and the influence of a ROCK-inhibitor. Understanding the cell migration mechanism from phenotypically distinct regions of the endothelium may assist in optimizing regenerative therapies for endothelial diseases and whether other means of pharmaceutical modulation could further improve the outcomes.

Supporting information

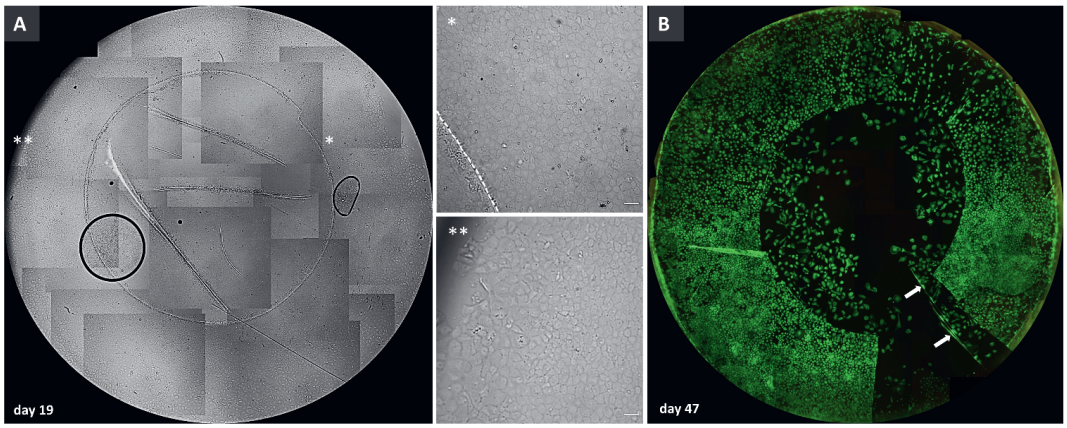

Supplementary Figure 1| Control graft - outer rim pair showing different cell migration behavior. (A) Light microscopy overview collage (x50) of a control graft cultured for 19 days in 3D gel matrix showing the formation of a continuous monolayer. Higher magnification images from the areas marked by * and ** in the overview image illustrate a contact inhibited cell monolayer. (B) Composite photos (x50) stitched together to create an image panorama of the outer rim stained with Calcein-AM after 47 days of gel culture. Note the imprints (market by white arrows) left by the surgical blade on the well surface after cutting open the outer rim. Scale bars:100 µm.

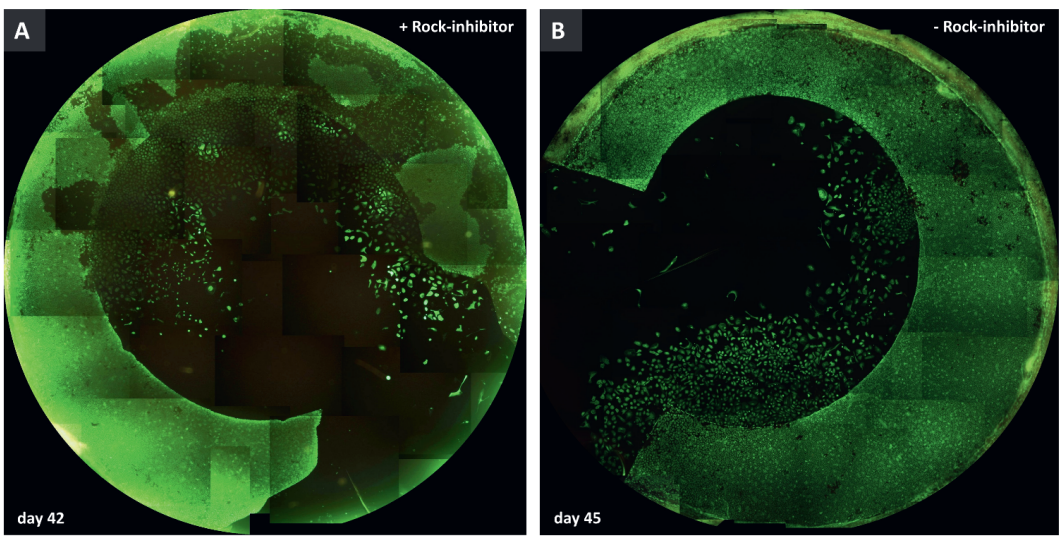

Supplementary Figure 2| Fluorescence imaging overviews. Overviews (collage of x50) are shown for two unpaired outer rims stained with Calcein-AM and cultured (A) in the presence or (B) absence of ROCK-inhibitor. Both outer rims showed cells migrating from areas with low viability.

REFERENCES

1. Rolev K, Coussons P, King L, Rajan M. Experimental models of corneal endothelial cell therapy and translational challenges to clinical practice. Exp Eye Res. 2019;188:107794. https://doi.org/10.1016/j.exer.2019.107794 PMID: 31518569
2. Faye PA, Poumeaud F, Chazelas P, Duchesne M, Rassat M, Miressi F, Lia AS, Sturtz F, Robert PY, Favreau F, Benayoun Y. Focus on cell therapy to treat corneal endothelial diseases. Exp Eye Res. 2021;204:108462. https://doi.org/10.1016/j.exer.2021.108462 PMID: 33493477
3. Català P, Thuret G, Skottman H, Mehta JS, Parekh M, Ní Dhubhghaill S, Collin RWJ, Nuijts RMMA, Ferrari S, LaPointe VLS, Dickman MM. Approaches for corneal endothelium regenerative medicine. Prog Retin Eye Res. 2022;87:100987. https://doi.org/10.1016/j.preteyeres.2021.100987 PMID: 34237411
4. Van den Bogerd B, Dhubhghaill SN, Koppen C, Tassignon MJ, Zakaria N. A review of the evidence for *in vivo* corneal endothelial regeneration. Surv Ophthalmol. 2018 Mar-Apr;63(2):149-165. https://doi.org/10.1016/j.survophthal.2017.07.004 PMID: 28782549
5. Vercammen H, Miron A, Oellerich S, Melles GRJ, Ní Dhubhghaill S, Koppen C, Van Den Bogerd B. Corneal endothelial wound healing: understanding the regenerative capacity of the innermost layer of the cornea. Transl Res. 2022:S1931-5244(22)00114-1. https://doi.org/10.1016/j.trsl.2022.05.003 PMID: 35609782
6. Moloney G, Chan UT, Hamilton A, Zahidin AM, Grigg JR, Devasahayam RN. Descemetorhexis for Fuchs' dystrophy. Can J Ophthalmol. 2015;50(1):68-72. https://doi.org/10.1016/j.jcjo.2014.10.014 PMID: 25677286
7. Borkar DS, Veldman P, Colby KA. Treatment of Fuchs endothelial dystrophy by Descemet stripping without endothelial keratoplasty. Cornea. 2016;35(10):1267-73. https://doi.org/10.1097/ICO.0000000000000915 PMID: 27310885
8. Iovieno A, Neri A, Soldani AM, Adani C, Fontana L. Descemetorhexis without graft placement for the treatment of Fuchs endothelial dystrophy: preliminary results and review of the literature. Cornea. 2017;36(6):637-641. https://doi.org/10.1097/ICO.0000000000001202 PMID: 28410355
9. Kinoshita S, Colby KA, Kruse FE. A close look at the clinical efficacy of Rho-associated protein kinase inhibitor eye drops for Fuchs endothelial corneal dystrophy. Cornea. 2021;40(10):1225-1228. https://doi.org/10.1097/ICO.0000000000002642 PMID: 34481406
10. Choi SO, Jeon HS, Hyon JY, Oh YJ, Wee WR, Chung TY, et al. Recovery of corneal endothelial cells from periphery after injury. PLoS One. 2015;10(9):e0138076. https://doi.org/10.1371/journal.pone.0138076 PMID: 26378928
11. He Z, Campolmi N, Gain P, Binh Thi BMH, Dumollard JM, Duband S, et al. Revisited microanatomy of the corneal endothelial periphery: new evidence for continuous centripetal migration of endothelial cells in humans. Stem Cells. 2012;30(11):2523-34. https://doi.org/10.1002/stem.1212 PMID: 22949402
12. Hara S, Hayashi R, Soma T, Kageyama T, Duncan T, Tsujikawa M, et al. Identification and potential application of human corneal endothelial progenitor cells. Stem Cells Dev. 2014;23(18):2190-201. https://doi.org/10.1089/scd.2013.0387 PMID: 24588720
13. Yam GHF, Seah X, Yusoff NZBM, Setiawan M, Wahlig S, Htoon HM, et al. Characterization of human transition zone reveals a putative progenitor-enriched niche of corneal endothelium. Cells. 2019;8(10):1244. https://doi.org/10.3390/cells8101244 PMID: 31614883
14. Yu WY, Sheridan C, Grierson I, Mason S, Kearns V, Lo ACYL, et al. Progenitors for the corneal endothelium and trabecular meshwork: a potential source for personalized stem cell therapy in corneal endothelial diseases and glaucoma. J Biomed Biotechnol. 2011:412743. https://doi.org/10.1155/2011/412743 PMID: 22187525
15. Moloney G, Petsoglou C, Ball M, Kerdraon Y, Höllhumer R, Spiteri N, et al. Descemetorhexis without grafting for Fuchs endothelial dystrophy-supplementation with topical Ripasudil. Cornea. 2017;36(6):642-648. https://doi.org/10.1097/ICO.0000000000001209 PMID: 28476048

16. Huang MJ, Kane S, Dhaliwal DK. Descemetorhexis without endothelial keratoplasty versus DMEK for treatment of Fuchs endothelial corneal dystrophy. Cornea. 2018;37(12):1479-1483. https://doi.org/10.1097/ICO.0000000000001742 PMID: 30222714

17. Macsai MS, Shiloach M. Use of topical Rho kinase inhibitors in the treatment of Fuchs dystrophy after Descemet stripping only. Cornea. 2019;38(5):529-534. https://doi.org/10.1097/ICO.0000000000001883 PMID: 30720541

18. Artieda JA, Wells M, Devasahayam RN, Moloney G. 5-Year outcomes of Descemet stripping only in Fuchs dystrophy. Cornea. 2020;39(8):1048-1051. https://doi.org/10.1097/ICO.0000000000002270 PMID: 31990847

19. Davies E, Jurkunas U, Pineda R. Pilot Study of corneal clearance with the use of a Rho-kinase inhibitor after descemetorhexis without endothelial keratoplasty for Fuchs endothelial corneal dystrophy. Cornea. 2021;40(7):899-902. https://doi.org/10.1097/ICO.0000000000002691 PMID: 33758139

20. Garcerant D, Hirnschall N, Toalster N, Zhu M, Wen L, Moloney G. Descemet's stripping without endothelial keratoplasty. Curr Opin Ophthalmol. 2019;30(4):275-285. https://doi.org/10.1097/ICU.0000000000000579 PMID: 31033737

21. Lie JT, Birbal R, Ham L, van der Wees J, Melles GRJ. Donor tissue preparation for Descemet membrane endothelial keratoplasty. J Cataract Refract Surg. 2008;34(9):1578-83. https://doi.org/10.1016/j.jcrs.2008.05.036 PMID: 18721723

22. Groeneveld-van Beek EA, Lie JT, van der Wees J, Bruinsma M, Melles GRJ. Standardized 'no-touch' donor tissue preparation for DALK and DMEK: harvesting undamaged anterior and posterior transplants from the same donor cornea. Acta Ophthalmol. 2013;91(2):145-50. https://doi.org/10.1111/j.17553768.2012.02462.x PMID: 22672202

23. Miron A, Spinozzi D, Lie J, Melles GRJ, Oellerich S, Dhubhghaill SN. Improving endothelial explant tissue culture by novel thermoresponsive cell culture system. Curr Eye Res. 2021;46(3):290-293. https://doi.org/10.1080/02713683.2020.1798468 PMID: 32727221

24. Miron A, Spinozzi D, Dhubhghaill SN, Lie J, Oellerich S, Melles GRJ. *In vitro* endothelial cell migration from limbal edge-modified Quarter-DMEK grafts. PLoS One. 2019 ;14(11):e0225462. https://doi.org/10.1371/journal.pone.0225462 PMID: 31747441

25. Dhubhghaill SN, Miron A, Lie JT, Dapena I, Oellerich S, Melles GRJ. Preclinical testing of small diameter Descemet membrane endothelial keratoplasty grafts to increase tissue availability. PLoS One. 2021;16(2):e0246516. https://doi.org/10.1371/journal.pone.0246516 PMID: 33539395

26. Ming NM, Yam GHY, Soh YQ, Lovatt M, Dhaliwal D, Kocaba V, et al. Regenerative capacity of the corneal transition zone for endothelial cell therapy. Stem Cell Res Ther. 2020;11(1):523. https://doi.org/10.1186/s13287-020-02046-2 PMID: 33276809

27. Wongvisavavit R, Parekh M, Ahmad S, Daniels JT. Challenges in corneal endothelial cell culture. Regen Med. 2021;16(9):871-891. https://doi.org/10.2217/rme-2020-020 PMID: 34380324

28. Yokoo S, Yamagami S, Yanagi Y, Uchida S, Mimura T, Usui T, et al. Human corneal endothelial cell precursors isolated by sphere-forming assay. Invest Ophthalmol Vis Sci. 2005;46(5):1626-31. https://doi.org/10.1167/iovs.04-1263 PMID: 15851561

29. Mimura T, Yamagami S, Yokoo S, Araie M, Amano S. Comparison of rabbit corneal endothelial cell precursors in the central and peripheral cornea. Invest Ophthalmol Vis Sci. 2005;46(10):3645-8. https://doi.org/10.1167/iovs.05-0630 PMID: 16186345

30. Mimura T, Yamagami S, Yokoo S, Yanagi Y, Usui T, Ono K, et al. Sphere therapy for corneal endothelium deficiency in a rabbit model. Invest Ophthalmol Vis Sci 2005,46:3128-3135. https://doi.org/10.1167/iovs.05-0251 PMID: 16123411

31. Zhang J, Ahmad AM, Ng H, Shi J, McGhee CNJ, Patel DV. Successful culture of human transition zone cells. Clin Exp Ophthalmol. 2020;48(5):689-700. https://doi.org/10.1111/ceo.13756 PMID: 32249477

32. Chen S, Zhu Q, Sun H, Zhang Y, Tighe S, Xu L, et al. Advances in culture, expansion and mechanistic studies of corneal endothelial cells: a systematic review. J Biomed Sci. 2019;26(1):2. https://doi.org/10.1186/s12929-018-0492-7 PMID: 30609919

33. Pipparelli A, Arsenijevic Y, Thuret G, Gain P, Nicolas M, Majo F. ROCK inhibitor enhances adhesion and wound healing of human corneal endothelial cells. PLoS One. 2013;8(4):e62095. https://doi.org/10.1371/journal.pone.0062095 PMID: 23626771

34. Wu Q, Ouyang C, Xie L, Ling Y, Huang T. The ROCK inhibitor, thiazovivin, inhibits human corneal endothelial-to-mesenchymal transition/epithelial-to-mesenchymal transition and increases ionic transporter expression. Int J Mol Med. 2017;40(4):1009-1018. https://doi.org/10.3892/ijmm.2017.3103 PMID: 28849097

CHAPTER 9

Preclinical testing of small diameter Descemet membrane endothelial keratoplasty grafts to increase tissue availability

PLoS One. 2021 Feb 4;16(2):e0246516

Sorcha Ní Dhubhghaill, Alina Miron, Jessica T. Lie, Isabel Dapena, Silke Oellerich, Gerrit R. J. Melles

Abstract

In this study, we describe a process of preparing, surgically manipulating, and validating a novel "small diameter" 4 mm circular Descemet membrane endothelial keratoplasty (DMEK) graft *in vitro*. Three small diameter DMEK grafts can be prepared from a single donor endothelium and could, therefore, potentially expand the donor pool. Prior to clinical use, however, we aimed to examine each step of the process to determine the effect on the endothelial cell loss and whether or not cells retained their capacity to migrate uniformly. For this study, circular small diameter grafts, obtained from twelve corneas of ten donors deemed ineligible for transplantation, were included. Small diameter DMEK graft preparation was successful in all cases (n = 36). Endothelial cell density (ECD), determined in the eye bank on seventeen grafts, showed an average decrease from 2413(±189) cells/mm^2 before to 2240 (±413) cells/mm^2 after preparation. Twenty-four grafts were used to simulate DMEK-surgery *in vitro* and were successfully stained with 0.06% trypan blue, loaded into a straight DMEK-injector, unfolded, positioned, and centered within the circular ≈ 4 mm descemetorhexis. The estimated % area populated by viable cells on the grafts decreased from on average 92 (±3) % before to 78 (±10) % (n = 4) after *in vitro* surgery. Cells displayed a capacity for uniform cell migration from all edges of the graft (n = 4) when embedded in the 3D hydrogel system. Our data show, that by using an *in vitro* model of DMEK-surgery it was possible to test the 4 mm circular DMEK grafts from eye bank preparation to surgical implantation. The cell loss after *in vitro* surgery was comparable with the *in vivo* ECD decline early after DMEK and the capacity of the cells to migrate to potentially cover bare stroma indicates that these small diameter grafts may be a viable clinical option to treat central endothelial disease.

Introduction

Descemet membrane endothelial keratoplasty (DMEK) is the current standard of care for patients with symptomatic corneal endothelial dysfunction, with some of the best outcomes being seen in cases of Fuchs endothelial corneal dystrophy (FECD).[1] While this technique represents an improvement over the classical penetrating keratoplasty (PK)[2] and Descemet stripping (automated) endothelial keratoplasty (DSAEK),[3] it is limited by the 1:1 endothelial donor to recipient ratio, though the stroma may be repurposed for anterior corneal use.[4,5] In an effort to address this and at the same time trying to possibly reduce the antigen load of the transplanted tissue, Quarter-DMEK was developed, where four patients with central FECD could be treated using a single donor endothelium.[6–10] Clinically, Quarter-DMEK grafts perform well, with similar best corrected visual acuity (BCVA) to conventional DMEK, though the endothelial cell density (ECD) is lower,[9] which may be due to the shape mismatch between a round descemetorhexis and a triangular graft. These bare stromal areas require migration of endothelial cells to clear the cornea which could be cause of the reduced ECD.[7]

Donor independent strategies for central FECD have also been explored. In these approaches, known as 'Descemet stripping only' (DSO) or 'Descemetorhexis without endothelial keratoplasty' (DWEK), a smaller descemetorhexis of 4–5mm is performed, removing both the endothelium and associated guttae.[10–15] In successful cases, the residual peripheral endothelial cells spread and migrate to close the defect and clear the cornea. While this does avoid the need for donor tissue, the postoperative healing time is longer, and the success rate is less than that of gold standard DMEK techniques.[16]

A smaller graft that matches a smaller descemetorhexis could, in theory, be combined to marry the best aspects of both techniques. Miniature DMEK grafts or bare Descemet membrane transplants have been used previously to treat stromal hydrops[17,18] or to promote endothelial cell migration after manual removal of diseased central corneal endothelial cells from the recipient cornea.[19,20] While it was technically challenging, it was still feasible to place the patch in the correct place and resulted in clinical improvement. The technique, however, has not been applied to FECD and the effect of preparing and manipulating such grafts on the endothelium is not known.

In this study, we describe a process of preparing and surgically testing small diameter DMEK grafts *in vitro*. The aim was to evaluate not only the feasibility of the surgery but also the effect on endothelial cell density, viability, and migration capacity.

Materials and methods

Corneas

Human postmortem corneas, that were deemed ineligible for transplantation, but which had an intact and viable endothelial cell layer, were obtained from Amnitrans EyeBank Rotterdam. Small diameter DMEK grafts were prepared from twelve corneas of ten donors (mean age 69 (±9) years; range 57–85 years) for a total of 36 grafts. The average storage time prior to graft preparation was 13 (±6) days (range 4–21 days) and average ECD 2500 (±230) cells/mm^2 (range 2100–3000 cells/mm^2) (**Table 1**).

All donors had stated to have no objection to transplant-related research and the study adhered to the tenets of the Declaration of Helsinki. No institutional review board approval was obtained as under national regulation no approval is required for this research if no extra procedure was performed to obtain the samples and donors had consented to having the samples used for research purposes (https://www.ccmo.nl/onderzoekers/aanvullende-informatie-over-bepaalde-soorten-onderzoek/niet-wmo-onderzoek/onderzoek-met-lichaamsmateriaal).

Table 1. Basic donor demographics of corneas used for small diameter DMEK graft preparation.

Donor Information	
Number of corneas (donors)	12 (10)
Gender	
Female	5
Male	5
Mean age (±SD), yrs. (range)	69 (±9), (57–85)
Mean storage time (±SD), days (range)	13 (±6), (4–21)
Mean ECD (±SD), cells/mm^2 (range)	2500 (±230), (2100–3000)
Rejection reason for corneas (donors)	
Virology	6 (5)
Guttae	1 (1)
Poor endothelium quality (e.g., IOL scars, low ECD, loose roll)	3 (2)
Outdated tissue	2 (2)
Cause of death for corneas (donors)	
Respiratory	4 (3)
Circulatory	2 (2)
Unknown/Others	4 (4)
Cardiovascular	2 (1)

*Mean storage time = time between death and evaluation of the Micro-DMEK at day 0; SD = standard deviation; yrs. = years; ECD = endothelial cell density

Small diameter Descemet membrane endothelial keratoplasty graft preparation

Small diameter DMEK donor tissue preparation was performed by a single experienced eye bank technician (JL). Corneoscleral buttons were excised and stored in organ culture medium at 31˚C (CorneaMax, Eurobio, Courtaboeuf, France) until graft preparation from whole donor globes obtained less than 24 hours postmortem. The corneoscleral buttons were mounted endothelial side up on a custom-made holder with a suction cup (DORC International, Zuidland, The Netherlands). The Descemet membrane (DM) was separated from the stroma by using a hydro-separation technique using a bent 30G needle (BD Microlance, Drogheda, Ireland) inserted just underneath the DM layer bevel up until the bevel was completely inserted. A small amount of 0.9% physiological salt solution (BSS, B. Braun, Melsungen, Germany) was injected in order to separate DM from the stroma (**Figure 1A**).

Additional physiological salt solution was injected with increased pressure aiming to establish a bubble spanning the full diameter of the cornea (**Figure 1B** and **1C**). Throughout the hydro-separation of the DM from its underlying stroma, the endothelium surface was kept moist by regularly applying BSS solution. After the hydro-dissection, the peripheral DM with its adjacent trabecular meshwork (TM) was loosened over 360 degrees by using a hockey stick blade (**Figure 1D**) and the anterior remnant was replaced by a soft contact lens (**Figure 1E**).[4] The soft contact lens supporting the DM still attached to the TM was placed on a punch block (Network medical products, Ripon North Yorkshire, UK) (**Figure 1F** and **1G**). Attachment of the TM prevented the tissue from scrolling and facilitated further handling. Subsequently, the three grafts were carefully punched out by using a 4 mm diameter biopsy punch (Kai Europe GmbH, Solingen, Germany) (**Figure 1H**, **1J** and **1K**). Small diameter DMEK grafts were stored in organ-culture medium until the time came for further analysis or *in vitro* surgery (**Figure 1L**). Endothelial cell density was calculated centrally on the corneas before preparation and on the grafts after preparation using the fixed-frame method by using at least three frames per cornea and graft,

respectively (**Figure 1M**). Post-preparation ECD counts were available for 17 small diameter DMEK grafts with sufficient image quality.



Figure 1| Image collage showing the different steps of preparing three small diameter grafts from one donor cornea. (A) Local DM separation from the stoma by hydro-dissection using a bent 30G needle. (B, C) Separation of the DM along with the corneal endothelium by a bubble spanning the full diameter of the cornea. (D) Complete detachment of the peripheral DM with its adjacent TM using a hockey stick blade. (E) The anterior remnant was replaced on a soft contact lens. (F, G) Transfer of the soft contact lens holding the DM with its TM to a punch block. (H) Preparation of three small diameter grafts by carefully punching out the grafts using a 4 mm diameter biopsy punch. (J) Schematic representation of the trephination pattern for the three grafts. (K, L) Remaining part of the DM sheet after punching out three 4 mm grafts and the three resulting grafts. (M) Light microscopy image of a graft showing the endothelial cells on the graft and a very thin denuded band along the graft edge caused by trephination.

In vitro surgery

In vitro surgery for 24 of the 4 mm DMEK grafts was performed in a manner similar to conventional DMEK,[21] with some modifications. All grafts were prepared by staining them twice with 0.06% trypan blue for three minutes (**Figure 2A**). Grafts were then loaded into a straight DMEK injector (Geuder DMEK injector, Heidelberg, Germany) (**Figure 2B**). Twenty small diameter DMEK grafts were used during the optimization steps using two types of anterior chamber set ups. The first experiments were performed using a donor corneoscleral button mounted on an artificial anterior chamber. The small graft size and deep chamber, however, made modelling the surgery very difficult. This was made easier by using a flexible thermoplastic material (Parafilm, Bemis Co, USA) to simulate the function of the iris in DMEK surgery. The artificial chamber was primed with balanced salt

solution and the film was stretched over it, followed by locking the corneoscleral button in place. Adjusting the pressure in the anterior chamber allowed the surgeon to shallow or deepen the chamber as needed and it was possible to position the graft in the Descemetorhexis (**Figure 2C**). While this partitioned anterior chamber was very helpful for practicing the maneuvers, the endothelium can adhere to the thermoplastic film and be damaged. To better model the true surgical situation, the final round of experiments was therefore, performed on whole globes (n = 4). The allowed better control of the iris and anterior chamber dept than the model setup.

The globes used were also obtained from Amnitrans EyeBank Rotterdam and had been deemed ineligible for transplantation. Globes were stabilized on a suction support device (DALK/PLK Holder, DORC International). The intraocular pressure could be adjusted by increasing or decreasing the aspiration, fixating the globe. A 4 mm circular guiding mark was colored using gentian violet and then stamped on the anterior surface of the cornea. A 3 mm self-sealing corneal incision and three 1mm paracentesis incisions were created at the limbus. Air was then injected into the anterior chamber and a Descemetorhexis, slightly larger than the 4 mm guiding ring, was created. The graft was then injected into the anterior chamber ensuring that it retained its orientation and that the pressure remained soft to prevent reflux. The anterior chamber was kept relatively shallow during the surgical maneuvers.

Once the graft was centered in the Descemetorhexis, air was slowly injected under the graft until the anterior chamber was completely full (**Figure 2D**). Full air fill was maintained for 30–45 minutes and imaging was performed using an anterior segment optical coherence tomographer (AS-OCT) (CASIA SS-1000 OCT, Tomey GmbH, Erlangen, Germany) (**Figure 2E**). At the end of the air-fill period, the corneoscleral rims were carefully excised and transferred endothelial side-up in a glass jar filled with BSS. By gently moving the corneal remnant through the liquid, the graft came loose and, with a glass pipette, could be transferred onto any support and subjected to further biological analysis.

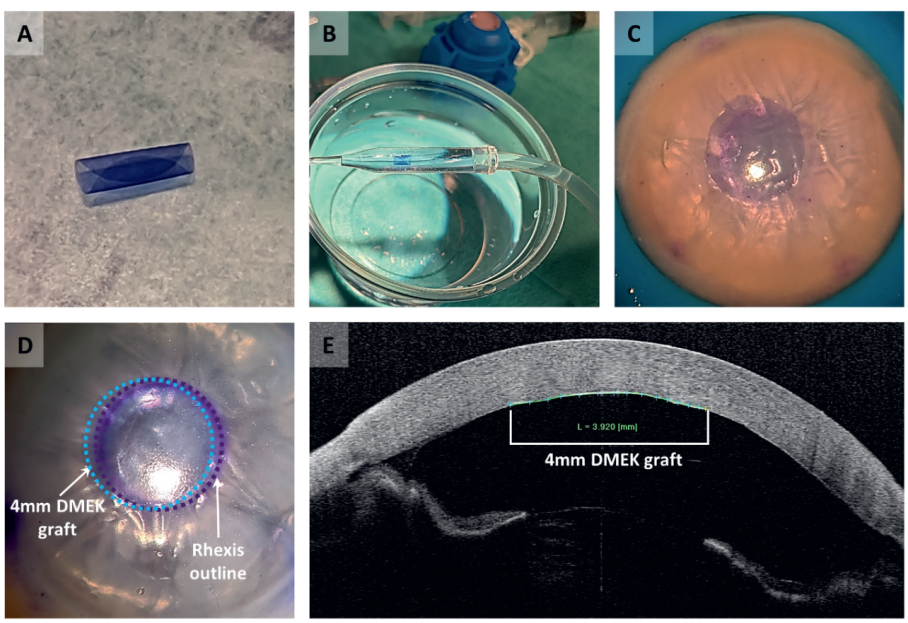

Figure 2| *In vitro* surgery performed with the small diameter DMEK graft. (A) Graft staining with 0.06% trypan blue. (B) Graft loading into a straight DMEK injector. (C) Descemetorhexis performed on a cornea mounted on an artificial anterior chamber. (D) Graft unfolding and positioning in the descemetorhexis area performed in a whole globe. Purple dashed line indicates the outline of the descemetorhexis, and the blue dashed line indicates the position of the 4 mm DMEK graft. (E) AS-OCT graft imaging after 30–45 minutes of a fully pressurized anterior chamber

Graft viability

Calcein-AM was used to examine the cell viability of the grafts both before (i.e., immediately after preparation) and after *in vitro* surgeries. 100 µl of 400 µM Calcein-AM (Sigma-Aldrich Chemistry BV, Zwijndrecht, The Netherlands) in phosphate-buffered saline (PBS) was added directly to grafts that were flattened on silane-coated glass slides. After a 45-minute incubation period at room temperature and one more PBS washing step, fluorescence images were taken (AxioVert.A1 microscope with AxioCam 305 color camera (Zeiss, Oberkochen, Germany)), and the level of cellular fluorescence was determined with ImageJ using the thresholding method.

Cell migration study

Four small diameter DMEK rolls were successfully unfolded endothelial-side-up on FNC-coated (fibronectin, collagen, and albumin coating mix, Athena ESTM Baltimore, MD, USA) glass coverslip and evaluated *in vitro* in order to examine the cellular migration behavior. One graft was accidently unfolded endothelium-side-down on the FNC-coated glass and was excluded from the study. The unfolding of all the grafts was performed in a "no-touch" manner by dropping organ-culture medium onto the graft until complete unfolding. Each glass coverslip, which supported one graft, was transferred to a 24-well plate and embedded into the thermoresponsive gel matrix as described previously.[22] Grafts were cultured in a humidified atmosphere at 37°C and 5% CO_2 for up to 2 weeks. Medium was refreshed every 2–3 days. Grafts were photographed daily with an AxioVert.A1 microscope to examine cell morphology and cell migration. The recovery of the grafts after cultivation was performed by gradually cooling the gel below the sol-gel transition temperature (<20°C) using low-temperature PBS as the low transfer medium.[20]

Cell monolayer integrity was evaluated after gel removal by immunohistochemistry. Two samples were stained for the expression of zonula occludens-1 (ZO-1) according to a protocol that has been described previously.[22, 23]

Results

Graft preparation

Preparation was successful for all 12 corneas and resulted in 36 grafts of 4 mm diameter (**Figure 1**). All grafts showed endothelial cells up to the graft edge with only a small outer band of cells becoming depleted due to the trephination (**Figure 1M**). Cells showed the typical endothelial cell morphology and no micro-fibrillar arrangements representative for the far corneal periphery were observed. Post- preparation ECD was 2240 (±413) cells/mm^2 (n = 17) and it was not statistically significant compared to an ECD of 2413 (±189) cells/mm^2 (P = .141) calculated centrally before preparation on the same donor corneas used for graft preparation. The cell viability assay performed directly after preparation showed that, on average, 92 (±3)% of the graft surface area was covered by viable cells (**Figure 3**).

In vitro surgery

In vitro surgery was performed using 24 of the 4 mm DMEK grafts. In all cases the grafts could be successfully positioned centrally in a 4 mm descemetorhexis area. It should be noted that the graft was opened slightly differently than in conventional DMEK. It was noted that intracameral direct fluid injection and air bubble unfolding were not helpful surgical maneuvers, given that the grafts responded by moving too freely around the anterior chamber. Unfolding and centration were instead achieved by soft taps and strokes with a cannula on the outer corneal surface. Post-surgery OCT imaging confirmed complete adherence of the grafts in all cases.

For *in vitro* surgeries performed in globes, assessment of cell viability by Calcein-AM assay showed that the estimated average % area populated by viable cells on the grafts was 78 (±10)% (n = 4) after *in vitro* surgery. This would correspond to an average decline of 14% (±5) inviable cell area compared to the 92 (±3)% surface area covered by viable cells determined directly after graft preparation (**Figure 4**).

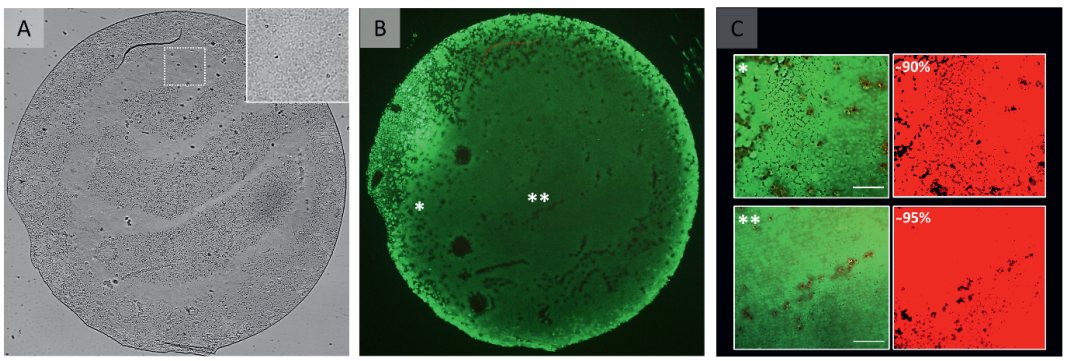

Figure 3| Graft viability after preparation. (A) Light microscopy image of a flattened 4 mm DMEK graft. The insert in the right top corner represents an area on the graft (white square) that may be perceived as a bare area in the overview image but is populated by cells. Please note that areas on the graft that may be perceived as bare areas in are artefacts from the mounting the flat tissue and keeping the graft moist to avoid tissue drying during imaging, which in turn causes some areas to be out of focus. (B) Fluorescence microscopy image of the same graft showing Calcein-AM staining for cell viability. The fluorescence image in (B) shows that all those areas that appeared to be devoid of cells in (A) are indeed covered by viable cells. (C) Higher magnification images from the areas marked by * and ** in overview image (B) to illustrate the viable cells (green) and the corresponding segmentation images (red). Scale bar: 100 µm.

Cell migration study

Grafts (n = 4) placed in 3D-gel culture showed uniform cell migration around the entire circular graft edge (**Figure 5A** and **5C**). Endothelial cells appeared densely packed with a homogenous morphology on all grafts (**Figure 5B**). After gel removal cells showed expression of ZO-1 all across the graft (**Figure 5D**) and also in the newly formed cell monolayer (**Figure 5E**).

Discussion

In this study, we present a new tissue-efficient surgical strategy for the treatment of central FECD by successfully validating the preparation process and *in vitro* surgically protocol for a circular small diameter DMEK graft. With this new application of the small diameter DMEK technique, three circular mini-DMEK grafts with a diameter of 4 mm can be obtained from one donor cornea.

The circular shape allows for the graft to be well matched to a 4 mm circular descemetorhexis similar to those used in DSO/DWEK procedures,[12–21] thereby reducing the bare stroma area that needs to be re-populated postoperatively by endothelial cells. At the same time, harvesting three circular 4 mm grafts avoids the far periphery of the corneal endothelium from being included in the graft (**Figure 1J**). The far peripheral corneal cells of the endothelium are intermingled with collagen fibers which inhibit their capacity to migrate.[8,9] Thus, by avoiding the periphery in these circular trepanations, it was possible to maintain migration capability from the entire perimeter of the graft.

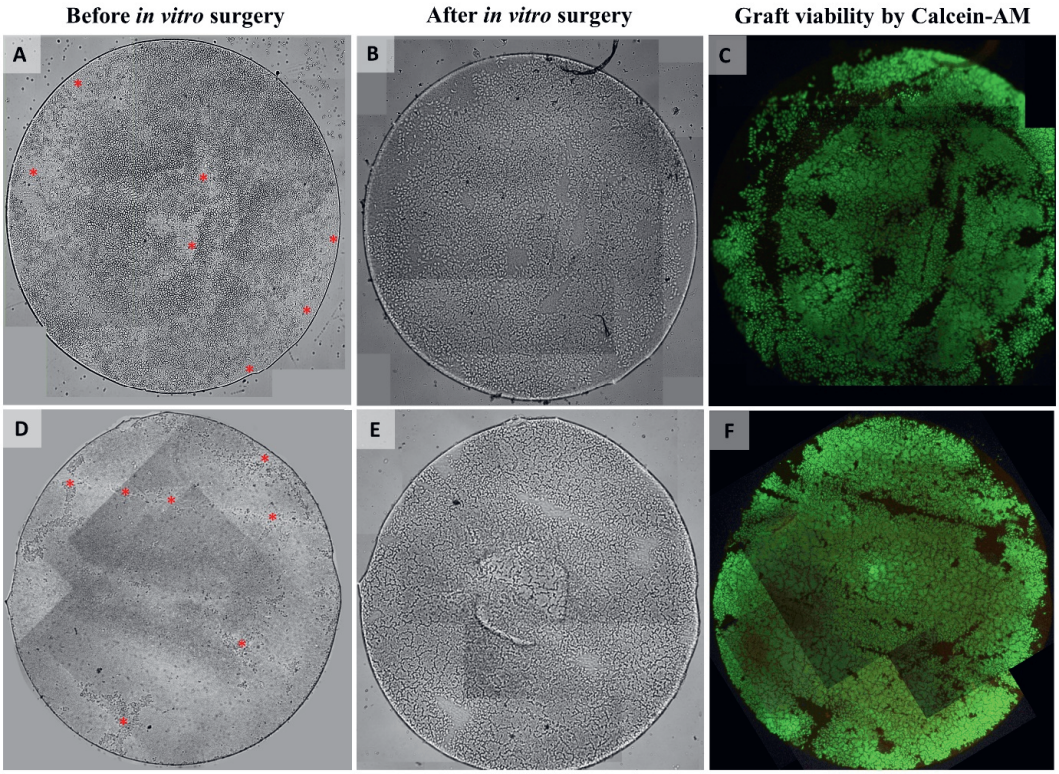

Figure 4| Light and fluorescence microscopy images of two 4 mm DMEK grafts before and after *in vitro* surgery. (A, D) Light microscopy images of the grafts before *in vitro* surgery already showing some areas denuded of cells (red asterisk mark) directly after preparation which is probably related to the low-quality of the corneas ineligible for transplantation that were used for preparation. (B, E) Light microscopy images and (C, F) fluorescence microscopy images of the grafts after *in vitro* surgery showing again the same areas devoid of cells in addition to some other small areas on the graft that do not show any Calcein-AM fluorescence signal (indicative for the presence of viable cells). Note that one image tile each if missing in (C, F). The graft surface area within these missing image tiles was calculated (0.7% and 1.9%, respectively) and cell viability percentages were corrected for the missing graft area to avoid a potential overestimation.

While surgical handling of such small DMEK grafts could be intuited as prohibitively challenging, the previous work of both Bachmann et al.[17] and Tu[18] indicates that small DMEK grafts can be mobilized effectively in the anterior chamber, even under the visual obstruction of stromal hydrops. Postoperative endothelial cell density was not a main outcome parameter, however, as the primary purpose was to patch ruptured DM so "no-touch" handling was not mandatory. In our surgical testing model, we demonstrated that circular 4 mm DMEK grafts can be handled and centered in a circular descemetorhexis in a "no-touch" fashion with minimal loss in cell viability and migration capacity offering the possibility of using this small patch technique for FECD. The model itself also provided an opportunity to practice surgical maneuvers which may help in reducing the learning curve when translating this technique to patients.

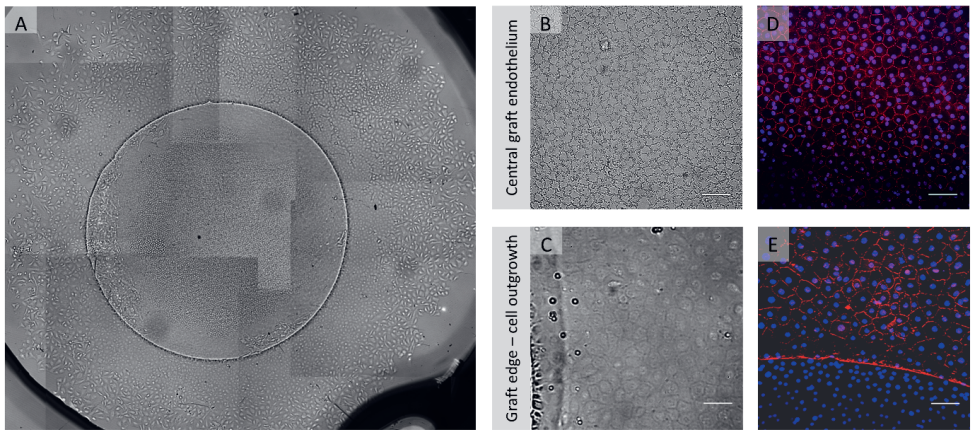

Figure 5| Example of *in vitro* endothelial cell migration from a gel-cultured 4 mm graft. (A) Light microscopy overview collage (50x magnification) of a 4 mm DMEK graft after 17 days in gel culture showing uniform cell migration from all around the graft. (B) Light microscopy image showing central graft endothelium and (C) graft edge (bottom of the image) from where migration was directed as a confluent cellular monolayer. (D, E) Fluorescence microscopy images showing expression of ZO-1 (red signal) counterstained with DAPI (blue signal) in the graft center and in the migrated monolayer. The absence of ZO-1 stained cell borders in the lower part of image 5E can be attributed to the fact that cells in this area reside on the graft and are elevated as compared to the new cell monolayer. Therefore, the cells on the graft have an elevation of about 10 µm (on the Descemet membrane) when compared to the migrated cells on the glass cover slide and therefore appear out of focus. Scale bars: 100 µm.

One limitation of our analysis is the small number of grafts tested in a globe model while the other grafts were used for technique optimization in a different surgical model. This limits the sample size and thus accuracy of the cell viability analysis. Also, for cell viability analysis grafts could not be evaluated before and after surgery, and in addition had to be removed from the globe for imaging which constitutes an additional handling. However, the latter may be expected to have rather decreased than increased the reported cell viability percentage after *in vitro* surgery. With these limitations, the viability estimates are to be considered an extrapolation, but they still provide some reassurance prior to applying this technique in a patient's eye. For future studies, using prolonged Calcein-AM staining to monitor the decrease in cell viability during the entire process from graft preparation to surgery may provide more detailed information on the effect of each handling step.[24]

It should also be noted that small-diameter DMEK grafts are not a replacement for full-sized DMEK, particularly in extensive FECD and bullous keratopathy, where peripheral corneal edema is a prominent feature. They should rather be considered an option for central FECD and a potential alternative, or rescue strategy, for DSO/DWEK. By having a matching shape to the circular descemetorhexis, small diameter DMEK grafts may provide a faster corneal clearance than DSO. After successfully *in vitro* testing of small diameter DMEK grafts from eye bank preparation to surgical implantation, clinical tests will be required to evaluate if small diameter-DMEK can indeed become a viable clinical option to treat central endothelial disease.

Supporting information



Supplementary Figure 1| Light microscopy examination of the research-graded human corneas before small dimeter DMEK graft preparation. For cell viability assessment after preparation. For cell viability assessment after preparation in the eye bank, grafts of corneas A, B, C, I and K were used. Grafts used to optimize the learning curve and tested using artificial anterior chamber model were prepared from corneas A-I. The four grafts transferred into globes were prepared from L and K. Migration studies were performed with grafts of corneas B, C and J.

References

1. Birbal RS, Baydoun L, Ham L, Miron A, van Dijk K, Dapena I, et al. Effect of surgical indication and preoperative lens status on Descemet membrane endothelial keratoplasty outcomes. Am J Ophthalmol. 2020 Apr; 212:79–87. https://doi.org/10.1016/j.ajo.2019.12.011 PMID: 31863726
2. Fernandez MM, Afshari NA. Endothelial keratoplasty: From DLEK to DMEK. Middle East Afr J Ophthalmol. 2010 Jan; 17(1):5–8. https://doi.org/10.4103/0974-9233.61210 PMID: 20543930
3. Price FW Jr, Price MO. Descemet's stripping with endothelial keratoplasty in 200 eyes: Early challenges and techniques to enhance donor adherence. Cataract Refract Surg. 2006 Mar; 32(3):411–418. https://doi.org/10.1016/j.jcrs.2005.12.078 PMID: 16631048
4. Groeneveld-van Beek EA, Lie JT, van der Wees J, Bruinsma M, Melles GRJ. Standardized 'no-touch' donor tissue preparation for DALK and DMEK: harvesting undamaged anterior and posterior transplants from the same donor cornea. Acta Ophthalmol. 2013 Mar; 91(2):145–150. https://doi.org/10.1111/j.1755-3768.2012.02462.x PMID: 22672202
5. Lie JT, Groeneveld-van Beek EA, Ham L, van der Wees J, Melles GRJ. More efficient use of donor corneal tissue with Descemet Membrane Endothelial Keratoplasty (DMEK): Two lamellar keratoplasty procedures with one donor cornea. Br J Ophthalmol. 2010 Sept: 94(9):1265–1266. https://doi.org/10.1136/bjo.2009.171629 PMID: 20576762
6. Baydoun L, Zygoura V, Hsien S, Birbal RS, Spinozzi D, Lie JT, et al. Clinical feasibility of using multiplegrafts from a single donor for Quarter-DMEK. Acta Ophthalmol. 2018 Aug; 96(5):656–658. https://doi.org/10.1111/aos.13720 PMID: 29498213
7. Zygoura V, Baydoun L, Ham L, Bourgonje VJA, van Dijk K, Lie JT, et al. Quarter-Descemet membrane endothelial keratoplasty (Quarter-DMEK) for Fuchs endothelial corneal dystrophy: 6 months clinical outcome. Br J Ophthalmol. 2018 Oct; 102(10):1425–1430. https://doi.org/10.1136/bjophthalmol-2017-311398 PMID: 29343529
8. Muller TM, Lavy I, Baydoun L, Lie JT, Dapena I, Melles GR. Case report of Quarter-Descemet membrane endothelial keratoplasty for Fuchs endothelial dystrophy. Cornea. 2017 Jan; 36(1):104–107. https://doi.org/10.1097/ICO.0000000000001008 PMID: 27583798
9. Birbal RS, Ni Dhubhghaill S, Baydoun L, Ham L, Bourgonje VJA, Dapena I, et al. Quarter-Descemet membrane endothelial keratoplasty: One- to two-year clinical outcomes. Cornea. 2020 Mar; 39(3):277–282. https://doi.org/10.1097/ICO.0000000000002127 PMID: 31490274
10. Oganesyan OG, Neroev VV, Grdikanyan AA, Getadaryan VR. Five keratoplasties from one donor cornea. Cornea. 2018 May; 37(5):667–671. https://doi.org/10.1097/ICO.0000000000001551 PMID: 29489516
11. Moloney G, Chan UT, Hamilton A, Zahidin AM, Grigg JR, Devasahayam RN. Descemetorhexis for Fuchs' dystrophy. Can J Ophthalmol. 2015 Feb; 50(1):68–72. https://doi.org/10.1016/j.jcjo.2014.10.014 PMID: 25677286
12. Borkar DS, Veldman P, Colby KA. Treatment of Fuchs endothelial dystrophy by Descemet stripping without endothelial keratoplasty. Cornea. 2016 Oct; 35(10):1267–1273. https://doi.org/10.1097/ICO.0000000000000915 PMID: 27310885
13. Iovieno A, Neri A, Soldani AM, Adani C, Fontana L. Descemetorhexis without graft placement for the treatment of Fuchs endothelial dystrophy: Preliminary results and review of the literature. Cornea. 2017 Jun;36(6):637–641. https://doi.org/10.1097/ICO.0000000000001202 PMID: 28410355
14. Moloney G, Petsoglou C, Ball M, Kerdraon Y, Ho¨llhumer R, Spiteri N, et al. Descemetorhexis without grafting for Fuchs endothelial dystrophy-supplementation with topical ripasudil. Cornea. 2017 Jun; 36(6):642–648. https://doi.org/10.1097/ICO.0000000000001209 PMID: 28476048
15. Garcerant D, Hirnschall N, Toalster N, Zhu M, Wen L, Moloney G. Descemet's stripping without endothelial keratoplasty. Curr Opin Ophthalmol. 2019 Jul; 30(4):275–285. https://doi.org/10.1097/ICU.0000000000000579 PMID: 31033737
16. Van den Bogerd B, Ni Dhubhghaill S, Koppen C, Tassignon MJ, Zakaria N. A review of the evidence for *in vivo* corneal endothelial regeneration. Surv Ophthalmol. 2018 Mar-Apr; 63(2):149–165. https://doi.org/10.1016/j.survophthal.2017.07.004 PMID: 28782549
17. Bachmann B, Ha¨ndel A, Siebelmann S, Matthaei M, Cursiefen C. Mini-Descemet membrane endothelial keratoplasty for the early treatment of acute corneal hydrops in keratoconus. Cornea. 2019 Aug; 38(8):1043–1048. https://doi.org/10.1097/ICO.0000000000002001 PMID: 31276462
18. Tu EY. Descemet membrane endothelial keratoplasty patch for persistent corneal hydrops. Cornea. 2017 Dec; 36(12):1559–1561. https://doi.org/10.1097/ICO.0000000000001351 PMID: 28872520

19. Soh YQ and Mehta JS. Regenerative Therapy for Fuchs Endothelial Corneal Dystrophy. Cornea. 2018 Apr;37(4):523–527. https://doi.org/10.1097/ICO.0000000000001518 PMID: 29384808
20. Ong HS, Ang M, Mehta J. Evolution of therapies for the corneal endothelium: past, present and future approaches. Br J Ophthalmol. 2021 Apr;105(4):454-467. https://doi.org/10.1136/bjophthalmol-2020-316149 PMID: 32709756
21. Dapena I, Moutsouris K, Droutsas K, Ham L, van Dijk K, Melles GR. Standardized "no-touch" technique for Descemet membrane endothelial keratoplasty. Arch Ophthalmol. 2011 Jan; 129(1):88–94. https://doi.org/10.1001/archophthalmol.2010.334 PMID: 21220634
22. Miron A, Spinozzi D, Ni Dhubhghaill S, Lie JT, Oellerich S, Melles GRJ. In vitro endothelial cell migration from limbal edge-modified Quarter-DMEK grafts. PLOS ONE. 2019 Nov 20; 14(11):e0225462 https://doi.org/10.1371/journal.pone.0225462 PMID: 31747441
23. Miron A, Spinozzi D, Bruinsma M, Lie JT, Birbal RS, Baydoun L, et al. Asymmetrical endothelial cell migration from *in vitro* Quarter-Descemet membrane endothelial keratoplasty grafts. Acta Ophtalmol. 2018 Dec; 96(8):828–833. https://doi.org/10.1111/aos.13841 PMID: 30171674
24. Bhogal M, Lwin CN, Seah XY, Murugan E, Adnan K, Lin SJ, et al. Real-time assessment of corneal endothelial cell damage following graft preparation and donor insertion for DMEK. PLoS One. 2017 Oct 4; 12(10):e0184824. http://doi.org/10.1371/journal.pone.0184824 PMID: 28977017

CHAPTER 10

Summary, Discussion, and Future Perspectives

SUMMARY AND DISCUSSION

An intact corneal endothelium is essential for corneal transparency as it regulates corneal nutrition and hydration by balancing a semipermeable barrier activity with active ion transport mechanisms. The human endothelium is thought to be an amitotic cell layer with a continuous and age-dependent loss of endothelial cells of about 0.5 to 0.9% annually.[1] However, the endothelial cell loss can be accelerated due to corneal diseases, damage by inflammatory processes or by mechanical trauma following intraocular surgery or penetrating injury. Although the corneal endothelial cells (CEC) in low density conditions will display increased cellular migration by decreasing contact inhibition, once the endothelial cell density (ECD) drops below a minimum required to maintain the pumping function of the endothelium (typically around 400 – 500 cells/mm^2), it will result in corneal decompensation. In such cases, the damaged or diseased portion of the cornea is surgically replaced either by a full thickness corneal graft (Penetrating Keratoplasty – PK) or a lamellar endothelial cell layer graft (lamellar endothelial keratoplasty – EK). Descemet Membrane Endothelial Keratoplasty (DMEK) is the most selective EK technique and nowadays the preferred treatment option for endothelial diseases.

Similar to solid organ grafting, transplanted corneal tissue possesses a limited lifespan that is often related to the density of cells transplanted. Grafts may display an acute (related to surgical technique or graft preparation) or chronic endothelial cell loss (subclinical immunological reaction) that could lead to graft failure. Moreover, due to the global deficit of donor corneas it is estimated that only 1 in 70 visually impaired patients that require a corneal graft actually receive one.[2,3] In an effort to overcome tissue shortage, Hemi-[4–6] and Quarter-DMEK[7–10] were developed to use the available donor tissue more efficiently. These techniques, like other new treatment options to alleviate tissue shortage, are most appropriate for patients with still healthy peripheral endothelial cells. Therefore, regeneration of the corneal endothelium by tissue engineering techniques, administration of pharmacological modulators or synthetic alternatives is being researched to overcome these problems.[11]

This thesis outlines the rapid progression of the corneal regeneration field, including an in-depth analysis of wound healing pathways and biological modulators. In addition, *in vitro* studies were conducted to evaluate the migration capacity of corneal endothelium before and after EK. These findings result in a better understanding of endothelial cell migration and provided further knowledge for the ongoing research on endothelial graft substitutes.

Early postoperative decrease in ECD after DMEK and DMEK graft viability prior to transplantation

DMEK has become the gold standard to treat endothelial dysfunction owing to the rapid visual rehabilitation, near-normal anatomical restoration of the cornea and a lower risk of allograft rejection.[12] Initially, the DMEK technique was met with some reluctance as there were concerns regarding the technical aspects of graft preparation and surgery.[13] Preparation of thin (10–15 µm) grafts can be challenging and, together with intraoperative graft handling, could potentially lead to either complete tissue loss especially during preparation or to high postoperative endothelial cells loss and low graft survival rate.[14] Since ECD is fundamentally tied to the longevity of endothelial keratoplasty, ECD decrease is considered one of the main outcome measures in the investigation of the efficacy and safety of DMEK, as well as for predicting long-term graft survival.[14–16] Postoperative ECD decrease for all endothelial keratoplasty techniques is usually reported for the six-month follow-up and shows a drop of about 30–40%, comparative to preoperative values, followed by an annual decrease of 7–9% thereafter.[17,18] However, it is unclear at what time point the decrease in ECD reported at six months actually occurred, and whether it reflects a gradual decrease or a sudden drop. The results of a small

case series at our institute showed a larger than 30% decrease in ECD within the first month after DMEK.[19] This finding was substantiated in a follow-up study (**Chapter 1**) on a series of 24 DMEK eyes operated for Fuchs endothelial cell dystrophy (FECD). In this study we were able to obtain specular microscopy images already 1 day and 1 week postoperatively due to the fast corneal clearance after DMEK and we could show that the 30% ECD drop occurs within the first postoperative week; about 2/3 of the total decrease could already be observed after the first postoperative day.[20] Such a rapid decrease cannot be explained by endothelial cell migration and/or redistribution that usually requires more time.[21] Similarly, it is unlikely that such an early drop was caused by an immune response, especially because an allograft rejection is generally considered to be a delayed reaction.[22] Other possibilities for causing the sudden early onset drop in ECD after DMEK may be intraoperative handling or an overestimation of preoperative viable cells on the graft. Since for most surgeries in this study no intraoperative complications were reported, the larger portion of the ECD decrease within the early postoperative phase after DMEK may primarily be explained by the overestimation of the eye bank viable ECD. This led us to examine endothelial cell viability after graft preparation in more detail.

Evaluation of the cell viability and quality of endothelial grafts prepared in the eye bank has become the subject of numerous studies. Endothelial cell loss was evaluated following various graft preparation methods or surgical manipulations.[23–29] Current eye banking practices determine ECD based on the structural integrity of the cells (assessed by trypan blue staining) though this does not exactly reflect the viable cell pool of corneal endothelium allocated for transplantation. Our follow-up study (**Chapter 2**) on graft viability using surgery grade DMEK grafts that could not be allocated (due to the Covid-19-related cancellation of elective surgeries), demonstrated the need to perform a more accurate post-processing corneal endothelial cell analysis.[30] Ideally, grafts should not only be evaluated based on live-dead analysis, but it should be differentiated between various forms of cell death (apoptosis, necrosis, autophagy) since otherwise e.g. apoptotic cells are considered as 'live' cells. For a better differentiation, multiple biochemical and functional assays should be applied. In this regard, Calcein acetoxymethyl ester (Calcein-AM) has been used for studies of enzymatic activity, cell membrane integrity, and long-term cell tracking due to its low cellular toxicity.[31,32] In our study, the cell viability of five grafts scheduled for transplantation was assessed by Calcein-AM on the originally planned surgery day and revealed that the percentage of central surface area covered by viable cells ranged from 57% to 97%. Because of this scattered viability range, we continued with the viability analysis of 11 paired donor corneas evaluated either directly post-preparation or after 3–7 days of storage. Our results showed that cell viability of most DMEK grafts seems not to be affected by preparation and storage, while for some grafts endothelial cell damage undetected by trypan blue could be observed within hours after graft preparation. Because trypan blue can only identify dead cells, it fails to detect apoptotic or necrotic cells.[33] Therefore, when ECD was evaluated after graft preparation by trypan blue staining (eye bank procedure), we observed an average ECD difference of 10 (±21)% compared to ECD determined on the same grafts by Calcein-AM. This large variability of endothelial cell loss observed by Calcein-AM after graft preparation supported our clinical observation that the high endothelial cell loss detected in the early postoperative phase after DMEK can be primarily explained by an overestimation of the graft's viable endothelial cell population.

As an alternative to Calcein-AM, an annexin V-FITC assay has also been reported to detect early apoptosis by targeting negatively-charged phosphatidylserine translocated from the inner membrane leaflet of viable cells to the outer membrane surface during apoptosis.[34] Therefore, combining assays routinely used to characterize cell apoptosis with membrane impermeable dyes such as trypan blue would allow for the detection and quantification, in the same sample, of the apoptotic/necrotic and viable cell populations. However, these assays are not yet approved for the use on transplantable tissue and therefore, there is a still a strong need to develop and validate cell viability and cytotoxicity detection methods that analyze the functional status of the corneal endothelial cells after graft preparation and provide an accurate cell count. Meanwhile, an additional DMEK quality check by light microscopy performed within hour after graft preparation or just before surgery

could help to detect grafts with doubtful endothelial quality and thus, reduce postoperative DMEK complications and low postoperative ECD outcomes.

Perceiving the morphological changes and regenerative capacity of the corneal endothelium *in vivo* and *in vitro*

Intracellular signaling in wound healing

Next to improving the quality of the available corneal donor tissue, current research is also focusing on non-surgical treatments for restoration of corneal endothelium by first understanding the concepts and limitations of clinical procedures. In this regard, the extensive review (**Chapter 3**) on signaling pathways involved in CEC proliferation and migration could lead to new ideas on how to treat corneal endothelial dysfunction in the future.[35]

Developing novel strategies to re-activate CEC regenerative capacity is challenging as CEC are blocked in the G0/G1 phase of the cell cycle *in vivo* and this is further hindered by endothelial-to-mesenchymal transition (EMT). Literature and gene and genome data base analysis revealed a complex interplay of pathways regulating the cell cycle and migration including among others the β-catenin and transforming growth factor (TGF-β) pathways, the PI3K/Akt pathway, and the Rho-ROCK pathway.[36-43] Especially the Rho/ROCK pathway regulates a wide spectrum of fundamental cellular events and is involved in a variety of pathological conditions; its inhibition may trigger various signaling cascades and produce multiple biological effects such as enhanced proliferation, increased motility, or cytoskeleton rearrangements.

In the process of wound repair, corneal endothelial cells may undergo EMT and transform to fibrogenic myofibroblasts. Myofibroblast generation through EMT is largely modulated by the transforming growth factor β (TGF-β)[44,45] that activates not only Smad signals but also other cytokines/growth factors such as mitogen-activated protein kinase (MAPK), P38MAPK.[46–48] Because migration is a major component of wound healing in the corneal endothelium, strategies to inhibit of the unfavorable EMT of the corneal endothelium should not be accompanied with an impairment of cell migration.

The wound healing process of corneal endothelium considers that cells close the wounded gap mainly by migration and increased cell spreading,[49] while cell division remains very low[34] with cells dividing mostly amitotic with formation of binuclear cells.[50] Successful clinical options for replacing the diseased endothelium include approaches that accelerate endothelial healing and suppress EMT through topical administration of ROCK inhibitor eye drops. There is clear evidence that topical Rock inhibitor administered after removal of non-confluent guttae (Descemet stripping only (DSO))[51,52] or after transplanting a devitalized DM[53] for treating central FECD, sustained cornea clearance, improved endothelial cell density, while overall, cells displayed a better architecture. ROCK inhibitors played also a major role in the clinical trial for injecting cultured human CEC into the anterior chamber of the eye.[54,55]

Corneal endothelial cells migrate by transiently acquiring a fibroblast morphology reorganizing the actin into stress fibers, events that are consistent with EMT. Furthermore, EMT may lead to fibrotic complications of healing such as the formation of a retrocorneal fibrous membrane.[56] Inducers of EMT and fibrotic changes in the endothelial layer include interleukine-1 beta (IL-1β) that may be released in response to many 'pathogen associated molecular patterns' (PAMPs) and TGF-β. Although TGF-β can stimulate healing, it also promotes fibrogenic changes including deposition of aberrant extracellular matrix (ECM).[57] To counteract the fibrogenic response, inhibition of TGF-β signaling, viral-mediated overexpression of SMAD7[58] – a natural TGF-β signaling inhibitor, proved to suppress the inhibitory action of TGF-β on cell proliferation, which was mediated by inhibition of SMAD2 phosphorylation and downregulation of p27Kip1.[59] SMAD7 therapy is being currently considered useful for prevention and treatment of fibrogenic disorders in the corneal endothelium.[57]

Clinical scenarios that require corneal endothelial cell migration

Clinical studies on endothelial healing are usually restricted to observations of cases with ocular chemical burn,[60,61] or after replacement of the abnormal corneal endothelium with healthy donor tissue.[62,63] These cases reported corneal recovery either through proliferation of endothelial progenitors from specific regions of the eye (progenitor-enriched niche adjacent to the peripheral endothelium and named inner transition zone (TZ))[64] or combined migration of both donor and remaining recipient endothelial cells. However, the wound healing process of corneal endothelium gives rise to many unanswered questions. For instance, endothelial cell migration insights after Quarter-DMEK surgery (that is, a modified DMEK-technique in which a full-sized DMEK graft is divided in quarters to treat 4 eyes),[8–10] did not succeed in confirming the presence of endothelium progenitors residing in the area close to the limbus. All operated eyes cleared centrally, while the peripheral bare stroma showed persistent edema.[8] The lack of cell migration from that specific region was attributed to the arrangement of collagen fibrillary bands in the graft periphery acting as a barrier for cell migration[6] but could also be caused by the removal of (progenitor) cells during Quarter-DMEK graft preparation. Typical, a DMEK graft diameter of 8–8.5 mm, that is prepared using the no-touch peeling technique, has low chances to show endothelial damage because trephination is performed outside the touched area during preparation.[66,67] However, Quarter-DMEK graft preparation requires manual removal of trabecular meshwork[9] and this technical step may be likely to deteriorate the quality of the peripheral endothelium.

The clinical results of Quarter-DMEK eyes showed a different corneal clearance pattern with clearing primarily occurring adjacent to the radial cut graft edges but not along the 'limbal' round edge of the Quarter-DMEK grafts and in the adjacent bare stromal areas.[8,10] This observation was mainly attributed to an asymmetric endothelial cell migration over different anatomical corneal areas. To better understand the heterogenous cell migration behavior, with migration almost entirely absent in the far periphery of the endothelium, we performed *in vitro* studies to determine how Quarter-DMEK grafts may be positioned best onto the posterior recipient stroma in order to create a more homogeneous corneal clearance pattern (**Chapter 4**).The main experimental challenge was to keep a tissue, inherently inclined to curl, to stay flat in a fixed position on a surface in fluid. While Quarter-DMEK grafts were sandwiched between two glass coverslips spatially separated by a suture wire, the assembly was transferred to a culture plate and cell migration documented over 6 days.[68] Although the experimental set up was rather restrictive for nutrient diffusion, endothelial cells migrated from the radial cut edges but failed from the limbal round edge of the Quarter-DMEK grafts. This finding was mainly attributed to Descemet membrane architecture that organizes the cells in small radial rows induced by the furrow-like distribution of the underlying collagen fibers.[65] Also, it was suggested that endothelial cells undergo, throughout life, a continuous slow centripetal migration from deeper niches toward the center and lose their progenitor phenotype in response to contact with aqueous humor, the presence of TGF-β, and by cell contact inhibition as soon as they form a monolayer.[65] Hence, endothelial cells in the periphery will unlikely migrate outside from the graft area but might still possess residual proliferative capacity.[69,70]

Three-dimensional *in vitro* cell culture model: concept and its applications

Concept description

Given the success to reproduce a clinical observation using an *in vitro* system and research grade donor tissue, we decided to improve the culture technique in order to gather more insight regarding the movement of corneal endothelial cells. But to achieve more reproducible results and reduce the technical burden of the experiments, further optimization of the explant culture system was required. Therefore, we developed a 3D culture technique for explant tissue by using a temperature-reversible hydrogel system which was biocompatible, non-toxic, 100% synthetic, pathogen-free and highly transparent for cell observation (**Chapter 5**). Also, the temperature-dependent dynamic viscosity is an important characteristic that allows the gel to swell, become

soft and flexible upon warming and liquefy upon cooling. This property is very useful to develop methods to harvest cultured cells for specifically planned procedures[71,72] or develop techniques to preserve viable cells within the gel,[73] with no need for an enzymatic treatment.[74] In this study, we expanded the scope of the gel, from an effective culture matrix that provides mechanical support while directing cell adhesion to a structure that adds weight when placed over the top of the biological sample without deteriorating its structure and functionality. In our first *in vitro* cell migration study with Quarter-DMEK grafts sandwiched between two glass slides cell migration could be studied for about 7 days before cells died due to the insufficient supply of nutrients (**Chapter 4**).[68] The new adapted 3D explant culture protocol improved cell viability and collective cell migration continued far longer (>3 weeks).[75] Also, the gel's thermo-reversibility allowed the removal of liquefied gel and enabled the detection of biomolecular markers in the tissue and migrated cell layer which was not possible with the previous experimental set-up.

Study the capacity to induce CEC mitosis in the peripheral corneal endothelium, via the controlled disruption of contact inhibition

Given the advantages of the new 3D culture method to enhance the viability and migration capacity of cells from explant tissue, we continued with testing the effect of different types of peripheral Quarter-DMEK graft modifications on endothelial cell migration (**Chapter 6**). The objective of the study was to further optimize the Quarter-DMEK preparation in order to accelerate corneal clearance in patients along the round edge of the graft. Quarter-DMEK grafts with intact and viable endothelial cells were embedded in a cooled biocompatible, temperature-reversible polymer matrix and cultured over two weeks in a humidified atmosphere.[76] The peripheral edge of Quarter-DMEK grafts was physically modified by either introducing radial cuts into the far peripheral area or by removing parts of the far periphery with a trephine. Immunohistochemistry analysis performed after the two-week culture on grafts retrieved from the polymer matrix, demonstrated the presence of tightly packed and viable cells that showed high migratory ability at the leading edge of the monolayers formed from the radial cut graft edges.

Next to better understanding the molecular pathways involved in endothelial migration (**Chapter 3**), current research also focuses on understanding the structure-function relationships in the adhesive structures of an endothelial monolayer that enable the cell to exert traction on its environment.[77,78] Cells spreading is a process largely determined by two interdependent and interactive systems: the integrin-based apparatus for substrate adhesion and the actin cytoskeleton characterized by distinct arrangements of actin filaments.[79–81] Integrins and actin are coupled through a physical linkage, which provides traction for migration. In collective cell migration cells carry out specialized functions according to their position within the group. Front-rear polarization is an example in which one subset of leader cells at the front guides a larger group of follower cells at the rear.[82] Leader cells typically exhibit a mesenchymal migration phenotype and function by degrading and remodeling the ECM to create channels for the whole cell group to advance cohesively.[83,84] By contrast, followers retain endothelial features such as apical-basolateral polarity and tight junctions and express relatively low levels of guidance receptors. Importantly, cells are not dragged or pushed by neighbors, but actively sense and respond to stresses imposed on them.

Endothelial cell migration from the limbal graft edge, however, was not triggered by increasing cell exposure to free space through surgical modifications of the far periphery. Lack of migration from this area was also not due to an absence of viable cells, since immunolocalization showed cells with expression of structural (zonula occludens-1 (ZO-1) and vimentin) and functional markers (sodium/potassium pump (Na^+/K^+ –ATPase)). At first instance, the furrowed collagen microstructure of the peripheral cornea[65] might have acted as a barrier, thereby preventing migration. At the same time, other stimulus-specific gene expression responses might be required in order to prompt these cells to move. It is possible that important factors responsible for regulating cell migration such as cell-matrix adhesion molecules (e.g., integrins, selectins, cadherins), the Rho family of

small GTPases, and proteases (matrix-metallo proteases (MMPs)), are less expressed in the peripheral cells. When functional integrins recognize ECM ligands (fibronectin, laminin) to form focal adhesion,[85] signaling proteins are recruited to focal adhesion to regulate their assembly and disassembly.[86] Rho family of small GTPases[87] have been reported as key regulators of focal adhesion dynamics by dictating contact association, maturation, and turn over. The disassembly process through which cell adhesions are resealed could be mediated by ECM degradation by MMPs[88,89] or cellular contractile machinery ,i.e., Rho and myosin II, that cause cell rear detachment.[90,91] Taken together, cell migration framework outlines a complex map of processes, with multiple cross-talks between members of different families that influence the cell movement through mutually antagonistic pathways.[92]

Study the regenerative potential of the peripheral corneal endothelium

The failure of far peripheral EC to migrate, in spite of limbal area modifications, still limits the clinical application of Quarter-DMEK. Understanding the nature of these peripheral endothelial cells, how they differ from the central cells, and how to encourage them to migrate would greatly improve the pool of donor tissue available for patients with an immediate need of a transplant.

After having explored the controlled mechanical perturbation of the peripheral endothelium as a possible promoter of collective cell migration, we performed an *in vitro* study to evaluate the potential of ROCK-inhibitor to stimulate peripheral endothelial cell migration. We first adapted the explant tissue shape from a pizza-pie (Quarter-DMEK) to an open-ring (6.5 mm punched out endothelium with TM still attached) to create a better system model for mimicking *in vitro* the *in vivo* effect of ROCK-inhibitor on cell migration outcomes after placing a pie-shaped Quarter-DMEK graft in a circular descemetorhexis area or after DSO (**Chapter 7**). The curved outer graft rims were mounted flat on a substrate, a central prerequisite for observing cell motility, and were cultured in a 3D thermo-reversible hydrogel matrix for over a month. This enabled the assessment whether continuous ROCK-inhibition creates long-term alteration in the migration characteristics of corneal endothelial cells. Our results, described in **Chapter 7,** showed that all cultured rims remained viable and displayed either single regions or collective areas of cell migration, regardless of the presence or absence of a ROCK-inhibitor. Rock-inhibitor, on the other hand, seemed to enhance the morphological stability of the migrated cells. Interestingly, late-onset cell migration from an area close to the limbus was observed. These late-onset cells grew fast into a contact inhibited monolayer displaying the typical hexagonal cell morphology, first adopted a fibroblast-like morphology before acquiring a cell phenotype with a regular morphology and appeared less differentiated compared to other areas of migration. This late-onset cell population not only showed high proliferative capacity but also emerged from outer rim grafts cultured without dysregulating the Rho-ROCK pathway. While it did not alter the cell outgrowth from the outer graft rims, the presence of ROCK-inhibitor did appear beneficial for maintaining the cell shape and cell-cell adhesion contacts during collective migration. The ability of ROCK-inhibitor to promote corneal endothelial wound healing by enhancing endothelial remodeling, adhesion and cell migration has been reported previously.[92]

The broad range of cell migration phenotypes, from non-invasive motility to single-cell mesenchymal style to collective motility, differed in this study compared to previous migration studies of Quarter-DMEK grafts (**Chapter 6**),[76]. The main distinctions in the experimental design were presence of TM that remained adhered to endothelium and cell motility study-period that was considerably longer than two weeks. Thus, it is possible that a particular cell type localized at the insert region of the TM required long-term culture before displaying the characteristics of undifferentiated cells. When cell viability was evaluated on outer graft rims with the late-onset cell population, the intensity of Calcein-AM signal varied over the sample wherein the lowest signal intensity corresponded to the cell population that had emerged from the far periphery of the endothelium. We suspect that this late-onset but fast growing cell population has a low intracellular esterase activity that does not signal damaged membranes but rather low-level expression of esterase-specific genes that serves as a

reliable indicator of undifferentiated cells.[93] Similar to our explant culture, Zhang et al.[94] demonstrated that cells proliferated from peripheral corneal areas with similar morphological characteristics during cell growth, timing, and end cell morphology. Furthermore, by using quantitative polymerase chain reaction (q-PCR), the cultured cells in their study were initially found to express increased levels of stem cell genes and minimal levels of pluripotency but these gene expression levels were reversed later during culture. The conclusion was that cells residing in the Schwalbe's ring region, a transition area between the peripheral corneal endothelium and the anterior non-filtering portion of the TM (collectively called the 'transition zone' [TZ]) displayed characteristics of adult stem cells.

Generally, these cells seem to form a distinct cell population in the transition area displaying distinct ultrastructural features and with a whorled-like pattern oriented circumferentially at the corneal periphery and deep to the corneal endothelium lining of the anterior chamber.[95] Although they were proposed to have neuroregulatory function in the anterior segment [96] they were also found responsible for the formation of an aberrant endothelial membrane covering the anterior uveal meshwork in some patients treated for glaucoma with argon laser trabeculoplasty (ALT).[97,98] In addition, increased cell density in the peripheral areas of the cornea compared to the central area (average range 17%–23%)[99] also suggests that stem-like cells may be present in the peripheral transition region to provide differentiated CEC. Also, it has been documented in the literature that under some circumstances mitosis occurs in the endothelium of the adult human cornea[100,101] and percentage of replication-competent cells is higher in the peripheral CEC than those in the central cornea, which was independent of donor age.[102] These findings suggest that peripheral CEC possess regenerative capacity and may be able to supply new cells for the corneal endothelium. Although molecular marker studies for the stem cell niche at the transition zone provide supportive data,[103,104] there has not been a stem cell signature established so far.[105] Also, attempts to isolate and propagate undifferentiated progenitor cells using a sphere culture protocol have proved to be more effective in isolating young precursor cells[106] from the peripheral corneal endothelium than the central region.[107–110] Therefore, it still remains to be determined if the Schwalbe's cells, TZ cells, and precursors are the same cell type, the extent to which they retain regenerative potential, and how cellular proliferation could be unlocked *in vivo* to repopulate corneal endothelium in age and disease.

Improving surgical technique by integrating *in vitro* cell culture observations

While trying to understand and promote EC migration from the peripheral cornea, the low postoperative ECD after Quarter-DMEK helped us to focus on continuous technique improvement. In an effort to address the significant ECD decrease after Quarter-DMEK,[8,10] which was thought to be caused by the shape mismatch between a round descemetorhexis and a triangular graft, a new surgical option was described, where small diameter DMEK grafts were prepared to match a small descemetorhexis and validated through a series of *in vitro* experimental conditions (**Chapter 8**). The main findings of this study were: (1) three circular mini-DMEK grafts with a diameter of 4 mm can be successfully prepared from one donor cornea, (2) the surgical procedure could be validated *in vitro*, and (3) small-diameter grafts embedded into a thermo-responsive hydrogel matrix showed uniform cell migration around the entire circular graft edge with cells displaying typical hexagonal close-packed morphology.[111] Similar to Quarter-DMEK, transplantation of a small-diameter graft offers the theoretical benefit of reduced donor antigen load and may allow using donor corneas with multiple incisional scars following cataract extraction. Initially, grafts as small as the 4 mm diameter (mini-DMEK) were reported to treat acute corneal hydrops in keratoconus (i.e., rupture and detachment of the stiff DM due to progressing ectasia of the corneal stroma).[112,113] Not only the shape and size of the DMEK grafts used to close the tear in the DM were not standardized (5 mm round DMEK graft or razor blade cut graft with a width of 3 mm and a length adjusted to the length of the tear in the recipients' DM) but also the orientation of the graft was not important for the surgery, presumably because the healthy host endothelium would easily repopulate the DM

even if the graft was accidentally inverted.[113] In a more recent study, Handel et al.[114] utilized mini-DMEK grafts to treat chronic focal corneal endothelial decompensation caused by tears in Descemet membrane after intraocular surgeries or corneal edema in the area of Haab striae in buphthalmus. Therefore, corneas were healthy and no disease except for the focal DM defect was present. The mini-DMEK grafts were trimmed from remaining DM to a width and a length equal to the length of the tear in the recipient's DM, while the central DM was used for patients with FECD. Although cornea deswelling was observed in all cases, the role of endothelial cells in small DM defects remained unclear.

It should also be noted that the small-diameter DMEK grafts have the potential to increase the use of one donor cornea to benefit three recipients only for treating mild FECD with guttae confined to the 4 mm central area. To avoid the 'no-touch' handling-related challenges of such small DMEK grafts, two alternative methods have been clinically tested so far, namely DSO and transplantation of acellular DM (i.e., Descemet membrane transplantation, DMT).[115–120] DSO represents a donor-independent strategy for central FECD, an approach that has already extensively been discussed in **Chapter 4**, while DMT represents a strategy for using non-clinical grade DMEK tissue. Although both techniques have the potential to treat FECD without the need for allogenic cell transplantation and fear of graft rejection, DMT provides an appropriate substrate that supports host endothelial cell migration with reduced risk for cells to enter endothelial-to-mesenchymal transition.[53] In addition, it seals the stroma to avoid keratocyte activation close to the wound space by the aqueous TGF-β,[121] that may lead to fibrosis and increased risk for retrocorneal membrane formation.[122,123] However, both DSO and DMT report a long recovery time with complete anatomical cornea restoration and visual rehabilitation not earlier than 3 months postoperatively.

Small diameter DMEK grafts showed great surgical feasibility with improved graft characteristics (i.e., ECD, graft viability, uniform cell migration capacity) and by having a matching shape to the circular descemetorhexis, clinical recovery could be similar to conventional DMEK. However, results of clinical tests would provide greater clarity about the efficiency of small diameter-DMEK grafts for treatment of mild FECD.

FUTURE PERSPECTIVES

DMEK is nowadays the gold standard for the treatment of corneal endothelial dysfunction. Since its introduction, DMEK has proved superior to PK and other keratoplasty techniques in terms of faster visual recovery, lower rejection rates, better refractive outcomes, and increased structural integrity.[124–128] Therefore, the number of DMEK procedures performed worldwide has increased, particularly, in patients with Fuchs endothelial corneal dystrophy (FECD).[129,130]

By only replacing the diseased tissue, DMEK embodies conceptual simplicity and surgical sophistication. Nonetheless, the main problem with endothelial keratoplasty is the chronic loss of endothelial cell density (ECD) over time which is similar to PK.[124,131,132] The effect of several donor- and patient-related parameters on endothelial cell loss has been evaluated in several studies in the literature, but with no consistent outcome.[15,133–140] However, the intraocular handling of the 15–20 µm thick membrane and the preoperative manual graft preparation represent technical challenges that may affect the final outcome.

We performed studies to better understand the postoperative ECD decline, as described in this thesis. One aspect regards the overestimation of graft viability in the eye bank,[30] which in turn results in an unrealistic high drop in ECD in the early postoperative phase after DMEK.[20] Grafts seem to develop pronounced endothelial cell damage even after an unremarkable preparation process, However, performing DMEK surgery using tissue with suboptimal endothelium quality could increase the risk of graft detachment and early graft failure.[14] While candidate fluorescent vital dyes can visualize life and apoptotic cells, regulatory and safety concerns as well as economic considerations may prevent eye banks from implementing such a step in their current protocol. One short-term solution could be to check the tissue quality just before releasing the graft for

transplantation. Although implementing this step might lead to an increase in the discard rate of already scarce tissue, it may result in a lower re-transplantation rate. An alternative strategy could be to improve the quality of donated corneas, by boosting the storage media with pharmacological modulators able to promote corneal endothelial regeneration and by maintaining a low level of oxidative stress. Furthermore, storing the cornea in a bioreactor, and not just free floating in a sealed bottle, could recreate the pressure gradient equivalent to intraocular pressure associated with a continuous renewal of storage medium, reduce stromal swelling, and therefore improve EC viability.[141,142] However, further research is needed to evaluate the safety of such storage methods and the therapeutical relevance of pharmaceutical agents.

In an effort to overcome tissue shortage, the use of Quarter-DMEK could potentially quadruple the pool of donor tissue. However, the technique may benefit from some further modification to improve ECD outcomes. *In vitro* studies on the endothelial cell migration included in this thesis showed that the round peripheral edge of the Quarte-DMEK graft will constitute a physical barrier for cell migration[68,76] unless progenitor-like cells, recently discovered in an area close to the limbus,[64] could be unlocked to induce sufficient corneal deturgescence. Also, by adapting the graft preparation protocol to eliminate the round peripheral edge of the Quarter-DMEK, small diameter-DMEK may provide a fast and uniform corneal clearance and become a viable clinical option to treat central endothelial disease.[111]

The limited numbers of high-quality corneal donors, and the surgical complexity of DMEK has promoted significant research interest in developing alternative techniques that either encourage a more efficient use of donor tissue or completely eliminate the need for implanting donor tissue.

To date, no better therapeutic alternatives are available for the treatment of diseased endothelium than corneal transplantation. However, current tissue engineering approaches for corneal replacement represent a promising avenue for clinical applications. To overcome cornea donor shortage, researchers have adopted two basic tissue-engineering approaches: a “cell-based” strategy to allow the cells to create their own extracellular matrix, and “scaffold-based” strategies to provide strong and biocompatible matrices upon which to grow cells.[143–146] Regardless of strategy, *in vitro* expansion or the *de novo* generation of corneal endothelial cells (CEC) from pluripotent stem cells or other cell sources is required.[147,148] The main challenge for the *in vitro* proliferation of terminally differentiated cells is to preserve their phenotype by avoiding endothelial-to-mesenchymal transition (EMT), which can cause CEC to lose their normal cell morphology and induce cell fibrosis. The alternative of differentiating CEC from pluripotent stem cells or other cell sources such as bone marrow-derived endothelial precursors, neural crest cells, corneal stromal stem cells, skin-derived precursors, or mesenchymal stem cells requires suitable culture protocols which have to comply with regulatory directives to guarantee that the final cell source resembles CEC.[148–154] While good manufacturing practice directives may differ depending on the country or region in which they are defined, there is an urgent need for standardization of endpoint parameters that generated CEC should fulfil. Therefore, the list of quality criteria should be reviewed for: (i) morphology assessment by checking cellular hexagonality upon reaching confluence in culture, (ii) genotype and phenotype by examining structural and functional markers, (iii) karyotype conservation by checking the integrity of the DNA to demonstrate the lack of gross chromosomal aberration, and (iv) functionality checked *in vitro* by tools that measure ion permeability across a monolayer of cells, *ex vivo* using corneas in a setting that mimics physiological conditions and allows the measurement of corneal thickness and further correlate to cell functionality, or *in vivo* using animal models of corneal edema.[155]

After facing all challenges with CEC culture in terms of cellular profile, proliferative capacity, and downstream analysis, cells must be delivered alive and with sufficient potential to adhere to the posterior part of the cornea. The “cell-based” strategy proposes the delivery of CEC in a simple and minimal invasive manner via injection into the anterior chamber of the eye.[155] After the procedure, placing the subject in a prone position for 3 hours allows gravity to increase the attachment of CEC to the posterior part of the cornea. The proof-of-concept clinical study by Kinoshita and associates demonstrated that corneal edema could be reversed by injecting about

$1x10^6$ cultured human CEC supplemented with ROCK inhibitor Y-27632 into the anterior chamber after mechanical scrapping of the diseased endothelium; corneal clarity was maintained at least 5 years postoperatively.[54,55] Additionally, the latest technique refinement suggests that injection therapy using highly purified mature cultured human CEC for corneal endothelial failure is safer, provides rapid recovery of corneal thickness, better ECD, and a low cell attrition rate over 3 years postsurgery.[156] However, larger, prospective, randomised controlled trials are required to ensure the long term efficacy and safety.

The main challenge for the "scaffold-based" strategy is to obtain a monolayer of CEC on a biocompatible carrier to produce bioengineered corneal endothelial grafts.[145] The use of a carrier that supports cell replication is an attractive approach because it has the added advantage of delivering a contact-inhibited and functional cell monolayer to the correct place and in a controlled manner. In addition, fewer cells are needed to populate the carrier compared to cell injection, thereby increasing the number of patients that could benefit. Assuming a surface area of 57 mm^2 (8.5 mm circular carrier) and a final ECD of 2300 cells/mm^2 (usual threshold value set up by eye banks), an endothelial graft should contain about 1.3×10^5 CEC. Based on a simple calculation, the expanded CECs used to treat 11 patients by cell injection could hypothetically populate 84 carriers and treat patients by a delivery strategy similar to DMEK or DSEK. However, an ideal cell carrier should mimic key architectural and functional features of the DM and therefore be dense, thick enough to provide sufficient mechanical strength, relatively transparent, semi-permeable to aqueous humour, flexible enough to mould to the curvature of the cornea, biocompatible, promote cell adhesion and phenotype, and maybe biodegradable to enables cells to produce their own DM while simultaneously degrading the surrounding scaffold. Many *in vitro* studies have reported promising research results when using either natural tissues such as decellulared biological membranes (e.g., amniotic membrane, denuded DM or stroma of both human and animal origin, human anterior lens capsule)[157–167] or polymeric materials (natural and synthetic).[161,168–192] Subsequent *in vivo* testing of tissue-engineered corneal endothelial cell-carrier sheets in animal models has, however, not proven any of the constructs suitable to progress into clinical practise.[160,193–195]

The option to eliminate the transplant altogether and allow a person's own endothelial cells to redistribute was introduced by Descemet stripping only (DSO) for the treatment of early FECD. In a primary analysis of DSO, the removal of a 6mm diameter area of the diseased DM led to an incomplete recovery.[116,196] Better clearance rates were reported where a smaller 4-5mm descemetorhexis was employed in selected cases of relatively young patients with central guttae and an adequate peripheral endothelial reserve.[116,197] Despite these limitations, DSO benefits from 0% rejection rate (no risk of immunologic graft rejection) and no need to use long term topical corticosteroids to prevent graft rejection thereby reducing the side effect of intraocular pressure elevation. However, DSO is not yet a replacement for DMEK for two primary reasons: clearing a smaller area may still lead to suboptimal vision, and corneal edema may persist for months hindering visual recovery, rendering its outcome unpredictable.[119] To improve its success, this technique may require the use of pharmacological modulators such as Rho-associated protein kinase (ROCK) inhibitors.[118] Although the biological action of ROCK-inhibitors is completely understood, they have been described to significantly speed up the visual recovery and induce higher central endothelial cell counts in a restored endothelium and with an improved cell architecture.[52] Therefore, DSO may be a suitable first-line surgical treatment option prior to DMEK or small diameter-DMEK, for those willing to try if stripping alone will resolve their vision problems. However, larger trials are still required to assess the effect of DSO in conjunction with pharmacological drugs on longer-term clinical efficacy and drug safety.

A potential hybrid technique between DSO and conventional, circular DMEK employs the use of endothelial graft substitutes comprising of tissue-derived or synthetic matrices.[120,198,199] Transplantation of an acellular DM into a patient has recently been reported as part of a larger clinical trial in Singapore [identification number NCT03275896]. The patient was transplanted with a 4 mm decellularized membrane and showed a four-line improvement in acuity 6 month after transplant, with near to normal restauration of central corneal

thickness and ECD values comparable to DSO.[120] Alternatively, a synthetic graft substitute (EndoArt) has been implanted to reverse corneal enema and promote sight recovery.[198] Attached to the back of the cornea, EndoArt should prevent the transfer of fluids into the cornea and inhibit the fluid accumulation leading to edema. A summary of the first results for two patients as part of a multi-center, prospective feasibility clinical study [identification number NCT03069521] showed that patients had a reduction of corneal edema with transparency recovery after EndoArt implantation. Limitations of implanting this synthetic construct include: (i) regular repositioning by rebubbling until complete adherence to the stromal bed, (ii) unclear timespan over which the cornea will remain transparent and properly hydrated, (iii) long-term effect of restricting diffusion of vitamin and essential nutrients from the aqueous humour to the cornea and (iv) inability of corneal endothelial cells to migrate and populate the artificial layer. Overall, natural-derived or engineered graft substitutes will still have to be evaluated in large clinical trials with long-term follow-up results to further determine their implementation success and also identify the right target populations.

Another strategy to increase corneal endothelial graft availability is to treat the genetic disorder by replacing the need for a corneal transplant. The current strategies able to correct the genetic alteration or avoid their associated effects are gene augmentation therapy (GAT), antisense oligonucleotide-based modulation (AON), and clustered regularly interspaced short palindromic repeats (CRISPR/Cas9)-based modulation.[200–205] It has also been reported that FED pathophysiology manifests through a combination of various genetic and non-heritable factors, such as channel dysfunction (e.g., solute carrier family 4 member 11 – SLC4A11), abnormal extracellular matrix deposition (e.g., collagen type VIII alpha 2 chain – COL8A2), RNA toxicity, oxidative stress (e.g., nuclear factor, erythroid 2 like 2 transcription factor – NRF2), and apoptosis (e.g., zinc finger e-box binding homeobox 1 – ZEB1).[206,207] The most common genetic alteration in FECD is a microsatellite region comprising CTG trinucleotide repeats (TNRs) in the fourth intron of the TCF4 gene to be abnormally expanded and segregated. While the genetic mechanism responsible for the effect of this trinucleotide expansion on the TCF4 gene is unclear, it will contribute to cellular dysfunction by triggering RNA mis-splicing. The genetic modulation of TCF4 expression is done either by transferring a functioning copy of this defective gene aimed to correct the disease, by introducing antisense oligonucleotides such as small interference RNA (siRNA) or micro-RNA (miRNA) that could diminish the toxic effects associated with the defective gene, or by eliminating the CTG expansion in order to revert the mutation causing FECD.[208–214] Further research is also needed to explore the immune tolerance towards the transgene products following repeated administration in the anterior eye chamber, find the most efficient and cost-effective delivery methods, and identity the off-target effects.

Over the past several years, the use of pharmaceutical agents for the treatment of corneal endothelial diseases has been explored.[35] The working principle relies on promoting cell survival, proliferation, and migration with a minimally invasive approach of intracameral or topical drug delivery. ROCK-inhibitors have been the most studied drugs with great potential to trigger CEC repair *in vivo* in humans when administrated topically as an adjuvant to DSO.[51,52] Worldwide clinical series report on ROCK-inhibitors success to reverse corneal edema after surgical removal of diseased CEC, restore corneal anatomy after partially detached DM in BK eyes after cataract surgery, and regenerate the corneal endothelium through a presumed increase in cell proliferation.[118,215–217] Also, promising research has been reported for other pharmaceutical drugs such as epidermal growth factor, platelet-derived growth factor, or fibroblast growth factors.[218–220] However, they should be administered with caution as they show a dual mechanism of action, i.e., regeneration potential with the risk of causing an undesired EMT. Attention has also been directed to reduce oxidative stress by upregulating transcription factors to promote the expression of antioxidative stress proteins thereby decreasing CEC apoptosis.[221–226] Also, profiling new drug candidates require a systematic examination of the functional effect in a variety of *in vitro* and *in vivo* assays. Furthermore, patient assignment in a clinical trial requires extensive knowledge on the diseases to be treated. In order to conclude any beneficial effects of the drug candidates mentioned above, it is mandatory to perform large, randomized control trials to generate higher level evidence.

Conclusive remarks

Despite significant progress towards therapies to promote corneal endothelial regeneration, there is still a long way before such therapies are approved by regulatory bodies and become routine clinical practice. To date, replacing the diseased endothelium by DMEK is still the most efficient treatment option for endothelial dysfunction, but the number of procedures is still restricted by a worldwide shortage of suitable and available human donors, especially in resource-poor parts of the world. Moreover, considering the COVID-19 pandemic, tissue exclusion criteria have become even more stringent, limiting considerably the pool of available donors.[227] It is essential to make the added value of the donation process clear to people, to have an incentive to register for donation because they are more likely to gain from the system than to contribute to it,[228–230] while in the meantime new treatment options are being developed and translated into clinical practice.

References

1. Tuft SJ, Coster DJ. The corneal endothelium. Eye (Lond). 1990;4 (Pt 3):389-424. https://doi.org/10.1038/eye.1990.53 PMID: 2209904
2. Wong KH, Kam KW, Chen LJ, Young AL. Corneal blindness and current major treatment concern-graft scarcity. Int J Ophthalmol. 2017 Jul 18;10(7):1154-1162. https://doi.org/10.18240/ijo.2017.07.21 PMID:28730122
3. Gain P, Jullienne R, He Z, Aldossary M, Acquart S, Cognasse F, et al. Global survey of corneal transplantation and eye banking. JAMA Ophthalmol. 2016 Feb;134(2):167-73. https://doi.org/10.1001/jamaophthalmol.2015.4776 PMID: 26633035
4. Lam FC, Baydoun L, Dirisamer M, Lie J, Dapena I, Melles GRJ. Hemi-Descemet membrane endothelial keratoplasty transplantation: a potential method for increasing the pool of endothelial graft tissue. JAMA Ophthalmol. 2014 Dec;132(12):1469-73. https://doi.org/10.1001/jamaophthalmol.2014.3328 PMID: 25211529
5. Birbal RS, Hsien S, Zygoura V, Parker JS, Ham L, van Dijk K, et al. Outcomes of Hemi-Descemet membrane endothelial keratoplasty for Fuchs endothelial corneal dystrophy. Cornea. 2018 Jul;37(7):854-858. https://doi.org/10.1097/ICO.0000000000001578 PMID: 29557816
6. Müller TM, Baydoun L, Melles GRJ. 3-Year update on the first case series of Hemi-Descemet membrane endothelial keratoplasty. Graefes Arch Clin Exp Ophthalmol. 2017 Jan;255(1):213-215. https://doi.org/10.1007/s00417-016-3517-5 PMID: 27783157
7. Baydoun L, Zygoura V, Hsien S, Birbal RS, Spinozzi D, Lie JT, et al. Clinical feasibility of using multiple grafts from a single donor for Quarter-DMEK. Acta Ophthalmol. 2018 Aug;96(5):e656-e658. https://doi.org/10.1111/aos.13720. PMID: 29498213
8. Zygoura V, Baydoun L, Ham L, Bourgonje VJA, van Dijk K, Lie JT. Quarter-Descemet membrane endothelial keratoplasty (Quarter-DMEK) for Fuchs endothelial corneal dystrophy: 6 months clinical outcome. Br J Ophthalmol. 2018 Oct;102(10):1425-1430. https://doi.org/10.1136/bjophthalmol-2017-311398 PMID: 29343529
9. Müller TM, Lavy I, Baydoun L, Lie JT, Dapena I, Melles GRJ. Case report of Quarter-Descemet membrane endothelial keratoplasty for Fuchs endothelial dystrophy. Cornea. 2017 Jan;36(1):104-107. https://doi.org/10.1097/ICO.0000000000001008 PMID: 27583798
10. Birbal RS, Ni Dhubhghaill S, Baydoun L, Ham L, Bourgonje VJA, Dapena I, et al. Quarter-Descemet membrane endothelial keratoplasty: one- to two-year clinical outcomes. Cornea. 2020 Mar;39(3):277-282. https://doi.org/10.1097/ICO.0000000000002127 PMID: 31490274
11. Català P, Thuret G, Skottman H, Mehta JS, Parekh M, Ní Dhubhghaill S, et al. Approaches for corneal endothelium regenerative medicine. Prog Retin Eye Res. 2022 Mar;87:100987. https://doi.org/10.1016/j.preteyeres.2021.100987 PMID: 34237411
12. Deng SX, Lee WB, Hammersmith KM, Kuo AN, Li JY, Shen JF, et al. Descemet membrane endothelial keratoplasty: safety and outcomes: a report by the American Academy of Ophthalmology. Ophthalmology. 2018 Feb;125(2):295-310. https://doi.org/10.1016/j.ophtha.2017.08.015 PMID: 28923499
13. Terry MA. Endothelial keratoplasty: why aren't we all doing Descemet membrane endothelial keratoplasty? Cornea. 2012 May;31(5):469-71. https://doi.org/10.1097/ICO.0b013e31823f8ee2 PMID: 22367047
14. Vasiliauskaitė I, Quilendrino R, Baydoun L, van Dijk K, Melles GRJ, Silke Oellerich. Effect of six-month postoperative endothelial cell density on graft survival after Descemet membrane endothelial keratoplasty. Ophthalmology. 2021 Dec;128(12):1689-1698. https://doi.org/10.1016/j.ophtha.2021.05.022 PMID: 34033824
15. Vasiliauskaitė I, Oellerich S, Ham L, Dapena I, Baydoun L, van Dijk K, et al. Descemet membrane endothelial keratoplasty: ten-year graft survival and clinical outcomes. Am J Ophthalmol. 2020 Sep;217:114-120. https://doi.org/10.1016/j.ajo.2020.04.005 PMID: 32283096
16. Calvo-de-Mora MR, Quilendrino R, Ham L, Liarakos VS, van Dijk K, Baydoun L, et al. Clinical outcome of 500 consecutive cases undergoing Descemet's membrane endothelial keratoplasty. Ophthalmology. 2015 Mar;122(3):464-70. https://doi.org/10.1016/j.ophtha.2014.09.004 PMID: 25439596
17. Ham L, Dapena I, Liarakos VS, Baydoun L, van Dijk K, Ilyas A, et al. Midterm results of Descemet membrane endothelial keratoplasty: 4 to 7 years clinical outcome. Am J Ophthalmol. 2016 Nov;171:113-121. https://doi.org/10.1016/j.ajo.2016.08.038 PMID: 27609712
18. Hayashi T, Schrittenlocher S, Siebelmann S, Le VNH, Matthaei M, Franklin J, et al. Risk factors for endothelial cell loss after Descemet membrane endothelial keratoplasty (DMEK). Sci Rep. 2020 Jul 6;10(1):11086. https://doi.org/10.1038/s41598-020-68023-0 PMID: 32632151

19. Quilendrino R, Höhn H, Tse WHW, Chi H, Dapena I, Ham L, et al. Do we overestimate the endothelial cell "loss" after Descemet membrane endothelial keratoplasty? Curr Eye Res. 2013 Feb;38(2):260-5. https://doi.org/10.3109/02713683.2012.753095 PMID: 23294140
20. Miron A, Bruinsma M, Ham L, Schaal SC, Baydoun L, Dapena I, et al. *In vivo* endothelial cell density decline in the early postoperative phase after Descemet membrane endothelial keratoplasty. Cornea. 2018 Jun;37(6):673-677. https://doi.org/10.1097/ICO.0000000000001484 PMID: 29737973
21. Dirisamer M, Dapena I, Ham L, van Dijk K, Oganes O, Frank LE, et al. Patterns of corneal endothelialization and corneal clearance after Descemet membrane endothelial keratoplasty for Fuchs endothelial dystrophy. Am J Ophthalmol. 2011 Oct;152(4):543-555.e1. https://doi.org/10.1016/j.ajo.2011.03.031 PMID: 21726849
22. Qazi Y, Hamrah P. Corneal allograft rejection: immunopathogenesis to therapeutics. J Clin Cell Immunol. 2013 Nov 20;2013(Suppl 9):006. https://doi.org/10.4172/2155-9899.S9-006 PMID: 24634796
23. Parekh M, Borroni D, Ruzza A, Levis HJ, Ferrari S, Ponzin D, et al. A comparative study on different Descemet membrane endothelial keratoplasty graft preparation techniques. Acta Ophthalmol. 2018 Sep;96(6):e718-e726. https://doi.org/10.1111/aos.13746 PMID: 29520992
24. Tran KD, Alabi RO, Odell K, Dye PK, Downes K, Sales CS. Measuring endothelial cell loss on DMEK grafts after transplantation in human cadaveric whole eyes: Description of the technique and pilot study. Cornea. 2018 Aug;37(8):1075-1080. https://doi.org/10.1097/ICO.0000000000001602 PMID: 29634671
25. Bhogal M, Balda MS, Matter K, Allan BD. Global cell-by-cell evaluation of endothelial viability after two methods of graft preparation in Descemet membrane endothelial keratoplasty. Br J Ophthalmol. 2016 Apr;100(4):572-8. https://doi.org/10.1136/bjophthalmol-2015-307534 PMID: 26740609
26. Borroni D, Gadhvi K, Wojcik G, Pennisi F, Vallabh NA, Galeone A. The Influence of Speed During Stripping in Descemet Membrane Endothelial Keratoplasty Tissue Preparation. Cornea. 2020 Sep;39(9):1086-1090. https://doi.org/10.1097/ICO.0000000000002338 PMID: 32301812
27. Downes K, Tran KD, Stoeger CG, Chamberlain W. Cumulative endothelial cell loss in Descemet membrane endothelial keratoplasty grafts from preparation through insertion with glass injectors. Cornea. 2018 Jun;37(6):698-704. https://doi.org/10.1097/ICO.0000000000001588 PMID: 29561351
28. Bhogal M, Lwin CN, Seah XY, Murugan E, Adnan K, Lin SJ. Real-time assessment of corneal endothelial cell damage following graft preparation and donor insertion for DMEK. PLoS One. 2017 Oct 4;12(10):e0184824. https://doi.org/10.1371/journal.pone.0184824 PMID: 28977017
29. Birbal RS, Sikder S, Lie JT, Groeneveld-van Beek EA, Oellerich S, Melles GRJ. Donor tissue preparation for Descemet membrane endothelial keratoplasty: an updated review. Cornea. 2018 Jan;37(1):128-135. https://doi.org/10.1097/ICO.0000000000001368 PMID: 28990995
30. Miron A, Sajet A, Groeneveld-van Beek EA, Kok JS, Dedeci M, de Jong M, et al. Endothelial cell viability after DMEK graft preparation. Curr Eye Res. 2021 Nov;46(11):1621-1630. https://doi.org/10.1080/02713683.2021.1927111 PMID: 34027768
31. Papadopoulos NG, Dedoussis GV, Spanakos G, Gritzapis AD, Baxevanis CN, Papamichail M. An improved fluorescence assay for the determination of lymphocyte-mediated cytotoxicity using flow cytometry. J Immunol Methods. 1994 Dec 28;177(1-2):101-11. https://doi.org/10.1016/0022-1759(94)90147-3 PMID: 7822816
32. Suuronen EJ, McLaughlin CR, Stys PK, Nakamura M, Munger R, Griffith M. Functional innervation in tissue engineered models for *in vitro* study and testing purposes. Toxicol Sci. 2004 Dec;82(2):525-33. https://doi.org/10.1093/toxsci/kfh270 PMID: 15342958
33. Banfalvi G. Methods to detect apoptotic cell death. Apoptosis. 2017 Feb;22(2):306-323. https://doi.org/10.1007/s10495-016-1333-3 PMID: 28035493
34. Gatti R, Belletti S, Orlandini G, Bussolati O, Dall'Asta V, Gazzola GC. Comparison of annexin V and calcein-AM as early vital markers of apoptosis in adherent cells by confocal laser microscopy. J Histochem Cytochem. 1998 Aug;46(8):895-900. https://doi.org/10.1177/002215549804600804 PMID: 9671440
35. Vercammen H, Miron A, Oellerich S, Melles GRJ, Ní Dhubhghaill S, Koppen C, et al. Corneal endothelial wound healing: understanding the regenerative capacity of the innermost layer of the cornea. Transl Res. 2022 May 21:S1931-5244(22)00114-1. https://doi.org/10.1016/j.trsl.2022.05.003 PMID: 35609782.
36. Maurizi E, Schiroli D, Zini R, Limongelli A, Mistò R, Macaluso C. A fine-tuned β-catenin regulation during proliferation of corneal endothelial cells revealed using proteomics analysis. Sci Rep. 2020 Aug 14;10(1):13841. https://doi.org/10.1038/s41598-020-70800-w PMID: 32796906

37. Joyce NA. Cell cycle status in human corneal endothelium. Exp Eye Res. 2005 Dec;81(6):629-38. https://doi.org/10.1016/j.exer.2005.06.012 PMID: 16054624
38. Kikuchi M, Zhu C, Senoo T, Obara Y, Joyce NC. p27kip1 siRNA induces proliferation in corneal endothelial cells from young but not older donors. Invest Ophthalmol Vis Sci. 2006 Nov;47(11):4803-9. https://doi.org/10.1167/iovs.06-0521 PMID: 17065491
39. Lee HT, Kay EDP. Regulatory role of cAMP on expression of Cdk4 and p27(Kip1) by inhibiting phosphatidylinositol 3-kinase in corneal endothelial cells. Invest Ophthalmol Vis Sci. 2003 Sep;44(9):3816-25. https://doi.org/10.1167/iovs.03-0147 PMID: 12939297
40. Ando K, Fukuhara S, Moriya T, Obara Y, Nakahata N, Mochizuki N. Rap1 potentiates endothelial cell junctions by spatially controlling myosin II activity and actin organization. J Cell Biol. 2013 Sep 16;202(6):901-16. https://doi.org/10.1083/jcb.201301115 PMID: 24019534
41. Coleman ML, Marshall CJ, Olson MF. RAS and RHO GTPases in G1-phase cell-cycle regulation. Nat Rev Mol Cell Biol. 2004 May;5(5):355-66. https://doi.org/10.1038/nrm1365 PMID: 15122349
42. Lee JG, Kay EDP. FGF-2-induced wound healing in corneal endothelial cells requires Cdc42 activation and Rho inactivation through the phosphatidylinositol 3-kinase pathway. Invest Ophthalmol Vis Sci. 2006 Apr;47(4):1376-86. https://doi.org/10.1167/iovs.05-1223 PMID: 16565371
43. Roovers K, Klein EA, Castagnino P, Assoian RK. Nuclear translocation of LIM kinase mediates Rho-Rho kinase regulation of cyclin D1 expression. Dev Cell. 2003 Aug;5(2):273-84. https://doi.org/10.1016/s1534-5807(03)00206-5 PMID: 12919678
44. Roberts AB, Tian F, Byfield SDC, Stuelten C, Ooshima A, Saika S, et al. Smad3 is key to TGF-beta-mediated epithelial-to-mesenchymal transition, fibrosis, tumor suppression and metastasis. Cytokine Growth Factor Rev. 2006 Feb-Apr;17(1-2):19-27. https://doi.org/10.1016/j.cytogfr.2005.09.008 PMID: 16290023
45. Saika S. TGFbeta pathobiology in the eye. Lab Invest. 2006 Feb;86(2):106-15. https://doi.org/10.1038/labinvest.3700375 PMID: 16341020
46. Itoh S, ten Dijke P. Negative regulation of TGF-beta receptor/Smad signal transduction. Curr Opin Cell Biol. 2007 Apr;19(2):176-84. https://doi.org/10.1016/j.ceb.2007.02.015 PMID: 17317136
47. Massagué J, Gomis RR. The logic of TGFbeta signaling. FEBS Lett. 2006 May 22;580(12):2811-20. https://doi.org/10.1016/j.febslet.2006.04.033 PMID: 16678165
48. Byfield SDC, Roberts AB. Lateral signaling enhances TGF-beta response complexity. Trends Cell Biol. 2004 Mar;14(3):107-11. https://doi.org/10.1016/j.tcb.2004.01.001 PMID: 15055198
49. Mimura T, Yamagami S, Amano S. Corneal endothelial regeneration and tissue engineering. Prog Retin Eye Res. 2013 Jul;35:1-17. https://doi.org/10.1016/j.preteyeres.2013.01.003 PMID: 23353595
50. Landshman N, Solomon A, Belkin M. Cell division in the healing of the corneal endothelium of cats. Arch Ophthalmol. 1989 Dec;107(12):1804-8. https://doi.org/10.1001/archopht.1989.01070020886032 PMID: 2597071
51. Macsai MS, Shiloach M. Use of topical Rho kinase inhibitors in the treatment of Fuchs dystrophy after Descemet stripping only. Cornea. 2019 May;38(5):529-534. https://doi.org/10.1097/ICO.0000000000001883 PMID:30720541
52. Davies E, Jurkunas U, Pineda R. Pilot study of corneal clearance with the use of a Rho-kinase inhibitor after descemetorhexis without endothelial keratoplasty for Fuchs endothelial corneal dystrophy. Cornea. 2021 Jul 1;40(7):899-902. https://doi.org/10.1097/ICO.0000000000002691 PMID: 33758139
53. Soh YQ, Peh G, George BL, Seah XY, Primalani NK, Adnan K, et al. Predicative factors for corneal endothelial cell migration. Invest Ophthalmol Vis Sci. 2016 Feb;57(2):338-48. https://doi.org/10.1167/iovs.15-18300 PMID: 26842752
54. Kinoshita S, Koizumi N, Ueno M, Okumura N, Imai K, Tanaka H, et al. Injection of Cultured Cells with a ROCK Inhibitor for Bullous Keratopathy. N Engl J Med. 2018 Mar 15;378(11):995-1003. https://doi.org/10.1056/NEJMoa1712770 PMID: 29539291
55. Numa K, Imai K, Ueno M, Kitazawa K, Tanaka H, John D Bush JD, et al. Five-year follow-up of first 11 patients undergoing injection of cultured corneal endothelial cells for corneal endothelial failure. Ophthalmology. 2021 Apr;128(4):504-514. https://doi.org/10.1016/j.ophtha.2020.09.002 PMID: 32898516
56. Ichijima H, Petroll WM, Jester JV, Barry PA, Andrews PM, Dai M, et al. *In vivo* confocal microscopic studies of endothelial wound healing in rabbit cornea. Cornea. 1993 Sep;12(5):369-78. https://doi.org/10.1097/00003226-199309000-00001 PMID: 8306656
57. Miyamoto T, Sumioka T, Saika S. Endothelial mesenchymal transition: a therapeutic target in retrocorneal membrane. Cornea. 2010 Nov;29 Suppl 1:S52-6. https://doi.org/10.1097/ICO.0b013e3181efe36a PMID: 20935543

58. Sumioka T, Ikeda K, Okada Y, Yamanaka O, Kitano A, Saika S. Inhibitory effect of blocking TGF-beta/Smad signal on injury-induced fibrosis of corneal endothelium. Mol Vis. 2008;14:2272-81. PMID: 19081766
59. Funaki T, Nakao A, Ebihara N, Setoguchi Y, Fukuchi Y, Okumura Ko, et al. Smad7 suppresses the inhibitory effect of TGF-beta2 on corneal endothelial cell proliferation and accelerates corneal endothelial wound closure *in vitro*. Cornea. 2003 Mar;22(2):153-9. https://doi.org/10.1097/00003226-200303000-00015 PMID: 12605052
60. Choi SO, Jeon HS, Hyon JY, Oh YJ, Wee WR, Chung TY, et al. Recovery of corneal endothelial cells from periphery after injury. PLoS One. 2015 Sep 17;10(9):e0138076. https://doi.org/10.1371/journal.pone.0138076 PMID: 26378928
61. Ying LY, Qiu WY, Wang BH, Zhou P, Zhang B, Yao YF. Corneal endothelial regeneration in human eyes using endothelium-free grafts. BMC Ophthalmol. 2022 Jan 21;22(1):32. https://doi.org/10.1186/s12886-022-02260-x PMID: 35062892
62. Dirisamer M, Ham L, Dapena I, van Dijk K, Melles GRJ. Descemet membrane endothelial transfer: "free-floating" donor Descemet implantation as a potential alternative to "keratoplasty". Cornea. 2012 Feb;31(2):194-7. https://doi.org/10.1097/ICO.0b013e31821c9afc PMID: 22146548
63. Balachandran C, Ham L, Verschoor CA, Ong TS, van der Wees J, Melles GRJ. Spontaneous corneal clearance despite graft detachment in Descemet membrane endothelial keratoplasty. Am J Ophthalmol. 2009 Aug;148(2):227-234.e1. https://doi.org/10.1016/j.ajo.2009.02.033. PMID:19442962
64. Yam GHF, Seah X, Yusoff NZBM, Setiawan M, Wahlig S, Htoon HM, et al. Characterization of Human Transition Zone Reveals a Putative Progenitor-Enriched Niche of Corneal Endothelium. Cells. 2019 Oct 12;8(10):1244. https://doi.org/10.3390/cells8101244 PMID: 31614883
65. He Z, Campolmi N, Gain P, Thi BMH, Dumollard JM, Duband S, et al. Revisited microanatomy of the corneal endothelial periphery: new evidence for continuous centripetal migration of endothelial cells in humans. Stem Cells. 2012 Nov;30(11):2523-34. https://doi.org/10.1002/stem.1212 PMID: 22949402
66. van Beek EAG, Lie JT, van der Wees J, Bruinsma M, Melles GRJ. Standardized 'no-touch' donor tissue preparation for DALK and DMEK: harvesting undamaged anterior and posterior transplants from the same donor cornea. Acta Ophthalmol. 2013 Mar;91(2):145-50. https://doi.org/10.1111/j.17553768.2012.02462.x PMID: 22672202
67. Lie JT, Birbal R, Ham L, van der Wees J, Melles GRJ. Donor tissue preparation for Descemet membrane endothelial keratoplasty. J Cataract Refract Surg. 2008 Sep;34(9):1578-83. https://doi.org/10.1016/j.jcrs.2008.05.036 PMID: 18721723
68. Miron A, Spinozzi D, Bruinsma M, Lie JT, Birbal RS, Baydoun L, et al. Asymmetrical endothelial cell migration from *in vitro* Quarter-Descemet membrane endothelial keratoplasty grafts. Acta Ophthalmol. 2018 Dec;96(8):828-833. https://doi.org/10.1111/aos.13841 PMID: 30171674
69. Konomi K, Joyce NC. Age and topographical comparison of telomere lengths in human corneal endothelial cells. Mol Vis. 2007 Jul 23;13:1251-8. PMID: 17679950
70. Egan CA, Train IS, Shay JW, Wilson SE, Bourne WM. Analysis of telomere lengths in human corneal endothelial cells from donors of different ages. Invest Ophthalmol Vis Sci. 1998 Mar;39(3):648-53. PMID: 9501879
71. Kataoka K, Huh N. Application of a thermo-reversible gelation polymer, Mebiol gel, for stem cell culture and regenerative medicine. J Stem Cells Regen Med. 2010 Apr 5;6(1):10-4. https://doi.org/10.46582/jsrm.0601003 PMID: 24693055
72. Sudha B, Madhavan HN, Sitalakshmi G, Malathi J, Krishnakumar S, Mori Y, Yoshioka H, et al. Cultivation of human corneal limbal stem cells in Mebiol gel--A thermo-reversible gelation polymer. Indian J Med Res. 2006 Dec;124(6):655-64. PMID: 17287553
73. Bray LJ, Binner M, Holzheu A, Friedrichs J, Freudenberg U, Hutmacher DW, et al. Multi-parametric hydrogels support 3D *in vitro* bioengineered microenvironment models of tumour angiogenesis. Biomaterials. 2015;53:609-20. https://doi.org/10.1016/j.biomaterials.2015.02.124 PMID: 25890757
74. Jooybar E, Abdekhodaie MJ, Alvi M, Mousavi A, Karperien M, Dijkstra PJ. An injectable platelet lysate-hyaluronic acid hydrogel supports cellular activities and induces chondrogenesis of encapsulated mesenchymal stem cells. Acta Biomater. 2019 Jan 1;83:233-244. https://doi.org/10.1016/j.actbio.2018.10.031 PMID: 30366137
75. Miron A, Spinozzi D, Lie J, Melles GR, Oellerich S, Ni Dhubhghaill S. Improving endothelial explant tissue culture by novel thermoresponsive cell culture system. Curr Eye Res. 2021 Mar;46(3):290-293. https://doi.org/10.1080/02713683.2020.1798468 PMID: 32727221

76. Miron A, Spinozzi D, Ní Dhubhghaill S, Lie JT, Oellerich S, Melles GRJ. *In vitro* endothelial cell migration from limbal edge-modified Quarter-DMEK grafts. PLoS One. 2019 Nov 20;14(11):e0225462. https://doi.org/10.1371/journal.pone.0225462 PMID: 31747441
77. Maruthamuthu V, Schaus YA, Gardel ML. Conserved F-actin dynamics and force transmission at cell adhesions. Curr Opin Cell Biol. 2010 Oct;22(5):583-8. https://doi.org/10.1016/j.ceb.2010.07.010 PMID: 20728328
78. Gardel ML, Sabass B, Ji L, Danuser G, Schwarz US, Waterman CM. Traction stress in focal adhesions correlates biphasically with actin retrograde flow speed. J Cell Biol. 2008 Dec 15;183(6):999-1005. https://doi.org/10.1083/jcb.200810060 PMID: 19075110
79. Schoenwaelder SM, Burridge K. Bidirectional signaling between the cytoskeleton and integrins. Curr Opin Cell Biol. 1999 Apr;11(2):274-86. https://doi.org/10.1016/s0955-0674(99)80037-4 PMID: 10209151
80. Small JV, Rottner K, Kaverina I, Anderson KI. Assembling an actin cytoskeleton for cell attachment and movement. Biochim Biophys Acta. 1998 Sep 16;1404(3):271-81. https://doi.org/10.1016/s0167-4889(98)00080-9 PMID: 9739149
81. Heath JP, Holifield BF. On the mechanisms of cortical actin flow and its role in cytoskeletal organisation of fibroblasts. Symp Soc Exp Biol. 1993;47:35-56. PMID: 8165576
82. Trepat X, Chen Z, Jacobson K. Cell migration. Compr Physiol. 2012 Oct;2(4):2369-92. https://doi.org/10.1002/cphy.c110012 PMID: 23720251
83. Gaggioli C, Hooper S, Carcedo CH, Grosse R, Marshall JF, Harrington K, et al. Fibroblast-led collective invasion of carcinoma cells with differing roles for Rho GTPases in leading and following cells. Nat Cell Biol. 2007 Dec;9(12):1392-400. https://doi.org/10.1038/ncb1658 PMID: 18037882
84. Wolf K, Wu YI, Liu Y, Geiger J, Tam E, Overall C, et al. Multi-step pericellular proteolysis controls the transition from individual to collective cancer cell invasion. Nat Cell Biol. 2007 Aug;9(8):893-904. https://doi.org/10.1038/ncb1616 PMID: 17618273
85. Tavella S, Bellese G, Castagnola P, Martin I, Piccini D, Doliana R, et al. Regulated expression of fibronectin, laminin and related integrin receptors during the early chondrocyte differentiation. J Cell Sci. 1997 Sep;110 (Pt 18):2261-70. https://doi.org/10.1242/jcs.110.18.2261 PMID: 9378775
86. Edwards DC, Sanders LC, Bokoch GM, Gill GN. Activation of LIM-kinase by Pak1 couples Rac/Cdc42 GTPase signalling to actin cytoskeletal dynamics. Nat Cell Biol. 1999 Sep;1(5):253-9. https://doi.org.10.1038/12963 PMID: 10559936
87. Hall A. Rho GTPases and the actin cytoskeleton. Science. 1998 Jan 23;279(5350):509-14. https://doi.org/10.1126/science.279.5350.509 PMID: 9438836
88. Cort JH, Sedláková E, I Kluh. Neurophysin binding and naturiuretic peptides from the posterior pituitary. Ann N Y Acad Sci. 1975 Feb 21;248:336-44. https://doi.org/10.1111/j.1749-6632.1975.tb34196.x PMID: 1054550
89. Linder S. The matrix corroded: podosomes and invadopodia in extracellular matrix degradation. Trends Cell Biol. 2007 Mar;17(3):107-17. https://doi.org/10.1016/j.tcb.2007.01.002 PMID: 17275303
90. Ram SE, Doyle AD, Conti MA, Matsumoto K, Adelstein RS, Yamada KM. Myosin IIA regulates cell motility and actomyosin-microtubule crosstalk. Nat Cell Biol. 2007 Mar;9(3):299-309. https://doi.org/10.1038/ncb1540 PMID: 17310241
91. Manzanares MV, Zareno J, Whitmore L, Choi CK, Horwitz AF. Regulation of protrusion, adhesion dynamics, and polarity by myosins IIA and IIB in migrating cells. J Cell Biol. 2007 Feb 26;176(5):573-80. https://doi.org/10.1083/jcb.200612043 PMID: 17312025
92. Pipparelli A, Arsenijevic Y, Thuret G, Gain P, Nicolas M, Majo F. ROCK Inhibitor enhances adhesion and wound healing of human corneal endothelial cells. PLoS ONE 8(4): e62095. https://doi.org/10.1371/journal.pone.0062095 PMID: 23626771
93. Pamies D, Reig JA, Vilanova E, Sogorb MA. Expression of Neuropathy Target Esterase in mouse embryonic stem cells during differentiation. Arch Toxicol. 2010 Jun;84(6):481-91. https://doi.org/10.1007/s00204-010-0518-8 PMID: 20112100
94. Zhang J, Ahmad AM, Ng H, Shi J, McGhee CNJ, Patel DV. Successful culture of human transition zone cells. Clin Exp Ophthalmol. 2020 Jul;48(5):689-700. https://doi.org/10.1111/ceo.13756 PMID: 32249477
95. Raviola G. Schwalbe line's cells: a new cell type in the trabecular meshwork of Macaca mulatta. Invest Ophthalmol Vis Sci. 1982 Jan;22(1):45-56. PMID: 7056624
96. Stone RA, Kuwayama Y, Laties AM, Marangos PJ. Neuron-specific enolase-containing cells in the rhesus monkey trabecular meshwork. Invest Ophthalmol Vis Sci. 1984 Nov;25(11):1332-4. PMID: 6490334.

97. Rodrigues MM, Spaeth GL, Donohoo P. Electron microscopy of argon laser therapy in phakic open-angle glaucoma. Ophthalmology. 1982 Mar;89(3):198-210. https://doi.org/10.1016/s0161-6420(82)34806-x PMID: 7088502
98. Alexander RA, Grierson I. Morphological effects of argon laser trabeculoplasty upon the glaucomatous human meshwork. Eye (Lond). 1989;3 (Pt 6):719-26. https://doi.org/10.1038/eye.1989.111 PMID: 2630352
99. Amann J, Holley GP, Lee SB, Edelhauser HF. Increased endothelial cell density in the paracentral and peripheral regions of the human cornea. Am J Ophthalmol. 2003 May;135(5):584-90. https://doi.org/10.1016/s0002-9394(02)02237-7 PMID: 12719063
100. Laing RA, Neubauer L, Oak SS, Kayne HL, Leibowitz HM. Evidence for mitosis in the adult corneal endothelium. Ophthalmology. 1984 Oct;91(10):1129-34. https://doi.org/10.1016/s0161-6420(84)34176-8 PMID: 6392976
101. Treffers WF. Human corneal endothelial wound repair. *In vitro* and *in vivo*. Ophthalmology. 1982 Jun;89(6):605-13. https://doi.org/10.1016/s0161-6420(82)34757-0 PMID: 6181449.
102. Mimura T, Joyce NC. Replication competence and senescence in central and peripheral human corneal endothelium. Invest Ophthalmol Vis Sci. 2006 Apr;47(4):1387-96 https://doi.org/10.1167/iovs.05-1199 PMID: 16565372
103. Whikehart DR, Parikh CH, Vaughn AV, Mishler K, Edelhauser HF. Evidence suggesting the existence of stem cells for the human corneal endothelium. Mol Vis. 2005 Sep 26;11:816-24. PMID: 16205623
104. Kelley MJ, Rose AY, Keller KE, Hessle H, Samples JR, Acott TS. Stem cells in the trabecular meshwork: present and future promises. Exp Eye Res. 2009 Apr;88(4):747-51. https://doi.org/10.1016/j.exer.2008.10.024 PMID: 19061887
105. Braunger BM, Ademoglu B, Koschade SE, Fuchshofer R, Gabelt BT, Kiland JA, et al. Identification of adult stem cells in Schwalbe's line region of the primate eye. Invest Ophthalmol Vis Sci. 2014 Oct 16;55(11):7499-507. https://doi.org/10.1167/iovs.14-14872 PMID: 25324280
106. Mimura T, Yamagami S, Yokoo S, Usui T, Amano S. Selective isolation of young cells from human corneal endothelium by the sphere-forming assay. Tissue Eng Part C Methods. 2010 Aug;16(4):803-12. https://doi.org/10.1089/ten.TEC.2009.0608 PMID: 19852617
107. Yokoo S, Yamagami S, Yanagi Y, Uchida S, Mimura T, Usui T, et al. Human corneal endothelial cell precursors isolated by sphere-forming assay. Invest Ophthalmol Vis Sci. 2005 May;46(5):1626-31. https://doi.org/10.1167/iovs.04-1263 PMID: 15851561
108. Mimura T, Yamagami S, Yokoo S, Araie M, Amano S. Comparison of rabbit corneal endothelial cell precursors in the central and peripheral cornea. Invest Ophthalmol Vis Sci. 2005 Oct;46(10):3645-8. https://doi.org/10.1167/iovs.05-0630 PMID: 16186345
109. Amano S, Yamagami S, Mimura T, Uchida S, Yokoo S. Corneal stromal and endothelial cell precursors. Cornea. 2006 Dec;25(10 Suppl 1):S73-7. https://doi.org/10.1097/01.ico.0000247218.10672.7e PMID: 17001199
110. Yamagami S, Yokoo S, Mimura T, Takato T, Araie M, Amano S. Distribution of precursors in human corneal stromal cells and endothelial cells. Ophthalmology. 2007 Mar;114(3):433-9. https://doi.org/10.1016/j.ophtha.2006.07.042 PMID: 17324693
111. Ní Dhubhghaill S, Miron A, Lie JT, Dapena I, Oellerich S, Melles GRJ. Preclinical testing of small diameter Descemet membrane endothelial keratoplasty grafts to increase tissue availability. PLoS One. 2021 Feb 4;16(2):e0246516. https://doi.org/10.1371/journal.pone.0246516 PMID: 33539395
112. Bachmann B, Händel A, Siebelmann S, Matthaei M, Cursiefen C. Mini-Descemet membrane endothelial keratoplasty for the early treatment of acute corneal hydrops in Keratoconus. Cornea. 2019 Aug;38(8):1043-1048. https://doi.org/10.1097/ICO.0000000000002001 PMID: 31276462
113. Tu EY. Descemet membrane endothelial keratoplasty patch for persistent corneal hydrops. Cornea. 2017 Dec;36(12):1559-1561. https://doi.org/10.1097/ICO.0000000000001351 PMID: 28872520
114. Händel A, Siebelmann S, Matthaei M, Cursiefen C, Bachmann B. Mini-DMEK for the treatment of chronic focal corneal endothelial decompensation. Cornea: July 5, 2022. https://doi.org/10.1097/ICO.0000000000003048
115. Moloney G, Chan UT, Hamilton A, Zahidin AM, Grigg JR, Devasahayam RN. Descemetorhexis for Fuchs' dystrophy. Can J Ophthalmol. 2015 Feb;50(1):68-72. https://doi.org/10.1016/j.jcjo.2014.10.014 PMID: 25677286
116. Borkar DS, Veldman P, Colby KA. Treatment of Fuchs Endothelial Dystrophy by Descemet Stripping Without Endothelial Keratoplasty. Cornea. 2016 Oct;35(10):1267-73. https://doi.org/10.1097/ICO.0000000000000915 PMID: 27310885
117. Iovieno A, Neri A, Soldani AM, Adani C, Fontana L. Descemetorhexis without graft placement for the treatment of Fuchs endothelial dystrophy: preliminary results and review of the literature. Cornea. 2017 Jun;36(6):637-641. https://doi.org/10.1097/ICO.0000000000001202 PMID: 28410355

118. Moloney G, Petsoglou C, Ball M, Kerdraon Y, Höllhumer R, Spiteri N, et al. Descemetorhexis without grafting for Fuchs endothelial dystrophy-supplementation with topical ripasudil. Cornea. 2017 Jun;36(6):642-648. https://doi.org/10.1097/ICO.0000000000001209 PMID: 28476048
119. Garcerant D, Hirnschall N, Toalster N, Zhu M, Wen L, Moloney G. Descemet's stripping without endothelial keratoplasty. Curr Opin Ophthalmol. 2019 Jul;30(4):275-285. https://doi.org/10.1097/ICU.0000000000000579 PMID: 31033737
120. Soh YQ, Mehta JS. Regenerative therapy for Fuchs endothelial corneal dystrophy. Cornea. 2018 Apr;37(4):523-527. https://doi.org/10.1097/ICO.0000000000001518 PMID: 29384808
121. Chen J, Li Z, Zhang L, Ou S, Wang Y, He X, et al. Descemet's membrane supports corneal endothelial cell regeneration in rabbits. Sci Rep. 2017 Aug 1;7(1):6983. https://doi.org/10.1038/s41598-017-07557-2 PMID: 28765543
122. Wunderlich K, Senn BC, Reiser P, Pech M, Flammer J, Meyer P. Connective tissue growth factor in retrocorneal membranes and corneal scars. Ophthalmologica. 2000 Sep-Oct;214(5):341-6. https://doi.org/10.1159/000027517 PMID: 10965248
123. Maycock NJ, Marshall J. Genomics of corneal wound healing: a review of the literature. Acta Ophthalmol. 2014 May;92(3):e170-84. https://doi.org/10.1111/aos.12227 PMID: 23819758
124. Heinzelmann S, Böhringer D, Eberwein P, Reinhard T, Maier P. Outcomes of Descemet membrane endothelial keratoplasty, Descemet stripping automated endothelial keratoplasty and penetrating keratoplasty from a single centre study. Graefes Arch Clin Exp Ophthalmol. 2016 Mar;254(3):515-22. https://doi.org/10.1007/s00417-015-3248-z PMID: 26743748
125. Melles GR. Posterior lamellar keratoplasty: DLEK to DSEK to DMEK. Cornea. 2006 Sep;25(8):879-81. https://doi.org/10.1097/01.ico.0000243962.60392.4f PMID: 17102659
126. Dapena I, Ham L, Melles GR. Endothelial keratoplasty: DSEK/DSAEK or DMEK--the thinner the better? Curr Opin Ophthalmol. 2009 Jul;20(4):299-307. https://doi.org/10.1097/ICU.0b013e32832b8d18 PMID: 19417653.
127. Melles GR, Ong TS, Ververs B, van der Wees J. Preliminary clinical results of Descemet membrane endothelial keratoplasty. Am J Ophthalmol. 2008 Feb;145(2):222-227. https://doi.org/10.1016/j.ajo.2007.09.021 PMID: 18061137
128. Price MO, Fairchild KM, Price DA, Price FWJ. Descemet's stripping endothelial keratoplasty five-year graft survival and endothelial cell loss. Ophthalmology. 2011 Apr;118(4):725-9. https://doi.org/10.1016/j.ophtha.2010.08.012 PMID: 21035862
129. Soh YQ, Kocaba V, Pinto M, Mehta JS. Fuchs endothelial corneal dystrophy and corneal endothelial diseases: East meets West. Eye (Lond). 2020 Mar;34(3):427-441. https://doi.org/10.1038/s41433-019-0497-9 PMID: 31267087
130. Oellerich S, Baydoun L, Peraza-Nieves J, Ilyas A, Frank L, Binder PS, et al. Multicenter Study of 6-Month Clinical Outcomes After Descemet Membrane Endothelial Keratoplasty. Cornea. 2017 Dec;36(12):1467-1476. https://doi.org/10.1097/ICO.0000000000001374 PMID: 28957979.
131. Price, M.O., Lass, J.H. & Price, F.W. Clinical factors for early and late endothelial cell loss after corneal transplantation. Curr Ophthalmol Rep 6, 191–199 (2018). https://doi.org/10.1007/s40135-018-0179-y
132. Price MO, Mehta JS, Jurkunas UV, Price FW Jr. Corneal endothelial dysfunction: evolving understanding and treatment options. Prog Retin Eye Res. 2021 May;82:100904. https://doi.org/10.1016/j.preteyeres.2020.100904 PMID: 32977001
133. Birbal RS, Ni Dhubhghaill S, Bourgonje VJA, Hanko J, Ham L, Jager MJ, et al. Five-Year Graft Survival and Clinical Outcomes of 500 Consecutive Cases After Descemet Membrane Endothelial Keratoplasty. Cornea. 2020 Mar;39(3):290-297. https://doi.org/10.1097/ICO.0000000000002120 PMID: 31478948
134. Oellerich S, Ham L, Frank LE, Gorges S, Bourgonje VJA, Baydoun L, et al. Parameters associated with endothelial cell density variability after Descemet membrane endothelial keratoplasty. Am J Ophthalmol. 2020 Mar;211:22-30. https://doi.org/10.1016/j.ajo.2019.10.017 PMID: 31647928
135. Hayashi T, Schrittenlocher S, Siebelmann S, Le VNH, Matthaei M, Franklin J, et al. Risk factors for endothelial cell loss after Descemet membrane endothelial keratoplasty (DMEK). Sci Rep. 2020 Jul 6;10(1):11086. https://doi.org/10.1038/s41598-020-68023-0 PMID: 32632151
136. Birbal RS, Baydoun L, Ham L, Miron A, van Dijk K, Dapena I, et al. Effect of surgical indication and preoperative lens status on Descemet membrane endothelial keratoplasty outcomes. Am J Ophthalmol. 2020 Apr;212:79-87. https://doi.org/10.1016/j.ajo.2019.12.011 PMID: 31863726
137. Rodríguez-Calvo de Mora M, Groeneveld-van Beek EA, Frank LE, van der Wees J, Oellerich S, Bruinsma M, et al. Association between graft storage time and donor age with endothelial cell density and graft adherence after

Descemet membrane endothelial keratoplasty. JAMA Ophthalmol. 2016 Jan;134(1):91-4. https://doi.org/10.1001/jamaophthalmol.2015.4499 PMID: 26562408

138. Baydoun L, Ham L, Borderie V, Dapena I, Hou J, Frank LE, et al. Endothelial survival after Descemet membrane endothelial keratoplasty: effect of surgical indication and graft adherence status. JAMA Ophthalmol. 2015 Nov;133(11):1277-85. https://doi.org/10.1001/jamaophthalmol.2015.3064 PMID: 26355238
139. Gundlach E, Spiller N, Pilger D, Dietrich-Ntoukas T, Joussen AM, Torun N, et al. Impact of difficult unfolding and attachment of the graft lamella on the long-term outcome after Descemet membrane endothelial keratoplasty. Graefes Arch Clin Exp Ophthalmol. 2020 Nov;258(11):2459-2465. https://doi.org/10.1007/s00417-020-04852-z PMID: 32705337
140. Musayeva A, Livny E, Dragnea DC, Ham L, Vasiliauskaitė I, Ní Dhubhghaill S, et. al. Endothelial cell density changes in the corneal center versus paracentral areas after Descemet membrane endothelial keratoplasty. Cornea. 2020 Sep;39(9):1091-1095. https://doi.org/10.1097/ICO.0000000000002326 PMID: 32282357
141. Guindolet D, Crouzet E, He Z, Herbepin P, Jumelle C, Perrache C, et al. Storage of Porcine Cornea in an Innovative Bioreactor. Invest Ophthalmol Vis Sci. 2017 Nov 1;58(13):5907-5917. https://doi.org/10.1167/iovs.17-22218 PMID: 29164231
142. Garcin T, Gauthier AS, Crouzet E, He Z, Herbepin P, Perrache C, et al. Innovative corneal active storage machine for long-term eye banking. Am J Transplant. 2019 Jun;19(6):1641-1651. https://doi.org/10.1111/ajt.15238 PMID: 30589181
143. Parekh M, Romano V, Hassanin K, Testa V, Wongvisavavit R, Ferrari S, et al. Biomaterials for corneal endothelial cell culture and tissue engineering. J Tissue Eng. 2021 Feb 16;12:2041731421990536. https://doi.org/10.1177/2041731421990536 PMID: 33643603
144. De Pieri A, Rochev Y, Zeugolis DI. Scaffold-free cell-based tissue engineering therapies: advances, shortfalls and forecast. NPJ Regen Med. 2021 Mar 29;6(1):18. https://doi.org/10.1038/s41536-021-00133-3 PMID: 33782415
145. Spinozzi D, Miron A, Bruinsma M, Dapena I, Kocaba V, Jager MJ, et al. New developments in corneal endothelial cell replacement. Acta Ophthalmol. 2021 Nov;99(7):712-729. https://doi.org/10.1111/aos.14722 PMID: 33369235
146. Hussain Z and Pei R. Scaffold-free and scaffold-based cellular strategies and opportunities for cornea tissue engineering. Prog. Biomed. Eng. 2021 Jul 26; 3(3):032003 https://doi.org/10.1088/2516-1091/ac12d7
147. Wongvisavavit R, Parekh M, Ahmad S, Daniels JT. Challenges in corneal endothelial cell culture. Regen Med. 2021 Sep;16(9):871-891. https://doi.org/10.2217/rme-2020-0202 PMID: 34380324
148. Hatou S, Shimmura S. Review: corneal endothelial cell derivation methods from ES/iPS cells. Inflamm Regen. 2019 Oct 3;39:19. https://doi.org/10.1186/s41232-019-0108-y PMID: 31592286
149. Shao C, Fu Y, Lu W, Fan X. Bone marrow-derived endothelial progenitor cells: a promising therapeutic alternative for corneal endothelial dysfunction. Cells Tissues Organs. 2011;193(4):253-63. https://doi.org/10.1159/000319797 PMID: 20962503
150. Ju C, Zhang K, Wu X. Derivation of corneal endothelial cell-like cells from rat neural crest cells *in vitro*. PLoS One. 2012;7(7):e42378. https://doi.org/10.1371/journal.pone.0042378. Erratum in: PLoS One. 2012;7(10). https://doi.org/10.1371/annotation/931e92e2-ee2d-4f4f-b0b6-89a7a3f8fbad PMID: 22860120
151. Hatou S, Yoshida S, Higa K, Miyashita H, Inagaki E, Okano H, et al. Functional corneal endothelium derived from corneal stroma stem cells of neural crest origin by retinoic acid and Wnt/β-catenin signaling. Stem Cells Dev. 2013 Mar 1;22(5):828-39. https://doi.org/10.1089/scd.2012.0286 PMID: 22974347
152. Inagaki E, Hatou S, Higa K, Yoshida S, Shibata S, Okano H, et al. Skin-derived precursors as a source of progenitors for corneal endothelial regeneration. Stem Cells Transl Med. 2017 Mar;6(3):788-798. https://doi.org/10.1002/sctm.16-0162 PMID: 28186681
153. Yamashita K, Inagaki E, Hatou S, Higa K, Ogawa A, Miyashita H, et al. Corneal endothelial regeneration using mesenchymal stem cells derived from human umbilical cord. Stem Cells Dev. 2018 Aug 15;27(16):1097-1108. https://doi.org/10.1089/scd.2017.0297 PMID: 29929442
154. Joyce NC, Harris DL, Markov V, Zhang Z, Saitta B. Potential of human umbilical cord blood mesenchymal stem cells to heal damaged corneal endothelium. Mol Vis. 2012;18:547-64. PMID: 22419848
155. Mimura T, Yokoo S, Araie M, Amano S, Yamagami S. Treatment of rabbit bullous keratopathy with precursors derived from cultured human corneal endothelium. Invest Ophthalmol Vis Sci. 2005 Oct;46(10):3637-44. https://doi.org/10.1167/iovs.05-0462 PMID: 16186344

156. Ueno M, Toda M, Numa K, Tanaka H, Imai K, Bush J, et al. Superiority of mature differentiated cultured human corneal endothelial cell injection therapy for corneal endothelial failure. Am J Ophthalmol. 2022 May;237:267-277. https://doi.org/10.1016/j.ajo.2021.11.012 PMID: 34788595
157. Fan T, Zhao J, Ma X, Xu X, Zhao W, Xu B. Establishment of a continuous untransfected human corneal endothelial cell line and its biocompatibility to denuded amniotic membrane. Mol Vis. 2011 Feb 15;17:469-80. PMID: 21365020
158. Ishino Y, Sano Y, Nakamura T, Connon CJ, Rigby H, Fullwood NJ, et al. Amniotic membrane as a carrier for cultivated human corneal endothelial cell transplantation. Invest Ophthalmol Vis Sci. 2004 Mar;45(3):800-6. https://doi.org/10.1167/iovs.03-0016 PMID: 14985293
159. Fan T, Ma X, Zhao J, Wen Q, Hu X, Yu H, et al. Transplantation of tissue-engineered human corneal endothelium in cat models. Mol Vis. 2013;19:400-7. PMID: 23441111
160. Diao YM, Hong J. Feasibility and safety of porcine Descemet's membrane as a carrier for generating tissue-engineered corneal endothelium. Mol Med Rep. 2015 Aug;12(2):1929-34. https://doi.org/10.3892/mmr.2015.3665 PMID: 25937160
161. Spinozzi D, Miron A, Bruinsma M, Dapena I, Lavy I, Binder PS, et al. Evaluation of the Suitability of Biocompatible Carriers as Artificial Transplants Using Cultured Porcine Corneal Endothelial Cells. Curr Eye Res. 2019 Mar;44(3):243-249. https://doi.org/10.1080/02713683.2018.1536215 PMID: 30339045
162. Bayyoud T, Thaler S, Hofmann J, Maurus C, Spitzer MS, Bartz-Schmidt KU, et al. Decellularized bovine corneal posterior lamellae as carrier matrix for cultivated human corneal endothelial cells. Curr Eye Res. 2012 Mar;37(3):179-86. https://doi.org/10.3109/02713683.2011.644382 PMID: 22335804
163. Arnalich-Montiel F, Moratilla A, Fuentes-Julián S, Aparicio V, Cadenas Martin M, Peh G, et al. Treatment of corneal endothelial damage in a rabbit model with a bioengineered graft using human decellularized corneal lamina and cultured human corneal endothelium. PLoS One. 2019 Nov 21;14(11):e0225480. https://doi.org/10.1371/journal.pone.0225480 PMID: 31751429
164. Choi JS, Williams JK, Greven M, Walter KA, Laber PW, Khang G, et al. Bioengineering endothelialized neo-corneas using donor-derived corneal endothelial cells and decellularized corneal stroma. Biomaterials. 2010 Sep;31(26):6738-45. https://doi.org/10.1016/j.biomaterials.2010.05.020 PMID: 20541797
165. He Z, Forest F, Bernard A, Gauthier AS, Montard R, Peoc'h M, et al. Cutting and decellularization of multiple corneal stromal lamellae for the bioengineering of endothelial grafts. Invest Ophthalmol Vis Sci. 2016 Dec 1;57(15):6639-6651. https://doi.org/10.1167/iovs.16-20256 PMID: 27926756
166. Spinozzi D, Miron A, Lie JT, Rafat M, Lagali N, Melles GRJ, et al. *In vitro* Evaluation and transplantation of human corneal endothelial cells cultured on biocompatible carriers. Cell Transplant. 2020 Jan-Dec;29:963689720923577. https://doi.org/10.1177/0963689720923577 PMID: 32363924
167. Kopsachilis N, Tsinopoulos I, Tourtas T, Kruse FE, Luessen UW. Descemet's membrane substrate from human donor lens anterior capsule. Clin Exp Ophthalmol. 2012 Mar;40(2):187-94. https://doi.org/10.1111/j.1442-9071.2011.02678.x PMID: 21902779
168. Bourget JM, Proulx S. Characterization of a corneal endothelium engineered on a self-assembled stromal substitute. Exp Eye Res. 2016 Apr;145:125-129. https://doi.org/10.1016/j.exer.2015.11.019 PMID: 26658713
169. Koizumi N, Sakamoto Y, Okumura N, Okahara N, Tsuchiya H, Torii R, et al. Cultivated corneal endothelial cell sheet transplantation in a primate model. Invest Ophthalmol Vis Sci. 2007 Oct;48(10):4519-26. https://doi.org/10.1167/iovs.07-0567 PMID: 17898273
170. Levis HJ, Peh GS, Toh KP, Poh R, Shortt AJ, Drake RA, et al. Plastic compressed collagen as a novel carrier for expanded human corneal endothelial cells for transplantation. PLoS One. 2012;7(11):e50993. https://doi.org/10.1371/journal.pone.0050993 PMID: 23226443
171. Mimura T, Yamagami S, Yokoo S, Usui T, Tanaka K, Hattori S, et al. Cultured human corneal endothelial cell transplantation with a collagen sheet in a rabbit model. Invest Ophthalmol Vis Sci. 2004 Sep;45(9):2992-7. https://doi.org/10.1167/iovs.03-1174 PMID: 15326112
172. Palchesko RN, Funderburgh JL, Feinberg AW. Engineered Basement Membranes for Regenerating the Corneal Endothelium. Adv Healthc Mater. 2016 Nov;5(22):2942-2950. https://doi.org/10.1002/adhm.201600488 PMID: 27723276
173. Vázquez N, Chacón M, Rodríguez-Barrientos CA, Merayo-Lloves J, Naveiras M, Baamonde B, et al. Human bone derived collagen for the development of an artificial corneal endothelial graft. *In vivo* results in a rabbit model. PLoS One. 2016 Dec 1;11(12):e0167578. https://doi.org/10.1371/journal.pone.0167578 PMID: 27907157

174. Yamaguchi M, Shima N, Kimoto M, Ebihara N, Murakami A, Yamagami S. Optimization of cultured human corneal endothelial cell sheet transplantation and post-operative sheet evaluation in a rabbit model. Curr Eye Res. 2016 Sep;41(9):1178-84. https://doi.org/10.3109/02713683.2015.1101774 PMID: 26828450
175. Kimoto M, Shima N, Yamaguchi M, Hiraoka Y, Amano S, et al. Development of a bioengineered corneal endothelial cell sheet to fit the corneal curvature. Invest Ophthalmol Vis Sci. 2014 Apr 11;55(4):2337-43. https://doi.org/10.1167/iovs.13-13167 PMID: 24651553
176. Watanabe R, Hayashi R, Kimura Y, Tanaka Y, Kageyama T, et al. A novel gelatin hydrogel carrier sheet for corneal endothelial transplantation. Tissue Eng Part A. 2011 Sep;17(17-18):2213-9. https://doi.org/10.1089/ten.TEA.2010.0568 PMID: 21534849
177. Aghaei-Ghareh-Bolagh B, Guan J, Wang Y, Martin AD, Dawson R, Mithieux SM, et al. Optically robust, highly permeable and elastic protein films that support dual cornea cell types. Biomaterials. 2019 Jan;188:50-62. https://doi.org/10.1016/j.biomaterials.2018.10.006 PMID: 30317114
178. Choi JH, Jeon H, Song JE, Oliveira JM, Reis RL, Khang G. Biofunctionalized lysophosphatidic acid/silk fibroin film for cornea endothelial cell regeneration. Nanomaterials (Basel). 2018 Apr 30;8(5):290. https://doi.org/10.3390/nano8050290 PMID: 29710848
179. Kim DK, Sim BR, Kim JI, Khang G. Functionalized silk fibroin film scaffold using β-Carotene for cornea endothelial cell regeneration. Colloids Surf B Biointerfaces. 2018 Apr 1;164:340-346. https://doi.org/10.1016/j.colsurfb.2017.11.052 PMID: 29413615
180. Kim do K, Sim BR, Khang G. Nature-derived aloe vera gel blended silk fibroin film scaffolds for cornea endothelial cell regeneration and transplantation. ACS Appl Mater Interfaces. 2016 Jun 22;8(24):15160-8. https://doi.org/10.1021/acsami.6b04901 PMID: 27243449
181. Madden PW, Lai JN, George KA, Giovenco T, Harkin DG, Chirila TV. Human corneal endothelial cell growth on a silk fibroin membrane. Biomaterials. 2011 Jun;32(17):4076-84. https://doi.org/10.1016/j.biomaterials.2010.12.034 PMID: 21427010
182. Ramachandran C, Gupta P, Hazra S, Mandal BB. *In vitro* culture of human corneal endothelium on non-mulberry silk fibroin films for tissue regeneration. Transl Vis Sci Technol. 2020 Mar 9;9(4):12. https://doi.org/10.1167/tvst.9.4.12 PMID: 32818099
183. Vázquez N, Rodríguez-Barrientos CA, Aznar-Cervantes SD, Chacón M, Cenis JL, Riestra AC, et al. Silk fibroin films for corneal endothelial regeneration: transplant in a rabbit Descemet membrane endothelial keratoplasty. Invest Ophthalmol Vis Sci. 2017 Jul 1;58(9):3357-3365. https://doi.org/10.1167/iovs.17-21797 PMID: 28687847
184. Kruse M, Walter P, Bauer B, Rütten S, Schaefer K, et al. Electro-spun Membranes as scaffolds for human corneal endothelial cells. Curr Eye Res. 2018 Jan;43(1):1-11. https://doi.org/10.1080/02713683.2017.1377258 PMID: 29281419
185. Ozcelik B, Brown KD, Blencowe A, Ladewig K, Stevens GW, Scheerlinck JP,et al. Biodegradable and biocompatible poly(ethylene glycol)-based hydrogel films for the regeneration of corneal endothelium. Adv Healthc Mater. 2014 Sep;3(9):1496-507. https://doi.org/10.1002/adhm.201400045 PMID: 24652807
186. Van Hoorick J, Delaey J, Vercammen H, Van Erps J, Thienpont H, Dubruel P, et al. Designer Descemet membranes containing PDLLA and functionalized gelatins as corneal endothelial scaffold. Adv Healthc Mater. 2020 Aug;9(16):e2000760. https://doi.org/10.1002/adhm.202000760 PMID: 32603022
187. Liang Y, Liu W, Han B, Yang C, Ma Q, Zhao W, et al. Fabrication and characters of a corneal endothelial cells scaffold based on chitosan. J Mater Sci Mater Med. 2011 Jan;22(1):175-83. https://doi.org/10.1007/s10856-010-4190-6 PMID: 21107657
188. Rizwan M, Peh GS, Adnan K, Naso SL, Mendez AR, Mehta JS, et al. *In vitro* topographical model of Fuchs dystrophy for evaluation of corneal endothelial cell monolayer formation. Adv Healthc Mater. 2016 Nov;5(22):2896-2910. https://doi.org/10.1002/adhm.201600848 PMID: 27701826
189. Seow WY, Kandasamy K, Peh GSL, Mehta JS, Sun W. Ultrathin, Strong, and Cell-Adhesive Agarose-Based Membranes Engineered as Substrates for Corneal Endothelial Cells. ACS Biomater Sci Eng. 2019 Aug 12;5(8):4067-4076. https://doi.org/10.1021/acsbiomaterials.9b00610 PMID: 33448808
190. Song JE, Sim BR, Jeon YS, Kim HS, Shin EY, Carlomagno C, et al. Characterization of surface modified glycerol/silk fibroin film for application to corneal endothelial cell regeneration. J Biomater Sci Polym Ed. 2019 Mar;30(4):263-275. https://doi.org/10.1080/09205063.2018.1535819 PMID: 30324858
191. Wang TJ, Wang IJ, Lu JN, Young TH. Novel chitosan-polycaprolactone blends as potential scaffold and carrier for corneal endothelial transplantation. Mol Vis. 2012;18:255-64. PMID: 22328821

192. Young TH, Wang IJ, Hu FR, Wang TJ. Fabrication of a bioengineered corneal endothelial cell sheet using chitosan/polycaprolactone blend membranes. Colloids Surf B Biointerfaces. 2014 Apr 1;116:403-10. https://doi.org/10.1016/j.colsurfb.2014.01.024 PMID: 24531150
193. Honda N, Mimura T, Usui T, Amano S. Descemet stripping automated endothelial keratoplasty using cultured corneal endothelial cells in a rabbit model. Arch Ophthalmol. 2009 Oct;127(10):1321-6. https://doi.org/10.1001/archophthalmol.2009.253 PMID: 19822849
194. Peh GSL, Ang HP, Lwin CN, Adnan K, George BL, Seah XY et al. Regulatory compliant tissue-engineered human corneal endothelial grafts restore corneal function of rabbits with bullous keratopathy. Sci Rep. 2017 Oct 26;7(1):14149. https://doi.org/10.1038/s41598-017-14723-z PMID: 29074873
195. Telinius N, Spinozzi D, Rasic D, Dapena I, Baandrup U, Miron A, et al. Göttingen minipig is not a suitable animal model for *in vivo* testing of tissue-engineered corneal endothelial cell-carrier sheets and for endothelial keratoplasty. Curr Eye Res. 2020 Aug;45(8):945-949. https://doi.org/10.1080/02713683.2019.1706747 PMID: 31851850
196. Arbelaez JG, Price MO, Price FWJ. Long-term follow-up and complications of stripping Descemet membrane without placement of graft in eyes with Fuchs endothelial dystrophy. Cornea. 2014 Dec;33(12):1295-9. https://doi.org/10.1097/ICO.0000000000000270 PMID: 25299425
197. Shah RD, Randleman JB, Grossniklaus HE. Spontaneous corneal clearing after Descemet's stripping without endothelial replacement. Ophthalmology. 2012 Feb;119(2):256-60. https://doi.org/10.1016/j.ophtha.2011.07.032 PMID: 21982414
198. Auffarth GU, Son HS, Koch M, Weindler J, Merz P, Daphna O, et al. Implantation of an Artificial Endothelial Layer for Treatment of Chronic Corneal Edema. Cornea. 2021 Dec 1;40(12):1633-1638. https://doi.org/10.1097/ICO.0000000000002806 PMID: 34294634
199. Bhogal M, Lwin CN, Seah XY, Peh G, Mehta JS. Allogeneic Descemet's membrane transplantation enhances corneal endothelial monolayer formation and restores functional integrity following Descemet's stripping. Invest Ophthalmol Vis Sci. 2017 Aug 1;58(10):4249-4260. https://doi.org/10.1167/iovs.17-22106 PMID: 28850636
200. Robbins PD, Ghivizzani SC. Viral vectors for gene therapy. Pharmacol Ther. 1998 Oct;80(1):35-47. PMID: 9804053
201. Lebherz C, Maguire A, Tang W, Bennett J, Wilson JM. Novel AAV serotypes for improved ocular gene transfer. J Gene Med. 2008 Apr;10(4):375-82. https://doi.org/10.1002/jgm.1126 PMID: 18278824
202. Rinaldi C, Wood MJA. Antisense oligonucleotides: the next frontier for treatment of neurological disorders. Nat Rev Neurol. 2018 Jan;14(1):9-21. https://doi.org/10.1038/nrneurol.2017.148 PMID: 29192260
203. Moore CBT, Christie KA, Marshall J, Nesbit MA. Personalised genome editing - The future for corneal dystrophies. Prog Retin Eye Res. 2018 Jul;65:147-165. https://doi.org/10.1016/j.preteyeres.2018.01.004 PMID: 29378321
204. Cox DB, Platt RJ, Zhang F. Therapeutic genome editing: prospects and challenges. Nat Med. 2015 Feb;21(2):121-31. https://doi.org/10.1038/nm.3793 PMID: 25654603
205. Jiang F, Doudna JA. CRISPR-Cas9 Structures and Mechanisms. Annu Rev Biophys. 2017 May 22;46:505-529. https://doi.org/10.1146/annurev-biophys-062215-010822 PMID: 28375731
206. Nanda GG, Alone DP. REVIEW: Current understanding of the pathogenesis of Fuchs' endothelial corneal dystrophy. Mol Vis. 2019 Jun 5;25:295-310. PMID: 31263352
207. Ong Tone S, Kocaba V, Böhm M, Wylegala A, White TL, Jurkunas UV. Fuchs endothelial corneal dystrophy: the vicious cycle of Fuchs pathogenesis. Prog Retin Eye Res. 2021 Jan;80:100863. https://doi.org/10.1016/j.preteyeres.2020.100863 PMID: 32438095
208. Wu Z, Yang H, Colosi P. Effect of genome size on AAV vector packaging. Mol Ther. 2010 Jan;18(1):80-6. https://doi.org/10.1038/mt.2009.255 PMID: 19904234
209. Hu J, Rong Z, Gong X, Zhou Z, Sharma VK, Xing C, et al. Oligonucleotides targeting TCF4 triplet repeat expansion inhibit RNA foci and mis-splicing in Fuchs' dystrophy. Hum Mol Genet. 2018 Mar 15;27(6):1015-1026. https://doi.org/10.1093/hmg/ddy018 PMID: 29325021
210. Hu J, Shen X, Rigo F, Prakash TP, Mootha VV, Corey DR. Duplex RNAs and ss-siRNAs Block RNA Foci Associated with Fuchs' Endothelial Corneal Dystrophy. Nucleic Acid Ther. 2019 Apr;29(2):73-81. https://doi.org/10.1089/nat.2018.0764 PMID: 30676271
211. Zarouchlioti C, Sanchez-Pintado B, Hafford Tear NJ, Klein P, Liskova P, Dulla K, et al. Antisense Therapy for a Common Corneal Dystrophy Ameliorates TCF4 Repeat Expansion-Mediated Toxicity. Am J Hum Genet. 2018 Apr 5;102(4):528-539. https://doi.org/10.1016/j.ajhg.2018.02.010 PMID: 29526280
212. Chau VQ, Hu J, Gong X, Hulleman JD, Ufret-Vincenty RL, Rigo F, et al. Delivery of Antisense Oligonucleotides to the Cornea. Nucleic Acid Ther. 2020 Aug;30(4):207-214. https://doi.org/10.1089/nat.2019.0838 PMID: 32202944

213. Rong Z, Gong X, Hulleman JD, Corey DR, Mootha VV. Trinucleotide Repeat-Targeting dCas9 as a Therapeutic Strategy for Fuchs' Endothelial Corneal Dystrophy. Transl Vis Sci Technol. 2020 Aug 31;9(9):47. https://doi.org/10.1167/tvst.9.9.47 PMID: 32934897
214. Uehara H, Zhang X, Pereira F, Narendran S, Choi S, Bhuvanagiri S, et al. Start codon disruption with CRISPR/Cas9 prevents murine Fuchs' endothelial corneal dystrophy. Elife. 2021 Jun 8;10:e55637. https://doi.org/10.7554/eLife.55637 PMID: 34100716
215. Koizumi N, Okumura N, Ueno M, Nakagawa H, Hamuro J, Kinoshita S. Rho-associated kinase inhibitor eye drop treatment as a possible medical treatment for Fuchs corneal dystrophy. Cornea. 2013 Aug;32(8):1167-70. https://doi.org/10.1097/ICO.0b013e318285475d PMID: 23715376
216. Okumura N, Koizumi N, Kay EP, Ueno M, Sakamoto Y, Nakamura S, et al. The ROCK inhibitor eye drop accelerates corneal endothelium wound healing. Invest Ophthalmol Vis Sci. 2013 Apr 3;54(4):2493-502. https://doi.org/10.1167/iovs.12-11320 PMID: 23462749
217. Okumura N, Inoue R, Okazaki Y, Nakano S, Nakagawa H, Kinoshita S, et al. Effect of the Rho Kinase Inhibitor Y-27632 on Corneal Endothelial Wound Healing. Invest Ophthalmol Vis Sci. 2015 Sep;56(10):6067-74. https://doi.org/10.1167/iovs.15-17595 PMID: 26393474
218. Hoppenreijs VP, Pels E, Vrensen GF, Oosting J, Treffers WF. Effects of human epidermal growth factor on endothelial wound healing of human corneas. Invest Ophthalmol Vis Sci. 1992 May;33(6):1946-57. PMID: 1582800
219. Hoppenreijs VP, Pels E, Vrensen GF, Treffers WF. Effects of platelet-derived growth factor on endothelial wound healing of human corneas. Invest Ophthalmol Vis Sci. 1994 Jan;35(1):150-61. PMID: 8300342
220. Lu J, Lu Z, Reinach P, Zhang J, Dai W, Lu L, et al. TGF-beta2 inhibits AKT activation and FGF-2-induced corneal endothelial cell proliferation. Exp Cell Res. 2006 Nov 1;312(18):3631-40. https://doi.org/10.1016/j.yexcr.2006.08.004 PMID: 16963022
221. Halilovic A, Schmedt T, Benischke AS, Hamill C, Chen Y, Santos JH, et al. Menadione-Induced DNA Damage Leads to Mitochondrial Dysfunction and Fragmentation During Rosette Formation in Fuchs Endothelial Corneal Dystrophy. Antioxid Redox Signal. 2016 Jun 20;24(18):1072-83. https://doi.org/10.1089/ars.2015.6532 PMID: 26935406
222. Kim EC, Meng H, Jun AS. N-Acetylcysteine increases corneal endothelial cell survival in a mouse model of Fuchs endothelial corneal dystrophy. Exp Eye Res. 2014 Oct;127:20-5. https://doi.org/10.1016/j.exer.2014.06.002 PMID: 24952277
223. Liu C, Miyajima T, Melangath G, Miyai T, Vasanth S, Deshpande N, et al. Ultraviolet A light induces DNA damage and estrogen-DNA adducts in Fuchs endothelial corneal dystrophy causing females to be more affected. Proc Natl Acad Sci U S A. 2020 Jan 7;117(1):573-583. https://doi.org/10.1073/pnas.1912546116 PMID: 31852820
224. Lovatt M, Kocaba V, Hui Neo DJ, Soh YQ, Mehta JS. Nrf2: A unifying transcription factor in the pathogenesis of Fuchs' endothelial corneal dystrophy. Redox Biol. 2020 Oct;37:101763. https://doi.org/10.1016/j.redox.2020.101763 PMID: 33099215
225. Ziaei A, Schmedt T, Chen Y, Jurkunas UV. Sulforaphane decreases endothelial cell apoptosis in Fuchs endothelial corneal dystrophy: a novel treatment. Invest Ophthalmol Vis Sci. 2013 Oct 15;54(10):6724-34. https://doi.org/10.1167/iovs.13-12699 PMID: 24030461
226. Kim EC, Toyono T, Berlinicke CA, Zack DJ, Jurkunas U, Usui T, et al. Screening and Characterization of Drugs That Protect Corneal Endothelial Cells Against Unfolded Protein Response and Oxidative Stress. Invest Ophthalmol Vis Sci. 2017 Feb 1;58(2):892-900. https://doi.org/10.1167/iovs.16-20147 PMID: 28159976
227. Thuret G, Courrier E, Poinard S, Gain P, Baud'Huin M, et al. One threat, different answers: the impact of COVID-19 pandemic on cornea donation and donor selection across Europe. Br J Ophthalmol. 2022 Mar;106(3):312-318. https://doi.org/10.1136/bjophthalmol-2020-317938 PMID: 33243832
228. Cronin AJ. Points mean prizes: priority points, preferential status and directed organ donation in Israel. Isr J Health Policy Res. 2014 Feb 24;3(1):8. https://doi.org/10.1186/2045-4015-3-8 PMID: 24565060
229. Iyer TK. Kidneys for transplant--"opting out" law in Singapore. Forensic Sci Int. 1987 Oct-Nov;35(2-3):131-40. https://doi.org/10.1016/0379-0738(87)90048-x PMID: 3322992
230. Zúñiga-Fajuri A. Increasing organ donation by presumed consent and allocation priority: Chile. Bull World Health Organ. 2015 Mar 1;93(3):199-202. https://doi.org/10.2471/BLT.14.139535 PMID: 25767299

CHAPTER 11

Nederlandse samenvatting (Dutch summary)

SAMENVATTING EN DISCUSSIE

Een intact corneaendotheel is essentieel voor de helderheid van de cornea, aangezien het de voeding en hydratatie van de cornea reguleert. Het endotheel vormt een semipermeabele barrière met actieve ion-transportmechanismen. Het menselijk endotheel wordt gezien als een niet-delende cellaag waarin een continu leeftijdsafhankelijk verlies van endotheelcellen plaatsvindt van 0,5-0,9% per jaar.[1] Dit verlies van cellen kan versneld worden door ziekte van de cornea, schade door ontstekingsprocessen of door trauma ten gevolge van operaties in het oog, of penetrerend letsel. De endotheelcellen van de cornea (corneal endothelial cells, CEC) zullen bij een lage celdichtheidmeer migratie vertonen. Dit komt door een verminderde contacinhibitie. Wanneer de endotheelceldichtheid (endothelial cell density, ECD) daalt tot 400 – 500 cellen/mm^2, is dit lager dan de minimaal benodigde dichtheid om de pompfunctie van het endotheel te behouden, hetgeen resulteert in corneadecompensatie. Dit houdt in dat de corneadikte toeneemt, wat slecht zicht geeft, en tenslotte een pijnlijk oog. In dit soort gevallen wordt het aangedane deel van de cornea middels een operatie vervangen door een volledige cornea (Perforerende Keratoplastiek – PK) of een lamellair transplantaat van de achterkant van de cornea (Endotheliale Keratoplastiek – EK). Descemet Membraan Endotheliale Keratoplastiek (DMEK) is de meest selectieve EK techniek en tegenwoordig de voorkeursbehandeling voor endotheel afwijkingen. Hierbij wordt het endotheel samen met de Membraan van Descemet vervangen.

Vergelijkbaar met orgaantransplantaties heeft een getransplanteerd hoornvlies een beperkte levensduur die vaak gerelateerd is aan de celdichtheid. Transplantaten kunnen een acuut (gerelateerd aan chirurgische techniek of transplantaat preparatie) of chronisch (subklinische immunologische reactie) verlies aan celdichtheid ondergaan wat kan leiden tot “graft failure” (transplantaatfalen). Daarnaast wordt geschat dat, door het wereldwijde tekort aan donorcornea’s, maar één op de zeventig slechtziende patiënten die een transplantaat nodig hebben, er daadwerkelijk één krijgen.[2,3] Als poging om het weefseltekort te verminderen zijn de Hemi- [4–6] en Quarter-DMEK [7–10] ontwikkeld om het beschikbare weefsel efficiënter te kunnen gebruiken. Deze technieken, evenals andere nieuwe behandelingsmethoden om het weefseltekort te verlichten, zijn het meest geschikt voor patiënten die in de periferie van de cornea nog gezonde endotheelcellen hebben. Om meer patiënten te kunnen helpen wordt onderzoek gedaan naar de regeneratie van het cornea-endotheel door verandering van transplantaatpreparatietechnieken, toediening van farmacologische modulatoren en synthetische alternatieven.[11]

Dit proefschrift beschrijft de snelle progressie in het onderzoek naar cornearegeneratie en bevat tevens een een diepgaande analyse van wondgenezing en biologische modulatoren. Ook zijn in vitro experimenten uitgevoerd om de migratiecapaciteit van het endotheel vóór en na EK te evalueren. De verkregen uitkomsten resulteren in meer inzicht betreffende endotheelcelmigratie en in meer kennis betreffende het voortdurende onderzoek naar mogelijke vervangers van endotheel transplantaten.

Vroege postoperatieve afname van ECD na DMEK en levensvatbaarheid van de DMEK-transplantaat vóór transplantatie

DMEK is de gouden standaard geworden om endotheeldysfunctie te behandelen vanwege het snelle visuele herstel, het anatomisch vrijwel normale herstel van de cornea en een laag afstotingsrisico .[12] Aanvankelijk was er enige terughoudendheid voor gebruik van de DMEK-techniek in verband met zorgen over de technische aspecten van zowel transplantaatpreparatie als operatie.[13] Preparatie van deze dunne (10–15 µm) grafts kan uitdagend zijn en zou daarnaast kunnen leiden tot volledig verlies van weefsel of een hoge postoperatieve afname van de ECD en een korte transplantaat levensduur, wat mede veroorzaakt kan worden door de intra-operatieve transplantaathantering.[14] Aangezien de ECD samenhangt met de levensduur van de EK, wordt de afname van de ECD beschouwd als een van de belangrijkste maten van uitkomst in het onderzoek naar de

doeltreffendheid en veiligheid van de DMEK, evenals voor het voorspellen van de levensvatbaarheid van het transplantaat op lange termijn.[14–16] Voor alle EK's wordt de postoperatieve afname van de ECD gewoonlijk gerapporteerd bij een 6-maandse follow-up, waarbij een gemiddelde daling beschreven wordt van ongeveer 30 tot 40% ten opzichte van de preoperatieve waarden. Deze daling wordt gevolgd door een jaarlijkse daling van 7 tot 9%.[17,18] Het is echter onduidelijk wannéér de afname van de ECD, die bij de 6-maanden follow-up wordt gemeten, daadwerkelijk heeft plaatsgevonden en of dit een geleidelijke afname of plotselinge daling weerspiegelt. De resultaten van een kleiner onderzoek in ons instituut tonen een afname van meer dan 30% van de ECD binnen de eerste maand na DMEK.[19] Deze bevinding werd eerder bevestigd in de vervolgstudie (Hoofdstuk 1) met een serie van 24 DMEK-ogen die werden behandeld voor Fuch's endotheelceldystrofie (FECD). In deze studie konden we al op 1 dag en 1 week na de operatie speculaire (spiegelende) microscopische beelden verkrijgen door de snelle helderheid van de cornea na een DMEK-ingreep, waardoor we konden aantonen dat de ECD-daling van 30% al binnen de eerste postoperatieve week plaatsvindt. Ongeveer 2/3 van de totale daling kon al na de eerste postoperatieve dag worden waargenomen.[20] Een dermate snelle daling kan niet worden verklaard door migratie en/of herverdeling van het endotheel, waarvoor meer tijd nodig is.[21] Het is daarnaast ook onwaarschijnlijk dat een daling in zo'n korte periode werd veroorzaakt door een immuunrespons, zeker omdat transplantaatafstoting over het algemeen wordt beschouwd als een vertraagde reactie.[22] Andere mogelijke oorzaken voor vroegtijdige postoperatieve ECD-afname na DMEK kunnen intra-operatieve handelingen zijn of een preoperatieve overschatting van het aantal levensvatbare cellen op de transplantaat. Aangezien voor de meeste operaties in dit onderzoek geen intra-operatieve complicaties werden gerapporteerd kan het grotere deel van de ECD-afname voornamelijk worden verklaard door overschatting van de levensvatbare ECD in de hoornvliesbank. Dit leidde ons ertoe om de levensvatbaarheid na transplantaatpreparatie nader te onderzoeken.

Het onderzoek naar de levensvatbaarheid en kwaliteit van de door de hoornvliesbank geprepareerde grafts is het onderwerp geworden van talrijke studies. Afname van de ECD werd gerapporteerd na verschillende preparatiemethoden of chirurgische manipulaties.[23–29] De huidige manier van werken in de hoornvliesbank is om de ECD te bepalen op basis van structurele integriteit van de cellen (beoordeeld door trypaanblauwkleuring), hoewel dit niet precies de levensvatbare endotheelcelpool weergeeft die wordt getransplanteerd. Onze vervolgstudie (Hoofdstuk 2) over de levensvatbaarheid van het DMEK-transplantaat, waarin gebruik is gemaakt van DMEK-transplantaten met chirurgisch goede kwaliteit die niet voor een patiënt gebruikt konden worden (als gevolg van de coronapandemie), heeft de noodzaak aangetoond om een meer nauwkeurige analyse uit voeren na weefselpreparatie.[30] Idealiter worden transplantaten niet enkel geëvalueerd op basis van levend en dood, maar wordt er onderscheid gemaakt tussen de verschillende vormen van celdood (apoptose, necrose, autofagie), aangezien anders bijvoorbeeld apoptotische cellen nog als "levend" kunnen worden beschouwd. Om beter onderscheid te kunnen maken moeten meerdere biochemische en functionele tests worden uitgevoerd. Dit is eerder gedaan met Calceïne-acetoxymethylester (Calceïne-AM) voor onderzoek naar enzymatische activiteit, integriteit van het celmembraan en het tracken van cellen op lange termijn, vanwege de lage cellulaire toxiciteit.[31,32] In onze studie werd de levensvatbaarheid van vijf transplantaten die gepland stonden voor transplantatie beoordeeld door middel van de Calceïne-AM kleuring op de oorspronkelijk geplande operatiedag. Hieruit bleek dat het percentage van het centrale oppervlak dat door levensvatbare cellen werd bedekt varieerde van 57 tot 97%. Vanwege deze grote spreiding zijn we doorgegaan met de analyse van elf gepaarde donorcornea's, welke direct na preparatie of na 3 tot 7 dagen opslag in kweekmedium werden geëvalueerd. De resultaten toonden aan dat de levensvatbaarheid van de meeste DMEK-transplantaten niet beïnvloed leek te zijn door preparatie en opslag, terwijl bij sommige transplantaten enkele uren na preparatie endotheelschade kon worden waargenomen welke niet door trypaanblauw werd gedetecteerd. Deze kleurstof kan namelijk geen apoptotische of necrotische cellen detecteren en enkel dode cellen.[33] Toen de ECD na preparatie werd geëvalueerd door middel van trypaanblauw (oogbankprocedure), werd een gemiddeld verschil in ECD geobserveerd van 10 (±21)%

vergeleken met evaluatie van de ECD van dezelfde transplantaten door middel van Calceïne-AM. Deze grote variabiliteit in de afname van de ECD, geobserveerd door Calceïne-AM na transplantaat preparatie, ondersteunt onze klinische waarneming dat deze afname in de vroege postoperatieve fase na DMEK voornamelijk kan worden verklaard door een overschatting van de levensvatbare endotheelcelpopulatie van de transplantaat.

Als alternatief voor Calceïne-AM kan ook een annexine V-FITC assay worden uitgevoerd, waarmee vroege apoptose kan worden gedetecteerd door te kijken naar negatief geladen fosfatidylserine dat tijdens apoptose van het binnenste membraanblad van levensvatbare cellen naar het buitenste membraanoppervlak wordt gebracht.[34] Door assays die routinematig worden gebruikt om apoptose te karakteriseren te combineren met membraan-permeabele kleurstoffen zoals trypaanblauw, zouden in hetzelfde monster zowel de apoptotische/necrotische als de levensvatbare cellen kunnen worden gedetecteerd en gekwantificeerd. Deze tests zijn echter nog niet goedgekeurd voor gebruik op transplanteerbaar weefsel. Hierdoor is er nog steeds een grote behoefte aan de ontwikkeling en validatie van detectiemethoden voor levensvatbaarheid van cellen en cytotoxiteit, die de functionele status van het endotheel na preparatie van het transplataat analyseren en een nauwkeurige levensvatbare celtelling opleveren. Ondertussen zou een aanvullende DMEK-kwaliteitscheck door middel van lichtmicroscopie binnen drie uren na preparatie of vlak voor de operatie kunnen helpen om transplantaten met matige endotheelkwaliteit te kunnen opsporen en zo postoperatieve DMEK-complicaties en de kans op een lage postoperatieve ECD te verminderen.

Het in vivo en in vitro waarnemen van de morfologische veranderingen en regeneratieve capaciteit van het endotheel

Intracellulaire signaalroutes in wondgenezing

Naast het verbeteren van de kwaliteit van het beschikbare corneadonorweefsel richt het huidige onderzoek zich ook op niet-chirurgische behandelingen voor het herstel van het endotheel door eerst de concepten en beperkingen van klinische procedures te begrijpen. In dit verband zou het uitgebreide overzicht (Hoofdstuk 3) over signaalroutes die betrokken zijn bij zowel proliferatie als migratie van de CEC kunnen leiden tot nieuwe ideeën over de behandeling van corneale endotheeldysfunctie.[35]

Het ontwikkelen van nieuwe strategieën om de regeneratieve capaciteit van de CEC te herstellen is uitdagend, aangezien de CEC in vivo zijn blijven steken in de G0/G1-fase van de celcyclus. Het wordt daarnaast verder belemmerd door de endotheel-naar-mesenchymale celtransitie (endothelial-to-mesenchymal transition, EMT). Uit literatuur en gen- en genoomanalyse blijkt dat een complex samenspel van signaalroutes de celcyclus en migratie regelt, waaronder de β-catenine en transforming growth factor β (TGF-β) route, de PI3K/Akt routeen de Rho-ROCK route.[36–43] Vooral de Rho-ROCK route reguleert een breed spectrum aan fundamentele cellulaire gebeurtenissen en is betrokken bij diverse pathologische aandoeningen. De remming ervan kan diverse signaalcascades op gang brengen en meerdere biologische effecten veroorzaken, zoals verhoogde proliferatie, verhoogde motiliteit of herschikking van het cytoskelet.

In het wondgenezingsproces kunnen endotheelcellen een EMT ondergaan en transformeren tot fibrogene myofibroblasten. Dit wordt grotendeels gemoduleerd door TGF-β [44,45] wat niet enkel Smad-signalen maar ook andere cytokines en groeifactoren activeert, zoals mitogen-activated protein kinase (MAPK) P38MAPK.[46–48] Omdat migratie een belangrijke component is van wondgenezing in het endotheel, mogen strategieën om het optreden van EMT van het endotheel te remmen niet gepaard gaan met aantasting van celmigratie.

Tijdens het wondgenezingsproces van het endotheel vullen de cellen een gat vooral op door middel van migratie en verhoogde celverspreiding[49], terwijl de celdeling erg laag blijft [34] en de cellen zich met name a-mitotisch delen waarbij tijdelijke binucleaire cellen ontstaan.[50] Succesvolle klinische opties voor het vervangen van ziek

endotheel zijn oa. het versnellen van de genezing van het endotheel en het onderdrukken van de EMT door lokale toediening van ROCK-inhibitor oogdruppels. Er zijn duidelijke aanwijzingen dat lokale ROCK-inhibitoren, toegediend na verwijdering van niet-confluente guttae (Descemet Stripping Only, DSO)[51,52] of na transplantatie van een gedevitaliseerd DM [53] voor de behandeling van FECD, de helderheid van de cornea bevorderen en de ECD verbeterden, terwijl de cellen over het geheel genomen ook een betere architectuur vertoonden. ROCK-inhibitoren speelden ook een belangrijke rol in de klinische trial voor het injecteren van gekweekte humane CEC in de voorste oogkamer.[54,55]

CEC migreren door tijdelijk een fibroblastmorfologie aan te nemen, waarbij actine wordt gereorganiseerd tot "stressvezels", hetgeen consistent is met EMT. EMT kan leiden tot fibrotische complicaties, zoals de vorming van een retro-corneaal fibreus membraan.[56] EMT en fibrotische veranderingen in het endotheel worden geïnduceerd door onder andere interleukine-1 beta (IL-1β), dat kan vrijkomen als reactie op veel "pathogen associated molecular patterns" (PAMPs) en TGF-β. Hoewel TGF-β genezing kan stimuleren, bevordert het ook fibrogene veranderingen waaronder afzetting van een afwijkende extracellulaire matrix (ECM).[57] Om deze respons tegen te gaan, bleek remming van TGF-β signalering door virale overexpressie van SMAD7[58] (een natuurlijke TGF-β signaleringsremmer) de remmende werking van TGF-β op celproliferatie te onderdrukken.[59] SMAD7-therapie wordt momenteel nuttig geacht voor preventie en behandeling van fibrogene aandoeningen in het endotheel.

Klinische scenario's waarbij corneale endotheelcelmigratie vereist is

Klinische studies naar wondgenezing zijn vaak beperkt tot observaties in gevallen van chemische verbranding van het oog,[60,61] of na vervanging van het abnormale cornea-endotheel door gezond donorweefsel.[62,63] In deze gevallen is herstel beschreven door enerzijds proliferatie van endotheelstamcellen uit specifieke gebieden van het oog (de met stamcellen verrijkte niche naast het perifere endotheel, de zogenaamde "inner transition zone")[64] en anderzijds gecombineerde migratie van zowel donor- als overblijvende ontvanger-endotheelcellen. Het wondgenezingsproces van het endotheel geeft echter aanleiding tot veel onbeantwoorde vragen. Onderzoek naar de migratie van endotheelcellen na Quarter-DMEK operatie (een aangepaste DMEK-techniek waarbij een volwaardig DMEK-transplantaat in vieren wordt verdeeld om vier ogen te behandelen),[8–10] kon de aanwezigheid van endotheelstamcellen in het gebied nabij de limbus niet bevestigen. Alle geopereerde ogen werden centraal helder, terwijl het perifere kale stroma aanhoudend oedeem vertoonde.[8] Het gebrek aan celmigratie vanuit dat specifieke gebied werd toegeschreven aan de rangschikking van collagene fibrillaire banden in de periferie van het transplantaat die als een barrière voor celmigratie werken[6], maar kan ook worden veroorzaakt door de verwijdering van (stam)cellen tijdens het prepareren van het Quarter-DMEK-transplantaat. Bij een DMEK-transplantaat met een diameter van 8–8.5 mm dat is geprepareerd met de no-touch peeling techniek, is de kans klein dat er endotheelschade optreedt, omdat er tijdens de preparatie buiten het aangeraakte gebied wordt getrepaneerd.[66,67] Bij de preparatie van Quarter-DMEK transplantaten moet het trabeculaire meshwork echter handmatig worden verwijderd[9] en deze technische stap kan de kwaliteit van het endotheel in de periferie aantasten.

De klinische resultaten van de Quarter-DMEK ogen lieten een ander ophelderingspatroon van de cornea zien, waarbij opheldering vooral optrad naast de gesneden randen, maar niet langs de "limbale" ronde rand van de Quarter-DMEK transplantaten en in de aangrenzende, kale stromale gebieden.[8,10] Deze observatie werd voornamelijk toegeschreven aan asymmetrische endotheelcelmigratie in verschillende anatomische gebieden van de cornea. Om heterogeen celmigratiegedrag, waarbij migratie vrijwel volledig afwezig is in de verre periferie van het endotheel, beter te kunnen begrijpen, zijn in vitro experimenten uitgevoerd om te bepalen hoe een Quarter-DMEK transplantaat het beste op het posterieure stroma van de ontvanger kan worden geplaatst om een homogener ophelderingspatroon te creëren in de cornea (Hoofdstuk 4). De belangrijkste experimentele uitdaging was om het weefsel, inherent geneigd om op te krullen, plat te houden in een vaste

positie op een oppervlak in vloeistof. Terwijl de Quarter-DMEK transplantaten ingeklemd werden tussen twee glazen dekglaasjes die ruimtelijk werden gescheiden door hechtdraad, werd deze constructie overgebracht naar een kweekplaat en werd de celmigratie gedurende zes dagen vastgelegd.[68] Hoewel de experimentele opzet nogal beperkend was voor de verspreiding van voedingsstoffen, was duidelijk dat endotheelcellen wel vanaf de radiale snijranden migreerden, maar niet vanaf de limbale ronde rand van de Quarter-DMEK transplantaten. Deze bevinding werd voornamelijk toegeschreven aan de Descemet membraan structuur, die de cellen organiseert in kleine radiale rijen, geïnduceerd door de groefachtige verdeling van de onderliggende collageenvezels.[65] Ook werd gesuggereerd dat endotheelcellen gedurende hun hele leven een continue, langzame, middelpuntzoekende migratie ondergaan vanuit diepere niches naar het centrum en hun stamcelfenotype verliezen in reactie op contact met het voorste oogkamervocht, met daarin de aanwezigheid van TGF-β, en door contactinhibitie zodra zij een monolaag vormen.[65] Om deze reden migreren perifere endotheelcellen waarschijnlijk niet naar buiten vanuit het transplantaat, maar kunnen ze nog wel een restproliferatievermogen bezitten.[69,70]

Driedimensionaal in vitro celkweek model: het concept en haar toepassingen

Concept omschrijving

Na de succesvolle poging om een klinische observatie te reproduceren met een in vitro systeem en met donorweefsel dat niet geschikt was voor transplantatie, werd besloten de kweektechniek te verbeteren om zo meer inzicht te verkrijgen in het beweeggedrag van het endotheel. Om reproduceerbare resultaten te verkrijgen en de technische belasting van de experimenten te verminderen, was echter verdere optimalisatie van het explantatiekweeksysteem nodig. Om deze reden werd een 3D kweektechniek ontwikkeld voor uitgenomen weefsel door gebruik te maken van een temperatuur-omkeerbaar hydrogelsysteem dat biocompatibel, niet toxisch, 100% synthetisch, pathogeenvrij en zeer transparant was zodat celobservatie mogelijk werd (Hoofdstuk 5). De temperatuur-afhankelijke viscositeit is een belangrijke eigenschap waardoor de gel kan opzwellen, zacht en flexibel wordt bij verwarming en vloeibaar wordt bij afkoeling. Deze eigenschap is erg nuttig om methoden te ontwikkelen om gekweekte cellen te oogsten voor specifiek geplande procedures[71,72] of om technieken te ontwikkelen om zonder enzymatische behandeling levensvatbare cellen te bewaren in de gel.[73] In deze studie hebben we het toepassingsgebied van de gel uitgebreid. Behalve dat de gel een effectieve kweekmatrix is die mechanische steun biedt en tegelijkertijd celadhesie stuurt, gaf hij massa aan de gekweekte cellen zonder de structuur en functionaliteit hiervan te verslechteren. In onze eerste in vitro cel migratiestudie met Quarter-DMEK transplantaten die werden ingeklemd tussen twee glasplaatjes, kon migratie ongeveer 7 dagen worden bestudeerd voordat de cellen stierven door onvoldoende toevoer van voedingsstoffen (Hoofdstuk 4).[75] Ook maakte de temperatuuromkeerbaarheid van de gel het mogelijk om vloeibaar gemaakte gel te verwijderen en biomoleculaire markers in het weefsel en de gemigreerde cellaag te detecteren, wat niet mogelijk was met de eerdere experimentele opzet.

Inductie van CEC mitosen in het perifere cornea-endotheel via gecontroleerde verstoring van contactinhibitie

Aangezien de nieuwe 3D kweekmethode de levensvatbaarheid en migratiecapaciteit van cellen uit donorweefsel verbeterde, zijn we verdergegaan met het testen van het effect van verschillende soorten perifere Quarter-DMEK transplantaten op endotheelcelmigratie (Hoofdstuk 6). Het doel van dit onderzoek was om de Quarter-DMEK graftpreparatietechniek verder te optimaliseren om op deze wijze bij patiënten de opheldering van de cornea aan de ronde zijde van de transplantaat te versnellen. Quarter-DMEK transplantaten met een intact en levensvatbaar endotheel werden ingebed in een gekoelde biocompatibele, temperatuur-omkeerbare polymeermatrix en vervolgens twee weken gekweekt in een bevochtigde atmosfeer.[76] De perifere rand van de Quarter-DMEK transplantaten werden ofwel radiaal ingesneden in de uiterste periferie, of delen ervan werden verwijderd met een trepaan. Na twee weken op kweek werd een immunohistochemische analyse

uitgevoerd op het weefsel uit de matrix. Deze toonde de aanwezigheid van dicht opeengepakte en levensvatbare cellen met een hoog migratievermogen aan de vookant van de monolayers die werden gevormd uit de radiaal ingesneden randen van de transplantaat.

Naast het krijgen van meer inzicht in de moleculaire signaalroutes die betrokken zijn bij endotheelcelmigratie (Hoofdstuk 3), richt het huidige onderzoek zich ook op de structuur-functierelatie van de adhesiestructuur van de endothele monolaag, die de cel in staat stelt om grip te hebben op zijn omgeving.[77,78] Verspreiding van cellen is een proces dat grotendeels bepaald wordt door twee onderling afhankelijke en interactieve systemen: het op integrine-gebaseerde systeem voor substraatadhesie en het actine cytoskelet, gekarakteriseerd door verschillende rangschikkingen van actinefilamenten.[79–81] Integrines en actine zijn gekoppeld door een fysieke koppeling die voorziet in grip om migratie mogelijk te maken. In collectieve celmigratie voeren cellen gespecialiseerde functies uit, afhankelijk van hun positie binnen de groep. 'Front-rear' polarisatie is een voorbeeld waarbij een subgroep van leidende cellen aan de voorkant een grotere groep volgcellen gidst.[82] Specifiek deze leidende cellen vertonen een mesenchymaal migratie-fenotype en functioneren door het afbreken en remodelleren van de ECM om zo kanalen te creëren voor de gehele celgroep om samen vooruit te gaan.[83,84] Volgcellen daarentegen behouden endotheeleigenschappen zoals apicale-basolaterale polariteit en tight junctions en ze brengen relatief weinig gidsreceptoren tot expressie. Deze cellen worden niet meegesleurd of geduwd door hun buurcellen, maar zij reageren actief op signalen van de leidende cellen.

Endotheelcelmigratie vanuit de limbale rand van de transplantaat werd echter niet uitgelokt door een grotere blootstelling van de cellen aan vrije ruimte door chirurgische aanpassingen in de periferie. Het gebrek aan migratie vanuit dit gebied was ook niet te wijten aan de afwezigheid van levensvatbare cellen, aangezien immunolokalisatie cellen liet zien die structurele (zonula occludens-1 eiwit ZO-1 en vimentine) en functionele markers (natrium/kalium ATPase (Na^+/K^+ –ATPase)) tot expressie brachten. In eerste instantie zou de gegroefde collageen microstructuur in het perifere gebied van de cornea gediend kunnen hebben als barrière, waardoor migratie werd tegengehouden. Tegelijkertijd zouden andere stimulus-specifieke genexpressiereacties nodig kunnen zijn om deze cellen aan te zetten tot migratie. Het is mogelijk dat belangrijke factoren die verantwoordelijk zijn voor de regulatie van celmigratie zoals cel-matrix adhesiemoleculen (zoals integrines, selectines en cadherines), de Rho-familie van kleine GTPase's en proteases (matrix-metallo proteases, MMPs), minder tot expressie komen in de perifere cellen. Wanneer functionele integrines ECM-liganden (fibronectine, laminine) herkennen om focale adhesie te vormen,[85] worden signaaleiwitten gerekruteerd naar die focale adhesie om hun opbouw en afbraak te regelen.[86] De Rho-familie van kleine GTPase's[87] is beschreven als belangrijke regulator van de dynamiek van focale adhesie, door het dicteren van contactassociatie, cel maturatie en omslag. Het loslatingsproces kan plaatsvinden door ECM-degradatie door MMP's[88,89] of door cellulaire contractiele machines (Rho en myosine II), die ervoor zorgen dat de cellen van onderen loslaten.[90,91] Alles bij elkaar genomen zijn bij celmigratie vele processen betrokken met meerdere kruisverbanden tussen leden van verschillende families, die de celbeweging beïnvloeden via wederzijds antagonistische pathways.[92]

Het bestuderen van het herstelvermogen van het perifere endotheel

Het feit dat endotheelcellen vanuit de verre periferie niet kunnen migreren, ondanks wijzigingen in het limbale gebied, beperkt nog steeds de klinische applicatie van de Quarter-DMEK. Inzicht in de aard van deze perifere endotheelcellen, hoe zij verschillen van centrale endotheelcellen en hoe zij soms wel tot migratie kunnen worden aangezet, zou de pool van donorweefsel die beschikbaar is voor patiënten die onmiddellijk een transplantaat nodig hebben sterk vergroten.

Na het onderzoeken van de gecontroleerde, mechanische verstoring van het perifere endotheel als mogelijke stimulans voor collectieve celmigratie, hebben we een in vitro onderzoek uitgevoerd om het potentieel van een

ROCK-inhibitor te evalueren en om perifere endotheelcelmigratie te stimuleren. Eerst is de vorm van het donorweefsel aangepast van een pizzapunt, zoals de Quarter-DMEK, naar een open ring (6.5 mm uitgeponst endotheel met het TM er nog aan vast), om een beter model te creëren voor het in vitro nabootsen van het in vivo effect van ROCK-inhibitor op de migratie. De pizzapunt Quarter-DMEK transplantaat werd geplaatst in een cirkelvormig descemetorhexis gebied of na DSO behandeling (Hoofdstuk 7). De gebogen buitenste randen van de transplantaat werden plat op een substraat geplaatst, een centrale voorwaarde voor het observeren van cel motiliteit, en werden langer dan een maand gekweekt in een 3D temperatuur-omkeerbare hydrogelmatrix. Dit maakte het mogelijk om te beoordelen of continue ROCK-inhibitie op lange termijn veranderingen oplevert in de migratiekenmerken van de endotheelcellen van de cornea. De resultaten, beschreven in Hoofdstuk 7, laten zien dat alle gekweekte randen levensvatbaar bleven en ofwel afzonderlijke regio's, ofwel collectieve gebieden van celmigratie vertoonden, onafhankelijk van de aan- of afwezigheid van de ROCK-inhibitor. De ROCK-inhibitor bleek daarentegen wel de morfologische stabiliteit van de gemigreerde cellen te verbeteren. Interessant genoeg werd ook op een later moment celmigratie vanuit een gebied dicht bij de limbus geobserveerd. Deze "late" cellen groeiden snel uit tot een contact- geïnhibeerde monolaag met de typische hexagonale celmorfologie (nadat ze eerst een fibroblastachtige morfologie aangenomen hadden) en leken minder gedifferentieerd in vergelijking met andere migratiegebieden. Deze laat-ontstane populatie van cellen vertoonde niet alleen een hoge proliferatiecapaciteit, maar kwam ook voort uit rim-transplantaten die waren gekweekt zonder ontregeling van de Rho-ROCK signaalroute. Hoewel het de celgroei vanuit de buitenrand van de transplantaat niet veranderde, bleek de aanwezigheid van ROCK-inhibitor gunstig voor het behoud van de celvorm en de cel-cel adhesiecontacten tijdens de collectieve migratie. Het vermogen van de ROCK-inhibitor om endotheliale wondgenezing van de cornea te bevorderen door het verbeteren van de endotheliale remodelering, adhesie en celmigratie was al eerder beschreven.[92]

Het brede scala aan celmigratiefenotypes in dit onderzoek verschilde van eerdere migratieonderzoeken met Quarter-DMEK transplantaten (Hoofdstuk 6).[76] De belangrijkste verschillen in experimentele aanpak waren de aanwezigheid van het TM dat aan het endotheel bleef kleven en de celmotiliteitonderzoeksperiode die aanzienlijk langer was dan twee weken. Het is dus mogelijk dat een bepaald celtype dat gelokaliseerd is in de insertiezone van het TM, langdurig gekweekt moest worden voordat het de kenmerken van niet-gedifferentieerde cellen vertoonde. Bij het evalueren van de levensvatbaarheid van de cellen viel het op dat de intensiteit van het Caleïne-AM varieerde over het gehele monster, waarbij de laagste signaalintensiteit overeenkwam met de celpopulatie afkomstig uit de verre periferie van het endotheel. We vermoeden dat deze laat ontstane, doch snel groeiende celpopulatie een lage intracellulaire esterase-activiteit heeft, die geen beschadigde membranen signaleert maar eerder een lage expressie van esterase-specifieke genen, die dient als een betrouwbare indicator van niet-gedifferentieerde cellen.[93] Vergelijkbaar met onze gekweekte uitgenomen donorweefsels, toonde ook Zhang et al.[94] cellen aan die prolifereerden uit perifere gebieden van het hoornvlies met vergelijkbare morfologische kenmerken tijdens celgroei, timing en uiteindelijke celmorfologie. Bovendien werd met behulp van kwantitatieve polymerase chain reaction (qPCR) vastgesteld dat de gekweekte cellen in hun onderzoek aanvankelijk verhoogde niveaus van stamcelgenen en minimale niveaus van pluripotentie tot expressie brachten, en dat deze genexpressieniveaus in kweek omkeerden. De conclusie was dat cellen in het gebied van Schwalbe's ring, een overgangsgebied tussen het perifere endotheel van het hoornvlies en het voorste niet-gefilterde deel van het TM (gezamenlijk de "transitiezone", TZ, genoemd), kernmerken vertoonden van volwassen stamcellen.

Over het algemeen lijken deze cellen een aparte celpopulatie te vormen met duidelijke ultrastructurele kenmerken en met een welvelvormig patroon in de periferie van het achterste hoornvlies.[95] Hoewel werd voorgesteld dat de cellen een neuroregulerende functie hebben in het anterieure segment[96] bleken ze ook verantwoordelijk te zijn voor de vorming van een afwijkend endotheelmembraan dat het anterieure uveale netwerk bedekt bij sommige patiënten die voor glaucoom werden behandeld met argonlaser trabeculoplastiek (ALT).[97,98] Bovendien suggereert de hogere ECD in de perifere gebieden van de cornea, vergeleken met die

van de centrale gebieden (gemiddeld 17–23%), ook dat stamcelachtige cellen aanwezig kunnen zijn in het perifere overgangsgebied om gedifferentieerde CEC te leveren. Daarnaast is eerder beschreven dat onder bepaalde omstandigheden mitose optreedt in het endotheel van de volwassen cornea van de mens[100,101] en dat het percentage cellen dat kan delen, perifeer hoger is dan centraal, onafhankelijk van donorleeftijd.[102] Deze bevindingen suggereren dat de perifere CEC regeneratieve capaciteit bezitten en mogelijk nieuwe cellen voor het endotheel kunnen leveren. Alhoewel moleculaire merkerstudies voor de stamcelniche in de overgangszone hiervoor ondersteunende gegevens opleveren[103,104], is tot nu toe nog niet definitief vastgesteld dat de TZ endotheliale stamcellen herbergt.[105] Pogingen om ongedifferentieerde stamcellen te isoleren en te vermeerderen met behulp van een bol kweekoppervlak bleken efficiënter wanneer perifeer endotheel gebruikt werd vergeleken met centraal endotheel.[107–110] Er moet nog worden vastgesteld of de cellen van Schwalbe, TZ-cellen en stamcellen/voorlopers hetzelfde celtype zijn, in hoeverre zij hun regeneratieve potentieel behouden en hoe de celproliferatie in vivo zou kunnen worden ontsloten om het endotheel opnieuw te bevolken bij ouderdom en bij ziekte.

Het verbeteren van de chirurgische techniek door integratie van in vitro celkweek observaties

Terwijl wij probeerden EC-migratie vanuit het perifere hoornvlies te begrijpen en tegelijkertijd bevorderen, zette de lage postoperatieve ECD na Quarter-DMEK ons aan om ons te richten op verdere verbetering van de techniek. We vermoedden dat de aanzienlijke ECD-afname na Quarter-DMEK[8,10] werd veroorzaakt door de vorm-mismatch tussen de ronde descemetorhexis en het driehoekige transplantaat. In een poging de ECD-afname te verminderen werd een nieuwe chirurgische optie getest waarbij DMEK-transplantaten met een kleine diameter werden geprepareerd, om te passen bij een kleine descemetorhexis. Deze werd in vitro gevalideerd onder meerdere experimentele omstandigheden (Hoofdstuk 8). De voornaamste bevindingen van dit onderzoek waren: (1) drie cirkelvormige mini-DMEK's met een diameter van 4 mm kunnen succesvol worden geprepareerd uit één donorcornea, (2) de chirurgische procedure kon in vitro worden gevalideerd en (3) transplantaten met een kleine diameter, ingebed in temperatuur-omkeerbare hydrogelmatrix, vertoonden uniforme celmigratie rond de volledige, cirkelvormige transplantaat rand met cellen die een typische hexagonale, dichtopeengepakte morfologie vormden.[111] Vergelijkbaar met de Quarter-DMEK biedt de transplantatie van een klein transplantaat het theoretische voordeel van verminderde donor-antigeenbelasting en kan gebruik gemaakt worden van donorcornea's met meerdere littekens na een staaroperatie. Aanvankelijk werden transplantaten met een diameter van 4 mm (mini-DMEK) beschreven als behandeling van acute corneahydrops bij keratoconus (dat wil zeggen, breuk en loslating van een stijf DM als gevolg van toenemende dikte van het corneale stroma).[112,113] Niet alleen waren de vorm en grootte van de DMEK-transplantaten die werden gebruikt om de scheur in het DM te sluiten niet gestandaardiseerd (een 5 mm, ronde DMEK-transplantaat of een met een mes gesneden transplantaat van 3 mm breed en met een lengte die was aangepast aan de lengte van de scheur in het DM van de patiënt), ook de oriëntatie van het transplantaat was niet belangrijk voor de operatie, vermoedelijk omdat het gezonde endotheel van de patiënt het DM makkelijk zou herbevolken, zelfs als de transplantaat per ongeluk was omgekeerd.[113]

In een meer recente studie gebruikten Handel et al.[114] mini-DMEK transplantaten om chronische focale corneale endotheeldecompensatie te behandelen, die veroorzaakt was door scheuren in het DM na intraoculaire operaties of cornea-oedeem in het gebied van Haab-striae bij buphthalmos. Het hoornvlies was gezond en er was geen ziekte aanwezig, behalve het DM-defect. De mini-DMEK transplantaten werden van het resterende DM getrimd tot een lengte en breedte gelijk aan de scheur in het DM van de patiënt, terwijl het centrale DM werd gebruikt voor patiënten met FECD. Hoewel de cornea's in alle gevallen dun werden, bleef de rol van endotheelcellen in kleine DM-defecten onduidelijk.

DMEK transplantaten met een kleine diameter hebben hiernaast het voordeel dat met één donorcornea drie patiënten voorzien kunnen worden van weefsel en men zo een milde FECD met guttae kan behandelen, indien

deze zich beperken tot het centrale gebied van 4 mm. Om de “no-touch” behandeling in stand te houden bij transplantaten van klein formaat zijn tot dusver twee alternatieve methoden klinisch getest, namelijk DSO en transplantatie van het acellulaire DM (in andere woorden, DM transplantatie, DMT).[115–120] DSO vertegenwoordigt een donor-onafhankelijke werkwijze bij centrale FECD, een aanpak die uitgebreid is beschreven in Hoofdstuk 4, terwijl DMT een strategie vertegenwoordigt voor het gebruik van niet-klinisch DMEK weefsel. Beide technieken kunnen mogelijk FECD te behandelen, zonder de noodzaak van allogene transplantatie en angst voor afstoting, maar DMT biedt toch een geschikter substraat dat de migratie van het endotheel van de patiënt ondersteunt met verminderd risico op EMT.[53] Bovendien wordt het stroma afgesloten met behulp van TGF-β, om keratocietactivatie in de buurt van de wond tegen te gaan, wat anders kan leiden tot fibrose en verhoogd risico op retrocorneale membraanvorming.[122,123] Zowel DSO als DMT gaan echter gepaard met een langere hersteltijd, waarbij volledige anatomisch en visueel herstel niet binnen 3 maanden postoperatief bereikt worden.

DMEK-transplantaten met een kleine diameter toonden vooruitstrevende chirurgische mogelijkheden met verbeterde graftkenmerken (ECD, levensvatbaarheid van het transplantaat, uniforme celmigratiecapaciteit). Doordat de vorm overeenkomt met de cirkelvormige descemetorhexis zou het klinisch herstel vergelijkbaar kunnen zijn met de conventionele DMEK. Resultaten van klinische tests zullen meer duidelijkheid geven over de doeltreffendheid van DMEK-transplantaten met kleine diameter voor behandeling van milde FECD.

Toekomstperspectieven

De DMEK is tegenwoordig de gouden standaard voor het behandelen van corneale endotheel disfunctie. Sinds de introductie ervan is DMEK superieur ten opzichte van de PK en andere keratoplastiek technieken wanneer men spreekt over sneller visueel herstel, lagere afstotingspercentages, betere refractieve resultaten en een grotere structurele integriteit.[124–128] Het aantal DMEK-procedures is hierdoor wereldwijd toegenomen, met name in patiënten met Fuchs endothelial corneal dystrophy (FECD).

Door enkel het zieke weefsel te vervangen belichaamt een DMEK conceptuele eenvoud en chirurgische verfijning. Het voornaamste probleem van endotheliale keratoplastiek is dan ook het chronische verlies van endotheelceldichtheid (ECD) over de tijd, wat vergelijkbaar is met een PK.[124,131,132] Het effect van verschillende donor- en patiënt-gerelateerde parameters op het verlies van het endotheel is onderzocht in verschillende studies, echter zonder consistent resultaat.[15,133–140] De intraoculaire behandeling van het 15-20 µm dunne membraan en de preoperatieve, handmatige preparatie van de graft vormen echter wel technische uitdagingen die het uiteindelijke resultaat kunnen beïnvloeden.

We hebben verschillende onderzoeken gedaan om de postoperatieve ECD-daling beter te begrijpen, zoals beschreven in dit proefschrift. Eén aspect hiervan betreft de overschatting van de levensvatbaarheid van de graft in de oogbank,[30] wat op zijn beurt resulteert in een onrealistisch hoge daling van het ECD in de vroege postoperatieve fase na DMEK.[20] Grafts lijken uitgesproken endotheelschade te ontwikkelen, zelfs na een normaal verlopende preparatie. Echter kan het uitvoeren van een DMEK-operatie met suboptimale endotheel kwaliteit het risico van loslating of vroegtijdig falen van het transplantaat vergroten.[14] Hoewel er fluorescerende kleurstoffen kandidaat staan om de levensvatbaarheid (levende en apoptotische cellen) te visualiseren, kunnen regelgevingen, veiligheids- en economische overwegingen banken ervan weerhouden om een dergelijke stap aan hun protocol toe te voegen. Een oplossing op korte termijn zou kunnen zijn om de weefselkwaliteit nog te controleren vlak voor de operatie. Hoewel een stap als deze kan leiden tot toename van het afkeuringspercentage, terwijl het weefsel al schaars is, kan het wél resulteren in een lager percentage her-transplantaties. Een andere strategie kan het verbeteren van de donorcornea kwaliteit zijn door het opslagmedium de boosten met farmacologische modulatoren die de regeneratie van het endotheel kunnen bevorderen en door een laag niveau van oxidatieve stress te handhaven. Bovendien zou het opslaan van de

cornea in een bioreactor, in plaats van zwevend in een afgesloten fles, de drukgradiënt kunnen creëren die equivalent is aan de intraoculaire druk. Dit zal gepaard gaan met een voortdurende vernieuwing van het opslagmedium, het verminderen van de corneale zwelling en verhogen van de levensvatbaarheid van de EC.[141,142] Er is echter wel verder onderzoek nodig om de veiligheid en therapeutische relevantie van deze opties te evalueren.

Als poging om het weefseltekort te verhelpen, zou het gebruik van de Quarter-DMEK de pool van donorweefsel kunnen vervierdvoudigen. De techniek kan echter baat hebben bij enkele verdere aanpassingen om de ECD-uitkomsten te verbeteren. *In vitro* onderzoek naar de migratie van het endotheel, wat is opgenomen in dit proefschrift, toonde aan dat de ronde perifere rand van een Quarter-DMEK graft een fysieke barrière vormt voor cel migratie [68,76] tenzij stamcel-achtige cellen, onlangs ontdekt in gebieden dichtbij de limbus [64], kunnen worden “ontwaakt” om voldoende dehydratatie van de cornea te induceren. Door het preparatieprotocol aan te passen om de ronde, perifere rand van de Quarter-DMEK te verwijderen, kan een kleine diameter DMEK een snelle en uniforme verheldering van de cornea bieden en een levensvatbare klinische optie worden voor de behandeling van centrale endotheel ziekten.[111]

Het beperkte aantal donorcornea’s van hoge kwaliteit en de operatieve complexiteit van de DMEK, hebben geleid tot aanzienlijke onderzoeksinteresse in de ontwikkeling van alternatieve technieken die efficiënter gebruik van donorweefsel bevorderen of de noodzaak van het implanteren van donorweefsel volledig wegnemen.

Tot op de dag van vandaag zijn er echter geen therapeutische alternatieven beschikbaar voor de behandeling van ziek endotheel, naast hoornvliestransplantaties. De huidige weefsel preparatie benaderingen voor hoornvlies vervanging zijn echter veelbelovend voor klinische toepassingen. Om het tekort aan donorcornea’s te verhelpen, hebben onderzoekers twee basisbenaderingen voor weefsel preparatie toegepast: op cellen gebaseerde strategieën, om de cellen in staat te stellen hun eigen extracellulaire matrix (ECM) te creëren, en “scaffold” gebaseerde strategieën, om sterke en biocompatibele matrixen t leveren waarop cellen kunnen groeien.[143–146] Onafhankelijk van de strategiekeuze is *in vitro* expansie of de novo generatie van corneale endotheelcellen (CEC) vanuit pluripotente stamcellen of andere cel-bronnen vereist.[147,148] De belangrijkste uitdaging voor de *in vitro* proliferatie van volledig gedifferentieerde cellen is om het fenotype te behouden, om zo de endotheliale tot mesenchymale transitie (EMT) tegen te gaan, wat anders resulteert in CEC die hun normale morfologie verliezen en fibrose kunnen induceren. Het alternatief van CEC differentiatie vanuit pluripotente stamcellen of andere cel-bronnen zoals van beenmerg afgeleide endotheel-precursoren, neurale kribcellen, stromale stamcellen, huid-afgeleide precursoren of mesenchymale stamcellen, vereist geschikte kweekprotocollen die moeten voldoen aan wettelijke richtlijnen om te garanderen dat de uiteindelijke cel-bron op CEC lijkt.[148–154] Hoewel de richtlijnen wat betreft goede fabricage praktijken kunnen verschillen aan de hand van het land/de regio waarin deze zijn vastgesteld, is er dringend behoefte aan standaardisering van de parameters waaraan gegenereerde CEC moeten voldoen wanneer deze in hun “eindstadium” zitten. Daarom moet de lijst van kwaliteitscriteria worden herzien voor: (i) beoordeling van de morfologie door controle van de hexagonaliteit van de cellen bij het bereiken van confluentie in kweek, ii) genotype en fenotype door onderzoek van structurele en functionele markers, iii) behoud van het karyotype door controle van de integriteit van het DNA, om aan te tonen dat er geen grove chromosoomafwijkingen zijn, en (iv) functionaliteit gecontroleerd *in vitro* met instrumenten die de ionendoorlaatbaarheid over een monolaag van cellen meten, ex vivo met hoornvliezen in een omgeving die fysiologische omstandigheden nabootst en de meting van hoornvliesdikte mogelijk maakt en verder correleert met cel functionaliteit, of *in vivo* met diermodellen van hoornvliesoedeem. [155]

Na alle uitdagingen met CEC-kweek wat betreft cellulair profiel, proliferatieve capaciteit en downstream analyse, moeten de cellen levend worden afgeleverd en met voldoende potentieel om zich te hechten aan het achterste deel van het hoornvlies. De "cel gebaseerde" strategie stelt de levering van CEC voor op een eenvoudige en minimaal invasieve manier via injectie in de voorste oogkamer.[155] Na de procedure, door de

patiënt gedurende 3 uur in buikligging te plaatsen, kan de zwaartekracht de hechting van CEC aan het posterieure deel van het hoornvlies vergroten. De proof-of-concept klinische studie van Kinoshita en medewerkers toonde aan dat cornea-oedeem kon worden omgekeerd door ongeveer 1x106 gekweekte menselijke CEC, aangevuld met ROCK-inhibitor Y-27632, in de voorste kamer te injecteren na het mechanisch schrapen van het zieke endotheel; de helderheid van het hoornvlies bleef ten minste 5 jaar postoperatief behouden.[54,55] Bovendien suggereert de meest recente verfijning van de techniek dat injectietherapie met behulp van sterk gezuiverde, volgroeide, gekweekte menselijke CEC voor endotheel-falen veiliger is, zorgt voor een snel herstel van de dikte van het hoornvlies, een betere ECD en een laag uitvalpercentage van de cellen gedurende 3 jaar na de operatie.[156] Er zijn echter grotere, toekomstige, willekeurig gekozen gecontroleerde onderzoeken nodig om de doeltreffendheid en veiligheid op lange termijn te garanderen.

De belangrijkste uitdaging voor de "scaffold-gebaseerde" strategie is het verkrijgen van een monolayer van CEC op een biocompatibele drager, om zo bio-engineered grafts te produceren.[145] Het gebruik van een drager die cel replicatie ondersteunt is een aantrekkelijke benadering, omdat het het bijkomende voordeel heeft dat een functionele monolayer met contactinhibitie op de juiste plaats en op een gecontroleerde manier wordt afgeleverd. Bovendien zijn er minder cellen nodig om de drager te bevolken dan bij cel injectie, waardoor het aantal patiënten dat er baat bij kan hebben, toeneemt. Uitgaande van een oppervlakte van 57 mm^2 (8,5 mm diameter graft) en een uiteindelijke ECD van 2300 cellen/mm^2 (gebruikelijke drempelwaarde die door oogbanken is vastgesteld), zou een graft ongeveer 1,3 x 10^5 CEC moeten bevatten. Op basis van een eenvoudige berekening zouden deze CEC's die zijn gebruikt voor de behandeling van 11 patiënten door middel van cel injectie, hypothetisch 84 dragers kunnen bevolken en patiënten kunnen behandelen met een toedieningsstrategie die vergelijkbaar is met DMEK of DSEK. Een ideale biocompatibele drager moet wel de belangrijkste architecturale en functionele kenmerken van het DM nabootsen en daarom dicht, relatief transparant, semi-permeabel, flexibel (in verband met de vorm van het hoornvlies), biocompatibel, dik genoeg om voldoende mechanische sterkte te bieden, bevorderlijk voor celadhesie en fenotype, en misschien biologisch afbreekbaar zijn, om cellen in staat te stellen hun eigen DM te produceren en tegelijkertijd de omringende scaffold af te breken. Veel *in vitro* studies hebben veelbelovende onderzoeksresultaten gerapporteerd bij het gebruik van natuurlijke weefsels zoals acellulaire biologische membranen (bijv. amniotisch membraan, ontleed DM of stroma van zowel menselijke als dierlijke oorsprong, menselijk voorste lenskapsel)[157–167] of (natuurlijke en synthetische) polymere materialen.[161,168–192] Latere *in vivo* tests van endotheelceldragervellen (geprepareerd vanuit donorweefsel) in diermodellen hebben echter geen van de constructen geschikt bevonden voor klinische toepassing.[160,193–195]

De optie om het transplantaat helemaal te verwijderen en iemands eigen endotheelcellen te laten herverdelen werd geïntroduceerd door Descemet stripping only (DSO), voor de behandeling van vroege FECD. In een primaire analyse van DSO leidde de verwijdering van een gebied met een diameter van 6 mm van het zieke DM tot een onvolledig herstel.[116,196] Er werden betere verhelderingspercentages gemeld wanneer een kleinere (4–5 mm) descemetorhexis werd toegepast, bij een select aantal relatief jonge patiënten met centrale guttae en een adequate perifere endotheelreserve.[116,197] Ondanks deze beperkingen heeft DSO het voordeel dat het afstotingspercentage 0% is (er is namelijk geen risico op immunologische afstoting van het transplantaat) en dat het niet nodig is om langdurig topische corticosteroïden te gebruiken om afstoting van het transplantaat te voorkomen, waardoor het neveneffect van verhoging van de intraoculaire druk wordt verminderd. DSO is echter nog geen vervanging voor DMEK om twee belangrijke redenen: (1) het vrijmaken van een kleiner gebied kan nog steeds leiden tot suboptimaal zicht, en (2) het cornea oedeem kan maandenlang aanhouden, waardoor het visueel herstel wordt belemmerd en het resultaat onvoorspelbaar is.[119] Het succes kan worden verbeterd door bij deze techniek farmacologische modulatoren te gebruiken, zoals Rho-geassocieerde proteïne kinase (ROCK) inhibitors.[118] Hoewel de biologische werking van ROCK-inhibitors niet volledig wordt begrepen, is beschreven dat zij het visueel herstel aanzienlijk versnellen, hogere aantallen centraal endotheel induceren wanneer hersteld én met een verbeterde cel architectuur.[52] DSO kan om deze reden een geschikte

chirurgische behandelingsoptie zijn, voorafgaand aan DMEK of kleine diameter-DMEK voor degenen die willen proberen of enkel strippen hun visusproblemen zal oplossen. Er zijn echter meer studies nodig om het effect van DSO in combinatie met farmacologische geneesmiddelen op de klinische werkzaamheid en de veiligheid van de geneesmiddelen op langere termijn te beoordelen.

Een mogelijke combinatie-techniek tussen DSO en conventionele, circulaire DMEK maakt gebruik van endotheel-graft vervangers, bestaande uit weefselafgeleide of synthetische matrixen.[120,198,199] Transplantatie van een acellulaire DM bij een patiënt is onlangs gemeld als onderdeel van een groter klinisch onderzoek in Singapore [identificatienummer NCT03275896]. De patiënt werd getransplanteerd met een acellulair membraan van 4 mm en vertoonde een verbetering van gezichtsvermogen met vier regels, al zes maanden na de transplantatie, met een bijna normale restauratie van de centrale dikte van het hoornvlies en ECD-waarden vergelijkbaar met DSO.[120] Als alternatief is een synthetisch graft substituut (EndoArt) geïmplanteerd om het hoornvliesoedeem om te keren en het herstel van het gezichtsvermogen te bevorderen.[198] Bevestigd aan de achterkant van het hoornvlies, zou EndoArt de overdracht van vloeistoffen naar het hoornvlies moeten voorkomen en de vochtophoping die leidt tot oedeem moeten remmen. Een samenvatting van de eerste resultaten voor twee patiënten als onderdeel van een multicenter, prospectief haalbaarheidsonderzoek [identificatienummer NCT03069521] toonde aan dat de patiënten een vermindering van het hoornvliesoedeem hadden met herstel van de transparantie na implantatie van EndoArt. Beperkingen van de implantatie van dit synthetische construct omvatten: (i) regelmatige herpositionering door rebubbling tot volledige hechting aan het stromale bed, (ii) onduidelijke tijdspanne gedurende welke de cornea transparant en goed gehydrateerd blijft, (iii) langetermijneffect van beperking van de diffusie van vitamine en essentiële voedingsstoffen uit het kamervocht naar de cornea en (iv) onvermogen van endotheelcellen om te migreren en de kunstmatige laag te bevolken. Over het geheel genomen zullen substituten voor transplantaten van natuurlijke of kunstmatige oorsprong nog moeten worden geëvalueerd in grote klinische proeven met follow-up-resultaten op lange termijn om het succes van hun toepassing verder te bepalen en ook de juiste doelgroepen te identificeren.

Een andere manier om de beschikbaarheid van hoornvlies donorweefsel te vergroten, is de behandeling van de genetische aandoening om zo de noodzaak van een hoornvliestransplantatie te “vervangen”. De huidige strategieën die de genetische verandering kunnen corrigeren of de bijbehorende effecten kunnen voorkomen, zijn gen vergrotingstherapie (Gene Augmentation Therapy, GAT), op antisense oligonucleotide gebaseerde modulatie (AON), en op CRISPR/Cas9 gebaseerde modulatie.[200–205] Er is ook gemeld dat de pathofysiologie van FECD zich manifesteert door een combinatie van verschillende genetische en niet-erfelijke factoren, zoals kanaaldisfunctie (bijv. Solute Carrier family 4 member 11 - SLC4A11), abnormale extracellulaire matrix depositie (bijv. collageen type VIII alpha 2 keten - COL8A2), RNA toxiciteit, oxidatieve stress (bijv. Nuclear factor, erythroid 2 like 2 Transcription factor - NRF2), en apoptose (bijv, Zinc finger E-box Binding homeobox 1 - ZEB1).[206,207] De meest voorkomende genetische verandering bij FECD is een microsatellietregio bestaande uit CTG trinucleotide herhalingen (TNR's) in het vierde intron van het TCF4-gen, wat abnormaal wordt verlengd. Hoewel het mechanisme dat verantwoordelijk is voor het effect van deze trinucleotide-expansie op het TCF4-gen onduidelijk is, zal het bijdragen aan cellulaire disfunctie door het triggeren van RNA splicing fouten. De genetische modulatie van TCF4-expressie gebeurt ofwel door het overbrengen van een functionerende kopie van dit defecte gen, met als doel de ziekte te corrigeren door het introduceren van antisense oligonucleotiden zoals small interference RNA (siRNA) of micro-RNA (miRNA) die de toxische effecten van het defecte gen kunnen verminderen, of door het elimineren van de CTG-uitbreiding om de mutatie die FECD veroorzaakt terug te draaien.[208–214] Verder onderzoek is ook nodig om de immuun-tolerantie ten opzichte van de transgenproducten na herhaalde toediening in de voorste oogkamer te onderzoeken, de meest efficiënte en kosteneffectieve toedieningsmethoden te vinden en de off-target effecten te identificeren.

In de afgelopen jaren is het gebruik van farmaceutische middelen voor de behandeling van corneale endotheelziekten onderzocht.[35] Het principe berust op het bevorderen van cel overleving, proliferatie en migratie met een minimaal invasieve benadering van intra-camerale of topische toediening van geneesmiddelen. ROCK-inhibitors zijn de meest bestudeerde geneesmiddelen met groot potentieel om het herstel van CEC *in vivo* bij de mens op gang te brengen, wanneer ze plaatselijk worden toegediend als adjuvans voor DSO.[51,52] Wereldwijde wordt gemeld dat ROCK-inhibitors succesvol zijn in het omkeren van cornea-oedeem na het operatief verwijderen van zieke CEC, het herstellen van de anatomie van het hoornvlies na gedeeltelijk losgemaakte DM in BK-ogen na cataractchirurgie, en het regenereren van het endotheel door een vermoedelijke toename van de cel proliferatie.[118,215–217] Ook is veelbelovend onderzoek gemeld voor andere farmaceutische geneesmiddelen, zoals epidermale groeifactor, uit bloedplaatjes afgeleide groeifactor en fibroblast-groeifactoren.[218–220] Deze moeten echter voorzichtig worden toegediend aangezien er sprake is van een tweeledig werkingsmechanisme, dat wil zeggen, regeneratiepotentieel met het risico van het veroorzaken van een ongewenste ongewenste verandering van endotheliale naar mesenchymale fenotype. Er is ook aandacht besteed aan het verminderen van oxidatieve stress door de up-regulatie van transcriptiefactoren om de expressie van anti-oxidatieve stresseiwitten te bevorderen, waardoor de CEC-apoptose afneemt.[221–226] Ook is voor het profileren van nieuwe kandidaat-geneesmiddelen een systematisch onderzoek nodig van het functionele effect in een verscheidenheid van *in vitro* en *in vivo* assays. Bovendien vereist de toewijzing van patiënten in een klinische studie uitgebreide kennis over de te behandelen ziekten. Om eventuele gunstige effecten van de bovengenoemde kandidaat-geneesmiddelen te concluderen, moeten grote, gerandomiseerde controleproeven worden uitgevoerd om bewijsmateriaal van een hoger niveau te genereren.

Conclusies

Ondanks aanzienlijke vooruitgang op het gebied van therapieën om de regeneratie van het endotheel te bevorderen, is er nog een lange weg te gaan voordat dergelijke therapieën zijn goedgekeurd door de regelgevende instanties en routine worden in de klinische praktijk. Tot op heden is vervanging van het zieke endotheel door DMEK nog steeds de meest efficiënte behandelingsoptie voor endotheel disfuncties, maar het aantal procedures wordt nog steeds beperkt door een wereldwijd tekort aan geschikte en beschikbare donoren, vooral in delen van de wereld waar weinig middelen beschikbaar zijn. Door de corona pandemie zijn de uitsluitingscriteria voor weefsels bovendien nog strenger geworden, waardoor de pool van beschikbare donoren aanzienlijk wordt beperkt.[227] Het is van essentieel belang dat de toegevoegde waarde van het donatieproces aan de mensen duidelijk wordt gemaakt, zodat zij worden gestimuleerd om zich voor donatie te laten registreren omdat zij waarschijnlijk meer baat hebben bij het systeem dan dat zij eraan bijdragen,[228–230] terwijl ondertussen nieuwe behandelingsmogelijkheden worden ontwikkeld en in de klinische praktijk worden omgezet.

Referenties

1. Tuft SJ, Coster DJ. The corneal endothelium. Eye (Lond). 1990;4 (Pt 3):389-424. https://doi.org/10.1038/eye.1990.53 PMID: 2209904
2. Wong KH, Kam KW, Chen LJ, Young AL. Corneal blindness and current major treatment concern-graft scarcity. Int J Ophthalmol. 2017 Jul 18;10(7):1154-1162. https://doi.org/10.18240/ijo.2017.07.21 PMID:28730122
3. Gain P, Jullienne R, He Z, Aldossary M, Acquart S, Cognasse F, et al. Global survey of corneal transplantation and eye banking. JAMA Ophthalmol. 2016 Feb;134(2):167-73. https://doi.org/10.1001/jamaophthalmol.2015.4776 PMID: 26633035
4. Lam FC, Baydoun L, Dirisamer M, Lie J, Dapena I, Melles GRJ. Hemi-Descemet membrane endothelial keratoplasty transplantation: a potential method for increasing the pool of endothelial graft tissue. JAMA Ophthalmol. 2014 Dec;132(12):1469-73. https://doi.org/10.1001/jamaophthalmol.2014.3328 PMID: 25211529
5. Birbal RS, Hsien S, Zygoura V, Parker JS, Ham L, van Dijk K, et al. Outcomes of Hemi-Descemet membrane endothelial keratoplasty for Fuchs endothelial corneal dystrophy. Cornea. 2018 Jul;37(7):854-858. https://doi.org/10.1097/ICO.0000000000001578 PMID: 29557816
6. Müller TM, Baydoun L, Melles GRJ. 3-Year update on the first case series of Hemi-Descemet membrane endothelial keratoplasty. Graefes Arch Clin Exp Ophthalmol. 2017 Jan;255(1):213-215. https://doi.org/10.1007/s00417-016-3517-5 PMID: 27783157
7. Baydoun L, Zygoura V, Hsien S, Birbal RS, Spinozzi D, Lie JT, et al. Clinical feasibility of using multiple grafts from a single donor for Quarter-DMEK. Acta Ophthalmol. 2018 Aug;96(5):e656-e658. https://doi.org/10.1111/aos.13720. PMID: 29498213
8. Zygoura V, Baydoun L, Ham L, Bourgonje VJA, van Dijk K, Lie JT. Quarter-Descemet membrane endothelial keratoplasty (Quarter-DMEK) for Fuchs endothelial corneal dystrophy: 6 months clinical outcome. Br J Ophthalmol. 2018 Oct;102(10):1425-1430. https://doi.org/10.1136/bjophthalmol-2017-311398 PMID: 29343529
9. Müller TM, Lavy I, Baydoun L, Lie JT, Dapena I, Melles GRJ. Case report of Quarter-Descemet membrane endothelial keratoplasty for Fuchs endothelial dystrophy. Cornea. 2017 Jan;36(1):104-107. https://doi.org/10.1097/ICO.0000000000001008 PMID: 27583798
10. Birbal RS, Ni Dhubhghaill S, Baydoun L, Ham L, Bourgonje VJA, Dapena I, et al. Quarter-Descemet membrane endothelial keratoplasty: one- to two-year clinical outcomes. Cornea. 2020 Mar;39(3):277-282. https://doi.org/10.1097/ICO.0000000000002127 PMID: 31490274
11. Català P, Thuret G, Skottman H, Mehta JS, Parekh M, Ní Dhubhghaill S, et al. Approaches for corneal endothelium regenerative medicine. Prog Retin Eye Res. 2022 Mar;87:100987. https://doi.org/10.1016/j.preteyeres.2021.100987 PMID: 34237411
12. Deng SX, Lee WB, Hammersmith KM, Kuo AN, Li JY, Shen JF, et al. Descemet membrane endothelial keratoplasty: safety and outcomes: a report by the American Academy of Ophthalmology. Ophthalmology. 2018 Feb;125(2):295-310. https://doi.org/10.1016/j.ophtha.2017.08.015 PMID: 28923499
13. Terry MA. Endothelial keratoplasty: why aren't we all doing Descemet membrane endothelial keratoplasty? Cornea. 2012 May;31(5):469-71. https://doi.org/10.1097/ICO.0b013e31823f8ee2 PMID: 22367047
14. Vasiliauskaitė I, Quilendrino R, Baydoun L, van Dijk K, Melles GRJ, Silke Oellerich. Effect of six-month postoperative endothelial cell density on graft survival after Descemet membrane endothelial keratoplasty. Ophthalmology. 2021 Dec;128(12):1689-1698. https://doi.org/10.1016/j.ophtha.2021.05.022 PMID: 34033824
15. Vasiliauskaitė I, Oellerich S, Ham L, Dapena I, Baydoun L, van Dijk K, et al. Descemet membrane endothelial keratoplasty: ten-year graft survival and clinical outcomes. Am J Ophthalmol. 2020 Sep;217:114-120. https://doi.org/10.1016/j.ajo.2020.04.005 PMID: 32283096
16. Calvo-de-Mora MR, Quilendrino R, Ham L, Liarakos VS, van Dijk K, Baydoun L, et al. Clinical outcome of 500 consecutive cases undergoing Descemet's membrane endothelial keratoplasty. Ophthalmology. 2015 Mar;122(3):464-70. https://doi.org/10.1016/j.ophtha.2014.09.004 PMID: 25439596
17. Ham L, Dapena I, Liarakos VS, Baydoun L, van Dijk K, Ilyas A, et al. Midterm results of Descemet membrane endothelial keratoplasty: 4 to 7 years clinical outcome. Am J Ophthalmol. 2016 Nov;171:113-121. https://doi.org/10.1016/j.ajo.2016.08.038 PMID: 27609712
18. Hayashi T, Schrittenlocher S, Siebelmann S, Le VNH, Matthaei M, Franklin J, et al. Risk factors for endothelial cell loss after Descemet membrane endothelial keratoplasty (DMEK). Sci Rep. 2020 Jul 6;10(1):11086. https://doi.org/10.1038/s41598-020-68023-0 PMID: 32632151

19. Quilendrino R, Höhn H, Tse WHW, Chi H, Dapena I, Ham L, et al. Do we overestimate the endothelial cell "loss" after Descemet membrane endothelial keratoplasty? Curr Eye Res. 2013 Feb;38(2):260-5. https://doi.org/10.3109/02713683.2012.753095 PMID: 23294140
20. Miron A, Bruinsma M, Ham L, Schaal SC, Baydoun L, Dapena I, et al. *In vivo* endothelial cell density decline in the early postoperative phase after Descemet membrane endothelial keratoplasty. Cornea. 2018 Jun;37(6):673-677. https://doi.org/10.1097/ICO.0000000000001484 PMID: 29737973
21. Dirisamer M, Dapena I, Ham L, van Dijk K, Oganes O, Frank LE, et al. Patterns of corneal endothelialization and corneal clearance after Descemet membrane endothelial keratoplasty for Fuchs endothelial dystrophy. Am J Ophthalmol. 2011 Oct;152(4):543-555.e1. https://doi.org/10.1016/j.ajo.2011.03.031 PMID: 21726849
22. Qazi Y, Hamrah P. Corneal allograft rejection: immunopathogenesis to therapeutics. J Clin Cell Immunol. 2013 Nov 20;2013(Suppl 9):006. https://doi.org/10.4172/2155-9899.S9-006 PMID: 24634796
23. Parekh M, Borroni D, Ruzza A, Levis HJ, Ferrari S, Ponzin D, et al. A comparative study on different Descemet membrane endothelial keratoplasty graft preparation techniques. Acta Ophthalmol. 2018 Sep;96(6):e718-e726. https://doi.org/10.1111/aos.13746 PMID: 29520992
24. Tran KD, Alabi RO, Odell K, Dye PK, Downes K, Sales CS. Measuring endothelial cell loss on DMEK grafts after transplantation in human cadaveric whole eyes: description of the technique and pilot study. Cornea. 2018 Aug;37(8):1075-1080. https://doi.org/10.1097/ICO.0000000000001602 PMID: 29634671
25. Bhogal M, Balda MS, Matter K, Allan BD. Global cell-by-cell evaluation of endothelial viability after two methods of graft preparation in Descemet membrane endothelial keratoplasty. Br J Ophthalmol. 2016 Apr;100(4):572-8. https://doi.org/10.1136/bjophthalmol-2015-307534 PMID: 26740609
26. Borroni D, Gadhvi K, Wojcik G, Pennisi F, Vallabh NA, Galeone A. The Influence of Speed During Stripping in Descemet Membrane Endothelial Keratoplasty Tissue Preparation. Cornea. 2020 Sep;39(9):1086-1090. https://doi.org/10.1097/ICO.0000000000002338 PMID: 32301812
27. Downes K, Tran KD, Stoeger CG, Chamberlain W. Cumulative endothelial cell loss in Descemet membrane endothelial keratoplasty grafts from preparation through insertion with glass injectors. Cornea. 2018 Jun;37(6):698-704. https://doi.org/10.1097/ICO.0000000000001588 PMID: 29561351
28. Bhogal M, Lwin CN, Seah XY, Murugan E, Adnan K, Lin SJ. Real-time assessment of corneal endothelial cell damage following graft preparation and donor insertion for DMEK. PLoS One. 2017 Oct 4;12(10):e0184824. https://doi.org/10.1371/journal.pone.0184824 PMID: 28977017
29. Birbal RS, Sikder S, Lie JT, Groeneveld-van Beek EA, Oellerich S, Melles GRJ. Donor tissue preparation for Descemet membrane endothelial keratoplasty: an updated review. Cornea. 2018 Jan;37(1):128-135. https://doi.org/10.1097/ICO.0000000000001368 PMID: 28990995
30. Miron A, Sajet A, Groeneveld-van Beek EA, Kok JS, Dedeci M, de Jong M, et al. Endothelial cell viability after DMEK graft preparation. Curr Eye Res. 2021 Nov;46(11):1621-1630. https://doi.org/10.1080/02713683.2021.1927111 PMID: 34027768
31. Papadopoulos NG, Dedoussis GV, Spanakos G, Gritzapis AD, Baxevanis CN, Papamichail M. An improved fluorescence assay for the determination of lymphocyte-mediated cytotoxicity using flow cytometry. J Immunol Methods. 1994 Dec 28;177(1-2):101-11. https://doi.org/10.1016/0022-1759(94)90147-3 PMID: 7822816
32. Suuronen EJ, McLaughlin CR, Stys PK, Nakamura M, Munger R, Griffith M. Functional innervation in tissue engineered models for in vitro study and testing purposes. Toxicol Sci. 2004 Dec;82(2):525-33. https://doi.org/10.1093/toxsci/kfh270 PMID: 15342958
33. Banfalvi G. Methods to detect apoptotic cell death. Apoptosis. 2017 Feb;22(2):306-323. https://doi.org/10.1007/s10495-016-1333-3 PMID: 28035493
34. Gatti R, Belletti S, Orlandini G, Bussolati O, Dall'Asta V, Gazzola GC. Comparison of annexin V and calcein-AM as early vital markers of apoptosis in adherent cells by confocal laser microscopy. J Histochem Cytochem. 1998 Aug;46(8):895-900. https://doi.org/10.1177/002215549804600804 PMID: 9671440
35. Vercammen H, Miron A, Oellerich S, Melles GRJ, Ní Dhubhghaill S, Koppen C, et al. Corneal endothelial wound healing: understanding the regenerative capacity of the innermost layer of the cornea. Transl Res. 2022 May 21:S1931-5244(22)00114-1. https://doi.org/10.1016/j.trsl.2022.05.003 PMID: 35609782.
36. Maurizi E, Schiroli D, Zini R, Limongelli A, Mistò R, Macaluso C. A fine-tuned β-catenin regulation during proliferation of corneal endothelial cells revealed using proteomics analysis. Sci Rep. 2020 Aug 14;10(1):13841. https://doi.org/10.1038/s41598-020-70800-w PMID: 32796906

37. Joyce NA. Cell cycle status in human corneal endothelium. Exp Eye Res. 2005 Dec;81(6):629-38. https://doi.org/10.1016/j.exer.2005.06.012 PMID: 16054624
38. Kikuchi M, Zhu C, Senoo T, Obara Y, Joyce NC. p27kip1 siRNA induces proliferation in corneal endothelial cells from young but not older donors. Invest Ophthalmol Vis Sci. 2006 Nov;47(11):4803-9. https://doi.org/10.1167/iovs.06-0521 PMID: 17065491
39. Lee HT, Kay EDP. Regulatory role of cAMP on expression of Cdk4 and p27(Kip1) by inhibiting phosphatidylinositol 3-kinase in corneal endothelial cells. Invest Ophthalmol Vis Sci. 2003 Sep;44(9):3816-25. https://doi.org/10.1167/iovs.03-0147 PMID: 12939297
40. Ando K, Fukuhara S, Moriya T, Obara Y, Nakahata N, Mochizuki N. Rap1 potentiates endothelial cell junctions by spatially controlling myosin II activity and actin organization. J Cell Biol. 2013 Sep 16;202(6):901-16. https://doi.org/10.1083/jcb.201301115 PMID: 24019534
41. Coleman ML, Marshall CJ, Olson MF. RAS and RHO GTPases in G1-phase cell-cycle regulation. Nat Rev Mol Cell Biol. 2004 May;5(5):355-66. https://doi.org/10.1038/nrm1365 PMID: 15122349
42. Lee JG, Kay EDP. FGF-2-induced wound healing in corneal endothelial cells requires Cdc42 activation and Rho inactivation through the phosphatidylinositol 3-kinase pathway. Invest Ophthalmol Vis Sci. 2006 Apr;47(4):1376-86. https://doi.org/10.1167/iovs.05-1223 PMID: 16565371
43. Roovers K, Klein EA, Castagnino P, Assoian RK. Nuclear translocation of LIM kinase mediates Rho-Rho kinase regulation of cyclin D1 expression. Dev Cell. 2003 Aug;5(2):273-84. https://doi.org/10.1016/s1534-5807(03)00206-5 PMID: 12919678
44. Roberts AB, Tian F, Byfield SDC, Stuelten C, Ooshima A, Saika S, et al. Smad3 is key to TGF-beta-mediated epithelial-to-mesenchymal transition, fibrosis, tumor suppression and metastasis. Cytokine Growth Factor Rev. 2006 Feb-Apr;17(1-2):19-27. https://doi.org/10.1016/j.cytogfr.2005.09.008 PMID: 16290023
45. Saika S. TGFbeta pathobiology in the eye. Lab Invest. 2006 Feb;86(2):106-15. https://doi.org/10.1038/labinvest.3700375 PMID: 16341020
46. Itoh S, ten Dijke P. Negative regulation of TGF-beta receptor/Smad signal transduction. Curr Opin Cell Biol. 2007 Apr;19(2):176-84. https://doi.org/10.1016/j.ceb.2007.02.015 PMID: 17317136
47. Massagué J, Gomis RR. The logic of TGFbeta signaling. FEBS Lett. 2006 May 22;580(12):2811-20. https://doi.org/10.1016/j.febslet.2006.04.033 PMID: 16678165
48. Byfield SDC, Roberts AB. Lateral signaling enhances TGF-beta response complexity. Trends Cell Biol. 2004 Mar;14(3):107-11. https://doi.org/10.1016/j.tcb.2004.01.001 PMID: 15055198
49. Mimura T, Yamagami S, Amano S. Corneal endothelial regeneration and tissue engineering. Prog Retin Eye Res. 2013 Jul;35:1-17. https://doi.org/10.1016/j.preteyeres.2013.01.003 PMID: 23353595
50. Landshman N, Solomon A, Belkin M. Cell division in the healing of the corneal endothelium of cats. Arch Ophthalmol. 1989 Dec;107(12):1804-8. https://doi.org/10.1001/archopht.1989.01070020886032 PMID: 2597071
51. Macsai MS, Shiloach M. Use of topical Rho kinase inhibitors in the treatment of Fuchs dystrophy after Descemet stripping only. Cornea. 2019 May;38(5):529-534. https://doi.org/10.1097/ICO.0000000000001883 PMID:30720541
52. Davies E, Jurkunas U, Pineda R. Pilot study of corneal clearance with the use of a Rho-kinase inhibitor after descemetorhexis without endothelial keratoplasty for Fuchs endothelial corneal dystrophy. Cornea. 2021 Jul 1;40(7):899-902. https://doi.org/10.1097/ICO.0000000000002691 PMID: 33758139
53. Soh YQ, Peh G, George BL, Seah XY, Primalani NK, Adnan K, et al. Predicative factors for corneal endothelial cell migration. Invest Ophthalmol Vis Sci. 2016 Feb;57(2):338-48. https://doi.org/10.1167/iovs.15-18300 PMID: 26842752
54. Kinoshita S, Koizumi N, Ueno M, Okumura N, Imai K, Tanaka H, et al. Injection of Cultured Cells with a ROCK Inhibitor for Bullous Keratopathy. N Engl J Med. 2018 Mar 15;378(11):995-1003. https://doi.org/10.1056/NEJMoa1712770 PMID: 29539291
55. Numa K, Imai K, Ueno M, Kitazawa K, Tanaka H, John D Bush JD, et al. Five-year follow-up of first 11 patients undergoing injection of cultured corneal endothelial cells for corneal endothelial failure. Ophthalmology. 2021 Apr;128(4):504-514. https://doi.org/10.1016/j.ophtha.2020.09.002 PMID: 32898516
56. Ichijima H, Petroll WM, Jester JV, Barry PA, Andrews PM, Dai M, et al. *In vivo* confocal microscopic studies of endothelial wound healing in rabbit cornea. Cornea. 1993 Sep;12(5):369-78. https://doi.org/10.1097/00003226-199309000-00001 PMID: 8306656
57. Miyamoto T, Sumioka T, Saika S. Endothelial mesenchymal transition: a therapeutic target in retrocorneal membrane. Cornea. 2010 Nov;29 Suppl 1:S52-6. https://doi.org/10.1097/ICO.0b013e3181efe36a PMID: 20935543

58. Sumioka T, Ikeda K, Okada Y, Yamanaka O, Kitano A, Saika S. Inhibitory effect of blocking TGF-beta/Smad signal on injury-induced fibrosis of corneal endothelium. Mol Vis. 2008;14:2272-81. PMID: 19081766
59. Funaki T, Nakao A, Ebihara N, Setoguchi Y, Fukuchi Y, Okumura Ko, et al. Smad7 suppresses the inhibitory effect of TGF-beta2 on corneal endothelial cell proliferation and accelerates corneal endothelial wound closure *in vitro*. Cornea. 2003 Mar;22(2):153-9. https://doi.org/10.1097/00003226-200303000-00015 PMID: 12605052
60. Choi SO, Jeon HS, Hyon JY, Oh YJ, Wee WR, Chung TY, et al. Recovery of corneal endothelial cells from periphery after injury. PLoS One. 2015 Sep 17;10(9):e0138076. https://doi.org/10.1371/journal.pone.0138076 PMID: 26378928
61. Ying LY, Qiu WY, Wang BH, Zhou P, Zhang B, Yao YF. Corneal endothelial regeneration in human eyes using endothelium-free grafts. BMC Ophthalmol. 2022 Jan 21;22(1):32. https://doi.org/10.1186/s12886-022-02260-x PMID: 35062892
62. Dirisamer M, Ham L, Dapena I, van Dijk K, Melles GRJ. Descemet membrane endothelial transfer: "free-floating" donor Descemet implantation as a potential alternative to "keratoplasty". Cornea. 2012 Feb;31(2):194-7. https://doi.org/10.1097/ICO.0b013e31821c9afc PMID: 22146548
63. Balachandran C, Ham L, Verschoor CA, Ong TS, van der Wees J, Melles GRJ. Spontaneous corneal clearance despite graft detachment in Descemet membrane endothelial keratoplasty. Am J Ophthalmol. 2009 Aug;148(2):227-234.e1. https://doi.org/10.1016/j.ajo.2009.02.033. PMID:19442962
64. Yam GHF, Seah X, Yusoff NZBM, Setiawan M, Wahlig S, Htoon HM, et al. Characterization of Human Transition Zone Reveals a Putative Progenitor-Enriched Niche of Corneal Endothelium. Cells. 2019 Oct 12;8(10):1244. https://doi.org/10.3390/cells8101244 PMID: 31614883
65. He Z, Campolmi N, Gain P, Thi BMH, Dumollard JM, Duband S, et al. Revisited microanatomy of the corneal endothelial periphery: new evidence for continuous centripetal migration of endothelial cells in humans. Stem Cells. 2012 Nov;30(11):2523-34. https://doi.org/10.1002/stem.1212 PMID: 22949402
66. van Beek EAG, Lie JT, van der Wees J, Bruinsma M, Melles GRJ. Standardized 'no-touch' donor tissue preparation for DALK and DMEK: harvesting undamaged anterior and posterior transplants from the same donor cornea. Acta Ophthalmol. 2013 Mar;91(2):145-50. https://doi.org/10.1111/j.17553768.2012.02462.x PMID: 22672202
67. Lie JT, Birbal R, Ham L, van der Wees J, Melles GRJ. Donor tissue preparation for Descemet membrane endothelial keratoplasty. J Cataract Refract Surg. 2008 Sep;34(9):1578-83. https://doi.org/10.1016/j.jcrs.2008.05.036 PMID: 18721723
68. Miron A, Spinozzi D, Bruinsma M, Lie JT, Birbal RS, Baydoun L, et al. Asymmetrical endothelial cell migration from *in vitro* Quarter-Descemet membrane endothelial keratoplasty grafts. Acta Ophthalmol. 2018 Dec;96(8):828-833. https://doi.org/10.1111/aos.13841 PMID: 30171674
69. Konomi K, Joyce NC. Age and topographical comparison of telomere lengths in human corneal endothelial cells. Mol Vis. 2007 Jul 23;13:1251-8. PMID: 17679950
70. Egan CA, Train IS, Shay JW, Wilson SE, Bourne WM. Analysis of telomere lengths in human corneal endothelial cells from donors of different ages. Invest Ophthalmol Vis Sci. 1998 Mar;39(3):648-53. PMID: 9501879
71. Kataoka K, Huh N. Application of a thermo-reversible gelation polymer, Mebiol gel, for stem cell culture and regenerative medicine. J Stem Cells Regen Med. 2010 Apr 5;6(1):10-4. https://doi.org/10.46582/jsrm.0601003 PMID: 24693055
72. Sudha B, Madhavan HN, Sitalakshmi G, Malathi J, Krishnakumar S, Mori Y, Yoshioka H, et al. Cultivation of human corneal limbal stem cells in Mebiol gel--A thermo-reversible gelation polymer. Indian J Med Res. 2006 Dec;124(6):655-64. PMID: 17287553
73. Bray LJ, Binner M, Holzheu A, Friedrichs J, Freudenberg U, Hutmacher DW, et al. Multi-parametric hydrogels support 3D *in vitro* bioengineered microenvironment models of tumour angiogenesis. Biomaterials. 2015;53:609-20. https://doi.org/10.1016/j.biomaterials.2015.02.124 PMID: 25890757
74. Jooybar E, Abdekhodaie MJ, Alvi M, Mousavi A, Karperien M, Dijkstra PJ. An injectable platelet lysate-hyaluronic acid hydrogel supports cellular activities and induces chondrogenesis of encapsulated mesenchymal stem cells. Acta Biomater. 2019 Jan 1;83:233-244. https://doi.org/10.1016/j.actbio.2018.10.031 PMID: 30366137
75. Miron A, Spinozzi D, Lie J, Melles GR, Oellerich S, Ni Dhubhghaill S. Improving endothelial explant tissue culture by novel thermoresponsive cell culture system. Curr Eye Res. 2021 Mar;46(3):290-293. https://doi.org/10.1080/02713683.2020.1798468 PMID: 32727221

76. Miron A, Spinozzi D, Ní Dhubhghaill S, Lie JT, Oellerich S, Melles GRJ. In vitro endothelial cell migration from limbal edge-modified Quarter-DMEK grafts. PLoS One. 2019 Nov 20;14(11):e0225462. https://doi.org/10.1371/journal.pone.0225462 PMID: 31747441
77. Maruthamuthu V, Schaus YA, Gardel ML. Conserved F-actin dynamics and force transmission at cell adhesions. Curr Opin Cell Biol. 2010 Oct;22(5):583-8. https://doi.org/10.1016/j.ceb.2010.07.010 PMID: 20728328
78. Gardel ML, Sabass B, Ji L, Danuser G, Schwarz US, Waterman CM. Traction stress in focal adhesions correlates biphasically with actin retrograde flow speed. J Cell Biol. 2008 Dec 15;183(6):999-1005. https://doi.org/10.1083/jcb.200810060 PMID: 19075110
79. Schoenwaelder SM, Burridge K. Bidirectional signaling between the cytoskeleton and integrins. Curr Opin Cell Biol. 1999 Apr;11(2):274-86. https://doi.org/10.1016/s0955-0674(99)80037-4 PMID: 10209151
80. Small JV, Rottner K, Kaverina I, Anderson KI. Assembling an actin cytoskeleton for cell attachment and movement. Biochim Biophys Acta. 1998 Sep 16;1404(3):271-81. https://doi.org/10.1016/s0167-4889(98)00080-9 PMID: 9739149
81. Heath JP, Holifield BF. On the mechanisms of cortical actin flow and its role in cytoskeletal organisation of fibroblasts. Symp Soc Exp Biol. 1993;47:35-56. PMID: 8165576
82. Trepat X, Chen Z, Jacobson K. Cell migration. Compr Physiol. 2012 Oct;2(4):2369-92. https://doi.org/10.1002/cphy.c110012 PMID: 23720251
83. Gaggioli C, Hooper S, Carcedo CH, Grosse R, Marshall JF, Harrington K, et al. Fibroblast-led collective invasion of carcinoma cells with differing roles for Rho GTPases in leading and following cells. Nat Cell Biol. 2007 Dec;9(12):1392-400. https://doi.org/10.1038/ncb1658 PMID: 18037882
84. Wolf K, Wu YI, Liu Y, Geiger J, Tam E, Overall C, et al. Multi-step pericellular proteolysis controls the transition from individual to collective cancer cell invasion. Nat Cell Biol. 2007 Aug;9(8):893-904. https://doi.org/10.1038/ncb1616 PMID: 17618273
85. Tavella S, Bellese G, Castagnola P, Martin I, Piccini D, Doliana R, et al. Regulated expression of fibronectin, laminin and related integrin receptors during the early chondrocyte differentiation. J Cell Sci. 1997 Sep;110 (Pt 18):2261-70. https://doi.org/10.1242/jcs.110.18.2261 PMID: 9378775
86. Edwards DC, Sanders LC, Bokoch GM, Gill GN. Activation of LIM-kinase by Pak1 couples Rac/Cdc42 GTPase signalling to actin cytoskeletal dynamics. Nat Cell Biol. 1999 Sep;1(5):253-9. https://doi.org.10.1038/12963 PMID: 10559936
87. Hall A. Rho GTPases and the actin cytoskeleton. Science. 1998 Jan 23;279(5350):509-14. https://doi.org/10.1126/science.279.5350.509 PMID: 9438836
88. Cort JH, Sedláková E, I Kluh. Neurophysin binding and naturiuretic peptides from the posterior pituitary. Ann N Y Acad Sci. 1975 Feb 21;248:336-44. https://doi.org/10.1111/j.1749-6632.1975.tb34196.x PMID: 1054550
89. Linder S. The matrix corroded: podosomes and invadopodia in extracellular matrix degradation. Trends Cell Biol. 2007 Mar;17(3):107-17. https://doi.org/10.1016/j.tcb.2007.01.002 PMID: 17275303
90. Ram SE, Doyle AD, Conti MA, Matsumoto K, Adelstein RS, Yamada KM. Myosin IIA regulates cell motility and actomyosin-microtubule crosstalk. Nat Cell Biol. 2007 Mar;9(3):299-309. https://doi.org/10.1038/ncb1540 PMID: 17310241
91. Manzanares MV, Zareno J, Whitmore L, Choi CK, Horwitz AF. Regulation of protrusion, adhesion dynamics, and polarity by myosins IIA and IIB in migrating cells. J Cell Biol. 2007 Feb 26;176(5):573-80. https://doi.org/10.1083/jcb.200612043 PMID: 17312025
92. Pipparelli A, Arsenijevic Y, Thuret G, Gain P, Nicolas M, Majo F. ROCK Inhibitor enhances adhesion and wound healing of human corneal endothelial cells. PLoS ONE 8(4): e62095. https://doi.org/10.1371/journal.pone.0062095 PMID: 23626771
93. Pamies D, Reig JA, Vilanova E, Sogorb MA. Expression of Neuropathy Target Esterase in mouse embryonic stem cells during differentiation. Arch Toxicol. 2010 Jun;84(6):481-91. https://doi.org/10.1007/s00204-010-0518-8 PMID: 20112100
94. Zhang J, Ahmad AM, Ng H, Shi J, McGhee CNJ, Patel DV. Successful culture of human transition zone cells. Clin Exp Ophthalmol. 2020 Jul;48(5):689-700. https://doi.org/10.1111/ceo.13756 PMID: 32249477
95. Raviola G. Schwalbe line's cells: a new cell type in the trabecular meshwork of Macaca mulatta. Invest Ophthalmol Vis Sci. 1982 Jan;22(1):45-56. PMID: 7056624
96. Stone RA, Kuwayama Y, Laties AM, Marangos PJ. Neuron-specific enolase-containing cells in the rhesus monkey trabecular meshwork. Invest Ophthalmol Vis Sci. 1984 Nov;25(11):1332-4. PMID: 6490334.

97. Rodrigues MM, Spaeth GL, Donohoo P. Electron microscopy of argon laser therapy in phakic open-angle glaucoma. Ophthalmology. 1982 Mar;89(3):198-210. https://doi.org/10.1016/s0161-6420(82)34806-x PMID: 7088502
98. Alexander RA, Grierson I. Morphological effects of argon laser trabeculoplasty upon the glaucomatous human meshwork. Eye (Lond). 1989;3 (Pt 6):719-26. https://doi.org/10.1038/eye.1989.111 PMID: 2630352
99. Amann J, Holley GP, Lee SB, Edelhauser HF. Increased endothelial cell density in the paracentral and peripheral regions of the human cornea. Am J Ophthalmol. 2003 May;135(5):584-90. https://doi.org/10.1016/s0002-9394(02)02237-7 PMID: 12719063
100. Laing RA, Neubauer L, Oak SS, Kayne HL, Leibowitz HM. Evidence for mitosis in the adult corneal endothelium. Ophthalmology. 1984 Oct;91(10):1129-34. https://doi.org/10.1016/s0161-6420(84)34176-8 PMID: 6392976
101. Treffers WF. Human corneal endothelial wound repair. *In vitro* and *in vivo*. Ophthalmology. 1982 Jun;89(6):605-13. https://doi.org/10.1016/s0161-6420(82)34757-0 PMID: 6181449.
102. Mimura T, Joyce NC. Replication competence and senescence in central and peripheral human corneal endothelium. Invest Ophthalmol Vis Sci. 2006 Apr;47(4):1387-96 https://doi.org/10.1167/iovs.05-1199 PMID: 16565372
103. Whikehart DR, Parikh CH, Vaughn AV, Mishler K, Edelhauser HF. Evidence suggesting the existence of stem cells for the human corneal endothelium. Mol Vis. 2005 Sep 26;11:816-24. PMID: 16205623
104. Kelley MJ, Rose AY, Keller KE, Hessle H, Samples JR, Acott TS. Stem cells in the trabecular meshwork: present and future promises. Exp Eye Res. 2009 Apr;88(4):747-51. https://doi.org/10.1016/j.exer.2008.10.024 PMID: 19061887
105. Braunger BM, Ademoglu B, Koschade SE, Fuchshofer R, Gabelt BT, Kiland JA, et al. Identification of adult stem cells in Schwalbe's line region of the primate eye. Invest Ophthalmol Vis Sci. 2014 Oct 16;55(11):7499-507. https://doi.org/10.1167/iovs.14-14872 PMID: 25324280
106. Mimura T, Yamagami S, Yokoo S, Usui T, Amano S. Selective isolation of young cells from human corneal endothelium by the sphere-forming assay. Tissue Eng Part C Methods. 2010 Aug;16(4):803-12. https://doi.org/10.1089/ten.TEC.2009.0608 PMID: 19852617
107. Yokoo S, Yamagami S, Yanagi Y, Uchida S, Mimura T, Usui T, et al. Human corneal endothelial cell precursors isolated by sphere-forming assay. Invest Ophthalmol Vis Sci. 2005 May;46(5):1626-31. https://doi.org/10.1167/iovs.04-1263 PMID: 15851561
108. Mimura T, Yamagami S, Yokoo S, Araie M, Amano S. Comparison of rabbit corneal endothelial cell precursors in the central and peripheral cornea. Invest Ophthalmol Vis Sci. 2005 Oct;46(10):3645-8. https://doi.org/10.1167/iovs.05-0630 PMID: 16186345
109. Amano S, Yamagami S, Mimura T, Uchida S, Yokoo S. Corneal stromal and endothelial cell precursors. Cornea. 2006 Dec;25(10 Suppl 1):S73-7. https://doi.org/10.1097/01.ico.0000247218.10672.7e PMID: 17001199
110. Yamagami S, Yokoo S, Mimura T, Takato T, Araie M, Amano S. Distribution of precursors in human corneal stromal cells and endothelial cells. Ophthalmology. 2007 Mar;114(3):433-9. https://doi.org/10.1016/j.ophtha.2006.07.042 PMID: 17324693
111. Ní Dhubhghaill S, Miron A, Lie JT, Dapena I, Oellerich S, Melles GRJ. Preclinical testing of small diameter Descemet membrane endothelial keratoplasty grafts to increase tissue availability. PLoS One. 2021 Feb 4;16(2):e0246516. https://doi.org/10.1371/journal.pone.0246516 PMID: 33539395
112. Bachmann B, Händel A, Siebelmann S, Matthaei M, Cursiefen C. Mini-Descemet membrane endothelial keratoplasty for the early treatment of acute corneal hydrops in Keratoconus. Cornea. 2019 Aug;38(8):1043-1048. https://doi.org/10.1097/ICO.0000000000002001 PMID: 31276462
113. Tu EY. Descemet membrane endothelial keratoplasty patch for persistent corneal hydrops. Cornea. 2017 Dec;36(12):1559-1561. https://doi.org/10.1097/ICO.0000000000001351 PMID: 28872520
114. Händel A, Siebelmann S, Matthaei M, Cursiefen C, Bachmann B. Mini-DMEK for the treatment of chronic focal corneal endothelial decompensation. Cornea: July 5, 2022. https://doi.org/10.1097/ICO.0000000000003048
115. Moloney G, Chan UT, Hamilton A, Zahidin AM, Grigg JR, Devasahayam RN. Descemetorhexis for Fuchs' dystrophy. Can J Ophthalmol. 2015 Feb;50(1):68-72. https://doi.org/10.1016/j.jcjo.2014.10.014 PMID: 25677286
116. Borkar DS, Veldman P, Colby KA. Treatment of Fuchs Endothelial Dystrophy by Descemet Stripping Without Endothelial Keratoplasty. Cornea. 2016 Oct;35(10):1267-73. https://doi.org/10.1097/ICO.0000000000000915 PMID: 27310885
117. Iovieno A, Neri A, Soldani AM, Adani C, Fontana L. Descemetorhexis without graft placement for the treatment of Fuchs endothelial dystrophy: preliminary results and review of the literature. Cornea. 2017 Jun;36(6):637-641. https://doi.org/10.1097/ICO.0000000000001202 PMID: 28410355

118. Moloney G, Petsoglou C, Ball M, Kerdraon Y, Höllhumer R, Spiteri N, et al. Descemetorhexis without grafting for Fuchs endothelial dystrophy-supplementation with topical ripasudil. Cornea. 2017 Jun;36(6):642-648. https://doi.org/10.1097/ICO.0000000000001209 PMID: 28476048
119. Garcerant D, Hirnschall N, Toalster N, Zhu M, Wen L, Moloney G. Descemet's stripping without endothelial keratoplasty. Curr Opin Ophthalmol. 2019 Jul;30(4):275-285. https://doi.org/10.1097/ICU.0000000000000579 PMID: 31033737
120. Soh YQ, Mehta JS. Regenerative therapy for Fuchs endothelial corneal dystrophy. Cornea. 2018 Apr;37(4):523-527. https://doi.org/10.1097/ICO.0000000000001518 PMID: 29384808
121. Chen J, Li Z, Zhang L, Ou S, Wang Y, He X, et al. Descemet's membrane supports corneal endothelial cell regeneration in rabbits. Sci Rep. 2017 Aug 1;7(1):6983. https://doi.org/10.1038/s41598-017-07557-2 PMID: 28765543
122. Wunderlich K, Senn BC, Reiser P, Pech M, Flammer J, Meyer P. Connective tissue growth factor in retrocorneal membranes and corneal scars. Ophthalmologica. 2000 Sep-Oct;214(5):341-6. https://doi.org/10.1159/000027517 PMID: 10965248
123. Maycock NJ, Marshall J. Genomics of corneal wound healing: a review of the literature. Acta Ophthalmol. 2014 May;92(3):e170-84. https://doi.org/10.1111/aos.12227 PMID: 23819758
124. Heinzelmann S, Böhringer D, Eberwein P, Reinhard T, Maier P. Outcomes of Descemet membrane endothelial keratoplasty, Descemet stripping automated endothelial keratoplasty and penetrating keratoplasty from a single centre study. Graefes Arch Clin Exp Ophthalmol. 2016 Mar;254(3):515-22. https://doi.org/10.1007/s00417-015-3248-z PMID: 26743748
125. Melles GR. Posterior lamellar keratoplasty: DLEK to DSEK to DMEK. Cornea. 2006 Sep;25(8):879-81. https://doi.org/10.1097/01.ico.0000243962.60392.4f PMID: 17102659
126. Dapena I, Ham L, Melles GR. Endothelial keratoplasty: DSEK/DSAEK or DMEK--the thinner the better? Curr Opin Ophthalmol. 2009 Jul;20(4):299-307. https://doi.org/10.1097/ICU.0b013e32832b8d18 PMID: 19417653.
127. Melles GR, Ong TS, Ververs B, van der Wees J. Preliminary clinical results of Descemet membrane endothelial keratoplasty. Am J Ophthalmol. 2008 Feb;145(2):222-227. https://doi.org/10.1016/j.ajo.2007.09.021 PMID: 18061137
128. Price MO, Fairchild KM, Price DA, Price FWJ. Descemet's stripping endothelial keratoplasty five-year graft survival and endothelial cell loss. Ophthalmology. 2011 Apr;118(4):725-9. https://doi.org/10.1016/j.ophtha.2010.08.012 PMID: 21035862
129. Soh YQ, Kocaba V, Pinto M, Mehta JS. Fuchs endothelial corneal dystrophy and corneal endothelial diseases: East meets West. Eye (Lond). 2020 Mar;34(3):427-441. https://doi.org/10.1038/s41433-019-0497-9 PMID: 31267087
130. Oellerich S, Baydoun L, Peraza-Nieves J, Ilyas A, Frank L, Binder PS, et al. Multicenter Study of 6-Month Clinical Outcomes After Descemet Membrane Endothelial Keratoplasty. Cornea. 2017 Dec;36(12):1467-1476. https://doi.org/10.1097/ICO.0000000000001374 PMID: 28957979.
131. Price, M.O., Lass, J.H. & Price, F.W. Clinical factors for early and late endothelial cell loss after corneal transplantation. Curr Ophthalmol Rep 6, 191–199 (2018). https://doi.org/10.1007/s40135-018-0179-y
132. Price MO, Mehta JS, Jurkunas UV, Price FW Jr. Corneal endothelial dysfunction: evolving understanding and treatment options. Prog Retin Eye Res. 2021 May;82:100904. https://doi.org/10.1016/j.preteyeres.2020.100904 PMID: 32977001
133. Birbal RS, Ni Dhubhghaill S, Bourgonje VJA, Hanko J, Ham L, Jager MJ, et al. Five-Year Graft Survival and Clinical Outcomes of 500 Consecutive Cases After Descemet Membrane Endothelial Keratoplasty. Cornea. 2020 Mar;39(3):290-297. https://doi.org/10.1097/ICO.0000000000002120 PMID: 31478948
134. Oellerich S, Ham L, Frank LE, Gorges S, Bourgonje VJA, Baydoun L, et al. Parameters associated with endothelial cell density variability after Descemet membrane endothelial keratoplasty. Am J Ophthalmol. 2020 Mar;211:22-30. https://doi.org/10.1016/j.ajo.2019.10.017 PMID: 31647928
135. Hayashi T, Schrittenlocher S, Siebelmann S, Le VNH, Matthaei M, Franklin J, et al. Risk factors for endothelial cell loss after Descemet membrane endothelial keratoplasty (DMEK). Sci Rep. 2020 Jul 6;10(1):11086. https://doi.org/10.1038/s41598-020-68023-0 PMID: 32632151
136. Birbal RS, Baydoun L, Ham L, Miron A, van Dijk K, Dapena I, et al. Effect of surgical indication and preoperative lens status on Descemet membrane endothelial keratoplasty outcomes. Am J Ophthalmol. 2020 Apr;212:79-87. https://doi.org/10.1016/j.ajo.2019.12.011 PMID: 31863726
137. Rodríguez-Calvo de Mora M, Groeneveld-van Beek EA, Frank LE, van der Wees J, Oellerich S, Bruinsma M, et al. Association between graft storage time and donor age with endothelial cell density and graft adherence after

Descemet membrane endothelial keratoplasty. JAMA Ophthalmol. 2016 Jan;134(1):91-4. https://doi.org/10.1001/jamaophthalmol.2015.4499 PMID: 26562408

138. Baydoun L, Ham L, Borderie V, Dapena I, Hou J, Frank LE, et al. Endothelial survival after Descemet membrane endothelial keratoplasty: effect of surgical indication and graft adherence status. JAMA Ophthalmol. 2015 Nov;133(11):1277-85. https://doi.org/10.1001/jamaophthalmol.2015.3064 PMID: 26355238
139. Gundlach E, Spiller N, Pilger D, Dietrich-Ntoukas T, Joussen AM, Torun N, et al. Impact of difficult unfolding and attachment of the graft lamella on the long-term outcome after Descemet membrane endothelial keratoplasty. Graefes Arch Clin Exp Ophthalmol. 2020 Nov;258(11):2459-2465. https://doi.org/10.1007/s00417-020-04852-z PMID: 32705337
140. Musayeva A, Livny E, Dragnea DC, Ham L, Vasiliauskaitė I, Ní Dhubhghaill S, et. al. Endothelial cell density changes in the corneal center versus paracentral areas after Descemet membrane endothelial keratoplasty. Cornea. 2020 Sep;39(9):1091-1095. https://doi.org/10.1097/ICO.0000000000002326 PMID: 32282357
141. Guindolet D, Crouzet E, He Z, Herbepin P, Jumelle C, Perrache C, et al. Storage of Porcine Cornea in an Innovative Bioreactor. Invest Ophthalmol Vis Sci. 2017 Nov 1;58(13):5907-5917. https://doi.org/10.1167/iovs.17-22218 PMID: 29164231
142. Garcin T, Gauthier AS, Crouzet E, He Z, Herbepin P, Perrache C, et al. Innovative corneal active storage machine for long-term eye banking. Am J Transplant. 2019 Jun;19(6):1641-1651. https://doi.org/10.1111/ajt.15238 PMID: 30589181
143. Parekh M, Romano V, Hassanin K, Testa V, Wongvisavavit R, Ferrari S, et al. Biomaterials for corneal endothelial cell culture and tissue engineering. J Tissue Eng. 2021 Feb 16;12:2041731421990536. https://doi.org/10.1177/2041731421990536 PMID: 33643603
144. De Pieri A, Rochev Y, Zeugolis DI. Scaffold-free cell-based tissue engineering therapies: advances, shortfalls and forecast. NPJ Regen Med. 2021 Mar 29;6(1):18. https//doi.org/10.1038/s41536-021-00133-3 PMID: 33782415
145. Spinozzi D, Miron A, Bruinsma M, Dapena I, Kocaba V, Jager MJ, et al. New developments in corneal endothelial cell replacement. Acta Ophthalmol. 2021 Nov;99(7):712-729. https://doi.org/10.1111/aos.14722 PMID: 33369235
146. Hussain Z and Pei R. Scaffold-free and scaffold-based cellular strategies and opportunities for cornea tissue engineering. Prog. Biomed. Eng. 2021 Jul 26; 3(3):032003 https://doi.org/10.1088/2516-1091/ac12d7
147. Wongvisavavit R, Parekh M, Ahmad S, Daniels JT. Challenges in corneal endothelial cell culture. Regen Med. 2021 Sep;16(9):871-891. https://doi.org/10.2217/rme-2020-0202 PMID: 34380324
148. Hatou S, Shimmura S. Review: corneal endothelial cell derivation methods from ES/iPS cells. Inflamm Regen. 2019 Oct 3;39:19. https://doi.org/10.1186/s41232-019-0108-y PMID: 31592286
149. Shao C, Fu Y, Lu W, Fan X. Bone marrow-derived endothelial progenitor cells: a promising therapeutic alternative for corneal endothelial dysfunction. Cells Tissues Organs. 2011;193(4):253-63. https://doi.org/10.1159/000319797 PMID: 20962503
150. Ju C, Zhang K, Wu X. Derivation of corneal endothelial cell-like cells from rat neural crest cells *in vitro*. PLoS One. 2012;7(7):e42378. https://doi.org/10.1371/journal.pone.0042378. Erratum in: PLoS One. 2012;7(10). https://doi.org/10.1371/annotation/931e92e2-ee2d-4f4f-b0b6-89a7a3f8fbad PMID: 22860120
151. Hatou S, Yoshida S, Higa K, Miyashita H, Inagaki E, Okano H, et al. Functional corneal endothelium derived from corneal stroma stem cells of neural crest origin by retinoic acid and Wnt/β-catenin signaling. Stem Cells Dev. 2013 Mar 1;22(5):828-39. https://doi.org/10.1089/scd.2012.0286 PMID: 22974347
152. Inagaki E, Hatou S, Higa K, Yoshida S, Shibata S, Okano H, et al. Skin-derived precursors as a source of progenitors for corneal endothelial regeneration. Stem Cells Transl Med. 2017 Mar;6(3):788-798. https://doi.org/10.1002/sctm.16-0162 PMID: 28186681
153. Yamashita K, Inagaki E, Hatou S, Higa K, Ogawa A, Miyashita H, et al. Corneal endothelial regeneration using mesenchymal stem cells derived from human umbilical cord. Stem Cells Dev. 2018 Aug 15;27(16):1097-1108. https://doi.org/10.1089/scd.2017.0297 PMID: 29929442
154. Joyce NC, Harris DL, Markov V, Zhang Z, Saitta B. Potential of human umbilical cord blood mesenchymal stem cells to heal damaged corneal endothelium. Mol Vis. 2012;18:547-64. PMID: 22419848
155. Mimura T, Yokoo S, Araie M, Amano S, Yamagami S. Treatment of rabbit bullous keratopathy with precursors derived from cultured human corneal endothelium. Invest Ophthalmol Vis Sci. 2005 Oct;46(10):3637-44. https://doi.org/10.1167/iovs.05-0462 PMID: 16186344

156. Ueno M, Toda M, Numa K, Tanaka H, Imai K, Bush J, et al. Superiority of mature differentiated cultured human corneal endothelial cell injection therapy for corneal endothelial failure. Am J Ophthalmol. 2022 May;237:267-277. https://doi.org/10.1016/j.ajo.2021.11.012 PMID: 34788595
157. Fan T, Zhao J, Ma X, Xu X, Zhao W, Xu B. Establishment of a continuous untransfected human corneal endothelial cell line and its biocompatibility to denuded amniotic membrane. Mol Vis. 2011 Feb 15;17:469-80. PMID: 21365020
158. Ishino Y, Sano Y, Nakamura T, Connon CJ, Rigby H, Fullwood NJ, et al. Amniotic membrane as a carrier for cultivated human corneal endothelial cell transplantation. Invest Ophthalmol Vis Sci. 2004 Mar;45(3):800-6. https://doi.org/10.1167/iovs.03-0016 PMID: 14985293
159. Fan T, Ma X, Zhao J, Wen Q, Hu X, Yu H, et al. Transplantation of tissue-engineered human corneal endothelium in cat models. Mol Vis. 2013;19:400-7. PMID: 23441111
160. Diao YM, Hong J. Feasibility and safety of porcine Descemet's membrane as a carrier for generating tissue-engineered corneal endothelium. Mol Med Rep. 2015 Aug;12(2):1929-34. https://doi.org/10.3892/mmr.2015.3665 PMID: 25937160
161. Spinozzi D, Miron A, Bruinsma M, Dapena I, Lavy I, Binder PS, et al. Evaluation of the Suitability of Biocompatible Carriers as Artificial Transplants Using Cultured Porcine Corneal Endothelial Cells. Curr Eye Res. 2019 Mar;44(3):243-249. https://doi.org/10.1080/02713683.2018.1536215 PMID: 30339045
162. Bayyoud T, Thaler S, Hofmann J, Maurus C, Spitzer MS, Bartz-Schmidt KU, et al. Decellularized bovine corneal posterior lamellae as carrier matrix for cultivated human corneal endothelial cells. Curr Eye Res. 2012 Mar;37(3):179-86. https://doi.org/10.3109/02713683.2011.644382 PMID: 22335804
163. Arnalich-Montiel F, Moratilla A, Fuentes-Julián S, Aparicio V, Cadenas Martin M, Peh G, et al. Treatment of corneal endothelial damage in a rabbit model with a bioengineered graft using human decellularized corneal lamina and cultured human corneal endothelium. PLoS One. 2019 Nov 21;14(11):e0225480. https://doi.org/10.1371/journal.pone.0225480 PMID: 31751429
164. Choi JS, Williams JK, Greven M, Walter KA, Laber PW, Khang G, et al. Bioengineering endothelialized neo-corneas using donor-derived corneal endothelial cells and decellularized corneal stroma. Biomaterials. 2010 Sep;31(26):6738-45. https://doi.org/10.1016/j.biomaterials.2010.05.020 PMID: 20541797
165. He Z, Forest F, Bernard A, Gauthier AS, Montard R, Peoc'h M, et al. Cutting and decellularization of multiple corneal stromal lamellae for the bioengineering of endothelial grafts. Invest Ophthalmol Vis Sci. 2016 Dec 1;57(15):6639-6651. https://doi.org/10.1167/iovs.16-20256 PMID: 27926756
166. Spinozzi D, Miron A, Lie JT, Rafat M, Lagali N, Melles GRJ, et al. *In vitro* Evaluation and transplantation of human corneal endothelial cells cultured on biocompatible carriers. Cell Transplant. 2020 Jan-Dec;29:963689720923577. https://doi.org/10.1177/0963689720923577 PMID: 32363924
167. Kopsachilis N, Tsinopoulos I, Tourtas T, Kruse FE, Luessen UW. Descemet's membrane substrate from human donor lens anterior capsule. Clin Exp Ophthalmol. 2012 Mar;40(2):187-94. https://doi.org/10.1111/j.1442-9071.2011.02678.x PMID: 21902779
168. Bourget JM, Proulx S. Characterization of a corneal endothelium engineered on a self-assembled stromal substitute. Exp Eye Res. 2016 Apr;145:125-129. https://doi.org/10.1016/j.exer.2015.11.019 PMID: 26658713
169. Koizumi N, Sakamoto Y, Okumura N, Okahara N, Tsuchiya H, Torii R, et al. Cultivated corneal endothelial cell sheet transplantation in a primate model. Invest Ophthalmol Vis Sci. 2007 Oct;48(10):4519-26. https://doi.org/10.1167/iovs.07-0567 PMID: 17898273
170. Levis HJ, Peh GS, Toh KP, Poh R, Shortt AJ, Drake RA, et al. Plastic compressed collagen as a novel carrier for expanded human corneal endothelial cells for transplantation. PLoS One. 2012;7(11):e50993. https://doi.org/10.1371/journal.pone.0050993 PMID: 23226443
171. Mimura T, Yamagami S, Yokoo S, Usui T, Tanaka K, Hattori S, et al. Cultured human corneal endothelial cell transplantation with a collagen sheet in a rabbit model. Invest Ophthalmol Vis Sci. 2004 Sep;45(9):2992-7. https://doi.org/10.1167/iovs.03-1174 PMID: 15326112
172. Palchesko RN, Funderburgh JL, Feinberg AW. Engineered Basement Membranes for Regenerating the Corneal Endothelium. Adv Healthc Mater. 2016 Nov;5(22):2942-2950. https://doi.org/10.1002/adhm.201600488 PMID: 27723276
173. Vázquez N, Chacón M, Rodríguez-Barrientos CA, Merayo-Lloves J, Naveiras M, Baamonde B, et al. Human bone derived collagen for the development of an artificial corneal endothelial graft. *In vivo* results in a rabbit model. PLoS One. 2016 Dec 1;11(12):e0167578. https://doi.org/10.1371/journal.pone.0167578 PMID: 27907157

174. Yamaguchi M, Shima N, Kimoto M, Ebihara N, Murakami A, Yamagami S. Optimization of cultured human corneal endothelial cell sheet transplantation and post-operative sheet evaluation in a rabbit model. Curr Eye Res. 2016 Sep;41(9):1178-84. https://doi.org/10.3109/02713683.2015.1101774 PMID: 26828450
175. Kimoto M, Shima N, Yamaguchi M, Hiraoka Y, Amano S, et al. Development of a bioengineered corneal endothelial cell sheet to fit the corneal curvature. Invest Ophthalmol Vis Sci. 2014 Apr 11;55(4):2337-43. https://doi.org/10.1167/iovs.13-13167 PMID: 24651553
176. Watanabe R, Hayashi R, Kimura Y, Tanaka Y, Kageyama T, et al. A novel gelatin hydrogel carrier sheet for corneal endothelial transplantation. Tissue Eng Part A. 2011 Sep;17(17-18):2213-9. https://doi.org/10.1089/ten.TEA.2010.0568 PMID: 21534849
177. Aghaei-Ghareh-Bolagh B, Guan J, Wang Y, Martin AD, Dawson R, Mithieux SM, et al. Optically robust, highly permeable and elastic protein films that support dual cornea cell types. Biomaterials. 2019 Jan;188:50-62. https://doi.org/10.1016/j.biomaterials.2018.10.006 PMID: 30317114
178. Choi JH, Jeon H, Song JE, Oliveira JM, Reis RL, Khang G. Biofunctionalized lysophosphatidic acid/silk fibroin film for cornea endothelial cell regeneration. Nanomaterials (Basel). 2018 Apr 30;8(5):290. https://doi.org/10.3390/nano8050290 PMID: 29710848
179. Kim DK, Sim BR, Kim JI, Khang G. Functionalized silk fibroin film scaffold using β-Carotene for cornea endothelial cell regeneration. Colloids Surf B Biointerfaces. 2018 Apr 1;164:340-346. https://doi.org/10.1016/j.colsurfb.2017.11.052 PMID: 29413615
180. Kim do K, Sim BR, Khang G. Nature-derived aloe vera gel blended silk fibroin film scaffolds for cornea endothelial cell regeneration and transplantation. ACS Appl Mater Interfaces. 2016 Jun 22;8(24):15160-8. https://doi.org/10.1021/acsami.6b04901 PMID: 27243449
181. Madden PW, Lai JN, George KA, Giovenco T, Harkin DG, Chirila TV. Human corneal endothelial cell growth on a silk fibroin membrane. Biomaterials. 2011 Jun;32(17):4076-84. https://doi.org/10.1016/j.biomaterials.2010.12.034 PMID: 21427010
182. Ramachandran C, Gupta P, Hazra S, Mandal BB. *In vitro* culture of human corneal endothelium on non-mulberry silk fibroin films for tissue regeneration. Transl Vis Sci Technol. 2020 Mar 9;9(4):12. https://doi.org/10.1167/tvst.9.4.12 PMID: 32818099
183. Vázquez N, Rodríguez-Barrientos CA, Aznar-Cervantes SD, Chacón M, Cenis JL, Riestra AC, et al. Silk fibroin films for corneal endothelial regeneration: transplant in a rabbit Descemet membrane endothelial keratoplasty. Invest Ophthalmol Vis Sci. 2017 Jul 1;58(9):3357-3365. https://doi.org/10.1167/iovs.17-21797 PMID: 28687847
184. Kruse M, Walter P, Bauer B, Rütten S, Schaefer K, et al. Electro-spun Membranes as scaffolds for human corneal endothelial cells. Curr Eye Res. 2018 Jan;43(1):1-11. https://doi.org/10.1080/02713683.2017.1377258 PMID: 29281419
185. Ozcelik B, Brown KD, Blencowe A, Ladewig K, Stevens GW, Scheerlinck JP,et al. Biodegradable and biocompatible poly(ethylene glycol)-based hydrogel films for the regeneration of corneal endothelium. Adv Healthc Mater. 2014 Sep;3(9):1496-507. https://doi.org/10.1002/adhm.201400045 PMID: 24652807
186. Van Hoorick J, Delaey J, Vercammen H, Van Erps J, Thienpont H, Dubruel P, et al. Designer Descemet membranes containing PDLLA and functionalized gelatins as corneal endothelial scaffold. Adv Healthc Mater. 2020 Aug;9(16):e2000760. https://doi.org/10.1002/adhm.202000760 PMID: 32603022
187. Liang Y, Liu W, Han B, Yang C, Ma Q, Zhao W, et al. Fabrication and characters of a corneal endothelial cells scaffold based on chitosan. J Mater Sci Mater Med. 2011 Jan;22(1):175-83. https://doi.org/10.1007/s10856-010-4190-6 PMID: 21107657
188. Rizwan M, Peh GS, Adnan K, Naso SL, Mendez AR, Mehta JS, et al. *In vitro* topographical model of Fuchs dystrophy for evaluation of corneal endothelial cell monolayer formation. Adv Healthc Mater. 2016 Nov;5(22):2896-2910. https://doi.org/10.1002/adhm.201600848 PMID: 27701826
189. Seow WY, Kandasamy K, Peh GSL, Mehta JS, Sun W. Ultrathin, Strong, and Cell-Adhesive Agarose-Based Membranes Engineered as Substrates for Corneal Endothelial Cells. ACS Biomater Sci Eng. 2019 Aug 12;5(8):4067-4076. https://doi.org/10.1021/acsbiomaterials.9b00610 PMID: 33448808
190. Song JE, Sim BR, Jeon YS, Kim HS, Shin EY, Carlomagno C, et al. Characterization of surface modified glycerol/silk fibroin film for application to corneal endothelial cell regeneration. J Biomater Sci Polym Ed. 2019 Mar;30(4):263-275. https://doi.org/10.1080/09205063.2018.1535819 PMID: 30324858
191. Wang TJ, Wang IJ, Lu JN, Young TH. Novel chitosan-polycaprolactone blends as potential scaffold and carrier for corneal endothelial transplantation. Mol Vis. 2012;18:255-64. PMID: 22328821

192. Young TH, Wang IJ, Hu FR, Wang TJ. Fabrication of a bioengineered corneal endothelial cell sheet using chitosan/polycaprolactone blend membranes. Colloids Surf B Biointerfaces. 2014 Apr 1;116:403-10. https://doi.org/10.1016/j.colsurfb.2014.01.024 PMID: 24531150
193. Honda N, Mimura T, Usui T, Amano S. Descemet stripping automated endothelial keratoplasty using cultured corneal endothelial cells in a rabbit model. Arch Ophthalmol. 2009 Oct;127(10):1321-6. https://doi.org/10.1001/archophthalmol.2009.253 PMID: 19822849
194. Peh GSL, Ang HP, Lwin CN, Adnan K, George BL, Seah XY et al. Regulatory compliant tissue-engineered human corneal endothelial grafts restore corneal function of rabbits with bullous keratopathy. Sci Rep. 2017 Oct 26;7(1):14149. https://doi.org/10.1038/s41598-017-14723-z PMID: 29074873
195. Telinius N, Spinozzi D, Rasic D, Dapena I, Baandrup U, Miron A, et al. Göttingen minipig is not a suitable animal model for *in vivo* testing of tissue-engineered corneal endothelial cell-carrier sheets and for endothelial keratoplasty. Curr Eye Res. 2020 Aug;45(8):945-949. https://doi.org/10.1080/02713683.2019.1706747 PMID: 31851850
196. Arbelaez JG, Price MO, Price FWJ. Long-term follow-up and complications of stripping Descemet membrane without placement of graft in eyes with Fuchs endothelial dystrophy. Cornea. 2014 Dec;33(12):1295-9. https://doi.org/10.1097/ICO.0000000000000270 PMID: 25299425
197. Shah RD, Randleman JB, Grossniklaus HE. Spontaneous corneal clearing after Descemet's stripping without endothelial replacement. Ophthalmology. 2012 Feb;119(2):256-60. https://doi.org/10.1016/j.ophtha.2011.07.032 PMID: 21982414
198. Auffarth GU, Son HS, Koch M, Weindler J, Merz P, Daphna O, et al. Implantation of an Artificial Endothelial Layer for Treatment of Chronic Corneal Edema. Cornea. 2021 Dec 1;40(12):1633-1638. https://doi.org/10.1097/ICO.0000000000002806 PMID: 34294634
199. Bhogal M, Lwin CN, Seah XY, Peh G, Mehta JS. Allogeneic Descemet's membrane transplantation enhances corneal endothelial monolayer formation and restores functional integrity following Descemet's stripping. Invest Ophthalmol Vis Sci. 2017 Aug 1;58(10):4249-4260. https://doi.org/10.1167/iovs.17-22106 PMID: 28850636
200. Robbins PD, Ghivizzani SC. Viral vectors for gene therapy. Pharmacol Ther. 1998 Oct;80(1):35-47. PMID: 9804053
201. Lebherz C, Maguire A, Tang W, Bennett J, Wilson JM. Novel AAV serotypes for improved ocular gene transfer. J Gene Med. 2008 Apr;10(4):375-82. https://doi.org/10.1002/jgm.1126 PMID: 18278824
202. Rinaldi C, Wood MJA. Antisense oligonucleotides: the next frontier for treatment of neurological disorders. Nat Rev Neurol. 2018 Jan;14(1):9-21. https://doi.org/10.1038/nrneurol.2017.148 PMID: 29192260
203. Moore CBT, Christie KA, Marshall J, Nesbit MA. Personalised genome editing - The future for corneal dystrophies. Prog Retin Eye Res. 2018 Jul;65:147-165. https://doi.org/10.1016/j.preteyeres.2018.01.004 PMID: 29378321
204. Cox DB, Platt RJ, Zhang F. Therapeutic genome editing: prospects and challenges. Nat Med. 2015 Feb;21(2):121-31. https://doi.org/10.1038/nm.3793 PMID: 25654603
205. Jiang F, Doudna JA. CRISPR-Cas9 Structures and Mechanisms. Annu Rev Biophys. 2017 May 22;46:505-529. https://doi.org/10.1146/annurev-biophys-062215-010822 PMID: 28375731
206. Nanda GG, Alone DP. REVIEW: Current understanding of the pathogenesis of Fuchs' endothelial corneal dystrophy. Mol Vis. 2019 Jun 5;25:295-310. PMID: 31263352
207. Ong Tone S, Kocaba V, Böhm M, Wylegala A, White TL, Jurkunas UV. Fuchs endothelial corneal dystrophy: the vicious cycle of Fuchs pathogenesis. Prog Retin Eye Res. 2021 Jan;80:100863. https://doi.org/10.1016/j.preteyeres.2020.100863 PMID: 32438095
208. Wu Z, Yang H, Colosi P. Effect of genome size on AAV vector packaging. Mol Ther. 2010 Jan;18(1):80-6. https://doi.org/10.1038/mt.2009.255 PMID: 19904234
209. Hu J, Rong Z, Gong X, Zhou Z, Sharma VK, Xing C, et al. Oligonucleotides targeting TCF4 triplet repeat expansion inhibit RNA foci and mis-splicing in Fuchs' dystrophy. Hum Mol Genet. 2018 Mar 15;27(6):1015-1026. https://doi.org/10.1093/hmg/ddy018 PMID: 29325021
210. Hu J, Shen X, Rigo F, Prakash TP, Mootha VV, Corey DR. Duplex RNAs and ss-siRNAs Block RNA Foci Associated with Fuchs' Endothelial Corneal Dystrophy. Nucleic Acid Ther. 2019 Apr;29(2):73-81. https://doi.org/10.1089/nat.2018.0764 PMID: 30676271
211. Zarouchlioti C, Sanchez-Pintado B, Hafford Tear NJ, Klein P, Liskova P, Dulla K, et al. Antisense Therapy for a Common Corneal Dystrophy Ameliorates TCF4 Repeat Expansion-Mediated Toxicity. Am J Hum Genet. 2018 Apr 5;102(4):528-539. https://doi.org/10.1016/j.ajhg.2018.02.010 PMID: 29526280
212. Chau VQ, Hu J, Gong X, Hulleman JD, Ufret-Vincenty RL, Rigo F, et al. Delivery of Antisense Oligonucleotides to the Cornea. Nucleic Acid Ther. 2020 Aug;30(4):207-214. https://doi.org/10.1089/nat.2019.0838 PMID: 32202944

213. Rong Z, Gong X, Hulleman JD, Corey DR, Mootha VV. Trinucleotide Repeat-Targeting dCas9 as a Therapeutic Strategy for Fuchs' Endothelial Corneal Dystrophy. Transl Vis Sci Technol. 2020 Aug 31;9(9):47. https://doi.org/10.1167/tvst.9.9.47 PMID: 32934897
214. Uehara H, Zhang X, Pereira F, Narendran S, Choi S, Bhuvanagiri S, et al. Start codon disruption with CRISPR/Cas9 prevents murine Fuchs' endothelial corneal dystrophy. Elife. 2021 Jun 8;10:e55637. https://doi.org/10.7554/eLife.55637 PMID: 34100716
215. Koizumi N, Okumura N, Ueno M, Nakagawa H, Hamuro J, Kinoshita S. Rho-associated kinase inhibitor eye drop treatment as a possible medical treatment for Fuchs corneal dystrophy. Cornea. 2013 Aug;32(8):1167-70. https://doi.org/10.1097/ICO.0b013e318285475d PMID: 23715376
216. Okumura N, Koizumi N, Kay EP, Ueno M, Sakamoto Y, Nakamura S, et al. The ROCK inhibitor eye drop accelerates corneal endothelium wound healing. Invest Ophthalmol Vis Sci. 2013 Apr 3;54(4):2493-502. https://doi.org/10.1167/iovs.12-11320 PMID: 23462749
217. Okumura N, Inoue R, Okazaki Y, Nakano S, Nakagawa H, Kinoshita S, et al. Effect of the Rho Kinase Inhibitor Y-27632 on Corneal Endothelial Wound Healing. Invest Ophthalmol Vis Sci. 2015 Sep;56(10):6067-74. https://doi.org/10.1167/iovs.15-17595 PMID: 26393474
218. Hoppenreijs VP, Pels E, Vrensen GF, Oosting J, Treffers WF. Effects of human epidermal growth factor on endothelial wound healing of human corneas. Invest Ophthalmol Vis Sci. 1992 May;33(6):1946-57. PMID: 1582800
219. Hoppenreijs VP, Pels E, Vrensen GF, Treffers WF. Effects of platelet-derived growth factor on endothelial wound healing of human corneas. Invest Ophthalmol Vis Sci. 1994 Jan;35(1):150-61. PMID: 8300342
220. Lu J, Lu Z, Reinach P, Zhang J, Dai W, Lu L, et al. TGF-beta2 inhibits AKT activation and FGF-2-induced corneal endothelial cell proliferation. Exp Cell Res. 2006 Nov 1;312(18):3631-40. https://doi.org/10.1016/j.yexcr.2006.08.004 PMID: 16963022
221. Halilovic A, Schmedt T, Benischke AS, Hamill C, Chen Y, Santos JH, et al. Menadione-Induced DNA Damage Leads to Mitochondrial Dysfunction and Fragmentation During Rosette Formation in Fuchs Endothelial Corneal Dystrophy. Antioxid Redox Signal. 2016 Jun 20;24(18):1072-83. https://doi.org/10.1089/ars.2015.6532 PMID: 26935406
222. Kim EC, Meng H, Jun AS. N-Acetylcysteine increases corneal endothelial cell survival in a mouse model of Fuchs endothelial corneal dystrophy. Exp Eye Res. 2014 Oct;127:20-5. https://doi.org/10.1016/j.exer.2014.06.002 PMID: 24952277
223. Liu C, Miyajima T, Melangath G, Miyai T, Vasanth S, Deshpande N, et al. Ultraviolet A light induces DNA damage and estrogen-DNA adducts in Fuchs endothelial corneal dystrophy causing females to be more affected. Proc Natl Acad Sci U S A. 2020 Jan 7;117(1):573-583. https://doi.org/10.1073/pnas.1912546116 PMID: 31852820
224. Lovatt M, Kocaba V, Hui Neo DJ, Soh YQ, Mehta JS. Nrf2: A unifying transcription factor in the pathogenesis of Fuchs' endothelial corneal dystrophy. Redox Biol. 2020 Oct;37:101763. https://doi.org/10.1016/j.redox.2020.101763 PMID: 33099215
225. Ziaei A, Schmedt T, Chen Y, Jurkunas UV. Sulforaphane decreases endothelial cell apoptosis in Fuchs endothelial corneal dystrophy: a novel treatment. Invest Ophthalmol Vis Sci. 2013 Oct 15;54(10):6724-34. https://doi.org/10.1167/iovs.13-12699 PMID: 24030461
226. Kim EC, Toyono T, Berlinicke CA, Zack DJ, Jurkunas U, Usui T, et al. Screening and Characterization of Drugs That Protect Corneal Endothelial Cells Against Unfolded Protein Response and Oxidative Stress. Invest Ophthalmol Vis Sci. 2017 Feb 1;58(2):892-900. https://doi.org/10.1167/iovs.16-20147 PMID: 28159976
227. Thuret G, Courrier E, Poinard S, Gain P, Baud'Huin M, et al. One threat, different answers: the impact of COVID-19 pandemic on cornea donation and donor selection across Europe. Br J Ophthalmol. 2022 Mar;106(3):312-318. https://doi.org/10.1136/bjophthalmol-2020-317938 PMID: 33243832
228. Cronin AJ. Points mean prizes: priority points, preferential status and directed organ donation in Israel. Isr J Health Policy Res. 2014 Feb 24;3(1):8. https://doi.org/10.1186/2045-4015-3-8 PMID: 24565060
229. Iyer TK. Kidneys for transplant--"opting out" law in Singapore. Forensic Sci Int. 1987 Oct-Nov;35(2-3):131-40. https://doi.org/10.1016/0379-0738(87)90048-x PMID: 3322992
230. Zúñiga-Fajuri A. Increasing organ donation by presumed consent and allocation priority: Chile. Bull World Health Organ. 2015 Mar 1;93(3):199-202. https://doi.org/10.2471/BLT.14.139535 PMID: 25767299

APPENDICES

List of Publications

Curriculum Vitae

Acknowledgements

LIST OF PUBLICATIONS

1. Vercammen H, **Miron A**, Oellerich S, Melles GRJ, Ní Dhubhghaill S, Koppen C, Van Den Bogerd B. Corneal endothelial wound healing: understanding the regenerative capacity of the innermost layer of the cornea. Transl Res. 2022 Oct;248:111-127. https://doi.org/10.1016/j.trsl.2022.05.003 PMID: 35609782

2. **Miron A**, Sajet A, Groeneveld-van Beek EA, Kok JS, Dedeci M, de Jong M, Amo-Addae V, Melles GRJ, Oellerich S, van der Wees J. Endothelial Cell Viability after DMEK Graft Preparation. Curr Eye Res. 2021 Nov;46(11):1621-1630. https://doi.org/10.1080/02713683.2021.1927111 PMID: 34027768

3. Spinozzi D, **Miron A**, Bruinsma M, Dapena I, Kocaba V, Jager MJ, Melles GRJ, Ni Dhubhghaill S, Oellerich S. New developments in corneal endothelial cell replacement. Acta Ophthalmol. 2021 Nov;99(7):712-729. https://doi.org/10.1111/aos.14722 PMID: 33369235

4. **Miron A**, Spinozzi D, Lie J, Melles GR, Oellerich S, Ni Dhubhghaill S. Improving Endothelial Explant Tissue Culture by Novel Thermoresponsive Cell Culture System. Curr Eye Res. 2021 Mar;46(3):290-293. https://doi.org/10.1080/02713683.2020.1798468 PMID: 32727221

5. Ní Dhubhghaill S, Miron A, Lie JT, Dapena I, Oellerich S, Melles GRJ. Preclinical testing of small diameter Descemet membrane endothelial keratoplasty grafts to increase tissue availability. PLoS One. 2021 Feb 4;16(2):e0246516. https://doi.org/10.1371/journal.pone.0246516 PMID: 33539395

6. Spinozzi D, **Miron A**, Lie J, Oellerich S, Ni Dhubhghaill S, Melles GRJ. The influence of preparation and storage time on endothelial cells in Quarter-Descemet membrane endothelial keratoplasty (Quarter-DMEK) grafts in vitro. Cell Tissue Bank. 2020 Dec;21(4):615-623. https://doi.org/10.1007/s10561-020-09854-z PMID: 32797333

7. Telinius N, Spinozzi D, Rasic D, Dapena I, Baandrup U, **Miron A**, Oellerich S, Hjortdal J. Göttingen Minipig is not a Suitable Animal Model for in Vivo Testing of Tissue-Engineered Corneal Endothelial Cell-Carrier Sheets and for Endothelial Keratoplasty. Curr Eye Res. 2020 Aug;45(8):945-949 https://doi.org/10.1080/02713683.2019.1706747 PMID: 31851850

8. Birbal RS, Baydoun L, Ham L, **Miron A**, van Dijk K, Dapena I, Jager MJ, Böhringer S, Oellerich S, Melles GRJ. Effect of Surgical Indication and Preoperative Lens Status on Descemet Membrane Endothelial Keratoplasty Outcomes. Am J Ophthalmol. 2020 Apr;212:79-87. https://doi.org/10.1016/j.ajo.2019.12.011 PMID: 31863726

9. Spinozzi D, **Miron A**, Lie JT, Rafat M, Lagali N, Melles GRJ, Dhubhghaill SN, Dapena I, Oellerich S. In Vitro Evaluation and Transplantation of Human Corneal Endothelial Cells Cultured on Biocompatible Carriers. Cell Transplant. 2020 Jan-Dec;29:963689720923577. https://doi.org/10.1177/0963689720923577 PMID: 32363924

10. **Miron A**, Spinozzi D, Ní Dhubhghaill S, Lie JT, Oellerich S, Melles GRJ. In vitro endothelial cell migration from limbal edge-modified Quarter-DMEK grafts. PLoS One. 2019 Nov 20;14(11):e0225462. https://doi.org/10.1371/journal.pone.0225462 PMID: 31747441

11. Spinozzi D, **Miron A**, Bruinsma M, Dapena I, Lavy I, Binder PS, Rafat M, Oellerich S, Melles GRJ. Evaluation of the Suitability of Biocompatible Carriers as Artificial Transplants Using Cultured Porcine Corneal Endothelial Cells. Curr Eye Res. 2019 Mar;44(3):243-249. https://doi.org/10.1080/02713683.2018.1536215 PMID: 30339045

12. **Miron A**, Spinozzi D, Bruinsma M, Lie JT, Birbal RS, Baydoun L, Oellerich S, Melles GRJ. Asymmetrical endothelial cell migration from in vitro Quarter-Descemet membrane endothelial keratoplasty grafts. Acta Ophthalmol. 2018 Dec;96(8):828-833. https://doi.org/10.1111/aos.13841 PMID: 30171674

13. **Miron A**, Bruinsma M, Ham L, Schaal SC, Baydoun L, Dapena I, Oellerich S, Melles GRJ. In Vivo Endothelial Cell Density Decline in the Early Postoperative Phase After Descemet Membrane Endothelial Keratoplasty. Cornea. 2018 Jun;37(6):673-677. https://doi.org/10.1097/ICO.0000000000001484 PMID: 29737973

14. Spinozzi D, **Miron A**, Bruinsma M, Lie JT, Dapena I, Oellerich S, Melles GRJ. Improving the success rate of human corneal endothelial cell cultures from single donor corneas with stabilization medium. Cell Tissue Bank. 2018 Mar;19(1):9-17. https://doi.org/10.1007/s10561-017-9665-y PMID: 29043524

15. Fernández-López E, Miron A, Pogorelova S, Oganesyan O, Baydoun L, Melles GR. A case of severe corneal flattening after Descemet stripping endothelial keratoplasty. Eur J Ophthalmol. 2015 Dec 1;26(1):e4-7. https://doi.org/10.5301/ejo.5000658 PMID: 26350990

16. Hintze V, **Miron A**, Moeller S, Schnabelrauch M, Wiesmann HP, Worch H, Scharnweber D. Sulfated hyaluronan and chondroitin sulfate derivatives interact differently with human transforming growth factor-β1 (TGF-β1). Acta Biomater. 2012 Jul;8(6):2144-52. https://doi.org/10.1016/j.actbio.2012.03.021 PMID: 22426137

17. Hintze V, **Miron A**, Moeller S, Schnabelrauch M, Wiesmann HP, Worch H, Scharnweber D. Sulfated hyaluronan and chondroitin sulfate derivatives interact differently with human transforming growth factor-β1 (TGF-β1). Acta Biomater. 2012 Jul;8(6):2144-52. https://doi.org/10.1016/j.actbio.2012.03.021 PMID: 22426137

18. **Miron A**, Rother S, Huebner L, Hempel U, Käppler I, Moeller S, Schnabelrauch M, Scharnweber D, Hintze V. Sulfated hyaluronan influences the formation of artificial extracellular matrices and the adhesion of osteogenic cells. Macromol Biosci. 2014 Dec;14(12):1783-94. https://doi.org/10.1002/mabi.201400292 PMID: 25219504

CURRICULUL VITAE

Alina Miron was born on July 9, 1982, in Iasi, Romania. After graduating from one of the most prestigious high schools in Romania, Costache Negruzzi National College, she decided to study Computer-Programming at the Alexandru Ioan Cuza University, the oldest university of Romania, where she received her Bachelor 's degree in 2005. After one year teaching high school computer science, she decided to change her life perspectives and obtained a Master's degree in Molecular Bioengineering in 2009 at the Technical University of Dresden, Germany, under close guidance of Prof. Dr. Dieter Scharnweber. During her master studies she worked as Student Assistant in the groups of Applied Bioinformatics at Biotechnology Center of the TU Dresden (Biotec, Dresden) (Oct. 2008 – Mar. 2009) and Material Surface at Max Bergmann Center of Biomaterials Dresden (MBC, Dresden), Germany (Apr. 2009 - June 2009). Following her passion for Biomaterials Science, she continued her work as a Scientific Assistant in the group of Biomaterial Innovation for Medicine and Technology at MBC Dresden, Germany (Dec. 2009 - Jul. 2011), where she published on the influence of artificial extracellular matrices – strengthened with ligands and growth factors, on cells of osteogenic lineages. Following her dream to work in the pharmaceutical industry she continued the continental journey to The Netherlands, where she hoped to learn about business-model innovation in health. From 2012 to 2014, she followed a practical oriented professional doctorate in engineering to better suit the needs of industry – Professional Doctorate in Engineering at the Delft University of Technology, The Netherlands. She became captivated by tissue culture technologies, while designing an individual project report for a client assigned by the TU Delft, i.e., the Netherlands Institute for Innovative Ocular Surgery (NIIOS) represented at that time by Dr. Marieke Bruinsma. Her main task was to design a cell culture methodology which could be transformed into promising therapies in an attempt to reduce corneal tissue shortage. After a six-month period spent on research to find the best conditions for culture followed by the proof-of-concept validation, she proposed the cell injection therapy to be implemented as a standalone corneal therapeutic procedure. In April 2014, after completing her PDEng programme, she continued her professional career at NIIOS, first as a research scientist and later as Cell Lab Manager. At NIIOS, her research focused on regenerative strategies for the treatment of Fuchs endothelial corneal dystrophy by developing and applying in vitro cell migration assays. Also, as part of the research department, she regularly presents her results on national and international conferences with positive feedback. In 2019, she became associated with the Leiden University Medical Center (LUMC), Leiden, as a PhD student under the guidance of Prof. Dr. M.J. Jager.

Due to her strong believe in quality education, she got involved in the training of eye bankers and cell lab technicians to enrich their research perspectives, and she often inspires them to have the courage to follow their passion. During NIIOS Wetlab courses, she could often be seen next to the international ophthalmologists providing tips and tricks on how to manually prepare one of the most fragile tissues (≈15 micrometers) with minimal cell damage and maximum cell viability. With the NIIOS team, she has high hopes she will actively contribute to developing new therapeutic concepts and clinical strategies for the treatment of corneal endothelial dysfunction in a world in which natural resources will become increasingly scarce and more expensive.

ACKNOWLEDGEMENTS

Words cannot express my gratitude to my promotoer, Professor Dr. Martine Jager. I am incredibly fortunate for having had you as my supervisor and I feel privileged that life has given me the opportunity to be your PhD student. To me, you are an utterly compassionate promoter as you inspire understanding and knowledge, and also you are able to empathize with the student and offer reassurance.

This venture would not have been possible outside the borders of NIIOS, meticulously built by Dr. Gerrit Melles. It was a privilege to experience innovation under NIIOS' custody.

My gratitude extends to my co-supervisors, Dr. Silke Oellerich and Dr. Sorcha NÍ Dhubhghaill. Silke, you guided my research with extreme patience and professionalism. You taught me how to break down intricated results to smaller pieces and extract, with high fitness and precision, essential information into editable and structured data. Sorcha, thank you so much for adding a 'magical touch' to my research and for 'lifting' my view over research design limitations. I will never forget the excitement after having successfully completed the first 'mini experiment' set up between consultations, surgeries, and train trips.

I would also like to offer my special thanks to Dr. Viridiana Kocaba for introducing the concept of "Professional Beauty Intelligence". In a changing business world, she has been showing us that we must respond to change when the need arises.

A special mention goes to Hanneke van Bergen and Marieta van Utrecht who offered outright support and significantly shaped my career trajectory over 9 years at NIIOS. Hanneke, you helped me to grow professionally by giving me time and space. Marieta, you always helped me to round off the corners of my Dutch-life. I would also like to extend my gratitude to Christa, for having shown me that an assertive voice accompanied by a laugh can make impossible things possible.

I would like to extend my sincere thanks to Dr. Marieke Bruinsma for having guided me through my first years at NIIOS. My sincere gratitude goes to Dr. Lamis Baydoun, who defined the framework upon which this thesis was built. Lamis, thank you for your initiative to involve me in elucidating the mystery of asymmetric endothelial cell migration after Quarter-DMEK surgery. Additionally, I would like to thank Dr. Isabel Dapena for encouraging me to pursue a PhD and for challenging her surgical skills through *in vitro* surgeries with the most peculiar tissue engineered in our cell culture lab. A special mention goes to Dr. Jacqueline van der Wees who meticulously checked my Dutch summary and allowed me to refine my graft preparation skills culminating with *in vivo* graft transplantation.

To all the colleagues I worked with at NIIOS, thank you for the cherished time spent together. It is your kind help and support that have made my study and work at NIIOS a wonderful time. To Sandra and Maureen, who had to deal with all the packages I received and returned weekly. Franka, thanks for all the talks we had, and for the shared fruits during long working days. Within the same context, I also thank Nilza for placing goodies on my desk (je moet eten!). I thank Dr. Vincent Bourgonje, for his companionship during clinical consultation days (laser roomies for almost 5 years). Dr. Korine van Dijk and Dr. Lisanne Ham, thank you for guiding me through the collection process of post-operative medical records and for the (gezellig) time spent together on our congress trips. Dr. Jessica Lie, Anita Sajet, and Mehtap Dedeci, thank you for understanding the urge of fresh tissue for medical research. Esther Groeneveld-van Beek and Kristin Mangundap, thank you for allowing me to learn graft preparation and eye banking knowledge, but most of all for your words of comfort and support. Jet Kok, I will never forget our time spent at the congress in Washington. Vicky Amo-Addae, I will always remember our viability experiments and the extended photo saving sessions during the pandemic-induced lockdown in 2020. Petra van Leeuwen, Dina Zomot, Paulina Bylewska, and Aurora thank you so much for your friendship and the fun moments we had during my few lunch breaks or at various gatherings.

Throughout my time as a “cell gardener” (Christa’s Patent) at NIIOS, it was a great privilege for me to meet and work with the NIIOS fellows. I thank Dr. Diana Dragnea, Dr Mohamed Ghaly, Dr Ruth Quilendrino, Dr. Jorge Peraza Nieves, Dr. Eitan Livny, and Dr. Salvatore Luceri for the long lasting friendship.

I would like to acknowledge my Dresdner team from Max Bergman Center of Biomaterials, Prof. Dr. Dieter Scharnweber, PhD Dr. habil. Vera Hintze, Heike Zimmermann, and Dr. Susanne Bierbaum for helping me discover the passion for research. Prof. Scharnweber, I cherish all the support and advice you gave me, your trust and compassion, your taste for adventure to travel to Romania and attend my wedding, and lastly your words of wisdom before leaving Dresden for Delft. Vera, no words can describe the good time spent together! I will always remember our weekly lab planner (every Monday around 11:00 AM), experiments run together, articles written in tandem, cooking & eating session, watching Eurovision, and above all your passion for science and meaningful knowledge. Heike, I thank you for sharing the lab tips, tricks, and techniques with me. Susanne, I shall never forget your help to obtain my work permit documents in Germany. To this wonderful team, there are many more memorable moments of extensive support and inspiration, and I can still feel the joy of those days.

To my PhD companion and friend, Indrė: thank you for sharing with me the happiest moments of the ‘pre-PhD’ life, glamour life of a young spirit, as well as some less fortunate events that forced us to think about the present movement. In spite of our different personalities, we always found the courage to admit mistakes and accept each other for who we are. To Daniele, a very dear friend and colleague with whom I had the opportunity to work closely for 4 years. I will always remember the moments of joy when ‘digging’ for fluorescence emission signals in the most remote room of the NIIOS building, the delight of exchanging Italian-Romanian goodies, and the shared adventures when traveling abroad. I am certain that our paths will continue to intermingle in the future. To Jacky, thank you for showing me that a dream must be persuaded in spite of fear for failure even if it means losing your security blanket. Louise, I am grateful for your kindness and your support, not only with the Dutch summary or team synergy but also for showing me that a soft soul can survive only in a hard shell. Maloeke and Lydia, you are two of the people I could talk to for hours. Your vast life experience, although not easily translucent, matches well Jung’s quote, i.e. “I am not what happened to me, I am what I choose to become”. I thank you both for your inspirational talks.

To my long-distance friend Andreea, who was always ready to share a laugh and advise me how to live a meaningful life, be kind to myself, and never be afraid to dream big. Thank you Cătălina, for adding a little sparkle to my ordinary life. To Iulie and Emilia (@IE-Clothing), my favourite designers with exquisite taste and great vision on how to reinvent Romanian folk customs and propel them into the future of haute couture. Iulia, I am very thankful and honoured for having accepted to design the thesis cover image.

Thank you, Aron, for your unconditional love. You’ve embraced life with goods and bads, grew up ahead of your time, and yet you hardly seem to lack power or confidence. You make me laugh, you make me cry, you give me power! and everything in spite of you feeling lovesick, me missing your birthdays or rarely being present when you were ill. I am so very proud of the young adult you’ve become.

Părinți dragi, vă mulțumesc pentru dragostea nemărginita, încurajare și cuvintele frumoase de susținere. De la voi am învățat ca un vis devine măret atunci când izvorăște din minte și trece prin inima capătând substanță doar prin muncă susținută. Însă, mai presus de toate, vă mulțumesc pentru creșterea exemplară a lui Aron; ați format 2 generații, una mai valoroasă decât cealaltă! Mătusica dragă, am avut norocul sa te întalnesc atunci când pașii de copil îmi erau înca tremurânzi si neîncrezători. Te-am privit întotdeauan cu sfială căci seriozitatea ta nu avea nevoie de cuvinte. Îți admir independența, spiritul creator și puterea de a conduce prin „curajul umil al celui care se roagă, iubeste si iartă”.