



Universiteit
Leiden
The Netherlands

Assessment of tissue viability following amputation surgery using near-infrared fluorescence imaging with indocyanine green

Hoven, P. van den; Berg, S.D. van den; Valk, J.P. van der; Krogt, H. van der; Doorn, L.P. van; Bogt, K.E.A. van de; ... ; Vorst, J.R. van der

Citation

Hoven, P. van den, Berg, S. D. van den, Valk, J. P. van der, Krogt, H. van der, Doorn, L. P. van, Bogt, K. E. A. van de, ... Vorst, J. R. van der. (2022). Assessment of tissue viability following amputation surgery using near-infrared fluorescence imaging with indocyanine green. *Annals Of Vascular Surgery*, 78, 281-287. doi:10.1016/j.avsg.2021.04.030

Version: Publisher's Version

License: [Licensed under Article 25fa Copyright Act/Law \(Amendment Taverne\)](#)

Downloaded from: <https://hdl.handle.net/1887/3566467>

Note: To cite this publication please use the final published version (if applicable).



Clinical Research

Assessment of Tissue Viability Following Amputation Surgery Using Near-Infrared Fluorescence Imaging With Indocyanine Green

Pim Van Den Hoven,¹ Simen D. Van Den Berg,¹ Jurrian P. Van Der Valk,¹ Hanneke Van Der Krogt,³ Louk P. Van Doorn,¹ Koen E.A. Van De Bogt,¹ Jan Van Schaik,¹ Abbey Schepers,¹ Alex L. Vahrmeijer,² Jaap F. Hamming,¹ and Joost R. Van Der Vorst,¹ Leiden, The Netherlands

Background: Patients with chronic limb threatening ischemia have a risk of undergoing a major amputation within 1 year of nearly 30% with a substantial risk of re-amputation since wound healing is often impaired. Quantitative assessment of regional tissue viability following amputation surgery can identify patients at risk for impaired wound healing. In quantification of regional tissue perfusion, near-infrared (NIR) fluorescence imaging using Indocyanine Green (ICG) seems promising.

Methods: This pilot study included adult patients undergoing lower extremity amputation surgery due to peripheral artery disease or diabetes mellitus. ICG NIR fluorescence imaging was performed within 5 days following amputation surgery using the Quest Spectrum Platform[®]. Following intravenous administration of ICG, the NIR fluorescence intensity of the amputation wound was recorded for 10 minutes. The NIR fluorescence intensity videos were analyzed and if a fluorescence deficit was observed, this region was marked as “low fluorescence.” All other regions were marked as “normal fluorescence.”

Results: Successful ICG NIR fluorescence imaging was performed in 10 patients undergoing a total of 15 amputations. No “low fluorescence” regions were observed in 11 out of 15 amputation wounds. In 10 out of these 11 amputations, no wound healing problems occurred during follow-up. Regions with “low fluorescence” were observed in 4 amputation wounds. Impaired wound healing corresponding to these regions was observed in all wounds and a re-amputation was necessary in 3 out of 4. When observing time-related parameters, regions with low fluorescence had a significantly longer time to maximum intensity (113 seconds vs. 32 seconds, $P = 0.003$) and a significantly lesser decline in outflow after five minutes (80.3% vs. 57.0%, $P = 0.003$).

Conclusions: ICG NIR fluorescence imaging was able to predict postoperative skin necrosis in all four cases. Quantitative assessment of regional perfusion remains challenging due to

The authors declare that they have no known competing financial interests or personal relationships that could have appeared to influence the work reported in this paper.

¹Department of Vascular Surgery, Leiden University Medical Center, Leiden, The Netherlands

²Department of Surgical Oncology, Leiden University Medical Center, Leiden, The Netherlands

³Department of Medical Rehabilitation, Leiden University Medical Center, Leiden, The Netherlands

Correspondence to: Joost R Van Der Vorst, PhD, Department of Surgery, Leiden University Medical Center, Albinusdreef 2, 2333 ZA Leiden, The Netherlands.; E-mail: j.r.van_der_vorst@lumc.nl

Ann Vasc Surg 2022; 78: 281–287

<https://doi.org/10.1016/j.avsg.2021.04.030>

© 2021 Published by Elsevier Inc.

Manuscript received: April 3, 2021; manuscript revised: April 14, 2021; manuscript accepted: April 14, 2021; published online: 25 June 2021

influencing factors on the NIR fluorescence intensity signal, including camera angle, camera distance and ICG dosage. This was also observed in this study, contributing to a large variety in fluorescence intensity parameters among patients. To provide surgeons with reliable NIR fluorescence cut-off values for prediction of wound healing, prospective studies on the intra-operative use of this technique are required. The potential prediction of wound healing using ICG NIR fluorescence imaging will have a huge impact on patient mortality, morbidity as well as the burden of amputation surgery on health care.

INTRODUCTION

Peripheral artery disease (PAD) affects more than 200 million people and the burden of PAD is increasing due to a rise in known risk factors such as increased age and diabetes mellitus.^{1,2} Patients with PAD present with a variety of symptoms with chronic limb threatening ischemia (CLTI) being the most severe form. It is estimated that the prevalence of CLTI in patients with PAD is between 3 and 10%.^{3,4} These patients have a risk of undergoing a major amputation within 1 year of nearly 30%.⁵ Furthermore, there is a substantial risk of re-amputation since wound healing is often impaired due to the compromised vascular status and concomitant comorbidities, including diabetes mellitus.⁶ Although wound healing depends on several factors, adequate blood supply to the wound site is most important.⁷ Therefore, in prediction of wound healing and assessing the level of amputation, quantification of regional tissue perfusion is crucial. Several modalities including transcutaneous oxygen pressure measurement and hyperspectral imaging have been examined for the purpose of quantifying perfusion, however evidence on prediction of wound healing is limited.^{7,8} For quantification of regional perfusion, near-infrared (NIR) fluorescence imaging using Indocyanine Green (ICG) has shown promising results.^{9,10} This technique is based on the visualization of a fluorescent dye, ICG, in the NIR light spectrum. Upon intravenous administration of ICG, a camera creates a time-intensity curve of the region of interest (ROI) (Fig. 1). Quantification of perfusion is achieved by extraction of parameters from these curves. The use of this technique following amputation surgery in patients with PAD has been described in several case studies.¹⁰⁻¹⁴ In a retrospective cohort study of 13 patients undergoing a lower extremity amputation, Yang et al.¹⁴ found a relative perfusion value lower than 32% to have a sensitivity of 100% in identifying necrotic tissue. Prospective studies on the predictive value of ICG NIR fluorescence imaging in healing of amputation wounds have yet to be performed.

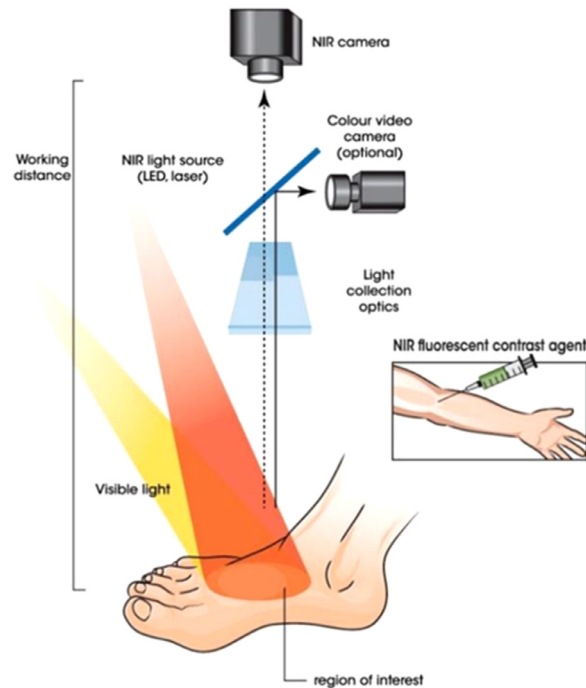


Fig. 1. ICG NIR fluorescence imaging setup.

MATERIAL AND METHODS

This prospective cohort study was approved by the Medical Research and Ethics Committee and registered in the Dutch Trial Register with number NL7531. Adult patients undergoing minor and major lower extremity amputation surgery due to PAD or diabetes mellitus were included in this study. Patients were included from October 2019 until March 2021 in a single academic hospital in the Netherlands. Exclusion criteria were allergy or hypersensitivity to sodium iodide, iodide, or ICG; hyperthyroidism or autonomous thyroid adenoma; pregnancy; kidney failure (eGFR <45) or severe liver failure. All patients were required to provide informed consent. The patients' sex, age, weight, length, Fontaine classification and previous medical history were obtained. All patients were treated according to Dutch clinical guidelines.¹⁵ To prevent postoperative edema, a soft dressing was used. Patients undergoing transtibial amputation were

treated with a rigid dressing (Össur, Reykjavik, Iceland).

ICG NIR Fluorescence Imaging Measurement

The Quest Spectrum Platform[®] (Quest Medical Imaging, Middenmeer, The Netherlands) was used to perform ICG NIR fluorescence imaging. This imaging system is capable of measuring both visible light as well as the NIR signal of ICG. Measurements were performed within 5 days following amputation surgery. Each patient was administered an intravenous bolus injection of 0.1 mg/kg ICG (VERDYE 25 mg, Diagnostic Green GmbH, Aschheim-Dornach, Germany), using a peripheral venous line. Following administration of ICG, fluorescence intensity of the amputation wound was recorded for 10 minutes. Measurements were performed on patients in a supine position in a room cleared of ambient light.

Data Interpretation

The NIR fluorescence intensity videos of the amputation wound were interpreted without knowledge of the clinical follow-up. If an area with diminished fluorescence intensity was observed, this region was marked as “low fluorescence.” All other regions were marked as “normal fluorescence.” The time-intensity curves of these regions were analyzed in the recorded videos using the Quest Research Framework[®] (Quest Medical Imaging, Middenmeer, the Netherlands). A tracker was used to ensure the region was synchronized with movement. Parameters extracted from the time intensity curves were: the ingress rate, maximum intensity, time to maximum intensity and the area under the curve for the egress after 5 minutes. Means of measured parameters were compared using an independent samples t-test. Data was analyzed using IBM SPSS Statistics 25 (IBM Corp. Released 2017. IBM SPSS Statistics for Windows, Version 25.0. Armonk, NY, USA: IBM Corp.).

RESULTS

During the study period, successful ICG NIR fluorescence imaging was performed in 10 patients undergoing a total of 15 amputations. A summary of the patient characteristics is given in [Table 1](#). Three patients underwent multiple amputations. One patient underwent a transtibial amputation after impaired wound healing following a digit amputation and a subsequent partial foot amputation. In this patient, a transfemoral

amputation of the contralateral leg was performed six months later. Another patient underwent a right transtibial amputation during follow-up following initial transtibial amputation on the left side. A third patient underwent a transfemoral amputation following a non-healing transtibial amputation wound.

No fluorescence intensity deficits were observed in 11 out of 15 amputation wounds. In 10 out of these 11 amputations, no wound healing problems occurred during follow-up. An example of a patient with a normal fluorescence intensity is shown in [Figure 2](#). This patient underwent a transtibial amputation on the left side. The merged image combines the visual and NIR fluorescence output. In one patient where no fluorescence intensity deficits were observed, a re-operation was necessary. This was a 69-year-old male with a history of diabetes mellitus undergoing a hallux amputation on the left side because of osteomyelitis. A re-operation was performed during follow-up because of ongoing bone infection. However, no skin necrosis was observed following the initial amputation and neither was debridement of the skin necessary.

Regions with “low fluorescence” were observed in 4 amputation wounds. One patient, an 82-year-old female, underwent a fourth digit amputation on the right side due to a non-healing diabetic ulcer ([Fig. 3](#)). ICG NIR fluorescence imaging showed a region of low fluorescence in the skin surrounding the amputation wound as well as the fifth digit. A partial foot amputation was performed six days later. ICG NIR fluorescence imaging showed an area of low fluorescence intensity following this amputation. A transtibial amputation was performed 5 days later, due to ischemia of the wound edges corresponding with the low fluorescence region. ICG NIR fluorescence imaging of the transtibial amputation wound showed a fluorescence deficit in the caudolateral wound edge. One month postoperatively, a necrosectomy was performed in this region of low fluorescence.

The fourth region of low fluorescence was observed in a 76-year-old male patient undergoing transtibial amputation on the right side due to Fontaine stage 4 PAD. This patient was discharged 9 days postoperatively without signs of impaired wound healing. However, three weeks postoperatively, necrosis of the wound occurred in the area corresponding with the low fluorescence region on NIR fluorescence imaging and a transfemoral amputation was necessary ([Fig. 4](#)). No fluorescence intensity deficits were observed on ICG NIR fluorescence imaging of the transfemoral amputation wound. No complications

Table I. Patient characteristics

Characteristics	Number of patients ($n = 10$)
Age (years, SD)	70.7 (7.0)
Female	4
Diabetes	7
Hypertension	5
Active smoking	0
History of smoking	5
Type amputation surgery	
Transfemoral	2
Transtibial	6
Partial foot	1
Digit(s)	6

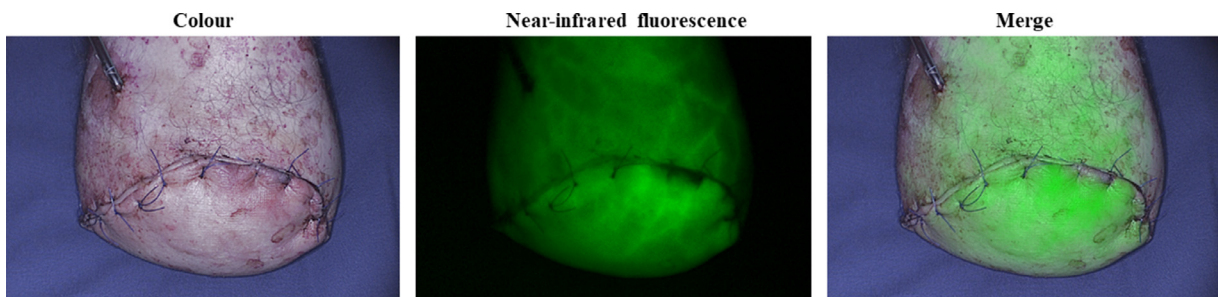


Fig. 2. ICG NIR fluorescence imaging in a 60-year-old male patient following transtibial amputation on the left side, showing the visual (*left*), NIR fluorescence (*middle*) and the merged image (*right*). No fluorescence intensity deficits were observed.

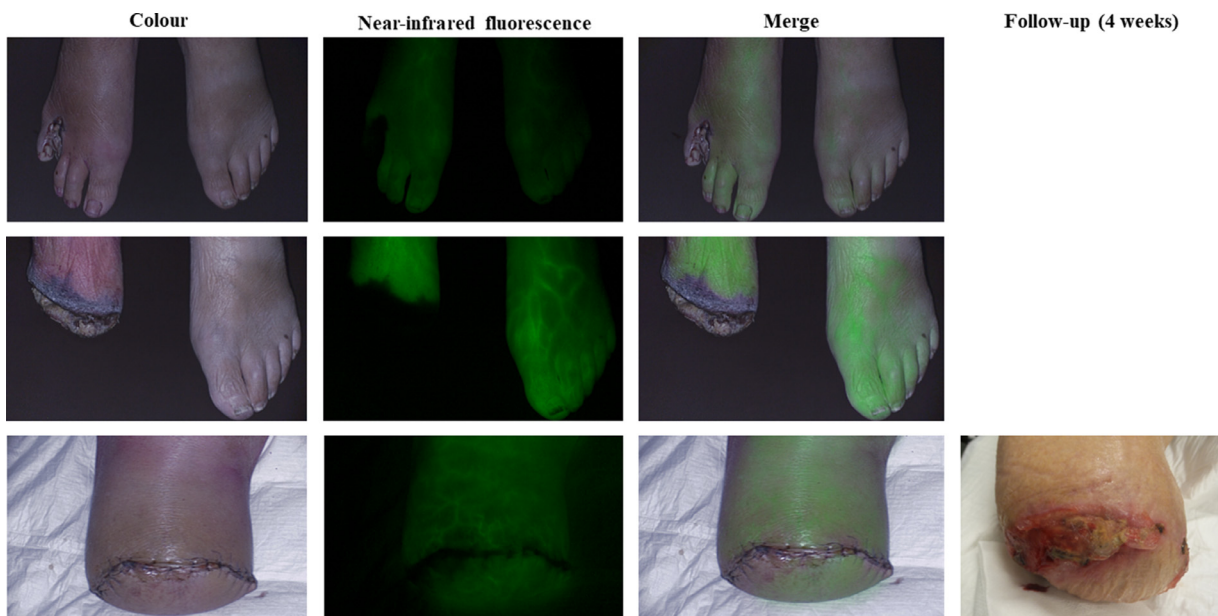


Fig. 3. ICG NIR fluorescence imaging in an 82-year-old female patient showing the visual (*left*), NIR fluorescence (*lower*) and merged image (*right*) following multiple amputations on the right side. A region of “low fluorescence” was seen in all wound edges. The region of low fluorescence of the transtibial amputation corresponded with the area where postoperative necrosectomy was necessary.

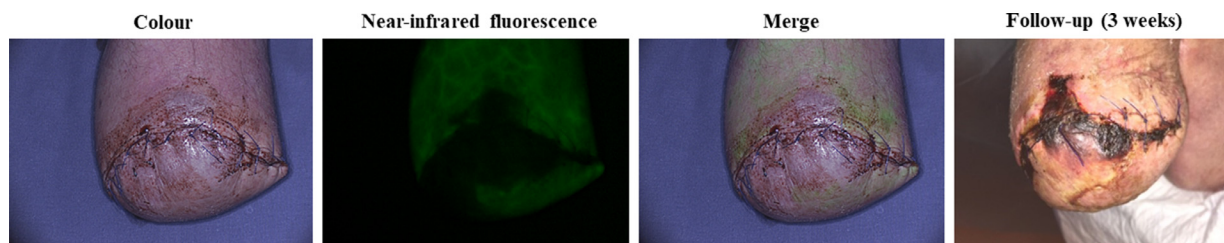


Fig. 4. ICG NIR fluorescence imaging in a 76-year-old male patient showing the visual (*left*), NIR fluorescence (*lower*) and merged image (*right*) following trans-tibial amputation on the right side. A region of low fluorescence is seen in the middle and lateral wound region. The demarcation of the skin was clearly visible 3 weeks postoperatively and corresponded with the area of low fluorescence.

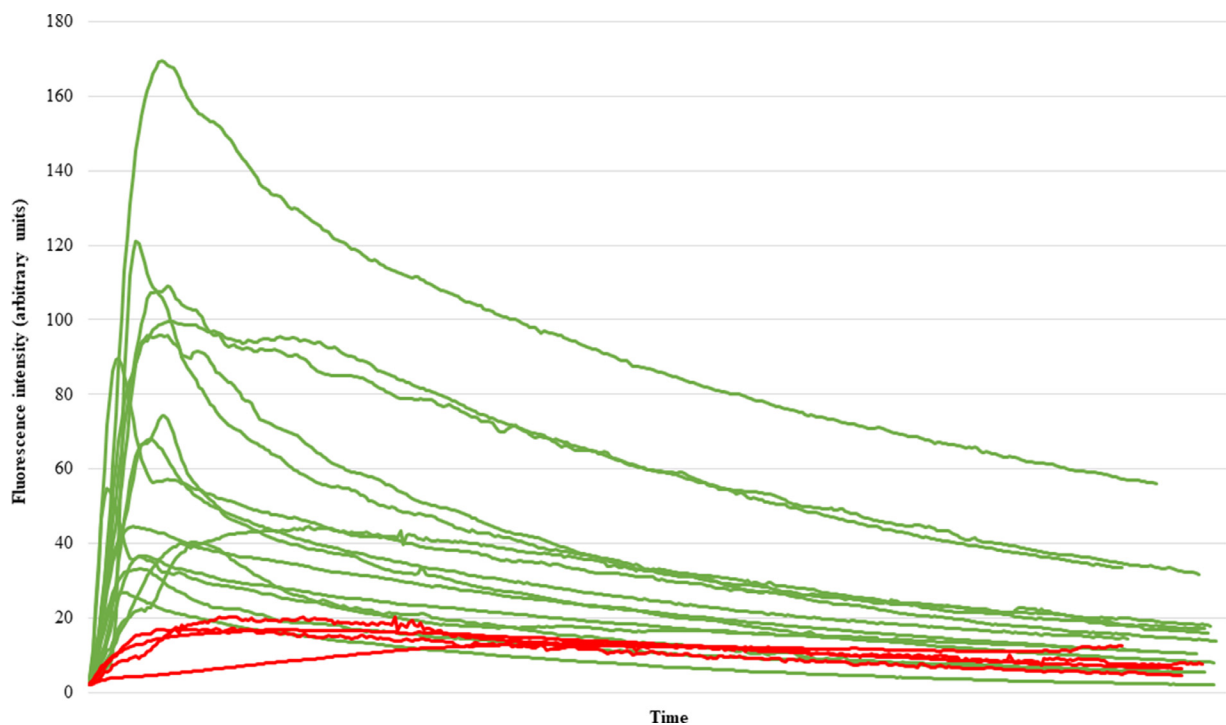


Fig. 5. Time-intensity curves in regions with normal (green) and low (red) NIR fluorescence intensity. (Color version of figure is available online.)

occurred during follow-up regarding wound healing.

Quantitative Analysis of ICG NIR Fluorescence Imaging

The time-intensity curves for the regions with “normal fluorescence” and “low fluorescence” were compared. An overview of these time-intensity curves is shown in Figure 5. Regions marked as normal fluorescence generally show a higher absolute intensity value compared with low fluorescence regions. Furthermore, an incline in inflow of fluorescence intensity can be observed. With regards to the outflow, regions

with low fluorescence tend to have a more gradual egress. The extracted fluorescence parameters are displayed in Table II. An increased maximum fluorescence intensity was observed in normal fluorescence intensity regions. Furthermore, there was a 15-fold increase in ingress rate in this group. When observing time-related parameters, regions with low fluorescence had a longer time to maximum intensity (113 seconds vs. 32 seconds, $P = 0.003$) and a lesser decline in outflow after five minutes (80.3% vs. 57.0%, $P = 0.003$). All reported fluorescence parameters were statistically significant between groups.

Table II. ICG NIR fluorescence imaging parameters of “normal fluorescence” and “low fluorescence” regions

Parameter	Normal fluorescence	Low fluorescence	P value
Maximum intensity (a.u.)	73.8 ± 10.4	16.6 ± 1.3	0.013
Ingress rate (a.u./s)	3.0 ± 0.6	0.2 ± 0.1	0.039
Tmax (s)	32.0 ± 6.1	113.0 ± 42	0.003
Egress AUC 300 (%)	57.0 ± 3.2	80.3 ± 4.4	0.003

Abbreviations

a.u., arbitrary units; AUC, area under the curve; s, second(s).

DISCUSSION

Wound healing problems occurred in 5 amputation wounds described in this cohort study. In 4 out of these 5 wounds, healing problems occurred due to non-viability of the surrounding skin. ICG NIR fluorescence imaging was able to predict this postoperative skin necrosis in all cases. Of the 11 amputation wounds classified as normal fluorescence on ICG NIR fluorescence imaging, 10 healed without complications. Impaired healing in the wound classified as normal fluorescence was not the result of skin necrosis, but ongoing osteomyelitis. Similar findings were observed in a study by Zimmerman et al.¹⁰ In this case series, ICG NIR fluorescence imaging was able to predict tissue necrosis of transtibial amputation wounds in 3 patients based on fluorescence deficits. A re-operation was needed in all these patients. The value of ICG NIR fluorescence imaging in predicting tissue necrosis in patients with PAD was also described in a retrospective cohort study of 17 amputation wounds.¹⁴ This study found a relative fluorescence intensity of <32% to be able to detect tissue necrosis. Whether this cut-off value is applicable for use in clinical practice has yet to be examined in prospective cohort studies. More extensive research on the quantitative assessment of tissue viability was conducted in reconstructive breast surgery.^{16,17} These studies show that the intra-operative use of ICG NIR fluorescence imaging has potential beneficial effects on the prediction of flap viability and clinical outcome, however, quantification of perfusion remains challenging. This is mainly the result of factors influencing the NIR fluorescence intensity signal, including camera angle, camera distance and ICG dosage.¹⁸ This was also observed in this study, contributing to a large variety in fluorescence intensity parameters among patients. Although a large inter-patient variety was observed, three parameters show a clear significant difference between “normal” and “low” fluorescence regions: the maximum intensity,

the time to maximum intensity and the egress after 5 minutes. Since relative and time-related parameters are less susceptible to camera settings and ICG dosage, it seems reasonable to explore these parameters in future studies on quantification of tissue perfusion. The same conclusion was stated in a recent systematic review on the quantification of ICG NIR fluorescence imaging in visceral perfusion.¹⁹ Although reliable quantification still faces several challenges, the potential prediction of ICG NIR fluorescence imaging on wound healing is promising. In this study, clinical judgement raised no concerns in 3 out of the 4 wounds where a low fluorescence signal was observed. In the first patient, described in [Figure 3](#), these findings could have led to an earlier, more proximal initial amputation. The second patient, described in [Figure 4](#), was admitted to the hospital 3 weeks postoperatively and underwent a transfemoral amputation on admission. More proximal amputation would possibly have resulted in prevention of re-admission, re-amputation and earlier recovery. However, this study is limited by a small set of patients and to incorporate ICG NIR fluorescence imaging for intra-operative decision making in amputation surgery, larger prospective studies with focus on quantification are needed. Providing vascular surgeons with an imaging technique able to reliably predict tissue necrosis intra-operatively will have a huge impact on patient mortality, morbidity as well as the burden of amputation surgery on health care.

CONCLUSION

This study emphasizes the potential of ICG NIR fluorescence imaging in predicting wound healing following amputation surgery. To provide surgeons with reliable NIR fluorescence cut-off values for prediction of wound healing, prospective studies on the intra-operative use of this technique are required. This includes further research on the

quantification of the measured NIR fluorescence intensity.

REFERENCES

1. Fowkes FG, Rudan D, Rudan I, et al. Comparison of global estimates of prevalence and risk factors for peripheral artery disease in 2000 and 2010: a systematic review and analysis. *Lancet* 2013;382:1329–40.
2. Criqui MH, Aboyans V. Epidemiology of peripheral artery disease. *Circ Res* 2015;116:1509–26.
3. Norgren L, Hiatt WR, Dormandy JA, et al. Inter-Society Consensus for the Management of Peripheral Arterial Disease (TASC II). *J Vasc Surg* 2007;45:S5–67 Suppl S.
4. Nehler MR, Duval S, Diao L, et al. Epidemiology of peripheral arterial disease and critical limb ischemia in an insured national population. *J Vasc Surg* 2014;60:686–95 e2.
5. Mustapha JA, Katzen BT, Neville RF, et al. Disease burden and clinical outcomes following initial diagnosis of critical limb ischemia in the medicare population. *JACC Cardiovasc Interv* 2018;11:1011–12.
6. Czerniecki JM, Thompson ML, Littman AJ, et al. Predicting reamputation risk in patients undergoing lower extremity amputation due to the complications of peripheral artery disease and/or diabetes. *Br J Surg* 2019;106:1026–34.
7. Benitez E, Sumpio BJ, Chin J, et al. Contemporary assessment of foot perfusion in patients with critical limb ischemia. *Semin Vasc Surg* 2014;27:3–15.
8. Wang Z, Hasan R, Firwana B, et al. A systematic review and meta-analysis of tests to predict wound healing in diabetic foot. *J Vasc Surg* 2016;63(2 Suppl):29S–36S.
9. van den Hoven P, Ooms S, van Manen L, et al. A systematic review of the use of near-infrared fluorescence imaging in patients with peripheral artery disease. *J Vasc Surg* 2019;70:286–97 e1.
10. Zimmermann A, Roenneberg C, Wendorff H, et al. Early postoperative detection of tissue necrosis in amputation stumps with indocyanine green fluorescence angiography. *Vasc Endovascular Surg* 2010;44:269–73.
11. Sumpio BE, Forsythe RO, Ziegler KR, et al. Clinical implications of the angiosome model in peripheral vascular disease. *J Vasc Surg* 2013;58:814–26.
12. Samies JH, Gehling M, Serena TE, et al. Use of a fluorescence angiography system in assessment of lower extremity ulcers in patients with peripheral arterial disease: a review and a look forward. *Semin Vasc Surg* 2015;28:190–4.
13. Joh JH, Park HC, Han SA, et al. Intraoperative indocyanine green angiography for the objective measurement of blood flow. *Ann Surg Treat Res* 2016;90:279–86.
14. Yang AE, Hartranft CA, Reiss A, et al. Improving outcomes for lower extremity amputations using intraoperative fluorescent angiography to predict flap viability. *Vasc Endovascular Surg* 2018;52:16–21.
15. Revalidatieartsen NVv. Amputatie en prothesiologie onderste extremiteit 2018 Available from: https://richtlijnendatabase.nl/richtlijn/amputatie_prothesiologie_onderste_extremiteit/startpagina_-_amputatie_en_prothesiologie_onderste_extremiteit.html, 18-03-2021.
16. Parmeshwar N, Sultan SM, Kim EA, et al. A systematic review of the utility of indocyanine angiography in autologous breast reconstruction. *Ann Plast Surg* 2021;86(5):601–6 Publish Ahead of Print. doi:10.1097/SAP.0000000000002576.
17. Driessen C, Arnardottir TH, Lorenzo AR, et al. How should indocyanine green dye angiography be assessed to best predict mastectomy skin flap necrosis? A systematic review. *J Plast Reconstr Aesthet Surg* 2020;73:1031–42.
18. Pruijboom T, van Kuijk SMJ, Qiu SS, et al. Optimizing indocyanine green fluorescence angiography in reconstructive flap surgery: a systematic review and ex vivo experiments. *Surg Innov* 2020;27:103–19.
19. Lutken CD, Achiam MP, Svendsen MB, et al. Optimizing quantitative fluorescence angiography for visceral perfusion assessment. *Surg Endosc* 2020;34:5223–33.