



Universiteit  
Leiden  
The Netherlands

## Maximal systolic acceleration in atherosclerotic vascular disease

Brouwers, J.J.W.M.

### Citation

Brouwers, J. J. W. M. (2023, February 16). *Maximal systolic acceleration in atherosclerotic vascular disease*. Retrieved from <https://hdl.handle.net/1887/3563626>

Version: Publisher's Version

License: [Licence agreement concerning inclusion of doctoral thesis in the Institutional Repository of the University of Leiden](#)

Downloaded from: <https://hdl.handle.net/1887/3563626>

**Note:** To cite this publication please use the final published version (if applicable).

# Part II

## Carotid artery stenosis



# Chapter 5

## A new Doppler-derived parameter to quantify internal carotid artery stenosis: maximal systolic acceleration

*Ann Vasc Surg.* 2022 Apr;81:202-210.

**Jeroen J.W.M. Brouwers**, Janey F.Y. Jiang, Robert T. Feld, Louk P. van Doorn, Rob C. van Wissen, Marianne A.A. van Walderveen, Jaap F. Hamming, Abbey Schepers



**Background**

Doppler ultrasonography (DUS) is used as initial measurement to diagnose and classify carotid artery stenosis. Local distorting factors such as vascular calcification can influence the ability to obtain DUS measurements. The DUS derived maximal systolic acceleration (ACCmax) provides a different way to determine the degree of stenosis. While conventional DUS parameters are measured at the stenosis itself, ACCmax is measured distal to the internal carotid artery (ICA) stenosis. The value of ACCmax in ICA stenosis was investigated in this study.

**Methods**

All carotid artery DUS studies of a tertiary academic center were reviewed from October 2007 until December 2017. Every ICA was included once. The ACCmax was compared to conventional DUS parameters: ICA peak systolic velocity (PSV), and PSV ratio (ICA PSV/ CCA PSV). ROC-curve analysis was used to evaluate accuracy of ACCmax, ICA PSV and PSV ratio as compared to CT-angiography (CTA) derived stenosis measurement as reference test.

**Results**

The study population consisted of 947 carotid arteries and was divided into 3 groups: <50% (710/947), 50–69% (109/947), and  $\geq$ 70% (128/947). Between these groups ACCmax was significantly different. Strong correlations between ACCmax and ICA PSV ( $R^2$  0.88) and PSV ratio ( $R^2$  0.87) were found. In ROC subanalysis, the ACCmax had a sensitivity of 90% and a specificity of 89% to diagnose a  $\geq$ 70% ICA stenosis, and a sensitivity of 82% and a specificity of 88% to diagnose a  $\geq$ 50% ICA stenosis. For diagnosing a  $\geq$ 50% ICA stenosis the area under the curve (AUC) of ACCmax (0.88) was significantly lower than the AUC of PSV ratio (0.94) and ICA PSV (0.94). To diagnose a  $\geq$ 70% ICA stenosis there were no significant differences in AUC between ACCmax (0.89), PSV ratio (0.93) and ICA PSV (0.94).

**Conclusions**

ACCmax is an interesting additional DUS measurement in determining the degree of ICA stenosis. ACCmax is measured distal to the stenosis and is not hampered by local distorting factors at the site of the stenosis. ACCmax can accurately diagnose an ICA stenosis, but was somewhat inferior compared to ICA PSV and PSV ratio to diagnose a  $\geq$ 50% ICA stenosis.

## Introduction

Carotid artery stenosis has long been recognized as an important etiological factor for ischemic stroke and large trials have determined the benefit of carotid endarterectomy (CEA) in symptomatic patients as prophylactic countermeasure against stroke.<sup>1,2,3,4,5</sup> Doppler ultrasonography (DUS) is the primary evaluation of carotid artery stenosis and management determination.<sup>6,7,8</sup> Although in many centers additional imaging (computed tomographic angiography (CTA) or MR angiography (MRA)) is obtained when intervention is considered, in some regions a majority of surgical interventions of the carotid artery is based on DUS-imaging alone.<sup>9</sup> Furthermore, the European and American guidelines mention the option of DUS alone to make a decision regarding intervention.<sup>6,7</sup> Therefore, the accuracy of this imaging technique is of the utmost importance.

According to the Society of Radiologists in Ultrasound Consensus Conference the evaluation of carotid artery stenosis with DUS-imaging relies on four parameters: peak systolic velocity (PSV) in the internal carotid artery (ICA), optical estimation of the stenosis, PSV ratio (PSV ICA/PSV common carotid artery (CCA)), and the end diastolic velocity (EDV) in the ICA.<sup>8</sup> While these parameters together provide an informative basis to determine and grade a stenosis, all four parameters are measured at the level of the stenosis and can therefore be influenced by local distorting factors. Presence of calcified atherosclerotic plaques and near occlusions can hamper these measurements and potentially lead to inaccurate estimation of degree of ICA stenosis.<sup>8,10,11,12,13</sup>

A relatively new velocimetric doppler-derived parameter, maximal systolic acceleration (ACCmax), has been evaluated in atherosclerotic diseases.<sup>14,15,16,17,18,19,20</sup> Recently we established in an in vitro study that a decreased ACCmax correlated very well with an increasing severity of stenosis, and a good correlation was found between the ACCmax and the intra-arterial pressure gradient (coefficient of determination ( $R^2$ ) of 0.937).<sup>14</sup> A high ACCmax value endorses that there is no hemodynamic inflow problem and excludes the presence of peripheral artery disease.<sup>16</sup> At the moment, ACCmax has not been evaluated in carotid artery atherosclerotic disease. A potentially benefit of ACCmax to evaluate the degree of carotid artery stenosis is the ability to perform the measurement distal from the stenosis, herewith avoiding the influence of local distorting factors, such as acoustic shadowing as a result of vascular calcification. Therefore, ACCmax could be an interesting additional feature in determining the degree of carotid artery stenosis. In this retrospective study we focused on the diagnostic value of ACCmax in a large group of ICA stenosis, as compared to conventional DUS parameters. To investigate which parameter is the most accurate one, various DUS parameters were compared to CTA as reference test.

## Methods

The institutional Medical Ethical Board approved this retrospective study. Patient data were reviewed using a local database of a tertiary academic center to identify all individuals who underwent carotid artery DUS-imaging, during the period from October 2007 until December 2017.

Measurements were excluded when DUS-imaging was performed for another reason than determining atherosclerotic ICA stenosis, including carotid body tumor, aneurysm or dissection. ICAs showing an occlusion were excluded. Carotid vessels with a stent and after CEA were excluded, since both these interventions may change the ipsilateral velocimetric properties of blood flow.<sup>21,22,23</sup> Carotid arteries showing near occlusion were excluded since ipsilateral velocities may be high, low, or undetectable.<sup>8</sup> An occlusion or >70% stenosis of the ICA is known to increase velocimetric values in the carotid artery on the contralateral side; so, their contralateral ICAs were also excluded.<sup>24,25</sup> After intervention the contralateral ICA was not excluded. Some patients had more than one DUS measurement during the study period. The repeated DUS measurements were excluded, so every ICA was included only once. Furthermore, patients with a proximal stenosis of the supra-aortic arteries (brachiocephalic and common carotid artery) were excluded. Lastly, DUS-imaging reports missing one or more critical velocimetric parameter values (CCA PSV, ICA PSV, and ACCmax in the distal ICA), were excluded.

### *Doppler Ultrasonography*

All Doppler ultrasound procedures were performed by the same vascular ultrasound specialist, using an Acuson S2000 System (Siemens Medical Solutions, Ultrasound Division, Issaquah, Wash) equipped with a 9L4 9-4 MHz linear and convex transducer. PSV ratio was measured by the PSV in the ICA at the level of the stenosis divided by PSV in the CCA. The study population was divided into the following categories: <50% stenosis, 50–69% stenosis, and ≥70% stenosis (occlusions and near occlusions were excluded), as determined on several parameters as described by Grant et al.<sup>8</sup> The ACCmax was calculated by computer at a single representative curve, as described in Brouwers et al. and is expressed in m/sec<sup>2</sup>.<sup>14</sup> The ACCmax occurs at the maximal slope in the systolic phase (see figure 1) and is measured distal to the stenosis. For an ICA stenosis the ACCmax is measured as distal as possible (extracranial), at least 2 cm distal of the ICA bulb. No additional software is necessary to obtain the ACCmax. As shown in figure 1, by clicking on two points in the screen there will be one tangent line. This tangent line must be placed manually at the maximal slope in the systolic phase at a single representative curve. The computer automatically calculates the acceleration of the tangent line at the steepest point in m/sec<sup>2</sup> (= maximal systolic acceleration). ACCmax should not be confused with either acceleration time (AT) or mean



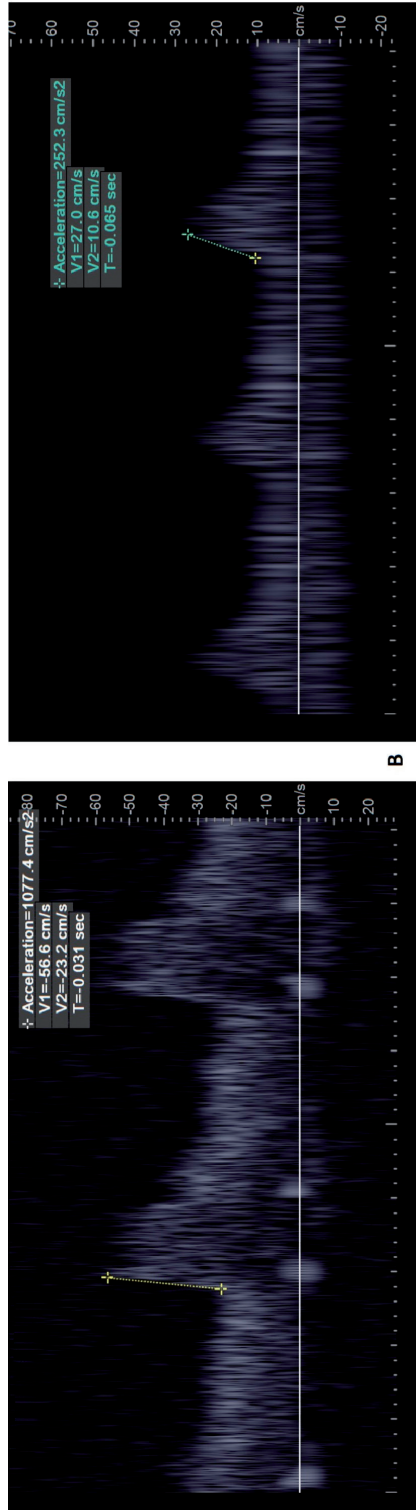


Fig. 1: Doppler waveforms from the distal extracranial ICA. (A) a normal waveform is shown without a stenosis (ACCmax 10.8 m/s<sup>2</sup>); (B) a post stenotic signal at 70–99% ICA stenosis is obtained with a decreased ACCmax (2.5 m/s<sup>2</sup>). In both figures, the ACCmax is measured at the maximal slope in the systolic phase.

systolic acceleration ( $ACC_{sys}$ ), which is the slope between beginning of systolic upstroke and peak of systole and is calculated using the following equation:  $ACC_{sys} = \Delta V_{sys}/AT$ .

### *Computed Tomography Angiography (CTA)*

DUS parameters ( $ACC_{max}$ , ICA PSV or PSV ratio) were compared to ICA stenosis measurement on CTA as reference test in a subgroup of patient, to investigate which DUS parameter is the most accurate for detecting carotid artery stenosis. CTAs which were performed in a period of six months before or after DUS examination of the study population, were included in the present study. CTA of carotid arteries was performed in patients with a  $\geq 50\%$  stenosis on DUS or debatable cases, therefore the number of CTA-imaging was less compared to DUS-studies. All included CTAs were re-examined by one radiologist (4 years of experience) blinded to the DUS results and the radiological reports of the initial examination, in order to determine the degree of stenosis. CTAs with poor image quality due to movement or insufficient contrast were excluded. All CTA examinations were performed using a 64-row or 320-row multidetector CT (Acquilion 64 and Acquilion-One Canon Medical Systems, Otawara, Japan). CTA acquisition was performed after intravenous injection of 70-75 ml of nonionic contrast medium (Ultravist 370; Bayer HealthCare) at 4.0–4.5 mL/s followed by a saline bolus of 40 mL at the same flow rate. A standard protocol was used, with 120kVp and 350 mA. Diameter reduction NASCET-style ratios were calculated for each carotid artery stenosis.<sup>1</sup> Semi-automated measurements were performed on a dedicated workstation (Vitrea, version 6.8; Vital Images). The vessel of interest was manually selected and subsequently the software automatically determined the center lumen line. After visual inspection the radiologist selected the segment of the ICA with the narrowest diameter and a distal normal post-stenotic segment as the reference site. The parameters that were then automatically assessed were the minimal and maximal vessel lumen diameters of the selected segment. All the results were verified at the perpendicular views and manually corrected if the minimal or maximal diameter was under- or overestimated. Marquering et al. showed an excellent reproducibility for this semi-automated method.<sup>26</sup>

### *Statistical Analysis*

The correlation between conventional velocimetric values (ICA PSV and PSV ratio) and the  $ACC_{max}$  was analyzed using the Pearson linear correlation test. The relation between  $ACC_{max}$  and conventional duplex parameters was fitted with nonlinear regression using the model:  $ACC_{max} \sim a/x + b/x^2$ , with  $x$  being ICA PSV or PSV ratio, the transformations  $1/x$  and  $1/x^2$  being motivated by visual inspection of the scatter plots. Note that no intercept was used since  $ACC_{max}$  tends to zero when increasing the degree of stenosis (i.e., corresponding to increasing values of ICA PSV or PSV ratio). For all analyses, the assumption was made that the velocimetric values in every vessel were independent. To investigate differences in  $ACC_{max}$  between categorical groups the Mann–Whitney U test was used (Fig. 4). In order to estimate the area under the curve (AUC) for the different parameters, ROC-curve analyses

were used. Bootstrap-analysis was used to evaluate confidence intervals for AUC ROC-curves of different parameters and Youden's index was used to determine the optimal cut-off value of a parameter. Differences with  $P < 0.05$  were considered statistically significant. For all statistical analysis and graphics R (R Foundation for Statistical Computing, Vienna, Austria) was used.

## Results

In total 676 patients underwent DUS of the carotid artery, which adds up to 2353 carotid artery measurements, as for some patients multiple DUS were performed during the study period. 1406 carotid arteries were excluded for several reasons mentioned in Figure 2, resulting in 947 carotid arteries available for analysis. From the group "post-surgical intervention (CEA)" in Figure 2, only three patients were excluded (485 carotid arteries) since the native contralateral side was not excluded after CEA. Repeated ICA measurements in the same patient were excluded in the last phase of the exclusion process, so every ICA was included only once.

The mean age of the study population was 67 years and 36% (198/545) of the patients were women. The majority of carotid arteries contained a  $<50\%$  stenosis (75%, 710/947), followed by a  $\geq 70\%$  stenosis (14%, 128/947), and 50–69% stenosis (12%, 109/947), based on DUS as determined by Grant et al.<sup>8</sup>

A Pearson correlation coefficient ( $r$ ) of  $-0.69$  was found between ACCmax and ICA PSV. The regression analysis using a nonlinear model shows a coefficient of determination ( $R^2$ ) of 0.88 between ACCmax and ICA PSV. By comparing ACCmax to PSV ratio a similar Pearson correlation coefficient ( $r -0.63$ ) and coefficient of determination ( $R^2 0.87$ ) were established. Figure 3 shows the measured data, as well as the fitted regression line of the nonlinear model between ACCmax versus ICA PSV and ACCmax versus PSV ratio.

Figure 4 depicts the plotted ACCmax divided in groups based on degree of stenosis as measured using DUS. There are significant differences in ACCmax between the following groups:  $<50\%$  versus 50–69% stenosis ( $P < 0.001$ ) and 50–69% versus  $\geq 70\%$  stenosis ( $P < 0.001$ ).

In order to investigate which DUS parameter (ACCmax, ICA PSV or PSV ratio) is the most accurate one, all parameters were compared to CTA. In this analysis, a total of 132 CTA-images were reviewed, which contained 182 carotid arteries. Sixteen CTA-images were excluded due to poor image quality, e.g., artefacts caused by movement or insufficient contrast, which included 25 carotid arteries (for some patients the contralateral side to a

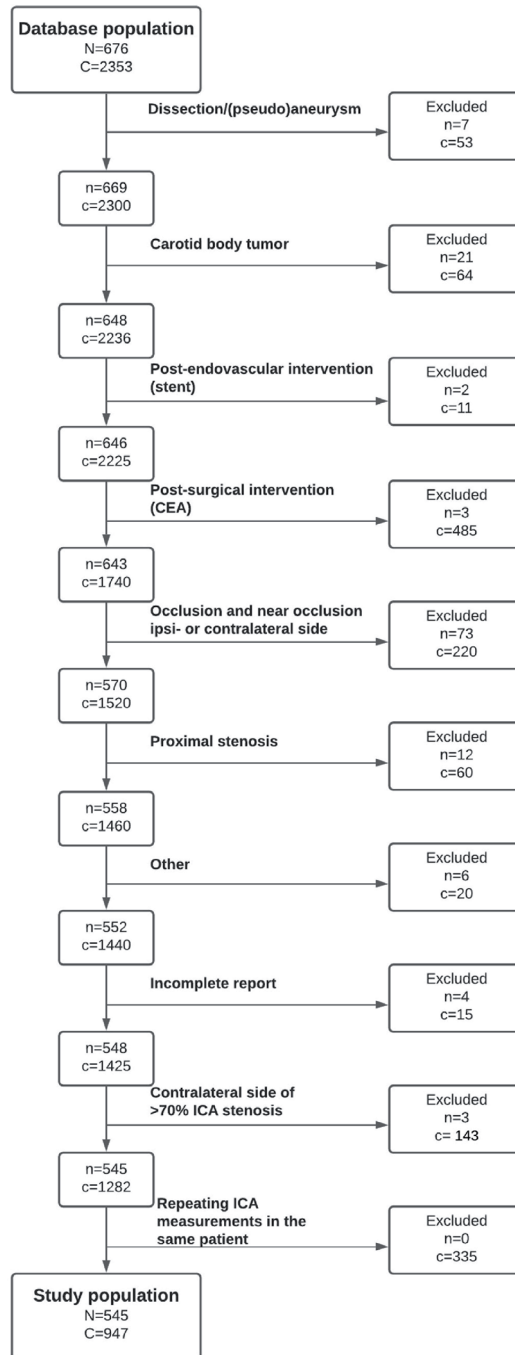


Fig. 2: Flowchart of the selection of patients. CEA = carotid endarterectomy; n = number of patients; c = number of carotid arteries; ICA = internal carotid artery. "Other" includes for example carotid-subclavian bypass. Repeating measurements in the same patient were excluded, so every ICA was included once.

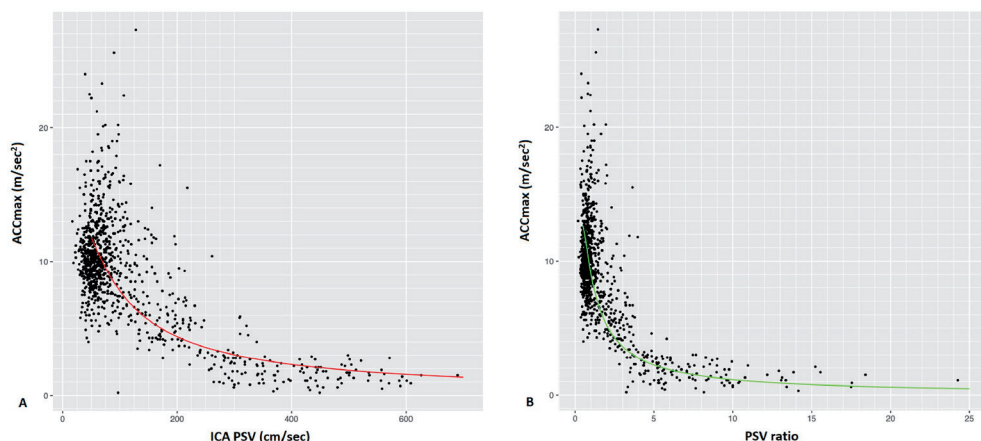


Fig. 3: Correlation between ACCmax vs. ICA PSV (A), and ACCmax versus PSV ratio (B). The scatterplot of 947 carotid arteries suggests a nonlinear relationship for both comparisons. For A, the line shows the data fitted by the nonlinear model:  $ACCmax \sim a/ICA\ PSV + b/ICA\ PSV^2$ . The fitted coefficients are  $a = 10.48$  and  $b = -2.19$ . The coefficient of determination of this model is  $R^2 = .88$ . For B, the following nonlinear model was used:  $ACCmax \sim a/PSV\ ratio + b/PSV\ ratio^2$ . The fitted coefficients are  $a = 12.93$  and  $b = -3.26$ . The coefficient of determination of this model is  $R^2 = .87$ . ACCmax: maximal systolic acceleration, ICA PSV: internal carotid artery peak systolic velocity, PSV ratio: peak systolic velocity ratio.

>70% ICA stenosis was already excluded by forming the study population, see Fig. 2). So, for this analysis 157 carotid arteries (116 patients) were enrolled. In this group 83 (53%) <50% ICA stenosis, 32 (20%) 50–69% ICA stenosis, and 42 (27%)  $\geq 70\%$  ICA stenosis was present.

Using ROC analysis, the area under the curves (AUC) for the different velocimetric parameters were calculated for detecting  $\geq 70\%$  and  $\geq 50\%$  stenosis, see Fig. 5, Fig. 6 respectively. Table I shows an overview of the performance characteristics of the cut-off values of ACCmax, ICA PSV and PSV ratio to diagnose a  $\geq 70\%$  and  $\geq 50\%$  ICA stenosis. For diagnosing a  $\geq 70\%$  ICA stenosis there were no significant differences in AUC between these parameters, calculated by bootstrap-analysis: AUC ACCmax versus AUC ICA PSV,  $P = 0.05$ ; AUC ACCmax versus AUC PSV ratio,  $P = 0.12$ ; and AUC PSV ratio versus AUC ICA PSV,  $P = 0.76$ . For diagnosing a  $\geq 50\%$  ICA stenosis there was a significant difference in AUC between ACCmax and PSV ratio ( $P = 0.02$ ), and between ACCmax and ICA PSV ( $P = 0.015$ ). The AUC between PSV ratio and ICA PSV was not significantly different ( $P = 0.94$ ).

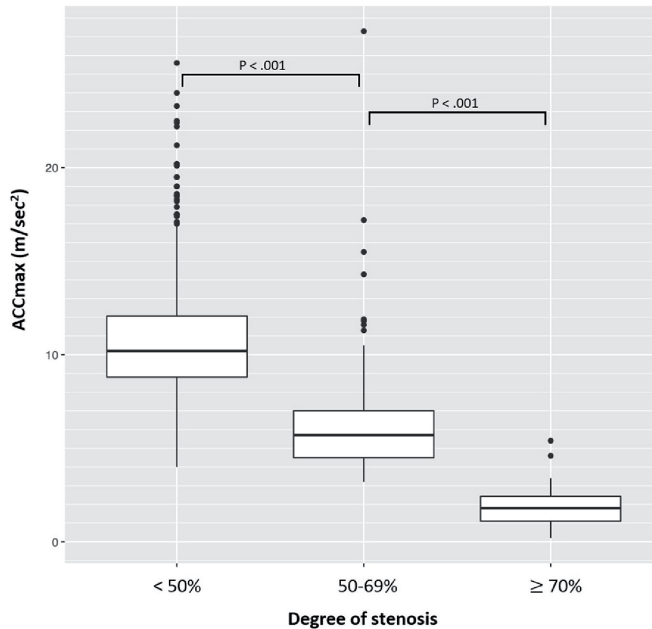


Fig. 4: ACCmax for different groups based on conventional DUS parameters. The study population (947 carotid arteries) were divided in different groups based on the criteria of Grant et al.7: <50%, 50–69%, and ≥70% stenosis but less than near occlusion. For each group the related ACCmax were given in boxplots (median, 25% quantile and 75% quantile are given). The significant differences in ACCmax between these groups are given in the figure and were determined with the Mann–Whitney U test.

	AUC (95% CI)	Optimal cut-off value	Sensitivity (%)	Specificity (%)	PLR	NLR
<b>To diagnose ≥ 50% ICA stenosis</b>						
<b>ACCmax</b>	0.88 (0.82-0.94)	7.15	82	88	6.83	0.20
<b>ICA PSV</b>	0.94 (0.91-0.97)	143	93	87	7.15	0.08
<b>PSV ratio</b>	0.94 (0.91-0.97)	1.77	88	89	8.00	0.13
<b>To diagnose ≥ 70% ICA stenosis</b>						
<b>ACCmax</b>	0.89 (0.82-0.95)	4.05	90	89	8.18	0.11
<b>ICA PSV</b>	0.94 (0.89-0.97)	212	86	90	8.60	0.16
<b>PSV ratio</b>	0.93 (0.89-0.97)	3.21	90	89	8.18	0.11

Table I: Diagnostic performance characteristics of DUS parameters to identify ICA stenosis compared to CTA as reference test

Optimal cut-off values were calculated using Youden's index

ACCmax, maximal systolic acceleration in m/sec<sup>2</sup>; AUC, area under the curve; ICA PSV, internal carotid artery peak systolic velocity in cm/sec; NLR, negative likelihood ratio; PLR, Positive likelihood ratio; PSV ratio, ICA PSV / CCA PSV

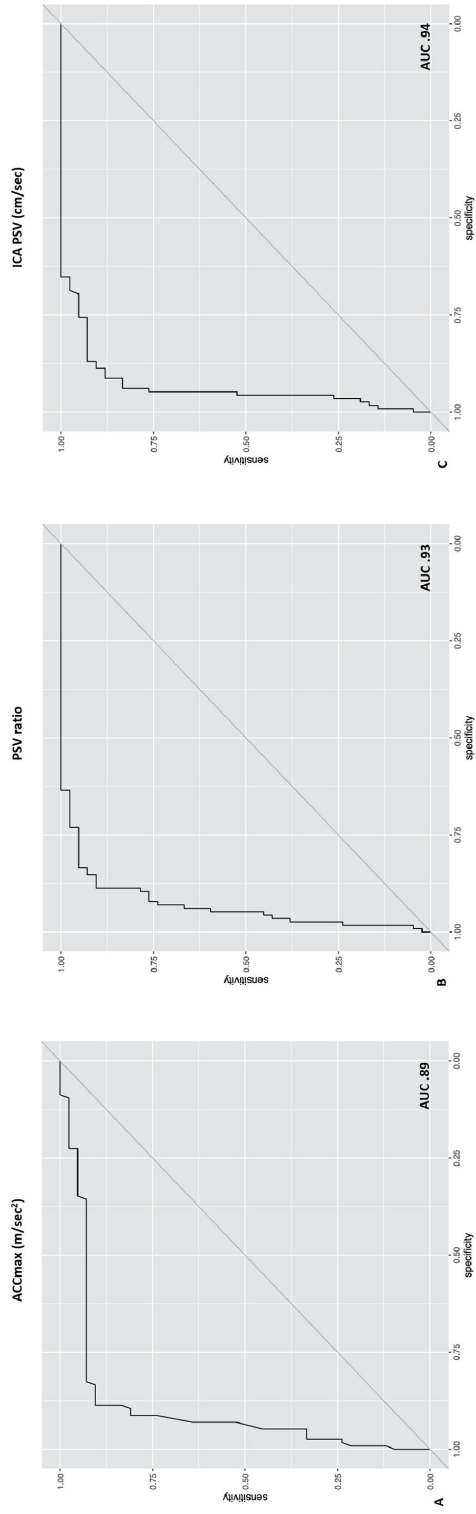


Fig. 5: ROC-curves for ACCmax, PSV ratio and ICA PSV for diagnosing  $\geq 70\%$  ICA stenosis. Data of 157 carotid arteries were used for determining the ROC-curves for ACCmax (A), PSV ratio (B) and ICA PSV (C) to diagnose  $\geq 70\%$  carotid stenosis (based on CTA-imaging). The area under the curve (AUC) is given in the figure. ACCmax: maximal systolic acceleration, PSV ratio: peak systolic velocity ratio, ICA PSV: internal carotid artery peak systolic velocity.

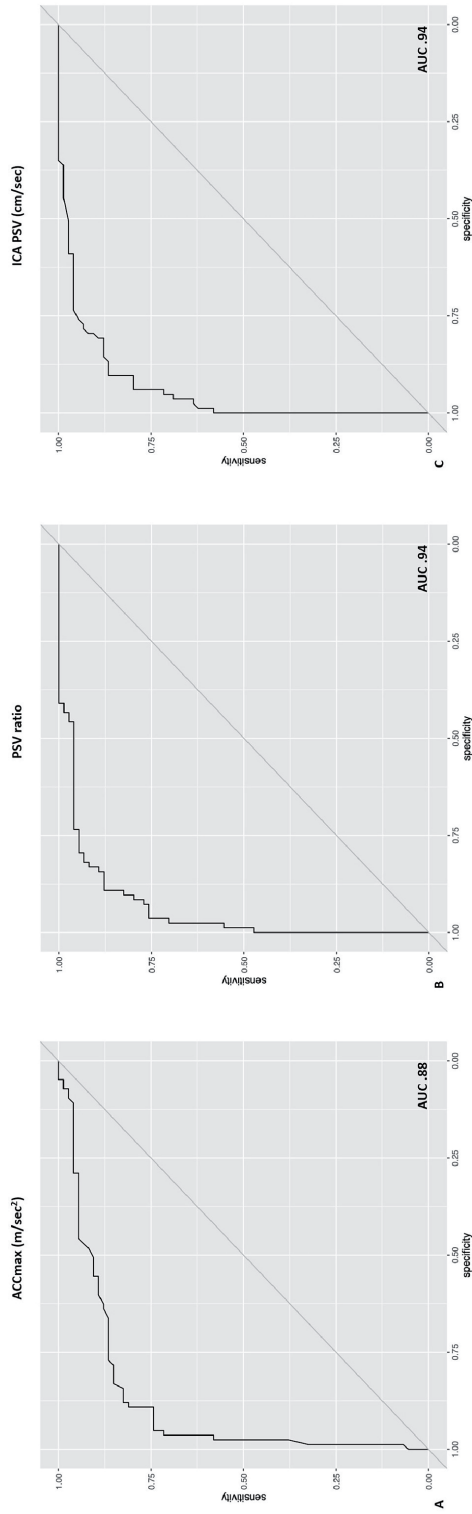


Fig. 6: ROC-curves for ACCmax, PSV ratio and ICA PSV for diagnosing  $\geq 50\%$  ICA stenosis. Data of 157 carotid arteries were used for determining the ROC-curves for ACCmax (A), PSV ratio (B) and ICA PSV (C) to diagnose  $\geq 50\%$  carotid stenosis (based on CTA-imaging). The area under the curve (AUC) is given in the figure. ACCmax: maximal systolic acceleration, PSV ratio: peak systolic velocity ratio, ICA PSV: internal carotid artery peak systolic velocity.



## Discussion

The velocimetric DUS parameter ACCmax has a strong correlation with conventional velocimetric DUS parameters that are currently used in clinical practice – ICA PSV and PSV ratio – for quantification the degree of ICA stenosis. The ACCmax decreased as the severity of stenosis increased, and by using the ACCmax a distinction can be made concerning stenosis categories (<50%, 50–69%, ≥70%). ACCmax can be used to diagnose a ≥50% and ≥70% ICA stenosis based on the diagnostic performance characteristics as given in Table I. However, ACCmax was somewhat inferior to diagnose a simple ≥50% ICA stenosis as compared to conventional Duplex parameters ICA PSV and PSV ratio.

The benefit of ACCmax is not in the accuracy of detecting a simple mild ICA stenosis, but in the ability to perform the measurement at an additional measuring point to avoid the influence of local distorting factors of a plaque. Note that all four conventional DUS parameters (ICA PSV, optical estimation of the stenosis, PSV ratio (ICA/CCA), ICA EDV) according to the Society of Radiologists in Ultrasound Consensus Conference, relies on measurements at the level of the stenosis.<sup>8</sup> From literature it is known that in 6.5% of the ICA stenosis acoustic shadow obscures the vessel lumen and thereby severely inhibiting the ability to obtain conventional DUS measurements.<sup>12</sup> ACCmax is measured distally to the stenosis, providing opportunities to avoid local acoustic shadow of a calcified stenosis. Therefore, ACCmax could be useful in patients with carotid artery stenosis that hamper an accurate DUS measurement in the stenosis.

The European and American guidelines mention DUS measurements as initial screening for carotid artery stenosis.<sup>6,7</sup> Considering the critical role of DUS in the evaluation of carotid artery stenosis, it is important that it is reliable and accurate. Since it is not possible to accurately derive the absolute degree of stenosis with DUS, multiple DUS parameters are combined to divide carotid stenosis in categories (<50%, 50–69%, and ≥70% stenosis but less than near occlusion).<sup>8</sup> Several studies report about the performance of DUS measurements. For detection of ≥70% stenosis a sensitivity of 89% and specificity of 84% was found for DUS in a meta-analysis (based on DSA).<sup>27</sup> However, to diagnose a 50–69% stenosis results are different, there seems to be less research available for this category. Wardlaw et al. shows that DUS (sensitivity of 36% and specificity of 91%) is substantially less accurate to diagnose a 50–69% stenosis and questioned the validity of them, since available data for this category is sparse.<sup>27</sup> Also, Sabeti et al. shows only 45% agreement between DUS and angiography in the differentiation of stenosis of less than 70%.<sup>28</sup> In these studies the gold standard DSA was used as reference test. Since DSA is not a common practice anymore for this patient population, CTA was used as reference test in the present study.

Bardelli et al.<sup>18</sup> described the novel ACCmax in 2006 for detection of renal artery stenosis. Subsequently several clinical studies were published about the ACCmax in renal artery stenosis<sup>17,19,20</sup> and peripheral artery diseases of the lower extremity<sup>15,16</sup>, however without investigating the interobserver agreement clinically. A previous in vitro study<sup>14</sup> revealed a good interobserver agreement for ACCmax (intraclass correlation coefficient of 0.99) and a good correlation between ACCmax and intra-arterial pressure gradient ( $R^2$  0.937) was found. In the present study the first perceptions of the value of ACCmax in carotid artery atherosclerotic disease are presented. Because a new parameter is introduced, we focused on basic principles in a large group of ICA stenosis. Apart from complex clinical settings (such as proximal stenosis of the supra-aortic arteries, near occlusions or tandem lesions), this study investigates the value of ACCmax at solitary ICA stenosis, in which the conventional DUS parameters have been proven. From here, future ACCmax research can be initiated. Future research should focus on: 1. evaluating ACCmax results in a prospective design to determine the performance of the cut-off values and interobserver agreement, 2. potential benefits of ACCmax in specific subgroups such as patients with proximal stenosis (diagnosed by a decreased ACCmax in CCA) and extensive calcific shadowing of the ICA. Novel spectral imaging (dual-energy CT) can be used to allow a more accurate assessment of calcified ICA stenosis compared to conventional CTA.<sup>29</sup>

### *Limitations*

This retrospective study has several limitations that warrant discussion. Most of the patients (75% of the carotid arteries) had a <50% stenosis and a substantial smaller number contained a 50–69% (12%) or a  $\geq 70\%$  (14%) stenosis. ACCmax was computer-based calculated and obtained at a single representative curve performed with DUS, as other DUS parameters were determined (PSV and EDV). Recently, Buschmann et al.<sup>16</sup> introduced a computer algorithm for ACCmax including several waveforms making the measurement more robust. Due to the retrospective design of the present study no interobserver analysis of ACCmax was possible to perform. However, a good interobserver agreement for ACCmax (at a single representative waveform) was revealed in a flow model study (ICC 0.99).<sup>14</sup> Bias could be introduced during the DUS measurement process, since one observer investigated several parameters. If one or more of these parameters seems suspicious, the observer is able to double check the other parameters, making the measurements more reliable clinically, but possibly interfering with the scientific method. Since DSA is nowadays not a common practice to determine the degree of a carotid artery, DUS parameters (including ACCmax) were compared to CTA-determined stenosis, instead of the historical gold standard: DSA. Finally, the number of extensive calcified plaques that hamper the ability to obtain a reliable DUS measurement in the ICA was unknown in this study population as a result of the retrospective design.

## Conclusion

The new velocimetric DUS parameter, maximal systolic acceleration (ACCmax), is an interesting diagnostic parameter in carotid artery stenosis. The present study shows that ACCmax has a strong correlation with currently used DUS parameters in detecting an ICA stenosis and can divided ICA stenosis into categories (<50%, 50–69%, ≥70%). Therefore, ACCmax can be used as additional measurement. It is easy to obtain and does not have the disadvantages of the conventional DUS parameters of local distorting factors since it is measured distal to the stenosis. Although, in our patient group ACCmax was less accurate to diagnose a ≥50% ICA stenosis compared to ICA PSV and PSV ratio, it is worthwhile to further investigate the accuracy of ACCmax in a prospective design and in specific subgroups such as patients with extensive calcified plaques.

## Acknowledgments

The authors thank professor H. Putter from the Department of Medical Statistics and Bioinformatics (Leiden University Medical Center) for assistance with statistical analysis.

## References

1. Methods, patient characteristics, and progress. *Stroke*. *Stroke* 1991;22:711–20.
2. Barnett HJM, Taylor DW, Haynes RB, et al. Beneficial effect of carotid endarterectomy in symptomatic patients with high-grade carotid stenosis. *N Engl J Med* 1991;325:445–53.
3. European Warlow CMRC. Carotid Surgery Trial: interim results for symptomatic patients with severe (70–99%) or with mild (0–29%) carotid stenosis. *Lancet* 1991;337:1235–43.
4. Rothwell PM, Eliasziw M, Gutnikov SA, et al. Analysis of pooled data from the randomised controlled trials of endarterectomy for symptomatic carotid stenosis. *Lancet* 2003;361:107–16.
5. Flaherty ML, Kissela B, Khoury JC, et al. Carotid artery stenosis as a cause of stroke. *Neuroepidemiology* 2013;40:36–41.
6. Naylor AR, Ricco JB, de Borst GJ, et al. Editor's Choice – Management of Atherosclerotic Carotid and Vertebral Artery Disease: 2017 Clinical Practice Guidelines of the European Society for Vascular Surgery (ESVS). *Eur J Vasc Endovasc Surg* 2018;55:3–81.
7. Ricotta JJ, Aburama A, Ascher E, et al. Updated Society for Vascular Surgery guidelines for management of extracranial carotid disease. *J Vasc Surg* 2011;54:e1–31.
8. Grant EG, Benson CB, Moneta GL, et al. Carotid Artery Stenosis: Gray-Scale and Doppler US Diagnosis—Society of Radiologists in Ultrasound Consensus Conference. *Radiology* 2003;229:340–6.
9. Cronenwett JL, Likosky DS, Russell MT, et al. A regional registry for quality assurance and improvement: The Vascular Study Group of Northern New England (VSGNNE). *J Vasc Surg* 2007;46:1093–103.
10. Corriveau MM, Johnston KW. Interobserver variability of carotid Doppler peak velocity measurements among technologists in an ICAVL-accredited vascular laboratory. *J Vasc Surg* 2004;39:735–41.
11. Criswell BK, Langsfeld M, Tullis MJ, et al. Evaluating institutional variability of duplex scanning in the detection of carotid artery stenosis. *Am J Surg* 1998;176:591–7.
12. Mohebbi J, Patel VI, Romero JM, et al. Acoustic shadowing impairs accurate characterization of stenosis in carotid ultrasound examinations Presented at the plenary session of the 2014 Joint Annual Meeting of the New England Society for Vascular Surgery and Eastern Vascular Society. Boston, Mas.. *J Vasc Surg* 2015;62:1236–44.
13. Back MR, Rogers GA, Wilson JS, et al. Magnetic resonance angiography minimizes need for arteriography after inadequate carotid duplex ultrasound scanning. *J Vasc Surg* 2003;38:422–30 discussion 431.
14. Brouwers JJWM, van Doorn LP, van Wissen RC, et al. Using maximal systolic acceleration to diagnose and assess the severity of peripheral artery disease in a flow model study. *J Vasc Surg* 2020;71:242–9.
15. Van Tongeren RB, Bastiaansen AJNM, Van Wissen RC, et al. A comparison of the Doppler-derived maximal systolic acceleration versus the ankle-brachial pressure index or detecting

- and quantifying peripheral arterial occlusive disease in diabetic patients. *J Cardiovasc Surg (Torino)* 2010;51:391–8.
16. Buschmann EE, Li L, Brix M, et al. A novel computer-aided diagnostic approach for detecting peripheral arterial disease in patients with diabetes. *PLoS One* 2018;13:e0199374. 1–7.
  17. Brouwers JJWM, van Wissen RC, Veger HTC, et al. The use of intrarenal Doppler ultrasonography as predictor for positive outcome after renal artery revascularization. *Vascular* 2017;25:63–73.
  18. Bardelli M, Veglio F, Arosio E, et al. New intrarenal echo-Doppler velocimetric indices for the diagnosis of renal artery stenosis. *Kidney Int* 2006;69:580–7.
  19. Johansson M, Jensen G, Aurell M, et al. Evaluation of duplex ultrasound and captopril renography for detection of renovascular hypertension. *Kidney Int* 2000;58:774–82.
  20. Saeed A, Bergstrom G, Zachrisson K, et al. Accuracy of colour duplex sonography for the diagnosis of renal artery stenosis. *J Hypertens* 2009;27:1690–6.
  21. Lucatelli P, Fanelli F, Cirelli C, et al. Carotid endarterectomy versus stenting: Does the flow really change? An Echo-Color-Doppler analysis. *Int J Cardiovasc Imaging* 2015;31:773–81.
  22. Grambow E, Heller T, Wieneke P, et al. Assessing the effect of different operation techniques on postoperative duplex ultrasound quality after carotid endarterectomy. *Clin Hemorheol Microcirc* 2018;68:17–24.
  23. Bandyk DF, Moldenhauer P, Lipchik E, et al. Accuracy of duplex scanning in the detection of stenosis after carotid endarterectomy. *J Vasc Surg* 1988;8:696–702.
  24. van Everdingen KJ, van der Grond J, Kappelle LJ. Overestimation of a stenosis in the internal carotid artery by duplex sonography caused by an increase in volume flow. *J Vasc Surg* 1998;27:479–85.
  25. Henderson RD, Steinman DA, Eliasziw M, et al. Effect of contralateral carotid artery stenosis on carotid ultrasound velocity measurements. *Stroke* 2000;31:2636–40.
  26. Marquering HA, Nederkoorn PJ, Smagge L, et al. Performance of semiautomatic assessment of carotid artery stenosis on CT angiography: clarification of differences with manual assessment. *AJNR Am J Neuroradiol* 2012;33:747–54.
  27. Wardlaw J, Chappell F, Best J, et al. Non-invasive imaging compared with intra-arterial angiography in the diagnosis of symptomatic carotid stenosis: a meta-analysis. *Lancet* 2006;367:1503–12.
  28. Sabeti S, Schillinger M, Mlekusch W, et al. Quantification of internal carotid artery stenosis with duplex US: Comparative analysis of different flow velocity criteria. *Radiology* 2004;232:431–9.
  29. Mannil M, Ramachandran J, Vittoria de Martini I, et al. Modified dual-energy algorithm for calcified plaque removal: evaluation in carotid computed tomography angiography and comparison with digital subtraction angiography. *Invest Radiol* 2017;52:680–5.