



Universiteit  
Leiden  
The Netherlands

## **Intensive endoscopic therapy for untreated cervical anastomotic strictures after esophagectomy: a pilot study**

Halsema, E.E. van; Bergman, J.J.G.H.M.; Sandick, J.W. van; Henegouwen, M.I.V.; Cats, A.; Veenhof, A.A.F.A.; ... ; Dieren, J.M. van

### **Citation**

Halsema, E. E. van, Bergman, J. J. G. H. M., Sandick, J. W. van, Henegouwen, M. I. V., Cats, A., Veenhof, A. A. F. A., ... Dieren, J. M. van. (2022). Intensive endoscopic therapy for untreated cervical anastomotic strictures after esophagectomy: a pilot study. *Surgical Endoscopy*, 37, 2029-2034. doi:10.1007/s00464-022-09731-8

Version: Publisher's Version

License: [Leiden University Non-exclusive license](#)

Downloaded from: <https://hdl.handle.net/1887/3563251>

**Note:** To cite this publication please use the final published version (if applicable).



# Intensive endoscopic therapy for untreated cervical anastomotic strictures after esophagectomy: a pilot study

Emo E. van Halsema<sup>1</sup> · Jacques J. G. H. M. Bergman<sup>1</sup> · Johanna W. van Sandick<sup>2</sup> · Mark I. van Berge Henegouwen<sup>3</sup> · Annemieke Cats<sup>5</sup> · Alexander A. F. A. Veenhof<sup>2</sup> · Jeanin E. van Hooft<sup>1,4</sup> · Jolanda M. van Dieren<sup>5</sup>

Received: 24 February 2022 / Accepted: 11 October 2022

© The Author(s), under exclusive licence to Springer Science+Business Media, LLC, part of Springer Nature 2022

## Abstract

**Background** Cervical anastomotic strictures after esophagectomy cause significant disease burden. We aimed to study the technical feasibility and safety of intensive endoscopic therapy.

**Methods** In this pilot study, we included 15 patients with an untreated benign cervical anastomotic stricture after esophagectomy. Intensive endoscopic therapy comprised three endoscopic modalities: in- and excision using a needle-knife, intralésional steroid injections and bougie dilation. In two endoscopic procedures, the stricture was dilated up to a luminal diameter of 18 mm. Patients were followed up to 6 months.

**Results** A luminal diameter of 18 mm was achieved in 13 of 15 patients (87%) after two endoscopic procedures. No major adverse events related to the investigational treatment occurred. Median dysphagia scores significantly improved from 2 (IQR, interquartile range, 2–3) at baseline to 0 (IQR 0–1) after 14 days ( $p < 0.001$ ). Eleven (73%) patients developed recurrent symptoms of dysphagia requiring a median of 1 (IQR 0–3) additional endoscopic dilation procedure.

**Conclusions** Achieving a luminal diameter of 18 mm in two procedures with intensive endoscopic therapy was technically feasible and effective in reducing dysphagia rapidly in patients with a cervical anastomotic stricture after esophagectomy. No major adverse events related to the investigational treatment were observed.

**Keywords** Benign esophageal strictures · Endoscopic dilation · Esophagus · Endoscopic therapy · Esophagectomy · Anastomosis

One of the major issues after esophagectomy with gastric tube reconstruction and cervical anastomosis is the

development of a benign anastomotic stricture, which occurs in up to 44% of patients [1]. Anastomotic strictures after esophagectomy cause complaints of dysphagia and weight loss, and have a negative impact on patients' quality of life [2]. Endoscopic bougie or balloon dilation is currently the standard treatment to resolve dysphagia caused by anastomotic strictures. However, this approach is time-consuming, because patients usually require repeated endoscopic dilation procedures to reach a satisfactory luminal diameter and there is a high risk of stricture recurrence [1, 3]. Other endoscopic approaches include electrocautery incision of the stricture and adding intralésional corticosteroid injections to dilation. These treatment modalities have been studied separately in randomized trials [4–6]. Our objective was to study the technical feasibility and safety of combining endoscopic in- and excision of the stricture followed by intralésional steroid injection and bougie dilation in one session as primary treatment for benign cervical anastomotic strictures after esophagectomy.

The study was accepted and presented as e-poster (ID: P1415) at UEG Week Virtual 2020.

✉ Jolanda M. van Dieren  
j.v.dieren@nki.nl

- <sup>1</sup> Department of Gastroenterology and Hepatology, Amsterdam University Medical Centers, Location AMC, Amsterdam, The Netherlands
- <sup>2</sup> Department of Surgical Oncology, The Netherlands Cancer Institute, Amsterdam, The Netherlands
- <sup>3</sup> Department of Surgery, Amsterdam University Medical Centers, Location VUMC, Amsterdam, The Netherlands
- <sup>4</sup> Department of Gastroenterology and Hepatology, Leiden University Medical Center, Leiden, The Netherlands
- <sup>5</sup> Department of Gastrointestinal Oncology, The Netherlands Cancer Institute, Amsterdam, The Netherlands

## Materials and methods

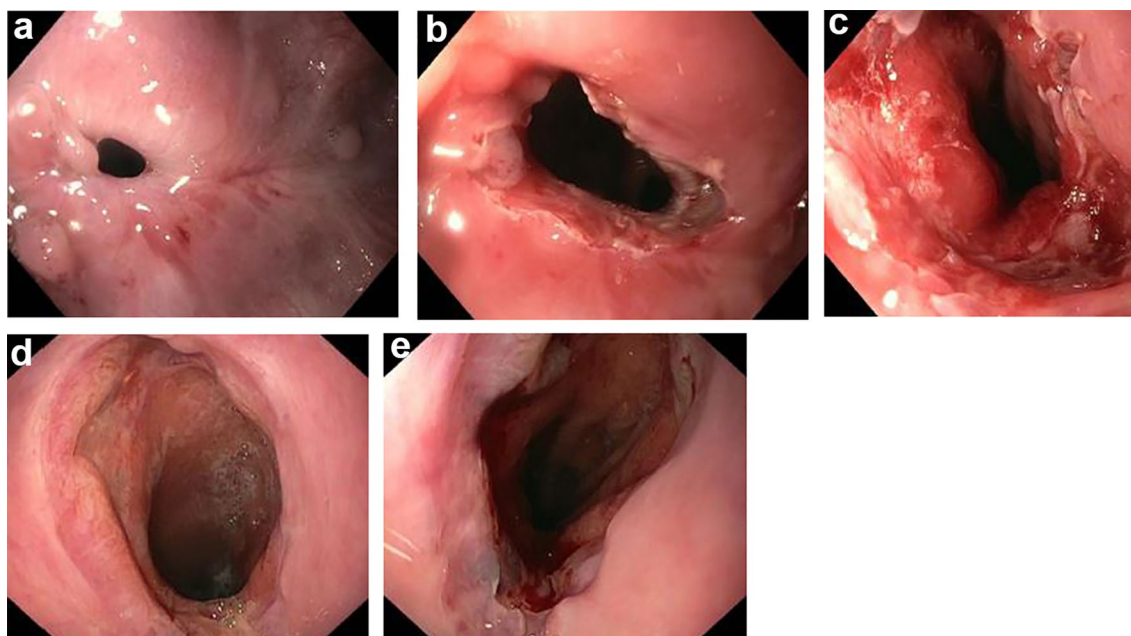
In this prospective pilot study, between July 2017 and September 2018, we included 15 patients with a newly diagnosed and untreated benign cervical anastomotic stricture after esophagectomy. All patients were included in a single center (the Netherlands Cancer Institute) and provided written informed consent before inclusion. Patients were eligible for inclusion if they had dysphagia for solid foods, i.e. Ogilvie dysphagia score of at least two [7]. A stricture was defined as the inability to pass with a regular diagnostic gastroscop. Exclusion criteria were: previous endoscopic stricture therapy; post-esophagectomy stent placement for anastomotic dehiscence; stricture morphology unsuitable for needle-knife incision (i.e. > 1 cm long, irregular or tortuous); recurrent or metastasized esophageal cancer; persisting postoperative esophageal fistula; the inability to discontinue anticoagulants or high-dose antiplatelet drugs at time of the baseline procedure.

The investigational treatment, hereafter referred to as ‘intensive endoscopic therapy’ (Fig. 1a–e), comprised three endoscopic modalities: (1) At least four longitudinal incisions around the circumference of the stenosis followed by excision of the fibrotic flaps using a needle-knife catheter, allowing the gastroscop to easily pass the stricture. (2) Following in- and excision, a total of 80 mg of triamcinolone was injected into four quadrants of the lesion. (3)

Thereafter, bougie dilation up to 16 mm was performed. Then the patient was scheduled for a second endoscopic procedure approximately 1 week later during which bougie dilation up to a luminal diameter of 18 mm was performed. We prescribed a proton pump inhibitor of 40 mg twice a day for at least 1 month after the first endoscopic procedure. The primary outcome was technical success, defined as the ability to reach a luminal diameter of 18 mm after two endoscopic procedures. Secondary outcomes included recurrence of dysphagia, number of additional endoscopic dilation procedures, adverse events, weight, general health score from 0 to 100 (i.e. worst to best imaginable health) and therapy satisfaction score from 0 to 10 (i.e. extremely unsatisfied to extremely satisfied). Patients were followed by telephonic interviews at 14 days after the second endoscopic procedure and thereafter monthly up to 6 months.

We described continuous variables as mean with standard deviation (SD) and median with interquartile range (IQR) when they had a normal and skewed distribution, respectively. To analyze the efficacy of intensive endoscopic therapy on dysphagia scores, weight and general health scores, we used the paired *t*-test and Wilcoxon signed rank test for normally and non-normally distributed variables, respectively.

The study protocol was reviewed and approved by the medical ethics review committee of the academic medical center (date of review: 11 October 2016). The study was



**Fig. 1** **a** Untreated cervical anastomotic esophageal stricture. **b** After four longitudinal incisions and excision of fibrotic flaps. **c** After in- and excision, intralésional steroid injection and bougie dilation up to

16 mm. **d** Eight days later. **e** After bougie dilation up to 18 mm during the 2nd endoscopy

registered in the Netherlands trial register (ID: NTR6006/NL5764; date of registration: 29 February 2016).

## Results

In 15 patients (9 males, mean age 64.5 years) intensive endoscopic therapy was performed after a mean of 78 days following esophagectomy, baseline characteristics are provided in Table 1. All cervical anastomoses were hand-sewn and 80% (12/15) of patients had experienced postoperative anastomotic leakage which was treated conservatively in all cases.

A luminal diameter of 18 mm was successfully achieved after the two endoscopic study procedures in 13 of 15 patients (87%). One patient did not undergo the 2nd endoscopic procedure because of a myocardial infarction. In the other patient in whom no 18 mm was achieved, a diameter of 14 mm was reached during the first study procedure and therefore it was not considered safe to dilate more than the usual 3 mm during the second procedure. Table 2 presents the technical outcomes of intensive endoscopic therapy.

All patients completed the 6 months of follow-up, except one patient who deceased after 4 months because of metastasized esophageal cancer. The median Ogilvie dysphagia score significantly improved from 2 (IQR 2–3) at baseline to 0 (IQR 0–1) after 14 days ( $p < 0.001$ ). The mean self-reported weight significantly decreased from 77.3 kg  $\pm$  SD 16.1 at baseline to 75.5 kg  $\pm$  SD 15.4 after one month ( $p = 0.021$ ) and remained stable at 75 kg up to 6 months of follow-up. The mean general health score significantly improved from 62  $\pm$  SD 17 at baseline to 73  $\pm$  SD 16 after 1 month ( $p = 0.041$ ), but this effect did not last up to 6 months (71  $\pm$  SD 28,  $p = 0.313$ ), see

**Table 1** Baseline characteristics ( $N = 15$ )

	Total
Gender; male	9 (60%)
Age; mean $\pm$ SD	64.5 $\pm$ 7.0 years
Weight; mean $\pm$ SD	77.3 $\pm$ 16.1 kg
BMI; median (IQR)	23.9 (22.5–26.0)
Time between esophagectomy and 1st endoscopic procedure; mean $\pm$ SD	78 $\pm$ 21 days
Anastomosis; hand-sewn	15 (100%)
Postoperative anastomotic leak	12 (80%)
Estimated length of stricture; median (IQR)	4 (4–5) mm
Ogilvie dysphagia score	
2	10 (66.7%)
3	4 (26.7%)
4	1 (6.7%)
Feeding jejunostomy	11 (73.3%)
General health score 0–100; mean $\pm$ SD	62 $\pm$ 17

Ogilvie dysphagia score: 0=able to eat everything, 1=occasional dysphagia for some solid food, 2=able to swallow semi-solid food, 3=able to swallow liquids, 4=dysphagia for liquids

SD standard deviation, IQR interquartile range

**Table 2** Technical outcomes of intensive endoscopic therapy ( $N = 15$ )

	Total
$\geq 4$ incisions and enough excisions to enable passage of diagnostic gastroscop	
Yes	9 (60%)
No	6 (40%)
20 mg of triamcinolone injected into four quadrants	
Yes	15 (100%)
No	0 (0%)
Bougie dilation up to 16 mm at 1st endoscopic study procedure	
Yes	13 (86.7%)
No	2 (13.3%)
Time between 1st and 2nd endoscopic study procedure <sup>a</sup> ; median (IQR)	8 (7–12) days
Ability to pass stricture with diagnostic gastroscop at 2nd endoscopic study procedure <sup>a</sup>	
Yes	14 (93.3%)
No	0 (0%)
Bougie dilation up to 18 mm at 2nd endoscopic study procedure <sup>a</sup>	
Yes	13 (86.7%)
No	1 (6.7%)

IQR interquartile range

<sup>a</sup>One patient did not undergo the 2nd endoscopic procedure because of a myocardial infarction

**Table 3** Outcomes ( $N=15$ )

	Total	<i>p</i> -value
Ogilvie dysphagia score; median (IQR)		
Baseline	2 (2–3)	Ref. <sup>b</sup>
2nd endoscopic study procedure; missing $n=1$	0.5 (0–1)	0.001
14 days	0 (0–1)	<0.001
1 month	1 (0–1)	0.001
2 months; missing $n=1$	1 (0–1.25)	0.002
3 months	1 (0–1)	0.001
4 months	1 (0–1)	<0.001
5 months; missing $n=3$	1 (0.25–1)	0.002
6 months; missing $n=1$	1 (0–1)	0.001
Weight (kg); mean $\pm$ SD		
Baseline	77.3 $\pm$ 16.1	Ref. <sup>a</sup>
14 days	76.1 $\pm$ 15.4	0.011
1 month	75.5 $\pm$ 15.4	0.021
2 months; missing $n=1$	75.1 $\pm$ 15.6	0.006
3 months	75.3 $\pm$ 14.0	0.035
4 months	75.0 $\pm$ 14.0	0.035
5 months; missing $n=3$	74.9 $\pm$ 14.8	0.166
6 months; missing $n=1$	75.0 $\pm$ 14.1	0.023
General health score 0–100; mean $\pm$ SD		
Baseline	62 $\pm$ 17	Ref. <sup>a</sup>
14 days	69 $\pm$ 22	0.412
1 month	73 $\pm$ 16	0.041
2 months; missing $n=1$	79 $\pm$ 14	0.007
3 months	75 $\pm$ 21	0.043
4 months	73 $\pm$ 21	0.084
5 months; missing $n=3$	72 $\pm$ 20	0.076
6 months; missing $n=1$	71 $\pm$ 28	0.313

Ogilvie dysphagia score: 0=able to eat everything, 1=occasional dysphagia for some solid food, 2=able to swallow semi-solid food, 3=able to swallow liquids, 4=dysphagia for liquids

SD standard deviation, *ref* reference, *IQR* interquartile range

<sup>a</sup>Paired *t*-test

<sup>b</sup>Wilcoxon signed rank test

also Table 3. The median therapy satisfaction scores after 14 days and 6 months were 9 (IQR 9–10) and 8 (IQR 7–9), respectively.

Eleven (73%) patients developed recurrent symptoms of dysphagia requiring a median of 1 (IQR 0–3) additional endoscopic dilation procedure after 6 months of follow-up, see also Fig. 2.

Adverse events related to the investigational treatment included candida esophagitis ( $n=2$ , 13%) and pale mucosa/superficial ischemia of the gastric tube after steroid injection ( $n=1$ , 7%). One patient (7%) on dual antiplatelet therapy, which was started after the initial endoscopic procedure, reported a small amount of hematemesis after regular bougie dilation for recurrence of dysphagia, without indication for

re-intervention. Three patients (20%) developed metastatic disease during the study period.

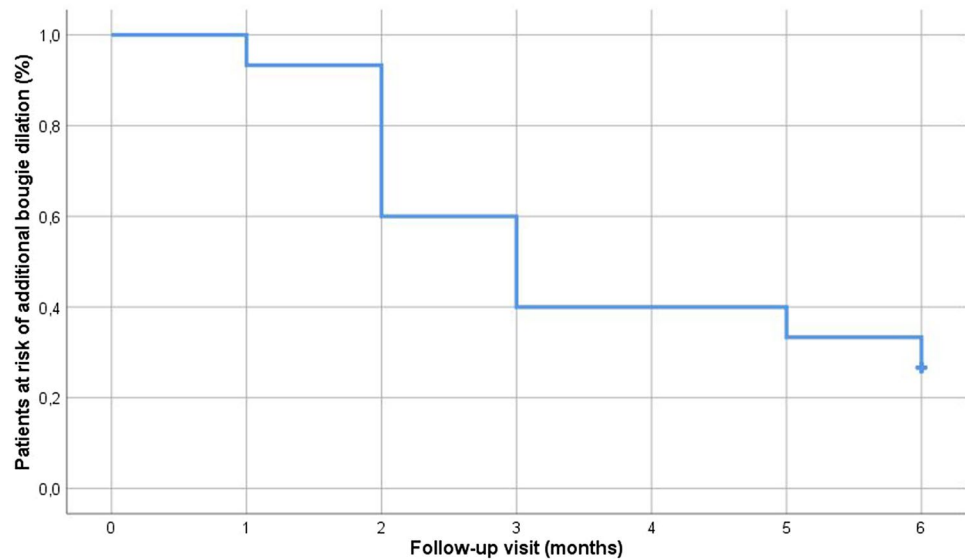
## Discussion

In this pilot study we demonstrated that intensive endoscopic therapy for untreated cervical anastomotic strictures after esophagectomy was technically feasible, safe, well tolerated and effective in resolving dysphagia rapidly. Using a combination of in- and excision, intralesional steroid injection and bougie dilation a luminal diameter of 18 mm was safely achieved in two endoscopic procedures scheduled within a time frame of approximately 1 week.

Achieving a luminal diameter of 18 mm in two endoscopic procedures may reduce patient's burden and save time on endoscopy programs. With the conventional method of no more than 3 mm dilation per endoscopic procedure, the reported median number of procedures needed to achieve a satisfactory luminal diameter is four [1, 8]. Intensive endoscopic therapy may therefore save two endoscopic dilation procedures. But even more importantly, it may relieve dysphagia much sooner than conventional endoscopic dilation, as in our pilot study all patients were able to tolerate solid foods at time of the second study procedure, which was scheduled approximately 1 week (median 8 days) after the first procedure. The general health score also clearly improved in the first 3 months, with a statistically significant improvement after 1 to 3 months, which might be related to relief of dysphagia.

No major adverse events had occurred related to the investigational treatment, particularly no perforations. The adverse events that we experienced were all attributable to intralesional steroid injection, i.e. candida esophagitis in two patients and superficial ischemia of the mucosa in a third patient. There are contradictory data on the effect of adding intralesional steroid injection to endoscopic dilation of anastomotic strictures, so one might question whether steroid injections have contributed to the effectiveness of the intensive endoscopic therapy. In a Dutch study there was no significant difference in the number of dilations needed during follow-up between intralesional steroid and sham injections [5]. However, Hanaoka et al. did observe a lower median number of dilations needed to resolve the stricture as well as a higher percentage of symptom-free patients after 6 months when using steroid injections compared to saline injections [6]. Although the superficial ischemia of the gastric conduit of the patient in our study did not result in a significant clinical problem, this was a remarkable observation. Ischemia of a gastric conduit after local steroid injection has not been described previously.

The need for additional endoscopic dilation in our pilot study (73% of patients) was comparable to the recurrent

**Fig. 2** Need for additional endoscopic bougie dilation

dysphagia rates of 50% up to 84% reported in the literature after endoscopic bougie or balloon dilation of anastomotic esophagogastric strictures [3, 5, 6, 8, 9]. So it seems that the risk of stricture recurrence after intensive endoscopic therapy still remains high.

The main limitations of this pilot study were the non-comparative design and small sample size of 15 patients.

In conclusion, in this pilot study intensive endoscopic therapy for untreated cervical anastomotic esophagogastric strictures was technically feasible and effective in resolving dysphagia already after the initial endoscopic procedure. No major adverse events related to the investigational treatment were observed. Future randomized studies should determine whether intensive endoscopic therapy reduces the number of dilation procedures in comparison with conventional endoscopic dilation.

**Funding** None.

## Declarations

**Disclosures** Emo E. van Halsema, Jacques J.G.H.M. Bergman, Johanna W. van Sandick, Annemieke Cats, Alexander A.F.A. Veenhof and Jolanda M. van Dieren have no conflicts of interest or financial ties to disclose. Prof. Mark I. van Berge Henegouwen declares grants from Stryker and consultancy for Johnson and Johnson, Alesi Surgical, Mylan, BBraun and Medtronic. All fees and grants paid to institution. Prof. Jeanin E. van Hoofst has received research support from Cook Medical and acted as consultant for Cook Medical, Boston Scientific, Olympus, Medtronics and Abbvie.

## References

- van Workum F, van der Maas J, van den Wildenberg FJ, Polat F, Kouwenhoven EA, van Det MJ, Nieuwenhuijzen GA, Luyer MD, Rosman C (2017) Improved functional results after minimally invasive esophagectomy: intrathoracic versus cervical anastomosis. *Ann Thorac Surg* 103(1):267–273. <https://doi.org/10.1016/j.athoracsur.2016.07.010>
- Huang Q, Zhong J, Yang T, Li J, Luo K, Zheng Y, Yang H, Fu J (2015) Impacts of anastomotic complications on the health-related quality of life after esophagectomy. *J Surg Oncol* 111(4):365–370. <https://doi.org/10.1002/jso.23837>
- van Halsema EE (2018) Endoscopic treatment of stenoses and leaks in the gastrointestinal tract: the role of self-expandable metal stents. Part I: benign esophageal strictures and leaks. PhD thesis, Digital Academic Repository of the University of Amsterdam (UvA-DARE). <https://dare.uva.nl/>
- Hordijk ML, van Hoofst JE, Hansen BE, Fockens P, Kuipers EJ (2009) A randomized comparison of electrocautery incision with Savary bougienage for relief of anastomotic gastroesophageal strictures. *Gastrointest Endosc* 70(5):849–855. <https://doi.org/10.1016/j.gie.2009.02.023>
- Hirdes MM, van Hoofst JE, Koornstra JJ, Timmer R, Leenders M, Weersma RK, Weusten BL, van Hillegersberg R, van Berge Henegouwen MI, Plukker JT, Wiezer R, Bergman JG, Vleggaar FP, Fockens P, Siersema PD (2013) Endoscopic corticosteroid injections do not reduce dysphagia after endoscopic dilation therapy in patients with benign esophagogastric anastomotic strictures. *Clin Gastroenterol Hepatol* <https://doi.org/10.1016/j.cgh.2013.01.016>
- Hanaoka N, Ishihara R, Motoori M, Takeuchi Y, Uedo N, Matsuura N, Hayashi Y, Yamada T, Yamashina T, Higashino K, Akasaka T, Yano M, Ito Y, Miyata H, Sugimura K, Hamada K, Yamasaki Y, Kanesaka T, Aoi K, Ito T, Iishi H (2018) Endoscopic balloon

dilation followed by intralesional steroid injection for anastomotic strictures after esophagectomy: a randomized controlled trial. *Am J Gastroenterol* 113(10):1468–1474. <https://doi.org/10.1038/s41395-018-0253-y>

7. Ogilvie AL, Dronfield MW, Ferguson R, Atkinson M (1982) Palliative intubation of oesophagogastric neoplasms at fiberoptic endoscopy. *Gut* 23(12):1060–1067
8. van Halsema EE, Noordzij IC, van Berge Henegouwen MI, Fockens P, Bergman JJ, van Hooft JE (2017) Endoscopic dilation of benign esophageal anastomotic strictures over 16 mm has a longer lasting effect. *Surg Endosc* 31(4):1871–1881. <https://doi.org/10.1007/s00464-016-5187-0>
9. Park JY, Song HY, Kim JH, Park JH, Na HK, Kim YH, Park SI (2012) Benign anastomotic strictures after esophagectomy:

long-term effectiveness of balloon dilation and factors affecting recurrence in 155 patients. *AJR* 198(5):1208–1213. <https://doi.org/10.2214/AJR.11.7608>

**Publisher's Note** Springer Nature remains neutral with regard to jurisdictional claims in published maps and institutional affiliations.

Springer Nature or its licensor (e.g. a society or other partner) holds exclusive rights to this article under a publishing agreement with the author(s) or other rightsholder(s); author self-archiving of the accepted manuscript version of this article is solely governed by the terms of such publishing agreement and applicable law.