



Universiteit
Leiden
The Netherlands

Acute liver injury and acute liver failure following bariatric surgery

Golen, R.F. van; Waard, N.E. de; Moolenaar, L.R.; Inderson, A.; Crobach, S.; Langers, A.M.J.; ... ; Tushuizen, M.E.

Citation

Golen, R. F. van, Waard, N. E. de, Moolenaar, L. R., Inderson, A., Crobach, S., Langers, A. M. J., ... Tushuizen, M. E. (2022). Acute liver injury and acute liver failure following bariatric surgery. *Case Reports In Gastroenterology*, 16(1), 240-246.
doi:10.1159/000523964

Version: Publisher's Version

License: [Creative Commons CC BY-NC 4.0 license](#)

Downloaded from: <https://hdl.handle.net/1887/3515267>

Note: To cite this publication please use the final published version (if applicable).

Case Series

Acute Liver Injury and Acute Liver Failure following Bariatric Surgery

Rowan F. van Golen^a Nadine E. de Waard^a Laura R. Moolenaar^a
Akin Inderson^a Stijn Crobach^b Alexandra M.J. Langers^a Bart van Hoek^a
Maarten E. Tushuizen^a

^aDepartment of Gastroenterology and Hepatology, Leiden University Medical Center, Leiden, The Netherlands; ^bDepartment of Pathology, Leiden University Medical Center, Leiden, The Netherlands

Keywords

Liver injury · Gastric bypass · Liver transplantation · Steatohepatitis · Protein malnutrition

Abstract

Bariatric surgery is the most effective treatment for obesity and improves several manifestations of the metabolic syndrome, including nonalcoholic fatty liver disease. Strict nutritional counseling after bariatric surgery is a key in realizing these outcomes. When postoperative nutrient intake or nutrient uptake is compromised, bariatric surgery can also lead to severe hepatic complications. Here, we describe 3 cases of acute liver injury and acute liver failure caused by bariatric surgery, all with different management strategies and outcomes.

© 2022 The Author(s).

Published by S. Karger AG, Basel

Introduction

Bariatric surgery is the most effective modality for reducing obesity-related comorbidities [1–3]. The goal of bariatric surgery is to maximize weight loss while retaining nutritional health, by preventing postoperative malnutrition and loss of lean body mass. Bariatric procedures are categorized as either restrictive (limiting stomach capacity), malabsorptive (bypassing a portion of the small intestines), or a combination of both. Weight loss after bariatric surgery generally has a beneficial effect on the hepatic complications of obesity, with improvement of steatosis, inflammation, and fibrosis [3]. However, a combination of malnutrition, malabsorption, and a compromised intestinal barrier function after surgery occasionally

also results in the deterioration of liver function [4, 5]. Acute liver failure (ALF) is a rare but life-threatening complication of bariatric surgery. We present three cases of severe hepatic dysfunction after bariatric surgery, all with different management strategies and outcomes.

Case Series

Case 1

A 37-year-old female was referred to our liver transplantation ward because of progressive jaundice. Seven months prior, she underwent a laparoscopic one-anastomosis gastric bypass for morbid obesity with a body mass index (BMI) of 45.5 kg/m² and multiple obesity-related comorbidities, including type-2 diabetes mellitus, diabetic nephropathy, and hypertension. The one-anastomosis gastric bypass was performed in the standard fashion with a biliopancreatic limb of 180 cm. Postoperative compliance to nutritional supplements was subpar. Within 6 months, she experienced a total weight loss of 45 kg, corresponding to a reduction in BMI to 29 kg/m². During follow-up, liver biochemistry and liver function tests initially remained normal. Two weeks prior to admission, she noticed progressive jaundice accompanied by fatigue and postprandial pain, followed by diarrhea. There was no history of alcohol or drug use, and she did not use of over-the-counter medication or herbal supplements. Clinical examination showed jaundice without signs of chronic liver disease or hepatic encephalopathy. Laboratory results showed acute hepatitis with coagulopathy (Table 1). Serology tests for infectious (e.g., viral) and noninfectious causes of hepatitis and stool examination were negative. Serum acetaminophen concentration was <0.3 mg/L. Abdominal computed tomography (CT) showed periportal edema and mild ascites, without signs of chronic liver disease. Upon referral, a percutaneous liver biopsy was performed, and total parenteral nutrition (TPN) was started, based on the hypothesis that severe acute liver injury (ALI) might be caused by extensive protein malnutrition and a consequent amino acid shortage [4]. Autoimmune hepatitis was initially also considered (IgG 15.4 g/L, anti-smooth muscle antibody positive at 1:40), and treatment with prednisone was initiated with a dose of 40 mg daily. Liver biopsy showed periportal and lobular hepatitis with prominent hepatocyte ballooning with Mallory-Denk bodies, bilirubinostasis, and no steatosis (<5%), in a panacinar pattern (Fig. 1). Since the liver biopsy was not compatible with autoimmune hepatitis, prednisone treatment was discontinued. After 2 weeks of TPN, liver biochemistry normalized without developing hepatic encephalopathy. She was referred to her bariatric surgeon for a redo procedure by lengthening the common loop. Currently, several years after revision surgery, liver function tests remain normal.

Case 2

A 49-year-old female was referred to our liver transplantation ward because of progressive jaundice. Seven months prior, she underwent a Roux-en-Y gastric bypass for morbid obesity with a BMI of 62.1 kg/m². Her past medical history showed hypothyroidism for which she was on treatment. Thyroid function was well regulated. Surgery was performed using a standard laparoscopic Roux-en-Y gastric bypass technique, creating a biliopancreatic limb of 150 cm and an alimentary limb of 75 cm. After surgery, she achieved a total weight loss of 40 kg, resulting in a BMI of 47.2 kg/m². During follow-up, liver biochemistry and function tests initially remained normal. However, adherence to nutritional supplements was subpar. Clinical examination revealed jaundice without signs of chronic liver disease or hepatic encephalopathy. Laboratory results revealed acute hepatitis with coagulopathy (Table 1). Serum markers for common infectious (e.g., viral) and noninfectious causes of hepatitis and stool examination were negative. Serum acetaminophen levels were <0.3 mg/L. Abdominal

Table 1. Evolution of liver function tests

Case 1	Unit	Reference range	D0	D2	D3	D7	D14	D23	D28	D39	D48	D74
AST	U/L	<31	723	778	629	143	150	116	71	NA	40	30
ALT	U/L	<34	428	526	393	187	109	90	57	NA	32	26
Total bilirubin	μmol/L	<17	247	325	270	238	143	73	42	NA	16	9
Albumin	g/L	34–38	24	26	20	25	27	36	27	NA	30	40
INR	Ratio	0.8–7.0	1.9	1.6	1.3	1.0	0.9	NA	NA	NA	NA	1.0
Case 2	Unit	Reference range	D0	D2	D3	D4	D6	D7	D10	D40		D102
			<i>Admission</i>	<i>Transfer</i>	<i>Start TPN</i>			<i>HU-list</i>	<i>Tx</i>	<i>Tx + 30D</i>		<i>Tx + 92D</i>
AST	U/L	<31	1,539	1,394	1,294	636	335	220	116	27		106
ALT	U/L	<34	1,168	1,014	997	733	528	429	220	241		375
Total bilirubin	μmol/L	<17	178	265	260	265	307	320	369	50		16
Albumin	g/L	34–38	32	28	26	24	19	20	18	28		40
INR	Ratio	0.8–7.0	2.6	3.1	2.9	3.2	4.0	4.1	3.7	1.1		1.0
Case 3	Unit	Reference range	D0	D1	D2	D5	D7	D13	D19			D27
			<i>Admission</i>	<i>Transfer</i>	<i>Start TPN</i>							
AST	U/L	<31	161	190	185	238	232	120	121			100
ALT	U/L	<34	30	36	34	38	37	30	36			32
Total bilirubin	μmol/L	<17	93	127	129	160	237	183	184			143
Albumin	g/L	34–38	NA	26	26	30	35	29	31			26
INR	Ratio	0.8–7.0	1.7	1.7	1.8	1.7	1.4	1.4	1.4			1.4

AST, aspartate transaminase; ALT, alanine transaminase; INR, international normalized ratio; D, day; TPN, total parenteral nutrition; HU-list, high-urgency list; Tx, transplantation; NA, not available.

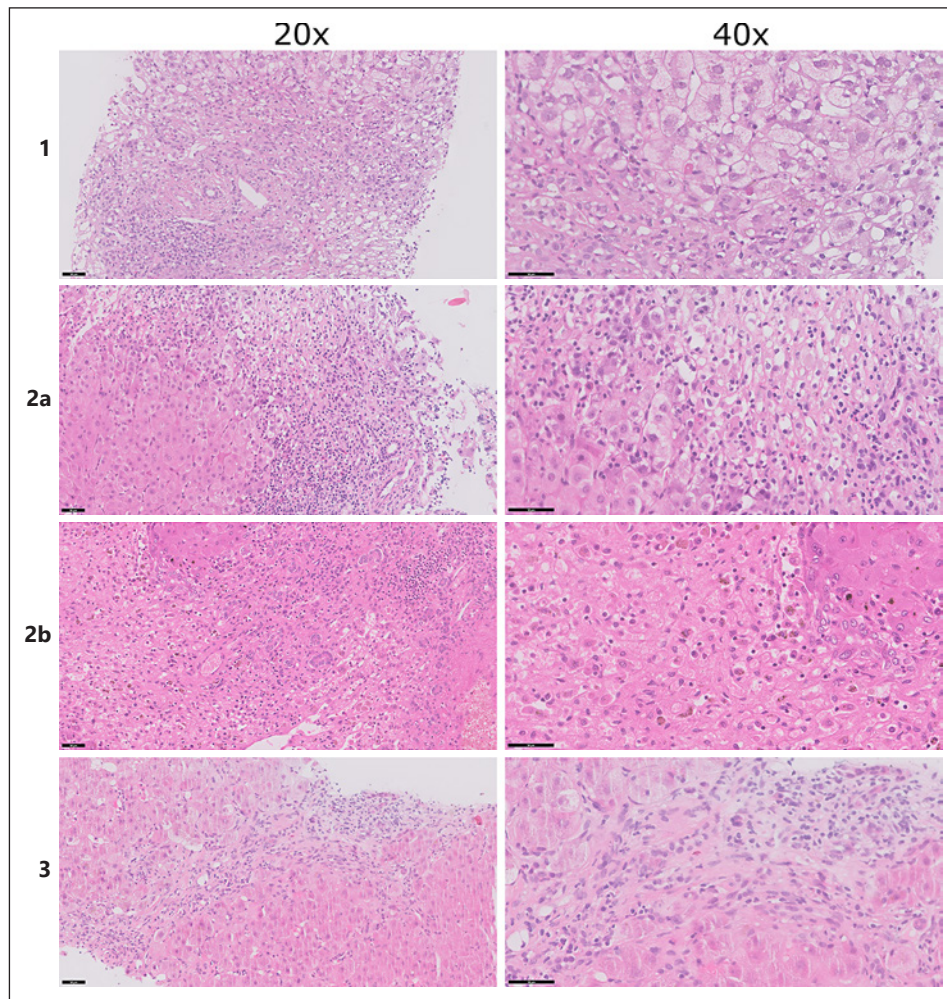


Fig. 1. Histological images. Case 1 (top row): periportal and lobular inflammation with prominent hepatocyte ballooning and Mallory-Denk bodies (HE staining, left column $\times 20$, right column $\times 40$). Case 2A (second row): severe acute hepatitis with extensive collapse and confluent hepatocellular necrosis (HE staining, left column $\times 20$, right column $\times 40$). Case 2B (third row): necrotic liver parenchyma with extensive inflammation without destruction of the bile ducts or blood vessels (HE staining, left column $\times 20$, right column $\times 40$). Case 3 (bottom row): periportal hepatitis with septating fibrosis (HE staining, left column $\times 20$, right column $\times 40$).

CT showed a normal liver with patent hepatic vasculature and no intrahepatic or extrahepatic biliary dilatation. Percutaneous liver biopsy revealed severe acute hepatitis with extensive collapse, causing a fibrotic morphology and confluent hepatocellular necrosis. The liver parenchyma showed a nodular aspect and prominent ductular reaction, without ballooning of hepatocytes or Mallory-Denk bodies and no steatosis ($<2\%$, Fig. 1). As in the first case, TPN was promptly started. However, she developed hepatic encephalopathy and was listed for high-urgency liver transplantation within 5 days after referral. Three days after listing, she underwent a liver transplantation. The postoperative course was uncomplicated, and she was discharged after 5 weeks following satisfactory clinical recovery. Histopathological examination of the explanted liver revealed a similar morphology as the previous liver biopsy, with increased bilirubinostasis and steatosis ($<10\%$, Fig. 1). She is now under strict nutritional surveillance with additional supplements and has not undergone revision surgery yet. Currently, several years after liver transplantation, the liver function tests remain normal.

Case 3

A 59-year-old female was referred from a regional hospital to our ICU because of ALF. Two years earlier, she underwent a sleeve gastrectomy for morbid obesity with a BMI of 70.1 kg/m². Weight regain prompted revision surgery with conversion to a single anastomosis duodeno-ileal bypass with a sleeve gastrectomy, with a biliopancreatic limb of 170 cm and an alimentary limb of 80 cm. Her medical history further included heterozygosity for hemochromatosis without cirrhosis, for which phlebotomies were performed. There was no history of an alcohol use disorder, and she did not use any over-the-counter medication or herbal supplements. Three months after revision surgery, she experienced severe dumping syndrome, leading to insufficient nutriment intake for which enteral tube feeding was initiated. Because of frequent dislodgement of the nasal tube, enteral feeding was discontinued. Six months after revision surgery, she was admitted to a regional hospital with refractory hypotension and required inotropic support. Clinical examination revealed jaundice and mild hepatic encephalopathy. Laboratory results showed acute hepatitis, with coagulopathy, and acute kidney injury (Table 1). Signs of preexisting liver disease were absent. Serology tests for common infectious (e.g., viral) and noninfectious causes of hepatitis were negative. Abdominal CT showed a normal liver and biliary system, without radiological signs of cirrhosis or portal hypertension. No infectious substrate for the hypotension was identified. Percutaneous liver biopsy was performed and revealed periportal hepatitis with bilirubinostasis and mild steatosis (<10%), without signs of ballooning. The liver parenchyma showed a nodular aspect with septating fibrosis and a prominent ductular reaction (Fig. 1). As in the first 2 cases, treatment with TPN was started directly after liver biopsy. Over the next couple of weeks, there was a gradual clinical recovery. She has been referred to her bariatric surgeon for a redo procedure by lengthening the common loop.

Discussion/Conclusion

ALI and ALF are uncommon but life-threatening complications of bariatric surgery [4]. In contrast to other case reports, only 1 out of 3 patients required liver transplantation in this case series. Based on the histological images showing an emaciated steatohepatitis, or so called “depleted nonalcoholic steatohepatitis (depleted NASH),” we decided to start treatment with TPN rich in amino acids directly after referral in all 3 cases, in order to “recharge” the hepatocytes. We assume that malabsorption, combined with nonadherence to nutritional supplements, results in protein-energy malnutrition and exhaustion of intrahepatic amino acid stores [4]. The lack of available resources in our cases, on average, emerged 8 months after bariatric surgery, which is relatively early as compared to the available literature [5]. Several cellular alterations seem to take place in protein-starved livers [6, 7]. Our cases represent different stages of the hepatocyte response to a lack of resources, ranging from an acute phase with prominent necrosis (Fig. 1) to a more chronic phase with fibrotic changes of the liver parenchyma (Fig. 1). The first case showed a (N)ASH like morphology as has been described in similar cases [7].

A major risk factor for the development of malabsorption and liver dysfunction after bariatric surgery is a (relatively) short common loop [8], causing malnutrition in general and amino acid deficiencies in particular [9]. Furthermore, small-intestinal bacterial overgrowth (SIBO) may contribute to malabsorption and thereby the development of ALF. SIBO is a common complication after either a malabsorptive or combined procedure, leading to loss of nutrients due to intestinal barrier alterations and increased intestinal permeability [10]. Bacterial translocation into the portal venous system may induce hepatocellular damage,

followed by liver dysfunction [4]. Preoperative deficiencies and reduced dietary intake may also contribute to enhanced depletion of liver energy reserves, in addition to inadequate supplement intake. Of note, mental illness is prevalent after bariatric surgery and may negatively impact adherence to nutritional support, increasing the risk for hepatic dysfunction and highlighting the importance of dedicated guidance and counseling after bariatric surgery [11, 12].

Our second case developed ALF within 2 days after referral, with rapid clinical deterioration. Unfortunately, there is no marker or clinical scoring system available to predict whether a patient will improve with TPN or will develop ALF, necessitating a liver transplant to prevent a fatal outcome. It is important to realize that there is a delicate balance in these patients, requiring intensive clinical and biochemical monitoring in a liver transplant center. To prevent recurrence of ALI following discharge, we referred our patients for a redo procedure with lengthening the common loop. Lengthening the common loop decreases the risk of malnutrition, malabsorption, and amino acid deficiency and also is a curative treatment for SIBO [10].

In conclusion, this case series illustrates the importance of recognizing the onset of ALI and ALF after bariatric surgery. It emphasizes the crucial role of adequate and timely (parenteral) nutrition in these patients, which may avoid liver transplantation in case of this life-threatening complication.

Statement of Ethics

Ethics approval by an Institutional Review Board was not required for this retrospective case series in accordance with local guidelines. Written informed consent was obtained from the patients for publication of this case report and any accompanying images.

Conflict of Interest Statement

The authors have no conflicts of interest to declare.

Funding Sources

The authors have no funding sources to disclose.

Author Contributions

Rowan F. van Golen, Nadine E. de Waard, Laura R. Moolenaar, Akin Inderson, Stijn Crobach, Alexandra M.J. Langers, Bart van Hoek, and Maarten E. Tushuizen contributed to data collection, data analysis, data interpretation, and critical revision of the manuscript. Rowan F. van Golen, Nadine E. de Waard, and Maarten E. Tushuizen.

Data Availability Statement

All data generated or analyzed during this study are included in this article. Further inquiries can be directed to the corresponding author.

References

- 1 Carlsson LMS, Sjöholm K, Jacobson P, Andersson-Assarsson JC, Svensson P-A, Taube M, et al. Life expectancy after bariatric surgery in the Swedish obese subjects study. *N Engl J Med*. 2020 Oct 15;383(16):1535–43.
- 2 Schauer PR, Bhatt DL, Kirwan JP, Wolski K, Aminian A, Brethauer SA, et al. Bariatric surgery versus intensive medical therapy for diabetes: 5-year outcomes. *N Engl J Med*. 2017 Feb 16;376(7):641–51.
- 3 Aminian A, Al-Kurd A, Wilson R, Bena J, Fayazzadeh H, Singh T, et al. Association of bariatric surgery with major adverse liver and cardiovascular outcomes in patients with biopsy-proven nonalcoholic steatohepatitis. *JAMA*. 2021 Nov 23;326(20):2031–42.
- 4 Moolenaar LR, de Waard NE, Heger M, de Haan LR, Slootmaekers CPJ, Nijboer WN, et al. Liver injury and acute liver failure after bariatric surgery: an overview of potential injury mechanisms. *J Clin Gastroenterol*. 2022 Apr 1;56(4):311–23.
- 5 Addeo P, Cesaretti M, Anty R, Iannelli A. Liver transplantation for bariatric surgery-related liver failure: a systematic review of a rare condition. *Surg Obes Relat Dis*. 2019 Aug;15(8):1394–401.
- 6 Corcos O, Cazals-Hatem D, Durand F, Kapel N, Guinhut M, Stefanescu C, et al. Intestinal failure after bariatric surgery. *Lancet*. 2013;382(9893):742.
- 7 Tsai JH, Ferrell LD, Tan V, Yeh MM, Sarkar M, Gill RM. Aggressive non-alcoholic steatohepatitis following rapid weight loss and/or malnutrition. *Mod Pathol*. 2017;30(6):834–42.
- 8 Mahawar KK. Liver dysfunction with both Roux-en-Y and one-anastomosis gastric bypass is almost exclusively seen with longer than standard limb lengths. *Obes Surg*. 2018;28(2):548–9.
- 9 Nicoletti CF, Morandi Junqueira-Franco MV, dos Santos JE, Marchini JS, Salgado W, Nonino CB. Protein and amino acid status before and after bariatric surgery: a 12-month follow-up study. *Surg Obes Relat Dis*. 2013 Dec;9(6):1008–12.
- 10 Alcaraz F, Frey S, Iannelli A. Surgical management of small intestinal bacterial overgrowth after Roux-en-Y gastric bypass. *Obes Surg*. 2020 Nov;30(11):4677–8.
- 11 Mingrone G, Bornstein S, Le Roux CW. Optimisation of follow-up after metabolic surgery. *Lancet Diabetes Endocrinol*. 2018 Jun;6(6):487–99.
- 12 Lammers WJ, van Tilburg AJ, Apers JA, Wiebolt J. Liver failure caused by prolonged state of malnutrition following bariatric surgery. *World J Hepatol*. 2018;10(3):396–9.