



Universiteit  
Leiden  
The Netherlands

## Improving the management of colorectal neoplasms in clinical practice

Leicher, L.W.

### Citation

Leicher, L. W. (2023, February 2). *Improving the management of colorectal neoplasms in clinical practice*. Retrieved from <https://hdl.handle.net/1887/3514669>

Version: Publisher's Version

License: [Licence agreement concerning inclusion of doctoral thesis in the Institutional Repository of the University of Leiden](#)

Downloaded from: <https://hdl.handle.net/1887/3514669>

**Note:** To cite this publication please use the final published version (if applicable).



CHAPTER

# 6

## Limited Endoscopic Assisted Wedge Resection for Excision of Colon Polyps

---

Laura W. Leicher M.D., Wouter H. de Vos tot Nederveen Cappel M.D. PhD,  
Henderik L. van Westreenen M.D. PhD.

*Diseases of the Colon & Rectum, 2016.*

## **ABSTRACT**

### **BACKGROUND**

Combined endoscopic laparoscopic surgical (CELS) removal is used for polyps in the colon that are not suitable for endoscopic removal due to size, location or scarring. However, the placement of a linear stapler can be challenging. Up to now, a wedge resection is mostly documented in the cecum or ascending colon.

### **OBJECTIVE**

We would like to report on our experience with limited endoscopy assisted wedge resections (LEAWR) in the entire colon.

### **METHODS**

A retrospective single-center study was performed. Eight patients were included between March 2015 and April 2016. The laparoscopic surgical technique consisted of placing a suture under endoscopic view through the base of the polyp into the lumen. Subsequently, traction was given on the suture to enable stapling of a wedge of the colon.

### **MAIN OUTCOME MEASURES**

Medical data were collected (i.e., indication for referral for surgery, location and size of the polyp, duration of surgical procedure, length of hospital stay and peri- and postoperative complications). Operative time was defined as total time of general anesthesia.

### **RESULTS**

Eight patients, with a mean age of 74.5 years (range 68-82), were treated. Main indications for laparoscopic resection were the size and difficult location of the polyp. There were no complications. Mean operative time was 132 minutes. Five patients were discharged the day after surgery, the other 3 patients were admitted a total of 2 days.

### **CONCLUSION**

Our study found that LEAWR is a feasible and easy technique for the removal of colon polyps and residual adenomatous tissue in scars not accessible for endoscopic removal. Due to traction given on the suture through the base of the polyp, the linear stapler is easily used for wedge resections of polyps even for those that are not in favorable positions.

## INTRODUCTION

The new combined endoscopic laparoscopic surgical (CELS) approach for the removal of difficult colon polyps, the so called CELS-full thickness excision (CELS-FT), was recently described by Lin et al.<sup>1</sup> They describe how to create a defect in the seromuscular layer circumferentially over the location by laparoscopy where indigo carmine solution was injected previously. Then, the dissected area is invaginated into the bowel lumen with a laparoscopic instrument. A snare is introduced and looped around the polyp. Before cutting through the polyp, the peritoneal surface is examined and there is laparoscopic closure to repair the colonic defect.<sup>1</sup> Three patients are described that underwent CELS-FT for difficult benign polyps. The average surgery time was 179 minutes. There was minimal blood loss and there were no perioperative complications. The authors describe a (limited) wedge resections by using a linear stapler without anastomosis is only feasible if the polyps are in a favorable position, such as in the cecum.<sup>1,2</sup> We would like to report on our experience with limited endoscopy assisted wedge resections (LEAWR) in 8 patients in Isala, Zwolle, The Netherlands.

## MATERIAL AND METHODS

### *Study design*

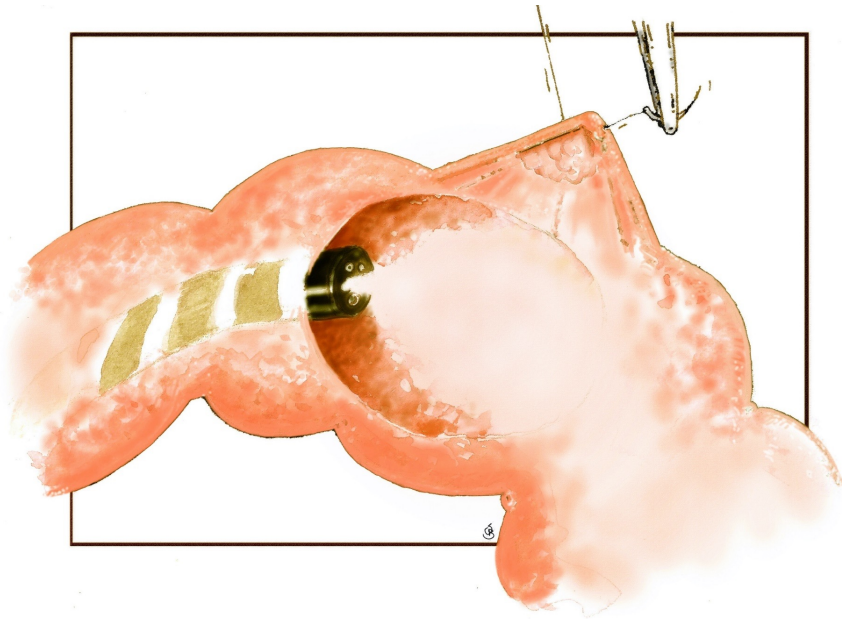
A retrospective single-center study was performed in Isala Hospital in Zwolle, The Netherlands between March 2015 and April 2016. We included patients with polyps that were eligible for a combined endoscopic laparoscopic surgical removal. Patients were mainly referred from our own department of Gastroenterology. There were various reasons for referral for surgical resection; endoscopic unresectability, size, localization or incomplete/failed resection. One surgeon, specialized in minimal invasive colorectal surgery, performed all procedures. We collected data on age, gender, localization of the polyp, pre- and postoperative pathology findings, indication for surgical resection, duration of surgical procedure, length of hospital stay and peri- and postoperative complications. We defined complications as excessive blood loss during surgical procedure, postoperative blood loss, perforation and perioperative infections. Operative time was defined as total time of general anesthesia.

### *Surgical technique*

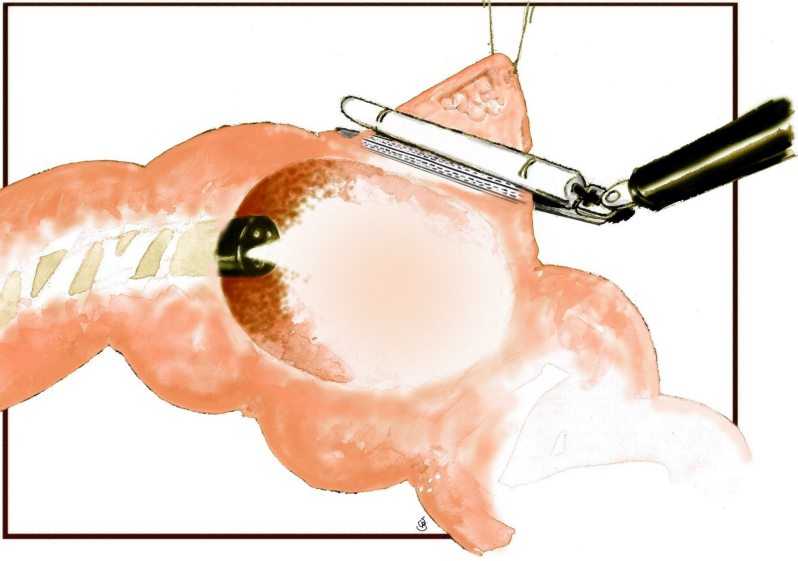
All patients underwent split-dose bowel preparation. Patients were placed under general anesthesia in French position. The surgeon started with a diagnostic laparoscopy with three trocars. At first, the spot in the colon was identified and the concerning part of the colon was mobilized to ensure the LEAWR. Secondly, the



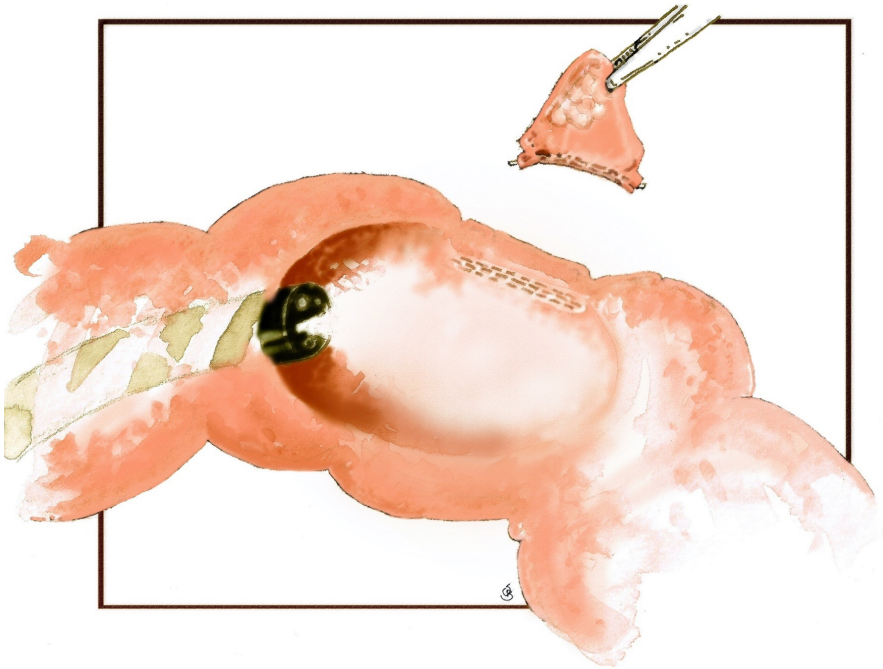
colonoscopy was performed by the gastroenterologist. A suture was placed laparoscopically with intraluminal endoscopic visualization through the base of the polyp. (Figure 1) Traction was given on the suture to enable positioning of the linear stapler (Endo-GIA tristaple, Covidien).(Figure 2) Before stapling off the polyp the patency of the lumen (i.e., the lumen of the colon or in case of a cecal lesion the lumen of the ileum) as well a total inclusion of the polyp tissue was checked endoscopically by the gastroenterologist. (Figure 3) The resected specimen was as removed in an endobag through the 12mm trocar. The surgeon as well as the endoscopist checked the colon for signs of bleeding or perforation before ending the procedure.



**Figure 1.**  
**Placing a suture through the base of the polyp into bowel lumen**  
**under endoscopic view**



**Figure 2.**  
Traction given on the suture before stapling off and to ensure positioning of the linear stapler



**Figure 3.**  
Before stapling off the polyp the patency of the lumen is checked endoscopically

## RESULTS

Eight patients with endoscopically unresectable colon polyps were treated. Seven patients were referred from our own department of Gastroenterology one patient was referred from another hospital.

Seven patients were male and the mean age of all patients was 74.5 years. (Table 1) The main indications for laparoscopic resection were the size and difficult location of the polyp. In three patients the indication was suspected residual adenomatous tissue after poliepectomy. (Table 2, patient 1, 4 and 6) There were no complications in our patients. The mean operative time was 132 minutes. In two patients the operative time was longer. In patient number 2 (Table 2) this is explained by the fact that we started with a transanal endoscopic microsurgery (TEM) procedure, which failed. In the other patient (patient 1, Table 2), two wedge

**Table 1.**  
**Demographics and mean operative time**

Parameter	n = 8
Age (years), median (range)	74.5 (68-82)
Sex	
Male	7 (87%)
Female	1 (13%)
ASA	
1	-
2	2 (25%)
3	2 (25%)
Operative time (min), median (range)	132 (110-170)

resections were performed. The perioperative blood loss was in negligible. Five patients were discharged the day after surgery, the other 3 patients left the hospital 2 days after surgery.(Table 2) In seven patients the margin of resection was clear of adenomatous tissue. In one patient (patient 1, Table 2) who underwent two wedge resections the margin of resection in one of the specimen was clear of adenomatous tissue. However, radicality of the other specimen was unclear due to the fact that the margin of this lesion (a sessile serrated adenoma with low graded dysplasia) was in the staples of the resection site that were removed before histological examination. Though we are convinced that this polyp is completely removed, we cannot prove radicality and we will plan this patient for surveillance endoscopy. One of eight patients underwent a follow up colonoscopy 6 months postoperatively, there was no stenosis of the colon.



**Table 2.****Details of cases undergoing endoscopic assisted laparoscopic full thickness excision**

	Age	M/F	ASA	Polyp location	Size mm	Preoperative pathology	Indication	Operative time, min	Final pathology	LOS d	Complications
1	68	M	2	transverse colon/ descending colon (2 polyps)	10/scar*	TA-HGD	difficult location/ SRATAP	165	SSA-LGD /scar tissue	1	none
2	82	M	3	sigmoid	10	AC	early carcinoma	170	pT1NxMx AC	2	none
3	76	M	3	transverse colon	28	TA-LGD	size and difficult location	126	TVA-LGD	2	none
4	78	F	2	cecum, valvula Bauhini	scar**	TA-HGD	non lifting and SRATAP	117	TVA-HGD	1	none
5	79	M	2	splenic flexure	20	TVA-HGD	en-bloc resection^^	119	TVA-HGD	1	none
6	69	M	2	hepatic flexure	scar^	TA-LGD	SRATAP	122	no polyp tissue	2	none
7	70	M	2	cecum	40	SSAP	size and difficult location	110	SSAP	1	none
8	74	M	2	cecum	43	SSAP	size and difficult location	124	TVA-LGD	1	none

Size of the polyp is based on the pathology report.

\* a 45mm LST was piecemeal removed, suspected irradicality

\*\* a 15mm sessile serrated polyp upon the valvula Bauhini was piecemeal removed, suspected irradicality

^ a 14mm tubular adenoma with low-grade dysplasia was removed, suspected irradicality

^^ endoscopic suspicion of an early carcinoma

**Abbreviations:**

AC = adenocarcinoma,

TVA = tubulovillous adenoma,

TA = tubular adenoma,

SSAP = sessile serrated adenoma/polyp,

HGD = high-grade dysplasia, LGD = low-grade dysplasia, SRATAP = suspected residual adenomatous tissue after poliepectomy,

LOS = length of stay

## DISCUSSION

We demonstrate limited EAWR is a feasible and safe procedure for polyps in the colon that are not suited for endoscopic removal due to size, place or scarring. Although patient numbers are low, so far we did not encounter any difficulties in placing the stapler. Due to traction given on the suture through the base of the polyp, the linear stapler is also easily used for wedge resections of polyps that are not in a favourable position. In the literature we did not find an earlier publication of using traction on a suture to perform a wedge resection. We performed a limited EAWR for polyps with sessile as well as (semi-) pedunculated morphology. Indication for limited EAWR of (semi-)pedunculated polyps was difficult location due to instability of the scoop.

Obviously, a limited EAWR is not suitable for the resection of malignant polyps, because radical lymph node dissection is not part of this technique.<sup>3</sup> In addition, leaving residual neoplasia could not be ruled out in one patient as described above. Patients with previous biopsies consistent with invasive cancer should be excluded from the limited endoscopic assisted wedge resection. However, we treated one patient (patient 2, table 2) for a polyp that was macroscopically suspect for cancer, because he refrained from treatment with an oncologic bowel resection. Histology in this patient showed a T1 carcinoma with 2.6mm submucosal invasion without angio-invasion or signs of perineural growth.

Even with laparoscopic assistance, endoscopic removal is not always technically possible or may not be effective in cases where a snare cannot be placed over the polyp because of size, location or scarring from previous biopsies. This may lead to piecemeal resection and subsequent inadequate histopathological assessment of the specimen as well as a higher risk of recurrence.<sup>1,4</sup> Endoscopic submucosal dissection (ESD) is a well-established technique that facilitates en bloc excision of large polyps. However, there are several disadvantages to ESD that limit its use in routine clinical practice, including the need for specialized equipment, procedure length and a long learning curve.<sup>5</sup>

Many patients now indicated for ESD can also easily be treated with limited EAWR. Caution is taken when polyps are situated in a sigmoid with multiple diverticula, in these patients endoscopic wedge resection might be challenging. A possible concern of a limited EAWR could be narrowing of the bowel. We prefer to place the stapler in a transverse direction, this is however not always possible. In our patients we did not have any complaints related to possible narrowing of the colon. In one patient, that underwent a limited wedge resection for an adenoma located in the hepatic flexure, follow up colonoscopy, showed no signs of stenoses.

Two patients had a limited wedge resection on the left side of the colon, they did not report any complaints which could be related to possible narrowing of the colon. In conclusion, limited EAWR is a safe technique with a relative short operative time. The technique seems feasible for colon polyps and residual adenomatous tissue in scars in practically all positions that are not accessible for endoscopic removal. If limited EAWR for any reason is not possible, CELS-FT as described by Lin et al. seems a good alternative.

#### **ACKNOWLEDGEMENTS**

The authors like to thank Sake Boersma for his drawings of the surgical technique.

## REFERENCES

1. Anthony T. Lin, et al, Dynamic Article: Full-Thickness Excision for Benign Colon Polyps Using Combined Endoscopic Laparoscopic Surgery, *Dis Colon Rectum* 2016; 59: 16–21
2. Jun Yan, et al. Treatment for right colon polyps not removable using standard colonoscopy: combined laparoscopic-colonoscopy approach. *Dis Colon Rectum*. 2011;54:753–758
3. Wilhelm D, von Delius S, Weber L, Meining A, Schneider A, Friess H, Schmid RM, Frimberger E, Feussner H, Combined laparoscopic–endoscopic resections of colorectal polyps: 10-year experience and follow-up, *Surgical Endoscopy* 2009; 23:688-693.
4. Ji Yeon Seo, et al. Novel risk stratification for recurrence after endoscopic resection of advanced colorectal adenoma. *Gastrointest Endosc*. 2015;81:655–664.
5. Taka Sakamoto, et al. Endoscopic submucosal dissection for colorectal neoplasms: a review. *World J Gastroenterol*. 2014;20:16153–16158..

