



Universiteit  
Leiden  
The Netherlands

## Spontaneous externalization of a ventriculoperitoneal shunt tip through the navel

Gadjradj, P.S.; Willemsz, L.; Spoor, J.K.

### Citation

Gadjradj, P. S., Willemsz, L., & Spoor, J. K. (2020). Spontaneous externalization of a ventriculoperitoneal shunt tip through the navel. *British Journal Of Neurosurgery*. doi:10.1080/02688697.2020.1716946

Version: Publisher's Version

License: [Creative Commons CC BY-NC-ND 4.0 license](https://creativecommons.org/licenses/by-nc-nd/4.0/)

Downloaded from: <https://hdl.handle.net/1887/3181485>

**Note:** To cite this publication please use the final published version (if applicable).

## Spontaneous externalization of a ventriculoperitoneal shunt tip through the navel

Pravesh S. Gadraj<sup>a</sup>, Laura Willemsz<sup>b</sup> and Jochem K. Spoor<sup>b</sup>

<sup>a</sup>Department of Neurosurgery, Leiden University Medical Center, Leiden, the Netherlands; <sup>b</sup>Department of Neurosurgery, Sophiàs Children Hospital, Erasmus MC: University Medical Center Rotterdam, Rotterdam, the Netherlands

### ABSTRACT

The authors describe spontaneous externalization of a ventriculo-peritoneal shunt through the navel.

### ARTICLE HISTORY

Received 9 October 2019  
Revised 31 December 2019  
Accepted 13 January 2020

### KEYWORDS

Ventriculoperitoneal shunt (VPS); complication; externalization

A 12-year old boy presented with spontaneous externalization of the ventriculoperitoneal shunt (VPS) through the navel. Two weeks before he noticed a pimple in the same area, but he had no accompanying complaints. The patient had a known arterio-venous fistula (AV) near the transverse sinus left for which the VPS was put in in China. Afterwards, he was adopted and moved to the Netherlands. Eight years prior he underwent shunt revision due to distal disconnection. The patient noted the shunt externalizing (Figure 1(A)). Ultrasound of the abdomen showed no masses or underlying abdominal wall pathology (Figure 1(B)) and X-ray showed that

the drain trajectory was intact (Figure 1(C)). After admission, the shunt was closed to test for shunt dependency. A day later, the cerebrospinal fluid showed growth of *Staphylococcus* and, therefore, it was removed. Afterwards, the patient showed no symptoms of meningitis and was discharged. Follow-up MRI at 6 months showed no further dilatation of the ventricles and no changes in the AV-fistula.

Spontaneous externalization of VPSs is rare. Reports exist of spontaneous or provoked migration of VPS through the umbilicus, mouth, vagina, ureter and penis, to the colon, the scrotum, the anus and extrusion through the spinal area<sup>1-5</sup>.

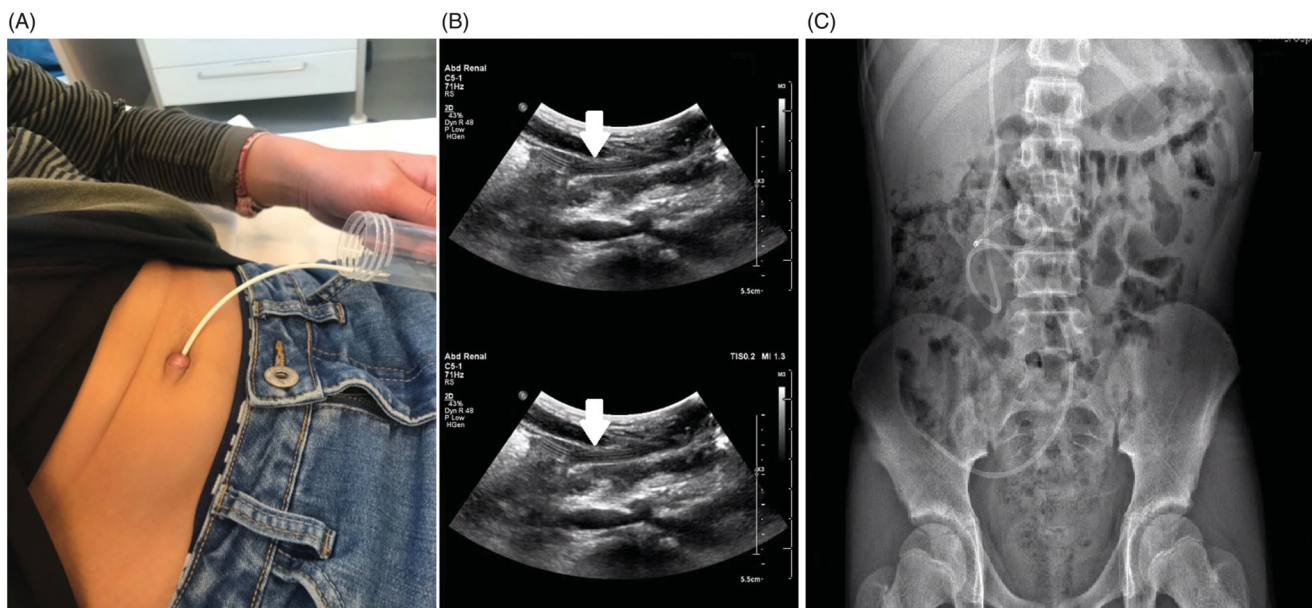


Figure 1. Extrusion of the distal part of the ventriculoperitoneal shunt through the navel. B Ultrasound imaging shows extrusion from the shunt, without abdominal wall pathology C X-ray shows an intact drain trajectory.

## Disclosure statement

No potential conflict of interest was reported by the authors.

## References

1. Berhouma M, Messerer M, Houissa S, Khaldi M. Transoral protrusion of a peritoneal catheter: a rare complication of ventriculoperitoneal shunt. *Pediatr Neurosurg* 2008;44:169–71.
2. Mutlu M, Kader S, Aslan Y, Yazar U, Imamoglu M. An acute complication of ventriculoperitoneal shunt with bladder perforation and extrusion through the urethra in a newborn: case report and review of the literature. *Pediatr Neurosurg* 2015;50:264–9.
3. Ezzat AAM, Soliman MAR, Hasanain AA, *et al.* Migration of the distal catheter of ventriculoperitoneal shunts in pediatric age group: case series. *World Neurosurg* 2018;119:e131–7.
4. Wani AA, Ramzan A, Wani MA. Protrusion of a peritoneal catheter through the umblicus: an unusual complication of a ventriculoperitoneal shunt. *Pediatr Surg Int* 2002;18:171–2.
5. Lotfinia I, Tubbs S, Mahdkhah A. Vaginal extrusion of a ventriculoperitoneal shunt: a case report and review of literature. *J Pediatr Adolesc Gynecol* 2017;30:e23–5.