



Universiteit
Leiden
The Netherlands

Selective fetal growth restriction in identical twins: from womb to adolescence

Groene, S.G.

Citation

Groene, S. G. (2023, January 11). *Selective fetal growth restriction in identical twins: from womb to adolescence*. Retrieved from <https://hdl.handle.net/1887/3511752>

Version: Publisher's Version

License: [Licence agreement concerning inclusion of doctoral thesis in the Institutional Repository of the University of Leiden](#)

Downloaded from: <https://hdl.handle.net/1887/3511752>

Note: To cite this publication please use the final published version (if applicable).

Part I

From unequal placental sharing to
a discordant intrauterine environment



Chapter 1

Placental characteristics in monochorionic twins with selective fetal growth restriction in relation to the umbilical artery Doppler classification.

Placenta. 2018 Nov;71:1-5.

Sophie G. Groene

Lisanne S.A. Tollenaar

Femke Slaghekke

Johanna M. Middeldorp

Monique C. Haak

Dick Oepkes

Enrico Lopriore

Abstract

Introduction: The objective of this study was to evaluate the placental characteristics of monochorionic twin pregnancies with selective fetal growth restriction (sFGR) classified according to the Gratacós classification based on umbilical artery Doppler measurements.

Methods: All consecutive placentas from monochorionic twin pregnancies with sFGR, (defined as a birth weight discordance > 25% and/or an estimated fetal weight in one twin <10th centile) examined at our center between May 2002 and February 2018 were included in the study. Each placenta was injected with colored dye to study the angioarchitecture. Primary outcomes were placental share discordance and diameter of the arterio-arterial anastomoses in relation to the umbilical artery Doppler types of sFGR (Gratacós classification).

Results: Of the 83 sFGR twins included, 27 were classified as Gratacós type I, 24 as type II and 32 as type III. The median gestational age at delivery was 34.3 weeks for type I, compared to 31.2 weeks and 31.6 weeks for type II and type III respectively. A trend towards a higher placental share discordance in type III sFGR was observed. The median arterio-arterial diameter was 1.7 mm (0.8-2.6) in type I, 1.7 mm (0.8-2.6) in type II and 2.8 (2.0-3.5) mm in type III ($p < 0.01$).

Conclusions: Type III sFGR placentas appear to be characterized by a larger diameter of the arterio-arterial anastomoses in type III and a larger placental share discordance compared to type I and II sFGR. The insights in the placental architecture of sFGR placentas may offer new views on the pathophysiology of the disease.

Funding: This research did not receive any specific grant from funding agencies in the public, commercial, or not-for-profit sectors.

Introduction

Monochorionic (MC) twin pregnancies are at increased risk of adverse perinatal outcome when compared to dichorionic twin pregnancies¹. This increased risk is mainly caused by the vascular anastomoses on the surface of the shared placenta, allowing intertwin blood transfusion between the two fetuses, which can lead to complications such as twin-twin transfusion syndrome (TTTS), twin anemia polycythemia sequence (TAPS) or selective fetal growth restriction (sFGR)^{2,3}. sFGR occurs in 10-15% of MC twin pregnancies and results from both intertwin blood flow and unequal placental sharing leading to severe growth restriction in the twin with the small placenta share.

In 2007, Gratacós et al proposed a classification system for sFGR based on the umbilical artery (UA) Doppler flow in the smaller twin⁴. Type I is characterized by positive UA Doppler flow and is considered to have a benign prognosis. Type II is defined as a persistently absent/reversed UA end-diastolic flow (A/REDF) and is associated with the highest perinatal mortality and morbidity. Lastly, type III is characterized by intermittent absent/reversed end-diastolic flow (iA/REDF) and has an atypical clinical evolution with an increased risk of unexpected fetal demise of the smaller twin and an increased risk of cerebral injury in the larger twin⁴⁻⁶.

Several studies previously described the placental angioarchitecture in MC twins with sFGR^{2,3,7,8}. However, no other studies, aside from Gratacós et al. in 2007, evaluated the association between placental characteristics and UA Doppler classification. The aim of the study is to evaluate the placental characteristics in MC twins with sFGR according to the Gratacós classification.

Methods

All placentas from MC pregnancies with a birth weight discordance > 25% and/or an estimated fetal weight in one twin < 10th centile consecutively examined at our specialized center between May 2002 and February 2018 were eligible for the study. We excluded MC pregnancies with co-existing TTTS or TAPS, cases where the UA Doppler classification was not recorded, cases with incomplete placental data (either due to placental damage or loss of the placenta) and cases in which placental measurements on the digital picture could not be performed. Cases with single or double intrauterine fetal demise (IUFD), defined as fetal death before 24 weeks of gestational age, were excluded when severe placental maceration made measurements impossible.

The following baseline characteristics were collected from our database: maternal age, gravidity, parity, sex, gestational age at diagnosis, gestational age at birth, mode of delivery, birth weight, birth weight discordance, intertwin hemoglobin (Hb) difference, perinatal survival and severe cerebral injury, defined as periventricular leukomalacia (PVL) ≥ grade 2, intraventricular hemorrhage (IVH) ≥ grade 3, ventricular dilatation, arterial or venous infarct or other severe cerebral injury. Birth weight discordance was calculated as follows: (birth weight larger twin – birth weight smaller twin)/birth weight larger twin x 100%. The Gratacós classification was established based on routine UA Doppler evaluations, with type I defined as a positive end-diastolic flow (pEDF), type II as A/REDF and type III as iA/REDF. iA/REDF was identified within the same acquisition of UA Doppler and checked within a short interval in the same exam. The cord was assessed at the insertion site of the placenta. In case this was not possible, a free loop close to the insertion of the placenta was assessed. When the classification changed over time, the most prevalent type was chosen with help of an ultrasound operator.

Each of the MC placentas was routinely injected with colored dye to examine the pattern of placental anastomoses. Specific colors correlated with specific vessels, allowing for careful observation of different types of anastomoses. The cords of the twins were marked differently at birth: one clamp for the firstborn and two clamps for the second-born twin. The fetal territories were demarcated by the margins of the twin-specific colored dyes and expressed by a percentage of the total placental surface. After the colored dye injection, the placentas were photographed and the images digitally saved for computer analysis. The placental measurements were

conducted retrospectively and unblinded by the primary investigator using Image J version 1.57.

We measured the diameter of each arterio-arterial (AA) anastomosis and veno-venous (VV) anastomosis and we recorded the proportion of cases with an AA anastomosis > 2 mm in diameter. This specific cut-off was solely chosen in analogy with Gratacós et al. to compare our results⁴. The total AA or VV diameter was calculated in case the placenta possessed multiple AA or VV anastomoses by adding the subsequent diameters together. The umbilical cord insertion ratio was determined by dividing the total distance of the placenta by the distance between the two cord insertions. The umbilical cord insertions were divided into velamentous, marginal and (para)central⁹. The fetal weight ratio was calculated using the following formula: fetal weight larger twin/fetal weight smaller twin. Similarly, placental territory ratio was calculated by dividing the larger placental territory by the smaller placental territory.

Primary outcomes were the placental share discordance and the diameter of the AA anastomoses. The primary outcomes were compared according to the Gratacós classification system.

Data are presented as median (range). Data were analyzed using a Chi-square test for categorical variables, a Kruskal Wallis test for numerical variables and a GEE-analysis for survival data. A *p*-value < 0.05 was considered statistically significant. Statistical data was analyzed using IBM statistics v23.0 (SPSS, Inc., an IBM company, Chicago, IL, USA).

Results

A total of 109 placentas were eligible for the study based on the aforementioned inclusion criteria. Fifteen cases were excluded because a Gratacós classification was not recorded and eleven cases were excluded because measurements could not be performed due to damage of the placenta, leaving 83 placentas to be included in the study (Figure 1).

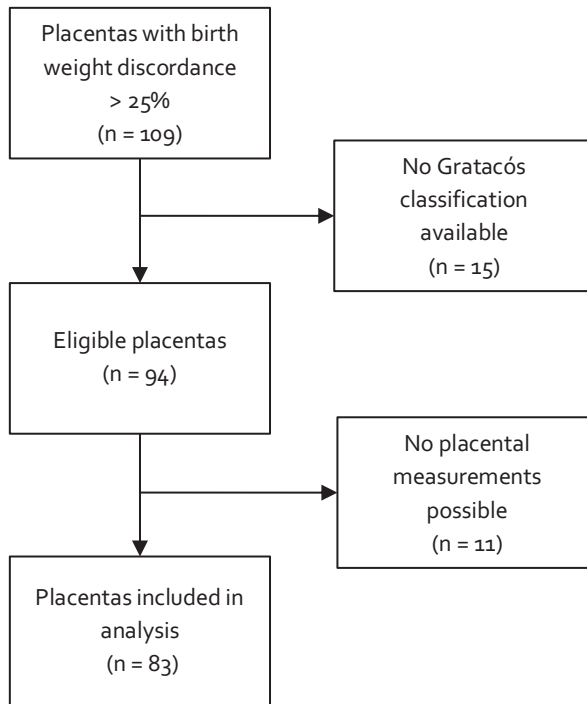


Figure 1. Flowchart of placenta inclusion.

Of the 83 pregnancies and placentas included, 28 were classified as type I, 24 as type II and 31 as type III. Table 1 summarizes the baseline characteristics of the pregnancies according to the Gratacós classification. Type II and type III had a significantly lower gestational age at birth than type I. Gestational age at birth for type I was 34.3 (32.7-35.9) weeks compared to 31.2 (28.4-34.0) and 31.4 (28.8-34.1) weeks for type II and type III respectively ($p < 0.01$). Type II sFGR cases demonstrated the highest birth weight discordance, namely 38.2% (31.7-44.7) as opposed to 32.8% (27.8-37.8) in type I and 31.9% (26.4-37.4) in type III ($p = 0.035$).

Table 1. Baseline characteristics according to umbilical artery Doppler classification.

Characteristics	Gratacós type I (n=28)	Gratacós type II (n=24)	Gratacós type III (n=31)	p-value
Age mother – years	32.5 (29.0-36.0)	32.0 (27.0-37.0)	31.0 (29.0-33.0)	0.610
Gravidity – n	2 (1-2)	2 (1-3)	2 (1-3)	0.512
Parity – n	0 (0-1)	0 (0-1)	0 (0-1)	0.800
GA at diagnosis – weeks	17.0 (13.7-20.4)	17.9 (13.1-22.8)	18.7 (16.9-20.6)	0.805
GA at birth – weeks	34.3 (32.7-35.9)	31.2 (28.4-34.0)	31.4 (28.8-34.1)	0.001
Caesarian section	16 (57)	18 (75)	24 (77)	0.273
Female	12 (42)	8 (33)	18 (58)	0.226
Birth weight – grams				
Larger twin	2356 (1966-2746)	1635 (1270-2001)	1540 (1015-2065)	<0.0001
Smaller twin	1474 (1117-1830)	941 (571-1311)	968 (671-1266)	<0.0001
BWD – %	32.8 (27.8-37.8)	38.2 (31.7-44.7)	31.9 (26.4-37.4)	0.035
Hb difference at birth – mmol/L	0.9 (0.0-1.8)	1.5 (0.5-2.5)	0.5 (-0.1-1.1)	0.194
Perinatal survival	49/54 (91)	40/48 (83)	53/62 (86)	0.577
Cerebral injury	0/39 (0)	1/41 (2)	2/47 (4)	0.433

GA: gestational age, BWD: birth weight discordance.

Data are median (IQR), n/N(%) or n (%); Cerebral injury defined as periventricular leukomalacia (PVL) \geq grade 2, intraventricular hemorrhage (IVH) \geq grade 3, ventricular dilatation, arterial or venous infarct or other severe cerebral injury.

Table 2 summarizes the placental characteristics according to the Gratacós classification. At least one AA anastomosis was detected in all sFGR placentas. In a few placentas (6.0%, 5/83), more than one AA anastomosis were present.

The diameter of the AA anastomoses was significantly higher in type III compared to type I and II, namely 2.8 mm (2.0-3.5) in type III versus 1.7 (0.8-2.6) in type I and 1.7 (0.8-2.6) in type II ($p < 0.01$). Moreover, type III demonstrated the highest proportion of AA anastomoses with a diameter larger than 2 mm, namely 77.4% as opposed to 42.9% in type I and 29.2% in type II ($p < 0.01$). The median fetal weight ratio was 1.5 (1.4-1.6) in type I, 1.6 (1.4-1.8) in type II and 1.5 (1.3-1.6) in type III ($p = 0.027$). The median placental territory ratio differed between the groups with 2.4 (1.7-2.9) in type I, 2.2 (1.5-2.9) in type II and 2.8 (2.2-3.5) in type III ($p = 0.044$). When dividing these (fetal weight ratio/placental territory ratio), type III sFGR cases had a significantly lower ratio ($p = 0.025$), meaning that type III sFGR cases have a lower fetal weight discordance than expected for the amount of placental territory discordance.

Mortality rate and the incidence of cerebral injury was low and similar in the three groups (Table 1). One twin pair (type I) had missing data concerning the perinatal mortality. In all cases, the cerebral injury affected the larger twin. The first case (type II) experienced an arterial infarction on the first day after birth. In the second case (type III), cerebral injury was caused by post-hemorrhagic ventricle dilatation one week after birth due to IVH grade 3. The last case (type III) suffered from a PVL grade III which was not present antenatally but developed several weeks after birth.

Table 2. Placental features and anastomoses according to umbilical artery Doppler classification.

Characteristics	Gratacós type I (n=28)	Gratacós type II (n=24)	Gratacós type III (n=31)	p- value
Placental share – %				
Larger twin	70.9 (64.4-77.3)	69.4 (62.7-76.2)	73.9 (69.6-78.3)	0.091
Smaller twin	29.1 (22.7-35.6)	30.6 (23.8-37.3)	26.1 (22.0-30.6)	0.091
Placental territory ratio	2.4 (1.7-2.9)	2.2 (1.5-2.9)	2.8 (2.2-3.5)	0.044
Fetal weight ratio	1.5 (1.4-1.6)	1.6 (1.4-1.8)	1.5 (1.3-1.6)	0.027
Fetal weight ratio/placental territory ratio	0.6 (0.4-0.8)	0.7 (0.4-0.9)	0.5 (0.4-1.6)	0.025
Arterio-arterial anastomoses				
1 AA	27 (96.4)	23 (95.8)	28 (90.3)	0.730
>1 AAs	1 (3.6)	1 (4.2)	3 (9.7)	
Total AA diameter – mm	1.7 (0.8-2.6)	1.7 (1.2-2.2)	2.8 (2.0-3.5)	0.002
AA diameter > 2 mm	12 (42.9)	7 (29.2)	24 (77.4)	0.001
Veno-venous anastomoses				
0 VV	22 (75.9)	18 (75.0)	24 (77.4)	0.764
1 VVs	6 (20.7)	5 (20.8)	5 (16.1)	
>1 VVs	1 (3.4)	1 (4.2)	2 (6.4)	
Total VV diameter – mm	2.2 (1.3-3.2)	2.7 (1.9-3.6)	3.0 (1.5-4.4)	0.884
Velamentous/marginal cord insertion				
Larger twin	4 (7.1)	2 (4.2)	1 (1.6)	0.293
Smaller twin	20 (35.7)	22 (45.8)	26 (41.9)	0.117
Umbilical cord insertion ratio	61.5 (46.5-86.5)	64.5 (56.0-73.0)	59.6 (43.6-75.6)	0.741

Data are median (IQR), n/N(%) or n (%).

Discussion

This study shows that the placental characteristics vary according to the type of sFGR, in particular the diameter of the AA anastomoses. We found that the AA diameter in type III pregnancies was significantly larger (almost double the size) compared to type I and II. In addition, we found a trend towards a higher placental share discordance in type III sFGR. Our data thus confirms that placentas in type III sFGR cases have larger AA anastomoses and a higher degree of sharing discordance.

The placental characteristics in type I and II placentas appear to be largely similar, with almost identical placental territory ratios (2.4 and 2.2, respectively) and equal size of the AA anastomoses (diameter of 1.7 mm in both types). Moreover, seven (24.1%) of the type I placentas and six (25.0%) of the type II placentas demonstrated VV anastomoses. Lastly, the umbilical cord insertions were farther apart in both groups compared to type III, as observed in the umbilical cord ratios of 61.5 in type I, 64.5 in type II and 59.6 in type III.

Due to the similarities of the placental characteristics between type I and type II sFGR, it is difficult to distinguish a type I sFGR from a type II based solely on observation of the placentas. So far, it is unclear why the UA Doppler of type II is abnormal.

In contrast, type III placentas reveal a different architecture as opposed to type I and II placentas, with a significantly larger median diameter of the AA anastomoses (2.8 mm) and a trend towards a higher placental share discrepancy, with a placental territory ratio of 2.8. Additionally, the umbilical cord ratio was smaller compared to type I and II (Figure 2).

When interpreting the size of the AA anastomoses, one should take into account the significantly lower gestational age at birth in type II and III sFGR. Placental vessels grow with advancing gestational age¹⁰, which could bias the comparison of the AA diameter, as type I twins have a higher gestational age allowing for a longer period of growth. This might lead to an underestimation of the discrepancy in diameter of type I AA anastomoses versus type II and III. However, more extensive research is required to confirm the correlation between gestational age and chorionic vessel diameter with more certainty.

Our results are largely similar to the results of Gratacós et al.⁴. The diameter of AA anastomoses in their study was larger than 2 mm, predominantly in type III sFGR compared to type I and II, namely 98% of the AA anastomoses in type III and 70% and

18% in type I and II respectively ($p < 0.01$). This correlates with our findings that type III sFGR has the largest AA diameter and in our study 77.4% of AA anastomoses also had a diameter > 2 mm. However, exact measurements of the AA anastomoses were not reported in the study from Gratacós et al. limiting the comparisons between our studies.

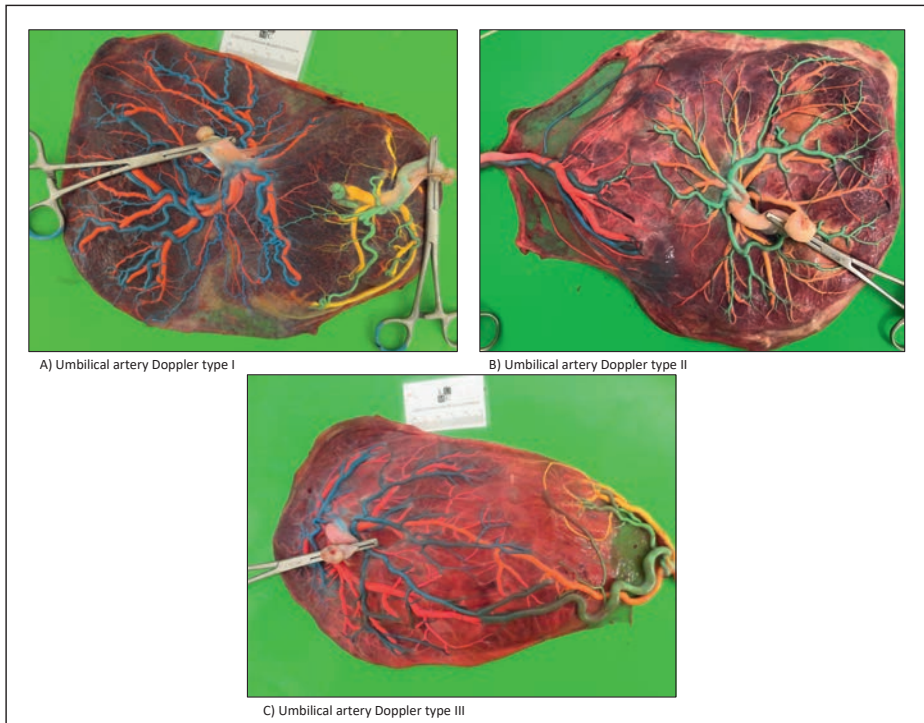


Figure 2. Pictures of injected placentas of pregnancies with sFGR with UA Doppler type I (A), type II (B) and type III (C). Type I demonstrates a small AA anastomosis. In type II the diameter of the AA anastomosis is slightly larger. Type III shows the largest diameter.

Gratacós et al. also found that the placental territory ratio increased significantly from type I to type III, namely from 1.8 in type I, 2.6 in type II and 4.4 in type III, which is not in agreement with our study results. They also concluded that the ratio between fetal and placental discordance followed a similar pattern. This is complementary to our results, even though the differences are not as broad. The reasons for the differences between the studies are not entirely clear. Heterogeneity in study populations may have contributed to the discrepancies between our results, however the true reasons remain elusive.

The larger diameter of the AA anastomoses and higher degree of sharing discordance in type III sFGR found in these two studies may explain the high rate of adverse outcome. This in turn leads to more detrimental clinical consequences, such as cerebral injury^{5,6} or neurodevelopmental impairment^{11,12}. Our study results elicit a possible pathophysiology of sFGR. Due to the AA anastomoses, there is a compensatory flow of the large twin to the smaller twin. This flow can serve as a rescue transfusion for the smaller twin, since its placental share is temporarily perfused by the flow of the larger twin through the AA anastomosis after the systole⁴. These flow patterns can be recognized in UA Doppler measurements. As the diameter of the AA anastomoses increases, there is more feto-fetal transfusion, resulting in an increased compensatory flow. However, larger AA anastomoses might also result in acute feto-fetal transfusion which leads to IUFD or neurological damage in either of the twins^{6,13}. Therefore, the larger diameter of AA anastomoses in type III is the most likely cause of the unpredictable clinical outcomes.

The lower gestational age at birth of type III sFGR twins is probably the direct consequence of the atypical clinical course, which leads to earlier iatrogenic delivery as compared to type I and type II as was observed in our results.

Furthermore, our results show that there is a larger discrepancy between fetal weight and placental share discordance in type III, suggesting that the placental anastomoses have less effect on the fetal weight than expected. A possible explanation for this is the rescue transfusion of the larger twin to the smaller twin. Since the AA anastomoses in type III have a significantly larger diameter, there is a larger net transfusion which compensates for the amount of placental share discordance and allows for growth of the smaller twin.

According to a study performed by Rustico et al.¹⁴, the UA Doppler classification is not static, but rather dynamic and may change over time into another type. This presents difficulty in determining the Gratacós type. The dynamic character of the flows could also have consequences for the outcomes and management and should be taken into account when assessing the individual risk per pregnancy. It stresses the importance of frequent and consistent monitoring of the UA flow, to document changes in flow patterns.

When interpreting our data, there are certain limitations that should be taken into account. Firstly, the retrospective character of the data collection and the relatively small sample size could introduce bias into our results. Since our institution is a

specialized center, referral bias could interfere with our results as well. Generally, only the complicated cases of sFGR are referred to our center for further diagnosis and therapy. Nevertheless, the number of cases with type I, II and III was evenly distributed in our study without an overrepresentation of the more severe cases. Additional studies with a prospective character and a larger study population of MC twin pregnancies with sFGR might present more evidence on the placental characteristics in relation to the UA Doppler classification with superior quality.

In conclusion, this study shows that the types of the Gratacós classification are associated with specific placental features, with type I and II having a relatively similar architecture as opposed to type III. These placental features can in turn determine the level of severity of the sFGR and perinatal outcomes. Type III sFGR has a larger AA anastomosis diameter and a larger placental share discordance and therefore has the most unpredictable clinical outcome due to the risk of acute feto-fetal transfusion, leading to IUFD or neurological damage. More research may lead to a better understanding of how the placental architecture contributes to the pathophysiology and clinical outcomes in MC twins with sFGR according to the UA Doppler measurements. In the future, early antenatal visualization of the AA anastomoses identifying the Gratacós classification with its associated risks might lead to timely and appropriate management.

References

1. Hack KE, Derks JB, Elias SG, et al. Increased perinatal mortality and morbidity in monochorionic versus dichorionic twin pregnancies: clinical implications of a large Dutch cohort study. *BJOG*. Jan 2008;115(1):58-67.
2. Lewi L, Cannie M, Blickstein I, et al. Placental sharing, birthweight discordance, and vascular anastomoses in monochorionic diamniotic twin placentas. *Am J Obstet Gynecol*. Dec 2007;197(6):587 e1-8.
3. Lewi L, Deprest J, Hecher K. The vascular anastomoses in monochorionic twin pregnancies and their clinical consequences. *Am J Obstet Gynecol*. Jan 2013;208(1):19-30.
4. Gratacos E, Lewi L, Munoz B, et al. A classification system for selective intrauterine growth restriction in monochorionic pregnancies according to umbilical artery Doppler flow in the smaller twin. *Ultrasound Obstet Gynecol*. Jul 2007;30(1):28-34.
5. Gratacos E, Carreras E, Becker J, et al. Prevalence of neurological damage in monochorionic twins with selective intrauterine growth restriction and intermittent absent or reversed end-diastolic umbilical artery flow. *Ultrasound Obstet Gynecol*. Aug 2004;24(2):159-63.
6. Inklaar MJ, van Klink JM, Stolk TT, van Zwet EW, Oepkes D, Lopriore E. Cerebral injury in monochorionic twins with selective intrauterine growth restriction: a systematic review. *Prenat Diagn*. Mar 2014;34(3):205-13.
7. Lewi L, Gucciardo L, Huber A, et al. Clinical outcome and placental characteristics of monochorionic diamniotic twin pairs with early- and late-onset discordant growth. *Am J Obstet Gynecol*. Nov 2008;199(5):511 e1-7.
8. Lopriore E, Pasman SA, Klumper FJ, Middeldorp JM, Walther FJ, Oepkes D. Placental characteristics in growth-discordant monochorionic twins: a matched case-control study. *Placenta*. Mar 2012;33(3):171-4.
9. Di Salvo DN, Benson CB, Laing FC, Brown DL, Frates MC, Doubilet PM. Sonographic evaluation of the placental cord insertion site. *AJR Am J Roentgenol*. May 1998;170(5):1295-8.
10. Nikkels PG, Hack KE, van Gemert MJ. Pathology of twin placentas with special attention to monochorionic twin placentas. *J Clin Pathol*. Dec 2008;61(12):1247-53.
11. Edmonds CJ, Isaacs EB, Cole TJ, et al. The effect of intrauterine growth on verbal IQ scores in childhood: a study of monozygotic twins. *Pediatrics*. Nov 2010;126(5):e1095-101.
12. Halling C, Malone FD, Breathnach FM, et al. Neuro-developmental outcome of a large cohort of growth discordant twins. *Eur J Pediatr*. Mar 2016;175(3):381-9.
13. Townsend R, Khalil A. Twin pregnancy complicated by selective growth restriction. *Curr Opin Obstet Gynecol*. Dec 2016;28(6):485-491.
14. Rustico MA, Consonni D, Lanna M, et al. Selective intrauterine growth restriction in monochorionic twins: changing patterns in umbilical artery Doppler flow and outcomes. *Ultrasound Obstet Gynecol*. Mar 2017;49(3):387-393.

