



Universiteit
Leiden
The Netherlands

Ischemia and no obstructive stenosis (INOCA) at CT angiography, CT myocardial perfusion, invasive coronary angiography, and SPECT: the CORE320 study

Schuijf, J.D.; Matheson, M.B.; Ostovaneh, M.R.; Arbab-Zadeh, A.; Kofoed, K.F.; Scholte, A.J.H.A.; ... ; Lima, J.A.C.

Citation

Schuijf, J. D., Matheson, M. B., Ostovaneh, M. R., Arbab-Zadeh, A., Kofoed, K. F., Scholte, A. J. H. A., ... Lima, J. A. C. (2020). Ischemia and no obstructive stenosis (INOCA) at CT angiography, CT myocardial perfusion, invasive coronary angiography, and SPECT: the CORE320 study. *Radiology*, 294(1), 61-73. doi:10.1148/radiol.2019190978

Version: Publisher's Version
License: [Creative Commons CC BY 4.0 license](https://creativecommons.org/licenses/by/4.0/)
Downloaded from: <https://hdl.handle.net/1887/3232730>

Note: To cite this publication please use the final published version (if applicable).

Ischemia and No Obstructive Stenosis (INOCA) at CT Angiography, CT Myocardial Perfusion, Invasive Coronary Angiography, and SPECT: The CORE320 Study

Joanne D. Schuijf, PhD • Matthew B. Matheson, MS • Mohammad R. Ostovaneh, MD • Armin Arbab-Zadeh, MD, MPH, PhD • Klaus F. Kofoed, MD, PhD, DmSc • Arthur J. H. A. Scholte, MD, PhD • Marc Dewey, MD, PhD • Chloe Steveson, MHLthSc • Carlos E. Rochitte, MD, PhD • Kunihiko Yoshioka, MD, PhD • Christopher Cox, PhD • Marcelo F. Di Carli, MD • João A. C. Lima, MD

From the Global RDC, Canon Medical Systems Europe, Zoetermeer, the Netherlands (J.D.S.); Department of Epidemiology, Johns Hopkins University, Baltimore, Md (M.B.M., C.C.); Departments of Medicine and Radiology, Johns Hopkins School of Medicine, 600 N Wolfe St, Blalock 524, Baltimore, MD 21287 (M.R.O., A.A., J.A.C.L.); Department of Cardiology and Radiology, Rigshospitalet, University of Copenhagen, Copenhagen, Denmark (K.F.K.); Department of Cardiology, Leiden University Medical Center, Leiden, the Netherlands (A.J.H.A.S.); Department of Radiology, Charité-Universitätsmedizin Berlin, Berlin, Germany (M.D.); Canon Medical Systems, Otawara, Japan (C.S.); InCor Heart Institute, University of São Paulo Medical School, São Paulo, Brazil (C.E.R.); Department of Radiology, Iwate Medical University, Morioka, Japan (K.Y.); and Departments of Radiology and Medicine, Brigham and Women's Hospital, Boston, Mass (M.F.D.C.). Received May 3, 2019; revision requested June 3; final revision received August 9; accepted September 30. Address correspondence to J.A.C.L. (e-mail: jlima@jhmi.edu).

The main trial, the CORE320 study, was funded by Canon (formerly Toshiba) Medical Systems. J.D.S. is an employee of Canon Medical Systems Europe. C.S. is an employee of Canon Medical Systems, Otawara, Japan. J.A.C.L. discloses grant support from Canon (formerly Toshiba) Medical Systems.

Conflicts of interest are listed at the end of this article.

See also the editorial by François in this issue.

Radiology 2020; 294:61–73 • <https://doi.org/10.1148/radiol.2019190978> • Content codes: **CA** **CT**

Background: CT allows evaluation of atherosclerosis, coronary stenosis, and myocardial ischemia. Data on the characterization of ischemia and no obstructive stenosis (INOCA) at CT remain limited.

Purpose: This was an observational study to describe the prevalence of INOCA defined at coronary CT angiography with CT perfusion imaging and associated clinical and atherosclerotic characteristics. The analysis was also performed for the combination of invasive coronary angiography (ICA) and SPECT as a secondary aim.

Materials and Methods: The prospective CORE320 study (*ClinicalTrials.gov*: NCT00934037) enrolled participants between November 2009 and July 2011 who were symptomatic and referred for clinically indicated ICA. Participants underwent CT angiography, rest-adenosine stress CT perfusion, and rest-stress SPECT prior to ICA. For this ancillary study, the following three phenotypes were considered, using either CT angiography/CT perfusion or ICA/SPECT data: (a) participants with obstructive ($\geq 50\%$) stenosis, (b) participants with no obstructive stenosis but ischemia (ie, INOCA) on the basis of abnormal perfusion imaging results, and (c) participants with no obstructive stenosis and normal perfusion imaging results. Clinical characteristics and CT angiography atherosclerotic plaque measures were compared by using the Pearson χ^2 or Wilcoxon rank-sum test.

Results: A total of 381 participants (mean age, 62 years [interquartile range, 56–68 years]; 129 [34%] women) were evaluated. A total of 31 (27%) of 115 participants without obstructive ($\geq 50\%$) stenosis at CT angiography had abnormal CT perfusion findings. The corresponding value for ICA/SPECT was 45 (30%) of 151. The prevalence of INOCA was 31 (8%) of 381 (95% confidence interval [CI]: 5%, 11%) with CT angiography/CT perfusion and 45 (12%) of 381 (95% CI: 9%, 15%) with ICA/SPECT. Participants with CT-defined INOCA had greater total atheroma volume (118 vs 60 mm³, $P = .008$), more positive remodeling (13% vs 1%, $P = .006$), and greater low-attenuation atheroma volume (20 vs 10 mm³, $P = .007$) than participants with no obstructive stenosis and no ischemia. Comparisons for ICA/SPECT showed similar trends.

Conclusion: In CORE320, ischemia and no obstructive stenosis (INOCA) prevalence was 8% and 12% at CT angiography/CT perfusion and invasive coronary angiography/SPECT, respectively. Participants with INOCA had greater atherosclerotic burden and more adverse plaque features at CT compared with those with no obstructive stenosis and no ischemia.

© RSNA, 2019

Online supplemental material is available for this article.

The diagnostic work-up of patients with chest pain suggestive of coronary artery disease (CAD) at presentation is typically oriented toward the detection of a hemodynamically relevant obstructive stenosis, which serves as the basis for further treatment decisions, such as coronary intervention. However, a considerable number of patients who have angina and signs of ischemia at presentation do not have significant obstructive disease, as defined by 50% or greater diameter stenosis detected at invasive coronary

angiography (ICA) (1). Initially, such observations were explained as false-positive results, but an elevated risk of adverse events has been repeatedly demonstrated in these patients as compared with participants in reference cohorts, suggesting that this condition, ischemia and no obstructive stenosis (INOCA), should not be considered benign (1–4). In addition, recurrent angina after successful percutaneous coronary intervention remains a clinically relevant issue occurring in a non-negligible percentage of patients (5). As a

Abbreviations

CAD = coronary artery disease, ICA = invasive coronary angiography, INOCA = ischemia and no obstructive stenosis, IQR = interquartile range

Summary

The combination of coronary CT angiography and CT myocardial perfusion provides a promising opportunity for detailed and noninvasive coronary artery disease phenotyping, including characterization of ischemia without obstructive stenosis.

Key Results

- In a high-risk symptomatic cohort referred for invasive coronary angiography, 27% of participants without significant stenosis at coronary CT angiography showed downstream perfusion defects at CT myocardial perfusion indicative of ischemia and no obstructive stenosis (INOCA), resulting in an overall prevalence of 8%.
- Participants with CT-defined INOCA had greater total atheroma volume (118 vs 60 mm³, $P = .008$), more positive remodeling (13% vs 1%, $P = .006$), and greater low-attenuation atheroma volume (20 vs 10 mm³, $P = .007$) than participants with normal perfusion at CT perfusion and no significant stenosis at CT angiography.
- These results suggest that patients with INOCA should be treated medically not only to control angina pectoris but also to forestall progression of atherosclerosis.

result, there is an emerging notion that the current diagnostic paradigm centered on the flow-limiting obstructive stenosis is incomplete and may fail to sufficiently recognize other clinically relevant pathophysiologic phenotypes of CAD (6). Indeed, beyond focal obstructive epicardial disease, diffuse nonobstructive atherosclerosis and microvascular disease may also contribute in varying degrees to myocardial ischemia, symptom development, and impaired prognosis (3,4,6,7).

Noninvasively, phenotypes beyond obstructive stenosis may be characterized by using CT (8), as the combination of coronary CT angiography and CT perfusion allows characterization of atherosclerotic plaque, coronary stenosis, and myocardial ischemia in a single examination. However, data characterizing INOCA with CT remain limited. In the CORE320 trial, all participants underwent both CT angiography and CT perfusion in addition to ICA and SPECT, regardless of stenosis severity (9). Although SPECT has lower diagnostic power for ischemia detection than CT perfusion imaging (10,11), the combination of ICA and SPECT remains far more commonly used to define CAD. The CORE320 study, performed in a heterogeneous and multinational high-risk cohort, enrolled only patients with typical or atypical angina pectoris or angina-equivalent symptoms suspected to be caused by ischemic heart disease. Most patients, including those without and those with a previous history of CAD, presented with chest pain and had been referred for ICA by their attending physician at the time of study enrollment. Thus, the CORE320 study offers a unique opportunity to provide data on the prevalence and characterization of different CAD phenotypes (9,12).

The aim of the current observational analysis was to describe the prevalence of INOCA defined at CT angiography with CT perfusion and associated clinical and atherosclerotic characteristics in the CORE320 study cohort. The analysis was also performed for the combination of ICA and SPECT as a secondary aim.

Materials and Methods

CORE320 Study Design and Study Population

The current analysis is an ancillary analysis of data from the CORE320 trial, a prospective, multicenter, multinational, diagnostic study (www.clinicaltrials.gov: NCT00934037) with participants enrolled from November 2009 to July 2011 at 16 sites (13 academic centers and three private hospitals) in eight countries. The study protocol was approved by central and local institutional review boards at each of the 16 institutions, and written informed consent was obtained from all participants. In the United States, Health Insurance Portability and Accountability Act approval was obtained as part of the central approval process. CORE320 evaluated the diagnostic accuracy of combined CT angiography and adenosine stress CT perfusion performed by using a 320 × 0.5-mm detector row system (Aquilion ONE; Canon Medical Systems, Otawara, Japan) against the combined reference standard of ICA and SPECT myocardial perfusion imaging results to identify patients with flow-limiting CAD. The study design, methods, and diagnostic and prognostic results have been reported previously, including the primary analysis of CORE320 (9,11–16). We now report on the prevalence of INOCA and associated clinical and atherosclerotic characteristics. The CORE320 study was funded by Canon (formerly Toshiba) Medical Systems. The study funder had no role in study design, data accrual, data analysis, or manuscript preparation. J.D.S. and C.S. are employees of Canon Medical Systems but did not control any data. All data were reconstructed, processed, interpreted, and/or analyzed by blinded core laboratories.

All participants included in the primary analysis of CORE320 (9) were also included in the current analysis, resulting in a total of 381 participants. Briefly, patients 45–85 years of age who were referred for clinically indicated ICA for suspected or known CAD and who were able to provide written informed consent were enrolled. Detailed exclusion criteria are described in Appendix E1 (online). The study enrolled and analyzed all participants regardless of calcium score and presence of stents. Detailed descriptions of the CORE320 design and methods have been published elsewhere (12,14).

Data Analysis

Details regarding data handling and analyses have been described previously (13). All studies were analyzed by independent core laboratories blinded to other data. The following two imaging combinations were used: (a) coronary angiography and perfusion imaging with CT (CT angiography/CT perfusion) and (b) invasive coronary angiography and SPECT perfusion imaging (ICA/SPECT).

For vessel-based analysis, the degree of stenosis at CT angiography was analyzed visually per vessel by using the following categories: 0% stenosis (normal coronary arteries), 1%–29% stenosis, 30%–49% stenosis, 50%–69% stenosis, and 70% or greater stenosis. The degree of stenosis at ICA was analyzed quantitatively per vessel by using the same categories. CT perfusion and SPECT data were read by using a 13-segment model. A summed stress score of 2 or greater was used to define the presence of abnormal perfusion in a vascular territory at CT perfusion. At

SPECT, abnormal perfusion was defined as a summed stress score of 1 or greater.

For patient-level analysis, participants with at least one stenosis of 50% or greater were categorized as having obstructive CAD. Participants without obstructive CAD (<50% stenosis) were further divided into participants with and those without evidence of ischemia. In addition, the number of participants with completely normal coronary arteries (defined as 0% luminal narrowing) yet abnormal perfusion was recorded.

The following three distinct phenotypes were constructed on a patient basis as described above: participants with 50% or greater stenosis at angiography were classified as having obstructive stenosis, participants without obstructive stenosis but with ischemia on the basis of abnormal perfusion imaging results were classified as having INOCA, and participants without obstructive stenosis and normal perfusion imaging results were classified as having normal or near-normal results. These phenotypes were constructed by using the combinations CT angiography/CT perfusion and ICA/SPECT separately.

Clinical and atherosclerotic plaque characteristics of participants with INOCA were investigated. To describe the extent of atherosclerosis, Agatston calcium score, number of vessels with plaque, number of segments with plaque, percentage atheroma volume, total atheroma volume, low-attenuation (lipid/necrotic core) atheroma volume, maximum lesion length, and positive remodeling were determined at CT angiography, as described in Appendix E1 (online) (16,17).

Two-year outcome data were collected as described in Appendix E1 (online) (15).

Statistical Analysis

Participants' baseline data were summarized by using medians and interquartile ranges for continuous variables and frequencies and percentages for categorical variables. For vessel-level observations, 95% confidence intervals were calculated from a generalized estimating equation model that accounted for within-patient clustering of vessels but assumed the vessels to be independent. For patient-level descriptions, this adjustment was not necessary.

The prevalence of INOCA was compared between the two combinations (CT angiography/CT perfusion and ICA/SPECT) by using the McNemar test. Clinical and atherosclerotic plaque characteristics were compared according to CT-based phenotypes (INOCA vs normal or near-normal findings and INOCA vs obstructive stenosis) by using the Pearson χ^2 or Wilcoxon rank-sum test, as appropriate. Per clinical characteristics, the proportion of INOCA between exposure groups was compared by using χ^2 tests. For the vessel-based analysis, the test of difference in INOCA proportion was adjusted for repeated measurements by using generalized estimating equation models. The analyses were repeated for the phenotypes based on ICA/SPECT. All analyses were performed by using SAS, version 9.4 for Windows (SAS Institute, Cary, NC). All statistical analyses were performed by the CORE320 Statistical Core Laboratory at the Johns Hopkins Bloomberg School of Public Health.

Table 1: Clinical Characteristics of the Study Population (n = 381)

Characteristic	Value
Age (y)*	62 (56–68)
Age \geq 60 years	226 (59)
No. of men/no. of women	252 (66)/129 (34)
Race	
White	213 (56)
Black	40 (10)
Asian	123 (32)
Other	5 (1)
BMI (kg/m ²)*	27 (24–30)
Obesity (BMI \geq 30 kg/m ²)	97 (25)
Hypertension	297 (78)
Diabetes	131 (34)
Dyslipidemia	254 (68)
Current smoker	64 (18)
Family history of CAD	162 (45)
Canadian angina classification available	289 (76)
Class 0–2	271 (94)
Class 3–4	18 (6)
Canadian angina classification unavailable	92 (24)
Diamond-Forrester risk score	
Low	8 (2)
Intermediate	255 (67)
High	118 (31)
Previous cerebrovascular accident	12 (3)

Note.—Unless otherwise specified, data are numbers of participants, with percentages in parentheses. BMI = body mass index, CAD = coronary artery disease.

* Data are medians, with interquartile ranges in parentheses.

Results

Study Cohort

All participants included in the primary analysis of CORE320 data (9) were also included in the current analysis, resulting in a total of 381 participants. Baseline characteristics can be found in Table 1.

Relationship between Degree of Stenosis and Perfusion on a Vessel Basis

In total, 1143 coronary arteries and corresponding vascular territories were available for analysis. The relationship between degree of stenosis and percentage of corresponding vascular territories with normal perfusion is illustrated in Figure 1 for the combinations CT angiography/CT perfusion and ICA/SPECT. The likelihood of normal myocardial perfusion decreases with increasing degree of luminal narrowing. In the intermediate ranges of stenosis (30%–50% and 50%–70% luminal narrowing), rates of normal perfusion were lower for the combination of CT angiography/CT perfusion than for ICA/SPECT. Results on a binary level (\geq 50% stenosis) were as follows: Among the 578 coronary arteries with 50% or greater stenosis at CT angiography, abnormal perfusion at CT perfusion was observed in 404 (70%) of

578 corresponding vascular territories. At the same time, however, abnormal perfusion was also observed in 141 (25%) of the 565 coronary artery territories without stenosis of 50% or greater. For the combination of ICA and SPECT, findings were comparable, with slightly lower rates of abnormal perfusion. Among the 464 coronary arteries with stenosis of 50% or greater at ICA, abnormal perfusion was observed in 263 (57%) of 464 corresponding vascular territories. In the 679 coronary arteries without stenosis of 50% or greater at ICA, abnormal perfusion at SPECT was observed in 115 (17%) of 679 territories.

Prevalence of INOCA

Clinical case examples of participants with IN-

OCA are provided in Figures 2 and 3 from participants without and participants with a previous history of CAD, respectively.

Obstructive stenosis ($\geq 50\%$) was absent at CT angiography in 115 (30%) of 381 participants. Abnormal perfusion at CT perfusion was observed in 31 (27%) of these 115 participants. Accordingly, the prevalence of INOCA was 31 (8%) of 381 (95% confidence interval: 5%, 11%) in the entire cohort on the basis of CT data. A defect at CT perfusion without obstructive stenosis in the corresponding coronary artery was also seen in 68 participants with at least one obstructive ($\geq 50\%$) stenosis at CT angiography and corresponding defect at CT perfusion. The prevalence of abnormal perfusion in the absence of any atherosclerosis (defined as 0% stenosis at CT) was very low and was observed in only nine (2%) of all 381 participants.

Obstructive ($\geq 50\%$) stenosis was absent at ICA in 151 (40%) of 381 participants. With the combination of ICA/SPECT, INOCA was seen in 45 (30%) of 151 participants without obstructive ($\geq 50\%$) stenosis, with a prevalence of 45 (12%) of 381 (95% confidence interval: 9%, 15%) in the overall cohort. Similar to CT angiography/CT perfusion, at SPECT, the prevalence of abnormal perfusion in the absence of any atherosclerosis visible at ICA (0% stenosis) was very low (2% [eight of 381 participants]).

The proportion of participants with INOCA was not significantly different between CT angiography/CT perfusion and ICA/SPECT, although the corresponding *P* value was borderline (*P* = .06).

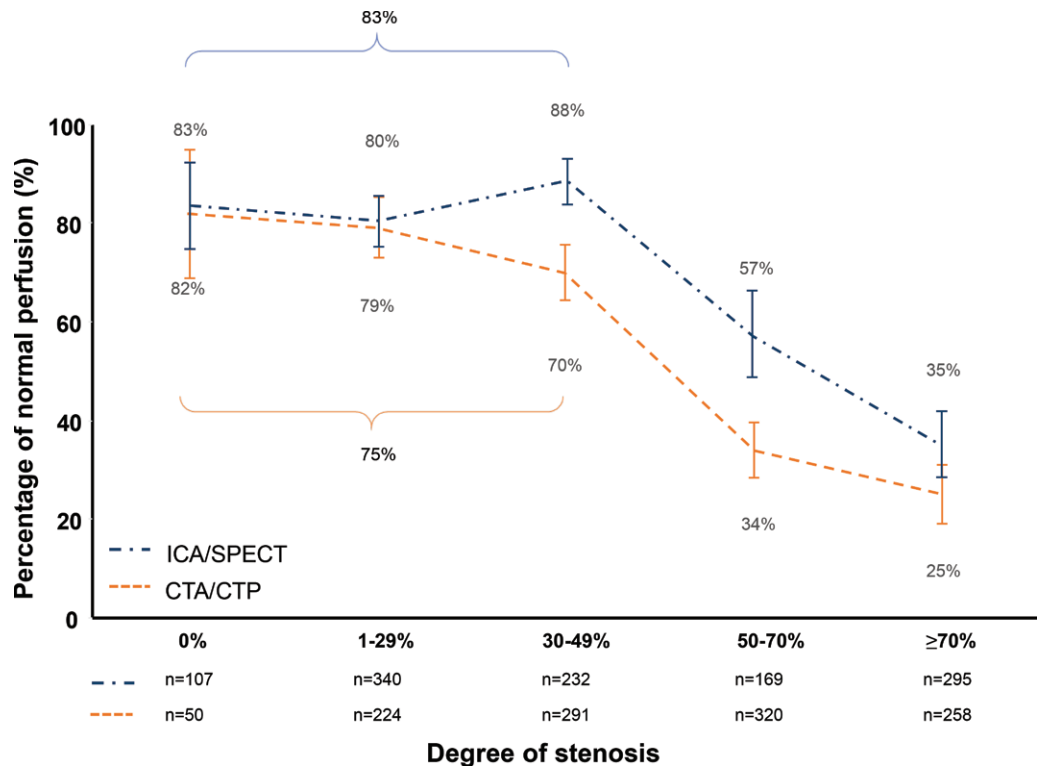


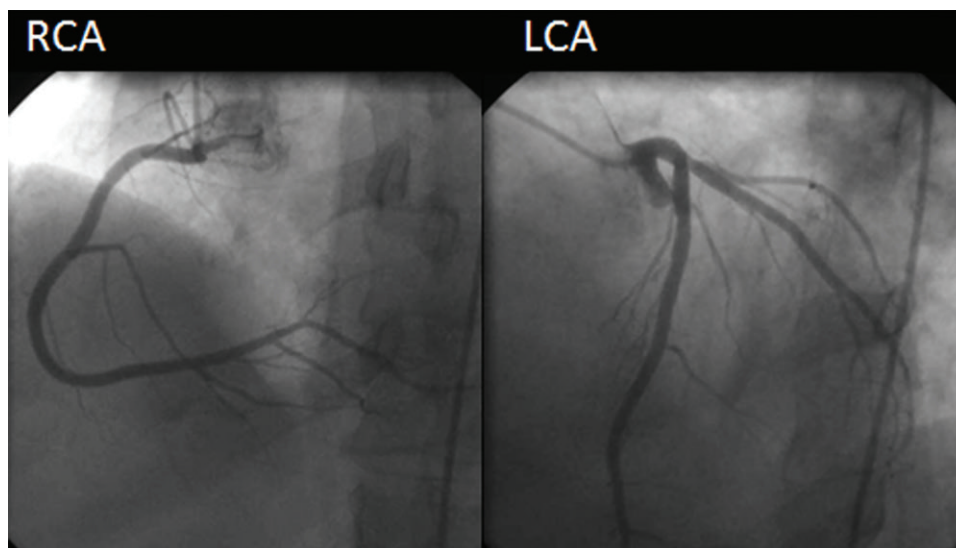
Figure 1: Graph shows relationship between the degree of stenosis and percentage normal perfusion in the corresponding vascular territory using either the combination of CT angiography (CTA) and CT perfusion (CTP) (orange line) or invasive coronary angiography (ICA) and SPECT (blue line). The percentage normal perfusion decreases with increasing degree of luminal narrowing. For ICA/SPECT and CT angiography/CT perfusion, 83% and 75% of vessels, respectively, had normal perfusion for vessels with stenosis of $< 50\%$ narrowing. Error bars = 95% confidence intervals. *n* = Number of coronary vessels.

Clinical Characteristics of INOCA

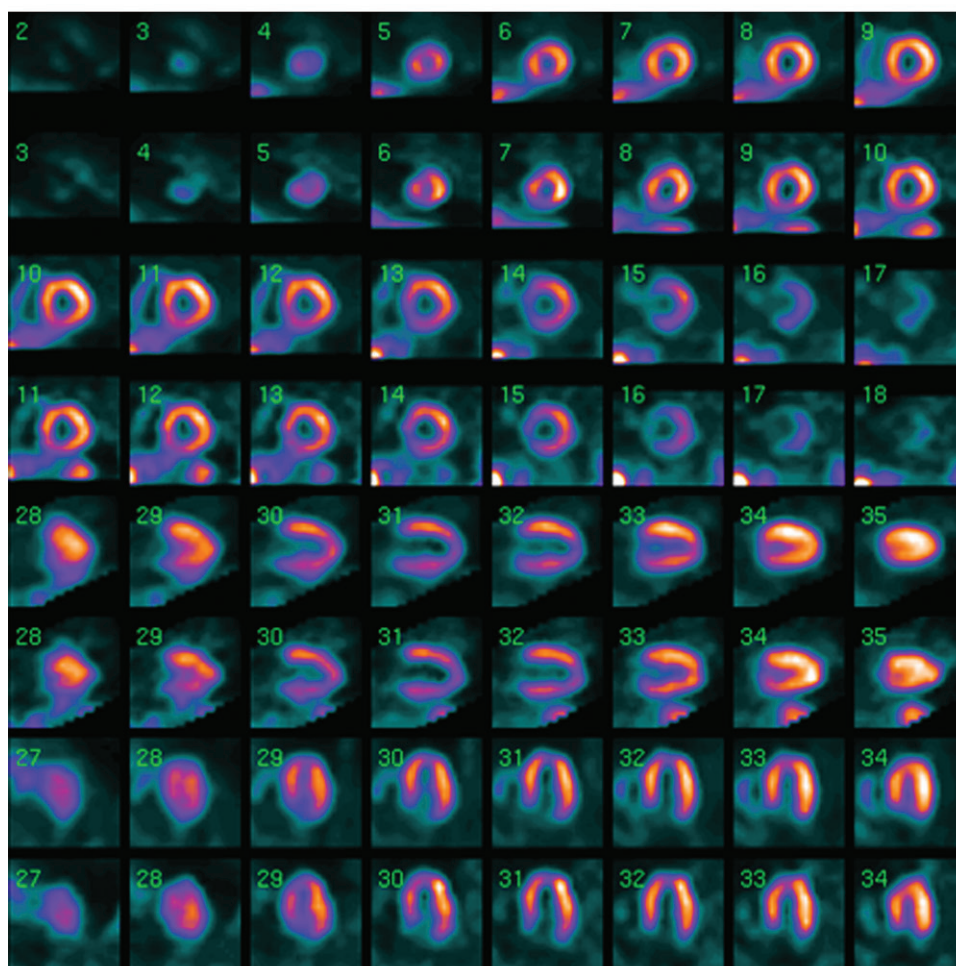
Comparisons of the clinical characteristics between participants defined as having normal or near-normal results (without $\geq 50\%$ stenosis and no ischemia) and INOCA, as well as between participants with obstructive stenosis and those with INOCA, are provided in Table E1 (online) (for CT angiography/CT perfusion) and Table E2 (online) (for ICA/SPECT). In Figure 4 (CT angiography/CT perfusion) the distribution of the three phenotypes is plotted in relation to the presence or absence of several clinical characteristics, and the proportion of INOCA is compared between exposure groups. For the combination of CT angiography/CT perfusion, no significant differences in the proportion of INOCA in relation to the presence or absence of clinical characteristics were found, although a twofold increase in presentation with INOCA (12%) was observed in women as compared with men (6%, *P* = .07). A trend toward younger age was also seen. On a vessel level (Fig E1 [online]), no difference in the proportion of patent arteries associated with perfusion defects was seen. Findings with ICA/SPECT are provided in Figures E2 and E3 (both online). The proportion of participants with INOCA was significantly different in relation to race and the presence of obesity.

Atherosclerotic Plaque Characteristics of INOCA

Comparison of atherosclerotic plaque characteristics (determined at CT angiography) between participants defined as having normal or near-normal findings (without $\geq 50\%$

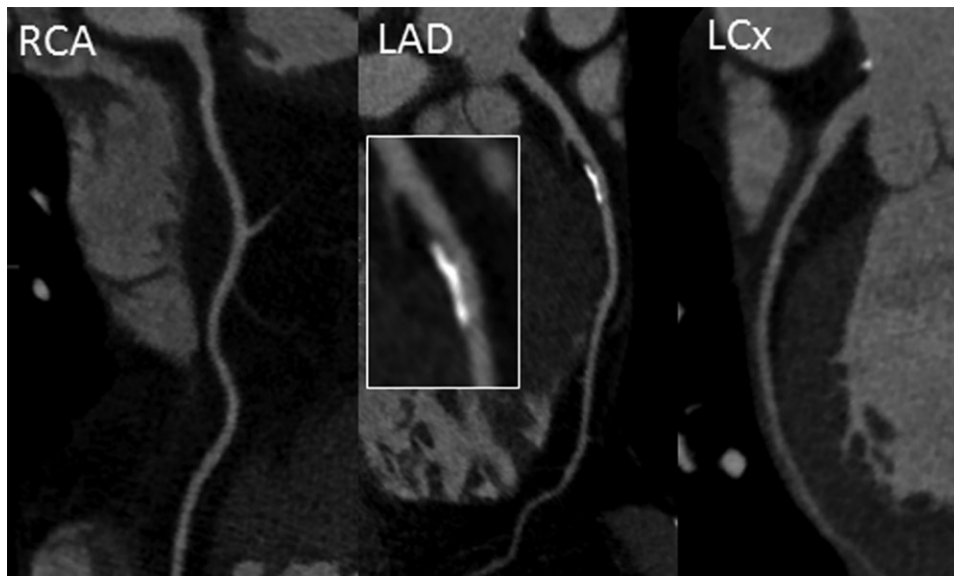


a.

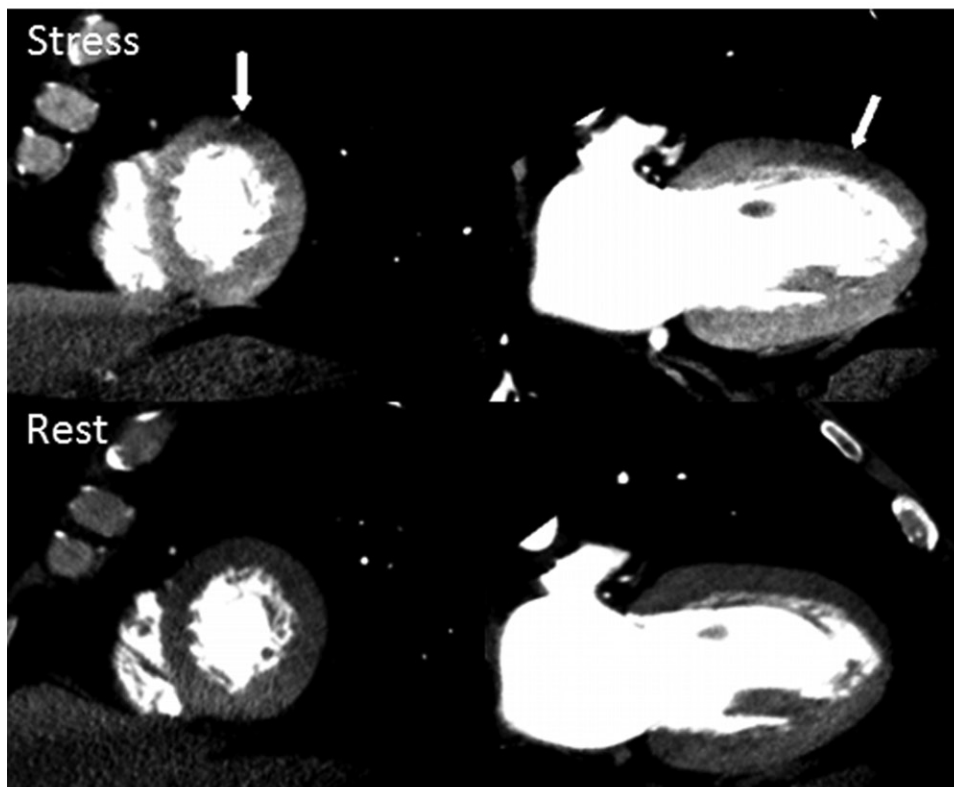


b.

Figure 2: Images in 64-year-old man who had typical angina at presentation, in combination with a high-risk profile (risk factors: hypertension, diabetes, former smoking, and a family history of coronary artery disease). **(a)** Diagnostic invasive coronary angiography showed completely normal coronary arteries and therefore could not provide an explanation for the patient's chest pain. LCA = left coronary artery, RCA = right coronary artery. **(b)** SPECT findings were also read as normal. (Fig 2 continues).



c.

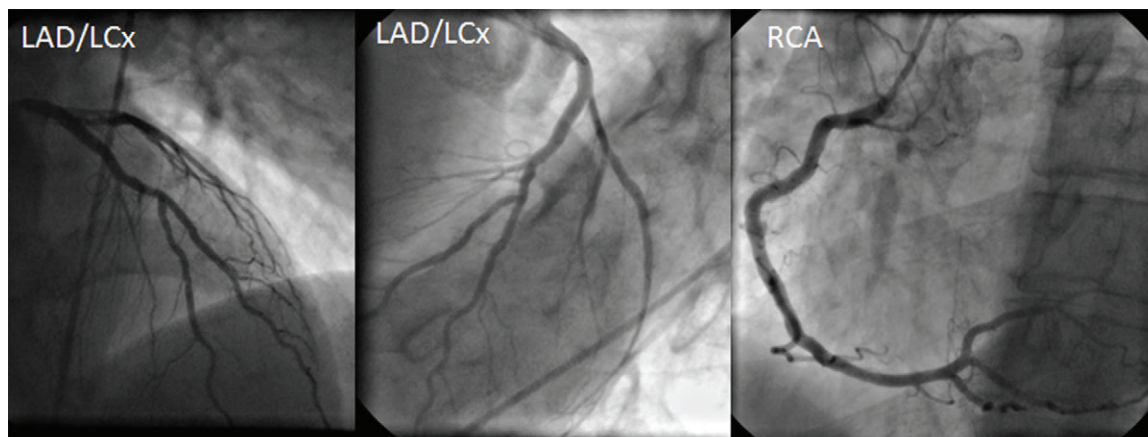


d.

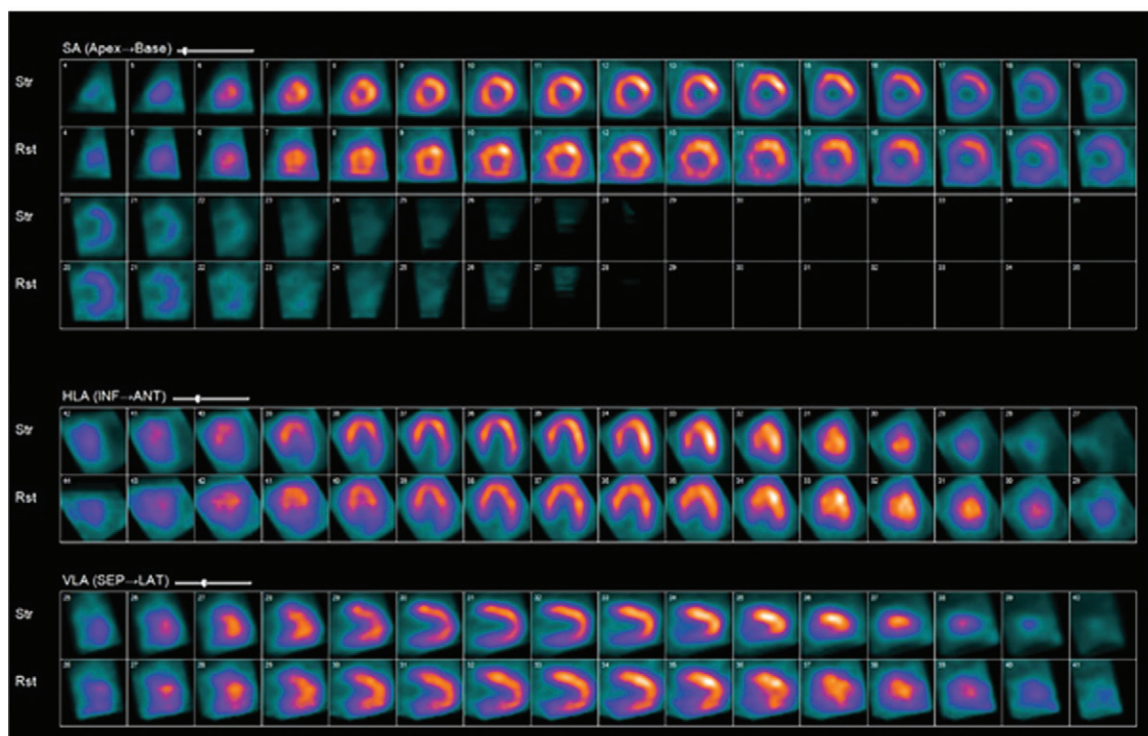
(**Figure 2** *continued*): The presence of significant stenoses was ruled out at (**c**) coronary CT angiography as well. LCx = left circumflex artery. However, a large, partially calcified plaque could be observed in the proximal left anterior descending (LAD) coronary artery with preserved lumen (see insert in **c**), indicating the presence of atherosclerosis without significant luminal narrowing. In addition, (**d**) CT perfusion during rest and stress showed a small reversible defect in the anterior wall (arrows), indicating the presence of ischemia. This case indicates how phenotyping with coronary CT angiography and myocardial CT perfusion allows noninvasive characterization of coronary artery disease by identifying nonobstructive atherosclerosis and ischemia.

stenosis and no ischemia) and INOCA, as well as between participants with obstructive stenosis and INOCA, are provided in Table 2 (CT angiography/CT perfusion) and Table 3 (ICA/SPECT) and are illustrated in Figure 5 (for CT angiography/CT perfusion) and Figure 6 (for ICA/SPECT).

Measures of atherosclerotic plaque burden were significantly higher in participants with obstructive stenosis than in participants with INOCA. With regard to the angiographic characteristics in participants with CT-defined INOCA versus those in participants without INOCA at CT angiography/



a.



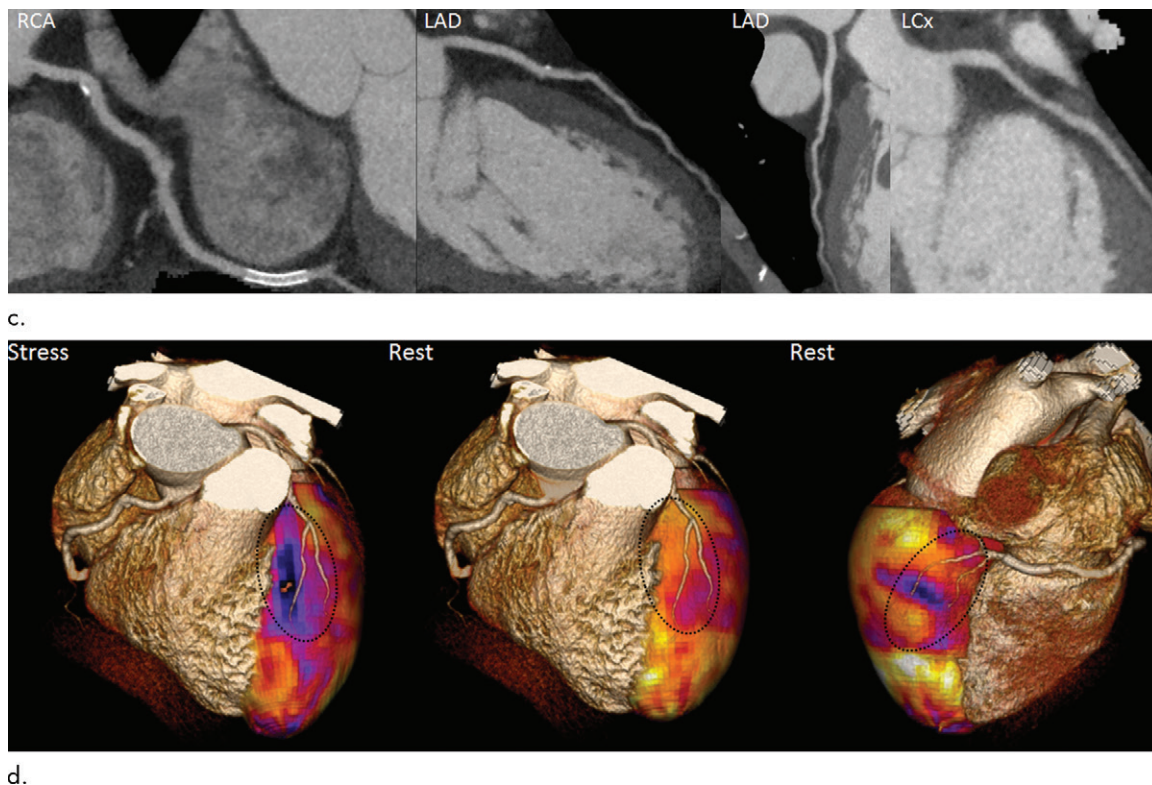
b.

Figure 3: Images in 53-year old man with atypical angina after previous inferior myocardial infarction followed by percutaneous coronary intervention with stent placement in the right coronary artery (RCA). Risk factors were hypertension and smoking. Normal coronary arteries were observed at **(a)** invasive coronary angiography, whereas **(b)** SPECT findings were positive. LAD = left anterior descending artery, LCx = left circumflex artery. (Fig 3 continues).

CT perfusion, total atherosclerotic burden and adverse plaque features such as positive remodeling and low-attenuation atheroma volume were significantly elevated; however, these differences were not as marked when compared with findings in participants with obstructive stenosis. Total atheroma volume was 118 mm³ (interquartile range [IQR], 62–166 mm³) in participants with INOCA versus 60 mm³ (IQR, 21–134 mm³) in participants with normal or near-normal findings ($P = .008$) and was 363 mm³ (IQR, 232–578 mm³) in participants with obstructive stenosis ($P < .0001$). Similarly, low-attenuation atheroma volume was 20 mm³ (IQR, 12–40 mm³) in participants with INOCA versus 10 mm³ (IQR, 3–26 mm³) in participants with normal or near-normal findings

($P = .007$) and was 63 mm³ (IQR, 31–107 mm³) in participants with obstructive disease ($P < .0001$). Positive remodeling was observed in one (1%) of 84 participants with normal or near-normal findings versus in four (13%) of 31 participants classified as having INOCA ($P = .006$). In 266 participants with obstructive disease, positive remodeling was observed in 135 (51%) of participants ($P < .0001$ vs INOCA).

At ICA/SPECT, measures of atherosclerotic plaque burden were also significantly higher in participants with obstructive stenosis than in participants with INOCA. No significant differences were seen in atherosclerotic plaque characteristics between participants with ICA/SPECT-defined INOCA and participants with normal or near-normal findings at ICA/SPECT.



d.

Figure 3: (continued). (c) Coronary CT angiography showed patency of the coronary stent and minimal plaque without any significant stenosis, in agreement with invasive coronary angiography findings. At (d) CT perfusion, a defect corresponding to the LAD territory could be observed during stress but not during rest, indicating ischemia. Also, a defect during rest in the RCA territory could be observed, corresponding to the previous myocardial infarction.

Outcome Data

A total of 379 participants (99.5%) had complete 2-year follow-up data. A major adverse cardiac event (49 late revascularizations [>30 days after index coronary catheterization], five myocardial infarctions, one cardiac death, nine hospitalizations for chest pain or congestive heart failure, and one arrhythmia) occurred in 51 (13.5%) of 379 participants. When the combination of CT angiography and CT perfusion was used to classify participants as having normal or near-normal findings, INOCA, or obstructive disease, events occurred in one (1%) of 84 participants, one (3%) of 30 participants, and 49 (18%) of 265 participants, respectively. For the combination of ICA and SPECT, these values were six (6%) of 105 participants, one (2%) of 45 participants, and 44 (19%) of 299 participants, respectively.

Discussion

With CT, ischemia and no obstructive stenosis (INOCA) can be accurately identified by using a single modality, but limited data are available. The primary aim of the current analysis was to describe the prevalence of INOCA defined by the combination of CT angiography with CT perfusion and its associated clinical and atherosclerotic plaque characteristics in the CORE320 study. In this high-risk symptomatic cohort referred for invasive coronary angiography (ICA), 27% of participants without significant stenosis at CT angiography showed downstream perfusion defects at CT perfusion,

resulting in an INOCA prevalence of 8%. Participants with CT-defined INOCA had greater total atheroma volume (118 vs 60 mm³, $P = .008$), more positive remodeling (13% vs 1%, $P = .006$), and greater low-attenuation atheroma volume (20 vs 10 mm³, $P = .007$) than participants without perfusion abnormalities at CT perfusion and no significant stenosis at CT angiography.

As a first step, we explored the relationship between the degree of stenosis and perfusion on a per-vessel basis. The overall shape of the curve resembled original experimental findings relating coronary stenosis to downstream myocardial ischemia. This pattern has been repeatedly observed since, with hyperemic flow abnormalities already occurring in the presence of limited luminal narrowing, and graded reduction in perfusion with more severe lesions (18). Data describing the relationship between degree of stenosis and perfusion at CT angiography/CT perfusion in humans are scarce. Interestingly, rates of normal perfusion in the presence of significant stenosis were lower for CT perfusion than for SPECT, reaffirming that SPECT may be less sensitive for detecting small reductions in blood flow in association with moderate stenoses (11,19). Although at present it is less commonly used, the combination of CT angiography and CT perfusion can potentially be a more sensitive and fully noninvasive method to assess CAD. Overall, the ICA/SPECT-based analysis produced comparable but less informative results in our study, likely because of the lower diagnostic power of SPECT (11,19).

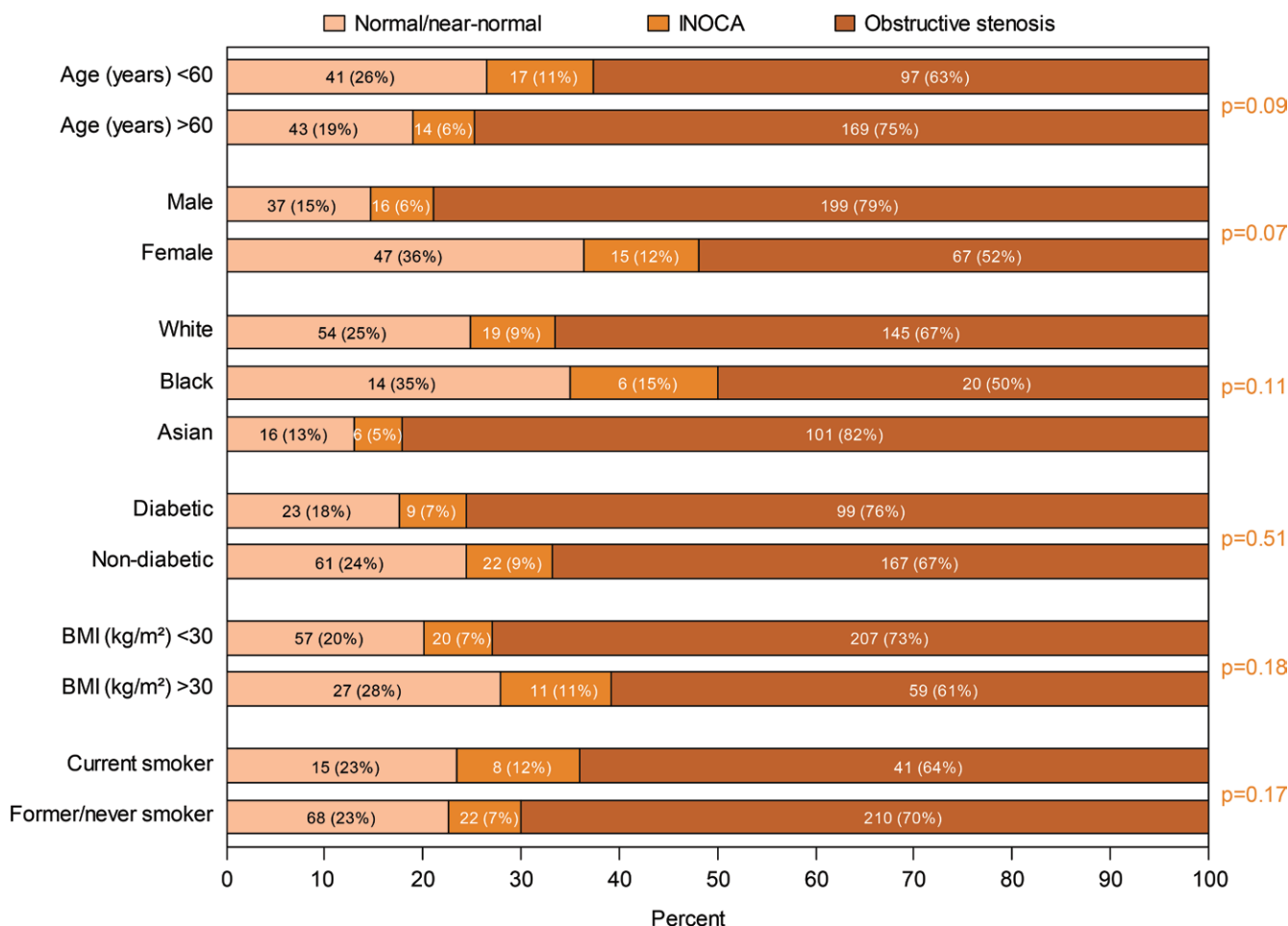


Figure 4: Bar graphs show percentages of participants whose findings were classified as either normal or near normal and who had ischemia and no obstructive stenosis (INOCA) at CT angiography/CT perfusion, grouped according to clinical characteristic. P values compare the proportion of INOCA between exposure groups. BMI = body mass index.

Depending on the combination used, abnormal perfusion was observed in 27%–30% of participants without obstructive stenosis, similar to findings in previous studies using other diagnostic methods (19). Accordingly, in this high-risk symptomatic cohort that was referred for ICA and in which obstructive disease was highly prevalent, CT angiography/CT perfusion- or ICA/SPECT-defined INOCA occurred in 8%–12% of participants. Female sex and diabetes have been typically linked to nonobstructive patterns of CAD and a higher frequency of INOCA. In CORE320, obstructive disease was commonly seen in men and was less frequently seen in women, in line with previous reports (1,20). However, in the absence of significant stenosis, not only were normal findings seen more often in women than in men but also a twofold increase in presentation with INOCA, which was of borderline significance. Indeed, the notion of a female-specific CAD phenotype that involves a larger contribution of diffuse nonobstructive atherosclerosis and microvascular disease rather than focal obstructive stenosis is gaining acceptance (21). This highlights the need for evaluation of both the anatomic and functional extent of disease in CAD. Interestingly, on a per-vessel basis, no differences between men and women were seen. The proportion of vessels

having no obstructive stenosis yet abnormal downstream perfusion was equal, suggesting that while men may more often present with obstructive disease in at least one artery, the pattern of a patent artery perfusing a compromised myocardial territory still frequently coexists. Such observations may explain recurrent angina despite successful revascularization and reaffirm the need for optimal medical therapy in symptomatic CAD. In addition, our study confirms previous findings that INOCA is associated with greater body mass index (22). Asian participants showed the highest rate of obstructive disease and were less often diagnosed with INOCA than white and black participants, consistent with findings in previous studies (20). Diabetes was not associated with INOCA in our study. This may have been due to the inclusion of sicker patients in CORE320 relative to other previous studies of patients with angina pectoris (1–4). At the same time, healthier participants with diabetes may have been selected because of the exclusion of participants with renal dysfunction, calculated creatinine clearance of less than 60 mL/min, and body mass index greater than 40 m/kg².

Data on atherosclerotic plaque and ischemia in patients without significant stenosis are mostly lacking and represent

Table 2: Atherosclerotic Plaque Characteristics at CT Angiography per CT Angiography/CT Perfusion-defined Phenotype

Characteristic	Normal/Near-Normal Findings (n = 84)	INOCA (n = 31)	P Value*	Obstructive Stenosis (n = 266)	P Value†
Agatston calcium score‡	1 (0–12)	12 (0–116)	.03	321 (111–800)	<.0001
Agatston calcium score category			.08		<.0001
0	42 (50)	11 (35)		11 (4)	
1–10	18 (21)	4 (13)		11 (4)	
11–100	16 (19)	8 (26)		38 (14)	
≥101	8 (10)	8 (26)		205 (77)	
Percentage atheroma volume‡	1.2 (0.3–2.8)	1.9 (1.2–3.4)	.04	7.7 (4.6–11.1)	<.0001
Total atheroma volume (mm ³)‡	60 (21–134)	118 (62–166)	.008	363 (232–578)	<.0001
Low-attenuation atheroma volume (mm ³)‡	10 (3–26)	20 (12–40)	.007	63 (31–107)	<.0001
Maximum lesion length (mm)‡	0 (0–4)	3 (0–10)	.02	16 (11–25)	<.0001
Positive remodeling	1 (1)	4 (13)	.006	135 (51)	<.0001
No. of vessels with any plaque			.86		<.0001
0	4 (5)	2 (6)		0	
1	5 (6)	3 (10)		1 (<1)	
2	7 (8)	3 (10)		4 (2)	
3	68 (81)	23 (74)		261 (98)	
No. of segments with any plaque‡	8 (6–12)	7 (4–9)	.04	13 (11–15)	<.0001

Note.—Unless otherwise specified, data are numbers of participants, with percentages in parentheses. INOCA = ischemia and no obstructive stenosis.

* For the comparison between normal findings and INOCA.

† For the comparison between obstructive stenosis and INOCA.

‡ Data are medians, with interquartile ranges in parentheses.

Table 3: Atherosclerotic Plaque Characteristics at CT Angiography per ICA/SPECT-defined Phenotype

Characteristic	Normal/Near-Normal Findings (n = 106)	INOCA (n = 45)	P Value*	Obstructive Stenosis (n = 230)	P Value†
Agatston calcium score‡	7 (0–123)	3 (0–116)	.55	353 (115–84)	<.0001
Agatston calcium score category			.57		<.0001
0	37 (35)	19 (42)		8 (3)	
1–10	17 (16)	6 (13)		10 (4)	
11–100	23 (22)	8 (18)		31 (14)	
≥101	29 (27)	12 (27)		180 (79)	
Percentage atheroma volume‡	1.7 (0.4–3.7)	2.1 (0.8–4.1)	.22	8.3 (5.0–11.3)	<.0001
Total atheroma volume (mm ³)‡	86 (22–190)	123 (50–193)	.20	376 (252–609)	<.0001
Low-attenuation atheroma volume (mm ³)‡	15 (4–39)	20 (10–39)	.18	68 (37–111)	<.0001
Maximum lesion length (mm)‡	0 (0–11)	1 (0–10)	.71	17 (12–25)	<.0001
Positive remodeling	13 (12)	6 (13)	.86	121 (53)	<.0001
No. of vessels with any plaque			.02		<.0001
0	1 (1)	5 (11)		0	
1	5 (5)	3 (7)		1 (<1)	
2	5 (5)	4 (9)		5 (2)	
3	95 (90)	33 (73)		224 (97)	
No. of segments with any plaque‡	10 (7–13)	9 (4–12)	.13	13 (11–15)	<.0001

Note.—Unless otherwise specified, data are numbers of participants, with percentages in parentheses. ICA = invasive coronary angiography, INOCA = ischemia and no obstructive stenosis.

* For the comparison between normal findings and INOCA.

† For the comparison between obstructive stenosis and INOCA.

‡ Data are medians, with interquartile ranges in parentheses.

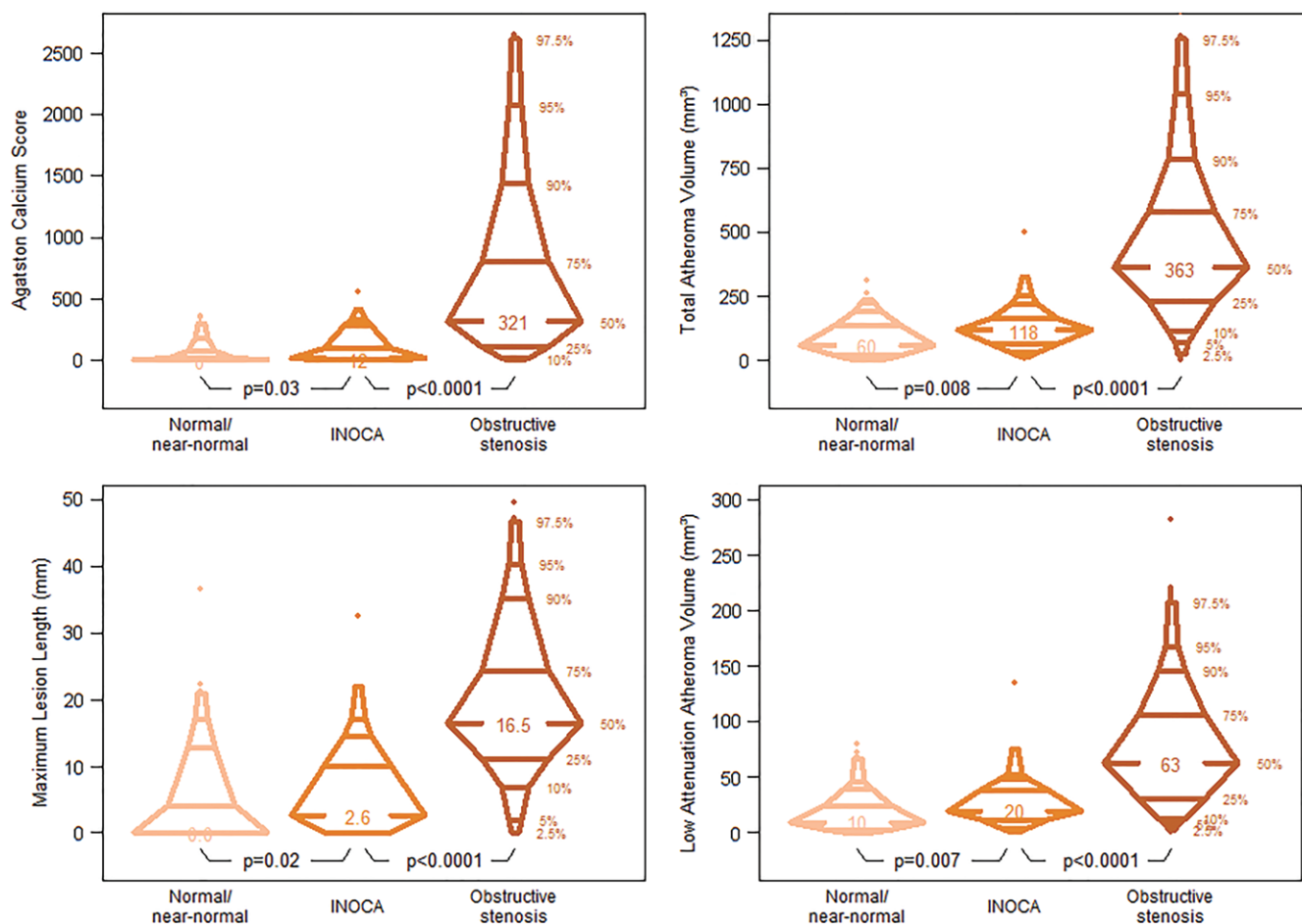


Figure 5: Percentile boxplots show Agatston calcium score, total atheroma volume, maximum lesion length, and low-attenuation atheroma volume according to CT angiography/CT perfusion phenotype. INOCA = ischemia and no obstructive stenosis.

an important knowledge gap, given that CT angiography is better positioned to characterize atherosclerotic burden and plaque composition than other noninvasive imaging modalities or ICA (3). Importantly, patients with abnormal perfusion at presentation despite completely normal coronary arteries (graded as having 0% luminal narrowing) were uncommon and constituted only 2% of the entire study cohort. Moreover, as compared with patients without obstructive stenosis (but not necessarily pristine vessels) and patients with normal perfusion, increased atherosclerotic plaque burden was seen in patients with INOCA. Significantly greater atheroma volume was observed, including greater low-attenuation atheroma volume and modest calcifications, while positive remodeling was also more prevalent (23). Coronary atherosclerosis with a high frequency of positive remodeling, larger plaque burden, and low-attenuation plaque has been previously proposed as a key mediator of INOCA (6,24–26), and the current observations support the relation between myocardial ischemia and systemic atherosclerosis, even in the absence of flow-limiting stenosis. Interestingly, however, this increase in plaque burden in patients with INOCA as compared with patients without perfusion abnormalities was modest in comparison to the increase observed in patients with obstructive lesions. Indeed, the pattern that emerges from this analysis is that the coronary

arteries of patients with INOCA appear to be at an earlier stage of plaque formation than those in patients with obstructive CAD-associated angina at presentation. Whether this observation reflects plaque formation induced by microvascular obstruction remains to be explored in future studies (27).

This study had limitations. Patient-level analyses were performed by using three phenotypes, while theoretically more detailed combinations between the degree of stenosis and type of macroatherosclerosis and perfusion are possible. In some patients, perfusion defects at either CT perfusion or SPECT may have been artifacts. The current study used static CT perfusion and SPECT to assess the presence or absence of regional perfusion abnormalities before and during stress-induced maximal vasodilation. In the absence of significant coronary obstruction, these abnormalities were interpreted as indirect measures of coronary microvascular dysfunction, which is clinically quantified by coronary flow reserve from PET. As a result, the number of patients with macro- or microvascular coronary dysfunction may have been underestimated. Evaluation of differences in myocardial tissue attenuation could serve as a surrogate marker for diffusely reduced myocardial blood flow (28), while quantification of coronary flow reserve may be possible using dynamic CT perfusion (29). Long or serial lesions of moderate severity

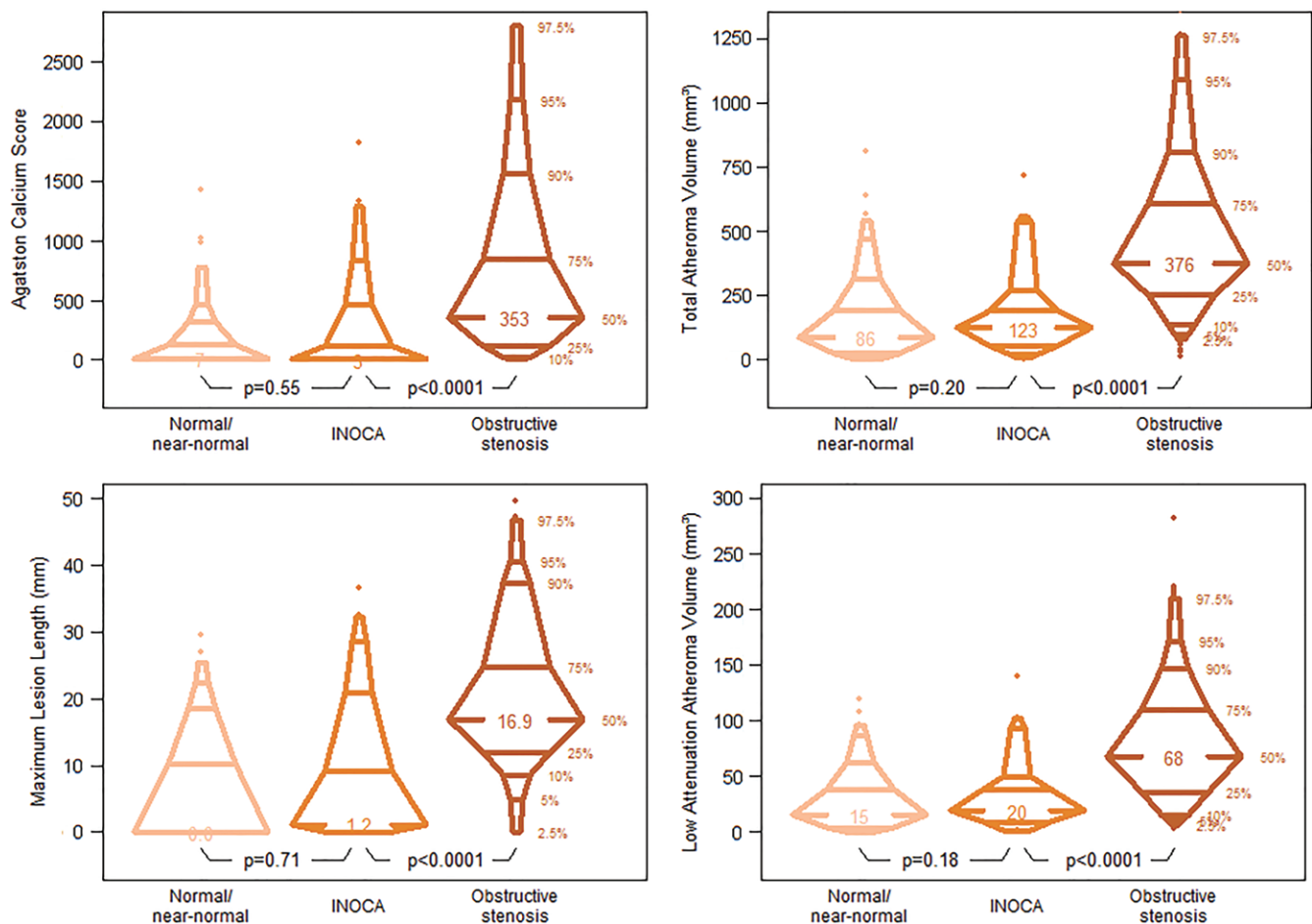


Figure 6: Percentile boxplots show Agatston calcium score, total atheroma volume, maximum lesion length, and low-attenuation atheroma volume according to invasive coronary angiography/SPECT phenotype. INOCA = ischemia and no obstructive stenosis.

may also contribute to abnormal perfusion in the absence of significant obstruction (30). Future studies in larger cohorts incorporating novel CT technologies may provide additional insight on the potential of CT to help further differentiate CAD phenotypes and guide treatment strategies.

In conclusion, despite the increasing awareness that ischemia may also occur in the absence of significant stenosis, patients with ischemia and no obstructive stenosis remain at present both underrecognized and undertreated because of the prevailing focus on obstructive stenosis as the hallmark of coronary artery disease (CAD). Noninvasive imagers could play a crucial role in recognizing phenotypes beyond obstructive CAD and guide referring physicians in treatment decisions. Evidence of atherosclerosis and ischemia in the absence of significant stenosis could provide an explanation for symptoms and trigger intensified medical therapy to treat angina and forestall further increase in atherosclerotic burden. The combination of CT angiography and CT perfusion provides a promising opportunity for such detailed and noninvasive CAD phenotyping.

Author contributions: Guarantor of integrity of entire study, J.A.C.L.; study concepts/study design or data acquisition or data analysis/interpretation, all authors; manuscript drafting or manuscript revision for important intellectual content, all authors; approval of final version of submitted manuscript, all authors; agrees to ensure any questions related to the work are appropriately resolved, all authors;

literature research, J.D.S., M.R.O., A.A., K.F.K., K.Y., M.F.D.C., J.A.C.L.; clinical studies, M.R.O., A.A., K.F.K., A.J.H.A.S., M.D., C.S., C.E.R., K.Y., C.C.; experimental studies, K.Y., J.A.C.L.; statistical analysis, M.B.M., M.R.O., K.Y., C.C.; and manuscript editing, J.D.S., M.B.M., M.R.O., A.A., K.F.K., A.J.H.A.S., M.D., C.E.R., K.Y., C.C., M.F.D.C., J.A.C.L.

Disclosures of Conflicts of Interest: J.D.S. Activities related to the present article: is an employee of Canon Medical Systems Europe. Activities not related to the present article: disclosed no relevant relationships. Other relationships: disclosed no relevant relationships. M.B.M. disclosed no relevant relationships. M.R.O. disclosed no relevant relationships. A.A. Activities related to the present article: institution has received grant support from Canon Medical Systems for acquisition of data. Activities not related to the present article: disclosed no relevant relationships. Other relationships: disclosed no relevant relationships. K.F.K. Activities related to the present article: institution has received unrestricted grant support from Canon Medical Systems; has received support for travel to meetings from Canon Medical Systems; is on the speakers bureau of Canon Medical Systems. Activities not related to the present article: disclosed no relevant relationships. Other relationships: disclosed no relevant relationships. A.J.H.A.S. Activities related to the present article: has received a consulting fee or honorarium from Canon Medical Systems. Activities not related to the present article: is a consultant for GE Healthcare. Other relationships: disclosed no relevant relationships. M.D. Activities related to the present article: disclosed no relevant relationships. Activities not related to the present article: is a consultant for Guerbet; has given cardiac CT courses in Berlin (www.ct-kurs.de); is Associate Editor for *Radiology* and *European Radiology*; has received research grants from the Heisenberg Program of the German Research Foundation for a professorship (DE 1361/14-1), the European Regional Development Fund, the joint program from the German Science Foundation and the German Federal Ministry of Education and Research for meta-analyses, the German Heart Foundation/German Foundation of Heart Research, GE Healthcare (Amersham), Bracco, Guerbet, and Toshiba Medical Systems; has received lecture fees from Toshiba Medical Systems, Guerbet, the Cardiac MR Academy Berlin, and Bayer (Schering-Berlex); has

received payment for manuscript preparation from the Lancet; holds a joint patent with Florian Michallek on dynamic perfusion analysis using fractal analysis (PCT/EP2016/071551). Other relationships: disclosed no relevant relationships. **C.S.** Activities related to the present article: is an employee of Canon Medical Systems. Activities not related to the present article: disclosed no relevant relationships. Other relationships: disclosed no relevant relationships. **C.E.R.** disclosed no relevant relationships. **K.Y.** disclosed no relevant relationships. **C.C.** Activities related to the present article: institution has received grant support from Toshiba Medical Systems. Activities not related to the present article: disclosed no relevant relationships. Other relationships: disclosed no relevant relationships. **M.F.D.C.** Activities related to the present article: disclosed no relevant relationships. Activities not related to the present article: is a member of the boards of Spectrum Dynamics and Gilead Sciences. Other relationships: disclosed no relevant relationships. **J.A.C.L.** Activities related to the present article: has received grant support from Canon Medical Systems. Activities not related to the present article: disclosed no relevant relationships. Other relationships: disclosed no relevant relationships.

References

- Jespersen L, Hvelplund A, Abildstrøm SZ, et al. Stable angina pectoris with no obstructive coronary artery disease is associated with increased risks of major adverse cardiovascular events. *Eur Heart J* 2012;33(6):734–744.
- Johnson BD, Shaw LJ, Pepine CJ, et al. Persistent chest pain predicts cardiovascular events in women without obstructive coronary artery disease: results from the NHLBI-sponsored Women's Ischemia Syndrome Evaluation (WISE) study. *Eur Heart J* 2006;27(12):1408–1415.
- Pepine CJ, Ferdinand KC, Shaw LJ, et al. Emergence of Nonobstructive Coronary Artery Disease: A Woman's Problem and Need for Change in Definition on Angiography. *J Am Coll Cardiol* 2015;66(17):1918–1933.
- Min JK, Dunning A, Lin FY, et al. Age- and sex-related differences in all-cause mortality risk based on coronary computed tomography angiography findings results from the International Multicenter CONFIRM (Coronary CT Angiography Evaluation for Clinical Outcomes: An International Multicenter Registry) of 23,854 patients without known coronary artery disease. *J Am Coll Cardiol* 2011;58(8):849–860.
- Niccoli G, Montone RA, Lanza GA, Crea F. Angina after percutaneous coronary intervention: The need for precision medicine. *Int J Cardiol* 2017;248:14–19.
- Bairey Merz CN, Pepine CJ, Walsh MN, Fleg JL. Ischemia and No Obstructive Coronary Artery Disease (INOCA): Developing Evidence-Based Therapies and Research Agenda for the Next Decade. *Circulation* 2017;135(11):1075–1092.
- Reis SE, Holubkov R, Conrad Smith AJ, et al. Coronary microvascular dysfunction is highly prevalent in women with chest pain in the absence of coronary artery disease: results from the NHLBI WISE study. *Am Heart J* 2001;141(5):735–741.
- Schuijff JD, Ko BS, Di Carli MF, et al. Fractional flow reserve and myocardial perfusion by computed tomography: a guide to clinical application. *Eur Heart J Cardiovasc Imaging* 2018;19(2):127–135.
- Rochitte CE, George RT, Chen MY, et al. Computed tomography angiography and perfusion to assess coronary artery stenosis causing perfusion defects by single photon emission computed tomography: the CORE320 study. *Eur Heart J* 2014;35(17):1120–1130.
- Takx RA, Blomberg BA, El Aidi H, et al. Diagnostic accuracy of stress myocardial perfusion imaging compared to invasive coronary angiography with fractional flow reserve meta-analysis. *Circ Cardiovasc Imaging* 2015;8(1).
- George RT, Mehra VC, Chen MY, et al. Myocardial CT perfusion imaging and SPECT for the diagnosis of coronary artery disease: a head-to-head comparison from the CORE320 multicenter diagnostic performance study. *Radiology* 2014;272(2):407–416.
- Vavere AL, Simon GG, George RT, et al. Diagnostic performance of combined noninvasive coronary angiography and myocardial perfusion imaging using 320 row detector computed tomography: design and implementation of the CORE320 multicenter, multinational diagnostic study. *J Cardiovasc Comput Tomogr* 2011;5(6):370–381.
- Cerci RJ, Arbab-Zadeh A, George RT, et al. Aligning coronary anatomy and myocardial perfusion territories: an algorithm for the CORE320 multicenter study. *Circ Cardiovasc Imaging* 2012;5(5):587–595.
- George RT, Arbab-Zadeh A, Cerci RJ, et al. Diagnostic performance of combined noninvasive coronary angiography and myocardial perfusion imaging using 320-MDCT: the CT angiography and perfusion methods of the CORE320 multicenter multinational diagnostic study. *AJR Am J Roentgenol* 2011;197(4):829–837.
- Chen MY, Rochitte CE, Arbab-Zadeh A, et al. Prognostic Value of Combined CT Angiography and Myocardial Perfusion Imaging versus Invasive Coronary Angiography and Nuclear Stress Perfusion Imaging in the Prediction of Major Adverse Cardiovascular Events: The CORE320 Multicenter Study. *Radiology* 2017;284(1):55–65.
- Bakhshi H, Meyghani Z, Kishi S, et al. Comparative Effectiveness of CT-Derived Atherosclerotic Plaque Metrics for Predicting Myocardial Ischemia. *JACC Cardiovasc Imaging* 2019;12(7 Pt 2):1367–1376.
- Kishi S, Magalhaes TA, George RT, et al. Relationship of left ventricular mass to coronary atherosclerosis and myocardial ischaemia: the CORE320 multicenter study. *Eur Heart J Cardiovasc Imaging* 2015;16(2):166–176.
- Gould KL, Lipscomb K, Hamilton GW. Physiologic basis for assessing critical coronary stenosis. Instantaneous flow response and regional distribution during coronary hyperemia as measures of coronary flow reserve. *Am J Cardiol* 1974;33(1):87–94.
- Danad I, Raijmakers PG, Driessen RS, et al. Comparison of Coronary CT Angiography, SPECT, PET, and Hybrid Imaging for Diagnosis of Ischemic Heart Disease Determined by Fractional Flow Reserve. *JAMA Cardiol* 2017;2(10):1100–1107.
- Shaw LJ, Shaw RE, Merz CN, et al. Impact of ethnicity and gender differences on angiographic coronary artery disease prevalence and in-hospital mortality in the American College of Cardiology-National Cardiovascular Data Registry. *Circulation* 2008;117(14):1787–1801.
- Baldassarre LA, Raman SV, Min JK, et al. Noninvasive Imaging to Evaluate Women With Stable Ischemic Heart Disease. *JACC Cardiovasc Imaging* 2016;9(4):421–435.
- Bajaj NS, Osborne MT, Gupta A, et al. Coronary Microvascular Dysfunction and Cardiovascular Risk in Obese Patients. *J Am Coll Cardiol* 2018;72(7):707–717.
- Park HB, Heo R, Ó Hartaigh B, et al. Atherosclerotic plaque characteristics by CT angiography identify coronary lesions that cause ischemia: a direct comparison to fractional flow reserve. *JACC Cardiovasc Imaging* 2015;8(1):1–10.
- Khuddus MA, Pepine CJ, Handberg EM, et al. An intravascular ultrasound analysis in women experiencing chest pain in the absence of obstructive coronary artery disease: a substudy from the National Heart, Lung and Blood Institute-Sponsored Women's Ischemia Syndrome Evaluation (WISE). *J Interv Cardiol* 2010;23(6):511–519.
- Stenström I, Maaniitty T, Uusitalo V, et al. Frequency and angiographic characteristics of coronary microvascular dysfunction in stable angina: a hybrid imaging study. *Eur Heart J Cardiovasc Imaging* 2017;18(11):1206–1213.
- Imai S, Kondo T, Stone GW, et al. Abnormal Fractional Flow Reserve in Nonobstructive Coronary Artery Disease. *Circ Cardiovasc Interv* 2019;12(2):e006961.
- Siasos G, Sara JD, Zaromytidou M, et al. Local Low Shear Stress and Endothelial Dysfunction in Patients With Nonobstructive Coronary Atherosclerosis. *J Am Coll Cardiol* 2018;71(19):2092–2102.
- Kühl JT, George RT, Mehra VC, et al. Endocardial-epicardial distribution of myocardial perfusion reserve assessed by multidetector computed tomography in symptomatic patients without significant coronary artery disease: insights from the CORE320 multicenter study. *Eur Heart J Cardiovasc Imaging* 2016;17(7):779–787.
- Kikuchi Y, Oyama-Manabe N, Naya M, et al. Quantification of myocardial blood flow using dynamic 320-row multi-detector CT as compared with ¹⁵O-H₂O PET. *Eur Radiol* 2014;24(7):1547–1556.
- G Toth G, Wijns W. Circulus vitiosus of validation. *Eur Heart J* 2018;39(46):4082–4085.