



**Universiteit
Leiden**
The Netherlands

Transcatheter aortic valve replacement role of multimodality imaging in common and complex clinical scenarios

Bax, J.J.; Delgado, V.; Hahn, R.T.; Leipsic, J.; Min, J.K.; Grayburn, P.; ... ; Windecker, S.

Citation

Bax, J. J., Delgado, V., Hahn, R. T., Leipsic, J., Min, J. K., Grayburn, P., ... Windecker, S. (2020). Transcatheter aortic valve replacement role of multimodality imaging in common and complex clinical scenarios. *Jacc: Cardiovascular Imaging*, 13(1), 124-139.
doi:10.1016/j.jcmg.2018.10.037

Version: Publisher's Version
License: [Creative Commons CC BY 4.0 license](https://creativecommons.org/licenses/by/4.0/)
Downloaded from: <https://hdl.handle.net/1887/3232681>

Note: To cite this publication please use the final published version (if applicable).

iREVIEW

STATE-OF-THE-ART REVIEW

Transcatheter Aortic Valve Replacement Role of Multimodality Imaging in Common and Complex Clinical Scenarios



Jeroen J. Bax, MD, PhD,^a Victoria Delgado, MD, PhD,^a Rebecca T. Hahn, MD,^b Jonathon Leipsic, MD, PhD,^c
James K. Min, MD,^d Paul Grayburn, MD,^e Lars Sondergaard, MD, DMSc,^f Sung-Han Yoon, MD,^g
Stephan Windecker, MD^h

JACC: CARDIOVASCULAR IMAGING CME/MOC/ECME

CME/MOC/ECME Editor: Ragavendra R. Baliga, MD

This article has been selected as this issue's CME/MOC/ECME activity, available online at <http://www.acc.org/jacc-journals-cme> by selecting the JACC Journals CME/MOC/ECME tab.

Accreditation and Designation Statement

The American College of Cardiology Foundation (ACCF) is accredited by the Accreditation Council for Continuing Medical Education (ACCME) to provide continuing medical education for physicians.

The ACCF designates this Journal-based CME/MOC/ECME activity for a maximum of 1 *AMA PRA Category 1 Credit(s)*TM. Physicians should only claim credit commensurate with the extent of their participation in the activity. Successful completion of this CME activity, which includes participation in the evaluation component, enables the participant to earn up to 1 Medical Knowledge MOC point in the American Board of Internal Medicine's (ABIM) Maintenance of Certification (MOC) program. Participants will earn MOC points equivalent to the amount of CME credits claimed for the activity. It is the CME activity provider's responsibility to submit participant completion information to ACCME for the purpose of granting ABIM MOC credit.

Transcatheter Aortic Valve Replacement: Role of Multimodality Imaging in Common and Complex Clinical Scenarios will be accredited by the European Board for Accreditation in Cardiology (EBAC) for 1 hour of External CME credits. Each participant should claim only those hours of credit that have actually been spent in the educational activity. The Accreditation Council for Continuing Medical Education (ACCME) and the European Board for Accreditation in Cardiology (EBAC) have recognized each other's accreditation systems as substantially equivalent. Apply for credit through the post-course evaluation. While offering the credits noted above, this program is not intended to provide extensive training or certification in the field.

Method of Participation and Receipt of CME/MOC/ECME Certificate

To obtain credit for this CME/MOC/ECME activity, you must:

1. Be an ACC member or JACC: *Cardiovascular Imaging* subscriber.
2. Carefully read the CME/MOC/ECME-designated article available online and in this issue of the journal.
3. Answer the post-test questions. A passing score of at least 70% must be achieved to obtain credit.
4. Complete a brief evaluation.
5. Claim your CME/MOC/ECME credit and receive your certificate electronically by following the instructions given at the conclusion of the activity.

CME/MOC/ECME Objective for This Article: Upon completion, the reader should be able to: 1. Identify which patients with severe mitral regurgitation can be candidates for each of the currently available transcatheter devices for mitral valve repair (targeting leaflets of mitral annulus) or replacement. 2. Select the most appropriate imaging techniques to plan and guide the transcatheter mitral valve/replacement procedures. 3. Discuss the important questions that need to be addressed when evaluating a patient with severe mitral regurgitation who may be referred for transcatheter mitral valve intervention.

CME/MOC/ECME Editor Disclosure: JACC: *Cardiovascular Imaging* CME/MOC/ECME Editor Ragavendra R. Baliga, MD, has reported that he has no relationships to disclose.

Author Disclosures: The Department of Cardiology, Leiden University Medical Center has received unrestricted research grants from Biotronik, Medtronic, Boston Scientific, GE Healthcare, and Edwards Lifesciences. Dr. Bax has received speaker fees from Abbott Vascular and Boehringer Ingelheim. Dr. Delgado has received speaker fees from Abbott Vascular. Dr. Leipsic has received institutional support through core laboratory services for Edwards Lifesciences, Medtronic, Abbott, and Neovasc; and serves as a consultant for Circle CVI and Heartflow. Dr. Windecker has received research and educational grants to the institution from Abbott, Amgen, Bayer, Bristol-Myers Squibb, Biotronik, Boston Scientific, CSL, Edwards, Medtronic, Sinomed, and Polares. Dr. Hahn has received speaker fees from Boston Scientific Corporation and Baylis Medical; consulting for Abbott Structural, Edwards Lifesciences, Gore&Associates, Medtronic, Navigate, Philips Healthcare, and Siemens Healthcare; non-financial support from 3mensio and GE Healthcare; is Chief Scientific Officer for the Echocardiography Core Laboratory at the Cardiovascular Research Foundation for multiple industry-sponsored trials, for which she receives no direct industry compensation. Dr. Sondergaard has received consultant fees and institutional research grants from Abbott, Boston Scientific, Edwards Lifesciences, and Medtronic. Dr. Min is on the Scientific Advisory Board of Arineta; has ownership in MDDX; and has a research agreement with GE Healthcare. Dr. Grayburn has received research grants Boston Scientific and under Core Lab contracts, Valtech Cardio is now Edwards Lifesciences.

Medium of Participation: Online (article and quiz).

CME/MOC/ECME Term of Approval

Issue Date: January 2020

Expiration Date: December 2020

Transcatheter Aortic Valve Replacement

Role of Multimodality Imaging in Common and Complex Clinical Scenarios

Jeroen J. Bax, MD, PhD,^a Victoria Delgado, MD, PhD,^a Rebecca T. Hahn, MD,^b Jonathon Leipsic, MD, PhD,^c James K. Min, MD,^d Paul Grayburn, MD,^e Lars Sondergaard, MD, DMSc,^f Sung-Han Yoon, MD,^g Stephan Windecker, MD^h

ABSTRACT

Transcatheter aortic valve replacement (TAVR) is an established therapy for patients with symptomatic severe aortic stenosis. Technological advances and the learning curve have resulted in better procedural results in terms of hemodynamic valve performance and intermediate-term clinical outcomes. The integration of anatomical and functional information provided by multimodality imaging has improved size selection of TAVR prostheses, permitted better patient selection, and provided new insights in the performance of the TAVR prostheses at follow-up. Furthermore, the field of TAVR continues to develop and expand the technique to younger patients with lower risk on the one hand, and more complex clinical scenarios, on the other hand, such as degenerated aortic bioprostheses, bicuspid aortic valves, or pure native aortic regurgitation. The present review article summarizes how multimodality imaging can be integrated in TAVR in clinical (sometimes complex) scenarios that have not been included in the landmark randomized clinical trials. (J Am Coll Cardiol Img 2020;13:124-39) © 2020 by the American College of Cardiology Foundation.

Trascatheter aortic valve replacement (TAVR) is an established therapy for patients with symptomatic severe aortic stenosis (AS). Randomized controlled trials have demonstrated the survival benefit of TAVR over medical treatment and balloon valvuloplasty in inoperable patients (1), as well as the non-inferiority of TAVR compared with surgical aortic valve replacement (SAVR) among patients with low, intermediate, and high surgical risk (2-5). Technological advances and the learning curve have resulted in better procedural results in terms of hemodynamic valve performance and intermediate-term outcomes, extending this therapy to patients with degenerated surgical aortic, bicuspid aortic valve anatomy, or native aortic regurgitation (6-9). The integration of anatomical and functional information provided using multimodality imaging has improved patient selection, selection of type

From the ^aDepartment of Cardiology, Leiden University Medical Center, Leiden, the Netherlands; ^bColumbia University Medical Center, NY Presbyterian Hospital, New York, New York; ^cDepartment of Radiology and Division of Cardiology, Centre for Heart Valve Innovation, St Paul's Hospital, University of British Columbia, Vancouver, Canada; ^dDepartment of Radiology, The New York-Presbyterian Hospital and the Weill Cornell Medical College, New York, New York; ^eBaylor Heart and Vascular Institute and the Division of Cardiology, Department of Internal Medicine, Baylor University Medical Center, Dallas, Texas; ^fThe Heart Center, Rigshospitalet, University of Copenhagen, Denmark; ^gDepartment of Interventional Cardiology, Cedars-Sinai Heart Institute, Los Angeles, California; and the ^hDepartment of Cardiology, Bern University Hospital, Inselspital, University of Bern, Bern, Switzerland. The Department of Cardiology, Leiden University Medical Center has received unrestricted research grants from Biotronik, Medtronic, Boston Scientific, GE Healthcare, and Edwards Lifesciences. Dr. Bax has received speaker fees from Abbott Vascular and Boehringer Ingelheim. Dr. Delgado has received speaker fees from Abbott Vascular. Dr. Leipsic has received institutional support through core laboratory services for Edwards Lifesciences, Medtronic, Abbott, and Neovasc; and serves as a consultant for Circle CVI and Heartflow. Dr. Windecker has received research and educational grants to the institution from Abbott, Amgen, Bayer, Bristol-Myers Squibb, Biotronik, Boston Scientific, CSL, Edwards, Medtronic, Sinomed, and Polares. Dr. Hahn has received speaker fees from Boston Scientific Corporation and Baylis Medical; consulting for Abbott Structural, Edwards Lifesciences, Gore&Associates, Medtronic, Navigate, Philips Healthcare, and Siemens Healthcare; non-financial support from 3mensio and GE Healthcare; is Chief Scientific Officer for the Echocardiography Core Laboratory at the Cardiovascular Research Foundation for multiple industry-sponsored trials, for which she receives no direct industry compensation. Dr. Sondergaard has received consultant fees and institutional research grants from Abbott, Boston Scientific, Edwards Lifesciences, and Medtronic. Dr. Min is on the Scientific Advisory Board of Arineta; has ownership in MDDX; and has a research agreement with GE Healthcare. Dr. Grayburn has received research grants Boston Scientific and under Core Lab contracts, Valtech Cardio is now Edwards Lifesciences. Harvey Hecht, MD, was Guest Editor on this paper.

Manuscript received December 23, 2017; revised manuscript received October 15, 2018, accepted October 18, 2018.

ABBREVIATIONS AND ACRONYMS

- 2/3D** = 2-/3-dimensional
- AS** = aortic stenosis
- CMR** = cardiac magnetic resonance
- CT** = computed tomography
- EOA** = effective orifice area
- EROA** = effective regurgitant orifice area
- LV** = left ventricle
- LVEF** = left ventricular ejection fraction
- LVOT** = left ventricular outflow tract
- MDCT** = multi-detector row computed tomography
- OR** = odds ratio
- PPM** = prosthesis-patient mismatch
- SAVR** = surgical aortic valve replacement
- STS/ACC TVT** = Society of Thoracic Surgeons/American College of Cardiology Transcatheter Valve Therapy
- TAVR** = transcatheter aortic valve replacement
- TEE** = transesophageal echocardiography
- THV** = transcatheter heart valve
- VIV** = valve-in-valve

and size of transcatheter heart valve prostheses, and planning of the procedure (predicting fluoroscopic angulation with computed tomography). However, there remain areas of uncertainties in diagnosis and newer indications are considered. The present review article discusses how multimodality imaging can be integrated in clinical scenarios that have not been included in landmark randomized clinical trials.

AREAS OF UNCERTAINTY IN TAVR FOR AS

CURRENT STATUS OF ANNULAR SIZING.

Aortic annulus sizing as well as characterization of the peri-annular region (left ventricular outflow tract [LVOT] and proximal aortic root) are essential steps in TAVR to minimize or avoid complications (10-12). Multi-detector row computed tomography (MDCT) has become the standard method for pre-procedural evaluation of the aortic annulus. However, in patients in whom the use of iodinated contrast should be avoided or when MDCT data acquisition does not allow accurate evaluation of the aortic annulus, 3-dimensional (3D) transesophageal echocardiography (TEE) is an accurate alternative (13).

The measured aortic annular plane is defined as the plane transecting the lowest hinge-points of the 3 aortic cusps. The annulus is thus “virtual” because >50% of the circumference of this plane is composed of the fibrous trigones between the cusps with no distinct anatomical or histological marker (14). In the majority of patients, the annulus is larger in systole and annular measurements for

transcatheter heart valve sizing are typically derived from a mid-systolic image (15). In fact, the systematically smaller annular area and perimeter measurement in diastole would undersize the prosthesis in nearly 50% of patients (15). Each type of commercially available transcatheter heart valve currently has different sizing algorithms using different measurements of the annular plane (Table 1) (16,17). Importantly the algorithms continue to use oversizing to ensure complete coverage of the aortic annulus.

When using MDCT or 3D TEE, the multiplanar reformation planes are oriented to create a double-oblique plane containing all 3 hinge points of the coronary cusps (Figure 1) (18). Vendor-specific software for MDCT and TEE data has facilitated assessment of the aortic annulus dimensions by setting 3 markers at the hinge points of the aortic cusps that define the aortic annulus plane (19). These software packages automate many of the steps needed to obtain the double-oblique plane and can reduce inter-observer variability of the aortic annulus measurements (20).

Assessment of calcifications of the landing zone (spanning from the LVOT to the aortic valve) is also important to predict the risk of paravalvular regurgitation and annulus rupture (10,11). Technological developments of current transcatheter heart valve (THV) generations that ensure accurate sealing of the aortic annulus despite the calcifications of the landing zone have significantly reduced the rate of paravalvular regurgitation (21). However, it is important to integrate this information if significant oversizing is anticipated. Moderate and severe LVOT calcification and ≥20% prosthesis oversizing have been associated with aortic root rupture (10).

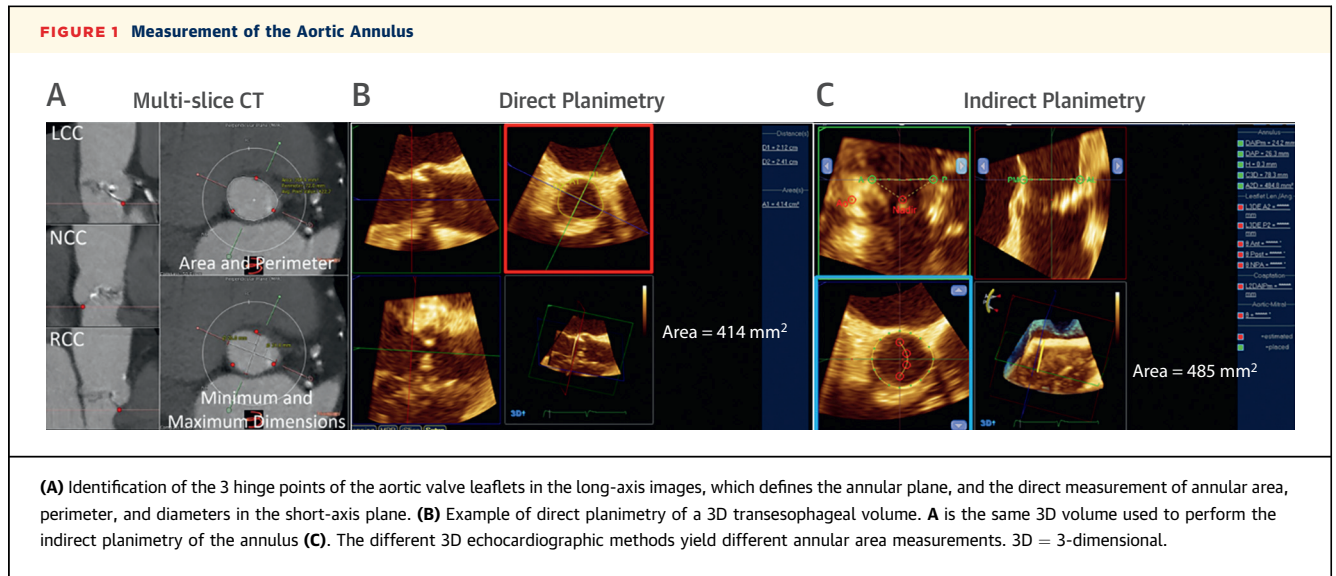
PATIENT PROSTHESIS MISMATCH.

Prosthesis-patient mismatch (PPM) is a limitation of both SAVR and TAVR. Based on echocardiographic assessment, PPM is defined as an effective orifice area (EOA) of the surgical valve or transcatheter heart valve indexed to body surface area ≤0.85 cm²/m² and it can be further graded as moderate PPM when the indexed EOA is between 0.65 cm²/m² and 0.85 cm²/m² and severe PPM when the indexed EOA is <0.65 cm²/m² (22). The incidence of PPM after TAVR ranges between 18% and 35% and is significantly lower compared with SAVR (20% for stentless bioprostheses, and up to 60% for mechanical prostheses) (23). The clinical importance of PPM in the setting of TAVR remains controversial. In the PARTNER I (Placement of Aortic Transcatheter Valves) trial, among patients at high surgical risk, PPM after TAVR or SAVR was associated with poor clinical outcome after adjusting for the presence of paravalvular regurgitation (24).

TABLE 1 Sizing Algorithms for the Current Commercially Available Balloon-Expandable and Self-Expanding Transcatheter Heart Valves

Annular Dimension	SAPIEN Valve Size			
	20 mm	23 mm	26 mm	29 mm
Nominal area (mm ²)	328	406	518	661
Annular range for S3 (mm ²)	273-345	338-430	430-546	540-683
	CoreValve Transcatheter Valve Size			
	23 mm	26 mm	29 mm	31 mm
Nominal perimeter (mm)	72.24	81.7	91.1	94.5
Perimeter range (mm)	56.5-62.8	62.8-72.3	72.3-84.8	81.7-91.1

The nominal areas (in mm²) and perimeter (in mm) are listed, as well as the appropriate ranges of annular measurements for each valve size. Note that a -5 to +20% oversizing may be used with the balloon-expandable valve and a perimeter oversizing of 7% to 30% for the self-expanding valve. (Note: A negative oversizing equates to undersizing of the valve, in which the native annulus can be up to 5% larger than the nominal area of the transcatheter valve.)



Conversely, in the PARTNER II trial, PPM was less frequently encountered (due to the greater valve areas that were achieved) and was not associated with adverse prognosis (3).

The reasons for the disparities in the incidence of PPM have been attributed to the methodology used to estimate the indexed EOA, type of prosthesis, and differences in patient populations (23). Compared with the geometric orifice area (obtained from the internal valve diameter provided by the manufacturer) and indexed EOA obtained from some commercially available charts based on in vitro or echocardiographic data, the projected indexed EOA derived from reference values published in the literature is the best method to predict the occurrence of PPM (25). Interestingly, when MDCT measurements of the cross-sectional area of the LVOT are integrated into the continuity equation, the frequency of severe and moderate PPM reduces from 36% and 9% to 18% and 6%, respectively (26). These findings suggest that the echocardiographic measurements of the LVOT may introduce a systematic error in the calculation of the indexed EOA that results in increased rates of PPM compared with MDCT-derived LVOT area. Of note, the appropriate cut-off values to define PPM based on MDCT calculations have not been established.

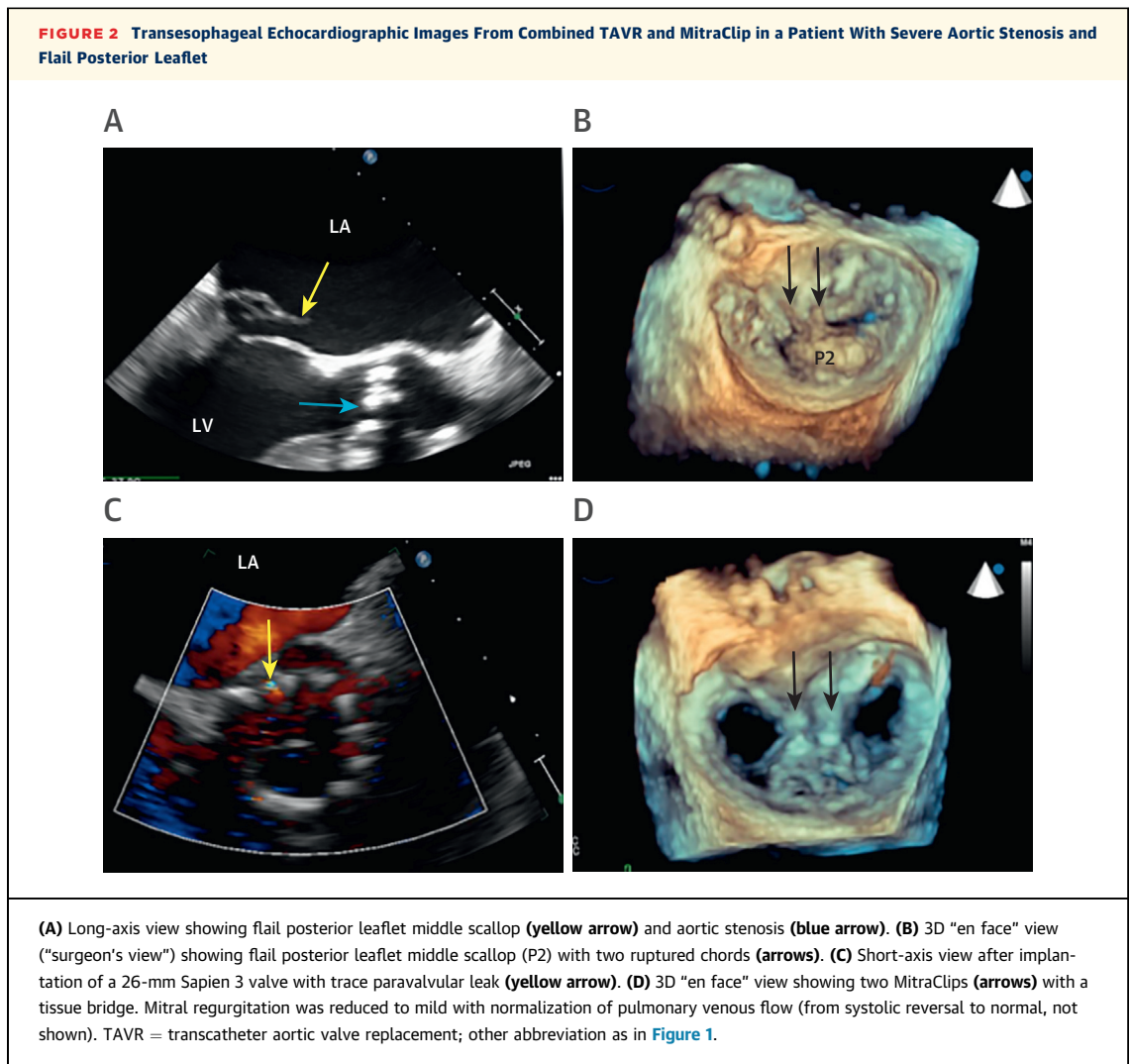
LOW-FLOW LOW-GRADIENT AS. Approximately 30% of patients with symptomatic severe AS (defined by an aortic valve area $<1 \text{ cm}^2$ or $\leq 0.6 \text{ cm}^2/\text{m}^2$) treated with TAVR have a low mean gradient ($<40 \text{ mm Hg}$) and low flow (stroke volume index $<35 \text{ ml}/\text{m}^2$) (27,28). This group of patients can be subdivided according to the left ventricular ejection fraction (LVEF): classical low-flow low-gradient severe AS when LVEF is $<50\%$

and paradoxical low-flow low-gradient severe AS when LVEF is $\geq 50\%$. Accurate identification of patients with low-flow low-gradient severe AS who will benefit from TAVR is pivotal.

In patients with classical low-flow low-gradient severe AS, the first step is to demonstrate the presence of flow reserve. If normalization of stroke volume (flow reserve) during low-dose dobutamine stress echocardiography significantly increases the peak velocity or mean gradient, but does not result in an increased aortic valve area, then the diagnosis of true severe AS is confirmed. Alternatively, an increase in aortic valve area $>1 \text{ cm}^2$ along with the stroke volume confirms the diagnosis of pseudosevere AS. However, when flow reserve cannot reliably be demonstrated, assessment of the aortic valve calcium load is useful to identify patients with true severe AS (29). The presence of an aortic valve calcium load measured on computed tomography (CT) according to the Agatston method $\geq 2,000$ (arbitrary units) in men and $\geq 1,200$ (arbitrary units) in women increases the likelihood of severe AS (22). However, the data supporting these cut-off values are based on retrospective studies and prospective validation is needed.

Patients with paradoxical low-flow low-gradient severe AS usually present with a severely hypertrophied left ventricle (LV) with a small cavity. In these patients, low-dose dobutamine stress echocardiography to calculate the projected aortic valve area and CT to assess the aortic valve calcium load may help to identify true severe AS (22,23).

Furthermore, correct measurement of the LVOT area is important to minimize the underestimation of



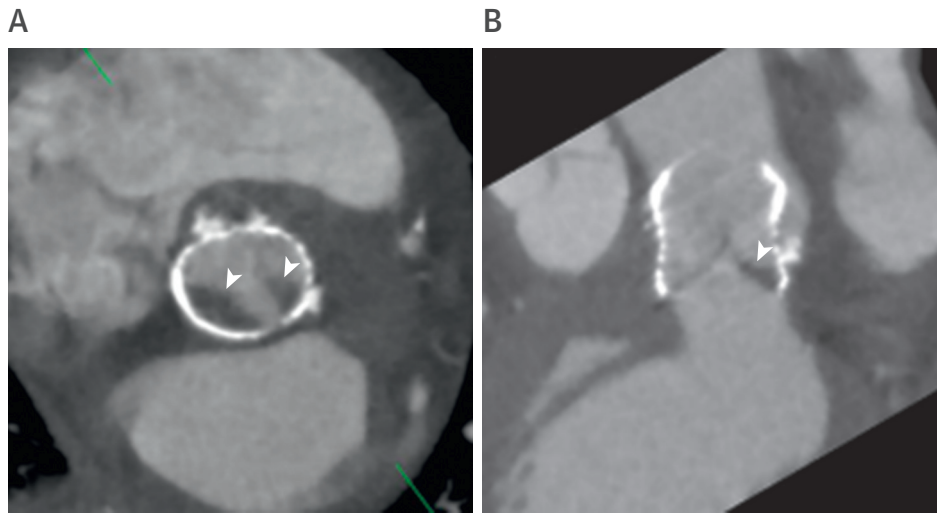
the aortic valve area. When using 2-dimensional (2D) echocardiography, the shape of the LVOT is assumed to be circular, which introduces an important measurement error. The use of 3D imaging techniques (MDCT, cardiac magnetic resonance [CMR], and echocardiography) that permit accurate measurement of the LVOT area by direct planimetry has demonstrated ability to reclassify severe AS patients into moderate AS by 12% in patients with low-flow low-gradient severe AS (based on an aortic valve area $<1 \text{ cm}^2$) (30). However, it has been suggested that when using 3D imaging modalities, a cut-off value of $<1.2 \text{ cm}^2$ has prognostic implications (31).

Low flow and low gradient have shown an independent association with poor prognosis in several registries, whereas LVEF has not (32,33). When evaluating the prognosis of these patients, additional parameters related to low flow and low gradient such as LV myocardial fibrosis have incremental prognostic

value (27,34). Direct assessment of myocardial fibrosis by means of late gadolinium-enhanced CMR and measurement of LV global longitudinal strain with speckle tracking echocardiography have been associated with increased all-cause mortality after aortic valve replacement (27,34). In addition, assessment of diffuse reactive fibrosis with T1 mapping CMR techniques has shown that patients with severe AS have increased native T1 values (indicating increased diffuse fibrosis) as compared with age- and sex-matched controls (35). Furthermore, patients with severe AS with the highest native T1 value presented higher events rates of all-cause mortality and hospitalization for heart failure at follow-up than those with lower values of native T1 (42.9% vs. 2.4%; $p < 0.001$) (35).

CONCOMITANT VALVE DISEASE. The prevalence of moderate or severe mitral and tricuspid regurgitation in patients undergoing TAVR varies widely (36), in

FIGURE 3 Hypoattenuated Leaflet Thickening of a Self-Expandable Transcatheter Aortic Valve on Multi-Detector Row Computed Tomography



(A) The reconstructed short-axis view of the transcatheter valve with hypoattenuated masses within the bioprosthetic frame (**arrowheads**).
(B) On the sagittal plane, hypoattenuation is visible in the belly of the leaflet on the aortic surface (**arrowhead**).

part due to differences in grading schemes and absence of valve regurgitation quantification or core laboratory adjudication. However, a recent report from the United States Society of Thoracic Surgeons/American College of Cardiology Transcatheter Valve Therapy (STS/ACC TVT) Registry shows that nearly 30% of patients undergoing TAVR have moderate-to-severe mitral regurgitation and 24% have moderate-to-severe tricuspid regurgitation (37).

The mechanism of mitral regurgitation varies and includes both hemodynamic and morphological abnormalities. The majority of patients have

high-gradient AS with very high LV systolic pressures, which results in more mitral regurgitation across a given effective regurgitant orifice area (EROA). In low-flow, low-gradient severe AS, global or regional wall motion abnormalities may cause functional mitral regurgitation due to tethering of nearly normal mitral leaflets. However, most patients undergoing TAVR are of older age, and mitral annular calcification combined with varying degrees of leaflet thickening and/or calcification are common. Thus, mitral regurgitation may be of mixed etiology, with some elements of leaflet tethering and high-driving pressures

TABLE 2 Incidence of Transcatheter Aortic Valve Thrombosis

First Author (Ref. #) (Year)	N	Prevalence of Thrombosis on MDCT (Time)	Prevalence of Thrombosis on Echo (Time)	Mean Gradient (mm Hg)-EOA (cm ²)
Latib et al. (49) (2015)	4266	NA	0.61% (median, 181 days)	40.5 ± 14.0-NA
Pache et al. (50) (2016)	156	10.6% (median, 5 days)	NA (median, 5 days)	8 ± 3.5-NA
Leetmaa et al. (51) (2016)	140	4% (1-3 months)	NA (1-3 months)	19.2-1.44
Del Trigo et al. (52) (2016)	1521	NA	4.5% (4 yrs)	26.1 ± 11-NA
Hansson et al. (53) (2016)	405	7% (1-3 months)	NA (1-3 months)	10 ± 7-1.5 ± 0.5
Makkar et al. (54) (2016)	55	40% (median, 32 days)	NA (30 days)	9.2 ± 4.9-NA
Makkar et al. (54) (2016)	132	13% (median, 86 days)	NA (30 days)	8.4 ± 2.9-NA
Yanagisawa et al. (55) (2017)	70	14.3% (1 yr)	NA (1 yr)	8.3 ± 0.8-1.03 ± 0.25
Chakravarty et al. (45) (2017)	752	13% (median, 58 days)	6% (median, 58 days)	13.8 ± 10.0-NA
Vollema et al. (56) (2017)	434	12% (median, 35 days)	3% (3 yrs)	9.3 ± 4.7-1.99 ± 0.56
Jose et al. (57) (2017)	642	9/10 (NA)	2.8% (median, 181 days)	34 ± 14-1.06 ± 0.46
Sondergaard et al. (58) (2017)	61	11% (140 ± 152 days)	NA	7.0 ± 3.2-NA

EOA = effective orifice area; MDCT = multi-detector row computed tomography; NA = not available.

superimposed on thickened leaflets with poor mobility. Prolapsed or flail leaflets are occasionally noted. Tricuspid regurgitation tends to occur with normal tricuspid leaflets due to pulmonary hypertension, annular dilation, and/or right ventricular dilation/dysfunction.

After successful TAVR, mitral regurgitation severity improves spontaneously in 50% to 60% of such patients (38). A 3D TEE study suggests that improvement in mitral regurgitation severity is largely due to improved hemodynamics (lower driving velocity from decreased LV systolic pressure) and reduced leaflet tethering after TAVR (39). However, when there is a major anatomical abnormality, such as a flail leaflet, TAVR would not be expected to improve mitral regurgitation severity. Such patients may benefit from combined TAVR and transcatheter mitral valve repair (i.e., MitraClip) (Figure 2), or, in the future, transcatheter mitral valve replacement (40).

Conflicting data exist regarding the prognostic significance of mitral regurgitation in TAVR patients. A recent PARTNER trial publication indicated that moderate or severe mitral regurgitation at discharge after TAVR is an independent predictor of 1-year mortality (41). In addition, a meta-analysis of 8 studies showed that baseline MR was associated with increased early and late mortality after TAVR (38). However, in the PARTNER A randomized trial, in which mitral regurgitation severity was adjudicated by a core laboratory, baseline mitral regurgitation was associated with mortality after SAVR, but not TAVR (42). In contrast, data from the large STS/ACC TVT registry with 22,248 patients from 318 United States sites showed that moderate or severe tricuspid regurgitation (odds ratio [OR]: 1.22 [95% confidence interval (CI): 1.05 to 1.41]), but not mitral regurgitation (OR: 1.02 [95% CI: 0.89 to 1.17]), was independently associated with mortality (43). Future studies should focus on the impact of persistent concomitant significant mitral and tricuspid valve disease after TAVR.

VALVE THROMBOSIS: HOW TO DIAGNOSE? The use of surgical bioprosthetic heart valves in patients with severe AS has increased significantly over the last decades (44). Avoidance of anti-coagulation therapy is attractive in elderly patients with increased bleeding risk. However, the bioprosthetic valves have limited durability, with a risk of structural degeneration (including thrombosis and pannus formation) and subsequent dysfunction. Recently, standardized definitions of structural deterioration and valve failure of transcatheter and surgical aortic bioprostheses have been proposed (45,46). These definitions include valve thrombosis as one of the causes of

bioprosthetic valve dysfunction. Besides visualization of leaflet thickening and restricted motion, the American College of Cardiology recommendations on echocardiographic surveillance of bioprostheses provide several functional criteria to define possible valve stenosis (peak prosthetic aortic jet velocity 3 to 4 m/s, mean gradient 20 to 35 mm Hg, and EOA between 0.88 and 1.2 cm²/m²) and significant stenosis (peak prosthetic aortic jet velocity >4 m/s, mean gradient >35 mm Hg, and EOA <0.8 cm²/m²) caused by thrombosis. The European recommendations further consider an increase in mean gradient during stress echocardiography or at follow-up between 10 and 19 mm Hg for possible valve stenosis and ≥20 mm Hg for significant stenosis (47,48). More recently, anatomical findings on MDCT for assessment of transcatheter heart valve and surgical aortic bioprostheses have added more controversy to the field by considering hypoattenuated leaflet thickening as valve thrombosis (Figure 3) (45,49-58). The association between hypoattenuated leaflet thickening and leaflet restrictive movement is not straightforward and not all thickened leaflets show restrictive motion, suggesting that these findings are two stages of the same phenomenon, with leaflet thickening occurring earlier, followed by reduced leaflet motion at a more advanced stage. Table 2 summarizes recent studies evaluating valve thrombosis of transcatheter heart valve (45,49-58). Note that the incidence of valve thrombosis is much higher when using MDCT anatomical criteria as compared with the incidence when echocardiographic functional criteria are considered. Accordingly, it has been suggested that MDCT may be the most sensitive method to detect transcatheter heart valve thrombus.

It is speculated whether subclinical leaflet thrombosis will have an impact on post-procedural outcome (e.g., an increased risk of stroke/transient ischemic attack) or will relate to early structural valve degeneration. Large registry data recently suggested that hypoattenuated leaflet thickening and restrictive leaflet motion may be associated with a higher prevalence of transient ischemic attack, but not stroke (56). These findings, however, must be interpreted with caution due to a time delay between MDCT and clinical event, and, therefore, prospective clinical studies are warranted.

Further studies characterizing predisposing factors for this phenomenon are clearly warranted because treatment with anticoagulation can resolve leaflet thrombosis. A recent in vitro imaging of flow characteristics of the transcatheter heart valve leaflets found a higher risk for thrombus formation in oversized transcatheter heart valve, reduced cardiac

output in balloon-expandable transcatheter heart valve, and implant depth in the self-expanding transcatheter heart valve (59). In addition, Fuchs et al. (60) showed, in self-expandable transcatheter heart valve, that regional stent frame under-expansion has been associated with increased rate of leaflet thrombosis, whereas supra-annular valve position as well as post-dilatation seem to reduce the occurrence of this phenomenon. Ongoing trials randomizing low-risk, severe AS patients to SAVR versus TAVR include in their designs the use of MDCT for follow-up (Placement of Aortic Transcatheter Valves 3 [PARTNER 3, NCT02675114; CoreValve Evolut R Transcatheter Aortic Valve [CoreValve EVOLUT R], NCT02746809). These results will help to elucidate the incidence of hypoattenuated leaflet thickening with and without leaflet motion restriction, the predisposing factors, and their impact on clinical outcomes. In addition, the role of MDCT in the management of patients with aortic bioprostheses at follow-up will be defined.

NEW INDICATIONS FOR TAVR

WHAT INFORMATION IS NEEDED FOR VALVE-IN-VALVE PROCEDURES? Transcatheter valve-in-valve (ViV) is a feasible and safe therapeutic strategy for failed surgical aortic bioprostheses. Recent data from large registries have reported 1-year survival rates of approximately 85% after transcatheter ViV implantation in degenerated aortic bioprostheses (6,7). Moreover, in contrast to native TAVR, the incidence of more than mild paravalvular regurgitation, new pacemaker implantation, and annulus rupture is low, probably related to the presence of a rigid sewing ring (7). However, the hemodynamics of the transcatheter heart valve after the ViV procedure are characterized by higher mean and peak gradients compared with those observed in native TAVR. These results have prompted the development of new surgical prostheses that can expand the sewing ring and host a larger transcatheter valve to prevent high transvalvular gradients. When evaluating patients with dysfunctioning surgical aortic bioprostheses, cardiac imaging plays a central role in the evaluation of the following aspects: mode of prosthesis dysfunction, prosthesis sizing, and risk of coronary ostia obstruction.

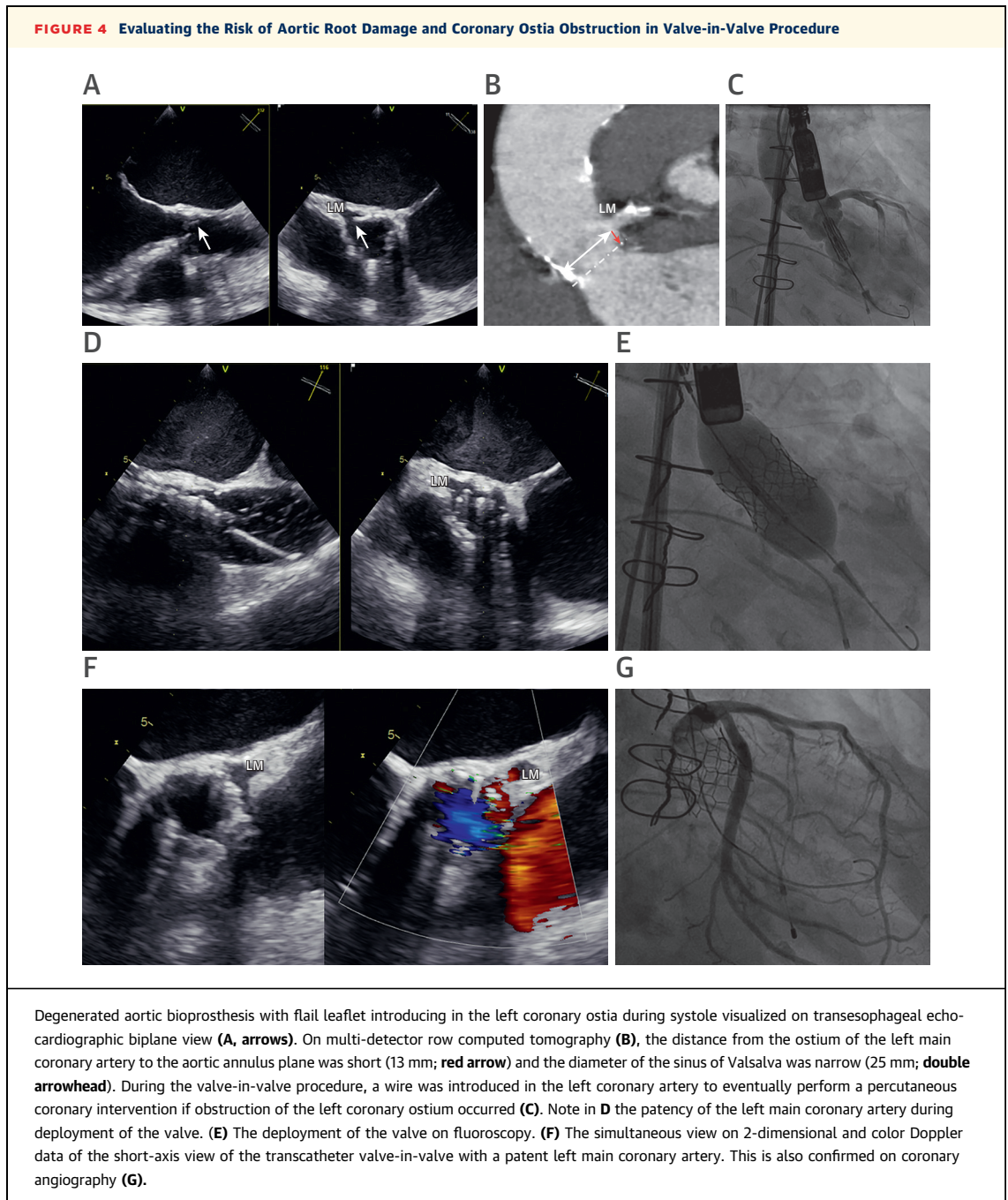
Mode of prosthesis dysfunction. Degeneration of the prosthetic leaflets with thickening and calcification frequently cause valve stenosis, whereas endocarditis or sewing ring dehiscence usually cause valve regurgitation. In the majority of the registries, stenosis is the mode of bioprosthesis dysfunction in 55% of the patients, regurgitation is observed in 23%, and

combination of both in 22% (61-63). In small surgical bioprostheses, differentiation between increased transvalvular gradients due to PPM and valve stenosis should be performed (48). When severe aortic regurgitation is the mode of dysfunction, analysis of the underlying mechanism is important to plan the procedure; when flail leaflets are present, the risk of obstruction of the coronary ostia should be foreseen. Large sewing ring dehiscence causing aortic regurgitation may not be appropriately treated with ViV intervention because the new implanted valve may not have appropriate anchoring. Also, MDCT provides important information in the mode of prosthesis degeneration showing thickening of the leaflets, thrombus or pannus formation, and dehiscence.

Prosthesis sizing. The internal dimensions of the aortic bioprosthesis indicated by the manufacturer can be used to size the transcatheter heart valve that will be implanted. The grade of oversizing needs to take into consideration the risk of incomplete deployment of the THV and increased residual transvalvular gradients. MDCT provides the highest spatial resolution to size the internal dimensions of the degenerated prosthesis. Eventually, when the use of iodinated contrast should be kept at a minimum, 3D TEE is a good alternative to size the prosthesis. The ViV aortic application developed by Dr. Vinayak Bapat is a useful tool to determine the prosthesis size based on the specific bioprosthesis manufacturer's dimensions (<http://www.ubqo.com/viv>).

Risk of coronary ostia obstruction. Furthermore, the dimensions of the sinus of Valsalva and the height of the coronary ostia are important to predict the risk of coronary ostia obstruction. When the diameter of the sinus of Valsalva is <30 mm and the distance of the coronary ostia relative to the aortic annulus is <12 mm, the risk of obstruction is high. MDCT and 3D TEE can accurately assess these dimensions (Figure 4). In addition, periprocedural aortography with a projection perpendicular to the aortic bioprosthesis and the coronary ostia should be performed to monitor the risk of this complication (62).

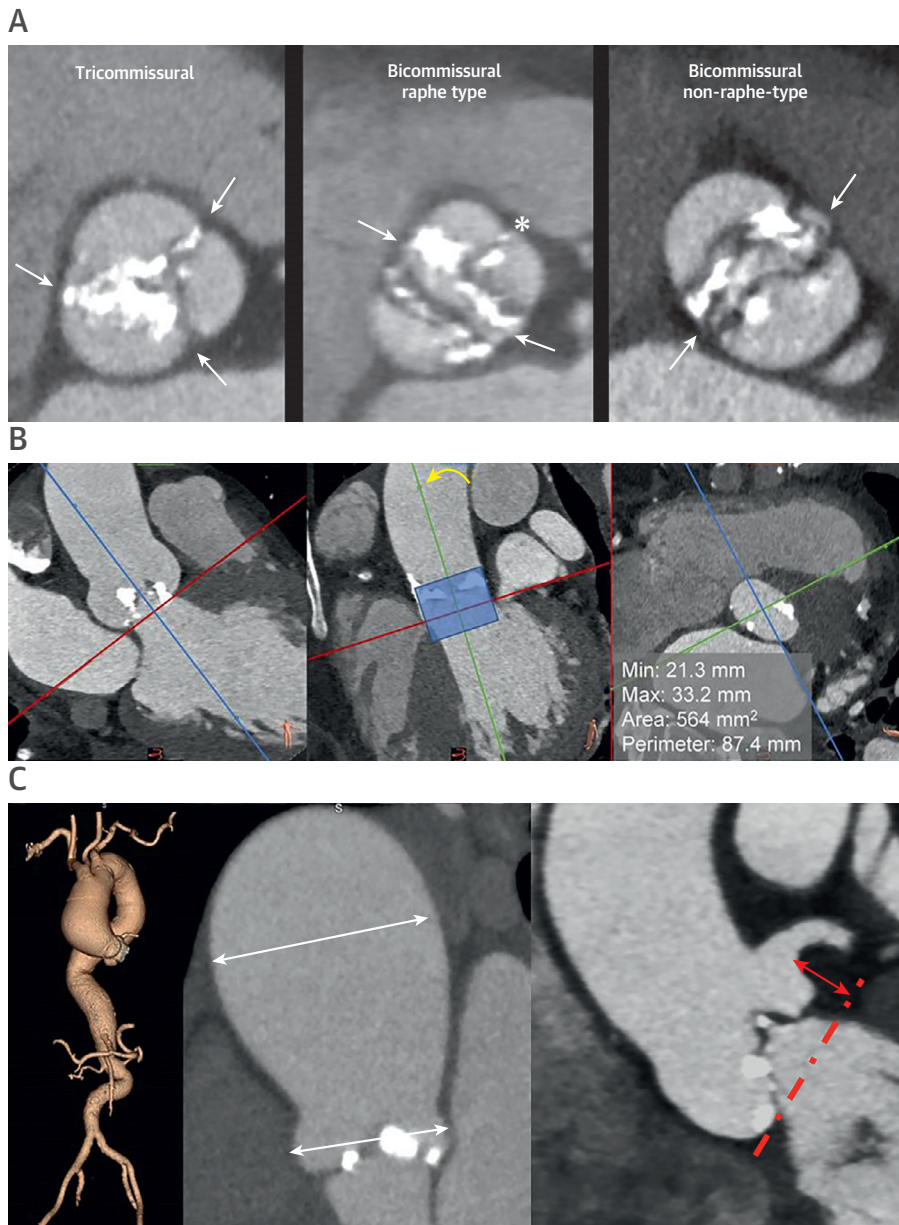
HOW TO EVALUATE PATIENTS WITH BICUSPID AORTIC VALVE? When evaluating patients with severe bicuspid AS for TAVR, the anatomy of the aortic valve should be first defined. The bicuspid aortic valve has been classified according to the presence and location of a raphe fusion and the orientation of the commissures (64). In elderly patients, bicuspid aortic valve with raphe may lead to controversy because it may be impossible to differentiate from heavily calcified tricuspid AS. Recently, a new classification based on MDCT has been proposed:



tri-commissural, when one commissure is completely fused by calcifications (also known as functional bicuspid aortic valve), bi-commissural raphe type, when there is a fibrous, calcified fusion raphe that does not reach the height of the commissure (the fusion of cusps affects to the proximal or basal third of the sinus), and bi-commissural non-raphe type, when 2 cusps and only 2 commissures are identified without a fusion raphe (Figure 5A) (65). Next, the selection of the appropriate prosthesis size in bicuspid

aortic valve anatomy can be challenging. When 3 aortic sinuses can be identified (type 1 and 2 morphologies), the annulus plane can be set as conventionally performed in tricuspid aortic valve. The hinge points of the 3 aortic cusps are demarcated and the annulus plane is defined. In contrast, in type 0 bicuspid AS, the hinge points of the 2 aortic cusps are defined and the third point will be set with an orthogonal plane parallel to the device landing zone including the LVOT and aortic annulus (Figure 5B).

FIGURE 5 Evaluation of Patients With Bicuspid Aortic Valve Stenosis Undergoing TAVR



First, the anatomy of the bicuspid aortic valve should be assessed (**A**). The tri-commissural type is defined by the presence of 3 commissures (**arrows**), one of them fused by calcification (functional bicuspid aortic valve). The bi-commissural raphe type is characterized by 2 commissures (**arrows**) and the presence of a raphe that affects to the proximal or basal third of the sinus (**asterisk**). The bi-commissural non-raphe type is defined by the presence of 2 cusps and 2 commissures (**arrows**). Second, measurement of the aortic annulus should be performed (**B**). When the aortic valve has only 2 cusps and 2 commissures, definition of the aortic annulus plane requires orientation of a plane crossing the hinge points of the cusps conventionally (**left, red line**) and a second orthogonal plane (**middle, green line**) parallel to the device landing zone (**middle, shaded zone**). The minimum and maximum diameters, cross-sectional area, and perimeter can be measured in the resultant short-axis of the aortic annulus (**right**). In addition, the dimensions of the aortic root and ascending aorta (**C, middle**) and the height of the coronary ostia relative to the annulus plane should be measured (**C, right, arrowhead**). Abbreviation as in [Figure 2](#).

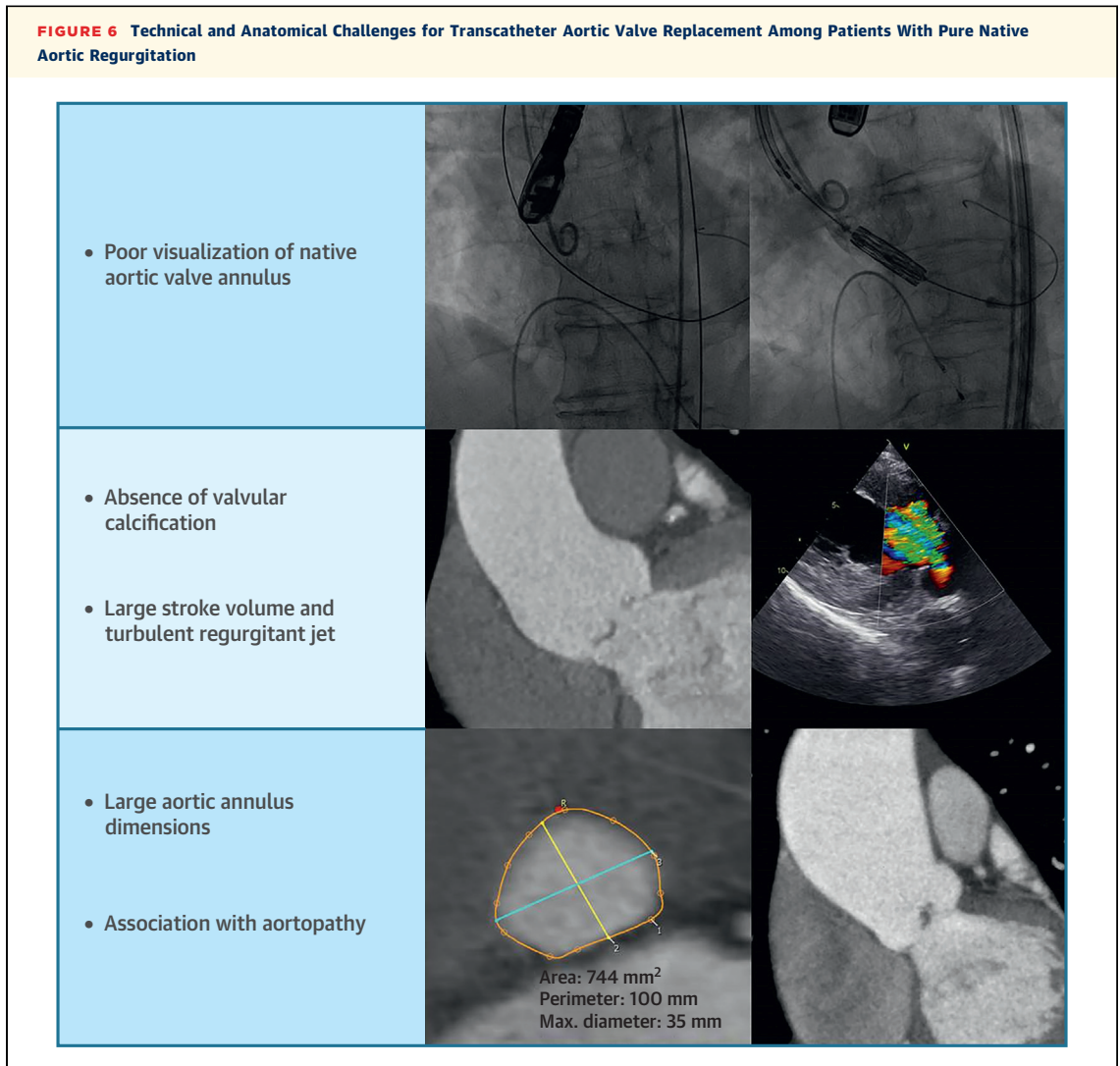
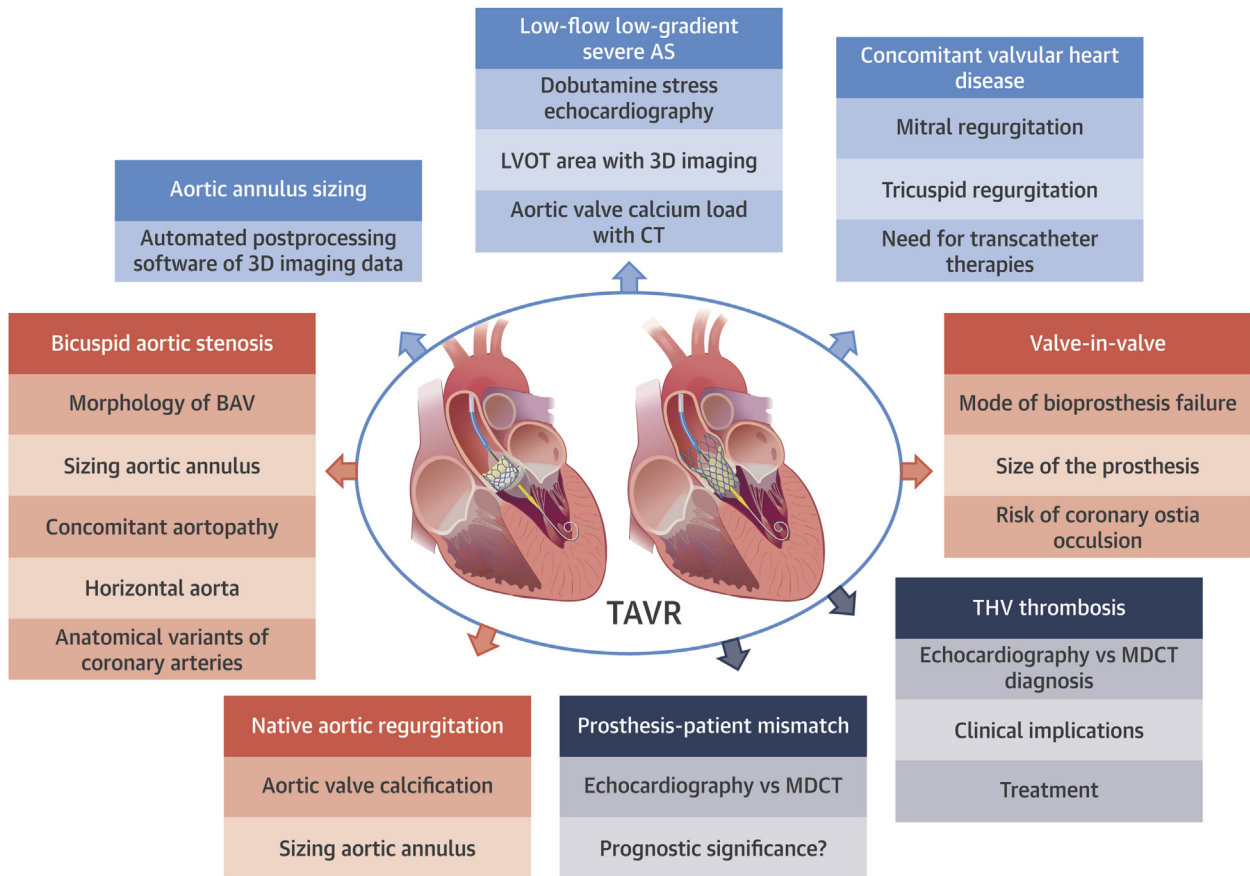


TABLE 3 Transcatheter Aortic Valve Replacement in Pure Native Aortic Regurgitation

First Author (Ref. #) (Year)	N	Age (yrs)	Logistic EuroSCORE (%)	Device	Access (%)	Device Success (%)	Conversion to Surgery (%)	30-day Mortality (%)	New PPI (%)
Zhu et al. (73) 2016	33	74.2 ± 5.2	24.4 ± 5.1	J-Valve	TA (100%)	97%	3%	3%	6%
Freker et al. (74) 2015	22	80.0 ± 5.6	25.0 ± 18.0	95.5% CoreValve 4.5% SAPIEN	-	77%	-	22.7%	27.3%
Seiffert et al. (75) 2014	31	80.0 ± 5.6	25.0 ± 18.0	JenaValve	TA (100%)	97%	0	12.9%	6.4%
Testa et al. (76) 2014	26	73.0 ± 10.0	24.0 ± 8.0	CoreValve	81% TF 19% non-TA/non-TF	77%	0	23%	16%
Roy et al. (77) 2013	43	75.3 ± 8.8	26.9 ± 17.9	CoreValve	81.4% TF 18.6% non-TA/non-TF	74%	2%	9.3%	16.3%
Sawaya et al. (63) 2017	78	74 ± 10	20.4 ± 11.8	42% CoreValve 29% JenaValve 29% Others	65% TF 29% TA 6% non-TA/non-TF	72%	0	14%	18%
Yoon et al. (78) 2017	331	74.4 ± 12.2	9.8 ± 10.7	48% CoreValve 19% JenaValve 12% SAPIEN 3 21% Others	70% TF 24% TA 26% non-TA/non-TF	74%	3.6%	10.9%	18.2%

The main studies (with 20 or more patients included) are summarized.
TA = transapical; TF = transfemoral.

CENTRAL ILLUSTRATION TAVR: The Pivotal Role of Multimodality Imaging to Evaluate Conventional and New Indications



Bax, J.J. et al. *J Am Coll Cardiol Img.* 2020;13(1):124-39.

3D = 3-dimensional; BAV = bicuspid aortic valve; CT = computed tomography; LVOT = left ventricular outflow tract; MDCT = multi-detector row computed tomography; TAVR = transcatheter aortic valve replacement.

In addition, concomitant aortopathy should be assessed for patients with bicuspid AS (Figure 5C). The risk of aortic dissection in patients with bicuspid aortic valve and severe aortic enlargement is established. According to current guidelines (66), repair of the aortic root or replacement of the ascending aorta is reasonable when the aortic diameter is ≥ 5.0 cm in patients with bicuspid aortic valve who are at low surgical risk. Furthermore, the recently updated 2016 American Heart Association/ACC guidelines stated that replacement of the ascending aorta is reasonable in patients with bicuspid aortic valve undergoing aortic valve replacement when the diameter of the ascending aorta is >4.5 cm (67). The decision made in favor of the less invasive “TAVR alone” approach may be

HIGHLIGHTS

- TAVR is an established therapy for patients with symptomatic severe AS.
- This therapy is safe and feasible in bicuspid AS, degenerated bioprostheses, and aortic regurgitation.
- CT is becoming the central imaging technique to plan the procedure.
- Multimodality imaging integrating functional and anatomical information expands this technique to complex clinical scenarios.

weighted toward older age with multiple comorbidities and limited expected life period after the procedure. However, if TAVR is an alternative for younger and lower-risk surgical populations, this dilemma will be more frequently encountered.

Furthermore, the presence of horizontal aorta defined as an acute angle ($<30^\circ$) between the plane perpendicular to the aortic annulus and the horizontal reference plane is more frequent than in tricuspid AS. A horizontal aorta may challenge the definition of the angiographic projection to deploy the transcatheter heart valve. On MDCT, horizontal aorta can be identified, and with specific software the angiographic projection to deploy the THV can be set before the procedure avoiding repeated aortograms. Finally, anomalous origin of the coronary arteries is associated with bicuspid aortic valve anatomy (68). The location and height of the coronary ostia relative to the aortic annulus plane can be defined with MDCT, which provides better spatial resolution than invasive aortography. This analysis is important before the procedure to minimize the risk of coronary ostia obstruction.

TAVR FOR THE TREATMENT OF NATIVE (PURE) AORTIC VALVE REGURGITATION. SAVR is the current standard of care for patients with severe aortic regurgitation in the presence of symptoms, LV dilatation, or reduced LV function (69). Notwithstanding, TAVR has been described among patients with native pure aortic regurgitation considered at prohibitive risk for surgery. As compared with calcific AS, the transcatheter treatment of native pure aortic regurgitation poses some unique challenges in terms of technical and anatomical feasibility including (Figure 6): the poor visualization of the native aortic valve annulus on fluoroscopy; the absence of valvular calcification impairing the placement and fixation of the prosthesis within the annulus; the large stroke volume combined with the turbulent regurgitant jet, limiting device control during positioning and release; the complex anatomy with larger and more elliptical annulus size exceeding the range of commercially available transcatheter valve prostheses; and the frequent association of native pure aortic regurgitation with an aortopathy and dilatation of the aortic root and ascending aorta.

Due to these issues, valve deployment is less predictable and may be complicated by dislocation of the prosthesis despite generous oversizing. In selecting patients with severe native aortic regurgitation for TAVR, echocardiography is the preferred imaging technique to evaluate the aortic regurgitation severity and the underlying mechanism of valve regurgitation and to determine the presence of

concomitant aortic root and ascending aorta dilation and the LV dimensions and function (70). Compared with 2D echocardiography, 3D echocardiography provides better agreement with CMR in the quantification of the regurgitant volume, particularly in eccentric regurgitant jets (71). CMR is the reference method to quantify LV volumes and function and, based on phase contrast analysis, an aortic regurgitant fraction $>50\%$ defines severe aortic regurgitation (72). Aortic regurgitation caused by restricted motion of the cusps due to degenerative changes without significant dilation of the annulus may be amenable for TAVR because frequently the aortic valve is calcified and ensures good anchoring of the transcatheter valve.

The evidence on the efficacy and safety of TAVR in pure native aortic regurgitation is summarized in Table 3 (63,73-78). The largest multicenter study includes 331 patients with native pure aortic regurgitation treated with TAVR (78). The estimated 30-day all-cause mortality was 10.9%. Device success was 74.3%, 16.6% of patients required the implantation of a second valve, and 3.6% of patients underwent conversion to SAVR. Moderate or severe post-procedural aortic regurgitation (9.6%) was observed at similar frequency compared with those reported in patients with severe AS treated with early-generation devices (79,80).

Although SAVR remains the standard therapeutic option for patients with native pure aortic regurgitation, TAVR may be considered among carefully selected patients with native pure aortic regurgitation deemed at inappropriately high risk. Novel devices featuring repositionability, self-positioning geometry, and specific fixation mechanisms have the potential to improve the performance of TAVR in patients with native pure aortic regurgitation.

CONCLUSIONS

Multimodality imaging plays an important role in the evaluation of patients referred for TAVR. The use of both echocardiography and MDCT is key in the diagnosis of patients with severe AS who may benefit from TAVR as well as in the procedural planning and evaluation of the results at follow-up. In addition, the excellent results of TAVR in inoperable and low-, intermediate-, and high-surgical risk populations have prompted the use of this therapy in other patients who were not represented in the randomized clinical trials. Ongoing trials evaluating the efficacy of TAVR in patients with heart failure and moderate AS will open new therapeutic possibilities to patients

with pseudosevere AS (81). Because TAVR prostheses have better hemodynamic profile than surgical prostheses, as demonstrated by lower incidence of PPM, relief of the increased afterload posed by the moderate AS may result in improvement of LVEF. Additionally, whether treatment of other concomitant clinically significant valve disease during the same TAVR procedure or afterward will provide better prognosis needs to be demonstrated. The number of patients with bicuspid AS treated with TAVR is increasing and the TAVR results with the use of new generation prostheses are promising. TAVR in degenerated bioprosthesis has been an important breakthrough because re-operation is associated with

increased mortality. Finally, patients with native aortic regurgitation are being treated with TAVR. These two clinical scenarios need careful evaluation of the anatomy of the landing zone to ensure successful anchoring of the TAVR prosthesis and to minimize complications. These new horizons put multimodality imaging at the epicenter of this evolving therapy (**Central Illustration**).

ADDRESS FOR CORRESPONDENCE: Dr. Jeroen J. Bax, Department of Cardiology, Leiden University Medical Center, Albinusdreef 2 2333 ZA Leiden, the Netherlands. E-mail: j.j.bax@lumc.nl.

REFERENCES

1. Leon MB, Smith CR, Mack M, et al. Transcatheter aortic-valve implantation for aortic stenosis in patients who cannot undergo surgery. *N Engl J Med* 2010;363:1597-607.
2. Adams DH, Popma JJ, Reardon MJ. Transcatheter aortic-valve replacement with a self-expanding prosthesis. *N Engl J Med* 2014;371:967-8.
3. Leon MB, Smith CR, Mack MJ, et al. Transcatheter or surgical aortic-valve replacement in intermediate-risk patients. *N Engl J Med* 2016;374:1609-20.
4. Reardon MJ, Van Mieghem NM, Popma JJ, et al. Surgical or transcatheter aortic-valve replacement in intermediate-risk patients. *N Engl J Med* 2017;376:1321-31.
5. Thyregod HG, Steinbruchel DA, Ihlemann N, et al. Transcatheter versus surgical aortic valve replacement in patients with severe aortic valve stenosis: 1-year results from the All-Comers NOTION Randomized Clinical Trial. *J Am Coll Cardiol* 2015;65:2184-94.
6. Dvir D, Webb JG, Bleiziffer S, et al. Transcatheter aortic valve implantation in failed bioprosthetic surgical valves. *JAMA* 2014;312:162-70.
7. Webb JG, Mack MJ, White JM, et al. Transcatheter aortic valve implantation within degenerated aortic surgical bioprostheses: PARTNER 2 Valve-in-Valve Registry. *J Am Coll Cardiol* 2017;69:2253-62.
8. Yoon SH, Bleiziffer S, De Backer O, et al. Outcomes in transcatheter aortic valve replacement for bicuspid versus tricuspid aortic valve stenosis. *J Am Coll Cardiol* 2017;69:2579-89.
9. Franzone A, Piccolo R, Siontis GC, et al. Transcatheter aortic valve replacement for the treatment of pure native aortic valve regurgitation: a systematic review. *J Am Coll Cardiol Intv* 2016;9:2308-17.
10. Barbanti M, Yang TH, Rodes Cabau J, et al. Anatomical and procedural features associated with aortic root rupture during balloon-expandable transcatheter aortic valve replacement. *Circulation* 2013;128:244-53.
11. Ewe SH, Ng AC, Schuijff JD, et al. Location and severity of aortic valve calcium and implications for aortic regurgitation after transcatheter aortic valve implantation. *Am J Cardiol* 2011;108:1470-7.
12. Ribeiro HB, Nombela-Franco L, Urena M, et al. Coronary obstruction following transcatheter aortic valve implantation: a systematic review. *J Am Coll Cardiol Intv* 2013;6:452-61.
13. Podlesnikar T, Pihadi EA, van Rosendaal PJ, et al. Influence of the quantity of aortic valve calcium on the agreement between automated 3-dimensional transesophageal echocardiography and multidetector row computed tomography for aortic annulus sizing. *Am J Cardiol* 2018;121:86-93.
14. Tretter JT, Spicer DE, Mori S, Chikkabyrappa S, Redington AN, Anderson RH. The significance of the interleaflet triangles in determining the morphology of congenitally abnormal aortic valves: implications for noninvasive imaging and surgical management. *J Am Soc Echocardiogr* 2016;29:1131-43.
15. Murphy DT, Blanke P, Alaamri S, et al. Dynamics of the aortic annulus: effect of diastolic versus systolic CT annular measurements on device selection in transcatheter aortic valve replacement (TAVR). *J Cardiovasc Comput Tomogr* 2016;10:37-43.
16. Blanke P, Willson AB, Webb JG, et al. Oversizing in transcatheter aortic valve replacement, a commonly used term but a poorly understood one: dependency on definition and geometrical measurements. *J Cardiovasc Comput Tomogr* 2014;8:67-76.
17. Hahn RT, Little SH, Monaghan MJ, et al. Recommendations for comprehensive intraprocedural echocardiographic imaging during TAVR. *J Am Coll Cardiol Intv* 2015;8:261-87.
18. Kasel AM, Cassese S, Bleiziffer S, et al. Standardized imaging for aortic annular sizing: implications for transcatheter valve selection. *J Am Coll Cardiol Intv* 2013;6:249-62.
19. Khalique OK, Hamid NB, White JM, et al. Impact of methodologic differences in three-dimensional echocardiographic measurements of the aortic annulus compared with computed tomographic angiography before transcatheter aortic valve replacement. *J Am Soc Echocardiogr* 2017;30:414-21.
20. Guez D, Boroumand G, Ruggiero NJ, Mehrotra P, Halpern EJ. Automated and manual measurements of the aortic annulus with ECG-gated cardiac CT angiography prior to transcatheter aortic valve replacement: comparison with 3D-transesophageal echocardiography. *Acad Radiol* 2017;24:587-93.
21. Kong WK, van Rosendaal PJ, van der Kley F, et al. Impact of different iterations of devices and degree of aortic valve calcium on paravalvular regurgitation after transcatheter aortic valve implantation. *Am J Cardiol* 2016;118:567-71.
22. Baumgartner H, Hung J, Bermejo J, et al. Recommendations on the echocardiographic assessment of aortic valve stenosis: a focused update from the European Association of Cardiovascular Imaging and the American Society of Echocardiography. *J Am Soc Echocardiogr* 2017;30:372-92.
23. Dayan V, Vignolo G, Soca G, Paganini JJ, Brusich D, Pibarot P. Predictors and outcomes of prosthesis-patient mismatch after aortic valve replacement. *J Am Coll Cardiol Intv* 2016;9:924-33.
24. Pibarot P, Weissman NJ, Stewart WJ, et al. Incidence and sequelae of prosthesis-patient mismatch in transcatheter versus surgical valve replacement in high-risk patients with severe aortic stenosis: a PARTNER trial cohort-a analysis. *J Am Coll Cardiol* 2014;64:1323-34.
25. Bleiziffer S, Eichinger WB, Hettich I, et al. Prediction of valve prosthesis-patient mismatch prior to aortic valve replacement: which is the best method? *Heart* 2007;93:615-20.
26. Mooney J, Sellers SL, Blanke P, et al. CT-defined prosthesis-patient mismatch downgrades frequency and severity, and demonstrates no association with adverse outcomes after transcatheter aortic valve replacement. *J Am Coll Cardiol Intv* 2017;10:1578-87.

27. Barone-Rochette G, Pierard S, De Meester de Ravenstein C, et al. Prognostic significance of LGE by CMR in aortic stenosis patients undergoing valve replacement. *J Am Coll Cardiol* 2014;64:144-54.
28. Herrmann HC, Pibarot P, Hueter I, et al. Predictors of mortality and outcomes of therapy in low-flow severe aortic stenosis: a Placement of Aortic Transcatheter Valves (PARTNER) trial analysis. *Circulation* 2013;127:2316-26.
29. Clavel MA, Dumesnil JG, Capoulade R, Mathieu P, Senechal M, Pibarot P. Outcome of patients with aortic stenosis, small valve area, and low-flow, low-gradient despite preserved left ventricular ejection fraction. *J Am Coll Cardiol* 2012;60:1259-67.
30. Kamperidis V, van Rosendaal PJ, Katsanos S, et al. Low gradient severe aortic stenosis with preserved ejection fraction: reclassification of severity by fusion of Doppler and computed tomographic data. *Eur Heart J* 2015;36:2087-96.
31. Clavel MA, Malouf J, Messika-Zeitoun D, Araoz PA, Michelena HI, Enriquez-Sarano M. Aortic valve area calculation in aortic stenosis by CT and Doppler echocardiography. *J Am Coll Cardiol Img* 2015;8:248-57.
32. Bavishi C, Balasundaram K, Argulian E. Integration of flow-gradient patterns into clinical decision making for patients with suspected severe aortic stenosis and preserved LVEF: a systematic review of evidence and meta-analysis. *J Am Coll Cardiol Img* 2016;9:1255-63.
33. Kataoka A, Watanabe Y, Kozuma K, et al. Prognostic impact of low-flow severe aortic stenosis in small-body patients undergoing TAVR: the OCEAN-TAVI registry. *J Am Coll Cardiol Img* 2018;11:659-69.
34. Ng ACT, Pihadi EA, Antoni ML, et al. Left ventricular global longitudinal strain is predictive of all-cause mortality independent of aortic stenosis severity and ejection fraction. *Eur Heart J Cardiovasc Imaging* 2018;19:859-67.
35. Lee H, Park JB, Yoon YE, et al. Noncontrast myocardial T1 mapping by cardiac magnetic resonance predicts outcome in patients with aortic stenosis. *J Am Coll Cardiol Img* 2018;11:974-83.
36. Nombela-Franco L, Ribeiro HB, Urena M, et al. Significant mitral regurgitation left untreated at the time of aortic valve replacement: a comprehensive review of a frequent entity in the transcatheter aortic valve replacement era. *J Am Coll Cardiol* 2014;63:2643-58.
37. Holmes DR Jr., Nishimura RA, Grover FL, et al. Annual outcomes with transcatheter valve therapy: from the STS/ACC TVT Registry. *J Am Coll Cardiol* 2015;66:2813-23.
38. Nombela-Franco L, Eltchaninoff H, Zahn R, et al. Clinical impact and evolution of mitral regurgitation following transcatheter aortic valve replacement: a meta-analysis. *Heart* 2015;101:1395-405.
39. Shibayama K, Harada K, Berdejo J, et al. Effect of transcatheter aortic valve replacement on the mitral valve apparatus and mitral regurgitation: real-time three-dimensional transesophageal echocardiography study. *Circ Cardiovasc Imaging* 2014;7:344-51.
40. Guerrero M, Dvir D, Himbert D, et al. Transcatheter mitral valve replacement in native mitral valve disease with severe mitral annular calcification: results from the first multicenter global registry. *J Am Coll Cardiol Intv* 2016;9:1361-71.
41. Anjan VY, Herrmann HC, Pibarot P, et al. Evaluation of flow after transcatheter aortic valve replacement in patients with low-flow aortic stenosis: a secondary analysis of the PARTNER randomized clinical trial. *JAMA Cardiol* 2016;1:584-92.
42. Barbanti M, Dvir D, Tan J, Webb JG. Aortic stenosis and mitral regurgitation: implications for transcatheter valve treatment. *EuroIntervention* 2013;9 Suppl:569-71.
43. O'Brien SM, Cohen DJ, Rumsfeld JS, et al. Variation in hospital risk-adjusted mortality rates following transcatheter aortic valve replacement in the united states: a report from the Society of Thoracic Surgeons/American College of Cardiology Transcatheter Valve Therapy Registry. *Circ Cardiovasc Qual Outcomes* 2016;9:560-5.
44. Brown JM, O'Brien SM, Wu C, Sikora JA, Griffith BP, Gammie JS. Isolated aortic valve replacement in North America comprising 108,687 patients in 10 years: changes in risks, valve types, and outcomes in the Society of Thoracic Surgeons National Database. *J Thorac Cardiovasc Surg* 2009;137:82-90.
45. Chakravarty T, Sondergaard L, Friedman J, et al. Subclinical leaflet thrombosis in surgical and transcatheter bioprosthetic aortic valves: an observational study. *Lancet* 2017;389:2383-92.
46. Dvir D, Bourguignon T, Otto CM, et al. Standardized definition of structural valve degeneration for surgical and transcatheter bioprosthetic aortic valves. *Circulation* 2018;137:388-99.
47. Capodanno D, Petronio AS, Prendergast B, et al. Standardized definitions of structural deterioration and valve failure in assessing long-term durability of transcatheter and surgical aortic bioprosthetic valves: a consensus statement from the European Association of Percutaneous Cardiovascular Interventions (EAPCI) endorsed by the European Society of Cardiology (ESC) and the European Association for Cardio-Thoracic Surgery (EACTS). *Eur Heart J* 2017;38:3382-90.
48. Lancellotti P, Pibarot P, Chambers J, et al. Recommendations for the imaging assessment of prosthetic heart valves: a report from the European Association of Cardiovascular Imaging endorsed by the Chinese Society of Echocardiography, the Inter-American Society of Echocardiography, and the Brazilian Department of Cardiovascular Imaging. *Eur Heart J Cardiovasc Imaging* 2016;17:589-90.
49. Latib A, Naganuma T, Abdel-Wahab M, et al. Treatment and clinical outcomes of transcatheter heart valve thrombosis. *Circ Cardiovasc Interv* 2015;8:e001779.
50. Pache G, Schoeclin S, Blanke P, et al. Early hypo-attenuated leaflet thickening in balloon-expandable transcatheter aortic heart valves. *Eur Heart J* 2016;37:2263-71.
51. Leetmaa T, Hansson NC, Leipsic J, et al. Early aortic transcatheter heart valve thrombosis: diagnostic value of contrast-enhanced multidetector computed tomography. *Circ Cardiovasc Interv* 2015;8:e001596.
52. Del Trigo M, Munoz-Garcia AJ, Wijeyesundera HC, et al. Incidence, timing, and predictors of valve hemodynamic deterioration after transcatheter aortic valve replacement: multicenter registry. *J Am Coll Cardiol* 2016;67:644-55.
53. Hansson NC, Grove EL, Andersen HR, et al. Transcatheter aortic valve thrombosis: incidence, predisposing factors, and clinical implications. *J Am Coll Cardiol* 2016;68:2059-69.
54. Makkar RR, Fontana G, Jilaihawi H, et al. Possible subclinical leaflet thrombosis in bio-prosthetic aortic valves. *N Engl J Med* 2015;373:2015-24.
55. Yanagisawa R, Hayashida K, Yamada Y, et al. Incidence, predictors, and mid-term outcomes of possible leaflet thrombosis after TAVR. *J Am Coll Cardiol Img* 2016;10:1-11.
56. Vollema EM, Kong WK, Katsanos S, et al. Transcatheter aortic valve thrombosis: the relation between hypo-attenuated leaflet thickening, abnormal valve haemodynamics, and stroke. *Eur Heart J* 2017;38:1207-17.
57. Jose J, Sulimov DS, El-Mawardy M, et al. Clinical bioprosthetic heart valve thrombosis after transcatheter aortic valve replacement: incidence, characteristics, and treatment outcomes. *J Am Coll Cardiol Intv* 2017;10:686-97.
58. Sondergaard L, De Backer O, Kofoed KF, et al. Natural history of subclinical leaflet thrombosis affecting motion in bioprosthetic aortic valves. *Eur Heart J* 2017;38:2201-7.
59. Midha PA, Raghav V, Sharma R, et al. The fluid mechanics of transcatheter heart valve leaflet thrombosis in the neosinus. *Circulation* 2017;136:1598-609.
60. Fuchs A, De Backer O, Brooks M, et al. Subclinical leaflet thickening and stent frame geometry in self-expanding transcatheter heart valves. *EuroIntervention* 2017;13:e1067-75.
61. Deeb GM, Chetcuti SJ, Reardon MJ, et al. 1-year results in patients undergoing transcatheter aortic valve replacement with failed surgical bioprostheses. *J Am Coll Cardiol Intv* 2017;10:1034-44.
62. Ribeiro HB, Rodes-Cabau J, Blanke P, et al. Incidence, predictors, and clinical outcomes of coronary obstruction following transcatheter aortic valve replacement for degenerative bioprosthetic surgical valves: insights from the VIVID registry. *Eur Heart J* 2018;39:687-95.
63. Sawaya FJ, Deutsch MA, Seiffert M, et al. Safety and efficacy of transcatheter aortic valve replacement in the treatment of pure aortic regurgitation in native valves and failing surgical bioprostheses: results from an international registry study. *J Am Coll Cardiol Intv* 2017;10:1048-56.
64. Sievers HH, Stierle U, Mohamed SA, et al. Toward individualized management of the ascending aorta in bicuspid aortic valve surgery: the role of valve phenotype in 1362 patients. *J Thorac Cardiovasc Surg* 2014;148:2072-80.

65. Jilaihawi H, Chen M, Webb J, et al. A bicuspid aortic valve imaging classification for the TAVR era. *J Am Coll Cardiol Img* 2016;9:1145-58.
66. Nishimura RA, Otto CM, Bonow RO, et al. 2014 AHA/ACC Guideline for the Management of Patients With Valvular Heart Disease: a report of the American College of Cardiology/American Heart Association Task Force on Practice Guidelines. *Circulation* 2014;129:e521-643.
67. Hiratzka LF, Creager MA, Isselbacher EM, et al. Surgery for aortic dilatation in patients with bicuspid aortic valves: a statement of clarification from the American College of Cardiology/American Heart Association Task Force on Clinical Practice Guidelines. *J Am Coll Cardiol* 2016;67:724-31.
68. Naito S, Gross T, Disha K, von Kodolitsch Y, Reichenspurner H, Girdauskas E. Late post-AVR progression of bicuspid aortopathy: link to hemodynamics. *Gen Thorac Cardiovasc Surg* 2017;65:252-8.
69. Baumgartner H, Falk V, Bax JJ, et al. 2017 ESC/EACTS Guidelines for the management of valvular heart disease. *Eur Heart J* 2017;38:2739-91.
70. Lancellotti P, Tribouilloy C, Hagendorff A, et al. Recommendations for the echocardiographic assessment of native valvular regurgitation: an executive summary from the European Association of Cardiovascular Imaging. *Eur Heart J Cardiovasc Imaging* 2013;14:611-44.
71. Ewe SH, Delgado V, van der Geest R, et al. Accuracy of three-dimensional versus two-dimensional echocardiography for quantification of aortic regurgitation and validation by three-dimensional three-directional velocity-encoded magnetic resonance imaging. *Am J Cardiol* 2013;112:560-6.
72. Zoghbi WA, Adams D, Bonow RO, et al. Recommendations for Noninvasive Evaluation of Native Valvular Regurgitation: A Report from the American Society of Echocardiography Developed in Collaboration with the Society for Cardiovascular Magnetic Resonance. *J Am Soc Echocardiogr* 2017;30:303-71.
73. Zhu D, Wei L, Cheung A, et al. Treatment of pure aortic regurgitation using a second-generation transcatheter aortic valve implantation system. *J Am Coll Cardiol* 2016;67:2803-5.
74. Frerker C, Schewel J, Schewel D, et al. Expansion of the indication of transcatheter aortic valve implantation—feasibility and outcome in “off-label” patients compared with “on-label” patients. *J Invasive Cardiol* 2015;27:229-36.
75. Seiffert M, Diemert P, Koschyk D, et al. Transapical implantation of a second-generation transcatheter heart valve in patients with non-calcified aortic regurgitation. *J Am Coll Cardiol Intv* 2013;6:590-7.
76. Testa L, Latib A, Rossi ML, et al. CoreValve implantation for severe aortic regurgitation: a multicentre registry. *EuroIntervention* 2014;10:739-45.
77. Roy DA, Schaefer U, Guetta V, et al. Transcatheter aortic valve implantation for pure severe native aortic valve regurgitation. *J Am Coll Cardiol* 2013;61:1577-84.
78. Yoon SH, Schmidt T, Bleiziffer S, et al. Transcatheter aortic valve replacement in pure native aortic valve regurgitation. *J Am Coll Cardiol* 2017;70:2752-63.
79. Kodali SK, Williams MR, Smith CR, et al. Two-year outcomes after transcatheter or surgical aortic-valve replacement. *N Engl J Med* 2012;366:1686-95.
80. Ludman PF, Moat N, de Belder MA, et al. Transcatheter aortic valve implantation in the United Kingdom: temporal trends, predictors of outcome, and 6-year follow-up: a report from the UK Transcatheter Aortic Valve Implantation (TAVI) Registry, 2007 to 2012. *Circulation* 2015;131:1181-90.
81. Spitzer E, Van Mieghem NM, Pibarot P, et al. Rationale and design of the Transcatheter Aortic Valve Replacement to UNload the Left ventricle in patients with ADvanced heart failure (TAVR UNLOAD) trial. *Am Heart J* 2016;182:80-8.

KEY WORDS aortic regurgitation, bicuspid aortic valve, echocardiography, multi-detector row computed tomography, transcatheter aortic valve replacement



Go to <http://www.acc.org/jacc-journals-cme> to take the CME/MOC/ECME quiz for this article.