



**Universiteit
Leiden**
The Netherlands

Role of cardiovascular imaging in cancer patients receiving cardiotoxic therapies: a position statement on behalf of the Heart Failure Association (HFA), the European Association of Cardiovascular Imaging (EACVI) and the Cardio-Oncology Council of the European Society of Cardiology (ESC)

Celutkiene, J.; Pudil, R.; Lopez-Fernandez, T.; Grapsa, J.; Nihoyannopoulos, P.; Bergler-Klein, J.; ... ; Lyon, A.R.

Citation

Celutkiene, J., Pudil, R., Lopez-Fernandez, T., Grapsa, J., Nihoyannopoulos, P., Bergler-Klein, J., ... Lyon, A. R. (2020). Role of cardiovascular imaging in cancer patients receiving cardiotoxic therapies: a position statement on behalf of the Heart Failure Association (HFA), the European Association of Cardiovascular Imaging (EACVI) and the Cardio-Oncology Council of the European Society of Cardiology (ESC). *European Journal Of Heart Failure*, 22(9), 1504-1524. doi:10.1002/ejhf.1957

Version: Publisher's Version
License: [Creative Commons CC BY 4.0 license](https://creativecommons.org/licenses/by/4.0/)
Downloaded from: <https://hdl.handle.net/1887/3232671>

Note: To cite this publication please use the final published version (if applicable).

Role of cardiovascular imaging in cancer patients receiving cardiotoxic therapies: a position statement on behalf of the Heart Failure Association (HFA), the European Association of Cardiovascular Imaging (EACVI) and the Cardio-Oncology Council of the European Society of Cardiology (ESC)

Jelena Čelutkienė^{1,2*}†, Radek Pudil³, Teresa López-Fernández⁴, Julia Grapsa⁵, Petros Nihoyannopoulos^{6,7}, Jutta Bergler-Klein⁸, Alain Cohen-Solal⁹, Dimitrios Farmakis^{10,11}, Carlo Gabriele Tocchetti¹², Stephan von Haehling¹³, Vassilis Barberis¹⁴, Frank A. Flachskampf¹⁵, Indrė Čėponienė¹⁶, Eva Haegler-Laube¹⁷, Thomas Suter¹⁷, Tomas Lapinskas¹⁶, Sanjay Prasad^{18,19}, Rudolf A. de Boer²⁰, Kshama Wechalekar²¹, Markus S. Anker²², Zaza Iakobishvili^{23,24}, Chiara Bucciarelli-Ducci²⁵, Jeanette Schulz-Menger^{26,27}, Bernard Cosyns²⁸, Oliver Gaemperli²⁹, Yury Belenkov³⁰, Jean-Sébastien Hulot³¹, Maurizio Galderisi^{32†}, Patrizio Lancellotti³³, Jeroen Bax³⁴, Thomas H. Marwick³⁵, Ovidiu Chioncel^{36,37}, Tiny Jaarsma^{38,39}, Wilfried Mullens⁴⁰, Massimo Piepoli^{41,42}, Thomas Thum⁴³, Stephane Heymans^{44,45,46}, Christian Mueller⁴⁷, Brenda Moura⁴⁸, Frank Ruschitzka⁴⁹, Jose Luis Zamorano^{50,51,52}, Giuseppe Rosano⁵³, Andrew J.S. Coats⁵⁴, Riccardo Asteggiano⁵⁵, Petar Seferovic⁵⁶, Thor Edvardsen^{57,58}, and Alexander R. Lyon^{19,59†}

¹Clinic of Cardiac and Vascular Diseases, Institute of Clinical Medicine, Faculty of Medicine, Vilnius University, Vilnius, Lithuania; ²State Research Institute Centre For Innovative Medicine, Vilnius, Lithuania; ³First Department of Medicine - Cardioangiology, Charles University Prague, Medical Faculty and University Hospital Hradec Králové, Hradec Kralove, Czech Republic; ⁴Cardiology Department, La Paz University Hospital, IdiPAZ, Ciber CV, Madrid, Spain; ⁵Department of Cardiology, St Bartholomew Hospital, Barts Health Trust, London, UK; ⁶Unit of Inherited Cardiovascular Diseases/Heart Center of the Young and Athletes, First Department of Cardiology, Hippokrateion General Hospital, National and Kapodistrian University of Athens, Athens, Greece; ⁷National Heart and Lung Institute Imperial College London, Hammersmith Hospital, London, UK; ⁸Department of Cardiology, Medical University of Vienna, Vienna, Austria; ⁹UMR-S 942, Cardiology Department, Hôpital Lariboisière, AP-HP, Université de Paris, Paris, France; ¹⁰University of Cyprus Medical School, Nicosia, Cyprus; ¹¹Cardio-Oncology Clinic, Heart Failure Unit, Department of Cardiology, Athens University Hospital Attikon, National and Kapodistrian University of Athens, Athens, Greece; ¹²Department of Translational Medical Sciences, and Interdepartmental Center for Clinical and Translational Research (CIRCET), Federico II University, Naples, Italy; ¹³Department of Cardiology and Pneumology, University of Göttingen Medical Centre, Göttingen, Germany; ¹⁴American Medical Center, American Heart Institute, Nicosia, Cyprus; ¹⁵Department of Medical Sciences, Uppsala University, Clinical Physiology and Cardiology, Akademiska Hospital, Uppsala, Sweden; ¹⁶Department of Cardiology, Medical Academy, Lithuanian University of Health Sciences, Kaunas, Lithuania; ¹⁷Department of Cardiology, Inselspital, University of Bern, Bern, Switzerland;

*Corresponding author. Clinic of Cardiac and Vascular Diseases, Institute of Clinical Medicine, Faculty of Medicine, Vilnius University, Santariškių 2, LT-08661, Vilnius, Lithuania. Tel: +370 616 00180, Fax: +370 5 2501742, Email: jelena.celutkiene@santa.lt

†These authors contributed equally.

[Correction added on 16 March 2021, after first online publication: the affiliations of the author Giuseppe Rosano have been corrected to 'Centre for Clinical and Basic Research, Department of Medical Sciences, IRCCS San Raffaele Pisana, Rome, Italy', and succeeding affiliations and their respective link to the authors were renumbered in this online version.]

¹⁸Department of Cardiac Magnetic Resonance, Royal Brompton Hospital, London, UK; ¹⁹National Heart and Lung Institute, Imperial College, London, UK; ²⁰Department of Cardiology, University Medical Center Groningen, University of Groningen, Groningen, The Netherlands; ²¹Department of Nuclear Medicine, Royal Brompton Hospital, London, UK; ²²Division of Cardiology and Metabolism, Department of Cardiology, Charité; and Berlin Institute of Health Center for Regenerative Therapies (BCRT); and DZHK (German Centre for Cardiovascular Research), partner site Berlin; and Department of Cardiology, Charité Campus Benjamin Franklin, Berlin, Germany; ²³Sackler Faculty of Medicine, Tel Aviv University, Tel Aviv, Israel; ²⁴Tel Aviv-Jaffa District, Clalit Health Services, Tel Aviv, Israel; ²⁵Bristol Heart Institute, Bristol NIHR Biomedical Research Centre and Clinical Research and Imaging Centre (CRIC) Bristol, University Hospitals Bristol NHS Trust and University of Bristol, Bristol, UK; ²⁶Working Group on Cardiovascular Magnetic Resonance, Experimental and Clinical Research Center a joint cooperation between the Charité - Universitätsmedizin Berlin, Department of Internal Medicine and Cardiology and the Max-Delbrueck Center for Molecular Medicine, and HELIOS Klinikum Berlin Buch, Department of Cardiology and Nephrology, Berlin, Germany; ²⁷DZHK (German Centre for Cardiovascular Research), partner site Berlin, Berlin, Germany; ²⁸Department of Cardiology, CHVZ (Centrum voor Hart en Vaatziekten), ICMI (In Vivo Cellular and Molecular Imaging) Laboratory, Universitair Ziekenhuis Brussel, Brussels, Belgium; ²⁹Heart Clinic Hirslanden, Hirslanden Hospital, Zurich, Switzerland; ³⁰I.M. Sechenov's First Moscow State Medical University of Ministry of Health (Sechenov University), Moscow, Russia; ³¹Université de Paris, CIC1418, Paris Cardiovascular Research Center, INSERM, Paris, France; ³²Department of Advanced Biomedical Sciences, Federico II University Hospital, Naples, Italy; ³³University of Liège Hospital, GIGA Cardiovascular Sciences, Department of Cardiology, CHU Sart Tilman, Liège, Belgium; ³⁴Department of Cardiology, Leiden University Medical Centre, Leiden, The Netherlands; ³⁵Baker Heart and Diabetes Institute, Melbourne, Australia; ³⁶Emergency Institute for Cardiovascular Diseases C.C. Iliescu, Bucuresti, Romania; ³⁷University of Medicine Carol Davila, Bucuresti, Romania; ³⁸Department of Health, Medicine and Caring Sciences, Linköping University, Linköping, Sweden; ³⁹Julius Center for Health Sciences and Primary Care, University Medical Center Utrecht and Utrecht University, Utrecht, The Netherlands; ⁴⁰Ziekenhuis Oost Limburg, University Hasselt, Genk, Belgium; ⁴¹Heart Failure Unit, Cardiology, Guglielmo da Saliceto Hospital, Piacenza, Italy; ⁴²University of Parma, Parma, Italy; ⁴³Hannover Medical School, Institute of Molecular and Translational Therapeutic Strategies (IMTTS), Hannover, Germany; ⁴⁴Department of Cardiology, CARIM School for Cardiovascular Diseases Faculty of Health, Medicine and Life Sciences, Maastricht University, Maastricht, The Netherlands; ⁴⁵William Harvey Research Institute, Barts Heart Centre, Queen Mary University of London, Charterhouse Square, London, UK; ⁴⁶Department of Cardiovascular Sciences, Centre for Molecular and Vascular Biology, KU Leuven, Leuven, Belgium; ⁴⁷Department of Cardiology and Cardiovascular Research Institute Basel (CRIB), University Hospital Basel, University of Basel, Basel, Switzerland; ⁴⁸Cardiology Department, Military Hospital, and CINTESIS, CardioCare, Faculty of Medicine, Porto University, Porto, Portugal; ⁴⁹University Heart Center, Department of Cardiology, University Hospital Zurich, Zurich, Switzerland; ⁵⁰Cardiology Department, University Hospital Ramón y Cajal, Madrid, Spain; ⁵¹University Alcalá, Madrid, Spain; ⁵²CIBERCV, Instituto de Salud Carlos III (ISCIII), Madrid, Spain; ⁵³Centre for Clinical and Basic Research, Department of Medical Sciences, IRCCS San Raffaele Pisana, Rome, Italy; ⁵⁴IRCCS San Raffaele Pisana, Rome, Italy; ⁵⁵Cardiologist in Practice, Turin, Italy; ⁵⁶University of Belgrade Faculty of Medicine and Serbian Academy of Sciences and Arts, Belgrade, Serbia; ⁵⁷Department of Cardiology, Oslo University Hospital, Rikshospitalet, Oslo, Norway; ⁵⁸Faculty of Medicine, University of Oslo, Oslo, Norway; and ⁵⁹Cardio-Oncology Service, Royal Brompton Hospital, London, UK

Received 22 February 2020; revised 8 June 2020; accepted 1 July 2020; online publish-ahead-of-print 21 August 2020

Cardiovascular (CV) imaging is an important tool in baseline risk assessment and detection of CV disease in oncology patients receiving cardiotoxic cancer therapies. This position statement examines the role of echocardiography, cardiac magnetic resonance, nuclear cardiac imaging and computed tomography in the management of cancer patients. The Imaging and Cardio-Oncology Study Groups of the Heart Failure Association (HFA) of the European Society of Cardiology (ESC) in collaboration with the European Association of Cardiovascular Imaging (EACVI) and the Cardio-Oncology Council of the ESC have evaluated the current evidence for the value of modern CV imaging in the cardio-oncology field. The most relevant echocardiographic parameters, including global longitudinal strain and three-dimensional ejection fraction, are proposed. The protocol for baseline pre-treatment evaluation and specific surveillance algorithms or pathways for anthracycline chemotherapy, HER2-targeted therapies such as trastuzumab, vascular endothelial growth factor tyrosine kinase inhibitors, BCr-Abl tyrosine kinase inhibitors, proteasome inhibitors and immune checkpoint inhibitors are presented. The indications for CV imaging after completion of oncology treatment are considered. The typical consequences of radiation therapy and the possibility of their identification in the long term are also summarized. Special populations are discussed including female survivors planning pregnancy, patients with carcinoid disease, patients with cardiac tumours and patients with right heart failure. Future directions and ongoing CV imaging research in cardio-oncology are discussed.

Keywords

Imaging • Cardio-oncology • Cardiotoxicity • Heart failure • Echocardiography • Cardiac magnetic resonance • Computed tomography • Global longitudinal strain • Nuclear imaging

Introduction

Cardiovascular disease (CVD) and cardiovascular (CV) complications in cancer patients present a growing medical problem, causing substantial morbidity and premature mortality in this population. An increasing prevalence of pre-existing CVD and the CV toxicity of both established and emerging cancer treatments including anthracycline (AC) chemotherapy, targeted therapies such as trastuzumab, proteasome inhibitors (PIs), immune checkpoint inhibitors (ICI) and vascular endothelial growth factor inhibitors (VEGFi), along with biological treatments and radiation therapy collectively contribute to this new epidemic. There is an urgent clinical need to modernize and validate monitoring algorithms for

the early detection of CVD in cancer patients receiving potentially cardiotoxic treatments, and to intervene prior to the development of manifest CVD. Considerations are also needed as to which cancer survivors require screening after completion of oncology treatment.

Contemporary cardiac imaging is a valuable instrument to help in multiple ways—for baseline risk stratification, timely diagnosis of early CVD and of cardiac dysfunction, both during and following treatment, for the identification of cancer patients who may benefit from cardioprotective treatments whilst continuing oncology treatment, and prognostication to select cancer patients who may require long-term CVD follow-up. The Imaging and Cardio-Oncology Study Groups of the Heart Failure Association

(HFA) of the European Society of Cardiology (ESC) in collaboration with the European Association of Cardiovascular Imaging (EACVI) and the Cardio-Oncology Council of the ESC have evaluated the current evidence for the role of CV imaging including echocardiography, cardiac magnetic resonance (CMR), computed tomography (CT) and nuclear testing before, during and after cancer therapy. This position statement summarizes their consensus regarding the application of modern cardiovascular imaging in cancer patients. It focuses on the detection and assessment of myocardial dysfunction and heart failure (HF), the optimal timing for monitoring in various cardiotoxic cancer treatments, special populations and future developments in this field. The authors aim to provide cardiologists, oncologists, haematologists and general medical physicians with a framework for using cardiac imaging for the timely diagnosis of CV involvement and for prevention of CVD in cancer patients and survivors. This position statement examines CV imaging and has been developed in parallel to a position statement addressing the role of cardiac biomarkers in cancer patients and detailed cancer-treatment specific baseline risk assessment.¹ CV imaging and cardiac biomarkers in baseline risk assessment and in surveillance receiving cardiotoxic cancer therapies are synergistic and complementary approaches, and it is important that they should be considered together. A future HFA position statement will review the evidence and provide details of the specific treatment interventions recommended for the different cardiotoxicities detected using CV imaging for a range of cancer therapies. These are complex and beyond the scope of this article.

We emphasize that the suggested surveillance pathways and frequencies of use are based on expert opinion and experience, since validation studies are lacking in this area, especially with regard to cost-effectiveness and effect on long-term outcomes.

General principles

Cardiac imaging in general, and echocardiography in particular, play a central role in the expanding field of cardio-oncology. Given that the current definitions of cardiotoxicity in many guidelines and oncology trials are based on a reduction of left ventricular ejection fraction (LVEF),^{2,3} many oncologists restrict cardiotoxicity evaluation to measurement of this single parameter only. However, it is well known in contemporary cardiology that a normal LVEF does not exclude significant myocardial dysfunction.^{4,5} In addition, there are important limitations of serial measurement of LVEF such as physiological temporal and operator variability, and haemodynamic load-dependence. Concurrent measurement of blood pressure may help to avoid misinterpretations in cases of blood pressure and blood volume changes due to fluid excess during intravenous chemotherapy or fluid loss due to adverse reactions.⁶ Temporal variability of LVEF measured by two-dimensional (2D) echocardiography using biplane Simpson's method has been reported to be approximately 10%, with the same level of 10% seen for inter- and intra-observer variability.⁷ Thus, the LVEF should be reassessed to confirm the development of subclinical left ventricular (LV) dysfunction.²

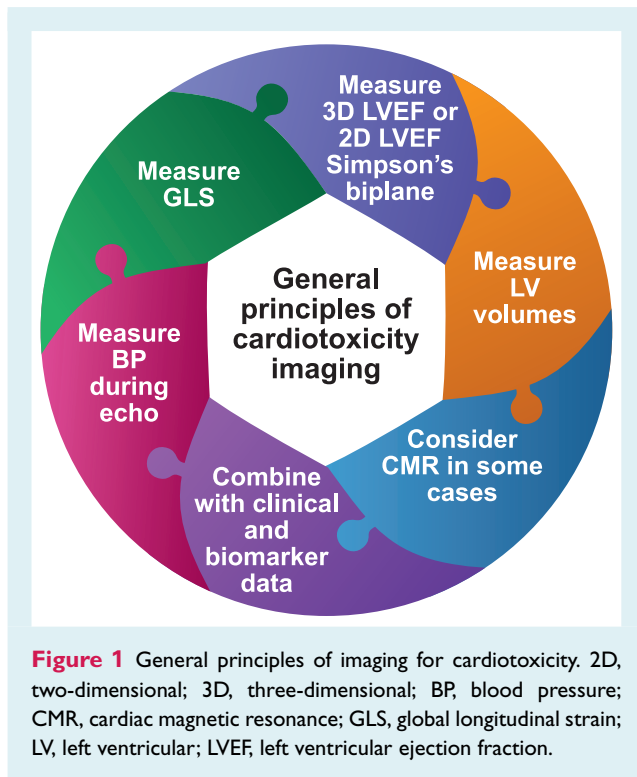
Three-dimensional (3D) echocardiography should be utilized for the assessment of LVEF and cardiac volumes when available and

with appropriate expertise and experience due to its lower inter-, intra-observer and test–retest variability.⁷ Adequate inter-reader agreement in an echocardiography laboratory may be achieved by standardizing the analytical approach through dedicated quality audit sessions.⁸ 3D echocardiography is likely to become more widely accepted in routine practice due to improved image acquisition and the implementation of semi- or fully automated analysis algorithms.⁴ The feasibility of 3D LVEF in breast cancer patients with adequate echocardiographic images was 88% at baseline and 66% after AC therapy, reduced during follow-up due to concomitant radiotherapy (RT), left mastectomy, left breast prosthesis and other patient factors.⁹

When transthoracic echocardiographic image quality is inadequate for the application of Simpson's method, which is more common in cancer patients who have previously undergone left breast or left chest surgery and/or RT, and sometimes in very cachectic patients, adding contrast media or using alternative imaging modalities such as CMR can be considered for serial monitoring of LV size and function. The latter technique, although less feasible and more expensive, has improved accuracy and reproducibility with the coefficient of variation for CMR LVEF being reported at approximately 4%.¹⁰ The historical method of planar imaging, multigated acquisition (MUGA) scan, used for serial assessment in earlier clinical trials, is not recommended as a first-line cardiac imaging modality, due to exposure to ionizing radiation and advances in ultrasound and CMR modalities.¹¹ Single photon emission computed tomography (SPECT) MUGA acquired with high-sensitivity cadmium zinc telluride cameras can be done with lower radiation dose, faster image acquisition time and improved reproducibility.¹¹

Global longitudinal strain (GLS) has emerged as a new marker of subclinical ventricular dysfunction demonstrating stronger association with prognosis than LVEF in non-oncology heart disease populations.^{12,13} This reflects the fact that LV longitudinal function may be reduced first and this component of ventricular function has a limited influence upon LVEF.¹⁴ Several researchers have reported a higher sensitivity and either a non-inferior or superior test–retest reliability of GLS compared to LVEF.^{5,14,15} A number of observational studies show potential for reduction in GLS to accurately predict a future decrease in LVEF and significant cardiotoxicity.^{14,16,17}

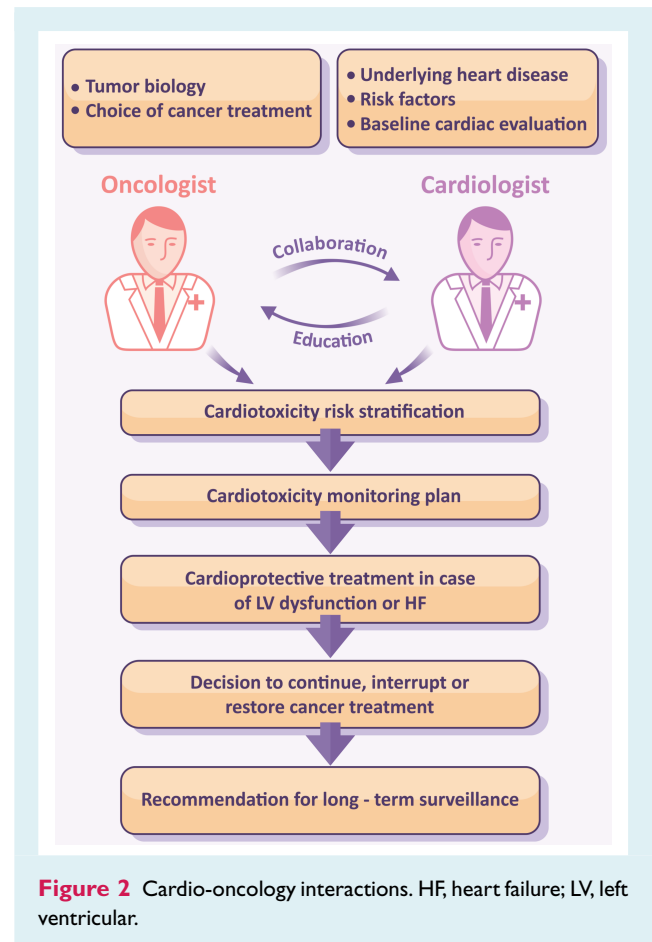
A recent study in 116 patients with human epidermal growth factor receptor 2 (HER2)-positive breast cancer supported the serial surveillance using GLS to guide cardioprotection and maintain patients on uninterrupted trastuzumab therapy.¹⁸ The ongoing SUCCOUR study is prospectively assessing the value of initiating cardioprotective medication triggered by the reduction of GLS vs. waiting for a decline in 3D LVEF.¹⁹ GLS should be based on three apical (long-axis) views and not replaced by single-view longitudinal strain due to substantial disagreement in the diagnosis of cardiotoxicity.²⁰ Although less feasible and reproducible, 2D- or 3D-derived global circumferential strain may also serve as additional markers of myocardial dysfunction but require more studies for validation.^{21,22} GLS surveillance may become a more sensitive strategy for early detection of cardiotoxicity and guide timing of cardioprotective treatment (Figure 1).



Several cardiotoxic cancer treatments including AC and trastuzumab have been shown to cause a persistent reduction in LVEF and GLS.⁶ Other cancer drugs may cause different forms of myocardial toxicity where LVEF reduction is not the primary manifestation. For example, ICIs cause myocarditis, which can lead to severe HF, cardiogenic shock and death, but in 38% of cases may also occur even without a fall in LVEF.^{23,24} Thus, decision-making concerning the continuation or interruption of such potentially life-saving therapy should no longer rely solely on the single, surrogate echocardiographic parameter (LVEF) which mainly reflects changes in LV volumes, rather than function.

Several small studies have analysed the serial measurement of LV diastolic function using tissue and transmitral Doppler (E/e') in various cancer populations.^{25,26} Most have not found improved sensitivity compared with measurements of LV systolic function for detection of cardiotoxicity. A sequential relation between diastolic and systolic impairment has not been proven, either in experimental, or in clinical settings. Initial investigations of left atrial size and function have shown that early atrial dilatation and a reduction in conduit and reservoir strain may be potential markers of cardiotoxicity.^{27,28}

Current recommendations of screening for cardiotoxicity using serial LVEF measurement remain sub-optimally implemented in the majority of patients with breast cancer.^{29,30} In one study baseline evaluation was performed in only 74% of patients receiving HER2-targeted therapy, and only 46% were assessed repeatedly during treatment.³¹ Quality of care may be improved by establishing dedicated cardio-oncology services delivering



structured pathways for baseline risk stratification and surveillance (Figure 2).^{32,33}

Assessment of cardiotoxicity risk

Systematic cardiac surveillance with more sensitive technologies and a higher frequency of measurements will lead to a greater incidence of detected cardiotoxicity.³¹ In order to maintain a balance between the rational use of resources and maximal patient safety, we recommend a personalized approach taking into account the patients' baseline risk of cardiotoxicity (Table 1). Cancer patients scheduled to receive potentially cardiotoxic cancer therapies are evaluated pre-treatment for cardiotoxicity risk and stratified into three categories (low, medium and high) according to the baseline CV profile and risk factors, pre-existing CVD, type and dose of cancer therapy.

New information on the risk of myocardial dysfunction was obtained analysing follow-up data in adult survivors of childhood cancer.³⁴ Even in this relatively young population, the effect size of traditional risk factors for HF, including hypertension, insulin resistance, obesity, was comparable or even higher than effect size of cancer treatment-related risk factors, such as an AC dose, RT, or current age. Traditional risk factors, including age, coronary artery disease, diabetes, hypertension, atrial fibrillation, renal

Table 1 Assessment of cardiotoxicity risk

Therapy-related factors	Patient-related factors
<p>Low risk of cardiotoxicity</p> <p>Lower dose AC (e.g. doxorubicin <200 mg/m², epirubicin <300 mg/m²), liposomal formulations</p> <p>Trastuzumab without AC</p> <p>Medium risk of cardiotoxicity</p> <p>Modest-dose AC (doxorubicin 200–400 mg/m² and epirubicin 300–600 mg/m²)</p> <p>AC followed by trastuzumab</p> <p>VEGF tyrosine kinase inhibitors</p> <p>Second- and third-generation Bcr-Abl tyrosine kinase inhibitors</p> <p>Proteasome inhibitors</p> <p>Combination immune checkpoint inhibitors</p> <p>High risk of cardiotoxicity</p> <p>Simultaneous AC and trastuzumab</p> <p>High-dose AC (doxorubicin ≥400 mg/m² or epirubicin ≥600 mg/m²)</p> <p>Modest-dose AC plus left chest radiation therapy</p> <p>Elevated cardiac troponin post-AC prior to HER2-targeted therapy</p> <p>High-dose radiation therapy to central chest including heart in radiation field ≥30 Gy</p> <p>VEGF tyrosine kinase inhibitors following previous AC chemotherapy</p>	<p>Age >18 and <50 years</p> <p>Age 50–64 years</p> <p>1–2 CV risk factors such as hypertension, dyslipidaemia, obesity, insulin resistance, smoking</p> <p>Age ≥65 years</p> <p>>2 CV risk factors as hypertension, dyslipidaemia, obesity, smoking</p> <p>Diabetes</p> <p>Underlying CV disease: CAD, PAD, CMP, severe VHD, heart failure</p> <p>Reduced or low-normal LVEF (50–54%) pre-treatment</p> <p>Prior cancer therapy</p>

Abr, active Bcr-related; AC, anthracycline; Bcr, breakpoint cluster region; CAD, coronary artery disease; CMP, cardiomyopathy; CV, cardiovascular; HER2, human epidermal growth factor receptor 2; LVEF, left ventricular ejection fraction; PAD, peripheral artery disease; VEGF, vascular endothelial growth factor; VHD, valvular heart disease.

failure, have also been predominant predictors of prevalent HF or cardiomyopathy in older women (mean age 74 years) after adjuvant trastuzumab therapy.³⁵ If LVEF falls to a marginally normal range (50–54%) before treatment, the incidence of HF rises remarkably in cancer patients receiving AC and trastuzumab.^{36,37} New targeted therapies including VEGF tyrosine kinase inhibitors (VEGF-TKIs), second- and third-generation Bcr-Abl TKIs for chronic myeloid leukaemia, and PIs for multiple myeloma (MM), are associated with an increased risk of HF and other CV toxicities.

Definitions of cardiotoxicity

The cancer therapy-related cardiac dysfunction (CTRCD) definition, which is adopted in the 2016 ESC Cardio-Oncology position statement, is defined as any reduction of LVEF to below 50% or a >10% reduction from baseline falling below the lower limit of normal.^{2,3} Current echocardiography recommendations set low normal value of 2D LVEF as 54% for women and 52% for men³⁸ and hence in the previous EACVI position statement a reduction of LVEF below 53% was classified as abnormal.²

Changes in the myocardial deformation parameter GLS may also be considered an early sign of CTRCD.^{39–42} When detected it correlates with focal and diffuse fibrosis.⁴³ During follow-up LV GLS falling below (–)18% into the abnormal range (0% to –17.9%) or a >15% relative decrease of this marker and to below the lower limit of normal may be considered abnormal.^{2,3,12}

There is a variation in the definition of CTRCD across guidelines, position statements and oncology trials (Table 2); numerous mechanisms of cardiotoxicity inherent to different cancer drug classes add to the complexity of this condition. Latest accumulating data on the specific incidence and reversibility of cardiotoxicity have forced the authors to abandon the outdated concept of type I and type II cardiotoxicity.⁴⁴ The recently proposed Royal Brompton Hospital classification of myocardial toxicity incorporated alterations of biomarkers and/or GLS as evidence of early biochemical, functional or early mixed cardiotoxicity where oncology treatment should continue but consideration to start cardioprotective medication or implement closer monitoring is advised.³²

Cardiovascular imaging at baseline pre-treatment

It is essential to evaluate cardiac function with echocardiography before starting potentially cardiotoxic therapy in every cancer patient as a baseline for monitoring and for risk stratification (online supplementary Figure S1, online supplementary Video S1). The most relevant parameters for initial and subsequent echocardiographic assessment are presented in Table 3. CMR is recommended in cases with poor quality echocardiographic images, in patients with complex pre-existing heart diseases (for example hypertrophic or dilated cardiomyopathy). In patients with suspected angina, stress echocardiography, vasodilator stress CMR or SPECT are recommended to diagnose the presence and extent

Table 2 The difference in published definitions of cardiotoxicity

	ESC	EACVI/ASE	ESMO/CREC	ASCO	CTCAE	FDA ^a
Cut-off for ejection fraction	<50%	<53%	<55%	<55%	<50%	–
Change in EF (absolute reduction)	>10% decline from baseline	>10% decline from baseline	Decline \geq 5% to less than 55% with symptoms, or decline \geq 10% to below 55% without symptoms	–	Grade 2 (resting EF 40–50%; 10–19% drop from baseline); Grade 3 (resting EF 20–39%; >20% drop from baseline); Grade 4 (resting EF <20%)	>20% decrease if EF remained normal, or >10% decrease if EF is less than normal
GLS	Relative reduction in GLS >15% from baseline	Relative reduction in GLS >15% from baseline	–	Relative reduction in GLS >15% from baseline	–	–

ASCO, American Society of Clinical Oncology; ASE, American Society of Echocardiography; CREC, Cardiac Review and Evaluation Committee; CTCAE, Common Terminology Criteria for Adverse Events (US Departments of Health and Human Services); EACVI, European Association of Cardiovascular Imaging; EF, ejection fraction; ESC, European Society of Cardiology; ESMO, European Society of Medical Oncology; FDA, US Food and Drug Administration; GLS, global longitudinal strain.

^aFor anthracyclines.

Table 3 Parameters relevant for cardio-oncology surveillance: echocardiography protocol

Parameters	Clinically significant changes	Comments
LV size and function		
LVEF by Simpson's 2D, or (semi)automatic 3D	Drop >10% (percentage points) for 2D, >5% for 3D from pre-treatment value	Decline of LVEF to value <40–50% suggests initiation of cardioprotection
2D/3D GLS, GCS	Relative reduction by >10–15% from pre-treatment value and to below lower limit of normal	Average from three apical views; do not use single-view value
LV 2D/3D systolic and diastolic volumes	Increase by 15 mL for ESV, 30–35 mL for EDV	Increase in volumes reflects remodelling and fluid status
RV function, pulmonary artery pressure and volaemia		
Markers of systolic RV function	TAPSE <1.7 cm, FAC <35%, RV free wall strain <20%, 3D RVEF <45%	Show prognostic value in heart failure and pulmonary hypertension
Velocity of TR	Peak systolic TR velocity >2.8 m/s	Indicates probable pulmonary hypertension
IVC diameter, collapse on inspiration	Dilatation >2.1 cm or narrowing <1.3 cm	Relates to hypervolaemia or dehydration, respectively

2D, two-dimensional; 3D, three-dimensional; EDV, end-diastolic volume; ESV, end-systolic volume; FAC, fractional area change; GCS, global circumferential strain; GLS, global longitudinal strain; IVC, inferior vena cava; LV, left ventricular; LVEF, left ventricular ejection fraction; RV, right ventricular; RVEF, right ventricular ejection fraction; TAPSE, tricuspid annular plane systolic excursion; TR, tricuspid regurgitation.

of myocardial ischaemia and assess the need for anti-anginal medications or alternative treatment. In patients with chest pain but no history of coronary disease, CT coronary angiography (CTCA) is recommended as an alternative to functional testing.⁴⁵

Echocardiography during anthracycline chemotherapy

Before starting AC therapy, we recommend classifying the cardiotoxicity risk as low, medium or high according to

therapy-related and patient-related factors (Table 1). The incidence of cardiac events during next 10 years after AC therapy accounts for 2% to 5% in the medium-risk and >5% in the high-risk group.³⁹ This empirical approach aims to personalize echocardiographic surveillance (Table 4, Figure 3), including 3D LVEF and GLS when available, intensifying follow-up in high-risk patients and reducing frequency in low-risk patients. In AC cardiotoxicity, most cases occur during the first year after completion of chemotherapy, and therefore assessments at 6 and/or 12 months post-completion of chemotherapy should be considered⁴⁶ (Table 4, Figure 4, online supplementary Figure S2, online supplementary Videos S2 and S3).

Table 4 Echocardiographic surveillance during and after anthracycline chemotherapy

Baseline risk of cardiotoxicity	During chemotherapy	Following chemotherapy
Low	<ul style="list-style-type: none"> • Baseline • Following cycle completing cumulative lifetime dose of 240 mg/m² doxorubicin or equivalent^a • Every additional 100 mg/m² doxorubicin above 240 mg/m² or every 2 cycles 	<ul style="list-style-type: none"> • 12 months after final cycle • 5 yearly review
Medium	<ul style="list-style-type: none"> • Baseline • Following 50% of planned total treatment or every 2 cycles (optional) • Following cycle completing cumulative lifetime cycle of 240 mg/m² doxorubicin or equivalent^a 	<ul style="list-style-type: none"> • 12 months after final cycle • 5 yearly review
High	<ul style="list-style-type: none"> • Baseline • Every 2 cycles • Consider after every cycle above 240 mg/m² doxorubicin or equivalent^b 	<ul style="list-style-type: none"> • 6 months after final cycle^c • 12 months after final cycle • Annually for 2 or 3 years thereafter, and then in 3- to 5-year intervals for life

cycle, chemotherapy infusion.

NB. All low and medium cardiovascular risk cancer patients who develop new cardiac symptoms or new left ventricular dysfunction during treatment are reclassified as high cardiovascular risk and if chemotherapy continues, they should follow the high-risk surveillance.

^a240 mg/m² doxorubicin is equivalent to 360 mg/m² epirubicin, 320 mg/m² daunorubicin and 50 mg/m² idarubicin.

^b300 mg/m² doxorubicin is equivalent to 420 mg/m² epirubicin, 400 mg/m² daunorubicin and 60 mg/m² idarubicin.

^cDepending upon symptoms and evidence of new left ventricular dysfunction during treatment.

Variable remodelling responses to AC chemotherapy can occur, including cardiomyocyte atrophy with reduced LV mass and dysfunction but relative preservation of LVEF.⁴⁷

In the long-term follow-up after completion of cancer therapy, repeated surveillance echocardiographic evaluation is recommended in selected populations such as young patients who received high total cumulative AC doses (>400 mg/m² doxorubicin or equivalent), patients with significant pre-existing CVD, female cancer survivors planning to become pregnant or at the end of the first trimester of pregnancy,⁴⁸ and survivors who are planning to compete in high-intensity exercise, for example, marathons, endurance cycling, triathlons.⁴⁹

Echocardiography during HER2-targeted treatment (trastuzumab, pertuzumab, trastuzumab emtansine, lapatinib, neratinib)

In patients on HER2-targeted therapies, standard surveillance according to the product license includes echocardiography at baseline (with 3D LVEF and GLS if available) and every 3 months during therapy.^{50,51} Similar to the monitoring during AC described above, we suggest taking into account baseline risk of cardiotoxicity with a frequency of surveillance personalized to this baseline risk (Table 5, Figure 5).^{35,36} The same frequency of imaging is recommended for patients starting trastuzumab alone, trastuzumab and pertuzumab, ado-trastuzumab or trastuzumab

emtansine (T-DM1) or oral HER2-targeted therapies. There are also important considerations for the different cancer populations (early invasive vs. metastatic HER2-positive breast cancer, HER2-positive gastric cancer).

The evidence for long-term follow-up echocardiography in patients following adjuvant HER2-targeted therapies for early invasive breast cancer is limited. Low-risk patients who are asymptomatic may not require any follow-up imaging, but a single review at 6–12 months following the final cycle may be considered if they have also received neoadjuvant or adjuvant AC. In asymptomatic patients with medium or high baseline cardiotoxicity risk, a follow-up echocardiogram and clinical assessment should be considered 3–6 months and 12 months after the final dose of HER2-targeted treatment (Table 5, Figure 5). Any patient who has new LV impairment or cardiotoxicity during HER2-targeted therapy will require follow-up assessment after starting any cardiac treatment to assess function and safety to continue HER2-targeted therapies, and at completion of treatment to assess for recovery and guide weaning of cardiac medication.

In asymptomatic patients who require long-term treatment in the setting of metastatic disease, echocardiography is recommended with the same frequency as for adjuvant trastuzumab during year 1, and then less frequent if cardiac biomarkers and LV function remain normal, e.g. 4 monthly in year 2, and 6 monthly thereafter in low-risk patients.⁵² Surveillance should continue at the same frequency if disease progression requires switching from trastuzumab and pertuzumab to T-DM1.⁵³ If new cardiotoxicity or cardiac symptoms develop, then more frequent monitoring is recommended.




Figure 3 A surveillance pathway using biomarkers and echocardiography for cancer patients receiving six cycles of anthracycline chemotherapy with timing based upon baseline cardiovascular risk. Pathways for low risk, medium risk and high risk are presented. ABVD, doxorubicin, bleomycin, vinblastine, dacarbazine; B, baseline pre-treatment; C, cycle of chemotherapy; M, months post-final cycle; R-CHOP, cyclophosphamide, doxorubicin, vincristine, prednisone with rituximab. *Optional additional assessment timepoints.

Echocardiography during vascular endothelial growth factor inhibitor and Bcr-Abl tyrosine kinase inhibitor treatment

Left ventricular dysfunction occurs in 5% to 10% of patients receiving VEGFi TKIs and 2% to 10% of patients receiving second- and third-generation Bcr-Abl TKIs due to direct myocardial toxicity, uncontrolled hypertension and exacerbation of pre-existing CVD.^{43,54–60} In the absence of prospective studies providing evidence, it is the opinion of the authors that echocardiography should be considered every 4 months during the first year in all patients receiving these treatments, with an additional early assessment 2–4 weeks after starting treatment in patients with high baseline CV risk.⁶¹ In patients who require long-term treatment with VEGFi or second- and third-generation Bcr-Abl TKIs 6–12 monthly echocardiography should be considered, as long as they remain asymptomatic and without clinical events during the first year. In patients who are candidates for dasatinib for chronic myeloid leukaemia, pre-treatment echocardiography screening to assess for pre-existing pulmonary hypertension is recommended, as well as maintaining a low threshold for repeat echocardiography if cardiac symptoms develop.⁶² The decision to stop the treatment if new pulmonary arterial hypertension is detected may require right heart catheterization in selected cases.⁶³

Echocardiography during proteasome inhibitor treatment

Proteasome inhibitors including bortezomib, carfilzomib and ixazomib, are targeted therapies for MM. Bortezomib introduces a modestly increased risk for cardiac disorders in a meta-analysis by the Cochrane group compared to control (odds ratio 1.74, 95% confidence interval 1.17–2.58).⁶⁴ Carfilzomib, which is an irreversible PI, has a higher risk of CV toxicity including myocardial infarction and LV dysfunction, as well as increased incidence of total symptomatic HF (7.1% vs. 4.1%) and HF categorized as grade ≥ 3 adverse reaction (4.3% vs. 2.1%) compared to control in the ASPIRE study.⁶⁵ Combined CV toxicities including HF were more frequent in MM patients receiving carfilzomib compared to bortezomib in the ENDEAVOR study.⁶⁶ A recent study reported CV toxicity rates in 95 MM patients receiving either carfilzomib ($n = 65$) or bortezomib ($n = 30$). At a follow-up of 18 months, 50% of carfilzomib-treated and 17% of bortezomib-treated MM patients had a significant clinical CV event, with new HF most common, and worse overall survival in the MM patients with CV events.⁶⁷ Given these high CV event rates, baseline echocardiography is advisable in all MM patients scheduled to receive a PI, which also allows assessment for cardiac AL amyloidosis. Surveillance may be considered in medium/high-risk patients receiving carfilzomib. Prompt echocardiography is strongly recommended if MM patients receiving PI therapy present with new cardiac symptoms and signs. The ENDEAVOR trial echocardiography sub-study

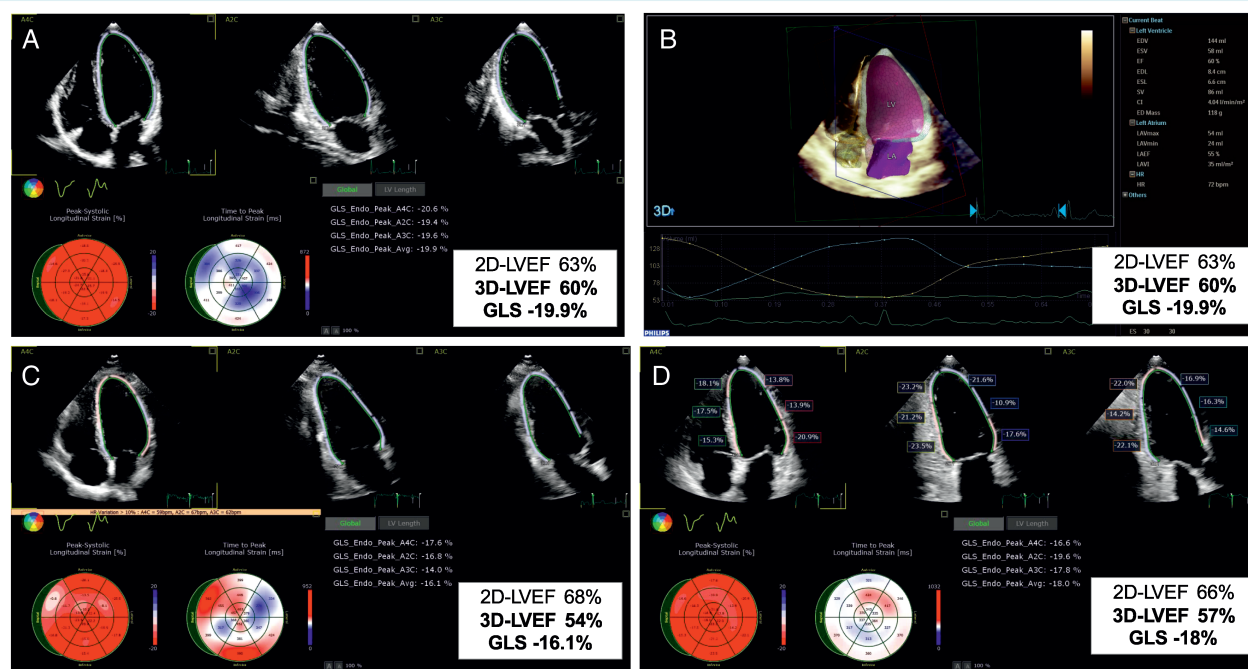


Figure 4 The case of a 66-year-old female with invasive breast ductal carcinoma (ER+ HER2+) treated by the combination of doxorubicin, cyclophosphamide, paclitaxel, radiotherapy (35 Gy + 10) and trastuzumab. (A) Baseline apical two-dimensional (2D) echocardiographic four-, two- and three-chamber views, showing normal left ventricular ejection fraction (LVEF), with speckle tracking-derived bull's eye and normal global longitudinal strain (GLS). (B) Baseline three-dimensional (3D) volumetric analysis of the left ventricle and left atrium; measurements are normal. (C) At 3-month follow-up, 2D LVEF remains normal, while 3D LVEF drops by 10% and GLS by 19%. This entailed the initiation of anti-remodelling treatment with no interruption of oncologic drugs. (D) At 6-month follow-up, while continuing cancer and cardiac medications, the 3D LVEF reversed by 5%, and GLS recovered by 10%. LA, left atrium; LV, left ventricle.

reported limited utility for serial echocardiographic screening as a risk mitigation tool in unselected patients receiving carfilzomib. However, the evaluation was limited to four parameters [LVEF, estimated pulmonary artery pressure, tricuspid annular plane systolic excursion (TAPSE) and right ventricular (RV) fractional area change] and less than 50% of patients completed the echocardiogram surveillance protocol limiting its validity.⁶⁸

Echocardiography during immune checkpoint inhibitor treatment

Immune checkpoint inhibitors have improved clinical outcome and overall survival in cancer patients with various metastatic malignancies. CV toxicity associated with ICI (e.g. ipilimumab, nivolumab, pembrolizumab, atezolizumab, avelumab, durvalumab), including myocarditis sometimes causing cardiogenic shock⁶⁹ and/or malignant ventricular tachyarrhythmias, pericarditis (including effusion and tamponade), arrhythmias, and non-inflammatory LV systolic dysfunction, was initially considered rare (<1%) but with expanding use its incidence is increasing.^{70,71} ICI-mediated fulminant myocarditis is relatively rare but has been associated with a high mortality rate (25–50%).²⁴ The echocardiographic findings may vary from a normal examination to reduced wall

thickening, reduced GLS, regional and global wall motion abnormalities and/or diastolic dysfunction.^{72–74} Serial echocardiographic screening may be considered in patients at high risk (combination ICI, ICI in combination with a second oncology drug with known cardiotoxicity, significant pre-existing heart disease, e.g. HF, cardiomyopathy). A recent study suggests a reduction in GLS is an early sign of ICI-induced myocarditis.²³ The timing and duration of surveillance remains to be determined as severe myocarditis and pericarditis usually appear early (within the first four cycles) whereas non-inflammatory LV dysfunction emerges later.²⁴

Cardiac magnetic resonance imaging during cancer therapy: why and when?

The routine use of CMR in cardio-oncology for surveillance is not feasible due to the lack of widespread accessibility and relatively high cost. However, when available, it is a very useful tool to identify changes in ventricular volumes and ejection fraction, especially in patients with poor quality echocardiographic images if a discrepancy between measurements of LV function exists, or if myocardial perfusion assessment for ischaemia is simultaneously planned.^{39,43}

Table 5 Echocardiographic surveillance during and after HER2-targeted therapies

Baseline risk of cardiotoxicity	During HER2-targeted therapies	Following completion of HER2-targeted therapy
Early invasive HER2+ breast cancer with neoadjuvant or adjuvant trastuzumab ^a	Low	<ul style="list-style-type: none"> • Optional 6–12 months after final cycle
	Medium	<ul style="list-style-type: none"> • 6 months after final cycle • Optional 12 months after final cycle
	High	<ul style="list-style-type: none"> • 3 and 12 months after final cycle • Optional 6 months after final cycle
Metastatic HER2+ breast cancer or gastric cancer with long-term HER2-targeted therapies ^b	Low	Not indicated unless symptomatic
	Medium	Not indicated unless symptomatic
	High	Not indicated unless symptomatic

cycle, chemotherapy infusion; HER2, human epidermal growth factor receptor 2.

NB. All low and medium cardiovascular risk cancer patients who develop new cardiac symptoms or new left ventricular dysfunction during HER2-targeted therapy are reclassified as high cardiovascular risk, and if HER2-targeted therapy continues they should follow the high-risk surveillance.

^aNeoadjuvant trastuzumab or trastuzumab and pertuzumab.

^bLong-term trastuzumab, trastuzumab and pertuzumab, or trastuzumab emtansine.

^cChoice of 2 or 3 depends upon variables including baseline left ventricular function, cardiovascular history, baseline troponin and previous anthracycline chemotherapy. In patients starting with surveillance after the first 2 cycles, reducing to every 3 and then every 4 from 6–12 months (and thereafter in metastatic patients) if asymptomatic and left ventricular function stable is recommended.

^dIn high-risk patients close surveillance every 2 cycles is recommended for the first 4 cycles and then reducing to every 3 cycles for the remainder of the first year of treatment. For high-risk patients with metastatic HER2+ breast cancer requiring long-term treatment, we recommend a reassessment at 12 months to then guide long-term frequency of surveillance depending upon symptoms, new left ventricular dysfunction and prognosis.

CMR also offers helpful information regarding the presence of prior myocardial infarction scar, diffuse fibrosis and intracellular or interstitial oedema (T1 mapping with extracellular volume fraction quantification and T2-STIR) during cancer treatment, facilitating our understanding of the pathogenesis of cardiotoxicity from the different cancer drug classes and radiation.^{75–77} Recent data suggest that novel CMR indices may be potentially the earliest markers of AC-induced damage: an intracellular water life time τ_{ic} , related to the size of cardiomyocyte,⁴⁷ and a prolongation of T₂ relaxation time, correlated with intra-cardiomyocyte oedema.⁷⁸

Cardiac magnetic resonance is particularly important for cancer patients receiving ICI with new cardiac symptoms, arrhythmias or cardiac troponin elevation when ICI-mediated myocarditis is suspected.⁷⁹ Additionally, CMR is an excellent test for the comprehensive evaluation of pericardial diseases, cardiac masses, infiltrative (amyloidosis) as well as storage diseases.^{80,81}

Cardiac nuclear imaging during cancer treatment

In a retrospective study of Hodgkin's lymphoma patients receiving AC-containing chemotherapy, serial [¹⁸F]fluorodeoxyglucose (¹⁸F-FDG) positron emission tomography-CT scans showed an increase in cardiac FDG uptake, which was associated with a decline in LVEF.⁸² Increased myocardial glucose utilization has also been observed after trastuzumab and radiation therapy, probably linked to myocardial inflammation and cell damage.¹¹ Given the common use of ¹⁸F-FDG PET to monitor cancer progression, this phenomenon of elevated ¹⁸F-FDG uptake might be exploited for cardiotoxicity surveillance. If echocardiography and CMR are not available, then SPECT MUGA may be used to measure LVEF.

Cardiac FDG-PET can be used to assess for ICI-mediated myocarditis in cases where CMR is not available, contraindicated, or provides equivocal results. There are also indications

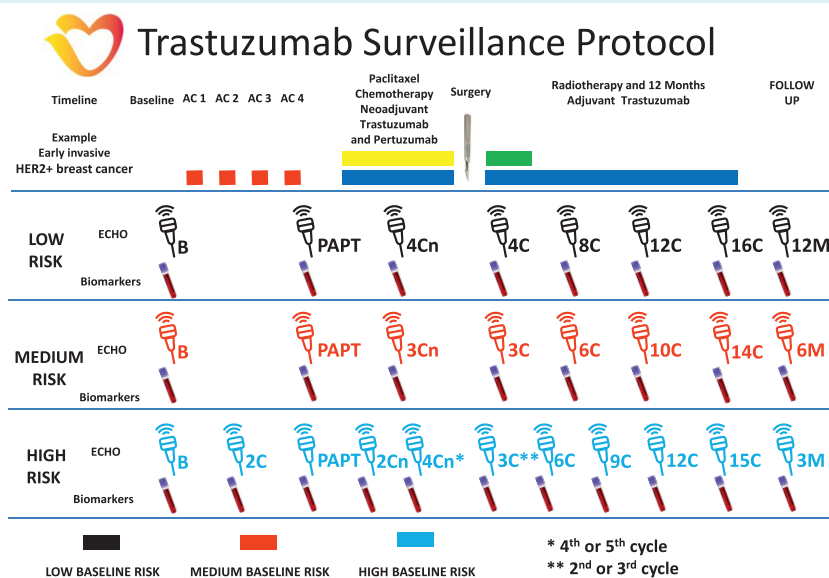


Figure 5 A surveillance pathway using biomarkers and echocardiography for patients receiving neoadjuvant anthracycline (AC) chemotherapy (doxorubicin or epirubicin) and trastuzumab followed by 12 months of adjuvant trastuzumab for HER2+ early breast cancer with timing based upon baseline cardiovascular risk. Pathways for low risk, medium risk and high risk are presented. B, baseline pre-treatment; C, cycle of chemotherapy or adjuvant trastuzumab; Cn, neoadjuvant cycle of trastuzumab; M, months post-final cycle; PAPT, post-anthracycline chemotherapy pre-trastuzumab. *, **Optional additional assessment timepoints.

for nuclear imaging studies where a specific tracer can evaluate for the presence of cardiac metastases, for example, radiolabelled octreotide for cardiac carcinoid metastases.

Cardiovascular imaging in first year after completing cancer treatment

Echocardiography is recommended during follow-up in cancer patients who developed new CTRCD or other CV toxicities requiring initiation of CV therapy during cancer therapy. The timing will depend upon several variables including the type of treatment (AC chemotherapy, HER2-targeted therapy, PI, VEGFi, second- and third-generation Bcr-Abl TKI, ICI), nature and severity of the CV toxicity and underlying status of their cancer and overall prognosis. All patients started on CV therapies (angiotensin-converting enzyme inhibitor, beta-blocker, angiotensin receptor blocker, mineralocorticoid receptor antagonist) for new LV dysfunction should have an echocardiogram 3–6 months after completing cancer treatment, whilst continuing cardiac medication before weaning CV medication. CMR may be indicated to assess response to treatment following systemic therapy, RT and/or surgery to cardiac tumours.

Cardiovascular imaging during and after radiation therapy

Radiotherapy including the heart in the radiation field (mediastinal, left breast or left chest) can affect the heart structures and

induce the excess of CV morbidity and mortality in cancer survivors. The prevalence of CTRCD increases linearly with the mean heart radiation dose; the risk can be potentiated by the adjunctive AC and interaction with pre-existing CVD.⁸³ Long-term CTRCD include valvular heart disease, constrictive pericarditis, cardiomyopathy, coronary artery disease, arrhythmias, autonomic dysfunction, carotid artery disease and other vascular disease.

Echocardiography

Echocardiography can assess left and right ventricular function, pericardial constriction and effusion and valvular disease.⁸⁴ Pericardial changes are the most frequent RT-induced CV abnormality and can develop months to years after completion of RT.^{85,86} Echocardiography is useful for evaluation of the presence and quantification of pericardial effusion and the presence of constrictive physiology.⁸⁷

Cardiomyopathy with a decrease in left and right ventricular function is the result of cell loss and myocardial fibrosis induced by high doses of RT. RT exposure to the heart of ≥ 15 Gy is associated with an increased risk of cardiotoxicity in comparison with non-irradiated survivors, especially in combination with AC (Figure 6, online supplementary Video S4).⁸⁸ Even lower doses of radiation to the heart in left breast cancer patients can interact with pre-existing CVD increasing the risk of HF including cases with preserved ejection fraction.³

Valvular disease can be caused by a fibrotic process within the valvular apparatus, which can result in leaflet thickening, fibrotic changes, shortening and calcifications, predominantly in left-sided valves with subsequent development of stenosis or insufficiency.

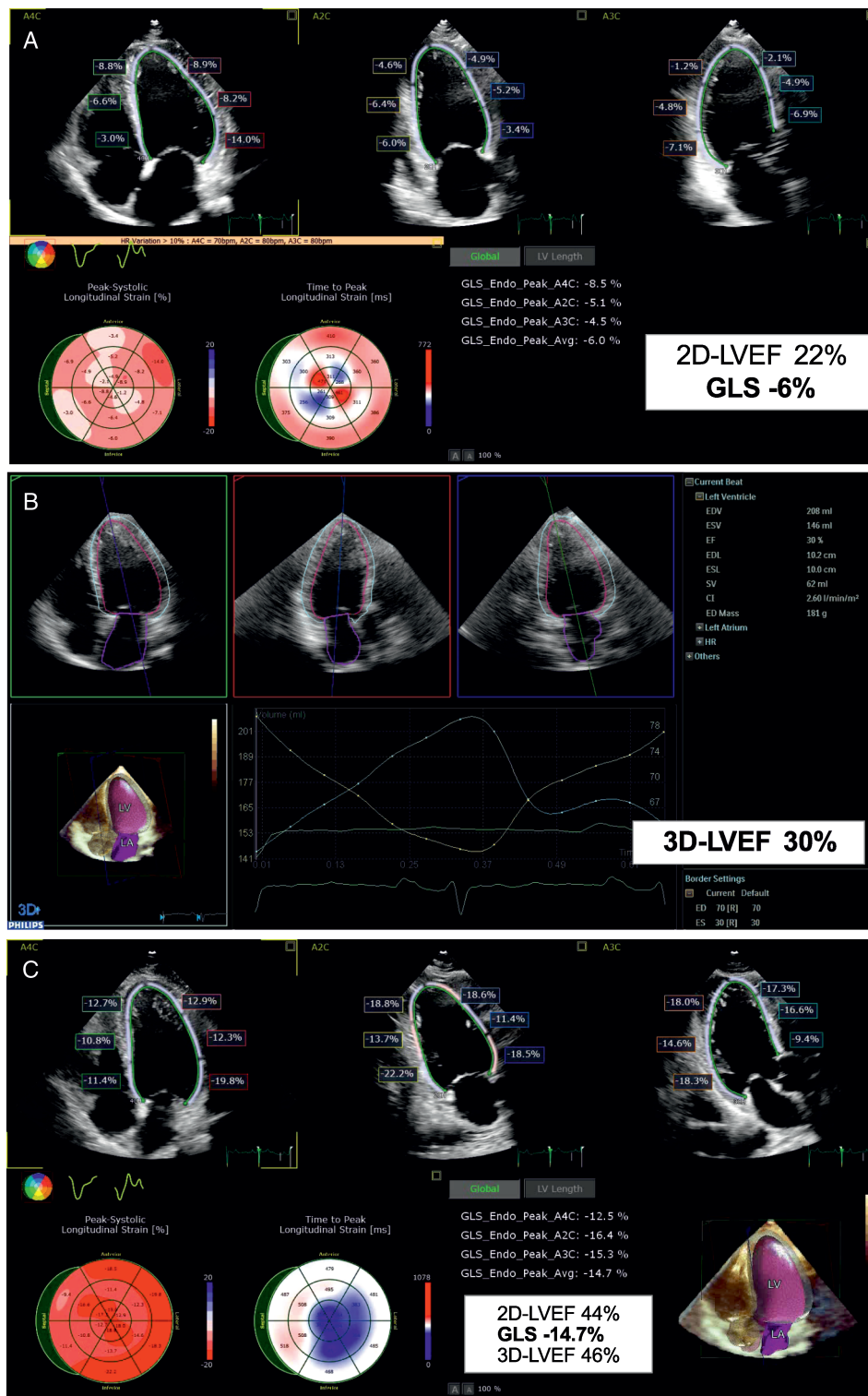


Figure 6 The case of a 44-year-old male in New York Heart Association functional class III. He had a history of Hodgkin's lymphoma at the age of 19 treated with doxorubicin, bleomycin, vinblastine, dacarbazine (ABVD) and mediastinal radiation. (A) Two-dimensional (2D) echocardiography with speckle tracking showed severe systolic dysfunction: low left ventricular ejection fraction (LVEF) and global longitudinal strain (GLS). Medical heart failure treatment (sacubitril/valsartan, bisoprolol, eplerenone, furosemide) and cardiac rehabilitation were administered. (B) Three-dimensional (3D) LVEF was equal to 30%. (C) After 6 months, a significant improvement of 2D, 3D LVEF and GLS is observed in parallel with a shift to New York Heart Association functional class I. LA, left atrium; LV, left ventricle.

Typically, alterations involve the base and mid-portions of the mitral valve leaflets, sparing tips and commissures. The incidence of valve disease increases significantly after 20 years following RT, and linearly with the RT dose, therefore careful evaluation of valve structure and function in serial echocardiography should be considered. The reasonable time of examination in asymptomatic cases may be at 5 years in high-risk patients and at 10 years in the rest of the patients followed by 5 yearly echocardiography.

Computed tomography coronary angiography and calcium score

Radiation-related coronary artery disease is observed 5 years and beyond after RT.⁸⁹ Cancer survivors have a more rapid progression of pre-existing atherosclerosis,^{90,91} indicating a potential need for earlier and more aggressive approach in older patients with known coronary artery disease or risk factors (online supplementary Figure S3). Conversely, in younger cancer survivors, a specific radiation-induced coronary disease, which is different from atherosclerosis, may develop following exposure to high radiation doses. Therefore, the role of surveillance CTCA to detect subclinical coronary artery disease has been proposed.

As in the general population, in RT survivors, the accuracy of CTCA and calcium score in the diagnosis of significant coronary artery disease is high and demonstrates excellent negative predictive value.^{92–94} Moreover, recent data show that the inclusion of CTCA in the diagnostic workup of stable patients improves long-term prognosis by reducing the incidence of myocardial infarction.⁹⁴ However, the timing of CTCA for surveillance in asymptomatic cancer survivors following high-dose radiation to the chest is unknown and requires further study.

Incidental coronary calcium in thoracic CT for staging and/or RT planning, subsequent follow-up CT and/or PET-CT scans should be reported and quantified according to recent recommendations from the Society of Cardiovascular Computed Tomography.⁹⁵ Coronary artery calcification obtained from non-gated chest CT scans correlates well with a 3 mm coronary calcium scan and is incrementally associated with worse CV outcomes in cancer patients⁹⁶ implicating timely prescription of preventive therapies.

Cardiovascular imaging in specific cancer populations

Cancer patients with pulmonary arterial hypertension and/or right ventricular dysfunction

Data on RV remodelling and dysfunction in oncology patients remain scarce. There are particular cardiotoxic cancer treatments that may specifically cause pulmonary arterial hypertension (dasatinib⁹⁷) and/or RV dysfunction (AC,⁹⁸ trastuzumab,⁹⁹ cyclophosphamide¹⁰⁰ and dasatinib⁹⁷). A significant reduction of RV longitudinal strain has been shown within 3 months of

the commencement of AC therapy.¹⁰¹ RV circumferential strain, assessed by CMR, decreased after 6 months of trastuzumab use in a cohort of HER2-positive breast cancer patients.¹⁰²

Right ventricular function and pulmonary artery pressure should be assessed at pre-treatment baseline and subsequently during echocardiographic surveillance (Table 3). The frequency of scanning depends upon the severity of the pre-existing pulmonary arterial hypertension or RV dysfunction and the risk of cardiotoxicity analogously to the monitoring of LV systolic dysfunction (Tables 4 and 5). Conventional 2D echocardiographic measurements such as RV fractional area change or TAPSE are recommended.¹⁰¹ The EACVI suggests routine measurement of RV free wall strain, which is more representative of RV longitudinal deformation than septal strain¹⁰³; recent advances in 3D quantification makes the estimation of RV ejection fraction possible not only by CMR but also by 3D echocardiography.¹⁰⁴

Cardiac masses

Echocardiography as initial imaging modality for the diagnosis of cardiac tumours provides important information regarding their location, size, attachment, mobility, echogenicity, calcification and potential mechanical complications, for example, valve obstruction (online supplementary Video S5A).¹⁰⁵ Nonbacterial thrombotic endocarditis is one of the findings, frequently associated with adenocarcinomas of the lung, ovary, gastrointestinal system.¹⁰⁶ Real-time 3D echocardiography by transthoracic or transoesophageal approach provides more accurate assessment of tumour mass (volume), homogeneity, vascularity or necrosis (online supplementary Video S5B).¹⁰⁷ Contrast echocardiography improves definition of intra-cavity structures and may help distinguish between vascular and perfused tumour vs. non-perfused thrombus, including chemotherapy infusion line-related right atrial thrombus.^{108,109}

Cardiac magnetic resonance and CT are excellent tools for mass tissue characterization and evaluation of perfusion. A CMR protocol includes black-blood T1- and T2-weighted imaging with or without fat tissue suppression before and after injection of gadolinium.¹¹⁰ Cardiac metastases appear as single or multiple masses with associated oedema in a patient with a known primary malignancy elsewhere. Compared with benign, malignant primary cardiac tumours are rare, larger, more frequently located in the right heart and pericardium, typically hyperintense on T2-weighted images, demonstrate vascularity on first-pass perfusion and are more likely to have positive late gadolinium enhancement.^{111,112} Primary cardiac lymphoma may show features of diffuse infiltration into the myocardium on contrast images and sign of 'floating artery', when epicardial vessels are encased by tumour but remain patent.¹¹³ Advanced CMR techniques such as parametric mapping or fat-water separation may help in differentiation from benign conditions such as lipomatous hypertrophy of the interatrial septum.^{114,115}

Computed tomography scanning can distinguish fat and calcium components and detect the relationship of a mass to adjacent structures including the coronary and pulmonary vessels.^{116,117} PET with ¹⁸F-FDG isotope can also be used to characterize cardiac

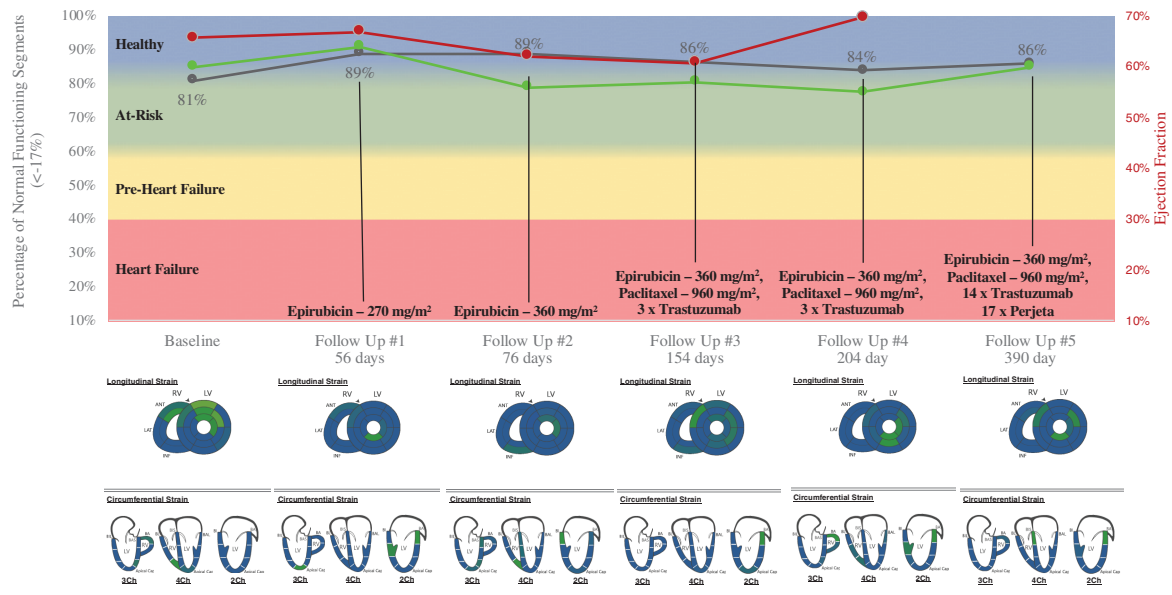


Figure 7 The case of a 58-year-old female suffering from HER2+ right breast cancer with a high baseline risk of cardiotoxicity. Cardiac magnetic resonance exams including Fast-SENC MyoStrain testing were performed at baseline and five follow-up intervals through 390 days after initiation of chemotherapy with no signs of cardiac damage. The graph shows % normal MyoStrain ($\leq -17\%$) in black with cardiac magnetic resonance left ventricular ejection fraction in green and echocardiography left ventricular ejection fraction in red. MyoStrain segmental reports are shown below the graph of % normal MyoStrain (blue colour codes normal deformation, green codes strain in the range between -17% and -10% , yellow codes strain less than -10%). HF, heart failure.

masses or detect metastases if diagnostic uncertainty exists or if CMR is contraindicated.¹¹⁸

Cardiac amyloidosis

Cardiac amyloidosis is an infiltrative disease in which the extracellular space of the myocardium is expanded by the deposition of abnormal protein known as amyloid.¹¹⁹ Most cases of amyloid involvement of the heart are either transthyretin (ATTR) type or immunoglobulin-derived light-chains (AL) from an underlying MM or lymphoproliferative malignancy.¹²⁰

Standard echocardiography typically shows all or some of the well-known characteristic features including LV wall thickening with normal or reduced LV volumes, enlarged atria, increased thickness of RV wall and cardiac valves, loss of drop of interatrial septum and pericardial or pleural effusion. Symmetric hypertrophy is generally related to AL amyloidosis whereas asymmetric patterns are found in 80% of ATTR amyloidosis.¹²¹ Due to extensive amyloid deposits, myocardial texture may develop a 'sparkling' appearance, although this is hard to recognize during harmonic imaging and more readily appreciated during fundamental imaging. Functional assessment may reveal normal or impaired LV systolic function, left or bi-atrial dilatation and restrictive LV filling pattern.^{40,122} Myocardial deformation analysis using speckle tracking echocardiography or CMR tissue tracking imaging shows significantly reduced global LV longitudinal strain, with more evident decrease of segmental strain in the basal and mid-ventricular zones compared to the apical area—a feature known as 'apical sparing'.^{42,123–127}

Cardiac magnetic resonance typically demonstrates a combination of global subendocardial, diffuse transmural or patchy late enhancement in a non-coronary distribution with a dark blood pool. Difficulties in nulling the myocardium when defining correct inversion time is another characteristic finding.^{128,129} Both types of cardiac amyloidosis significantly increase native T1 relaxation time and extracellular volume, which can be estimated using CMR parametric mapping.^{130,131}

^{99m}Tc-labelled pyrophosphate (^{99m}Tc-PYP) and 3,3-diphosphono-1,2-propanodicarboxic acid (^{99m}Tc-DPD) accumulate in the myocardium infiltrated by transthyretin amyloid, whereas hearts with AL deposits demonstrate ¹⁸F-florbetapir uptake,^{132,133} with no or minimal ^{99m}Tc-DPD uptake. Positive ^{99m}Tc-PYP or ^{99m}Tc-DPD scan is specific for ATTR diagnosis and in combination with CMR and absence of monoclonal protein band may be sufficient to confirm ATTR cardiac amyloidosis without the need for cardiac biopsy.¹³⁴

Carcinoid cardiac disease

Carcinoid tumours can secrete vasoactive substances causing a 'carcinoid syndrome' in the setting of liver or pulmonary metastases.¹³⁵ Carcinoid-related serotonin is deposited in the right heart endocardium and both tricuspid and pulmonary valves causing fibrosis.¹³⁶ Typical echocardiographic features in more than 50% of patients of carcinoid include retracted, shortened and thickened leaflets of both tricuspid and pulmonic valves.¹³⁷ The leaflets appear fixed and usually there is a significant coaptation

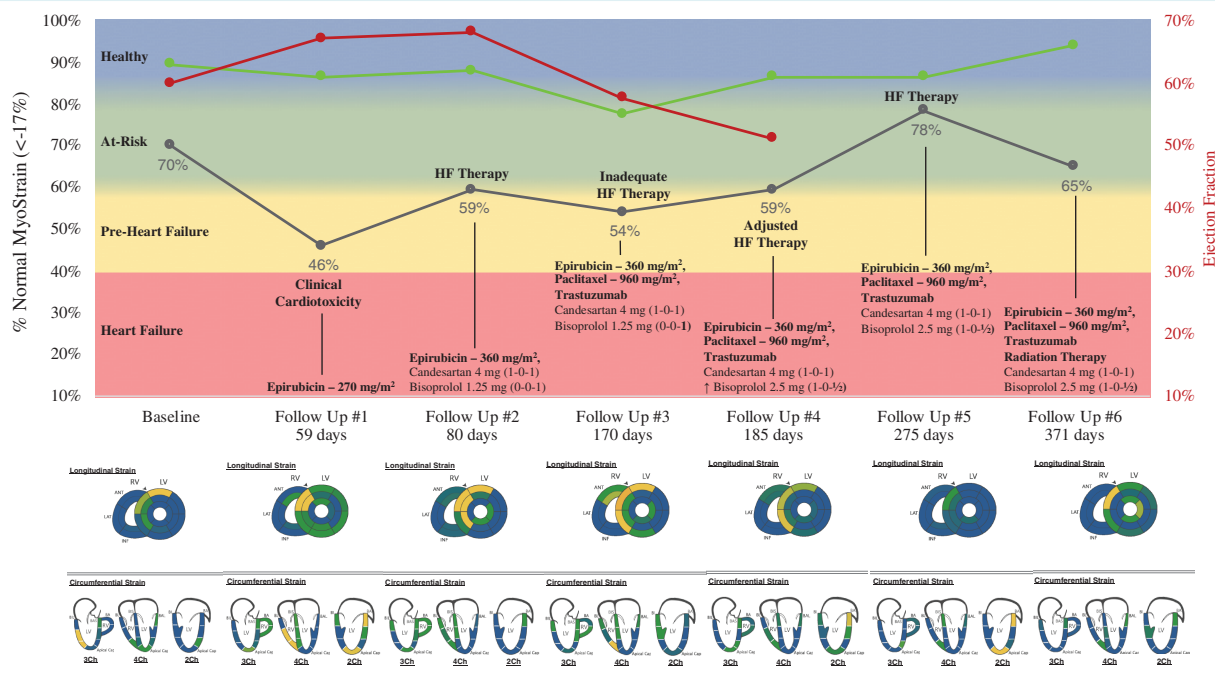


Figure 8 The case of a 52-year-old female suffering from HER2+ right breast cancer with a high risk of cardiotoxicity. Cardiac magnetic resonance (CMR) exams including Fast-SENC MyoStrain testing were performed at baseline and six follow-up intervals through 371 days after initiation of chemotherapy. The graph shows % normal MyoStrain ($\le -17\%$) in black with cardiac magnetic resonance left ventricular ejection fraction in green and echocardiography left ventricular ejection fraction in red. Upon administration of 270 mg/m² epirubicin at 59 days of follow-up, the patient exhibited clinical cardiotoxicity, with MyoStrain % normal left ventricular myocardium worsened from 70% to 46%. Echocardiography left ventricular ejection fraction (60% to 67%) and global longitudinal strain (-19.7%) did not identify the cardiotoxic response. The dynamics of imaging parameters in response of titration of cardioprotective therapy is shown. MyoStrain segmental reports are shown below the graph of % normal MyoStrain (blue colour codes normal deformation, green codes strain in the range between -17% and -10% , yellow codes strain less than -10%).

gap leading to severe or torrential tricuspid and pulmonary regurgitation. Subsequently, volume and pressure overload develop causing hypertrophy and dilatation of the right chambers. Less commonly, there may be a tricuspid or pulmonary stenosis.¹³⁸ Further cardiac imaging with high sensitivity and specificity include SPECT-CT with ¹¹¹Indium-labelled octreotide and PET-CT with ⁶⁸Gallium-labelled octreotide to examine for myocardial carcinoid metastases which are present in $\sim 4\%$ of carcinoid patients.^{139,140} In a minority of cases ($\sim 15\%$) in patients with pulmonary metastases, an intracardiac shunt can be detected¹³⁸; in the presence of high levels of vasoactive substances, left-sided heart valves may also be affected. Expert opinion regarding surveillance for development and progression of carcinoid valvular heart disease recommends 6 monthly echocardiography in asymptomatic patients with metastatic carcinoid syndrome and elevated N-terminal pro B-type natriuretic peptide levels.¹⁴¹

Future directions and imaging technologies

The important question is how to alter the management of cancer patients in whom new abnormalities of cardiac function are

detected with imaging. This is complex and will depend upon many variables including pre-existing CVD, pre-existing cardiac medication, current CV physiological parameters, the cause and severity of cardiotoxicity, the planned duration of ongoing treatment and patient preferences. Some guidance has been provided following new changes in GLS and/or biomarkers in a real-world cardio-oncology clinic.³² This topic will be addressed in a future HFA cardio-oncology position statement.

The main challenge in creating CV imaging surveillance recommendations is the lack of scientific evidence from randomized clinical trials. The ongoing SUCCOUR study will provide crucial data on the value of strain imaging for early detection of cardiotoxicity comparing to the conventional measurement of LVEF for timely guidance of cardioprotective treatment.¹⁹ Among the endpoints of the study are not only the risk of cardiac dysfunction and HF development, but also the completion rate of the planned chemotherapy.

An advanced strain-encoded (SENC and fast-SENC) CMR tagging technology provides high accuracy and reproducibility during single heartbeat acquisitions without contrast and may be helpful in the future to detect early cardiotoxicity.¹⁴² The PROACT study with mixed blinded and unblinded design will include breast cancer, lymphoma and sarcoma patients receiving AC chemotherapy,

also aiming to initiate cardioprotection at the earliest possible moment (Figures 7 and 8).¹⁴³ Also, a decrease of native T1 times as early as 48 h after the first AC cycle has been shown to predict the development of CTRCD after completion of chemotherapy.¹⁴⁴

Other recent hypotheses incorporate the use of baseline myocardial ¹⁸F-FDG uptake⁸² and machine learning models for prediction of cancer therapy-induced cardiotoxicity.¹⁴⁵ PET-CT protocols combining oncology and cardiology questions may be informative; LV mass reduction is suggested as a potential marker of CTRCD.¹⁴⁶ For the design of imaging trials, the standardization of image acquisition, evaluation, reporting, as well as staff training, blinded review and regular quality assessment are key considerations.¹⁴⁷

Future research should focus on the best timing of cardiac imaging during and after particular types of cancer therapy in different patient populations. Pragmatic and registry-based clinical trials may be helpful, with individual or cluster randomization by clinic or hospital. Observational studies to explore big databases including information on time and result of imaging tests with concomitant changes in cancer and CV therapy would be of great value. One of the most important questions is whether meticulous monitoring by echocardiography and biomarkers improves the mortality and morbidity of cancer patients. The consequences of cancer therapy interruptions and the cost-effectiveness of surveillance should be analysed. Preventive strategies aimed at treating all oncology patients do not seem practical to most clinicians at the present time due to the potential for substantial overtreatment and the high relative cost.

Conclusions

Cardiovascular imaging modalities demonstrate a remarkable progress in the developing field of cardio-oncology, providing highly sensitive methods for timely diagnosis of cardiotoxicity. Myocardial deformation imaging and 3D volumetric analysis seem to be optimal techniques to address temporal structural and functional changes during cancer therapy. The intensity of echocardiographic monitoring should be based on the individual risk of cardiotoxicity, coordination with cardiac biomarkers monitoring, and requires collaborative evaluation by the cardio-oncology team. Suggested detailed algorithms for anthracycline and HER2-targeted therapies aim to improve current clinical practice. Further studies are needed to establish effective surveillance schemes changing the outcomes of oncology patients.

Supplementary Information

Additional supporting information may be found online in the Supporting Information section at the end of the article.

Figure S1. Bull's eye of left ventricular global longitudinal strain (GLS) in a 62-year-old man with a metastatic colorectal adenocarcinoma after 8 cycles of XELOX regimen (capecitabine plus oxaliplatin): GLS decreased from -14% before to -7.5% after chemotherapy.

Figure S2. Bull's eye of left ventricular global longitudinal strain in a 63-year-old female who underwent surgery, radiotherapy and chemotherapy for left breast cancer, which was finished 4 years ago. Recently severe left ventricular systolic dysfunction was detected for the first time, along with the new onset of symptoms.

Figure S3. Radiotherapy-induced cardiovascular disease: computed tomography images from a patient with effort dyspnoea which manifested 24 years after mediastinal irradiation for Hodgkin's lymphoma. (A) Severe calcification of ascending aorta and left anterior descending coronary artery. (B) Severe calcification of aortic and mitral valves. (C) Calcification of aortic valve leaflets in a zoomed short-axis view. (D) Fibro-calcified plaques with significant ostial stenosis of the right coronary artery.

Video S1A. A 62-year-old man with a metastatic colorectal adenocarcinoma and a history of previous myocardial infarction. Echocardiographic four-chamber view before initiation of chemotherapy showing mildly reduced left ventricular ejection fraction (47%); measured global longitudinal strain was -14%

Video S1B. Echocardiographic four-chamber view after 8 cycles of XELOX regimen (capecitabine plus paxliplatin) revealed deterioration of left ventricular systolic function (ejection fraction 33%).

Video S2A. A 66-year-old female with invasive breast ductal carcinoma (RH+ HER2+) treated by the combination of doxorubicin, cyclophosphamide, paclitaxel, radiotherapy (35 Gy+10) and trastuzumab. Baseline measurement of segmental and global longitudinal strain in three apical planes and bull's eyes of peak systolic strain and time to peak systolic strain. Values are within normal range.

Video S2B. Baseline 3D echocardiography and volumetric analysis of the left ventricle and atrium: normal volumes and ejection fraction.

Video S2C. Three-month follow-up measurement of segmental and global longitudinal strain in three apical planes and bull's eyes showing significant (19%) reduction of peak systolic strain and prolonged time to peak systolic strain

Video S2D. Six-month follow-up measurement of segmental and global longitudinal strain in three apical planes and bull's eyes showing substantial (10%) recovery of peak systolic strain and normalized time to peak systolic strain.

Video S3A. A 63-year-old female underwent surgery, radiotherapy and chemotherapy for left breast cancer, which was finished 4 years ago. Within 2 years after therapy completion, left ventricular ejection fraction was 50%, while after next 2 years dyspnoea appeared and remarkable systolic dysfunction was revealed. Severe left ventricular dilatation and reduction of ejection fraction to 30% in (A) apical four-chamber view

Video S3B. A 63-year-old female underwent surgery, radiotherapy and chemotherapy for left breast cancer, which was finished 4 years ago. Within 2 years after therapy completion, left ventricular ejection fraction was 50%, while after next 2 years dyspnoea appeared and remarkable systolic dysfunction was revealed. Severe left ventricular dilatation and reduction of ejection fraction to 30% in (B) apical two-chamber view.

Video S3C. A 63-year-old female underwent surgery, radiotherapy and chemotherapy for left breast cancer, which

was finished 4 years ago. Within 2 years after therapy completion, left ventricular ejection fraction was 50%, while after next 2 years dyspnoea appeared and remarkable systolic dysfunction was revealed. Severe left ventricular dilatation and reduction of ejection fraction to 30% in (C) short-axis view.

Video S4A. A 44-year-old male in NYHA III functional class. He had a history of Hodgkin's lymphoma at the age of 19 treated with doxorubicin, bleomycin, vinblastine, dacarbazine (ABVD) and mediastinal radiation. Two-dimensional echocardiography with speckle tracking clearly showing severe systolic dysfunction: low left ventricular ejection fraction and global longitudinal strain.

Video S4B. Three-dimensional echocardiography confirms remarkably low left ventricular ejection fraction before the treatment.

Video S4C. A striking improvement of segmental and global longitudinal strain after 6 months of medical heart failure treatment and cardiac rehabilitation.

Video S5A. A 79-year-old man admitted due to abdominal pain was diagnosed with advanced liver cancer. A heterogeneous lobular 6.0 × 5.0 mass with irregular edges and numerous cuttings, largely occupying the volume of the right atrium, (A) on two-dimensional echocardiographic four-chamber view.

Video S5B. A 79-year-old man admitted due to abdominal pain was diagnosed with advanced liver cancer. A heterogeneous lobular 6.0 × 5.0 mass with irregular edges and numerous cuttings, largely occupying the volume of the right atrium, (B) three-dimensional echocardiographic view.

Funding

R.A.d.B. is supported by the Netherlands Heart Foundation (CVON DOSIS, grant 2014-40, CVON SHE-PREDICTS-HF, grant 2017-21, and CVON RED-CVD, grant 2017-11), and the European Research Council (ERC CoG 818715, SECRETE-HF). C.G.T. is supported by a Federico II University/Ricerca di Ateneo grant.

Conflict of interest: J.C. received personal fees from AstraZeneca, Novartis, Roche, Servier, Amgen, Berlin-Chemie, Grindex. R.P. received personal fees from Novartis, Roche, Servier and MSD. T.L.F. received speaker fees from Pfizer, Servier, Amgen, Janssens-Cilag Ltd, Daiichi-Sankyo, MSD, and Philips. D.F. received consultation fees, speaker honoraria and/or travel grants from Abbott Laboratories, Boehringer Ingelheim, Daiichi Sankyo, Menarini, Novartis, Pfizer, Roche Diagnostics and Servier. The UMCG, which employs Dr. de Boer, has received research grants and/or fees from AstraZeneca, Abbott, Bristol-Myers Squibb, Novartis, NovoNordisk, and Roche. R.A.d.B. is a minority shareholder of scPharmaceuticals, Inc.; and received personal fees from Abbott, AstraZeneca, MandalMed Inc, and Novartis. C.B.D. is in part supported by the NIHR Biomedical Research Centre at University Hospitals Bristol NHS Foundation Trust and the University of Bristol. The views expressed in this publication are those of the author(s) and not necessarily those of the NHS, the National Institute for Health Research or the Department of Health and Social Care. M.S.A. received personal fees from Servier. M.G. received advisory board fees from Pfizer, Bayer, Sobi. C.M. received research support from the Swiss National Science Foundation, the

Swiss Heart Foundation, the KTI, the Stiftung für kardiovaskuläre Forschung Basel, the University of Basel, the University Hospital Basel, Abbott, Beckman Coulter, Brahms, Novartis, Ortho Clinical Diagnostics, Quidel, Roche, Siemens, Singulex, Sphingotec, as well as speaker/consulting honoraria from Acon, Amgen, AstraZeneca, Boehringer Ingelheim, BMS, Idorsia, Novartis, Roche, Sanofi, and Singulex. The APHP, which employs J.S.H., received research grants from Bioserinity, Sanofi, Servier and NovoNordisk. J.S.H. received speaker, advisory board or consultancy fees from Amgen, AstraZeneca, Bayer, Bristol-Myers Squibb, Novartis, WeHealth. B.M. received personal fees from Servier, Novartis, Boehringer Ingelheim, Eli Lilly, AstraZeneca, BMS, Merck Serono, and consultancy fees from Novartis and Boehringer Ingelheim. P.S. received lecture and consultancy agreement honoraria from Medtronic, Abbott, Servier, AstraZeneca, Respicardia, Boehringer Ingelheim, Novartis. A.R.L. received speaker, advisory board or consultancy fees and/or research grants from Pfizer, Novartis, Servier, Amgen, Takeda, Roche, Janssens-Cilag Ltd, Clinigen Group, Eli Lilly, Eisai, Bristol-Myers Squibb, Ferring Pharmaceuticals and Boehringer Ingelheim.

References

- Lyon AR, Dent S, Stanway S, Earl H, Brezden-Masley C, Cohen-Solal A, Tocchetti CG, Moslehi J, Groarke JD, Bergler-Klein J, Khoo V, Tan LL, Anker MS, von Haehling S, Maack C, Pudil R, Barac A, Thavendirathan P, Ky B, Neilan TG, Belenkov Y, Rosen SD, Iakobishvili Z, Sverdlow AL, Hajjar LA, Macedo AV, Manisty C, Ciardiello F, Farmakis D, De Boer RA, Skouri H, Suter TM, Cardinale D, Witteles RM, Fradley MG, Herrmann J, Cornell RF, Wechelaker A, Mauro MJ, Milojkovic D, de Lavallade H, Ruschitzka F, Coats AJ, Seferovic PM, Chioncel O, Thum T, Bauersachs J, Andres MS, Wright DJ, López-Fernández T, Plummer C, Lenihan D. Baseline cardiovascular risk assessment in cancer patients scheduled to receive cardiotoxic cancer therapies: a position statement and new risk assessment tools from the Cardio-Oncology Study Group of the Heart Failure Association of the European Society of Cardiology in collaboration with the International Cardio-Oncology Society. *Eur J Heart Fail* 2020 May 28. <https://doi.org/10.1002/ejhf.1920> [Epub ahead of print].
- Zamorano JL, Lancellotti P, Rodriguez Munoz D, Aboyans V, Asteggiano R, Galderisi M, Habib G, Lenihan DJ, Lip GY, Lyon AR, Lopez Fernandez T, Mohty D, Piepoli MF, Tamargo J, Torbicki A, Suter TM, Zamorano JL, Aboyans V, Achenbach S, Agewall S, Badimon L, Baron-Esquivas G, Baumgartner H, Bax JJ, Bueno H, Carerj S, Dean V, Erol C, Fitzsimons D, Gaemperli O, Kirchhof P, Kolh P, Lancellotti P, Lip GY, Nihoyannopoulos P, Piepoli MF, Ponikowski P, Roffi M, Torbicki A, Vaz Carneiro A, Windecker S. 2016 ESC position paper on cancer treatments and cardiovascular toxicity developed under the auspices of the ESC Committee for Practice Guidelines: the Task Force for cancer treatments and cardiovascular toxicity of the European Society of Cardiology (ESC). *Eur J Heart Fail* 2017;19:9–42.
- Plana JC, Galderisi M, Barac A, Ewer MS, Ky B, Scherrer-Crosbie M, Ganame J, Sebag IA, Agler DA, Badano LP, Banchs J, Cardinale D, Carver J, Cerqueira M, DeCara JM, Edvardsen T, Flamm SD, Force T, Griffin BP, Jerusalem G, Liu JE, Magalhaes A, Marwick T, Sanchez LY, Sicari R, Villarraga HR, Lancellotti P. Expert consensus for multimodality imaging evaluation of adult patients during and after cancer therapy: a report from the American Society of Echocardiography and the European Association of Cardiovascular Imaging. *Eur Heart J Cardiovasc Imaging* 2014;15:1063–1093.
- Celutkienė J, Plymen CM, Flachskampf FA, de Boer RA, Grapsa J, Manka R, Anderson L, Garbi M, Barberis V, Filardi PP, Gargiulo P, Zamorano JL, Lainscak M, Seferovic P, Ruschitzka F, Rosano GM, Nihoyannopoulos P. Innovative imaging methods in heart failure: a shifting paradigm in cardiac assessment. Position statement on behalf of the Heart Failure Association of the European Society of Cardiology. *Eur J Heart Fail* 2018;20:1615–1633.
- Kalam K, Otahal P, Marwick TH. Prognostic implications of global LV dysfunction: a systematic review and meta-analysis of global longitudinal strain and ejection fraction. *Heart* 2014;100:1673–1680.
- Narayan HK, Finkelmann B, French B, Plappert T, Hyman D, Smith AM, Margulies KB, Ky B. Detailed echocardiographic phenotyping in breast cancer patients:

- associations with ejection fraction decline, recovery, and heart failure symptoms over 3 years of follow-up. *Circulation* 2017;**135**:1397–1412.
7. Thavendiranathan P, Grant AD, Negishi T, Plana JC, Popovic ZB, Marwick TH. Reproducibility of echocardiographic techniques for sequential assessment of left ventricular ejection fraction and volumes: application to patients undergoing cancer chemotherapy. *J Am Coll Cardiol* 2013;**61**:77–84.
 8. Tsang W, Salgo IS, Medvedofsky D, Takeuchi M, Prater D, Weinert L, Yamat M, Mor-Avi V, Patel AR, Lang RM. Transthoracic 3D echocardiographic left heart chamber quantification using an automated adaptive analytics algorithm. *JACC Cardiovasc Imaging* 2016;**9**:769–782.
 9. Santoro C, Arpino G, Esposito R, Lembo M, Paciolla I, Cardalesi C, de Simone G, Trimarco B, De Placido S, Galderisi M. 2D and 3D strain for detection of subclinical anthracycline cardiotoxicity in breast cancer patients: a balance with feasibility. *Eur Heart J Cardiovasc Imaging* 2017;**18**:930–936.
 10. Grothues F, Smith GC, Moon JC, Bellenger NG, Collins P, Klein HU, Pennell DJ. Comparison of interstudy reproducibility of cardiovascular magnetic resonance with two-dimensional echocardiography in normal subjects and in patients with heart failure or left ventricular hypertrophy. *Am J Cardiol* 2002;**90**:29–34.
 11. Soufer A, Liu C, Henry ML, Baldassarre LA. Nuclear cardiology in the context of multimodality imaging to detect cardiac toxicity from cancer therapeutics: established and emerging methods. *J Nucl Cardiol* 2020;**27**:1210–1224.
 12. Thavendiranathan P, Poulin F, Lim KD, Plana JC, Woo A, Marwick TH. Use of myocardial strain imaging by echocardiography for the early detection of cardiotoxicity in patients during and after cancer chemotherapy: a systematic review. *J Am Coll Cardiol* 2014;**63** (25 Pt A):2751–2768.
 13. Verdonchot JA, Merken JJ, Brunner-La Rocca HP, Hazebroek MR, Eurlings C, Thijssen E, Wang P, Weerts J, van Empel V, Schummers G, Schreckenbergh M, van den Wijngaard A, Lumens J, Brunner HG, Heymans SR, Krapels IP, Knackstedt C. Value of speckle tracking-based deformation analysis in screening relatives of patients with asymptomatic dilated cardiomyopathy. *JACC Cardiovasc Imaging* 2020;**13**:549–558.
 14. Negishi K, Negishi T, Haluska BA, Hare JL, Plana JC, Marwick TH. Use of speckle strain to assess left ventricular responses to cardiotoxic chemotherapy and cardioprotection. *Eur Heart J Cardiovasc Imaging* 2014;**15**:324–331.
 15. Baron T, Berglund L, Hedin EM, Flachskampf FA. Test-retest reliability of new and conventional echocardiographic parameters of left ventricular systolic function. *Clin Res Cardiol* 2019;**108**:355–365.
 16. Charbonnel C, Convers-Domart R, Rigaudeau S, Taksis AL, Baron N, Lambert J, Ghez S, Georges JL, Farhat H, Lambert J, Rousselot P, Livarek B. Assessment of global longitudinal strain at low-dose anthracycline-based chemotherapy, for the prediction of subsequent cardiotoxicity. *Eur Heart J Cardiovasc Imaging* 2017;**18**:392–401.
 17. Kang Y, Xu X, Cheng L, Li L, Sun M, Chen H, Pan C, Shu X. Two-dimensional speckle tracking echocardiography combined with high-sensitive cardiac troponin T in early detection and prediction of cardiotoxicity during epirubicin-based chemotherapy. *Eur J Heart Fail* 2014;**16**:300–308.
 18. Santoro C, Esposito R, Lembo M, Sorrentino R, De Santo I, Luciano F, Casciano O, Giuliano M, De Placido S, Trimarco B, Lancellotti P, Arpino G, Galderisi M. Strain-oriented strategy for guiding cardioprotection initiation of breast cancer patients experiencing cardiac dysfunction. *Eur Heart J Cardiovasc Imaging* 2019;**20**:1345–1352.
 19. Negishi T, Thavendiranathan P, Negishi K, Marwick TH; SUCCOUR Investigators. Rationale and design of the Strain Surveillance of Chemotherapy for Improving Cardiovascular Outcomes: the SUCCOUR Trial. *JACC Cardiovasc Imaging* 2018;**11**:1098–1105.
 20. Thavendiranathan P, Negishi T, Cote MA, Penicka M, Massey R, Cho GY, Hristova K, Vinereanu D, Popescu BA, Izumo M, Negishi K, Marwick TH; SUCCOUR Investigators. Single versus standard multiview assessment of global longitudinal strain for the diagnosis of cardiotoxicity during cancer therapy. *JACC Cardiovasc Imaging* 2018;**11**:1109–1118.
 21. Muraru D, Niero A, Rodriguez-Zanella H, Cherata D, Badano L. Three-dimensional speckle-tracking echocardiography: benefits and limitations of integrating myocardial mechanics with three-dimensional imaging. *Cardiovasc Diagn Ther* 2018;**8**:101–117.
 22. Zhang KW, Finkelman BS, Gulati G, Narayan HK, Upshaw J, Narayan V, Plappert T, Englefield V, Smith AM, Zhang C, Hundley WG, Ky B. Abnormalities in 3-dimensional left ventricular mechanics with anthracycline chemotherapy are associated with systolic and diastolic dysfunction. *JACC Cardiovasc Imaging* 2018;**11**:1059–1068.
 23. Lyon AR, Yousaf N, Battisti NM, Moslehi J, Larkin J. Immune checkpoint inhibitors and cardiovascular toxicity. *Lancet Oncol* 2018;**19**:e447–458.
 24. Moslehi JJ, Salem JE, Sosman JA, Lebrun-Vignes B, Johnson DB. Increased reporting of fatal immune checkpoint inhibitor-associated myocarditis. *Lancet* 2018;**391**:933.
 25. Honda K, Takeshita K, Murotani K, Mitsuma A, Hayashi H, Tsunoda N, Kikumori T, Murohara T, Ando Y. Assessment of left ventricular diastolic function during trastuzumab treatment in patients with HER2-positive breast cancer. *Breast Cancer* 2017;**24**:312–318.
 26. Calabrese V, Menna P, Annibali O, Armento G, Carpio A, Cerchiara E, Greco C, Marchesi F, Spallarossa P, Toglia G, Reggiardo G, Minotti G. Early diastolic dysfunction after cancer chemotherapy: primary endpoint results of a multicenter cardio-oncology study. *Chemotherapy* 2018;**63**:55–63.
 27. Meloche J, Nolan M, Amir E, Brezden-Masley C, Yan A, Thampinathan B, Woo A, Bernd W, Thavendiranathan P. Temporal changes in left atrial function in women with HER2+ breast cancer receiving sequential anthracyclines and trastuzumab therapy. *J Am Coll Cardiol* 2018;**71**:1524.
 28. Cerrito LF, Schiavone A, Bergamini C, Dal Porto M, Benfari G, Dolci G, Setti E, Comunello A, Rossi A, Fiorio E, Ribichini FL. Role of left atrial volume as simple and early predictor of cardiotoxicity. *Eur Heart J* 2019;**40** (Suppl 1):1422(abstr.).
 29. Chavez-MacGregor M, Niu J, Zhang N, Elting LS, Smith BD, Banchs J, Hortobagyi GN, Giordano SH. Cardiac monitoring during adjuvant trastuzumab-based chemotherapy among older patients with breast cancer. *J Clin Oncol* 2015;**33**:2176–2183.
 30. Thavendiranathan P, Abdel-Qadir H, Fischer HD, Liu Y, Camacho X, Amir E, Austin PC, Lee DS. Risk-imaging mismatch in cardiac imaging practices for women receiving systemic therapy for early-stage breast cancer: a population-based cohort study. *J Clin Oncol* 2018;**36**:2980–2987.
 31. Henry ML, Niu J, Zhang N, Giordano SH, Chavez-MacGregor M. Cardiotoxicity and cardiac monitoring among chemotherapy-treated breast cancer patients. *JACC Cardiovasc Imaging* 2018;**11**:1084–1093.
 32. Pareek N, Cevallos J, Moliner P, Shah M, Tan LL, Chambers V, Baksi AJ, Khattar RS, Sharma R, Rosen SD, Lyon AR. Activity and outcomes of a cardio-oncology service in the United Kingdom – a five-year experience. *Eur J Heart Fail* 2018;**20**:1721–1731.
 33. Lancellotti P, Suter TM, Lopez-Fernandez T, Galderisi M, Lyon AR, Van der Meer P, Cohen Solal A, Zamorano JL, Jerusalem G, Moonen M, Abovyan V, Bax JJ, Asteggiano R. Cardio-oncology services: rationale, organization, and implementation. *Eur Heart J* 2019;**40**:1756–1763.
 34. Nolan MT, Marwick TH, Plana JC, Li Z, Ness KK, Joshi VM, Green DM, Robison LL, Hudson MM, Armstrong GT. Effect of traditional heart failure risk factors on myocardial dysfunction in adult survivors of childhood cancer. *JACC Cardiovasc Imaging* 2018;**11**:1202–1203.
 35. Ezaz G, Long JB, Gross CP, Chen J. Risk prediction model for heart failure and cardiomyopathy after adjuvant trastuzumab therapy for breast cancer. *J Am Heart Assoc* 2014;**3**:e000472.
 36. Romond EH, Jeong JH, Rastogi P, Swain SM, Geyer CE Jr, Ewer MS, Rath V, Fehrenbacher L, Brufsky A, Azar CA, Flynn PJ, Zapas JL, Polikoff J, Gross HM, Biggs DD, Atkins JN, Tan-Chiu E, Zheng P, Yothers G, Mamounas EP, Wolmark N. Seven-year follow-up assessment of cardiac function in NSABP B-31, a randomized trial comparing doxorubicin and cyclophosphamide followed by paclitaxel (ACP) with ACP plus trastuzumab as adjuvant therapy for patients with node-positive, human epidermal growth factor receptor 2-positive breast cancer. *J Clin Oncol* 2012;**30**:3792–3799.
 37. Wang L, Tan TC, Halpern EF, Neilan TG, Francis SA, Picard MH, Fei H, Hochberg EP, Abramson JS, Weyman AE, Kuter I, Scherrer-Crosbie M. Major cardiac events and the value of echocardiographic evaluation in patients receiving anthracycline-based chemotherapy. *Am J Cardiol* 2015;**116**:442–446.
 38. Lang RM, Badano LP, Mor-Avi V, Afilalo J, Armstrong A, Ernande L, Flachskampf FA, Foster E, Goldstein SA, Kuznetsova T, Lancellotti P, Muraru D, Picard MH, Rietzschel ER, Rudski L, Spencer KT, Tsang W, Voigt JU. Recommendations for cardiac chamber quantification by echocardiography in adults: an update from the American Society of Echocardiography and the European Association of Cardiovascular Imaging. *Eur Heart J Cardiovasc Imaging* 2015;**16**:233–270.
 39. Lopez-Fernandez T, Thavendiranathan P. Emerging cardiac imaging modalities for the early detection of cardiotoxicity due to anticancer therapies. *Rev Esp Cardiol (Engl Ed)* 2017;**70**:487–495.
 40. Potter E, Marwick TH. Assessment of left ventricular function by echocardiography: the case for routinely adding global longitudinal strain to ejection fraction. *JACC Cardiovasc Imaging* 2018;**11** (2 Pt 1):260–274.
 41. Liu J, Banchs J, Mousavi N, Plana JC, Scherrer-Crosbie M, Thavendiranathan P, Barac A. Contemporary role of echocardiography for clinical decision making in patients during and after cancer therapy. *JACC Cardiovasc Imaging* 2018;**11**:1122–1131.
 42. Tops LF, Delgado V, Marsan NA, Bax JJ. Myocardial strain to detect subtle left ventricular systolic dysfunction. *Eur J Heart Fail* 2017;**19**:307–313.
 43. Plana JC, Thavendiranathan P, Bucciarelli-Ducci C, Lancellotti P. Multi-modality imaging in the assessment of cardiovascular toxicity in the cancer patient. *JACC Cardiovasc Imaging* 2018;**11**:1173–1186.

44. Witteles R. Type I and Type II cardiomyopathy classifications are complete nonsense: PRO. May 4, 2018. <https://www.acc.org/latest-in-cardiology/articles/2018/05/04/08/41/type-i-and-type-ii-cardiomyopathy-classifications-are-complete-nonsense-pro> (9 July 2020).
45. Knuuti J, Wijns W, Saraste A, Capodanno D, Barbato E, Funck-Brentano C, Prescott E, Storey RF, Deaton C, Cuisset T, Agewall S, Dickstein K, Edvardsen T, Escaned J, Gersh BJ, Svitol P, Gilard M, Hasdai D, Hatala R, Mahfoud F, Masip J, Muneretto C, Valgimigli M, Achenbach S, Bax JJ; ESC Scientific Document Group. 2019 ESC Guidelines for the diagnosis and management of chronic coronary syndromes. *Eur Heart J* 2020;**41**:407–477.
46. Cardinale D, Colombo A, Bacchiani G, Tedeschi L, Meroni CA, Veglia F, Civelli M, Lamantia G, Colombo N, Curigliano G, Fiorentini C, Cipolla CM. Early detection of anthracycline cardiotoxicity and improvement with heart failure therapy. *Circulation* 2015;**131**:1981–1988.
47. Ferreira de Souza T, Quinaglia AC, Osorio Costa F, Shah R, Neilan TG, Velloso L, Nadruz W, Brenelli F, Sposito AC, Matos-Souza JR, Cendes F, Coelho OR, Jerosch-Herold M, Coelho-Filho OR. Anthracycline therapy is associated with cardiomyocyte atrophy and preclinical manifestations of heart disease. *JACC Cardiovasc Imaging* 2018;**11**:1045–1055.
48. Armenian SH, Lacchetti C, Barac A, Carver J, Constine LS, Denduluri N, Dent S, Douglas PS, Durand JB, Ewer M, Fabian C, Hudson M, Jessup M, Jones LW, Ky B, Mayer EL, Moslehi J, Oeffinger K, Ray K, Ruddy K, Lenihan D. Prevention and monitoring of cardiac dysfunction in survivors of adult cancers: American Society of Clinical Oncology clinical practice guideline. *J Clin Oncol* 2017;**35**:893–911.
49. Armenian SH, Hudson MM, Mulder RL, Chen MH, Constine LS, Dwyer M, Nathan PC, Tissing WJ, Shankar S, Sieswerda E, Skinner R, Steinberger J, van Dalen EC, van der Pal H, Wallace WH, Levitt G, Kremer LC; International Late Effects of Childhood Cancer Guideline Harmonization Group. Recommendations for cardiomyopathy surveillance for survivors of childhood cancer: a report from the International Late Effects of Childhood Cancer Guideline Harmonization Group. *Lancet Oncol* 2015;**16**:e123–136.
50. Dang CT, Yu AF, Jones LW, Liu J, Steingart RM, Argolo DF, Norton L, Hudis CA. Cardiac surveillance guidelines for trastuzumab-containing therapy in early-stage breast cancer: getting to the heart of the matter. *J Clin Oncol* 2016;**34**:1030–1033.
51. Mehta LS, Watson KE, Barac A, Beckie TM, Bittner V, Cruz-Flores S, Dent S, Kondapalli L, Ky B, Okwuosa T, Pina IL, Volgman AS; American Heart Association Cardiovascular Disease in Women and Special Populations Committee of the Council on Clinical Cardiology; Council on Cardiovascular and Stroke Nursing; Council on Quality of Care and Outcomes Research. Cardiovascular disease and breast cancer: where these entities intersect: a scientific statement from the American Heart Association. *Circulation* 2018;**137**:e30–66.
52. Dang C, Guo H, Najita J, Yardley D, Marcom K, Albain K, Rugo H, Miller K, Ellis M, Shapira I, Wolff AC, Carey LA, Moy B, Groarke J, Moslehi J, Krop I, Burstein HJ, Hudis C, Winer EP, Tolanev SM. Cardiac outcomes of patients receiving adjuvant weekly paclitaxel and trastuzumab for node-negative, ERBB2-positive breast cancer. *JAMA Oncol* 2016;**2**:29–36.
53. Curigliano G, de Azambuja E, Lenihan D, Calabro MG, Cardinale D, Cipolla CM. Prevention, monitoring, and management of cardiac dysfunction in patients with metastatic breast cancer. *Oncologist* 2019;**24**:e1034–1043.
54. Choueiri TK, Mayer EL, Je Y, Rosenberg JE, Nguyen PL, Azzi GR, Bellmunt J, Burstein HJ, Schutz FA. Congestive heart failure risk in patients with breast cancer treated with bevacizumab. *J Clin Oncol* 2011;**29**:632–638.
55. Ghatalia P, Morgan CJ, Je Y, Nguyen PL, Trinh QD, Choueiri TK, Sonpavde G. Congestive heart failure with vascular endothelial growth factor receptor tyrosine kinase inhibitors. *Crit Rev Oncol Hematol* 2015;**94**:228–237.
56. Hall PS, Harshman LC, Srinivas S, Witteles RM. The frequency and severity of cardiovascular toxicity from targeted therapy in advanced renal cell carcinoma patients. *JACC Heart Fail* 2013;**1**:72–78.
57. Bronte E, Bronte G, Novo G, Bronte F, Bavetta MG, Lo Re G, Brancatelli G, Bazan V, Natoli C, Novo S, Russo A. What links BRAF to the heart function? New insights from the cardiotoxicity of BRAF inhibitors in cancer treatment. *Oncotarget* 2015;**6**:35589–35601.
58. Moslehi JJ. Cardiovascular toxic effects of targeted cancer therapies. *N Engl J Med* 2016;**375**:1457–1467.
59. Pun SC, Neilan TG. Cardiovascular side effects of small molecule therapies for cancer. *Eur Heart J* 2016;**37**:2742–2745.
60. Herrmann J, Lerman A, Sandhu NP, Villarraga HR, Mulvagh SL, Kohli M. Evaluation and management of patients with heart disease and cancer: cardio-oncology. *Mayo Clin Proc* 2014;**89**:1287–1306.
61. Touyz RM, Herrmann J. Cardiotoxicity with vascular endothelial growth factor inhibitor therapy. *NPJ Precis Oncol* 2018;**2**:13.
62. Aghel N, Delgado DH, Lipton JH. Cardiovascular toxicities of BCR-ABL tyrosine kinase inhibitors in chronic myeloid leukemia: preventive strategies and cardiovascular surveillance. *Vasc Health Risk Manag* 2017;**13**:293–303.
63. Ozgur Yurttas N, Eskazan AE. Dasatinib-induced pulmonary arterial hypertension. *Br J Clin Pharmacol* 2018;**84**:835–845.
64. Scott K, Hayden PJ, Will A, Wheatley K, Coyne I. Bortezomib for the treatment of multiple myeloma. *Cochrane Database Syst Rev* 2016;**4**:CD010816.
65. Siegel DS, Dimopoulos MA, Ludwig H, Facon T, Goldschmidt H, Jakubowiak A, San-Miguel J, Obreja M, Blaedel J, Stewart AK. Improvement in overall survival with carfilzomib, lenalidomide, and dexamethasone in patients with relapsed or refractory multiple myeloma. *J Clin Oncol* 2018;**36**:728–734.
66. Dimopoulos MA, Moreau P, Palumbo A, Joshua D, Pour L, Hajek R, Facon T, Ludwig H, Oriol A, Goldschmidt H, Rosinol L, Straub J, Suvorov A, Araujo C, Rimashevskaya E, Pika T, Gaidano G, Weisel K, Goranova-Marinova V, Schwarzer A, Minuk L, Masszi T, Karamanesh I, Offidani M, Hungria V, Spencer A, Orlowski RZ, Gillenwater HH, Mohamed N, Feng S, Chng WJ; ENDEAVOR Investigators. Carfilzomib and dexamethasone versus bortezomib and dexamethasone for patients with relapsed or refractory multiple myeloma (ENDEAVOR): a randomised, phase 3, open-label, multicentre study. *Lancet Oncol* 2016;**17**:27–38.
67. Cornell RF, Ky B, Weiss BM, Dahm CN, Gupta DK, Du L, Carver JR, Cohen AD, Engelhardt BG, Garfall AL, Goodman SA, Harrell SL, Kassim AA, Jadhav T, Jagasia M, Moslehi J, O'Quinn R, Savona MR, Slosky D, Smith A, Stadtmayer EA, Vogl DT, Waxman A, Lenihan D. Prospective study of cardiac events during proteasome inhibitor therapy for relapsed multiple myeloma. *J Clin Oncol* 2019;**37**:1946–1955.
68. Russell SD, Lyon A, Lenihan DJ, Moreau P, Joshua D, Chng WJ, Palumbo A, Goldschmidt H, Hajek R, Facon T, Ludwig H, Pour L, Niesvizky R, Oriol A, Rosinol L, Suvorov A, Gaidano G, Goranova-Marinova V, Gillenwater HH, Mohamed N, Feng S, Dimopoulos MA. Serial echocardiographic assessment of patients with relapsed multiple myeloma receiving carfilzomib and dexamethasone vs bortezomib and dexamethasone: a substudy of the phase 3 Endeavor trial (NCT01568866). *Blood* 2015;**126**:4250.
69. Keramida K, Parissis JT, Chioncel O, Farmakis D. Cardiogenic shock in cancer. *Heart Fail Rev* 2019;**24**:997–1004.
70. Haanen J, Carbone F, Robert C, Kerr KM, Peters S, Larkin J, Jordan K, Committee EG. Management of toxicities from immunotherapy: ESMO clinical practice guidelines for diagnosis, treatment and follow-up. *Ann Oncol* 2017;**28** (Suppl 4):iv119–142.
71. Varricchi G, Galdieri MR, Tocchetti CG. Cardiac toxicity of immune checkpoint inhibitors: cardio-oncology meets immunology. *Circulation* 2017;**136**:1989–1992.
72. Caforio AL, Marcolongo R, Jahns R, Fu M, Felix SB, Iliceto S. Immune-mediated and autoimmune myocarditis: clinical presentation, diagnosis and management. *Heart Fail Rev* 2013;**18**:715–732.
73. Mahmood SS, Fradley MG, Cohen JV, Nohria A, Reynolds KL, Heinzerling LM, Sullivan RJ, Damrongwatanasuk R, Chen CL, Gupta D, Kirchberger MC, Awadalla M, Hassan MZO, Moslehi JJ, Shah SP, Ganatra S, Thavendiranathan P, Lawrence DP, Groarke JD, Neilan TG. Myocarditis in patients treated with immune checkpoint inhibitors. *J Am Coll Cardiol* 2018;**71**:1755–1764.
74. Hsiao JF, Koshino Y, Bonnichsen CR, Yu Y, Miller FA Jr, Pellikka PA, Cooper LT Jr, Villarraga HR. Speckle tracking echocardiography in acute myocarditis. *Int J Cardiovasc Imaging* 2013;**29**:275–284.
75. Messroghli DR, Moon JC, Ferreira VM, Grosse-Wortmann L, He T, Kellman P, Mascherbauer J, Nezafat R, Salerno M, Schelbert EB, Taylor AJ, Thompson R, Ugander M, van Heeswijk RB, Friedrich MG. Clinical recommendations for cardiovascular magnetic resonance mapping of T1, T2, T2* and extracellular volume: a consensus statement by the Society for Cardiovascular Magnetic Resonance (SCMR) endorsed by the European Association for Cardiovascular Imaging (EACVI). *J Cardiovasc Magn Reson* 2017;**19**:75.
76. Jordan JH, Todd RM, Vasu S, Hundley WG. Cardiovascular magnetic resonance in the oncology patient. *JACC Cardiovasc Imaging* 2018;**11**:1150–1172.
77. Thavendiranathan P, Wintersperger BJ, Flamm SD, Marwick TH. Cardiac MRI in the assessment of cardiac injury and toxicity from cancer chemotherapy: a systematic review. *Circ Cardiovasc Imaging* 2013;**6**:1080–1091.
78. Galan-Arriola C, Lobo M, Vilchez-Tschischke JP, Lopez GJ, de Molina-Iracheta A, Perez-Martinez C, Aguero J, Fernandez-Jimenez R, Martin-Garcia A, Oliver E, Villena-Gutierrez R, Pizarro G, Sanchez PL, Fuster V, Sanchez-Gonzalez J, Ibanez B. Serial magnetic resonance imaging to identify early stages of anthracycline-induced cardiotoxicity. *J Am Coll Cardiol* 2019;**73**:779–791.
79. Bonaca MP, Olenchock BA, Salem JE, Wiviott SD, Ederhy S, Cohen A, Stewart GC, Choueiri TK, Di Carli M, Allenbach Y, Kumbhani DJ, Heinzerling L, Amiri-Kordestani L, Lyon AR, Thavendiranathan P, Padera R, Lichtman A, Liu PP, Johnson DB, Moslehi J. Myocarditis in the setting of cancer therapeutics:

- proposed case definitions for emerging clinical syndromes in cardio-oncology. *Circulation* 2019;**140**:80–91.
80. Lee SP, Park JB, Kim HK, Kim YJ, Grogan M, Sohn DW. Contemporary imaging diagnosis of cardiac amyloidosis. *J Cardiovasc Imaging* 2019;**27**:1–10.
 81. Mousavi N, Cheezum MK, Aghayev A, Padera R, Vita T, Steigner M, Hulthen E, Bittencourt MS, Dorbala S, Di Carli MF, Kwong RY, Dunne R, Blankstein R. Assessment of cardiac masses by cardiac magnetic resonance imaging: histological correlation and clinical outcomes. *J Am Heart Assoc* 2019;**8**:e007829.
 82. Sarocchi M, Bauckneht M, Arboscello E, Capitanio S, Marini C, Morbelli S, Miglino M, Congiu AG, Ghigliotti G, Balbi M, Brunelli C, Sambuceti G, Ameri P, Spallarossa P. An increase in myocardial 18-fluorodeoxyglucose uptake is associated with left ventricular ejection fraction decline in Hodgkin lymphoma patients treated with anthracycline. *J Transl Med* 2018;**16**:295.
 83. Darby SC, Cutter DJ, Boerma M, Constine LS, Fajardo LF, Kodama K, Mabuchi K, Marks LB, Mettler FA, Pierce LJ, Trott KR, Yeh ET, Shore RE. Radiation-related heart disease: current knowledge and future prospects. *Int J Radiat Oncol Biol Phys* 2010;**76**:656–665.
 84. Lancellotti P, Nkomo VT, Badano LP, Bergler-Klein J, Bogaert J, Davin L, Cosyns B, Coucke P, Dulgheru R, Edvardsen T, Gaemperli O, Galderisi M, Griffin B, Heidenreich PA, Nieman K, Plana JC, Port SC, Scherrer-Crosbie M, Schwartz RG, Sebag IA, Voigt JU, Wann S, Yang PC. Expert consensus for multi-modality imaging evaluation of cardiovascular complications of radiotherapy in adults: a report from the European Association of Cardiovascular Imaging and the American Society of Echocardiography. *Eur Heart J Cardiovasc Imaging* 2013;**14**:721–740.
 85. Filopei J, Frishman W. Radiation-induced heart disease. *Cardiol Rev* 2012;**20**:184–188.
 86. Heidenreich PA, Hancock SL, Lee BK, Mariscal CS, Schnittger I. Asymptomatic cardiac disease following mediastinal irradiation. *J Am Coll Cardiol* 2003;**42**:743–749.
 87. Chang HM, Okwuosa TM, Scarabelli T, Moudgil R, Yeh ET. Cardiovascular complications of cancer therapy: best practices in diagnosis, prevention, and management: part 2. *J Am Coll Cardiol* 2017;**70**:2552–2565.
 88. Mercurio V, Cuomo A, Della Pepa R, Ciervo D, Cella L, Pirozzi F, Parrella P, Campi G, Franco R, Varricchi G, Abete P, Marone G, Petretta M, Bonaduce D, Pacelli R, Picardi M, Tocchetti CG. What is the cardiac impact of chemotherapy and subsequent radiotherapy in lymphoma patients? *Antioxid Redox Signal* 2019;**31**:1166–1174.
 89. van Nimwegen FA, Schaapveld M, Janus CP, Krol AD, Petersen EJ, Raemaekers JM, Kok WE, Aleman BM, van Leeuwen FE. Cardiovascular disease after Hodgkin lymphoma treatment: 40-year disease risk. *JAMA Intern Med* 2015;**175**:1007–1017.
 90. Girinsky T, M'Kacher R, Lessard N, Koscielnny S, Elfassy E, Raoux F, Carde P, Santos MD, Margainaud JP, Sabatier L, Ghalibafian M, Paul JF. Prospective coronary heart disease screening in asymptomatic Hodgkin lymphoma patients using coronary computed tomography angiography: results and risk factor analysis. *Int J Radiat Oncol Biol Phys* 2014;**89**:59–66.
 91. Darby SC, Ewertz M, McGale P, Bennet AM, Blom-Goldman U, Bronnum D, Correa C, Cutter D, Gagliardi G, Gigante B, Jensen MB, Nisbet A, Peto R, Rahimi K, Taylor C, Hall P. Risk of ischemic heart disease in women after radiotherapy for breast cancer. *N Engl J Med* 2013;**368**:987–998.
 92. Daniels LA, Krol AD, de Graaf MA, Scholte AJ, Van't Veer MB, Putter H, de Roos A, Schaliq MJ, Creutzberg CL. Screening for coronary artery disease after mediastinal irradiation in Hodgkin lymphoma survivors: phase II study of indication and acceptance†. *Ann Oncol* 2014;**25**:1198–1203.
 93. Meijboom WB, van Mieghem CA, Mollet NR, Pugliese F, Weustink AC, van Pelt N, Cademartiri F, Nieman K, Boersma E, de Jaegere P, Krestin GP, de Feyter PJ. 64-Slice computed tomography coronary angiography in patients with high, intermediate, or low pretest probability of significant coronary artery disease. *J Am Coll Cardiol* 2007;**50**:1469–1475.
 94. Newby DE, Adamson PD, Berry C, Boon NA, Dweck MR, Flather M, Forbes J, Hunter A, Lewis S, MacLean S, Mills NL, Norrie J, Roditi G, Shah AS, Timmis AD, van Beek EJ, Williams MC; SCOT-HEART Investigators. Coronary CT angiography and 5-year risk of myocardial infarction. *N Engl J Med* 2018;**379**:924–933.
 95. Hecht HS, Cronin P, Blaha MJ, Budoff MJ, Kazerooni EA, Narula J, Yankelevitz D, Abbara S. 2016 SCCT/STR guidelines for coronary artery calcium scoring of noncontrast noncardiac chest CT scans: a report of the Society of Cardiovascular Computed Tomography and Society of Thoracic Radiology. *J Thorac Imaging* 2017;**32**:W54–66.
 96. Roos CT, van den Bogaard VA, Greuter MJ, Vliegthart R, Schuit E, Langendijk JA, van der Schaaf A, Crijns AP, Maduro JH. Is the coronary artery calcium score associated with acute coronary events in breast cancer patients treated with radiotherapy? *Radiother Oncol* 2018;**126**:170–176.
 97. Ryan JJ, Archer SL. Emerging concepts in the molecular basis of pulmonary arterial hypertension: part I: metabolic plasticity and mitochondrial dynamics in the pulmonary circulation and right ventricle in pulmonary arterial hypertension. *Circulation* 2015;**131**:1691–1702.
 98. Henriksen PA. Anthracycline cardiotoxicity: an update on mechanisms, monitoring and prevention. *Heart* 2018;**104**:971–977.
 99. Sandoo A, Kitas GD, Carmichael AR. Endothelial dysfunction as a determinant of trastuzumab-mediated cardiotoxicity in patients with breast cancer. *Anticancer Res* 2014;**34**:1147–1151.
 100. Ranchoux B, Meloche J, Paulin R, Boucherat O, Provencher S, Bonnet S. DNA damage and pulmonary hypertension. *Int J Mol Sci* 2016;**17**:990.
 101. Tadic M, Cuspodi C, Hering D, Venneri L, Danylenko O. The influence of chemotherapy on the right ventricle: did we forget something? *Clin Cardiol* 2017;**40**:437–443.
 102. Nakano S, Takahashi M, Kimura F, Senoo T, Saeki T, Ueda S, Tanno J, Senbonmatsu T, Kasai T, Nishimura S. Cardiac magnetic resonance imaging-based myocardial strain study for evaluation of cardiotoxicity in breast cancer patients treated with trastuzumab: a pilot study to evaluate the feasibility of the method. *Cardiol J* 2016;**23**:270–280.
 103. Galderisi M, Cosyns B, Edvardsen T, Cardim N, Delgado V, Di Salvo G, Donal E, Sade LE, Ernande L, Garbi M, Grapsa J, Hagendorff A, Kamp O, Magne J, Santoro C, Stefanidis A, Lancellotti P, Popescu B, Habib G; 2016–2018 EACVI Scientific Documents Committee. Standardization of adult transthoracic echocardiography reporting in agreement with recent chamber quantification, diastolic function, and heart valve disease recommendations: an expert consensus document of the European Association of Cardiovascular Imaging. *Eur Heart J Cardiovasc Imaging* 2017;**18**:1301–1310.
 104. Muraru D, Spadotto V, Cecchetto A, Romeo G, Aruta P, Ermacora D, Jenei C, Cucchini U, Illiceto S, Badano LP. New speckle-tracking algorithm for right ventricular volume analysis from three-dimensional echocardiographic data sets: validation with cardiac magnetic resonance and comparison with the previous analysis tool. *Eur Heart J Cardiovasc Imaging* 2016;**17**:1279–1289.
 105. Pepi M, Evangelista A, Nihoyannopoulos P, Flachskampf FA, Athanassopoulos G, Colonna P, Habib G, Ringelstein EB, Sicari R, Zamorano JL, Sitges M, Caso P; European Association of Echocardiography. Recommendations for echocardiography use in the diagnosis and management of cardiac sources of embolism: European Association of Echocardiography (EAE) (a registered branch of the ESC). *Eur J Echocardiogr* 2010;**11**:461–476.
 106. Mazokopakis EE, Syros PK, Starakis IK. Nonbacterial thrombotic endocarditis (marantic endocarditis) in cancer patients. *Cardiovasc Hematol Disord Drug Targets* 2010;**10**:84–86.
 107. Zaragoza-Macias E, Chen MA, Gill EA. Real time three-dimensional echocardiography evaluation of intracardiac masses. *Echocardiography* 2012;**29**:207–219.
 108. Bhattacharyya S, Khattar R, Senior R. Characterisation of intra-cardiac masses by myocardial contrast echocardiography. *Int J Cardiol* 2013;**163**:e11–13.
 109. Xia H, Gan L, Jiang Y, Tang Q, Zhang P, Tang X, Wen L, Liu Z, Gao Y. Use of transesophageal echocardiography and contrast echocardiography in the evaluation of cardiac masses. *Int J Cardiol* 2017;**236**:466–472.
 110. Fussen S, De Boeck BW, Zellweger MJ, Bremerich J, Goetschalckx K, Zuber M, Buser PT. Cardiovascular magnetic resonance imaging for diagnosis and clinical management of suspected cardiac masses and tumours. *Eur Heart J* 2011;**32**:1551–1560.
 111. Pazos-Lopez P, Pozo E, Siqueira ME, Garcia-Lunar I, Cham M, Jacobi A, Macaluso F, Fuster V, Narula J, Sanz J. Value of CMR for the differential diagnosis of cardiac masses. *JACC Cardiovasc Imaging* 2014;**7**:896–905.
 112. Motwani M, Kidambi A, Herzog BA, Uddin A, Greenwood JP, Plein S. MR imaging of cardiac tumors and masses: a review of methods and clinical applications. *Radiology* 2013;**268**:26–43.
 113. Kikuchi Y, Oyama-Manabe N, Manabe O, Naya M, Ito YM, Hatanaka KC, Tsutsui H, Terae S, Tamaki N, Shirato H. Imaging characteristics of cardiac dominant diffuse large B-cell lymphoma demonstrated with MDCT and PET/CT. *Eur J Nucl Med Mol Imaging* 2013;**40**:1337–1344.
 114. Ferreira VM, Holloway CJ, Piechnik SK, Karamitsos TD, Neubauer S. Is it really fat? Ask a T1-map. *Eur Heart J Cardiovasc Imaging* 2013;**14**:1060.
 115. Lapinskas T, Kouwenhoven M, Schnackenburg B, Bigvava T, Wassilew K, Gebker R, Jacobs S, Zaliunas R, Pieske B, Kelle S. Cardiac MRI quantitative tissue characterization of right atrial mass using mDixon and parametric mapping. *Clin Res Cardiol* 2017;**106**:840–845.
 116. Kassop D, Donovan MS, Cheezum MK, Nguyen BT, Gambill NB, Blankstein R, Villines TC. Cardiac masses on cardiac CT: a review. *Curr Cardiovasc Imaging Rep* 2014;**7**:9281.
 117. Young PM, Foley TA, Araoz PA, Williamson EE. Computed tomography imaging of cardiac masses. *Radiol Clin North Am* 2019;**57**:75–84.
 118. Rahbar K, Seifarth H, Schafers M, Stegger L, Hoffmeier A, Spieker T, Tiemann K, Maintz D, Scheld HH, Schober O, Weckesser M. Differentiation of malignant and benign cardiac tumors using 18F-FDG PET/CT. *J Nucl Med* 2012;**53**:856–863.

119. Patel KS, Hawkins PN. Cardiac amyloidosis: where are we today? *J Intern Med* 2015;**278**:126–144.
120. Falk RH, Alexander KM, Liao R, Dorbala S. AL (light-chain) cardiac amyloidosis: a review of diagnosis and therapy. *J Am Coll Cardiol* 2016;**68**:1323–1341.
121. Martinez-Naharro A, Treibel TA, Abdel-Gadir A, Bulluck H, Zumbo G, Knight DS, Kotecha T, Francis R, Hutt DF, Rezk T, Rosmini S, Quarta CC, Whelan CJ, Kellman P, Gillmore JD, Moon JC, Hawkins PN, Fontana M. Magnetic resonance in transthyretin cardiac amyloidosis. *J Am Coll Cardiol* 2017;**70**:466–477.
122. Maurer MS, Elliott P, Comenzo R, Semigran M, Rapezzi C. Addressing common questions encountered in the diagnosis and management of cardiac amyloidosis. *Circulation* 2017;**135**:1357–1377.
123. Buss SJ, Emami M, Mereles D, Korosoglou G, Kristen AV, Voss A, Schellberg D, Zugck C, Galuschky C, Giannitsis E, Heigenbart U, Ho AD, Katus HA, Schonland SO, Hardt SE. Longitudinal left ventricular function for prediction of survival in systemic light-chain amyloidosis: incremental value compared with clinical and biochemical markers. *J Am Coll Cardiol* 2012;**60**:1067–1076.
124. Phelan D, Collier P, Thavendiranathan P, Popovic ZB, Hanna M, Plana JC, Marwick TH, Thomas JD. Relative apical sparing of longitudinal strain using two-dimensional speckle-tracking echocardiography is both sensitive and specific for the diagnosis of cardiac amyloidosis. *Heart* 2012;**98**:1442–1448.
125. Baccouche H, Maunz M, Beck T, Gaa E, Banzhaf M, Knayer U, Fogarassy P, Beyer M. Differentiating cardiac amyloidosis and hypertrophic cardiomyopathy by use of three-dimensional speckle tracking echocardiography. *Echocardiography* 2012;**29**:668–677.
126. Williams LK, Forero JF, Popovic ZB, Phelan D, Delgado D, Rakowski H, Wintersperger BJ, Thavendiranathan P. Patterns of CMR measured longitudinal strain and its association with late gadolinium enhancement in patients with cardiac amyloidosis and its mimics. *J Cardiovasc Magn Reson* 2017;**19**:61.
127. Nicol M, Baudet M, Brun S, Harel S, Royer B, Vignon M, Lairez O, Lavergne D, Jaccard A, Attias D, Macron L, Gayat E, Cohen-Solal A, Arnulf B, Logeart D. Diagnostic score of cardiac involvement in AL amyloidosis. *Eur Heart J Cardiovasc Imaging* 2020;**21**:542–548.
128. Pozo E, Kanwar A, Deochand R, Castellano JM, Naib T, Pazos-Lopez P, Osman K, Cham M, Narula J, Fuster V, Sanz J. Cardiac magnetic resonance evaluation of left ventricular remodelling distribution in cardiac amyloidosis. *Heart* 2014;**100**:1688–1695.
129. Shah R, Nucifora G, Perry R, Selvanayagam JB. Noninvasive imaging in cardiac deposition diseases. *J Magn Reson Imaging* 2018;**47**:44–59.
130. Haaf P, Garg P, Messroghli DR, Broadbent DA, Greenwood JP, Plein S. Cardiac T1 mapping and extracellular volume (ECV) in clinical practice: a comprehensive review. *J Cardiovasc Magn Reson* 2016;**18**:89.
131. Martinez-Naharro A, Kotecha T, Norrington K, Boldrini M, Rezk T, Quarta C, Treibel TA, Whelan CJ, Knight DS, Kellman P, Ruberg FL, Gillmore JD, Moon JC, Hawkins PN, Fontana M. Native T1 and extracellular volume in transthyretin amyloidosis. *JACC Cardiovasc Imaging* 2019;**12**:810–819.
132. Manwani R, Page J, Lane T, Burniston M, Skillen A, Lachmann HJ, Gillmore JD, Fontana M, Whelan C, Hawkins PN, Wagner T, Wechalekar AD. A pilot study demonstrating cardiac uptake with ¹⁸F-florbetapir PET in AL amyloidosis patients with cardiac involvement. *Amyloid* 2018;**25**:247–252.
133. Ehman EC, El-Sady MS, Kijewski MF, Khor YM, Jacob S, Ruberg FL, Sanchowawala V, Landau H, Yee AJ, Bianchi G, Di Carli MF, Falk RH, Hyun H, Dorbala S. Early detection of multiorgan light chain (AL) amyloidosis by whole body (18)F-florbetapir PET/CT. *J Nucl Med* 2019;**60**:1234–1239.
134. Hutt DF, Quigley AM, Page J, Hall ML, Burniston M, Gopaul D, Lane T, Whelan CJ, Lachmann HJ, Gillmore JD, Hawkins PN, Wechalekar AD. Utility and limitations of ³²P-diphosphono-1,2-propanodicarboxylic acid scintigraphy in systemic amyloidosis. *Eur Heart J Cardiovasc Imaging* 2014;**15**:1289–1298.
135. Ha J, Tan W. Gastrointestinal carcinoid tumours: a review. *J Gastrointest Dig Syst* 2012;**2**:107.
136. Patel C, Mathur M, Escarcega RO, Bove AA. Carcinoid heart disease: current understanding and future directions. *Am Heart J* 2014;**167**:789–795.
137. Studer Bruengger AA, Wechalekar K, Khattar R, Rosen SD, Robertus JL, Chau I, Morganstein D, Rosendahl U, Lyon A, Mohiaddin R. Histologically proven myocardial carcinoid metastases: the value of multimodality imaging. *Can J Cardiol* 2017;**33**:1336.e9–12.
138. Bhattacharyya S, Davar J, Dreyfus G, Caplin ME. Carcinoid heart disease. *Circulation* 2007;**116**:2860–2865.
139. Pandya UH, Pellikka PA, Enriquez-Sarano M, Edwards WD, Schaff HV, Connolly HM. Metastatic carcinoid tumor to the heart: echocardiographic-pathologic study of 11 patients. *J Am Coll Cardiol* 2002;**40**:1328–1332.
140. Wong KK, Waterfield RT, Marzola MC, Scarsbrook AF, Chowdhury FU, Gross MD, Rubello D. Contemporary nuclear medicine imaging of neuroendocrine tumours. *Clin Radiol* 2012;**67**:1035–1050.
141. Davar J, Connolly HM, Caplin ME, Pavel M, Zacks J, Bhattacharyya S, Cuthbertson DJ, Dobson R, Grozinsky-Glasberg S, Steeds RP, Dreyfus G, Pellikka PA, Toumpanakis C. Diagnosing and managing carcinoid heart disease in patients with neuroendocrine tumors: an expert statement. *J Am Coll Cardiol* 2017;**69**:1288–1304.
142. Korosoglou G, Giusca S, Hofmann NP, Patel AR, Lapinskas T, Pieske B, Steen H, Katus HA, Kelle S. Strain-encoded magnetic resonance: a method for the assessment of myocardial deformation. *ESC Heart Fail* 2019;**6**:584–602.
143. PROactive Evaluation of Function to Avoid CardioToxicity (PROACT). ClinicalTrials.gov Identifier NCT0386131. <https://clinicaltrials.gov/ct2/results?recrs=ab&cond=Cardiotoxicity&term=NCT0386131&cntry=US&state=&city=&dist=> (9 July 2020).
144. Muehlberg F, Funk S, Zange L, von Knobelsdorff-Brenkenhoff F, Blaszczyk E, Schulz A, Ghani S, Reichardt A, Reichardt P, Schulz-Menger J. Native myocardial T1 time can predict development of subsequent anthracycline-induced cardiomyopathy. *ESC Heart Fail* 2018;**5**:620–629.
145. Cheng HZ, Zhu X, Smith AM, Qian Y, O'Quinn R, Silvestry F, Han Y, Scherrer-Crosbie M, Ferreri V, Duffy K, Jagasia D, Davatzikos C, Fan Y, Ky B. The use of machine learning to predict doxorubicin cardiotoxicity. *JACC Cardiovasc Imaging* 2018;**7**:1465.
146. Favreau-Lessard AJ, Sawyer DB, Francis SA. Anthracycline cardiomyopathy: the plot gets thinner. *Circ Heart Fail* 2018;**11**:e005194.
147. Gillam LD, Leipsic J, Weissman NJ. Use of imaging endpoints in clinical trials. *JACC Cardiovasc Imaging* 2017;**10**:296–303.