



Universiteit
Leiden
The Netherlands

Leaflet immobility and thrombosis in transcatheter aortic valve replacement

Ng, A.C.T.; Holmes, D.R.; Mack, M.J.; Delgado, V.; Makkar, R.; Blanke, P.; ... ; Bax, J.J.

Citation

Ng, A. C. T., Holmes, D. R., Mack, M. J., Delgado, V., Makkar, R., Blanke, P., ... Bax, J. J. (2020). Leaflet immobility and thrombosis in transcatheter aortic valve replacement. *European Heart Journal*, 41(33), 3184-3197. doi:10.1093/eurheartj/ehaa542

Version: Publisher's Version

License: [Creative Commons CC BY 4.0 license](https://creativecommons.org/licenses/by/4.0/)

Downloaded from: <https://hdl.handle.net/1887/3232658>

Note: To cite this publication please use the final published version (if applicable).

Leaflet immobility and thrombosis in transcatheter aortic valve replacement

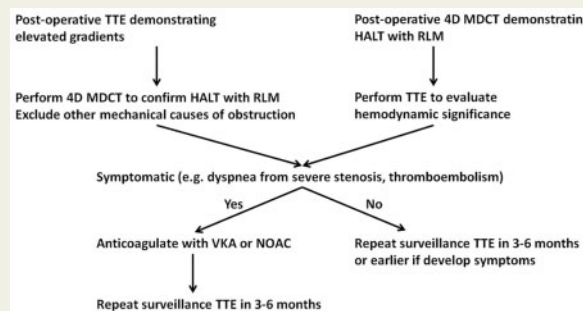
Arnold C. T. Ng ¹, David R. Holmes ², Michael J. Mack ³, Victoria Delgado ⁴, Raj Makkar ⁵, Philipp Blanke ⁶, Jonathon A. Leipsic ⁶, Martin B. Leon ⁷, and Jeroen J. Bax ^{4*}

¹Department of Cardiology, Princess Alexandra Hospital, Brisbane, Australia; ²Department of Cardiovascular Medicine, Mayo Clinic, Rochester, MN, USA; ³Baylor Scott and White Health, Plano, TX, USA; ⁴Department of Cardiology, Leiden University Medical Center, Albinusdreef 2, 2333 ZA Leiden, The Netherlands; ⁵Cedars-Sinai Medical Center, Los Angeles, CA, USA; ⁶Department of Radiology, St. Paul's Hospital and University of British Columbia, Vancouver, British Columbia, Canada; and ⁷Columbia University Medical Center, New York-Presbyterian Hospital, New York, NY, USA

Received 4 February 2020; revised 17 April 2020; editorial decision 10 June 2020; accepted 1 July 2020

Transcatheter aortic valve replacement (TAVR) has grown exponentially worldwide in the last decade. Due to the higher bleeding risks associated with oral anticoagulation and in patients undergoing TAVR, antiplatelet therapy is currently considered first-line antithrombotic treatment after TAVR. Recent studies suggest that some patients can develop subclinical transcatheter heart valve (THV) thrombosis after the procedure, whereby thrombus forms on the leaflets that can be a precursor to leaflet dysfunction. Compared with echocardiography, multidetector computed tomography is more sensitive at detecting THV thrombosis. Transcatheter heart valve thrombosis can occur while on dual antiplatelet therapy with aspirin and thienopyridine but significantly less with anticoagulation. This review summarizes the incidence and diagnostic criteria for THV thrombosis and discusses the pathophysiological mechanisms that may lead to thrombus formation, its natural history, potential clinical implications and treatment for these patients.

Graphical Abstract



Keywords

Thrombosis • Transcatheter aortic valve replacement • Antiplatelet therapy • Antithrombotic treatment • Transcatheter heart valve

*Corresponding author. Tel: +31 71 526 2020, Fax: +31 71 526 6709, Email: jj.bax@lumc.nl

© The Author(s) 2020. Published by Oxford University Press on behalf of the European Society of Cardiology.

This is an Open Access article distributed under the terms of the Creative Commons Attribution-NonCommercial License (<https://creativecommons.org/licenses/by-nc/4.0/>), which permits non-commercial re-use, distribution, and reproduction in any medium, provided the original work is properly cited. For commercial re-use, please contact journals.permissions@oup.com

Introduction

The use of bioprosthetic aortic valves as compared with mechanical valves has been the dominant strategy for the treatment of aortic stenosis in elderly patients. Worldwide, transcatheter aortic valve replacement (TAVR) has replaced surgical aortic valve replacement (SAVR) as the treatment of choice for high-risk patients and is increasingly utilized in lower-risk patients. Recent data suggested that TAVR for intermediate- and low-risk aortic stenosis patients was associated with significantly lower stroke and mortality risk at 1 year compared with SAVR.^{1,2} Furthermore, there is preliminary evidence for survival benefit in early TAVR for asymptomatic patients with very severe aortic stenosis.³ Accordingly, it is likely that TAVR will be increasingly utilized in the future.

However, subclinical transcatheter heart valve (THV) thrombosis (usually referring to thrombus formation on the valve leaflets) following TAVR is increasingly recognized in patients who undergo routine four-dimensional (4D) multidetector computed tomography (MDCT) post-procedure. This review aims to determine the incidence of THV thrombosis, identify potential pathogenesis, summarize the imaging diagnostic criteria, and explore potential clinical implications and management strategies for patients.

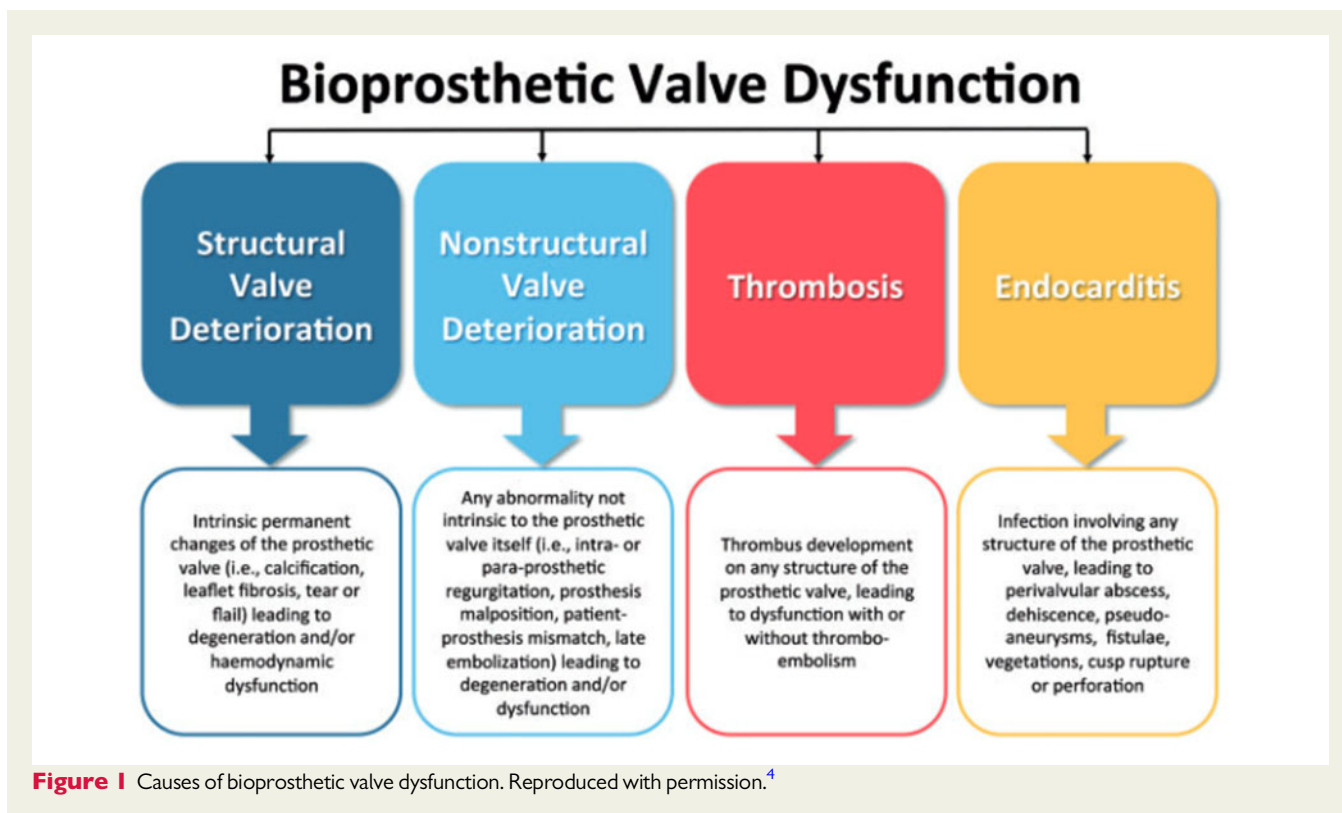
Bioprosthetic valve dysfunction

With the exponential growth of TAVR worldwide, valve durability is now a central consideration as the procedure moves towards becoming the dominant treatment strategy for aortic stenosis

irrespective of surgical risk scores. To date, there have been several attempts to define structural valve deterioration (SVD) primarily based on the echocardiographic quantification of valvular stenosis or paravalvular regurgitation.⁴⁻⁶ However, they are severely limited by highly variable echocardiographic criteria and do not provide insights into the pathophysiology of SVD. To facilitate and direct future research, the European Association of Percutaneous Cardiovascular Interventions (EAPCI) has proposed standardized definitions for valve dysfunction in conjunction with the European Society of Cardiology (ESC) and European Association for Cardio-Thoracic Surgery (EACTS).⁴ In their consensus statement, the task force proposed that bioprosthetic valve dysfunction may be categorized into SVD, non-SVD, thrombosis or endocarditis (Figure 1). Importantly, SVD was defined as irreversible valve dysfunction, whereas thrombosis and endocarditis are potential reversible causes of valve dysfunction and should be categorized separately. However, valve leaflet thrombosis can result in permanent dysfunction leading to bioprosthetic valve failure. Finally, bioprosthetic valve failure (a clinical correlate) was defined as valve dysfunction detected on autopsy likely causing death, valve reintervention (i.e. valve-in-valve, paravalvular leak closure or SAVR), or severe haemodynamic SVD. Over the last few years, it has been recognized that THV thrombosis is often under-diagnosed and may be a potential cause of valvular dysfunction.

Incidence of valve thrombosis

The reported incidence of THV thrombosis is dependent on several factors, including the population being evaluated, diagnostic imaging



modality (echocardiography vs. MDCT), and the definition of abnormality. Often, the diagnostic imaging modality utilized depends on the clinical setting (such as haemodynamic instability, or in relation to clinical events such as stroke or systemic embolism), or as part of routine clinical surveillance or randomized controlled clinical trial. Before the advent of TAVR, the reported incidence of bioprosthetic valve thrombosis was <1%.⁷ In a meta-analysis that included nine studies totalling 5837 patients with stented porcine bioprosthetic valves, there were only three reported cases of valve thrombosis and a calculated annual incidence of 0.03%. In a large single-centre series from Mayo Clinics that included 397 patients with explanted bioprosthetic valves, 46 (11.6%) patients had pathologically proven leaflet thrombosis.⁸ Based on the total 6178 bioprosthetic valve implanted within the reported period, the overall incidence of valve thrombosis requiring repeat surgery was 0.74%. However, these reported surgical incidences were likely an underestimation as the condition is often unrecognized. Even current surgical guidelines recommend including diagnostic imaging tests such as echocardiography to define SVD, non-SVD and valve thrombosis.⁹ While it is possible to draw lessons from long-term experiences with SAVR, there are fundamental differences in the valve construct when compared with TAVR. These differences may potentially impact the pathogenesis and natural history of SVD and remain to be fully explored in future studies.

Pathogenesis

Thrombosis plays a central role in some patients with early THV leaflet dysfunction. Resolution of the echocardiographic and MDCT THV abnormalities [e.g. hypoattenuated leaflet thickening (HALT)] with anticoagulation strongly suggests a thrombosis pathology, but specific insights into the pathophysiology of initial thrombus formation on the leaflets remain unclear. Whether unrecognized or untreated early THV thrombosis represents a long-term risk factor for subsequent SVD from tissue degeneration and/or fibrosis is unclear. However, determining its impact on THV longevity is of great clinical importance and can only be evaluated by long-term outcome studies. To develop effective risk stratification tools to identify at-risk patients, formulate effective treatment strategies, and determine appropriate surveillance protocols, it is important to identify the mechanisms leading to THV thrombosis.

Based on the principles of Virchow's triad, factors contributing to THV thrombosis can be categorized into alterations in the constitution of blood, endothelial dysfunction, or alterations in blood flow. For example, elderly TAVR patients more likely have underlying prothrombotic comorbidities such as cancer. Another potential prothrombotic aetiology concerns the recovery of large von Willebrand factor multimers following the treatment for aortic stenosis. Usually, the loss of these macromolecules due to shear stress is associated with bleeding diathesis in severe aortic stenosis. Recently, Yamashita et al.¹⁰ observed rapid correction of these high-molecular weight von Willebrand factor multimers post-aortic valve replacement, and patients were characterized as being in a 'von Willebrand factor predominant state' between post-operative Days 8 and 22, predisposing them to thrombosis rather than bleeding even in the early stage after surgery. These factors may potentially contribute to the pathogenesis of HALT early after TAVR.

Regarding endothelial dysfunction, the previous study demonstrated that bioprosthetic tissues undergo four phases of healing after implantation, starting from initial platelet and fibrin deposition to inflammation, granulation tissue, and eventual fibrous encapsulation.¹¹ Factors resulting in delayed re-endothelialization would theoretically increase thrombotic risks. Jilalawi et al.¹² have suggested a systematic and quantitative 4D MDCT analysis protocol evaluating stent frame-related factors that could potentially contribute to THV thrombosis, including native commissural/bioprosthetic leaflet orientation, stent frame expansion, stent frame fracture, depth, and symmetry of implantation. Theoretically, technical complications such as stent frame fracture could result in delayed re-endothelialization and increased risk of THV thrombosis. Midha et al.¹³ reported that over-expansion was associated with the higher incidence of THV thrombosis. The authors suggested that over-expansion of the THV stent may increase endothelial injury and provide a nidus for thrombus formation.

Notably, however, majority of studies on leaflet re-endothelialization is related to surgical valves with limited analyses on TAVR valves. However, endothelial-like cells noted on the leaflet surfaces of explanted TAVR often have an abnormal morphology suggestive of endothelial dysfunction.¹⁴ Studies on endothelial dysfunction of native valve leaflets have demonstrated impaired nitric oxide generation and subsequent activation and proliferation of interstitial valve cells, increased reactive oxygen species generation with promotion of osteogenic differentiation of the interstitial valve cells, and inflammation with recruitment of immune cells within the leaflets.^{15–17} Valvular endothelial dysfunction may also be related to valve toxicity related to fixatives such as glutaraldehyde used in manufacturing process.¹⁸

However, most studies have predominantly focused on alterations in blood flow leading to THV thrombosis.^{8,13,19–26} Transcatheter heart valve thrombosis is typically localized to the aortic side of the leaflets. Although all leaflets can be involved, previous studies suggested that the leaflet corresponding to the native right coronary cusp may be more commonly affected.^{27,28} Analysis of published literature revealed several common flow-related predictors of THV thrombosis including height of annular deployment and neo-sinuses, valve-in-valve procedures/patient-prosthesis mismatch, and reduced cardiac output.

Aortic root and neo-sinuses

Insights arising from cardiac magnetic resonance on aortic valve sparing surgery for aortic regurgitation showed that the sinuses of Valsalva generate vortices that form during early systole and persist into early diastole and may thus play a role in reducing the risk of thrombus formation on the aortic side of the leaflets (Figure 2).^{29,30} Using aortic root phantoms, Jahren et al.³¹ showed that the aortic root morphology can affect blood flow behind the TAVR prosthesis. Specifically, there was absent vortex formation within the sinuses and resultant relative blood stasis behind the TAVR leaflets. Unlike SAVR whereby the native leaflets are removed, TAVR results in a new small 'neo-sinus' located between the displaced diseased native valve leaflets and the TAVR leaflets where thrombus usually forms (Figure 3). Detailed *in vitro* modelling showed increased blood stasis within these neo-sinuses as quantified by blood residence time in TAVR compared with SAVR (Figure 4, top panel).¹⁹ The volume of these neo-sinuses

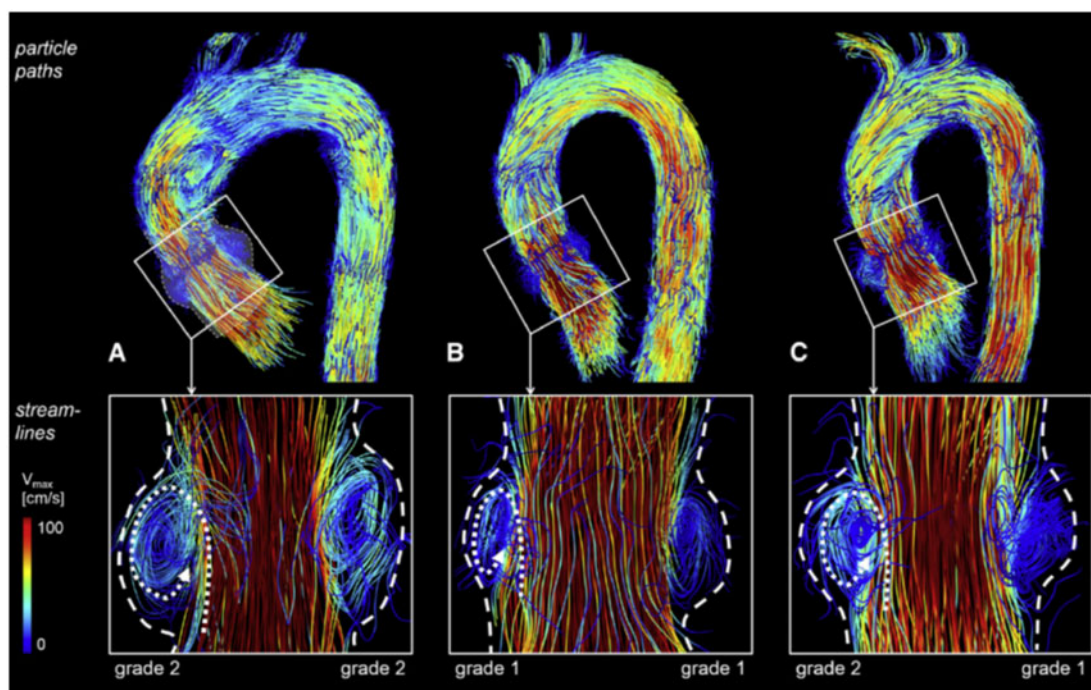


Figure 2 Vortices generated within the sinuses of Valsalva using time-resolved three-dimensional magnetic resonance phase contrast imaging. Top row: particle paths at peak systole delineate haemodynamics in the thoracic aorta of 60-year-old patient with sinus prosthesis (A), of a healthy 53-year-old age-matched volunteer (B), and a 30-year-old young volunteer (C). Bottom row: sinus vortices in the right and left coronary sinus as visualized by instantaneous streamlines. Dashed lines demonstrating sinus borders and dotted lines delineating vortex direction. These vortices may play a role in reducing the risk of thrombus formation on the aortic side of the leaflets in native and surgical aortic valve replacements. V_{max} , peak velocity. Reproduced with permission.³⁰

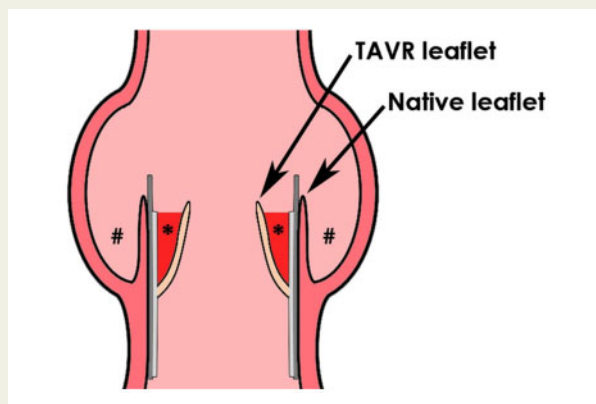


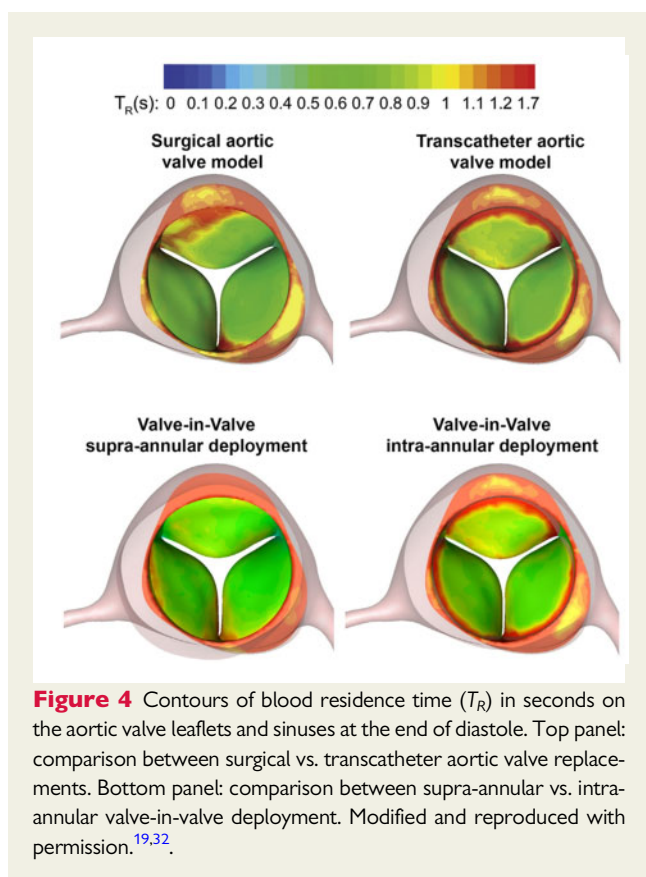
Figure 3 Transcatheter aortic valves divide the native aortic sinus of Valsalva into two new spaces: a smaller native sinus between the aortic wall and the native aortic valve leaflet (#) and a new 'neo-sinus' bounded by the native aortic valve leaflet and the transcatheter aortic valve leaflet (*) where thrombus is usually observed. TAVR, transcatheter aortic valve replacement.

also varies according to the TAVR type, position in relation to the aortic annulus, and the degree of apposition to the native valve (which is further influenced by local native valve characteristics such

as calcification, as well as the implanted TAVR size). This was demonstrated by Midha *et al.*¹³ who showed that supra-annular TAVR deployment resulted in nearly a seven-fold reduction in the size of the stagnation zone within the neo-sinus and a shorter blood residence time. However, a supra-annular TAVR deployment has to be balanced against the risk of coronary artery occlusion.

Valve-in-valve procedure and patient–prosthesis mismatch

With valve-in-valve procedures, these neo-sinuses are confined by the degenerated surgical bioprosthesis frame that circumferentially surrounds the TAVR leaflets. *In vitro* modelling also showed increased blood stasis on TAVR leaflets following valve-in-valve procedures.³² Similar to previous studies evaluating THV thrombosis for TAVR implanted in native aortic valves, a supra-annular TAVR deployment in valve-in-valve procedures had significantly shorter blood residence time within the neo-sinuses compared with an intra-annular position (Figure 4, bottom panel). Clinical studies have since corroborated the suggestion that valve-in-valve procedures may potentially increase THV thrombotic risks.^{22,33} In the multicentre registry by Del Trigo *et al.*²² including 1521 TAVR patients, there were 68 cases of THV thrombosis defined by echocardiography. The authors found that a higher body mass index (BMI), smaller TAVR size, and valve-in-valve procedures were independently



associated with valve thrombosis on multivariable analysis. Similarly, Jose *et al.*³³ also identified valve-in-valve procedures (in addition to increased BMI, absence of anticoagulation, and use of balloon-expandable valve) as independent determinants of THV thrombosis.

Valve-in-valve procedures are also more likely to result in patient–prosthesis mismatch with a smaller indexed effective orifice area. Moreover, Abdel-Wahab *et al.*²⁰ also demonstrated that a smaller TAVR size in relation to body surface area was associated with higher incidence of THV thrombosis. Similarly, the recently published FRANCE TAVR registry suggested that a higher BMI, previous TAVR (i.e. valve-in-valve), smaller prosthesis size (≤ 23 mm), moderate-to-severe chronic renal failure, and absence of anticoagulation were independently associated with SVD defined as an increase in mean gradient ≥ 10 mmHg or new mean gradient ≥ 20 mmHg (a surrogate for possible THV thrombosis).³⁴

It is interesting to note that a larger body size with a relatively smaller prosthetic aortic valve size are conditions with increased severe patient–prosthesis mismatch.³⁵ Although mild or even moderate patient–prosthesis mismatch may not impact on clinical outcomes, severe mismatch may result in haemodynamic flow perturbation, which could accelerate either thrombus or pannus formation. The multicentre registry by Yanagisawa *et al.*²⁶ including 485 TAVR patients also concluded that severe patient–prosthesis mismatch was associated with higher likelihood of early THV thrombosis (6.7% vs. 0.9%, $P = 0.02$). Clinically, severe patient–prosthesis

mismatch is associated with adverse outcomes and patients more likely to experience SVD early (2–3 years) after implantation.³⁶ Flameng *et al.*³⁶ showed that patients with severe patient–prosthesis mismatch who develop SVD were more likely to present clinically as valve stenosis on follow-up. However, the proportion of these patients with SVD due to valve thrombosis is unknown.

Cardiac output

In their *in vitro* study on fluid mechanics and neo-sinuses in TAVR, Midha *et al.*¹³ found that reduced cardiac output resulted in larger stagnation zone and increased blood residence time, theoretically increasing the risk of THV thrombosis. This hypothesis was supported by two clinical studies showing reduced cardiac output as an independent predictor for THV thrombosis.^{21,26} Chakravarty *et al.*²¹ included patients from the Assessment of Transcatheter and Surgical Aortic Bioprosthetic Valve Thrombosis and its Treatment with Anticoagulation (RESOLVE) and Subclinical Aortic Valve Bioprosthetic Thrombosis Assessed with Four-Dimensional Computed Tomography (SAVORY) registries and showed that reduced left ventricular ejection fraction (LVEF) was independently associated with THV thrombosis. Similarly, Yanagisawa *et al.*²⁶ reported that patients with low-flow, low-gradient severe aortic stenosis had higher incidence of early leaflet thrombosis on multivariable analysis (odds ratio 2.71, 95% confidence interval 1.11–6.62; $P = 0.03$). However, other studies failed to identify cardiac output as a predictor of THV thrombosis.^{23,37,38}

Balloon-expandable vs. self-expanding valves

Conflicting results exist on the thrombotic risks of various balloon-expandable vs. self-expanding TAVR in head-to-head comparisons.^{26,33,37,39,40} In the Repositionable Percutaneous Replacement of Stenotic Aortic Valve Through Implantation of Lotus Valve System–Randomized Clinical Evaluation (REPRISE III) trial that randomized 912 participants into the self-expanding CoreValve™ vs. the balloon-expandable Lotus™ valve, the self-expanding valve had better forward flow dynamics, effective orifice area, and mean gradient due to its supra-annular design and positioning.³⁹ Transcatheter heart valve thrombosis was identified in 16 cases during routine echocardiographic follow-up, all of which occurred with the balloon-expandable valve (3.0% vs. 0%, $P < 0.01$). However, there was no difference in all stroke rates (8.4% in balloon-expandable vs. 11.4% in self-expanding valves, $P = 0.75$). Similarly, Jose *et al.*³³ reported a higher incidence of THV in balloon-expandable valves compared with self-expanding valves. Conversely, other studies did not observe any differences in THV thrombosis rates between the balloon-expandable vs. self-expanding valves.^{26,37,40} Interestingly, Yanagisawa *et al.*²⁶ found that the Edwards Sapien 3™ had a significantly higher incidence of early leaflet thrombosis compared with the Sapien XT™ (17.9% vs. 4.1%, $P < 0.001$). On further inspection, the patients with Sapien 3™ valve thrombosis had their TAVR implanted in a lower position compared with those without thrombosis. This was consistent with the aforementioned *in vitro* study showing that a lower TAVR implantation (i.e. intra-annular deployment) results in larger neo-sinuses with increased stagnation zone and longer blood residence time independent of valve type.¹³

Transcatheter aortic valve replacement vs. surgical aortic valve replacement

The Placement of Aortic Transcatheter Valves (PARTNER) 3 trial randomized severe aortic stenosis patients of low surgical risk to undergo either TAVR with Sapien 3 or SAVR.² The primary objective of the PARTNER 3 computed tomography (CT) substudy was to evaluate HALT and reduced leaflet motion (RLM) in a subset of patients from the larger randomized trial.⁴¹ Four-dimensional MDCT was performed at 30 days and 1 year, and examinations were all interpreted in a CT core laboratory. Of the 408 patients, 346 and 312 patients had evaluable CT examinations at 30 days and 1 year, respectively. At 30 days, the incidence of HALT was significantly higher for TAVR compared with SAVR [22 of 165 patients (13.3%) vs. 6 of 119 patients (5%), $P=0.03$; relative risk ratio 2.64, 95% confidence interval 1.11–6.32]. However, the incidence of HALT was no longer different at 1 year [42 of 153 patients (27.5%) vs. 22 of 109 patients (20.2%), $P=0.19$; relative risk ratio 1.38, 95% confidence interval 0.87–2.18].

In the Evolut Low-Risk substudy that utilized the self-expanding TAVR, Blanke *et al.*⁴² reported similar rates of THV thrombosis between TAVR and SAVR at both 30 days and 1 year. At 30 days, the frequency of HALT was 17.3% in TAVR patients vs. 16.5% in SAVR patients and the frequency of RLM was 14.6% in TAVR patients vs. 14.3% in SAVR patients. At 1 year, the frequency of HALT was 30.9% in TAVR patients and 28.4% in SAVR patients (28.4%) and the frequency of RLM was 31% in TAVR patients vs. 27% in SAVR patients.

Diagnosis

Tables 1 and 2 summarize all recent publications on THV thrombosis by transthoracic echocardiography and 4D MDCT, respectively. The incidence of THV thrombosis ranged from as low as 0.6% and up to 40% depending on the imaging modality utilized and diagnostic criteria employed.^{20–24,26–28,33,37–40,43–48}

Echocardiography

By virtue of its ubiquitous availability and ease of use, echocardiography is the first imaging modality of choice. The main advantage is the quantification of valvular dysfunction based on the haemodynamic severity of obstruction. However, previously published mean gradient/peak velocity cut-off values to define bioprosthetic valve dysfunction due to THV thrombosis were highly variable (see Table 1). Despite the variable definitions, THV thrombosis by echocardiography is most frequently defined as a mean gradient of ≥ 20 mmHg, mean gradient increase by $>50\%$ compared with baseline, or effective orifice area <1.2 cm². Some studies have also incorporated other morphological abnormalities detected on echocardiography or 4D MDCT such as immobile/restricted leaflet motion, thrombotic mass or response to anticoagulation therapy.^{33,39,44,47} However, echocardiographic evaluation of increased leaflet thickness, RLM or identification of mobile mass suggestive of thrombus are frequently more challenging due to acoustic shadowing and ring-down artefacts arising from the valve struts. Overall, the published incidence of THV thrombosis detected by echocardiography ranged from 0.6% to 7.6% (Table 1).

Cardiac multidetector computed tomography

Due to its superior spatial resolution, 4D MDCT imaging is often used to detect THV thrombosis. The first case report of THV thrombosis detected by MDCT was published in 2013.⁴⁶ Since then, the reported incidence of THV thrombosis by 4D MDCT ranged from 4% to 40% (Table 2).^{27,45} The anatomical diagnostic hallmark of THV thrombosis is leaflet thickening that is meniscoid in configuration and extends from the base to the tip of the leaflet, usually recognized as HALT on 4D MDCT (Figure 5). Hypoattenuated leaflet thickening can functionally lead to RLM, usually without severely elevated transvalvular gradients on echocardiography. The assessment of RLM is based on maximal leaflet opening in the systolic phase, thereby further stratifying patients into normal, mild ($<50\%$ RLM), moderate (50–70% RLM), severe ($>70\%$ RLM), or immobile (100% RLM) leaflets.¹² Finally, HALT with \geq moderate RLM is defined as hypoattenuation affecting motion (HAM).

One important methodological issue with MDCT is the variability in temporal resolution due to different gantry rotation times of different CT scanners. Theoretically, a lower temporal resolution may reduce the diagnostic accuracy of RLM as maximally reduced leaflet excursion may not be imaged within the acquired dataset. Second, the need for contrast administration may also limit its use. Finally, due to the need for time-resolved imaging to visualize leaflet motion, 4D MDCT scanning protocol usually demands retrospective electrocardiogram gating without pulse modulation and occasionally at higher energy levels (140 kV compared to 'standard' 120 kV).¹² Therefore, radiation exposure should be minimized by limiting scan range to only the aortic valve.

Echocardiography vs. cardiac multidetector computed tomography

Given the differences in echocardiographic vs. 4D MDCT definitions for THV thrombosis, the timing of imaging post-procedure, and the different patient populations studied, there is a substantial variability in the overall reported incidence of THV thrombosis or valve leaflet dysfunction. Often, the anatomical diagnosis of THV thrombosis by 4D MDCT does not equate to haemodynamic obstruction on echocardiography. For example, in the largest 4D MDCT series to date that included 890 patients from the RESOLVE and SAVORY registries, patients with at least moderate RLM ($n=106$) had significantly higher mean aortic gradient (13.8 ± 10.0 vs. 10.4 ± 6.3 mmHg, $P=0.0004$).²¹ However, only 16% of patients with \geq moderate RLM had moderately elevated mean aortic gradient >20 mmHg and only 4% of patients had severely elevated mean aortic gradient >40 mmHg. This means that 96% of patients with \geq moderate RLM did not have haemodynamically severe valvular obstruction, and 84% had normal transvalvular aortic gradient on echocardiography. This was consistent with several other studies showing that, although patients with THV thrombosis on 4D MDCT had statistically higher mean transvalvular gradients compared with controls, the mean gradients are often still within normal ranges.^{21,23,26,38} In the latest PARTNER 3 CT substudy, there was a non-significant trend towards higher mean aortic gradients in all TAVR and SAVR patients with HALT vs. those without HALT (13.2 ± 0.81 vs. 11.7 ± 0.24 mmHg, $P=0.08$).⁴¹ Patients with RLM had significantly higher mean aortic

Table 1 Transcatheter heart valve thrombosis by echocardiography

Author (year)	Number of patients	Definition	Valve type	Number of THV thrombosis (prevalence)	Time to diagnosis	Mean gradient (mmHg)	Clinical sequelae
Latib et al. ⁴⁴ (2015)	4266	<p>THV leaflet dysfunction:</p> <ul style="list-style-type: none"> • Mean gradient ≥ 20 mmHg or AVA < 1.2 cm² or peak velocity ≥ 3 m/s; or • New moderate or greater aortic regurgitation <p>THV thrombosis:</p> <ul style="list-style-type: none"> • THV leaflet dysfunction secondary to thrombosis based on response to anticoagulation therapy, imaging modality (echocardiography or MDCT), or histopathology findings; or mobile mass suspicious of thrombus, irrespective of dysfunction, and in the absence of infection <p>Mean gradient ≥ 10 mmHg</p>	<p>Edwards Sapien/ Sapien XT (76.9%) Medtronic CoreValve (23.1%)</p>	26 (0.6%)	Median 181 days (IQR 45–313)	40.5 \pm 14.0	<ul style="list-style-type: none"> • 65% worsening dyspnoea • No stroke <p>Did not compare to patients without thrombosis</p>
Del Trigo et al. ²² (2016)	1521	Mean gradient ≥ 10 mmHg	<ul style="list-style-type: none"> • Edwards Sapien/ Sapien XT (48.5%) • Medtronic CoreValve (49.7%) • Others (1.8%) 	68 (4.5%)	—	26.1 \pm 11.0	<p>Compared with patients without thrombosis:</p> <ul style="list-style-type: none"> • Similar total mortality, cardiovascular mortality, and stroke • 70% worsening dyspnoea • 0% stroke <p>Did not compare to patients without thrombosis</p>
Franzone et al. ⁴³ (2018)	1396	Mean gradient ≥ 20 mmHg, or mean gradient increase by 50%, or recent or new onset heart failure	<ul style="list-style-type: none"> • Edwards Sapien 3/Sapien XT (48.6%) • Medtronic CoreValve/Evolut R (39.3%) • Others (12.1%) 	10 (0.71%)	Median 379 days (IQR 35–524)	36.4 \pm 8.3	<p>Did not compare to patients without thrombosis</p>
Jose et al. ³³ (2017)	642	Mean gradient > 20 mmHg, or AVA < 1.2 cm ² , or $>$ mild new aortic regurgitation secondary to thrombosis diagnosed by response to anticoagulation or 'typical' echocardiographic or MDCT findings, or mobile mass suspicious of thrombus	<ul style="list-style-type: none"> • Edwards Sapien 3/Sapien XT (72.2%) • Medtronic CoreValve/Evolut R (16.7%) • Others (11.1%) <ul style="list-style-type: none"> • 'Typical' echo findings include immobile or restricted leaflets, thrombotic mass, or thickened leaflets <p>'Typical' CT findings is HALT</p>	18 (2.8%)	Median 181 days (IQR 25–297)	34 \pm 14	<ul style="list-style-type: none"> • 38.9% worsening dyspnoea • 5.5% stroke <p>Did not compare to patients without thrombosis</p>

Continued

Table 1 Continued

Author (year)	Number of patients	Definition	Valve type	Number of THV thrombosis (prevalence)	Time to diagnosis	Mean gradient (mmHg)	Clinical sequelae
Vollema et al. ³⁸ (2017)	434	Mean gradient ≥ 20 mmHg and AVA ≤ 1.1 cm ²	<ul style="list-style-type: none"> Edwards Sapien/Sapien 3/Sapien XT (90.8%) Medtronic CoreValve (9.2%) 	2 (3%)	—	—	See Table 2
Spartera et al. ⁴⁷ (2018)	621	Mean gradient ≥ 20 mmHg and peak velocity ≥ 3 m/s, PLUS response to anticoagulation therapy, and/or HALT detected on MDCT	<ul style="list-style-type: none"> Edwards Sapien/Sapien 3/Sapien XT (48.1%) Medtronic CoreValve/Evolut R (35.3%) Others (16.6%) 	13 (2.1%)	179.5 \pm 252.9 days	36.2 \pm 16.5	—
Abdel-Wahab et al. ²⁰ (2018)	300 valve-in-valve	<ul style="list-style-type: none"> New valve leaflet dysfunction (mean gradient > 20 mmHg or increase by $> 50\%$) that responds to anticoagulation Imaging evidence of thrombosis on echo or HALT on MDCT 	<ul style="list-style-type: none"> Edwards Sapien/Sapien XT (48.7%) Medtronic CoreValve/Evolut R (50.3%) Others (1%) 	23 (7.6%)	—	—	<ul style="list-style-type: none"> 1 stroke
Reardon et al. ³⁹ (2019)	912	2 criteria = definite valve thrombosis1 criterion = probable valve thrombosis	<ul style="list-style-type: none"> Medtronic CoreValve (33.4%) Lotus (66.6%) 	16 (1.8%)	—	—	<ul style="list-style-type: none"> No death No stroke
Overtchouk et al. ³⁴ (2019)	2555	Mean gradient ≥ 20 mmHg and peak velocity ≥ 3 m/s, PLUS response to anticoagulation therapy, and/or HALT detected on MDCT Increase in mean gradient by ≥ 10 mmHg, or new mean gradient > 20 mmHg	<ul style="list-style-type: none"> Ballon-expandable (64.7%) Self-expanding (35.3%) 	140 (5.5%)	Median 12 months (IQR 11–15 months)	—	—

AVA, aortic valve area; CT, computed tomography; HALT, hypoattenuated leaflet thickening; IQR, interquartile range; MDCT, multidetector computed tomography; THV, transcatheter heart valve.

Table 2 Transcatheter heart valve thrombosis by multidetector computed tomography

Author (year)	Number of patients	Definition	Valve type	Number of THV thrombosis (prevalence)	Time to diagnosis	Mean gradient (mmHg)	Clinical sequelae
Makkar et al. ²⁷ (2015)	55	At least moderate ($\geq 50\%$) RLM	Self-expanding (100%)	22 (40%)	Median 32 days (IQR 28–37)	10.5 \pm 4.3 mmHg	Compared with patients with $< 50\%$ RLM: Similar mortality Similar stroke Compared with patients with $< 50\%$ RLM: Increased risk of TIA
Leetmaa et al. ⁴⁵ (2015)	140	HALT	Edwards Sapien/Sapien 3/Sapien XT (-) Medtronic CoreValve/Evolut R (-) Others (-)	17 (13%)	228 \pm 459 days	8.4 \pm 2.9 mmHg	No stroke 1 heart failure No stroke
Pache et al. ⁴⁶ (2016)	156	HALT	Edwards Sapien 3 (100%)	16 (10.3%)	Median 5 days (IQR 5–6)	14.9 \pm 5.3 mmHg	18% heart failure Compared with patients without HALT: Similar mortality rates Similar stroke rates
Hansson et al. ²³ (2016)	405	HALT	Edwards Sapien 3/Sapien XT (100%)	28 (6.9%)	Median 43 days (IQR 28–57)	10 \pm 7 mmHg	Compared with patients with $< 50\%$ RLM: Similar mortality Higher rates of TIA
Chakravarty et al. ²¹ (2017)	890	At least moderately ($\geq 50\%$) RLM	Edwards Sapien/Sapien 3/Sapien XT (-) Medtronic CoreValve/Evolut R (-) Others (-)	106 (11.9%)	Median 83 days (IQR 33–281)	13.8 \pm 10.0 mmHg	Compared with patients with $< 50\%$ RLM: Similar mortality Higher rates of TIA
Ruile et al. ³⁷ (2018)	629	HALT	Edwards Sapien 3/Sapien XT (85.5%) Medtronic CoreValve/Evolut R (14.5%)	93 (14.8%)	Median 5 days (IQR 5–6)	—	—
Sondergaard et al. ²⁴ (2017)	84	HALT with or without HAM (i.e. at least $\geq 50\%$ RLM)	Edwards Sapien 3 (-) Medtronic CoreValve/Evolut R (-) Others (-)	HALT: 32 (38.1%) HAM: 7 (20.2%)	159 \pm 177 days	HALT: 7.0 \pm 3.2 mmHg at time point 1 7.1 \pm 4.5 mmHg at time point 2 HAM: 7.2 \pm 2.4 mmHg at time point 1 5.7 \pm 3.3 mmHg at time point 2	2 patients with HAM had TIA/stroke

Continued

Table 2 Continued

Author (year)	Number of patients	Definition	Valve type	Number of THV thrombosis (prevalence)	Time to diagnosis	Mean gradient (mmHg)	Clinical sequelae
Vollema <i>et al.</i> ³⁸ (2017)	128	HALT with or without HAM	Edwards Sapien/Sapien XT (100%)	16 (12.5%)	Median 35 days (IQR 19–210)	12.4 ± 8.0 mmHg	No TIA/stroke
Yanagisawa <i>et al.</i> ²⁸ (2017)	70	HALT	Edwards Sapien XT (100%)	10 (14.3%)	—	8.3 ± 0.8 mmHg	Compared with patients without HALT: Similar mortality Similar TIA rates
Ruile <i>et al.</i> ⁴⁰ (2018)	754	HALT	Edwards Sapien 3/Sapien XT (80.1%) Medtronic CoreValve/Evolut R (14.5%) Others (5.4%)	120 (15.9%)	Median 5 days (IQR 4–6)	11.3 ± 4.9 mmHg	Compared with patients without HALT: Similar all-cause mortality Similar CVA/TIA
Yanagisawa <i>et al.</i> ²⁶ (2019)	485	HALT	Edwards Sapien 3/Sapien XT (89.9%) Medtronic CoreValve/Evolut R (10.1)	Early HALT: 45 (9.3%) Late HALT: 8 (12.3%)	Median 3 days >30 days	12.9 ± 5.6 mmHg	Compared with patients without HALT: Similar all-cause mortality Similar rehospitalization for heart failure
De Backer <i>et al.</i> ⁴⁸ (2020)	246	At least moderately (>50%) RLM (primary endpoint) HALT (secondary endpoint)	Balloon-expandable (45.9%) Self-expanding (54.1%)	RLM: 2 (2.1%) ^a 11 (10.9%) ^b HALT: 12 (12.4%) ^a 33 (32.4%) ^b	90 ± 15 days	11 ± 5 mmHg	No patients with >50% RLM had stroke or died

CVA, cerebrovascular accident; HALT, hypoattenuated leaflet thickening; HAM, hypoattenuation affecting motion; IQR, interquartile range; RLM, reduced leaflet motion; THV, transcatheter heart valve; TIA, transient ischaemic attack.

^aExperimental treatment group on rivaroxaban and aspirin for 3 months.

^bControl group on aspirin and clopidogrel for 3 months.

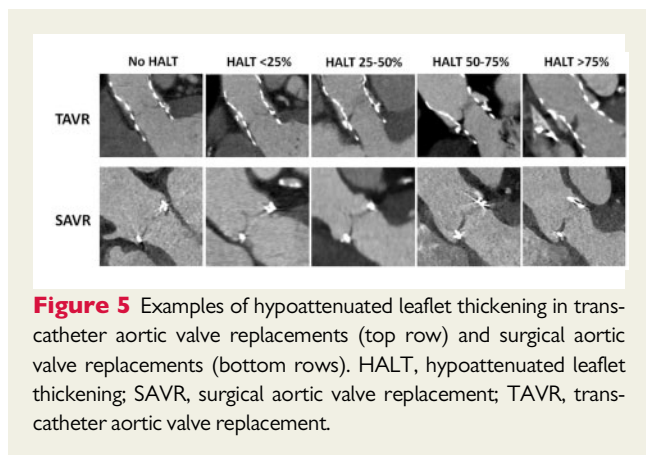


Figure 5 Examples of hypoattenuated leaflet thickening in transcatheter aortic valve replacements (top row) and surgical aortic valve replacements (bottom rows). HALT, hypoattenuated leaflet thickening; SAVR, surgical aortic valve replacement; TAVR, transcatheter aortic valve replacement.

gradient than those without RLM (13.3 ± 0.83 vs. 11.4 ± 0.23 mmHg, $P=0.04$). However, the degree of increased mean aortic gradient was not associated with clinically significant consequences. Other published MDCT studies showed no statistical differences in transvalvular gradients on echocardiography between the two patient groups.^{27,28,40,48}

Clinical consequences

Clinical consequences of THV thrombosis can be divided into haemodynamic effects of valvular obstruction, thromboembolic complications, and mortality. Due to the small number of patients with clinical events, no studies to date have systematically reported all these clinical sequelae. Haemodynamic effects of valvular obstruction often present clinically as heart failure symptoms such as exertional dyspnoea. The reported incidence of dyspnoea is higher in echocardiographic studies compared with 4D MDCT studies. As previously alluded to when comparing echocardiography vs. 4D MDCT, majority of patients diagnosed with THV thrombosis on 4D MDCT does not have significant haemodynamic obstruction on echocardiography and therefore absent heart failure symptoms (Table 2). Only one 4D MDCT study reported an incidence of heart failure as 18% (5 patients out of 28 cases of THV thrombosis).²³ Of these five patients, three had preserved LVEF, effective orifice area <1.0 cm², and mean gradient >20 mmHg but <40 mmHg (raising the possibility of paradoxical low-flow low-gradient as cause of dyspnoea rather than severe valvular obstruction). The remaining two patients had severely reduced LVEF (but no baseline echocardiographic data available), again raising the possibility that the symptoms were due to pre-existing heart failure with reduced LVEF instead of severe valvular obstruction from THV thrombosis.²³ To date, no other 4D MDCT studies have reported their overall incidence of heart failure associated with HALT or RLM.

In contrast, echocardiographic studies identify patients with already significant obstruction secondary to THV thrombosis. Therefore, patients are more likely to be symptomatic at presentation. Currently, three echocardiographic studies identified a total of 54 cases of THV thrombosis in 6304 TAVR patients (a pooled incidence of 0.9%), with reported incidence of worsening dyspnoea ranged from 38.9% to 70% in these patients.^{33,43,44} Finally, only one

published study has compared clinical symptoms between patients with or without THV thrombosis and reported no significant difference in the overall incidence of heart failure.²⁶

Thromboembolism, specifically transient ischaemic attack (TIA) or cerebrovascular accident (CVA), is the most likely reported clinical complication of THV thrombosis (Tables 1 and 2). The overall incidence of thromboembolism is low and the largest reported absolute number of TIA/CVA was 8 in 106 patients with THV thrombosis on 4D MDCT, equating to an overall incidence of 7.5%.²¹ To date, only 1 study has reported a significant difference in the incidence of thromboembolism in patients with and without THV thrombosis.²¹ From the RESOLVE and SAVORY registries where TIA and CVA were blindly adjudicated by a stroke neurologist, Chakravarty *et al.*²¹ reported a higher incidence of non-procedural TIA incidence (5% vs. 1%, $P=0.002$) but no difference in ischaemic stroke rates (4% vs. 2%, $P=0.14$) in patients with THV thrombosis. All other published studies showed no difference in TIA/CVA incidence.^{22,23,26,27} In the PARTNER 3 CT substudy, patients with HALT had 8.6% combined risk of death, CVA, TIA and thromboembolic events compared with 2.9% in patients without HALT ($P=0.11$).⁴¹ Long-term implications on TAVR longevity is unknown, and further follow-up is planned at 10 years.⁴¹ Similar results were also noted in the recently published Global Study Comparing a Rivaroxaban-Based Antithrombotic Strategy to an Antiplatelet-Based Strategy After Transcatheter Aortic Valve Replacement to Optimize Clinical Outcomes (GALILEO-4D) trial substudy where no patients with $\geq 50\%$ RLM had thromboembolic complications at 90 days.⁴⁸

Finally, all studies to date have reported a similar rate of all-cause mortality between patients with and without THV thrombosis.^{21–23,26–28,40,48} In the PARTNER 3 CT substudy, no patients with HALT died within the reported study period.⁴¹

Based on current publications, the incidence of clinical complications associated with subclinical THV thrombosis is very low. However, all these studies are limited by a small number of patients with THV thrombosis with limited follow-up duration. With the expected growth and utilization of TAVR for intermediate- and low-risk patient groups, future research into clinical implications of THV thrombosis on long-term valve integrity and patient morbidity/mortality is needed.

Treatment

Antithrombotic therapy post-bioprosthetic valve replacement is a balance between the risks of thromboembolism vs. bleeding. Following TAVR, the American Heart Association/American College of Cardiology (AHA/ACC) guidelines, the ESC/EACTS guidelines, and the latest TAVR expert consensus statement all recommend dual antiplatelet therapy (DAPT) for 3–6 months post-procedure (Table 3).^{49–51} For patients with high bleeding risks, the ESC/EACTS guidelines also suggested single antiplatelet therapy (SAPT) may be more appropriate (Class IIb, level of evidence C). This was based on three small randomized controlled trials including 421 TAVR patients comparing DAPT vs. SAPT. These trials suggested that TAVR could be safely performed using SAPT without increased procedural morbidity and mortality, and at 6 months follow-up.^{52–54} Subsequent meta-analyses of these three trials with other observational studies

suggested that DAPT after TAVR was associated with higher rates of bleeding, but there were no differences in the incidences of death, ischaemic events, myocardial infarction, or strokes.^{55,56}

It is possible that TAVR patients may be at higher risk for valve thrombosis compared with SAVR patients, and the routine clinical/research use of MDCT following TAVR has demonstrated a significant proportion of patients develop subclinical THV thrombosis despite DAPT. Often, treating THV thrombosis is based on the clinical judgement of variables such as acuity of patient presentation and severity of symptoms secondary to valve leaflet dysfunction. Clearly, patients presenting with heart failure and mean transvalvular gradient of 60 mmHg should be treated more urgently than those with asymptomatic HALT but normal mean gradients. As open thoracotomy for SAVR was initially deemed inappropriate for these high-risk TAVR patients in the first place and therefore redo-SAVR for THV thrombosis is unlikely to happen, there are two potential treatment strategies for THV thrombosis: conservative surveillance vs. anticoagulation.

Conservative surveillance

One of the advantages of bioprosthetic valve prosthesis is avoiding anticoagulation associated with mechanical prosthesis. Currently, many TAVR patients have an increased risk of bleeding due to advanced age or multiple comorbidities. Therefore, conservative surveillance of THV thrombosis may be more appropriate for TAVR patients with absent clinical symptoms or haemodynamically significant valve leaflet dysfunction. Sondergaard *et al.*²⁴ was first to provide some insights into the natural history of THV thrombosis where 84 patients (61 TAVR and 23 SAVR) from the SAVORY registry underwent two protocol-driven 4D MDCT examinations with unchanged antithrombotic medication between the scans. Baseline and follow-up 4D MDCT were performed at a mean of 140 ± 152 and 298 ± 141 days post-valve implantation, respectively, and all scans were evaluated at core laboratories blinded to baseline variables, antithrombotic medication, clinical events, and outcomes of previous CT scans. At baseline, 38.1% of patients had HALT and 20.2% had HAM. At follow-up, 15.5% of patients had progression of the abnormality, 10.7% showed regression, and 73.8% showed no change. All

patients with THV thrombosis were asymptomatic throughout the study duration. On multiple logistic regression, anticoagulation with either vitamin K antagonist (VKA) or non-vitamin K oral anticoagulants (NOAC) was significantly associated with non-progression. No patients on NOAC had progression of THV thrombosis. In the PARTNER 3 CT substudy, HALT spontaneously resolved in 56% of all patients (i.e. both TAVR and SAVR) at 1 year. Vice versa, 21% of all TAVR and SAVR patients developed new HALT at 1 year.⁴¹ These observations suggest that the time course of THV thrombosis is highly variable.

Anticoagulation

Currently, oral anticoagulation following TAVR is only recommended when there are other indications for anticoagulation such as atrial fibrillation.⁴⁹ In patients with surgical bioprosthetic valve thrombosis, the ESC/EACTS guidelines recommend anticoagulation with VKA and/or unfractionated heparin (UFH) as first-line therapy (Class I, level of evidence C).⁴⁹ However, there are no guideline treatment recommendations for subclinical THV thrombosis in TAVR patients. It is increasingly recognized that anticoagulation with either VKA or NOAC, not DAPT, reduces the incidence and promotes the regression of THV thrombosis.^{21–23,27,33,34,39,48} For example, of the 58 patients who were diagnosed with THV thrombosis from the RESOLVE and SAVORY registries, all 36 patients who were anticoagulated for 3 months (24 with VKA and 12 with NOAC) had restoration of normal leaflet motion on follow-up MDCT.²¹ In the remaining 22 patients who were not anticoagulated, 20 patients had either persistent or progressive leaflet abnormality.²¹ Other smaller series also reported high proportion of patients with the resolution of THV thrombosis with anticoagulation.^{23,27,33,39}

In the recently published GALILEO trial that was specifically designed to evaluate the clinical implications of THV thrombosis, TAVR patients were randomized to experimental low-dose rivaroxaban at 10 mg daily plus aspirin 75–100 mg daily for 3 months, followed by rivaroxaban 10 mg daily monotherapy vs. control aspirin 75–100 mg daily plus clopidogrel 75 mg daily for 3 months followed by aspirin 75–100 mg daily monotherapy.⁵⁷ No patient had an underlying baseline indication for chronic anticoagulation. The trial was

Table 3 Current guidelines for antithrombotic surgery after surgical aortic valve replacement and transcatheter aortic valve implantation

ESC/EACTS ⁴⁹	Class ^a	Level ^b	AHA/ACC ⁵⁰	Class ^a	Level ^b
Bioprosthetic SAVR					
Anticoagulation in first 3 months	IIb	C	Anticoagulation with INR goal 2.5 in first 3 months	IIb	B
Aspirin for first 3 months only	IIa	C	Aspirin long-term	IIa	B
TAVR					
DAPT for first 3–6 months followed by SAPT	IIa	C	Clopidogrel for first 6 months with lifelong aspirin	IIb	C
SAPT in case of high bleeding risk	IIb	C			

ACC, American College of Cardiology; AHA, American Heart Association; DAPT, dual antiplatelet therapy; EACTS, European Association for Cardio-Thoracic Surgery; ESC, European Society of Cardiology; INR, international normalized ratio; SAPT, single antiplatelet therapy; SAVR, surgical aortic valve replacement; TAVR, transcatheter aortic valve replacement.

^aClass of recommendation.

^bLevel of evidence.

terminated prematurely in November 2018 after interim analysis due to safety concerns with anticoagulation. At the time of trial termination, only 42% of the total planned 440 primary efficacy events (defined as combined higher death or first thromboembolic event) had occurred. Based on the intention-to-treat analysis, patients randomized to low-dose rivaroxaban had significantly higher risk of death or first thromboembolic event (hazard ratio 1.35, 95% confidence interval 1.01–1.81; $P=0.04$) and higher all-cause mortality (hazard ratio 1.69, 95% confidence interval 1.13–2.53). However, the higher all-cause mortality was primarily driven by non-cardiovascular causes. Patients were also more likely to have bleeding complications, and there was a trend towards a significant difference in the primary safety outcome (defined as the composite of life-threatening, disabling, or major bleeding according to the Valve Academic Research Consortium) (hazard ratio with rivaroxaban 1.50, 95% confidence interval 0.95–2.37; $P=0.08$).⁵⁷ As the study was terminated early with less than half of the projected primary efficacy events, it is difficult to assess the overall risks vs. benefits ratio especially in the context of the GALILEO-4D substudy.

In the GALILEO-4D substudy, 231 TAVR patients underwent 4D MDCT and echocardiograms at 3 months with the primary endpoint of \geq grade 3 (i.e. $>50\%$) RLM.⁴⁸ Anticoagulation with rivaroxaban with aspirin was associated with a lower incidence of RLM (between-group difference -8.8% , 95% confidence interval -16.5% to -1.9% ; $P=0.01$) and HALT (between-group difference -20.0% , 95% confidence interval -30.9% to -8.5%) compared with DAPT. Cross-sectionally, there were no differences in mean transvalvular gradients between both treatment arms at 3 months, between patients with or without \geq grade 2 RLM, between patients with or without \geq grade 3 RLM, or between patients with or without HALT.⁴⁸ However, longitudinally (when comparing baseline and follow-up echocardiographic examinations) patients with RLM or HALT were more likely to have ≥ 5 or ≥ 10 mmHg increase in mean gradient at follow-up. Overall, the numbers of patients with moderate haemodynamic SVD or clinical thromboembolic events were too small for meaningful interpretation.

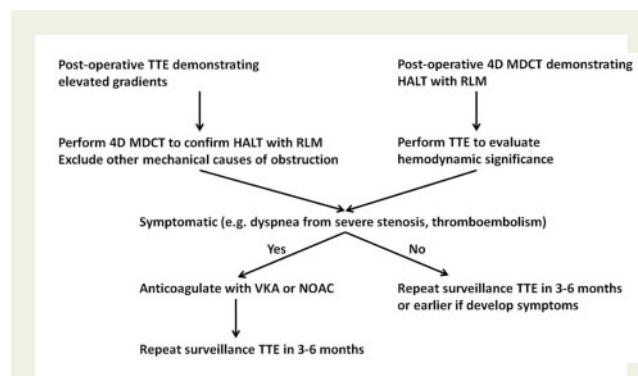
Although anticoagulation will result in the resolution of THV thrombosis, the optimal duration of anticoagulation is unknown. When anticoagulation was ceased in patients from the RESOLVE and SAVORY registries, THV thrombosis recurred in 50% of patients after a mean time of 164 ± 109 days.²¹ Yanagisawa et al.²⁶ also reported that the incidences of late THV thrombosis at 6 months, 1 year, 2 years, and 3 years were 7.1%, 11.3%, 12.7%, and 16.9%, respectively. Finally, the median time to THV thrombosis ranged from 5 to 379 days (Tables 1 and 2).^{37,43,46} These data suggest that a longer period of antithrombotic/anticoagulation therapy post-TAVR may be warranted, and it is unclear if the eventual 'protective' re-endothelialization of the bioprosthetic valve is enough to overcome the permanent 'prothrombotic' effects of altered flow (i.e. neosinuses, reduced cardiac output) across the valve. On the other hand, routine indiscriminate use of anticoagulation seems inappropriate in these TAVR patients with high bleeding risks as demonstrated in the GALILEO trial.⁵⁷ Therefore, future studies are clearly required to determine the optimal antithrombotic regimen after TAVR in terms of specific agent, dose, and duration of therapy.

Finally, the Antiplatelet Therapy for Patients Undergoing Transcatheter Aortic Valve Implantation (POPular-TAVI) trial

recently published the results for their cohort B TAVR patients who have an established indication for long-term anticoagulation such as atrial fibrillation.⁵⁸ Patients receiving oral anticoagulation alone had a significant lower risk of bleeding compared with the combination of oral anticoagulation plus clopidogrel (21.7% vs. 34.6%, $P=0.01$; relative risk ratio 0.63, 95% confidence interval 0.43–0.90). In the trial, the secondary composite endpoint #1 combined the risks of cardiovascular death and thromboembolism (i.e. CVA and myocardial infarction) with bleeding, and the secondary composite endpoint #2 combined the risks of cardiovascular death and thromboembolism without bleeding. For the secondary composite endpoint #1, oral anticoagulation alone was not inferior to combination therapy (31.2% vs. 45.5%, difference -14.3 percentage points, 95% confidence interval for non-inferiority -25.0 to -3.6 percentage points) and was superior to combination therapy (relative risk ratio 0.69, 95% confidence for superiority 0.51–0.92). For the secondary composite endpoint #2, oral anticoagulation alone was not inferior to combination therapy (13.4% vs. 17.3%, difference -3.9 percentage points, 95% confidence interval for non-inferiority) but was not superior to combination therapy (relative risk ratio 0.77, 95% confidence interval for superiority 0.46–1.31). Therefore, compared with the GALILEO trial, the POPular-TAVI trial suggested that selective single agent anticoagulation without antiplatelet therapy can be safely used in TAVR patients with pre-existing indications for long-term anticoagulation and is associated with a lower risk of bleeding.

Future directions

Based on the current evidence, the diagnosis and management of THV thrombosis should be based on the combined anatomic (i.e. the presence of HALT with or without RLM on 4D MDCT), functional (i.e. transvalvular gradients on echocardiography), and clinical evaluation of patient's symptoms (e.g. dyspnoea from severe stenosis, patient-prosthesis mismatch, or thromboembolism) as shown in [Take home figure](#). However, there are several questions on THV thrombosis that need to be answered in future research. The current



Take home figure Recommended flow chart for clinical decision-making for the diagnosis and treatment of transcatheter heart valve thrombosis. 4D, four-dimensional; HALT, hypoattenuated leaflet thickening; MDCT, multidetector computed tomography; NOAC, non-vitamin K oral anticoagulants; RLM, reduced leaflet motion; TTE, transthoracic echocardiography; VKA, vitamin K antagonist.

foremost research question is the unclear clinical significance/implications of subclinical THV thrombosis. If it is not associated with increased adverse outcomes such as heart failure, thromboembolism, or death compared with controls, there will be no clinical indication for regular surveillance or treatment. It is likely that the current absence of clinical outcomes associated with subclinical THV thrombosis is due to the small number of patients in studies and the short duration of follow-up. Alternatively, thrombosis may be part of the natural healing response after TAVR without clinical sequelae in majority of patients. If future research suggests that regular surveillance is required, the variable natural history of THV thrombosis may entail regular echocardiography instead of 4D MDCT be used to detect haemodynamically severe and symptomatic valvular obstruction without the risks of repeated radiation exposure. However, the frequency and duration of periodic surveillance is unknown. Finally, the optimal type (anticoagulation vs. antiplatelet) and duration of therapy after TAVR is also unknown. As before, routine indiscriminate use of anticoagulation in all TAVR patients is likely inappropriate and anticoagulation should probably only be given to patients with symptomatic THV thrombosis (e.g. dyspnoea from severe stenosis or severe patient–prosthesis mismatch, or evidence of thromboembolism) or pre-existing indications. Some of these research questions may be potentially answered by several upcoming clinical trials. For example, the DAPT vs. Oral Anticoagulation for a Short Time to Prevent Cerebral Embolism After TAVI (AUREA) (NCT01642134) trial will compare DAPT against VKA. The Anti-Thrombotic Strategy After Trans-Aortic Valve Implantation for Aortic Stenosis (ATLANTIS) (NCT02664649) trial aims to demonstrate the superiority of monotherapy anticoagulation with Apixaban 5 mg twice daily compared with either VKA or DAPT. Finally, the Edoxaban Compared to Standard Care After Heart Valve Replacement Using a Catheter in Patients With Atrial Fibrillation (ENVISAGE-TAVI AF) (NCT02943785) trial compares Edoxaban vs. VKA in TAVR patients with atrial fibrillation. Since TAVR is increasingly utilized in lower-risk patients, it is of utmost importance to answer these clinical questions.

Conflict of interest: M.J.M. is an uncompensated co-principal investigator of the COAPT trial (Abbott Vascular) and serves on the Apollo Trial Executive Committee (Medtronic). R.M. has received grants from Edwards Lifesciences and St. Jude Medical; is a consultant for Abbott Vascular, Cordis, and Medtronic; and holds equity in Entourage Medical. P.B. provides uncompensated computed tomography services for Edwards Lifesciences, Medtronic, Neovasc, Aegis, and Tendyne Holdings. J.A.L. is supported by the Canadian Research Chair in Advanced CardioPulmonary Imaging; consults for Edwards Lifesciences, HeartFlow, and CircleCVI; holds stock options in HeartFlow and Circle CVI; and provides uncompensated computed tomography services for Edwards Lifesciences, Medtronic, Neovasc, Aegis, and Tendyne Holdings. M.B.L. has served as a non-paid member of the scientific advisory board of Edwards Lifesciences and has served as a consultant for Abbott Vascular and Boston Scientific. The Department of Cardiology of the Leiden University Medical Center received unrestricted research grants from Abbott Vascular, Bayer, BioVentric, Biotronik, Boston Scientific, Edwards Lifesciences, Medtronic, and GE Healthcare. V.D. received speaker fees from Abbott Vascular, GHealthcare, Medtronic, MSD and Edwards

Lifesciences. J.J.B. received speaker fees from Abbot Vascular. All other authors declared no conflict of interest.

References

- Thourani VH, Kodali S, Makkar RR, Herrmann HC, Williams M, Babaliaros V, Smalling R, Lim S, Malaisrie SC, Kapadia S, Szeto WY, Greason KL, Kereiakes D, Ailawadi G, Whisenant BK, Devireddy C, Leipsic J, Hahn RT, Pibarot P, Weissman NJ, Jaber WA, Cohen DJ, Suri R, Tuzcu EM, Svensson LG, Webb JG, Moses JW, Mack MJ, Miller DC, Smith CR, Alu MC, Parvataneni R, D'Agostino RB Jr, Leon MB. Transcatheter aortic valve replacement versus surgical valve replacement in intermediate-risk patients: a propensity score analysis. *Lancet* 2016; **387**:2218–2225.
- Mack MJ, Leon MB, Thourani VH, Makkar R, Kodali SK, Russo M, Kapadia SR, Malaisrie SC, Cohen DJ, Pibarot P, Leipsic J, Hahn RT, Blanke P, Williams MR, McCabe JM, Brown DL, Babaliaros V, Goldman S, Szeto S, Hahn WY, Genereux P, Pershad A, Pocock SJ, Alu MC, Webb JG, Smith CR. Transcatheter aortic-valve replacement with a balloon-expandable valve in low-risk patients. *N Engl J Med* 2019; **380**:1695–1705.
- Kang DH, Park SJ, Lee SA, Lee S, Kim DH, Kim HK, Yun SC, Hong GR, Song JM, Chung CH, Song JK, Lee JW, Park SW. Early surgery or conservative care for asymptomatic aortic stenosis. *N Engl J Med* 2020; **382**:111–119.
- Capodanno D, Petronio AS, Prendergast B, Eltchaninoff H, Vahanian A, Modine T, Lancellotti P, Sondergaard L, Ludman PF, Tamburino C, Piazza N, Hancock J, Mehili J, Byrne RA, Baumhach A, Kappetein AP, Vranckx P, Webb JG, Haude M. Standardized definitions of structural deterioration and valve failure in assessing long-term durability of transcatheter and surgical aortic bioprosthetic valves: a consensus statement from the European Association of Percutaneous Cardiovascular Interventions (EAPCI) endorsed by the European Society of Cardiology (ESC) and the European Association for Cardio-Thoracic Surgery (EACTS). *Eur Heart J* 2017; **38**:3382–3390.
- Rodriguez-Gabella T, Voisine P, Puri R, Pibarot P, Rodés-Cabau J. Aortic bioprosthetic valve durability: incidence, mechanisms, predictors, and management of surgical and transcatheter valve degeneration. *J Am Coll Cardiol* 2017; **70**:1013–1028.
- Kappetein AP, Head SJ, Genereux P, Piazza N, van Mieghem NM, Blackstone EH, Brott TG, Cohen DJ, Cutlip DE, van Es GA, Hahn RT, Kirtane AJ, Krucoff MW, Kodali S, Mack MJ, Mehran R, Rodés-Cabau J, Vranckx P, Webb JG, Windecker S, Serruys PW, Leon MB. Updated standardized endpoint definitions for transcatheter aortic valve implantation: the Valve Academic Research Consortium-2 consensus document. *Eur Heart J* 2012; **33**:2403–2418.
- Puvimanasinghe JP, Steyerberg EW, Takkenberg JJ, Eijkemans MJ, van Herwerden LA, Bogers AJ, Habbema JD. Prognosis after aortic valve replacement with a bioprosthesis: predictions based on meta-analysis and microsimulation. *Circulation* 2001; **103**:1535–1541.
- EGbe AC, Pislaru SV, Pellikka PA, Poterucha JT, Schaff HV, Maleszewski JJ, Connolly HM. Bioprosthetic valve thrombosis versus structural failure: clinical and echocardiographic predictors. *J Am Coll Cardiol* 2015; **66**:2285–2294.
- Akins CW, Miller DC, Turina MI, Kouchoukos NT, Blackstone EH, Grunkemeier GL, Takkenberg JJ, David TE, Butchart EG, Adams DH, Shahian DM, Hagl S, Mayer JE, Lytle BW. Guidelines for reporting mortality and morbidity after cardiac valve interventions. *J Thorac Cardiovasc Surg* 2008; **135**:732–738.
- Yamashita K, Yagi H, Hayakawa M, Abe T, Hayata Y, Yamaguchi N, Sugimoto M, Fujimura Y, Matsumoto M, Taniguchi S. Rapid restoration of thrombus formation and high-molecular-weight von Willebrand factor multimers in patients with severe aortic stenosis after valve replacement. *J Atheroscler Thromb* 2016; **23**:1150–1158.
- Ladich E, Michaels MB, Jones RM, McDermott E, Coleman L, Komtebedde J, Glower D, Argenziano M, Feldman T, Nakano M, Virmani R. Pathological healing response of explanted MitraClip devices. *Circulation* 2011; **123**:1418–1427.
- Jilaihawi H, Asch FM, Manasse E, Ruiz CE, Jelvin V, Kashif M, Kawamori H, Maeno Y, Kazuno Y, Takahashi N, Olson R, Alkhatib J, Berman D, Friedman J, Gellada N, Chakravarty T, Makkar RR. Systematic CT methodology for the evaluation of subclinical leaflet thrombosis. *JACC Cardiovasc Imaging* 2017; **10**:461–470.
- Midha PA, Raghav V, Sharma R, Condado JF, Okafor IU, Rami T, Kumar G, Thourani VH, Jilaihawi H, Babaliaros V, Makkar RR, Yoganathan AP. The fluid mechanics of transcatheter heart valve leaflet thrombosis in the neosinus. *Circulation* 2017; **136**:1598–1609.
- Sellers SL, Turner CT, Sathananthan J, Cartledge TRG, Sin F, Bouchareb R, Mooney J, Norgaard BL, Bax JJ, Bernatchez PN, Dweck MR, Granville DJ, Newby DE, Lauck S, Webb JG, Payne GV, Pibarot P, Blanke P, Seidman MA, Leipsic JA. Transcatheter aortic heart valves: histological analysis providing insight to leaflet thickening and structural valve degeneration. *JACC Cardiovasc Imaging* 2019; **12**:135–145.
- Richards J, El-Hamamsy I, Chen S, Sarang Z, Sarathchandra P, Yacoub MH, Chester AH, Butcher JT. Side-specific endothelial-dependent regulation of aortic

- valve calcification: interplay of hemodynamics and nitric oxide signaling. *Am J Pathol* 2013;**182**:1922–1931.
16. Farrar EJ, Huntley GD, Butcher J. Endothelial-derived oxidative stress drives myofibroblastic activation and calcification of the aortic valve. *PLoS One* 2015;**10**: e0123257.
 17. Ghaisas NK, Foley JB, O'Briain DS, Crean P, Kelleher D, Walsh M. Adhesion molecules in nonrheumatic aortic valve disease: endothelial expression, serum levels and effects of valve replacement. *J Am Coll Cardiol* 2000;**36**:2257–2262.
 18. Lopez-Moya M, Melgar-Lesmes P, Kolandaivelu K, de la Torre Hernández JM, Edelman ER, Balcells M. Optimizing glutaraldehyde-fixed tissue heart valves with chondroitin sulfate hydrogel for endothelialization and shielding against deterioration. *Biomacromolecules* 2018;**19**:1234–1244.
 19. Vahidkhal K, Azadani AN. Supra-annular valve-in-valve implantation reduces blood stasis on the transcatheter aortic valve leaflets. *J Biomech* 2017;**58**:114–122.
 20. Abdel-Wahab M, Simonato M, Latib A, Goleski PJ, Allali A, Kaur J, Azadani AN, Horlick E, Testa L, Orvin K, Kornowski R, Kass M, Don CW, Richardt G, Webb JG, Dvir D. Clinical valve thrombosis after transcatheter aortic valve-in-valve implantation. *Circ Cardiovasc Interv* 2018;**11**:e006730.
 21. Chakravarty T, Søndergaard L, Friedman J, De Backer O, Berman D, Kofoed KF, Jilaihawi H, Shiota T, Abramowitz Y, Jørgensen TH, Rami T, Israr S, Fontana G, de Knecht M, Fuchs A, Lyden P, Trento A, Bhatt DL, Leon MB, Makkar RR, Ramzy D, Cheng W, Siegel RJ, Thomson LM, Mangat G, Hariri B, Sawaya FJ, Iversen HK. Subclinical leaflet thrombosis in surgical and transcatheter bioprosthetic aortic valves: an observational study. *Lancet* 2017;**389**:2383–2392.
 22. Del Trigo M, Muñoz-García AJ, Wijeyundera HC, Nombela-Franco L, Cheema AN, Gutierrez E, Serra V, Kefer J, Amat-Santos IJ, Benitez LM, Mewa J, Jiménez-Quevedo P, Alnasser S, García del Blanco B, Dager A, Abdul-Jawad Altisier O, Puri R, Campelo-Parada F, Dahou A, Paradis J-M, Dumont E, Pibarot P, Rodés-Cabau J. Incidence, timing, and predictors of valve hemodynamic deterioration after transcatheter aortic valve replacement: multicenter registry. *J Am Coll Cardiol* 2016;**67**:644–655.
 23. Hansson NC, Grove EL, Andersen HR, Leipsic J, Mathiassen ON, Jensen JM, Jensen KT, Blanke P, Leetmaa T, Tang M, Krusell LR, Klaaborg KE, Christiansen EH, Terp K, Terkelsen CJ, Poulsen SH, Webb J, Botker HE, Nørgaard BL. Transcatheter aortic valve thrombosis: incidence, predisposing factors, and clinical implications. *J Am Coll Cardiol* 2016;**68**:2059–2069.
 24. Søndergaard L, De BO, Kofoed KF, Jilaihawi H, Fuchs A, Chakravarty T, Kashif M, Kazuno Y, Kawamori H, Maeno Y, Bieliauskas G, Guo H, Stone GW, Makkar R. Natural history of subclinical leaflet thrombosis affecting motion in bioprosthetic aortic valves. *Eur Heart J* 2017;**38**:2201–2207.
 25. Vahidkhal K, Abbasi M, Barakat M, Azadani PN, Tandar A, Dvir D, Azadani AN. Effect of reduced cardiac output on blood stasis on transcatheter aortic valve leaflets: implications for valve thrombosis. *EuroIntervention* 2017;**13**:811–819.
 26. Yanagisawa R, Tanaka M, Yashima F, Arai T, Jinzaki M, Shimizu H, Fukuda K, Watanabe Y, Naganuma T, Higashimori A, Mizutani K, Araki M, Tada N, Yamanaka F, Otsuka T, Yamamoto M, Hayashida K. Early and late leaflet thrombosis after transcatheter aortic valve replacement. *Circ Cardiovasc Interv* 2019;**12**: e007349.
 27. Makkar RR, Fontana G, Jilaihawi H, Chakravarty T, Kofoed KF, De BO, Asch FM, Ruiz CE, Olsen NT, Trento A, Friedman J, Berman D, Cheng W, Kashif M, Jelnin V, Kliger CA, Guo H, Pichard AD, Weissman NJ, Kapadia S, Manasse E, Bhatt DL, Leon MB, Søndergaard L. Possible subclinical leaflet thrombosis in bioprosthetic aortic valves. *N Engl J Med* 2015;**373**:2015–2024.
 28. Yanagisawa R, Hayashida K, Yamada Y, Tanaka M, Yashima F, Inohara T, Arai T, Kawakami T, Maekawa Y, Tsuruta H, Itabashi Y, Murata M, Sano M, Okamoto K, Yoshitake A, Shimizu H, Jinzaki M, Fukuda K. Incidence, predictors, and mid-term outcomes of possible leaflet thrombosis after TAVR. *JACC Cardiovasc Imaging* 2017;**10**:1–11.
 29. Kvitting JP, Ebbers T, Wigstrom L, Engvall J, Olin CL, Bolger AF. Flow patterns in the aortic root and the aorta studied with time-resolved, 3-dimensional, phase-contrast magnetic resonance imaging: implications for aortic valve-sparing surgery. *J Thorac Cardiovasc Surg* 2004;**127**:1602–1607.
 30. Oechtering TH, Hons CF, Sieren M, Hunold P, Hennemuth A, Huellebrand M, Drexler J, Scharfshwerdt M, Richardt D, Sievers HH, Barkhausen J, Frydrychowicz A. Time-resolved 3-dimensional magnetic resonance phase contrast imaging (4D Flow MRI) analysis of hemodynamics in valve-sparing aortic root repair with an anatomically shaped sinus prosthesis. *J Thorac Cardiovasc Surg* 2016;**152**:418–427.
 31. Jahren SE, Heinisch PP, Hasler D, Winkler BM, Stortecky S, Pilgrim T, Londono MC, Carrel T, von Tengg-Kubligk H, Obrist D. Can bioprosthetic valve thrombosis be promoted by aortic root morphology? An in vitro study. *Interact Cardiovasc Thorac Surg* 2018;**27**:108–115.
 32. Vahidkhal K, Javani S, Abbasi M, Azadani PN, Tandar A, Dvir D, Azadani AN. Blood stasis on transcatheter valve leaflets and implications for valve-in-valve leaflet thrombosis. *Ann Thorac Surg* 2017;**104**:751–759.
 33. Jose J, Sulimov DS, El-Mawardi M, Sato T, Allali A, Holy EW, Becker B, Landt M, Kebernik J, Schwarz B, Richardt G, Bdel-Wahab M. Clinical bioprosthetic heart valve thrombosis after transcatheter aortic valve replacement: incidence, characteristics, and treatment outcomes. *JACC Cardiovasc Interv* 2017;**10**:686–697.
 34. Overtchouk P, Guedeney P, Rouanet S, Verhoye JP, Lefevre T, Van BE, Eltchaninoff H, Gilard M, Leprince P, Iung B, Barthelemy O, Le BH, Souteyrand G, Vicaut E, Montalescot G, Collet JP. Long-term mortality and early valve dysfunction according to anticoagulation use: the FRANCE TAVI registry. *J Am Coll Cardiol* 2019;**73**:13–21.
 35. Pibarot P, Dumesnil JG. Prosthesis-patient mismatch: definition, clinical impact, and prevention. *Heart* 2006;**92**:1022–1029.
 36. Flameng W, Herregods MC, Vercauteren M, Herijgers P, Bogaerts K, Meuris B. Prosthesis-patient mismatch predicts structural valve degeneration in bioprosthetic heart valves. *Circulation* 2010;**121**:2123–2129.
 37. Ruile P, Minners J, Schoechlin S, Pache G, Hochholzer W, Blanke P, Jander N, Gick M, Schrofel H, Siepe M, Neumann FJ, Hein M. Impact of the type of transcatheter heart valve on the incidence of early subclinical leaflet thrombosis. *Eur J Cardiothorac Surg* 2018;**53**:778–783.
 38. Vollema EM, Kong WKF, Katsanos S, Kamperidis V, van Rosendaal PJ, van der KF, de WA, Ajmone MN, Delgado V, Bax JJ. Transcatheter aortic valve thrombosis: the relation between hypo-attenuated leaflet thickening, abnormal valve haemodynamics, and stroke. *Eur Heart J* 2017;**38**:1207–1217.
 39. Reardon MJ, Feldman TE, Meduri CU, Makkar RR, O'Hair D, Linke A, Kereiakes DJ, Waksman R, Babliaros V, Stoler RC, Mishkel G, Rizik DG, Iyer VS, Gleason TG, Tchetcher D, Rovin JD, Lhermusier T, Carrie D, Hodson RW, Alocco DJ, Meredith IT; for the Reprise III Investigators. Two-year outcomes after transcatheter aortic valve replacement with mechanical vs self-expanding valves: the REPRIS III randomized clinical trial. *JAMA Cardiol* 2019;**4**:223.
 40. Ruile P, Minners J, Breitbart P, Schoechlin S, Gick M, Pache G, Neumann FJ, Hein M. Medium-term follow-up of early leaflet thrombosis after transcatheter aortic valve replacement. *JACC Cardiovasc Interv* 2018;**11**:1164–1171.
 41. Makkar R. <https://www.tctmd.com/slide/partner-3-low-risk-computed-tomography-substudy-subclinical-leaflet-thrombosis-transcatheter> (2 July 2020). 2019.
 42. Blanke P, Leipsic JA, Popma JJ, Yakubov SJ, Deeb GM, Gada H, Mumtaz M, Ramlawi B, Kleiman NS, Sorajja P, Askew J, Meduri CU, Kauten J, Melnitchouk S, Inglessis I, Huang J, Boulware M, Reardon MJ. Leaflet thickening or immobility following aortic valve replacement: results from the Evolut Low Risk sub-study. *J Am Coll Cardiol* 2020;**75**. doi:10.1016/S0735-1097(20)31728-9.
 43. Franzone A, Pilgrim T, Haynes AG, Lanz J, Asami M, Praz F, Raber L, Roost E, Langhammer B, Windecker S, Stortecky S. Transcatheter aortic valve thrombosis: incidence, clinical presentation and long-term outcomes. *Eur Heart J Cardiovasc Imaging* 2018;**19**:398–404.
 44. Latib A, Naganuma T, Bdel-Wahab M, Danenberg H, Cota L, Barbanti M, Baumgartner H, Finkelstein A, Legrand V, de Lezo JS, Kefer J, Messika-Zeitoun D, Richardt G, Stabile E, Kaleschke G, Vahanian A, Laborde JC, Leon MB, Webb JG, Panoulas VF, Maisano F, Alfieri O, Colombo A. Treatment and clinical outcomes of transcatheter heart valve thrombosis. *Circ Cardiovasc Interv* 2015;**8**:e001779.
 45. Leetmaa T, Hansson NC, Leipsic J, Jensen K, Poulsen SH, Andersen HR, Jensen JM, Webb J, Blanke P, Tang M, Nørgaard BL. Early aortic transcatheter heart valve thrombosis: diagnostic value of contrast-enhanced multidetector computed tomography. *Circ Cardiovasc Interv* 2015;**8**:e001596.
 46. Pache G, Schoechlin S, Blanke P, Dorfs S, Jander N, Arepalli CD, Gick M, Buettner HJ, Leipsic J, Langer M, Neumann FJ, Ruile P. Early hypo-attenuated leaflet thickening in balloon-expandable transcatheter aortic heart valves. *Eur Heart J* 2016;**37**:2263–2271.
 47. Spartera M, Ancona F, Barletta M, Rosa I, Stella S, Marini C, Italia L, Montorfano M, Latib A, Alfieri O, Margonato A, Colombo A, Agricola E. Echocardiographic features of post-transcatheter aortic valve implantation thrombosis and endocarditis. *Echocardiography* 2018;**35**:337–345.
 48. De Backer O, Dangas GD, Jilaihawi H, Leipsic JA, Terkelsen CJ, Makkar R, Kini AS, Veien KT, Abdel-Wahab M, Kim W-K, Balan P, Van Mieghem N, Mathiassen ON, Jeger RV, Arnold M, Mehran R, Guimarães AHC, Nørgaard BL, Kofoed KF, Blanke P, Windecker S, Søndergaard L. Reduced leaflet motion after transcatheter aortic-valve replacement. *N Engl J Med* 2020;**382**:130–139.
 49. Baumgartner H, Falk V, Bax JJ, De Bonis M, Hamm C, Holm PJ, Iung B, Lancellotti P, Lansac E, Rodriguez Muñoz D, Rosenhek R, Sjögren J, Tornos Mas P, Vahanian A, Walther T, Wendler O, Windecker S, Zamorano JL; ESC Scientific Document Group. 2017 ESC/EACTS Guidelines for the management of valvular heart disease. *Eur Heart J* 2017;**38**:2739–2791.
 50. Nishimura RA, Otto CM, Bonow RO, Carabello BA, Erwin JP, Guyton RA, O'Gara PT, Ruiz CE, Skubas NJ, Sorajja P, Sundt TM, Thomas JD. 2014 AHA/ACC Guideline for the management of patients with valvular heart disease: a report of the American College of Cardiology/American Heart Association Task Force on Practice Guidelines. *Circulation* 2014;**129**:e521–e643.
 51. Otto CM, Kumbhani DJ, Alexander KP, Calhoun JH, Desai MY, Kaul S, Lee JC, Ruiz CE, Vassileva CM. 2017 ACC expert consensus decision pathway for transcatheter aortic valve replacement in the management of adults with aortic

- stenosis: a report of the American College of Cardiology Task Force on Clinical Expert Consensus Documents. *J Am Coll Cardiol* 2017;**69**:1313–1346.
52. Ussia GP, Scarabelli M, Mule M, Barbanti M, Sarkar K, Cammalleri V, Imme S, Aruta P, Pistrutto AM, Gulino S, Deste W, Capodanno D, Tamburino C. Dual antiplatelet therapy versus aspirin alone in patients undergoing transcatheter aortic valve implantation. *Am J Cardiol* 2011;**108**:1772–1776.
 53. Stabile E, Pucciarelli A, Cota L, Sorropago G, Tesorio T, Salemme L, Popusoi G, Ambrosini V, Cioppa A, Agrusta M, Catapano D, Moscariello C, Trimarco B, Esposito G, Rubino P. SAT-TAVI (single antiplatelet therapy for TAVI) study: a pilot randomized study comparing double to single antiplatelet therapy for transcatheter aortic valve implantation. *Int J Cardiol* 2014;**174**:624–627.
 54. Rodés-Cabau J, Masson J-B, Welsh RC, Garcia del Blanco B, Pelletier M, Webb JG, Al-Qoofi F, Généreux P, Maluenda G, Thoenes M, Paradis J-M, Chamandi C, Serra V, Dumont E, Côté M. Aspirin versus aspirin plus clopidogrel as antithrombotic treatment following transcatheter aortic valve replacement with a balloon-expandable valve: the ARTE (aspirin versus aspirin + clopidogrel following transcatheter aortic valve implantation) randomized clinical trial. *JACC Cardiovasc Interv* 2017;**10**:1357–1365.
 55. Maes F, Stabile E, Ussia GP, Tamburino C, Pucciarelli A, Masson JB, Marsal JR, Barbanti M, Cote M, Rodes-Cabau J. Meta-analysis comparing single versus dual antiplatelet therapy following transcatheter aortic valve implantation. *Am J Cardiol* 2018;**122**:310–315.
 56. Siddamsetti S, Balasubramanian S, Yandrapalli S, Vij A, Joshi U, Tang G, Kodumuri V. Meta-analysis comparing dual antiplatelet therapy versus single antiplatelet therapy following transcatheter aortic valve implantation. *Am J Cardiol* 2018;**122**:1401–1408.
 57. Dangas GD, Tijssen JGP, Wohrle J, Sondergaard L, Gilard M, Mollmann H, Makkar RR, Herrmann HC, Giustino G, Baldus S, De BO, Guimaraes AHC, Gullestad L, Kini A, von LD, Mack M, Moreno R, Schafer U, Seeger J, Tchetché D, Thomitzek K, Valgimigli M, Vranckx P, Welsh RC, Wildgoose P, Volkl AA, Zazula A, van Amsterdam RGM, Mehran R, Windecker SA. Controlled trial of rivaroxaban after transcatheter aortic-valve replacement. *N Engl J Med* 2020;**382**:120–129.
 58. Nijenhuis VJ, Brouwer J, Delewi R, Hermanides RS, Holvoet W, Dubois CLF, Frambach P, De Bruyne B, van Houwelingen GK, Van Der Heyden JAS, Toušek P, van der Kley F, Buysschaert I, Schotborgh CE, Ferdinand B, van der Harst P, Roosen J, Peper J, Thielen FWF, Veenstra L, Chan Pin Yin DRPP, Swaans MJ, Rensing BJWM, van 't Hof AWJ, Timmers L, Kelder JC, Stella PR, Baan J, ten Berg JM. Anticoagulation with or without clopidogrel after transcatheter aortic-valve implantation. *N Engl J Med* 2020;**382**:1696–1707.