



Universiteit
Leiden
The Netherlands

Comparing heterotopic ossification in two cervical disc prostheses

Yang, X.Y.; Donk, R.; Bartels, R.H.M.A.; Arts, M.P.; Depreitere, B.; Vleggeert-Lankamp, C.L.A.

Citation

Yang, X. Y., Donk, R., Bartels, R. H. M. A., Arts, M. P., Depreitere, B., & Vleggeert-Lankamp, C. L. A. (2020). Comparing heterotopic ossification in two cervical disc prostheses. *Spine*, 45(19), 1329-1334. doi:10.1097/BRS.0000000000003537

Version: Publisher's Version

License: [Creative Commons CC BY-NC-ND 4.0 license](https://creativecommons.org/licenses/by-nc-nd/4.0/)

Downloaded from: <https://hdl.handle.net/1887/3185394>

Note: To cite this publication please use the final published version (if applicable).

CERVICAL SPINE

OPEN

Comparing Heterotopic Ossification in Two Cervical Disc Prostheses

Xiaoyu Yang, MD, MSc,^a Roland Donk, MD, PhD,^b Ronald H.M.A. Bartels, MD, PhD,^c
Mark P. Arts, MD, PhD,^d Bart Depreitere, MD, PhD,^e and Carmen L.A. Vleggeert-Lankamp, MD, PhD^a

Study Design. Retrospective analysis using data from randomized clinical trials.

Objective. To compare the occurrence of heterotopic ossification (HO) between two cervical disc prostheses. Clinical outcome and range of motion (ROM) were also evaluated.

Summary of Background Data. Cervical arthroplasty was reported to be able to maintain the segmental ROM. However, controversy exists since the difference of the occurrence of HO concerning cervical prosthesis is still huge.

Methods. Patients who underwent anterior cervical discectomy with arthroplasty for a cervical radiculopathy due to a herniated disc from the The Netherlands Cervical Kinematics (NECK) trial (activC; metal endplates with a polyethylene inlay and a keel for primary stability) and the PROCON trial (Bryan; metal-on-polymer with titanium coated endplates without a keel) were analyzed for HO at 12 and 24 months postoperatively. HO was scored according to the McAfee–Mehren classification. Segmental ROM was defined by a custom developed image analysis tool, and global cervical ROM was

measured by Cobb's angle. Clinical outcome was evaluated by means of the neck disability index (NDI) as well as physical-component summary (PCS) and mental-component summary (MCS).

Results. At 2-year follow-up, the occurrence of HO was 68% in patients treated with the activC prosthesis (severe HO 55%), which was comparable with 85% ($P=0.12$) in patients with the Bryan disc (severe HO 44%; $P=0.43$). The HO progression was similar between groups. Clinically, the patients had comparable NDI, PCS, and MCS at 2-year follow-up, and comparable improvement of clinical outcomes. The global ROM in the Bryan group ($56.4 \pm 10.8^\circ$) was significantly higher than in the activC group (49.5 ± 14.0 , $P=0.044$) at 2-year follow-up.

Conclusion. In comparison of two cervical disc prostheses the development of HO is independent on their architecture. Although global ROM was higher in the Bryan prosthesis group, this difference was not deemed clinically important, particularly because the clinical condition of patients with and without severe HO was comparable.

Key words: adjacent segment degeneration, arthroplasty, cervical discectomy.

Level of Evidence: 2

Spine 2020;45:1329–1334

From the ^aDepartment of Neurosurgery, Leiden University Medical Centre, Leiden, The Netherlands; ^bDepartment of Orthopaedic Surgery, Via Sana Clinics, Mill, The Netherlands; ^cDepartment of Neurosurgery, Radboud University Medical Centre, Nijmegen, The Netherlands; ^dDepartment of Neurosurgery, Haaglanden Medical Centre, The Hague, The Netherlands; and ^eDepartment of Neurosurgery, University Hospitals Leuven, Leuven, Belgium.

Acknowledgment date: January 16, 2020. First revision date: February 5, 2020. Second revision date: February 28, 2020. Acceptance date: March 23, 2020.

The legal regulatory status of the device(s)/drug(s) that is/are the subject of this manuscript is not applicable in my country.

China Scholarship Council and the Department of Neurosurgery, Leiden University Medical Centre, The Netherlands funds were received in support of this work. The Netherlands Cervical Kinematics (NECK) trial was sponsored by B. Braun Medical and the Department of Neurosurgery of the Leiden University Medical Centre, the Netherlands.

Relevant financial activities outside the submitted work: royalties.

This is an open access article distributed under the terms of the Creative Commons Attribution-Non Commercial-No Derivatives License 4.0 (CCBY-NC-ND), where it is permissible to download and share the work provided it is properly cited. The work cannot be changed in any way or used commercially without permission from the journal.

Address correspondence and reprint requests to Xiaoyu Yang, MD, MSc, J11-R-83: Department of Neurosurgery, Leiden University Medical Centre, Albinusdreef 2, Leiden, 2300 RC, The Netherlands; E-mail: X.Yang@lumc.nl

DOI: 10.1097/BRS.0000000000003537

Anterior cervical discectomy and fusion (ACDF) has been a common surgical treatment for cervical radiculopathy since it was initially described in the 1950s^{1–3} and became the gold standard procedure. Nevertheless, it was postulated that arthrodesis of a motion segment caused by ACDF leads to increased mechanical load at the adjacent levels.⁴ Accordingly, cervical arthroplasty (ACDA) was introduced with the aim to preserve the mobility at the index level. A variety of studies have demonstrated that ACDA is able to maintain the range of motion (ROM) at the index level.^{5–9} However, an adverse effect has been reported after cervical arthroplasty, namely heterotopic ossification (HO), which was first reported in 2005.^{10,11}

HO is a phenomenon of any bone formation outside the skeletal system that occurs after surgery. It is well known that HO occurs after arthroplasty in the lumbar spine and classified by McAfee *et al.*¹² In 2006, Mehren *et al.*¹³ published their classification system focusing on the cervical spine based on the

classification presented by McAfee *et al*.¹² Subsequently, several studies have been published on the incidence of HO which was reported to vary considerably, from 7.8% to 94.1%.^{14–19} This difference was possibly due to interobserver error¹⁵ and the dynamic nature of HO.²⁰ Yi *et al*¹⁵ and Zeng *et al*²¹ demonstrated that different type of prosthesis could also influence the occurrence rate of HO. However, controversy exists since the difference of the occurrence of HO concerning same cervical prosthesis is still huge.^{16,22} In addition, a recent meta-analysis reported that the severity of HO impacted clinical outcome,²³ but some other studies debated this.^{18,24}

The objective of the present study is to investigate the occurrence of HO in patients that were treated by anterior cervical discectomy for cervical radiculopathy with arthroplasty using two different cervical prostheses. The clinical outcome and ROM of the cervical spine will be evaluated as well.

MATERIALS AND METHODS

Study Design

NECK Trial

A prospective, randomized double-blind multicenter trial among patients with cervical radiculopathy due to single level disc herniation was conducted. Patients were randomly assigned into three groups: anterior cervical discectomy with arthroplasty (ACDA; activC, Aesculap AG, Tuttlingen, Germany), anterior cervical discectomy with fusion (ACDF; Cage stand-alone), and anterior cervical discectomy without fusion (ACD). The protocol was approved by medical ethics committees, including an approval for randomization after anesthetic induction. All patients gave informed consent. The design and study protocol were published previously.²⁵

PROCON Trial

The trial design was a prospective, double blind, single center randomized study, with a three-arm parallel group. Patients were randomly allocated into three groups: ACDA (Bryan disc prosthesis, Sofamor Danek, Kerkrade, the Netherlands), ACDF (Cage stand-alone, DePuy Spine, Johnson and Johnson, Amsterfoort, the Netherlands), and ACD. The trial was approved by medical ethics committee. All patients gave informed consent. The design and study protocol were published previously.²⁶

Patients and Disc Prostheses

Patients that were allocated to a prosthesis in the NECK trial and PROCON trial were subject of this study.

The activC device is composed of two flat Cobalt-Chrome-Molybden alloy metal endplate components with spikes on the superior endplate and an inferior endplate and a keel for primary stability. The inferior prosthesis plate has an integrated polyethylene inlay.²⁷

The Bryan disc is a one-piece, biarticulating, metal-on-polymer, unconstrained device with a fully variable instantaneous axis of rotation.²⁸ Initial stability is achieved by precision milling of the vertebral endplates, and long-term stability is provided by bone growth into the porous-coated titanium alloy endplates.²⁹

Clinical Outcomes

Neck disability index (NDI) is a 10-item questionnaire on three different aspects: pain intensity, daily work-related activities, and nonwork-related activities. Each item is scored from 0 to 5 and the total score ranges from 0 (best score) to 50 (worst score). This 50 points score was converted to a percentage (50 points = 100%). The NDI is a modification of the Oswestry Low Back Pain Index and has been shown to be reliable and valid for patients with cervical pathology.^{30–32}

Moreover, physical-component summary (PCS) and mental-component summary (MCS) were derived from the 36-Item Short Form Survey. The PCS and MCS range from 0 to 100, with higher scores representing better self-reported health.

Radiological Evaluation

Lateral radiographs of the cervical spine were obtained with the patients in a neutral standing position and instructed to look straight ahead, with hips and knees extended. HO was evaluated according to the McAfee-Mehren classification system¹³ (Table 1). The patients were divided by the grade of HO²³: mild HO was defined as grade 0 to grade II, and severe HO was defined as grade III and IV.

Flexion–extension radiographs were obtained preoperatively and at 12 and 24 months postoperatively. The ROM at the index level was defined as the intervertebral sagittal motion between full flexion and extension. The ROM at index level was measured with a custom developed image analysis tool (BMGO, KU Leuven, Belgium), which has a measurement error of 0.3° and 0.3 mm and excellent inter-rater and intrarater agreement (intraclass correlation

TABLE 1. The Classification of Heterotopic Ossification (From Mehren Classification System¹⁶)

Grade	Classification
Grade 0	No HO present
Grade I	HO is detectable in front of the vertebral body but not in the anatomic interdiscal space
Grade II	HO is growing into the disc space. Possible affection of the function of the prosthesis
Grade III	Bridging ossifications which still allow movement of the prosthesis
Grade IV	Complete fusion of the treated segment without movement in the flexion/extension

HO indicates heterotopic ossification.

TABLE 2. Demographics of the Patients

	ActivC Group	Bryan Group	P Value
Population	35	48	
Age (yrs, mean \pm SD)	46.5 \pm 8.7	43.6 \pm 6.7	0.086
Body mass index (mean \pm SD)	26.9 \pm 3.7	26.6 \pm 4.4	0.725
Gender (female, No. [%])	18 (52.9%)	25 (52.4%)	0.939
Height (cm, mean \pm SD)	174.3 \pm 11.2	175.3 \pm 9.1	0.663
Weight (kg, mean \pm SD)	82.1 \pm 14.3	82.2 \pm 17.2	0.978
Smoking (%)	14 (40.0%)	25 (52.1%)	0.276
Operated level			
C5–C6	19	22	
C6–C7	16	26	

SD indicates standard deviation.

coefficient >0.75).³³ The ROM of the total cervical spine was evaluated using Cobb's method: the angle of C2 to C7 was measured between the lines drawn parallel to the caudal endplates of C2 and C7.³⁴

HO was independently evaluated by one senior neurosurgeon (C.V.L.) dedicated to spine surgery and ROM was measured by a junior medical doctor (X.Y.). The reviewers were not provided with any clinical information of the included patients.

Statistical Analysis

All the data were presented as mean \pm standard deviation. Data of the activC group and Bryan group were compared using Student *t* test for continuous data and chi-square test for categorical data. Paired *t* test was performed on the comparison of segmental ROM between baseline and 2-year follow-up. Tests were two tailed, and a *P* value of <0.05 was considered significant. SPSS software, version 25.0 was used for all statistical analyses (SPSS, Inc., Chicago, IL).

RESULTS

Demographics

In the NECK trial, 35 patients were randomly assigned to the activC group, and 48 patients were assigned to the Bryan

group in the PROCON trial. There was no difference between the two groups in baseline characteristics (Table 2).

The Occurrence of HO

At 2-year follow-up in the activC group, HO was absent in 10 patients (32%) and was present as grade I in one patient (3%), grade II in three patients (10%), and grade III in four patients (13%). Thirteen patients were evaluated to have grade IV (42%). In the Bryan patient group at 2-year follow-up, four patients had no HO (15%), five patients had grade I HO (19%), six patients had grade II (22%), eight patients had grade III (30%), and grade IV was found in four patients (15%) (Figure 1). Consequently, the overall HO occurrence of the activC group was 68%, which is comparable with 85% HO in the Bryan group ($P=0.121$). Furthermore, severe HO was present in 55% of the patients that received an activC prosthesis and in 44% of the patients that received a Bryan disc ($P=0.430$).

The Progression of HO

In Table 3, the progression of HO grading is summarized. In the activC group, 48% of the 29 patients that demonstrated low grade HO at 1-year follow-up to high grade HO at 2-year follow-up. This increase was comparable to 42% of the

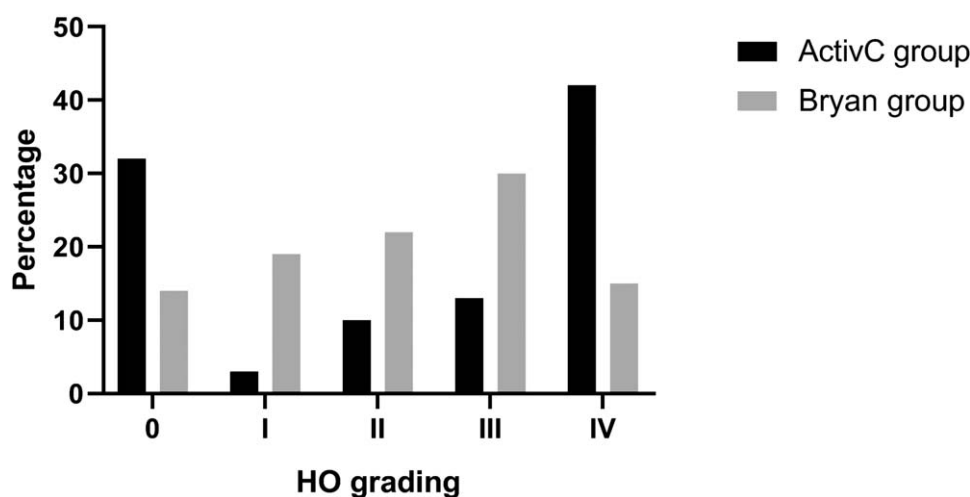


Figure 1. The occurrence of heterotopic ossification (HO) at 2-year follow-up.

TABLE 3. Progression of Heterotopic Ossification

ActivC Group						
1-Year Follow-up	2-Year Follow-up					
	0	I	II	III	IV	Total
0	9	0	2	3	4	18
I	0	1	0	0	2	3
II	0	0	0	0	2	2
III	0	0	0	1	1	2
IV	0	0	0	0	4	4
Total	9	1	2	4	13	29

Bryan Group						
1-Year Follow-up	2-Year Follow-up					
	0	I	II	III	IV	Total
0	4	2	0	0	0	6
I	0	3	4	2	0	9
II	0	0	2	2	0	4
III	0	0	0	3	1	4
IV	0	0	0	0	3	3
Total	4	5	6	7	4	26

26 patients in the Bryan group that increased from low to high grade HO ($P = 0.657$).

Comparison on Clinical Outcome

At 2 years after surgery, the mean NDI value decreased 25.7 points from baseline in the activC group, which is comparable with a decrease of 28.0 points in the Bryan group ($P = 0.879$). The PCS mean value improved 31.3 points in

the activC group, compared with an improvement of 33.8 points in the Bryan group ($P = 0.987$). Likewise, the patients in both groups had an increased MCS value without a statistically significant difference (16.8 vs. 19.9, $P = 0.702$) (Table 4). No correlation between clinical outcome and severe HO could be demonstrated, neither in the activC group, the Bryan group, nor in the combination group (Table 5).

TABLE 4. The Improvement of Clinical Outcome Between activC and Bryan

	ActivC Group			Bryan Group			P Value
	Baseline	2-Year FU	Difference	Baseline	2-Year FU	Difference	
NDI	45.8 ± 17.1	20.1 ± 22.0	25.7	40.4 ± 15.0	12.4 ± 15.8	28.0	0.879
PCS	41.0 ± 14.7	72.2 ± 27.3	31.3	42.6 ± 15.6	76.4 ± 24.8	33.8	0.984
MCS	57.0 ± 24.5	73.8 ± 25.7	16.8	59.0 ± 22.8	78.9 ± 18.7	19.9	0.702

FU indicates follow up; MCS, mental-component summary; NDI, Neck Disability Index; PCS, physical-component summary.

TABLE 5. Clinical Outcome and the Severity of HO

		Mild HO	Severe HO	P Value
ActivC group	NDI	19.5 ± 21.7	18.8 ± 20.7	0.933
	PCS	73.1 ± 27.2	74.2 ± 25.8	0.915
	MCS	75.3 ± 24.0	75.8 ± 27.4	0.961
Bryan group	NDI	13.4 ± 18.4	15.3 ± 15.3	0.832
	PCS	79.6 ± 24.6	80.4 ± 21.1	0.947
	MCS	85.5 ± 16.5	72.2 ± 22.3	0.206
Combination group	NDI	16.7 ± 20.0	17.8 ± 19.2	0.857
	PCS	76.0 ± 25.6	75.9 ± 24.3	0.988
	MCS	79.9 ± 21.1	74.8 ± 25.7	0.490

HO indicates heterotopic ossification; MCS, mental-component summary; NDI, Neck Disability Index; PCS, physical-component summary.

Comparison on ROM

At baseline, there was no difference in segmental ROM between the activC group ($8.3 \pm 4.4^\circ$) and the Bryan group ($7.7 \pm 3.7^\circ$, $P = 0.609$). Likewise, no difference was detected in ROM of the total cervical spine (44.9 ± 17.3 vs. $51.4 \pm 16.0^\circ$, $P = 0.215$). At 2-year follow-up, the segmental ROM in both groups was comparable to baseline: $5.7 \pm 5.5^\circ$ in the activC group ($P = 0.071$), and $8.2 \pm 4.7^\circ$ in Bryan group ($P = 0.277$); no significant difference between the activC and Bryan group was present ($P = 0.065$). At 2 years follow-up, the ROM of the total cervical spine differed between the groups: in the Bryan group the ROM of the total cervical spine ($56.4 \pm 10.8^\circ$) was significantly larger than in the activC group (49.5 ± 14.0 , $P = 0.044$).

DISCUSSION

The initial purpose of ACDA is to preserve segmental motion close to the physiological kinematics of the cervical spine after discectomy. However, HO is a phenomenon that is observed with varying reported incidences after implanting a cervical prosthesis. In the current article it was demonstrated that the HO was present in the vast majority of patients 2 years after surgery and that the occurrence of severe HO was present in almost half of the patients. The phenomenon was independent of the type of implant used. However, the occurrence of HO had no detrimental influence on clinical outcome.

A difference in architecture between the Bryan and the activC prosthesis is the presence of a keel in the activC prosthesis. The purpose of a keel is to affirm the prosthesis to the end plate in a solid way. However, a keel violates the cortical surface of the end plate and this can hypothetically result in overgrowth of bone, and thus in HO.¹⁵ However, in the present study, the presence or absence of a keel did apparently not influence the formation and progression of HO.

Although the ROM of the total cervical spine was larger in the Bryan prosthesis group, this did not affect clinical outcome. A larger ROM in the Bryan prosthesis group may (partially) be explained by the lower proportion of patients with severe HO in the Bryan group. The absence of a correlation between a ROM and clinical condition corresponds with our previous result demonstrating that there is no correlation between ROM and clinical outcome after cervical discectomy.³⁵

A limitation of the current study may be that determining ROM on x-ray is dependent on the ability and willingness of the patients to reach full flexion and extension of the cervical spine. The inability to demonstrate full flexion/extension may be due to neck pain. It was evaluated whether there was an association between neck pain and limited range of motion of the cervical spine, but this appeared to be absent. Another limitation may be that HO is suboptimally evaluated on x-ray. Yi *et al*²⁰ evaluated CT-scans after implanting prosthesis in addition to x-rays and found that severe HO allowed segmental motion, while mild HO could have no

motion in some case. They proposed to also evaluate CT anteroposterior views to properly evaluate HO. This may be the best evaluation method to judge HO. However, in order to study the preservation of motion, which is the primary goal of implanting a prosthesis, evaluating dynamic x-rays is indispensable. On the other hand, since clinical outcome is not related to HO, the necessity to evaluate the occurrence of HO is questionable. This could be an argument to obtain radiographs only in case of clinical relevant complaints of the patient.

CONCLUSION

The development of HO is present in the vast majority of patients receiving a prosthesis. In comparison of two cervical disc prostheses the development of HO is independent on their architecture. The presence of HO did not influence clinical outcome.

Key Points

- ❑ In comparison of two cervical disc prostheses the development of HO is independent on their architecture.
- ❑ ROM of the total spine was higher in the Bryan prosthesis group than that in the activC prosthesis group.
- ❑ The clinical condition of patients with and without severe HO was comparable.

References

1. Smith GW, Robinson RA. The treatment of certain cervical-spine disorders by anterior removal of the intervertebral disc and interbody fusion. *J Bone Joint Surg Am* 1958;40-A:607–24.
2. Bartels R, Goffin J. Albert Dereymaeker and Joseph Cyriel Mulier's description of anterior cervical discectomy with fusion in 1955. *J Neurosurg Spine* 2018;28:395–400.
3. Cloward RB. The anterior approach for removal of ruptured cervical disks. *J Neurosurg* 1958;15:602–17.
4. Goffin J, Geusens E, Vantomme N, et al. Long-term follow-up after interbody fusion of the cervical spine. *J Spinal Disord Tech* 2004;17:79–85.
5. Janssen ME, Zigler JE, Spivak JM, et al. ProDisc-C total disc replacement versus anterior cervical discectomy and fusion for single-level symptomatic cervical disc disease: seven-year follow-up of the prospective randomized U.S. Food and Drug Administration Investigational Device Exemption Study. *J Bone Joint Surg Am* 2015;97:1738–47.
6. Park JH, Roh KH, Cho JY, et al. Comparative analysis of cervical arthroplasty using mobi-c(r) and anterior cervical discectomy and fusion using the solis(r) -cage. *J Korean Neurosurg Soc* 2008;44: 217–21.
7. Hou Y, Nie L, Pan X, et al. Effectiveness and safety of Mobi-C for treatment of single-level cervical disc spondylosis: a randomised control trial with a minimum of five years of follow-up. *Bone Joint J* 2016;98-B:829–33.
8. Zhang H-X, Shao Y-D, Chen Y, et al. A prospective, randomised, controlled multicentre study comparing cervical disc replacement with anterior cervical decompression and fusion. *Int Orthop* 2014;38:2533–41.

9. Coric D, Kim PK, Clemente JD, et al. Prospective randomized study of cervical arthroplasty and anterior cervical discectomy and fusion with long-term follow-up: results in 74 patients from a single site. *J Neurosurg Spine* 2013;18:36–42.
10. Parkinson JF, Sekhon LH. Cervical arthroplasty complicated by delayed spontaneous fusion. Case report. *J Neurosurg Spine* 2005;2:377–80.
11. Bartels RH, Donk R. Fusion around cervical disc prosthesis: case report. *Neurosurgery* 2005;57:E194; discussion E.
12. McAfee PC, Cunningham BW, Devine J, et al. Classification of heterotopic ossification (HO) in artificial disk replacement. *J Spinal Disord Tech* 2003;16:384–9.
13. Mehren C, Suchomel P, Grochulla F, et al. Heterotopic ossification in total cervical artificial disc replacement. *Spine (Phila Pa 1976)* 2006;31:2802–6.
14. Heidecke V, Burkert W, Brucke M, et al. Intervertebral disc replacement for cervical degenerative disease—clinical results and functional outcome at two years in patients implanted with the Bryan cervical disc prosthesis. *Acta Neurochir (Wien)* 2008;150:453–9; discussion 459.
15. Yi S, Kim KN, Yang MS, et al. Difference in occurrence of heterotopic ossification according to prosthesis type in the cervical artificial disc replacement. *Spine (Phila Pa 1976)* 2010;35:1556–61.
16. Leung C, Casey AT, Goffin J, et al. Clinical significance of heterotopic ossification in cervical disc replacement: a prospective multicenter clinical trial. *Neurosurgery* 2005;57:759–63; discussion 759–63.
17. Pimenta L, Oliveira L, Coutinho E, et al. Bone formation in cervical total disk replacement (CTDR) up to the 6-year follow-up: experience from 272 levels. *Neurosurg Q* 2013;23:1–6.
18. Suchomel P, Jurak L, Benes V 3rd, et al. Clinical results and development of heterotopic ossification in total cervical disc replacement during a 4-year follow-up. *Eur Spine J* 2010;19: 307–15.
19. Park JH, Rhim SC, Roh SW. Mid-term follow-up of clinical and radiologic outcomes in cervical total disk replacement (Mobi-C): incidence of heterotopic ossification and risk factors. *J Spinal Disord Tech* 2013;26:141–5.
20. Yi S, Oh J, Choi G, et al. The fate of heterotopic ossification associated with cervical artificial disc replacement. *Spine (Phila Pa 1976)* 2014;39:2078–83.
21. Zeng J, Liu H, Chen H, et al. Comparison of heterotopic ossification after fixed- and mobile-core cervical disc arthroplasty. *World Neurosurg* 2018;120:e1319–24.
22. Tu TH, Wu JC, Huang WC, et al. Heterotopic ossification after cervical total disc replacement: determination by CT and effects on clinical outcomes. *J Neurosurg Spine* 2011;14:457–65.
23. Zhou HH, Qu Y, Dong RP, et al. Does heterotopic ossification affect the outcomes of cervical total disc replacement? A meta-analysis. *Spine (Phila Pa 1976)* 2015;40:E332–40.
24. Sundseth J, Jacobsen EA, Kolstad F, et al. Heterotopic ossification and clinical outcome in nonconstrained cervical arthroplasty 2 years after surgery: the Norwegian Cervical Arthroplasty Trial (NORCAT). *Eur Spine J* 2016;25:2271–8.
25. Arts MP, Brand R, van den Akker E, et al. The NETHERlands Cervical Kinematics (NECK) trial. Cost-effectiveness of anterior cervical discectomy with or without interbody fusion and arthroplasty in the treatment of cervical disc herniation; a double-blind randomised multicenter study. *BMC Musculoskelet Disord* 2010;11:122.
26. Bartels RH, Donk R, van der Wilt GJ, et al. Design of the PROCON trial: a prospective, randomized multi-center study comparing cervical anterior discectomy without fusion, with fusion or with arthroplasty. *BMC Musculoskelet Disord* 2006;7:85.
27. Vleggeert-Lankamp CLA, Janssen TMH, van Zwet E, et al. The NECK trial: effectiveness of anterior cervical discectomy with or without interbody fusion and arthroplasty in the treatment of cervical disc herniation; a double-blinded randomized controlled trial. *Spine J* 2019;19:965–75.
28. Goffin J, Casey A, Kehr P, et al. Preliminary clinical experience with the Bryan Cervical Disc Prosthesis. *Neurosurgery* 2002;51:840–5; discussion 5–7.
29. Anderson PA, Sasso RC, Rouleau JP, et al. The Bryan Cervical Disc: wear properties and early clinical results. *Spine J* 2004;4: 303S–9S.
30. Vernon H, Mior S. The Neck Disability Index: a study of reliability and validity. *J Manipulative Physiol Ther* 1991;14:409–15.
31. Vos CJ, Verhagen AP, Koes BW. Reliability and responsiveness of the Dutch version of the Neck Disability Index in patients with acute neck pain in general practice. *Eur Spine J* 2006;15:1729–36.
32. Pietrobon R, Coeytaux RR, Carey TS, et al. Standard scales for measurement of functional outcome for cervical pain or dysfunction: a systematic review. *Spine (Phila Pa 1976)* 2002;27:515–22.
33. Walraevens J, Demaerel P, Suetens P, et al. Longitudinal prospective long-term radiographic follow-up after treatment of single-level cervical disk disease with the Bryan Cervical Disc. *Neurosurgery* 2010;67:679–87; discussion 687.
34. Cobb J. Outline for the study of scoliosis. *Am Acad Orthop Surg Instr Course Lect* 1948;5:261–75.
35. Yang X, Donk R, Arts MP, et al. Maintaining range of motion after cervical discectomy does not prevent adjacent segment degeneration. *Spine J* 2019;19:1816–23.