



Universiteit
Leiden
The Netherlands

The phenotypic spectrum of PNKP-associated disease and the absence of immunodeficiency and cancer predisposition in a Dutch cohort

Garrelfs, M.R.; Takada, S.; Kamsteeg, E.J.; Pegge, S.; Mancini, G.; Engelen, M.; ... ; Willemsen, M.A.

Citation

Garrelfs, M. R., Takada, S., Kamsteeg, E. J., Pegge, S., Mancini, G., Engelen, M., ... Willemsen, M. A. (2020). The phenotypic spectrum of PNKP-associated disease and the absence of immunodeficiency and cancer predisposition in a Dutch cohort. *Pediatric Neurology*, 113, 26-32. doi:10.1016/j.pediatrneurol.2020.07.014

Version: Publisher's Version

License: [Creative Commons CC BY 4.0 license](https://creativecommons.org/licenses/by/4.0/)

Downloaded from: <https://hdl.handle.net/1887/3185319>

Note: To cite this publication please use the final published version (if applicable).



Original Article

The Phenotypic Spectrum of *PNKP*-Associated Disease and the Absence of Immunodeficiency and Cancer Predisposition in a Dutch Cohort



Mark R. Garrelfs, MD ^{a,*}, Sanami Takada, MD, PhD ^b, Erik-Jan Kamsteeg, PhD ^c, Sjoert Pegge, MD, PhD ^d, Grazia Mancini, MD, PhD ^e, Marc Engelen, MD, PhD ^f, Bart van de Warrenburg, MD, PhD ^g, Alexander Rennings, MD, PhD ^h, Judith van Gaalen, MD, PhD ^g, Ivo Peters, MD ^g, Corry Weemaes, MD, PhD ^a, Mirjam van der Burg, PhD ^b, Michèl A. Willemsen, MD, PhD ^{a,i}

^a Department of Pediatrics, Radboud University Medical Center, Nijmegen, the Netherlands

^b Laboratory for Immunology, Department of Pediatrics, Leiden University Medical Center, Leiden, the Netherlands

^c Department of Human Genetics, Radboud University Medical Center, Nijmegen, the Netherlands

^d Department of Radiology, Radboud University Medical Center, Nijmegen, the Netherlands

^e Department of Clinical Genetics, Erasmus University Medical Center, Rotterdam, the Netherlands

^f Department of Pediatric Neurology, Amsterdam University Medical Center, Amsterdam, the Netherlands

^g Department of Neurology, Donders Institute for Brain, Cognition, and Behaviour, Nijmegen, the Netherlands

^h Department of Internal Medicine, Radboud University Medical Center, Nijmegen, the Netherlands

ⁱ Department of Pediatric Neurology, Radboud University Medical Center, Amalia Children's Hospital and Donders Institute for Brain, Cognition and Behavior, Nijmegen, the Netherlands

ARTICLE INFO

Article history:

Received 5 May 2020

Accepted 23 July 2020

Available online 28 July 2020

Keywords:

PNKP Polynucleotide kinase 3'-phosphatase

AOA4 ataxia with oculomotor apraxia type 4

MCSZ microcephaly, seizures and

developmental delay

DNA repair

Immunodeficiency

ABSTRACT

Background: We aimed to expand the number of currently known pathogenic *PNKP* mutations, to study the phenotypic spectrum, including radiological characteristics and genotype-phenotype correlations, and to assess whether immunodeficiency and increased cancer risk are part of the DNA repair disorder caused by mutations in the *PNKP* gene.

Methods: We evaluated nine patients with *PNKP* mutations. A neurological history and examination was obtained. All patients had undergone neuroimaging and genetic testing as part of the prior diagnostic process. Laboratory measurements included potential biomarkers, and, in the context of a DNA repair disorder, we performed a detailed immunologic evaluation, including B cell repertoire analysis.

Results: We identified three new mutations in the *PNKP* gene and confirm the phenotypic spectrum of *PNKP*-associated disease, ranging from microcephaly, seizures, and developmental delay to ataxia with oculomotor apraxia type 4. Irrespective of the phenotype, alpha-fetoprotein is a biochemical marker and increases with age and progression of the disease. On neuroimaging, (progressive) cerebellar atrophy was a universal feature. No clinical signs of immunodeficiency were present, and immunologic assessment was unremarkable. One patient developed cancer, but this was attributed to a concurrent von Hippel-Lindau mutation.

Conclusions: Immunodeficiency and cancer predisposition do not appear to be part of *PNKP*-associated disease, contrasting many other DNA repair disorders. Furthermore, our study illustrates that the previously described syndromes microcephaly, seizures, and developmental delay, and ataxia with oculomotor apraxia type 4, represent the extremes of an overlapping spectrum of disease. Cerebellar atrophy

Statistical analysis: Statistical analysis was conducted by Sanami Takada, affiliated with the Leiden University Medical Center, The Netherlands.

Financial disclosures: This research received no specific grant from any funding agency, commercial or not-for-profit sectors.

Conflicts of interest: None.

Informed consent: Informed consent was obtained from all individual participants, or their parents, included in the study.

Disclosure statement: Mark Garrelfs reports no disclosures. Sanami Takada reports no disclosures. Erik-Jan Kamsteeg reports no disclosures. Sjoert Pegge reports no disclosures. Grazia Mancini reports no disclosures. Marc Engelen reports no disclosures. Bart van de Warrenburg reports research grants from Radboud University Medical Center, ZonMW, Hersenstichting, Gossweiler Foundation, and uniQure. Alexander Rennings reports no disclosures. Judith van Gaalen reports no disclosures. Ivo Peters reports no disclosures. Corry Weemaes reports no disclosures. Mirjam van der Burg reports no disclosures. Michèl Willemsen reports no disclosures.

* Communications should be addressed to: Dr. Garrelfs; Department of Pediatrics; Radboud University Medical Centre; PO box 9101; 6500 HB, Nijmegen, the Netherlands.

E-mail addresses: m.r.garrelfs@amsterdamumc.nl, m.r.garrelfs@amsterdamumc.nl (M.R. Garrelfs).

and elevated serum alpha-fetoprotein levels are early diagnostic findings across the entire phenotypical spectrum.

© 2020 The Author(s). Published by Elsevier Inc. This is an open access article under the CC BY license (<http://creativecommons.org/licenses/by/4.0/>).

Introduction

DNA repair disorders are a heterogeneous group of disorders with several common features, including neurodegeneration, immunodeficiency, premature aging, and cancer predisposition.¹ Polynucleotide kinase 3'-phosphatase (*PNKP*) is an enzyme that plays a crucial role in DNA repair. Mutations in the *PNKP* gene result in a DNA repair disorder that is associated with a spectrum of neurodevelopmental disorders ranging from "microcephaly, seizures, and developmental delay" (MCSZ) to "ataxia with oculomotor apraxia type 4" (AOA4).^{2,3}

Immunodeficiency can be associated with DNA repair disorders because DNA repair is essential for the development of antigen receptors expressed on B and T lymphocytes. To date, the clinical signs of immunodeficiency have not been described in patients with *PNKP* mutations, but studies that systematically assess the immune system are lacking. Here, we studied the naive and antigen-selected B cell antigen receptor (BCR) repertoire to reveal potential defects in immune repertoire formation, V(D)J recombination, or specification (somatic hypermutation, subclass distribution, or selection).

In this article we report new *PNKP* mutations, describe the results of immunologic testing, and discuss genotype-phenotype correlations, radiological findings, potential biomarkers, and cancer occurrence in a cohort of nine Dutch patients with *PNKP*-associated disease.

Methods

Participants and clinical information

Nine patients participated in the study through attendance at our outpatient department at the Radboud University Medical Center, Nijmegen, The Netherlands. All patients had been diagnosed using whole-exome or Sanger sequencing. A detailed history and neurological examination were taken, and laboratory evaluation was performed.

Standard protocol, approvals, and patient consents

This study was approved by the Committee Human Research Region Arnhem-Nijmegen (file number 2017-4016). Written informed consent was obtained from each participant or, if younger than 16 years, the parents before enrolment in the study.

Neuroradiology

Neuroimaging studies had been performed in all patients as part of the initial diagnostic evaluation and were systematically reviewed in the context of the present study.

Immunology

Immunologic investigations included full blood count, leukocyte differentiation, immunoglobulin levels, immunophenotyping, and BCR repertoire analysis.

B cell receptor repertoire analysis

Peripheral blood was drawn from the patients and healthy volunteers. Peripheral blood mononuclear cells (PBMCs) were isolated by using Ficoll (Apotheek AZL, Leiden, The Netherlands).

For the analysis of the naive BCR repertoire, genomic DNA was extracted from PBMCs by using the GenElute Mammalian Genomic DNA miniprep kit (Sigma-Aldrich, St. Louis, MO). DNA was subsequently subjected to polymerase chain reaction (PCR) amplification with the forward VH1-6 FR1 and reverse JH consensus BIOMED-2 primers for immunoglobulin heavy chain (IGH) rearrangements and sequenced using Illumina Miseq sequencing as previously described.^{4,5} PCR products were purified by MinElute gel extraction Kit (Qiagen, Valencia, CA) and Agencourt AMPure XP beads (Beckman Coulter, Fullerton, CA). The concentration of the PCR product was measured using the Qubit dsDNA HS Assay Kit (Thermo Fisher Scientific, Waltham, MA). The purified PCR products were ligated with index adapters for sequencing and sequenced on the Illumina Miseq with a Miseq v3 600 cycles kit (Illumina, San Diego, CA) using a 300-bp paired-end sequencing run according to the manufacturer's instructions.

For the analysis of the antigen-selected BCR repertoire, RNA was extracted from PBMCs using the GenElute mammalian total RNA miniprep kit (Sigma-Aldrich, St. Louis, MO) and subjected to reverse transcription with a SuperScript II Reverse Transcriptase (Thermo Fisher Scientific) using random primers. cDNA was amplified using VH1-6 FR1 forward primers and either the CgCH or the IGHA reverse primer.^{6,7} The product was purified and sequenced as described earlier. Sequences were demultiplexed based on their multiplex identifier sequence, and 40 nucleotides were trimmed from both sides to remove the primer sequence using the demultiplex tool. FASTA files were analyzed in IMG/HighV-QUEST (selection of IMG reference directory set: F+ORF+in-frame P with all alleles; search for insertions and deletions: yes; parameters for IMG/Junction Analysis: default).⁸ Subsequently, the IMG/HighV-QUEST output files were analyzed in the immune repertoire pipeline and/or the somatic hypermutations (SHM) and class switch recombination (CSR) pipeline from ARGalaxy (<https://bioinf-galaxian.erasmusmc.nl/argalaxy/>).⁵

To evaluate the selection of the antigen-experienced repertoire, we analyzed the replacement (R) and silent (S) mutations in the variable domain of the IGH gene. The R/S ratio in the complementarity-determining regions measures antigen binding affinity, and the R/S ratio in framework regions measures antibody stability.⁹

Data availability

All data generated in the study are presented in the current article.

Results

Genotype

We identified five different *PNKP* mutations in nine patients from six families (Table 1). The previously described c.1253_1269dup

mutation was present in eight patients and homozygous in three of them (Patients 2, 3, and 5). The patients in the same family (Patients 6 to 9) were compound heterozygous for the c.1253_1269dup mutation and a novel c.1189-17_1206del mutation. Patient 1 is compound heterozygous for the known c.1386+49_1387-33del mutation and a novel c.968C>T mutation. Lastly, one patient (Patient 4) was compound heterozygous for the c.1253_1269dup mutation and a novel c.1299-1G>T mutation.

Patient 6 developed a cerebellar hemangioblastoma and was found to have a concurrent mosaic frameshift mutation in the *von Hippel-Lindau (VHL)* gene, c.607_608del.

Neurological phenotype

Clinical characteristics of the patients are described in Table 1. Age at onset of neurological symptoms ranged from birth until eight years. Presenting symptoms were either progressive microcephaly (five of nine) or gait disturbances due to ataxia (four of nine). All patients had developed ataxia at their first visit to our outpatient department. Clinical signs of a polyneuropathy were present in all but one patient (Patient 1). All patients with microcephaly had epilepsy and global developmental delay with subsequent progressive cognitive decline. Although no formal psychometric testing was performed, based on the observation that the patients with an AOA4 phenotype went to regular secondary schools and finished a professional degree thereafter, we concluded that no intellectual impairment was present in these patients. Age at onset of epilepsy ranged from four months to four years. The epilepsy phenotype during infancy mainly consisted of abnormal eye movements, unresponsiveness, hypotonia and apneas, and advanced to tonic-clonic seizures in all patients. Epilepsy was

managed with conventional antiepileptic drugs (e.g., levetiracetam, valproate, oxcarbazepine, and lamotrigine) in all patients, except for Patient 1. Patient 1 reached a 50% reduction of seizures after starting a ketogenic diet in combination with oxcarbazepine, lamotrigine, and clobazam. Electroencephalographic data are not available. Eight patients learned to walk without assistance, but six had already lost this skill due to progressive ataxia and polyneuropathy at their first outpatient visit in our center. In the four patients from the same family, ataxia was the presenting symptom. Age of onset ranged from seven to 14 years. Chorea was noted in three patients (Patients 6 to 8) but diminished over time and had disappeared at ages 21 and 22 in Patients 7 and 8, respectively. Oculomotor apraxia was present in five patients, of whom one had microcephaly.

Neuroradiology

Brain magnetic resonance imaging (MRI) was available for all patients and unambiguously showed cerebellar atrophy, which proved to be progressive in patients who had a follow-up scan available. Patients had unremarkable white matter myelination and normal basal ganglia. In patients with microcephaly, a simplified gyral pattern was present, and a thin corpus callosum was noted in four patients. Representative magnetic resonance images are presented in Fig 1, and a detailed description of all available magnetic resonance images is provided in Supplemental Table 1.

Biochemistry

Laboratory evaluation, performed at the first visit to our outpatient department, revealed an elevated serum alpha-fetoprotein

TABLE 1.
Patient Characteristics and Genotype

Patient	1	2	3	4	5	6-9 (Same Family)
Age at evaluation	7 years	4 years	11 years	7 years	17 years	18–29 years
Genotype	Heterozygous*; c.968C>T (p.(Thr323Met)) c.1386+49_1387-33del (p.(Arg433 fs))	Homozygous; c.1253_1269dup (p.(Thr424fs))	Homozygous; c.1253_1269dup (p.(Thr424fs))	Heterozygous*; c.1253_1269dup (p.(Thr424fs)) c.1299-1G>T (r.spl)	Homozygous; c.1253_1269dup (p.(Thr424fs))	Heterozygous*; c.1189-17_1206del (r.spl?) c.1253_1269dup (p.(Thr424fs))
Phenotype	MCSZ	MCSZ	MCSZ	MCSZ	MCSZ	AOA4
Microcephaly	31.5 cm (–2.8)/42.6 cm (–5.4)	36 cm (–2.4)†/43 cm (–4.7)	31 cm (–3.5)/46.2 cm (–4.3)	31.5 cm (–4)/41.7 cm (–5.7)	30 cm (–4.2)/48.5 cm (–4.4)	Not present
Birth/Present (SDs)						
ID	+	+	+	+	+	–
Motor Development	Delayed; regression with loss of motor skills	Delayed; regression with loss of motor skills	Delayed; regression with loss of motor skills	Delayed; regression with loss of motor skills	Delayed; regression with loss of motor skills	Normal milestones
Age in Wheelchair	Never learnt how to walk	2 years	7 years	Able to walk short distances	15 years	17–19 years
Epilepsy	5 months	4 months	11 months	5 months	4 years	Not present
Ataxia	+	+	+	+	+	+
Polyneuropathy	+	+	+	+	+	+
Oculomotor Apraxia	–	–	–	–	+	+
Immunodeficiency	–	–	–	–	–	–
Other	–	Unilateral mixed hearing loss	–	Celiac disease, heterozygous mutation in LDL receptor	–	Patient 6: cerebellar hemangioblastoma Patients 6–8: chorea Patients 7–9: lower-extremity edema

Abbreviations:

+ = Present

– = Not present

ID = Intellectual disability

LDL = Low-density lipoprotein

* Compound heterozygous.

† Age 2 months.

(AFP) level in all except one patient (Patient 1). All patients with elevated serum AFP levels had hypoalbuminemia. Cross-sectional analysis of the data suggests that serum AFP appears to increase, whereas serum albumin appears to decrease with age (Fig 2). We found a Pearson correlation coefficient of 0.754 ($P = 0.019$) between the AFP/albumin ratio and age. Of the eight patients with hypoalbuminemia, three developed peripheral edema of the lower extremities. Analysis of the lipid profile revealed increased total cholesterol levels in Patients 4 (cholesterol 7.0 mmol/L; upper limit of normal (ULN) 5.2 mmol/L), 7 (cholesterol 7.0 mmol/L; ULN 6.5 mmol/L), and 9 (cholesterol 8.5 mmol/L; ULN 6.5 mmol/L). Patient 4 was the only patient with an MCSZ phenotype and aged less than 18 years with hypercholesterolemia, but was found to have a concurrent familial heterozygous mutation in the low-density lipoprotein receptor gene.

Immunology

Several DNA repair mechanisms, double-strand break repair (DSBR) in particular, are required for the normal development of antigen receptors expressed on B and T lymphocytes.¹⁰

Defective DNA repair can result in varying degrees of a combined B and T cell immunodeficiency. First-tier immunologic investigations in patients with DNA repair disorders should therefore include a complete blood count, immunoglobulin measurements, IgG subclasses, and immunophenotyping. Testing for specific

pneumococcal polysaccharide antibody deficiency should also be included, as this is a known feature of several DNA repair disorders.¹⁰ Due to practical limitations, we did not perform analysis for specific pneumococcal polysaccharide antibody deficiency in the current study.

Combined B and T cell immunodeficiency is associated with recurrent, prolonged, and severe infections with both intra- and extracellular microorganisms. Clinical signs of immunodeficiency were neither observed nor reported in any of the patients. Results of first-tier immunologic assessment are shown in Table 2 and were considered unremarkable.

For research purposes, we performed analysis of the BCR repertoire to determine subclinical involvement of the immune system in patients with *PNKP* deficiency.

B cell receptor repertoire analysis

We first analyzed the naive BCR repertoire using next-generation sequencing of functional IGH gene rearrangements in both controls and *PNKP*-deficient patients. The IGH junction characteristics (i.e., number of nucleotide deletions, N nucleotides, and P nucleotides) of the *PNKP*-deficient patients did not differ from those of the healthy controls (Supplemental Figure 1A, B). Furthermore, the complementarity-determining region 3 length was not affected in *PNKP* deficiency (Supplemental Figure 1B). Subsequently, we analyzed the antigen-selected repertoire of IGA

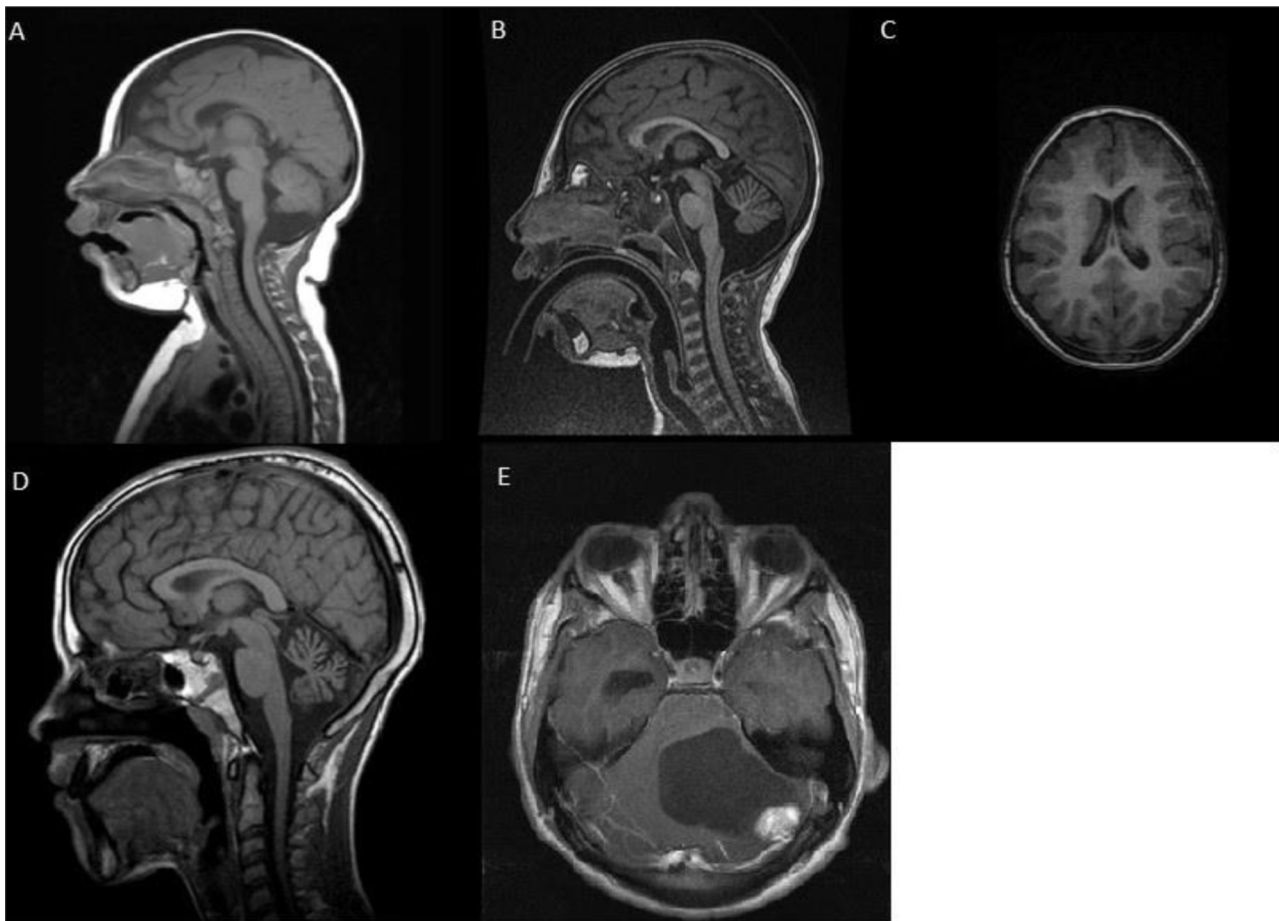


FIGURE 1. Representative magnetic resonance images. (A and B) Sagittal T1 of Patient 4 at five months (A) and three years (B) showing the development of cerebellar atrophy. (C) Transversal T1 of Patient 4 at three years showing microcephaly with a simplified gyral pattern. (D) Sagittal T1 of Patient 8 at 13 years showing cerebellar atrophy. (E) Transversal T1 of Patient 6 at 17 years showing a cerebellar hemangioblastoma.

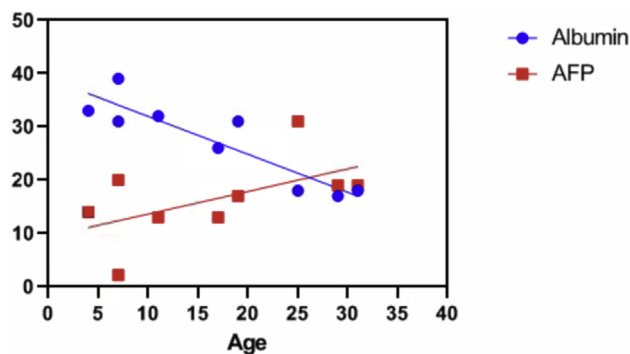


FIGURE 2. Relationship between AFP, albumin, and age. The graph represents a cross-sectional analysis. The dots and squares each represent a measurement from a single patient, taken at one point in time (visit at the outpatient department). Albumin in g/L, AFP in alpha-fetoprotein in µg/L. Measurements: included for your convenience (should not be included in the end product). The color version of this figure is available in the online edition.

	Units	Reference Values	Patient 1	Patient 2	Patient 3	Patient 4	Patient 5	Patient 6	Patient 7	Patient 8	Patient 9
Alpha-fetoprotein	µg/L	<7	2.2	14	13	20	13	17	31	19	19
Albumin	g/L	35–50	39	33	32	31	26	31	18	17	18

and IGG transcripts for the presence and selection of SHM in switched memory B cells. No significant difference in the percentage of SHM was found between patients and controls (Supplemental Figure 2A). Neither did *PNKP* mutations seem to affect selection of the antigen-experienced repertoire (Supplemental Figure 2B).

Malignancy

Except for Patient 6, who developed a cerebellar hemangioblastoma due to a concurrent (mosaic) *VHL* mutation, no malignancies were encountered in this study cohort.

Discussion

The protein *PNKP* is a DNA repair factor possessing both 5'-kinase and 3'-phosphatase activities to modify the ends of a DNA break before ligation.¹¹ Besides its role in both single-strand break repair (SSBR) and DSB, *PNKP* is crucial for normal neurogenesis and also fulfills important genome maintenance functions after its completion.¹¹ Although genome maintenance is critical for all cells, neurons seem particularly sensitive to mutations in DNA repair genes.¹²

Genetics

The *PNKP* gene is located on the long arm of chromosome 19 at position 13.33 (19q13.33). We identified five different mutations of which three have not been previously reported.

The novel c.1299-1G>T and c.1189-17_1206del mutations are likely pathogenic because they affect canonical splice sites. The predicted effects are exon 15 skipping for c.1299-1G>T, whereas the deletion of intron 13 acceptor splice site (c.1189-17_1206del) may result in skipping of exon 14, or the use of a weaker acceptor splice site formed by the deletion and subsequent in-frame deletion of seven amino acids. The c.968C>T mutation leads to the substitution of a methionine for a threonine p.(Thr323Met) that is conserved in orthologs in all species down to *C. elegans*. This variant is present in control databases (gnomAD) in very low frequencies (one in 5000 individuals of European ancestry) only. These data suggest that this variant is pathogenic.

Patient 6 was found to have a concurrent mosaic frameshift mutation in the *VHL* gene, c.607_608del (p.(Gln203 fs)), which is

associated with hemangioblastoma. The mutation was present in 5% to 8% reads in peripheral blood and 30% reads in the tumor. MRI screening of other organs showed two small pancreatic cysts and two contrast-enhanced lesions in the spinal cord, which require follow-up. To date, none of the other patients has developed a malignancy.

Phenotype

Historically, mutations in the *PNKP* gene have been associated with two distinct clinical syndromes; MCSZ and AOA4. MCSZ comprises microcephaly, early-onset intractable seizures and a developmental delay, and variable signs of neurodegeneration, ataxia, polyneuropathy, or oculomotor apraxia. AOA4 is characterized by progressive (cerebellar) ataxia, oculomotor apraxia, and axonal polyneuropathy without microcephaly or epilepsy. Intellectual disability is not apparent in patients with AOA4 in contrast to patients with the MCSZ phenotype. However, the observed overlapping features suggest a spectrum of disease rather than distinct clinical entities.

These findings are supported by several other reports in the literature.¹³ Previously, our group described two brothers with *PNKP* mutations causing a phenotype consisting of progressive microcephaly, developmental delay, epilepsy, progressive ataxia, progressive neuropathy, and oculomotor apraxia. Both patients died in the third decade due to the consequences of end-stage neurodegenerative disease. No clinical signs of immunodeficiency were present, and they did not develop cancer.¹⁴ More recently, a report was published describing two unrelated patients with a phenotype resembling MCSZ but including oculomotor apraxia.¹⁵ Patients with the AOA4 phenotype without oculomotor apraxia have also been described.¹⁶ Last, an Iranian cohort demonstrated patients with an MCSZ phenotype without seizures.¹⁷ The phenotypical spectrum of *PNKP*-associated disease has broadened over recent years. Patients with clinical syndromes that are dominated by chorea, peripheral neuropathy, and dystonia have been reported.^{3,18,19}

The diverse role of *PNKP* in both SSBR and DSB, neurogenesis, and genome maintenance might explain the presence of both microcephaly and neurodegeneration.²⁰ This does not, however, explain the difference in phenotype between patients harboring identical *PNKP* mutations. Patients from the same family appear to have a similar phenotype, suggesting other genetic modifiers

TABLE 2.
White Cell Count, Immunophenotyping, and Immunoglobulin Levels

Measurement	Reference*	Patient 1	Patient 2	Patient 3	Patient 4	Patient 5	Patient 6	Patient 7	Patient 8	Patient 9
Neutrophils	2.00-7.50	2.12	2.84	2.46	2.58	2.6	3.92	4.02	8.91	3.47
Monocytes	0.30-1.00	0.39	0.48	0.37	0.51	0.57	0.33	0.41	0.8	0.33
Eosinophils	<0.50	0.05	0.03	0.05	0.05	0.22	0.05	0.04	0.19	0.08
Basophils	<0.10	0.02	0.02	0.04	0.02	0.03	0.01	0.01	0.05	0.02
Leukocytes (CD45)	4.0-11.0	4.46	7.74	5.1	5.93	6.1	6	6	12.5	5.71
Lymphocytes (CD45)	1.0-2.8	1.88 (1.10-5.90)	4.37 (1.70-6.90)	2.09 (1.00-5.30)	2.77 (1.10-5.90)	2.2 (1.8-2.8)	1.1	1.8	2.55	1.81 (1.00-2.80)
T lymphocytes (CD3)	0.7-2.1	1.50 (0.7-4.2)	3.30 (0.9-4.5)	1.50 (0.8-3.5)	1.90 (0.7-4.2)	1.35 (0.7-2.1)	0.643	0.956	1.90	1.00 (0.7-2.1)
CD4+ in CD3	0.3-1.4	0.82 (0.3-2)	2.05 (0.5-2.4)	0.69 (0.4-2.1)	1.10 (0.3-2)	0.93 (0.3-1.4)	0.34	0.63	0.95	0.63 (0.3-1.4)
CD8+ in CD3	0.2-0.9	0.53 (0.3-1.8)	1.02 (0.3-1.6)	0.56 (0.2-1.2)	0.47 (0.3-1.8)	0.353 (0.2-0.9)	0.201	0.327	0.66	0.34 (0.2-0.9)
CD4/CD8 Ratio in CD3		1.57	2.00	1.24	2.32	2.6	1.7	1.9	1.44	1.85
B Lymphocytes (CD19)	0.1-0.5	0.33 (0.2-1.6)	0.67 (0.2-2.1)	0.24 (0.2-0.6)	0.47 (0.2-1.6)	0.372 (0.1-0.5)	0.272	0.407	0.25	0.20 (0.1-0.5)
NK Lymphocytes (CD3-CD16.56+)	0.09-0.6	0.08 (0.09-0.9)	0.22 (0.1-1)	0.15 (0.07-1.2)	0.11 (0.09-0.9)	0.318 (0.09-0.6)	0.15	0.259	0.35	0.33 (0.09-0.6)
IgG	7.00-16.00	8.52 (5.20-12.90)	6.04 (4.40-13.40)	6.77 (6.30-15.20)	8.99 (5.20-12.90)	7.54 (7.00-16.00)	9.94	10.5	8.96	7.12
IgA	0.70-4.00	2.21 (0.42-2.18)	1.44 (0.26-1.17)	0.83 (0.70-2.65)	0.93 (0.42-2.18)	1.18 (0.70-4.00)	1.8	1.22	2.56	1.18
IgM	0.40-2.30	0.91 (0.48-2.09)	1.24 (0.40-1.60)	1.85 (0.53-1.58)	0.51 (0.48-2.09)	0.48 (0.40-2.30)	1.47	0.9	1.18	1.17
Subclass IgG1	4.90-11.40	7.37 (4.00-10.80)	5.45 (3.50-9.40)	6.23 (4.00-11.50)	8.19 (4.00-10.80)	6.19 (3.70-12.80)	7.31	7.36	7.54	5.69
Subclass IgG2	1.50-6.40	0.85 (0.85-4.10)	1.14 (0.63-3.00)	1.05 (0.98-4.80)	1.32 (0.85-4.10)	1.29 (1.06-6.10)	2.4	3.77	1.54	1.12
Subclass IgG3	0.20-1.10	0.19 (0.13-1.42)	0.52 (0.13-1.26)	0.55 (0.15-1.49)	0.36 (0.13-1.42)	0.41 (0.18-1.63)	0.3	0.58	0.27	0.26
Subclass IgG4	0.08-1.40	0.58 (<1.89)	0.34 (<1.27)	0.1 (0.03-2.10)	0.06 (<1.89)	0.42 (0.04-2.30)	0.24	0.46	0.43	0.17

Absolute values are shown. Units of cell counts: $10^9/l$. Units of immunoglobulin levels: g/l.

* Adult reference ranges are shown, age related values can be found in the table.

affecting *PNKP* function. The exact reason for this phenotypic variability remains uncertain.

Another striking finding in three of our patients was lower-extremity edema. This finding was also reported in a Norwegian patient with AOA4.²¹ Hypoalbuminemia in *PNKP*-deficient patients is only mild and therefore not a sufficient explanation for the presence of edema. In these patients, other unknown factors seem to play a role in edema formation.

Neuroradiology

MRI findings are in line with the findings of other authors. Progressive cerebellar atrophy is a constant early feature in all patients across the whole phenotypic spectrum.

Biochemistry

Elevated levels of serum AFP are also seen in other neurodegenerative disorders, notably some of the autosomal recessive cerebellar ataxia. Genes involved in these disorders play a central role in mitochondrial and nuclear DNA maintenance, which is also true for *PNKP*.²²⁻²⁴ Hypoalbuminemia and hypercholesterolemia have previously been described in patients with AOA4.^{21,25} We found a significant correlation between the AFP/albumin ratio and age. The pathophysiology and clinical relevance of these laboratory abnormalities is unclear, although a similar pattern is seen in the related disorder ataxia telangiectasia.²⁶

Immunology

Immunodeficiency can be associated with DNA repair disorders because DNA repair is essential for the development of antigen receptors expressed on B and T lymphocytes. These antigen receptors are formed by recombination of the variable (V), diversity (D), and joining (J) genes (V[D]J recombination). During this process, DNA double-strand breaks are introduced and eventually

ligated via nonhomologous end joining (NHEJ).^{27,28} Further diversification of BCRs continues after antigen encounter by means of SHM and CSR.²⁹ Several DNA repair mechanisms play a role in these processes, including base excision repair, NHEJ, mismatch repair, and alternative-end joining.³⁰ *PNKP* is thought to play a role in at least two of these DNA repair pathways: base excision repair and NHEJ.^{11,31-33}

Deficient NHEJ is associated with (severe) combined immunodeficiency due to a failure to carry out V(D)J recombination and CSR.^{10,31} A reduced number of circulating T and B cells, frequently causing decreased or absent serum immunoglobulins, is encountered in similar conditions.³¹⁻³⁵ Even though clinical observations and first-tier immunologic testing showed no gross deficiencies, we wanted to investigate if the B cell repertoire could still be (mildly) affected due to the above described role of *PNKP* in NHEJ. In contrast to similar disorders that affect NHEJ, we did not find any signs of impaired maturation of the immune system including V[D]J recombination. The exact mechanism behind the seemingly separated function of *PNKP* in several DNA repair pathways remains elusive.

Malignancy

Increased cancer risk is part of some DNA repair disorders. Due to the concurrent (mosaic) VHL mutation, we do not attribute the development of a cerebellar hemangioma in Patient 6 to the *PNKP* mutation. There has been only one report of a patient with a *PNKP* mutation who developed a malignancy (astrocytoma).³⁶ Follow-up studies must determine the actual lifetime risk of cancer development in patients with *PNKP* mutations.

Study limitations

This study has several limitations. First, the number of patients is small. Second, our eldest patient is in his early thirties, which might underestimate cancer risk because, as in the general

population, this risk increases with age. Last, laboratory measurements and analysis were done in a cross-sectional matter. A temporal relationship between findings can therefore not be established with certainty.

Future perspectives

It was recently proposed that the neurodegeneration seen in patients with *PNKP* mutations might be, in part, caused by poly(ADP-ribose) polymerase 1 hyperactivity induced by unrepaired single-strand breaks.³⁷ This potential molecular mechanism triggering neuropathology was identified by researching the XRCC1 protein, which is a scaffold protein that assembles SSBR multi-protein complexes including *PNKP*. XRCC1 mutations are, similar to *PNKP* mutations, associated with oculomotor apraxia, axonal neuropathy, and progressive cerebellar ataxia.³⁷ These findings provide theoretical perspectives for future targeted therapies, for example, poly(ADP-ribose) polymerase 1 inhibitors, to slow the rate of neurodegeneration.

Conclusion

We described a Dutch cohort of nine patients with mutations in the *PNKP* gene, including three new mutations. We noted considerable overlap in phenotype suggesting a spectrum of disease rather than the historically described distinct clinical entities MCSZ and AOA4. Clinically, ataxia was present in all patients and cerebellar atrophy was a universal finding on MRI. Laboratory evaluation revealed a correlation between elevated levels of serum AFP and hypoalbuminemia. No clinical or biochemical signs of immunodeficiency were present, and to date, *PNKP*-associated disease does not appear to increase cancer risk, contrasting other DNA repair disorders.

Supplementary Data

Supplementary data to this article can be found online at <https://doi.org/10.1016/j.pediatrneurol.2020.07.014>.

References

- Keijzers G, Bakula D, Scheibye-Knudsen M. Monogenic diseases of DNA repair. *N Engl J Med*. 2017;377:1868–1876.
- Shen J, Gilmore EC, Marshall CA, et al. Mutations in *PNKP* cause microcephaly, seizures and defects in DNA repair. *Nat Genet*. 2010;42:245–249.
- Bras J, Alonso I, Barbot C, et al. Mutations in *PNKP* cause recessive ataxia with oculomotor apraxia type 4. *Am J Hum Genet*. 2015;96:474–479.
- van Dongen JJ, Langerak AW, Bruggemann M, et al. Design and standardization of PCR primers and protocols for detection of clonal immunoglobulin and T-cell receptor gene recombinations in suspect lymphoproliferations: report of the BIOMED-2 concerted action BMH4-CT98-3936. *Leukemia*. 2003;17:2257–2317.
- Ijspeert H, van Schouwenburg PA, van Zessen D, et al. Antigen receptor galaxy: a user-friendly, web-based tool for analysis and visualization of T and B cell receptor repertoire data. *J Immunol*. 2017;198:4156–4165.
- Tiller T, Meffre E, Yurasov S, et al. Efficient generation of monoclonal antibodies from single human B cells by single cell RT-PCR and expression vector cloning. *J Immunol Methods*. 2008;329:112–124.
- Berkowska MA, Schickel JN, Grosserichter-Wagener C, et al. Circulating human CD27-IgA+ memory B cells recognize bacteria with polyreactive Igs. *J Immunol*. 2015;195:1417–1426.
- Alamyar E, Duroux P, Lefranc MP, et al. IMGT((R)) tools for the nucleotide analysis of immunoglobulin (IG) and T cell receptor (TR) V-(D)-J repertoires, polymorphisms, and IG mutations: IMGT/V-QUEST and IMGT/HighV-QUEST for NGS. *Methods Mol Biol*. 2012;882:569–604.
- Ijspeert H, van Schouwenburg PA, van Zessen D, et al. Evaluation of the antigen-experienced B-cell receptor repertoire in healthy children and adults. *Front Immunol*. 2016;7:410.
- Gennery AR. Primary immunodeficiency syndromes associated with defective DNA double-strand break repair. *Br Med Bull*. 2006;77-78:71–85.
- Shimada M, Dumitrache LC, Russell HR, et al. Polynucleotide kinase-phosphatase enables neurogenesis via multiple DNA repair pathways to maintain genome stability. *EMBO J*. 2015;34:2465–2480.
- McKinnon PJ. DNA repair deficiency and neurological disease. *Nat Rev Neurosci*. 2009;10:100–112.
- Gatti M, Magri S, Nanetti L, et al. From congenital microcephaly to adult onset cerebellar ataxia: distinct and overlapping phenotypes in patients with *PNKP* gene mutations. *Am J Med Genet A*. 2019;179:2277–2283.
- Poulton C, Oegema R, Heijnsman D, et al. Progressive cerebellar atrophy and polyneuropathy: expanding the spectrum of *PNKP* mutations. *Neurogenetics*. 2013;14:43–51.
- Taniguchi-Ikeda M, Morisada N, Inagaki H, et al. Two patients with *PNKP* mutations presenting with microcephaly, seizure, and oculomotor apraxia. *Clin Genet*. 2018;93:931–933.
- Paucar M, Malmgren H, Taylor M, et al. Expanding the ataxia with oculomotor apraxia type 4 phenotype. *Neurol Genet*. 2016;2:e49.
- Entezam M, Razipour M, Talebi S, et al. Multi affected pedigree with congenital microcephaly: WES revealed *PNKP* gene mutation. *Brain Dev*. 2019;41:182–186.
- Caputi C, Tolve M, Galosi S, et al. *PNKP* deficiency mimicking a benign hereditary chorea: the misleading presentation of a neurodegenerative disorder. *Parkinsonism Relat Disord*. 2019;64:342–345.
- Leal A, Bogantes-Ledezma S, Ekici AB, et al. The polynucleotide kinase 3'-phosphatase gene (*PNKP*) is involved in Charcot-Marie-Tooth disease (CMT2B2) previously related to MED25. *Neurogenetics*. 2018;19:215–225.
- Dumitrache LC, McKinnon PJ. Polynucleotide kinase-phosphatase (*PNKP*) mutations and neurologic disease. *Mech Ageing Dev*. 2017;161:121–129.
- Tzoulis C, Sztromwasser P, Johansson S, et al. *PNKP* mutations identified by whole-exome sequencing in a Norwegian patient with sporadic ataxia and edema. *Cerebellum*. 2017;16:272–275.
- Schieving JH, de Vries M, van Vugt JM, et al. Alpha-fetoprotein, a fascinating protein and biomarker in neurology. *Eur J Paediatr Neurol*. 2014;18:243–248.
- Mandal SM, Hegde ML, Chatterjee A, et al. Role of human DNA glycosylase Neil-like 2 (NEIL2) and single strand break repair protein polynucleotide kinase 3'-phosphatase in maintenance of mitochondrial genome. *J Biol Chem*. 2012;287:2819–2829.
- Tahbaz N, Subedi S, Weinfeld M. Role of polynucleotide kinase/phosphatase in mitochondrial DNA repair. *Nucleic Acids Res*. 2012;40:3484–3495.
- Schiess N, Zee DS, Siddiqui KA, et al. Novel *PNKP* mutation in siblings with ataxia-oculomotor apraxia type 4. *J Neurogenet*. 2017;31:23–25.
- Stray-Pedersen A, Borresen-Dale AL, Paus E, et al. Alpha fetoprotein is increasing with age in ataxia-telangiectasia. *Eur J Paediatr Neurol*. 2007;11:375–380.
- Rooney S, Chaudhuri J, Alt FW. The role of the non-homologous end-joining pathway in lymphocyte development. *Immunol Rev*. 2004;200:115–131.
- Schoenaker MHD, Henriët SS, Zonderland J, et al. Immunodeficiency in Bloom's syndrome. *J Clin Immunol*. 2018;38:35–44.
- Methot SP, Di Noia JM. Molecular mechanisms of somatic hypermutation and class switch recombination. *Adv Immunol*. 2017;133:37–87.
- Xu Z, Fulop Z, Zhong Y, et al. DNA lesions and repair in immunoglobulin class switch recombination and somatic hypermutation. *Ann N Y Acad Sci*. 2005;1050:146–162.
- Woodbine L, Gennery AR, Jeggo PA. The clinical impact of deficiency in DNA non-homologous end-joining. *DNA Repair (Amst)*. 2014;16:84–96.
- van Os NJH, Jansen AFM, van Deuren M, et al. Ataxia-telangiectasia: immunodeficiency and survival. *Clin Immunol*. 2017;178:45–55.
- van der Burg M, van Veelen L, Verkaik NS, et al. A new type of radiosensitive T-B-NK+ severe combined immunodeficiency caused by a *LIG4* mutation. *J Clin Invest*. 2006;116:137–145.
- Weinfeld M, Mani RS, Abdou I, et al. Tidying up loose ends: the role of polynucleotide kinase/phosphatase in DNA strand break repair. *Trends Biochem Sci*. 2011;36:262–271.
- Murray JE, van der Burg M, Ijspeert H, et al. Mutations in the NHEJ component XRCC4 cause primordial dwarfism. *Am J Hum Genet*. 2015;96:412–424.
- Scholz C, Golas MM, Weber RG, et al. Rare compound heterozygous variants in *PNKP* identified by whole exome sequencing in a German patient with ataxia-oculomotor apraxia 4 and pilocytic astrocytoma. *Clin Genet*. 2018;94:185–186.
- Hoch NC, Hanzlikova H, Rulten SL, et al. XRCC1 mutation is associated with *PARP1* hyperactivation and cerebellar ataxia. *Nature*. 2017;541:87–91.