



Universiteit
Leiden
The Netherlands

HISTOLOGY OF BONE MARROW LESIONS IN OSTEOARTHRITIS: A SYSTEMATIC LITERATURE REVIEW

Beest, S. van; Kroon, F.P.; Damman, W.; Schoones, J.W.; Ioan-Facsinay, A.; Kloppenburg, M.

Citation

Beest, S. van, Kroon, F. P., Damman, W., Schoones, J. W., Ioan-Facsinay, A., & Kloppenburg, M. (2017). HISTOLOGY OF BONE MARROW LESIONS IN OSTEOARTHRITIS: A SYSTEMATIC LITERATURE REVIEW. *Osteoarthritis And Cartilage*, 25, S332-S333. Retrieved from <https://hdl.handle.net/1887/116217>

Version: Not Applicable (or Unknown)
License: [Creative Commons CC BY 4.0 license](https://creativecommons.org/licenses/by/4.0/)
Downloaded from: <https://hdl.handle.net/1887/116217>

Note: To cite this publication please use the final published version (if applicable).

Osteoarthritis and Cartilage



Review

Comparison of histological and morphometrical changes underlying subchondral bone abnormalities in inflammatory and degenerative musculoskeletal disorders: a systematic review



M. Loef †*, S. van Beest †, F.P.B. Kroon †, J.L. Bloem ‡, O.M. Dekkers §, M. Reijnen ‡, J.W. Schoones ||, M. Kloppenburg †§

† Department of Rheumatology, Leiden University Medical Center, The Netherlands

‡ Department of Radiology, Leiden University Medical Center, Leiden, The Netherlands

§ Department of Clinical Epidemiology, Leiden University Medical Center, Leiden, The Netherlands

|| Walaeus Library, Leiden University Medical Center, Leiden, The Netherlands

ARTICLE INFO

Article history:

Received 20 December 2017

Accepted 1 May 2018

Keywords:

Bone marrow lesions

Musculoskeletal

Histology

Imaging

Systematic literature review

SUMMARY

Objective: Subchondral bone abnormalities (SBAs) on magnetic resonance imaging (MRI) are observed frequently and associated with disease course in various musculoskeletal disorders. This review aims to map the existing knowledge of their underlying histological features, and to identify needs for future research.

Design: We conducted a systematic review following PRISMA guidelines until September 2017, including all studies correlating histological features to on MRI defined SBAs in patients with osteoarthritis (OA), rheumatoid arthritis (RA), spondyloarthritis (SpA) and degenerative disc disease (DDD). Two authors independently retrieved articles and assessed study quality.

Results: A total of 21 studies (466 patients) correlated histological features to SBAs in OA ($n = 13$), RA ($n = 3$), ankylosing spondylitis (AS) ($n = 1$) and DDD ($n = 4$). Reported changes in OA were substitution of normal subchondral bone with fibrosis and necrosis, and increased bone remodeling. In contrast, in RA, AS or DDD fibrosis was not reported and SBAs correlated to an increase in inflammatory cell number. In DDD necrosis was observed. Similar to OA, increased bone remodeling was shown in RA and DDD. The risk of bias assessment showed a lack in described patient criteria, blinding and/or adequate topographic correlation in approximately half of studies. There was heterogeneity regarding the investigated histological features between the different disorders.

Conclusions: Current studies suggest that SBAs correlate to various histological features, including fibrosis, cell death, inflammation and bone remodeling. In the majority of studies most quality criteria were not met. Future studies should aim for high quality research, and consistency in investigated features between different disorders.

© 2018 Osteoarthritis Research Society International. Published by Elsevier Ltd. All rights reserved.

Introduction

Since the introduction of the magnetic resonance imaging (MRI) technique for musculoskeletal disorders in the mid-1980s, its use has been ever increasing. MRI application has led to the recognition of abnormalities in the subchondral bone region, commonly called

bone marrow edema (BME), bone marrow lesions (BMLs), or bone marrow edema-like lesions (BMELs). These subchondral bone abnormalities have been found in a variety of inflammatory and non-inflammatory musculoskeletal disorders¹. Clinically they have been shown to be associated with pain^{2–4}, functional disability⁵ and structural progression^{2,6–9}. In addition, they are also shown to occur in approximately 50 percent of (elderly) adults without musculoskeletal disorders^{10,11}, in whom they seem to be more prevalent in painful joints¹⁰. However, insight in the etiology and pathogenesis of subchondral bone abnormalities is lacking.

Despite the fact that subchondral bone abnormalities occur in many musculoskeletal disorders, the terminology that is presently

* Address correspondence and reprint requests to: M. Loef, Department of Rheumatology, Leiden University Medical Center, PO Box 9600, 2300 RC Leiden, The Netherlands.

E-mail address: m.loef@lumc.nl (M. Loef).

used is not consistent. In osteoarthritis (OA) these subchondral abnormalities were previously named BME, but this recently changed to BML. In rheumatoid arthritis (RA) and spondyloarthritis (SpA) they are still mostly called BME. A slightly different classification, following the system of Modic *et al.*¹², is used to describe subchondral bone abnormalities in degenerative disc disease (DDD). While subchondral abnormalities may have different underlying pathologies in different diseases, their MR imaging appearance is defined identically. They are characterized as homogeneous, ill-defined areas with no respect for anatomical boundaries¹³. Compared to normal subchondral bone they appear as a hypointense or intermediate signal on T1-weighted imaging (T1w) and as a hyperintense signal on fluid sensitive sequences, such as fat-suppressed (FS) T2-weighted imaging (T2w), and on short-tau inversion recovery (STIR) images¹⁴. MC type 1 represents a decreased signal intensity on T1w images and an increased signal intensity on T2w images, therefore resembling the imaging abnormalities that are called BME or BML in other disorders¹². We will use the more general term subchondral bone abnormalities, encompassing all terms referring to the above described MRI features.

To increase knowledge of the histological substrate of subchondral bone abnormalities, and whether this differs in distinct clinical entities, we performed a systematic review including studies focusing on histological findings that are topographically correlated to on MRI defined subchondral bone abnormalities, in a variety of musculoskeletal disorders.

Methods

Search strategy

In this systematic literature review we performed a search aimed at the histological substrate of subchondral bone abnormalities in multiple musculoskeletal disorders, following PRISMA guidelines. We searched the following databases up to September 2017: PubMed, Embase, the Cochrane library, the Cochrane Central Register of Controlled Trials (CENTRAL), Emcare, Academic Search Premier, ScienceDirect and Web of Science. Included search terms regarding the different disorders were; “osteoarthritis”, “degenerative arthritis”, “RA”, “Caplan's syndrome”, “Felty's syndrome”, “Sjogren's syndrome”, “Still's disease”, “spondyloarthritis”, “spondyloarthropathies”, “ankylosing spondylitis (AS)” and “psoriatic arthritis”. Search terms for subchondral bone abnormalities included “bone marrow edema”, “BMLs”, “bone marrow abnormalities”, “bone marrow diseases”, “osteitis” and “Modic changes”. The full search strategy can be found in [Supplementary file \(A\)](#). We included all studies investigating the correlation of MRI defined subchondral bone abnormalities with histological findings in humans, without language restrictions or restrictions in calendar time.

Study selection and data extraction

The retrieved titles and abstracts were independently screened by two review authors (98% agreement). Full-text papers were retrieved and assessed for eligibility if necessary to determine inclusion. Disagreements between the authors were discussed and resolved in a consensus meeting. One reviewer extracted data from each included study regarding study design, study population, MRI sequences and settings, subchondral bone abnormalities assessment and scoring methods, histology methods, topographic correlation of subchondral bone abnormalities with histology and the results for the outcomes of interest. Main outcomes were the described histological features that topographically correlated to subchondral bone abnormalities. Due to heterogeneity between studies a formal meta-analysis was not performed.

Critical appraisal

A critical appraisal of included studies was independently performed by two review authors (93% agreement). Quality criteria deemed most valuable and applicable to the included studies were the following; use and quality of description of patient selection criteria, presence of a comparison with control samples without subchondral bone abnormalities, blinding for clinical and histology data for MRI assessment, blinding for clinical and imaging data for histology assessment, standardization of main outcome measures and clear description of the method to ensure topographic correlation of investigated tissue for histology with on MRI identified subchondral bone abnormalities. Each quality criterion was assessed and considered as “present”, “absent” or “unclear” for each study individually. In case of disagreement, consensus was reached in a consensus meeting. Heterogeneity of the studies was addressed separately.

Results

Search results

Database searching identified 1306 unique studies, of which, after screening on titles and abstracts, 87 full-text papers were assessed for eligibility. Twenty-one studies were finally included ([Fig. 1](#)), of which most regarded OA ($n = 13$)^{15–27}; other studies concerned RA ($n = 3$)^{28–30}, AS ($n = 1$)³¹ and DDD ($n = 4$)^{32–35}. In total this involved 466 patients of whom 403 samples were used for both imaging and histology. No studies investigating the histology of subchondral bone abnormalities were retrieved for Still's disease, Sjogren's syndrome or psoriatic arthritis.

Patients and study design ([Table 1](#) and [Supplementary file \(B\)](#))

OA

Thirteen studies (309 patients) investigated histological abnormalities correlating to BMLs in OA, of which eight studied knee OA^{15,16,18,20,21,23,24,27} and five studied hip OA^{17,19,22,25,26}. Three studies used the American College of Rheumatology (ACR) criteria^{25–27}, some used the Kellgren–Lawrence status^{18,20,24}, while in most studies selection criteria were not clearly described. All studies used specimens from total joint replacement surgery. The study size ranged from 6 to 84 patients. Approximately half of the studies used a control group consisting of joint areas without BMLs^{19–21,24,25,27} or OA patients without BMLs²⁶ as controls.

RA

Three articles described histological findings for BME in RA^{28–30}, including a small number of patients (range from 3 to 11) fulfilling the ACR criteria. Samples consisted of joints from the hand or feet, obtained from joint replacement surgery. Only Dalbeth *et al.* included a comparison with control samples³⁰.

AS

Only one study investigating BME in AS was retrieved, which obtained samples from eight patients undergoing polysegmental correction of kyphosis. Patient criteria were not clearly stated. A control group without rheumatic disease was included³¹.

DDD

The histological basis of MC in DDD was investigated in four studies^{32–35}. Inclusion of the in total 130 patients (range 14–56) was based on degenerative findings on MRI^{33–35} or clinical symptoms³². Samples were obtained from either subchondral bone biopsies during lumbar spine surgery³⁵ or from discectomy^{32–34}.

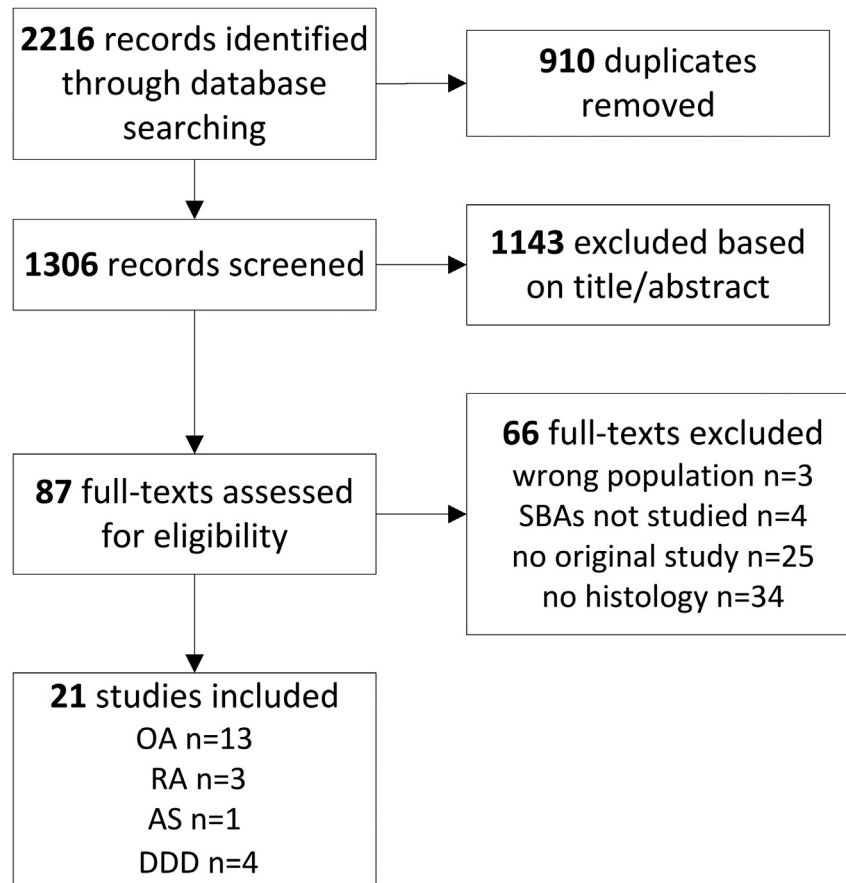


Fig. 1. Literature search and study selection process. SBAs = subchondral bone abnormalities, OA = osteoarthritis, RA = rheumatoid arthritis, AS = ankylosing spondylitis, DDD = degenerative disc disease, n = number.

Three studies included a control group with samples obtained from trauma patients^{32–34}.

Imaging and histology (Table I)

OA

Most studies used pre-operative MRI data^{15–20,22,26,27}, while three studies made MR images of explanted samples^{23–25}. A clearly described BML definition was lacking in a number of studies^{15,18–21,26}. Overall, BMLs were reported in 72% of patients. Only two studies described a blinding protocol for both imaging and histology^{18,22}. All studies used hematoxylin and eosin (H&E) for histology staining. Four studies used additional staining methods, mostly directed at visualizing cartilage^{18,24–26} and one included quantitative scoring for bone remodeling²⁴. In addition, some studies performed immunohistochemistry (IHC), with a variety of outcomes of interest^{21,25,26}. Topographic correlation of imaging with histology was not always described^{17,19,21,27}. Techniques varied from an estimation of location¹⁵ to the use of position markers²⁵. In addition to MRI and histology, some studies also investigated bone remodeling by use of micro-computed tomography (μ -CT)^{20,23,24}.

RA

In all RA studies MR images were obtained prior to surgery, using 1.5T field strength with T1w and T2w scanning sequences. MRI and histology scoring were performed blinded, methods were well-described and clear precautions were taken to correctly correlate histology location to BME^{28–30}. In addition to the H&E

staining used by all, Dalbeth *et al.* also performed IHC to quantitatively score RANKL expression³⁰.

AS

BME were defined by histology, as an accumulation of eosinophilic fluid in the bone marrow interstitium, and compared to MR images. For 3 of 8 AS patients BME was also observed on MRI. However, a description of how the histology tissue location was correlated to the MR images was not provided. Blinding was only described for histology scoring. In addition to H&E and Congo red staining, IHC was performed to semi-quantitatively score microvessel density³¹.

DDD

None of the articles stated the MRI field strength, all used T1w and T2w sequences and an *in vivo* scanning setting. Of all samples, 69% showed either a MC type I, II or III, 30% of which was MC type I. One study performed both MRI and histology scoring blinded³², while others were only blinded during MRI scoring³⁵, during histology scoring³³, or not at all³⁴. Perilli *et al.* studied bone remodeling by histology and μ -CT and clearly described topographic correlation of histology with MRI³⁵. The other studies focused on cellular infiltration and necrosis with IHC^{32–34}.

Tissue characteristics of subchondral bone abnormalities (Table II)

Bone remodeling

OA. Signs of bone remodeling were evident from an increase in bone density²³, thickening of the subchondral plate^{16,17,19,24,25} and

Table 1
Study design, strengths and limitations of included studies

Author, yr	Study population		MRI			Tissue				Remarks
	Selection criteria; n Controls; n	Sample localization; n	Field strength; sequences; setting	BMEI/MC n samples	n observers; blinding	Histology	IHC	n observers; blinding	Topographic correlation	
<i>Osteoarthritis</i> Bergman, 1994	Ahlbäck classification; 9 none	Knee; 9	0.3T T1w, T2w <i>In vivo</i>	7	1; NA	H&E	NA	NA	Estimated “closely corresponding MR image”	
Zanetti, 2000	None; 15 None	Knee; 16	1.0T T1w, T2w, STIR <i>In vivo</i>	11	2; NA	H&E	NA	1; blinded	Histologic slices compared with map of MRI abnormalities	
Boutry, 2002	Criteria for rapid destructive OA; 12 None	Hip; MRI 12, histology 7	0.5–1.5T T1w T2w FSSTIR <i>In vivo</i>	12	2; NA	H&E	NA	1; NA	NA	Retrospective study
Saadat, 2008	KL > 2; 7 None	Knee; 8	3T FS SPGR, FS <i>In vivo</i>	3	1; blinded for histology	H&E, Safranin-O	NA	1; blinded for radiology	Matched on morphology and observation units	Study focus on cartilage
Taljanovic, 2008	None; 19 None	Hip; 20	1.5T T2w, PDw <i>In vivo</i>	8	NA	H&E, BML = pale eosinophilic fluid	NA	1; blinded for imaging and clinical findings	NA	BML defined by histology.
Hunter, 2009	KL > 2; 6 Non-BML region	Knee; 6	1.5T T2w FS, SPGR <i>In vivo</i>	NA	NA	H&E	NA	NA	Map with BML location from MRI, overlay on sample	Other: μ -CT: BV/TV, TMD, Tb.Th, Tb.Sp, Tb.N, SMI. Histology results preliminary
Ogino, 2009	None; 15 LFC KL < 2	Knee; 15	1.5T T2w FS NA	NA	NA	H&E	Cox-1 Cox2 TNF α CD34 substance P TUJ1 TRAP NA	NA	NA	
Leydet-Quilici, 2010	NA; 23 None	Hip; 23	1.5T T1w, T2w FS post- Gd-DTPA <i>In vivo</i>	23	2; blinded for histology	H&E	NA	1; blinded for MRI data	Schematic drawing of MRI for correlation with histology	
Kazakia, 2013	None; 12 Non-BML region	Knee; 18	3T T1w, T2w FS, FS SPGR Ex vivo	16	1; NA	H&E	NA	NA	Spatial alignment	Other: HR-pQCT/ μ -CT: BV/TV, TMD, Tb.Th, Tb.Sp, Tb.N, SMI, vBMD. FTIR spectroscopy
Muratovic, 2015	KL; 56 Non-BML region	Knee; 56	3T FS, PDw, T1w Ex vivo	44	2; NA	von Kossa silver/ H&E (score 1–5) Safranin-O/Fast Green (OARSI grading)	NA	1; blinded for MRI findings	2D axial map of BML on MRI	Other: μ -CT: BV/TV, TMD, Tb.Th, Tb.Sp, Tb.N, SMI
Campbell, 2016	ACR criteria; 21 Non-BML region	Hip; 21	3T T1w, FS, PDw Ex vivo	20	2; blinded for patient data	H&E, Safranin-O	CD271	NA	Position markers	Other: qPCR, flow cytometry: CD90, CD73, D45, CD271
Shabestari, 2016	ACR criteria; 30 Patients without BML; 9	Hip; 30	1.5T STIR, T1w <i>In vivo</i>	21	1; NA	Goldner’s trichome (OARSI grading)	vWF, CD31	Blinded to BML status	Sampling guided by MR images	Tetracycline double- labeling
Kuttapitiya, 2017	ACR criteria; 84 Non-BML sample	Knee; MRI 84, histology 4	3T T1w, T2w FS <i>In vivo</i>	58	2; blinded for patient data	H&E (% presence of feature)	NA	NA	NA for correlation with histology	Microarray, qPCR, ELISA

(continued on next page)

Table 1 (continued)

Author, yr	Study population		MRI			Tissue				Remarks
	Selection criteria; n Controls; n	Sample localization; n	Field strength; sequences; setting	BMEL/MC n samples	n observers; blinding	Histology	IHC	n observers; blinding	Topographic correlation	
<i>Rheumatoid arthritis</i>										
Jimenez-Boj, 2007	ACR criteria; 3 None	MCP and PIP joints; 12	1.5T T1w, STIR <i>In vivo</i>	12	2; blinded	H&E	NA	2; blinded	3-D orientation documented	
McQueen, 2007 Dalbeth, 2009	ACR criteria; 4 None ACR criteria; 11 Non-BML region	Hand/wrist, feet; 7 Hand/wrist, feet; 28	1.5T T1w, T2w, T1w post-Gd-DTPA <i>In vivo</i>	3 14	2; blinded for patient data and histology 2; blinded for histology	H&E	CD68, CD8, CD20, TRAP. RANKL: 0–4, 0 < 5% – 4 > 75%	1; blinded to MRI findings 2; blinded to MRI findings	Site and orientation of samples were labeled	Patients overlap between articles
<i>Ankylosing spondylitis</i>										
Appel, 2006	None; 8 Autopsied patients without AS (histology only); 10	Zygapophyseal joints; 8	NA T1w, T2w, TIRM <i>In vivo</i>	3	NA	H&E, Congo red BML = eosinophilic fluid in bone marrow	CD3, CD4, CD8, CD20, CD34. Microvessel density (+++ - +)	1; blinded for patient and MRI data	NA	BMLs defined by histology
<i>Degenerative disc disease</i>										
Ohtori, 2006	Discogenic low back pain; 14 Scoliosis/trauma; 4 + non-MC region	Vertebrae; 14	NA T1w, T2w <i>In vivo</i>	MC I; 4 MC II; 5	3; blinded	NA	PGP 9.5, TNF	NA; blinded to patient data	NA	
Wang, 2011	Disc degeneration on MRI; 56 Trauma; 8+ non- MC region	Vertebrae; 56	NA T1w, T2w <i>In vivo</i>	MC I; 4 MC II; 17	3; NA	NA	FasR, TUNEL	2; blinded to patient data	NA	
Jiang, 2012	Disc degeneration and instability; 20 Trauma, no MC; 10	Vertebrae; 20	NA T1w, T2w <i>In vivo</i>	MC I; 10 MC II; 10	NA	NA	TNF α , MMP3	NA	NA	Article in Chinese
Perilli, 2015	Disc degeneration on MRI; 40 None	Vertebrae; 40	NA T1w, T2w <i>In vivo</i>	MC I; 9 MC II; 25 MC III; 6	2; blinded	H&E, von Kossa Silver: OS/BS, ES/BS, OS/ES	NA	NA	Biopsy region corresponding to MRI	Other: μ -CT; BV/TV, Tb.Th., Tb.Sp, Tb.N, SMI

ACR = American College of Rheumatology, BME = bone marrow edema, BML = bone marrow lesion, BV/TV = bone volume fraction, ES/BS = percent eroded surface to bone surface, FS = fat saturated, H&E = hematoxylin and eosin, IHC = immunohistochemistry, KL = Kellgren–Lawrence, LFC = lateral femoral condyle, MC = modic changes, MCP = metacarpophalangeal, MMP3 = Matrix metalloproteinase 3, MRI = magnetic resonance imaging, n = number, NA = not available, OARSI = Osteoarthritis research society international, OS/BS = percent osteoid surface to bone surface, OS/ES = osteoid surface to eroded surface ratio, PDw = proton density weighted, PIP = proximal interphalangeal, PGP = protein gene product, post-Gd-DTPA = post gadolinium diethylenetriamine pentaacetic acid, qPCR = quantitative polymerase chain reaction, SMI = structural model index, SPGR = spoiled gradient-recalled echo sequence, STIR = short tau inversion recovery, T = tesla, Tb.N = trabecular number (= (BV/TV)/Tb.Th), Tb.Th. = trabecular thickness, Tb.Sp = trabecular separation, TIRM = turbo inversion recovery magnitude, TMD = tissue mineral density, TNF = tumor necrosis factor, T1w = T1-weighted, T2w = T2-weighted, μ -CT = micro-computer tomography, vBMD = volumetric bone mineral density, vWF = von Willebrand Factor, Yr = year.

Table IIa
Histology features correlating to subchondral bone abnormalities in OA patients

Author, year	Bone remodeling	Necrosis	Fibrosis
<i>Osteoarthritis</i>			
Bergman <i>et al.</i> , 1994	Many of trabeculae were thicker than normal.	Some trabeculae exhibited empty lacunae, indicating bony necrosis.	7/9 samples showed focal regions where fibrous tissue replaced fatty marrow, varying from loosely fibromyxoid to dense, highly cellular tissue with extensive vascularization.
Zanetti <i>et al.</i> , 2000	Signs of repeated remodeling, increased sclerosis, reversal lines, bone resorption.	Evidence of foam cell formation, swollen fat cells with loss of nuclei.	Replacement of fatty marrow with collagenous fibers and with spindle-cell formations.
Boutry <i>et al.</i> , 2002	Reactive bone formation and resorption, subchondral bone sclerosis, abnormal trabeculae ($n = 3$ thickened, $n = 4$ thinned).	Focal marrow fat necrosis.	Foci of fibroconnective tissue ($n = 2$).
Saadat <i>et al.</i> , 2008	Increased bone remodeling.	NA	Subchondral ingrowth of fibrovascular tissue.
Taljanovic <i>et al.</i> , 2008	All BMLs had \uparrow subchondral sclerosis, evident from $\geq 2\times$ thickened subchondral plate.	100% of samples had marrow fat necrosis (swelling and disintegration of fat cells), comprising 5–60% of tissue volume	85% of patients had replacement of fatty marrow by collagen fibers up to 20% of tissue volume.
Hunter <i>et al.</i> , 2009	BMLs: \uparrow bone volume fraction, \downarrow tissue mineral density, \downarrow SMI, \uparrow trabecular thickness and spacing and trend \downarrow trabecular number.	Preliminary data: diffuse necrosis, granulation tissue	Preliminary data: fibrinoid deposition.
Ogino <i>et al.</i> , 2009	NA	Exclusive expression of TUJ1, substance P, Cox-2, and TNF- α in the MFC (containing BML) but not in the LFC (control).	Subchondral plate with BML had higher frequency of cystic lesions lined by fibrous tissue.
Leydet-Quilici <i>et al.</i> , 2010	NA	Accumulation of eosinophilic material, loss of nuclei.	Replacement of fatty marrow with collagenous fibers.
Kazakia <i>et al.</i> , 2013	BMLs: 47% \uparrow bone mineral density, \uparrow bone quantity (62%), \uparrow trabecular thickness (31%) and number (28%), \downarrow trabecular spacing (21%), \downarrow SMI \downarrow mineral-to-matrix (11%) and carbonate-to-matrix ratio (14%).	NA	Infiltration of marrow space by a fibrous collagen network.
Muratovic <i>et al.</i> , 2015	BMLs: thicker subchondral plate, \uparrow trabecular volume, \uparrow SMI, \uparrow osteoid volume and thickness of both plate and trabeculae and \downarrow eroded surface.	BMLs contained more necrosis compared to NBML groups.	BMLs contained higher fibrosis scores compared to NBML groups (NS).
Campbell <i>et al.</i> , 2016	BMLs: \uparrow trabecular area and sclerotic bone or reparative tissue within denuded surface.	NA	NA
Shabestari <i>et al.</i> , 2016	BMLs showed \uparrow mineralizing surface, bone formation rate, mineral apposition rate and bone volume.	NA	NA
Kuttapitiya <i>et al.</i> , 2017	BMLs showed \uparrow areas of thickened trabeculae adjacent to thinning trabeculae and \downarrow bone volume fraction compared to NBML.	NA	BMLs showed \uparrow percentage of cartilage formation within subchondral bone compared to NBML.

an increase in trabecular number, volume and thickness^{17,19,24,27}, compared to non-BML samples. Structural model index (SMI), reflecting the trabecular shape, was found increased in BML samples in one article²⁴, but decreased in two others^{20,23}.

RA. Increased osteoclast numbers and replacement of bone with myxoid tissue was shown in BME positive bone samples, compared to BME negative samples³⁰.

AS. Findings regarding bone remodeling were not reported.

DDD. Micro-CT of vertebrae from DDD patients showed significantly higher bone turnover in MC type I compared to MC type II and III. MC type III samples showed a significantly higher bone volume fraction and trabecular thickness when compared to MC type I and II³⁵.

Cell death

OA. Bergman *et al.* defined bone necrosis as trabeculae lacking osteocytes, as demonstrated by the presence of empty lacunae¹⁵. Others described focal areas of swelling or disintegration of fat cells^{16,17,19}. One study semi-quantitatively scored necrosis, showing a variable extent of marrow fat necrosis ranging from 5 to 60%¹⁹. The amount of necrosis in BMLs was significantly greater than in areas without BMLs²⁴.

DDD. A higher number of FasR-positive and apoptotic cells was observed in bone samples with MC compared to bone samples without MC³³.

Other. Findings regarding apoptosis or necrosis were not reported in the RA and AS studies.

Fibrosis

OA. All studies investigating fibrosis indicated partial replacement of adipose-type marrow with fibrous or fibrovascular tissue^{15–18,20–24,27}. Taljanovic *et al.* showed fibrosis in 85% of patients, which comprised up to 20% of the evaluated tissue volume. However, correlation to the MRI features was not described¹⁹.

Other. Fibrosis was not reported in the RA, AS and DDD studies.

Cellular infiltration

OA. Increased cellular infiltration was shown in the BML group compared to the non-BML group²⁷. None of the other studies described cellular infiltration in OA patients.

RA. A decrease in adipocytes and an increase in hematopoietic cell number in BME positive samples of RA patients was found, when compared to normal bone marrow²⁸. Samples with BME showed an increase in inflammatory cell number³⁰.

Table 11b
Histology features correlating to subchondral bone abnormalities in RA, AS and DDD patients

Author, year	Bone remodeling	Necrosis	Cellular infiltration
<i>Rheumatoid arthritis</i> Jimenez-Boj et al., 2007	NA	NA	Mostly mild infiltration with ↓ adipocyte and ↑ hematopoietic cells (<50% of tissue area), some areas severe infiltration almost completely replacing bone marrow fat.
McQueen et al., 2007/Dalbeth et al., 2009	BMEs showed ↑ osteoclasts and a trend to ↑ RANKL expression. RANKL expression strongly correlated to number of osteoclasts.	NA	BME: ↑ inflammatory cell number (macrophages, plasma cells, CD8 ⁺ T cells). 4/7 histology samples corresponded with BME presence and severity.
<i>Ankylosing spondylitis</i> Appel et al., 2006	NA	NA	Cellular infiltration (CD3 ⁺ , CD4 ⁺ CD8 ⁺ , CD20 ⁺) varied from +++ (n = 5) to + (n = 3). BME: ↑ cellular infiltration. Poor correlation interstitial edema and inflammatory cell infiltration.
<i>Degenerative disc disease</i> Ohtori et al., 2006	NA	NA	MC type I and II samples: ↑ PGP 9.5-positive nerve fibers (P = 0.008 and P = 0.01) and TNF-positive cells (P = 0.002 and P = 0.007) than samples without MCs. No difference between MC type I and II.
Wang et al., 2011	NA	Presence of MC associated with higher number of FasR-positive and apoptotic cells. No difference between MC types.	NA
Jiang et al., 2012	NA	NA	TNFα and MMP3 expression ↑ in MC type I compared to II and ↑ in patients compared to controls. No correlation TNFα and MMP3 expression.
Perilli et al., 2015	MC type III: ↑ osteoid surface to erode surface ratio, ↑ bone volume fraction, ↑ trabecular thickness compared to MC type I and II, ↓ percent erode surface to bone surface ratio compared to type I.	NA	Histology did not show associated edema or cellular infiltration.

BME = bone marrow edema, BML = bone marrow lesion, Cox-2 = anticyclooxygenase 2, LFC = lateral femoral condyle, MC = modic changes, MFC = medial femoral condyle, MMP 3 = matrix metalloproteinase 3, MR = Magnetic resonance, n = number, NA = not available, NBML = non-BML, NS = non-significant, PGP 9.5 = protein gene product 9.5, SMI = structural model index, TNF = tumor necrosis factor, TUJ1 = antineuron-specific class III beta-tubulin, ↑ = increased, ↓ = decreased.

AS. More cellular infiltration was found in AS patients with BME on MRI. They found a poor correlation between inflammatory cell infiltration and histologically observed interstitial edema³¹.

DDD. Perilli et al. did not find edema or cellular infiltration in histological sections corresponding to the MRI defined MC³⁵. An increase in PGP 9.5 positive nerve fibers and TNF positive cells was found in MC type I and II compared to samples without MCs³². A higher expression of TNF-α and MMP 3 was found in DDD patients compared to controls and in MC type I compared to MC type II³⁴.

Other findings

In addition to the results summarized in Table II, three studies investigated vascularity in OA patients. All showed an increase in vascularity in BML samples compared to control samples^{17,26,27}. Quantification of vascularization showed a fourfold increase in vascularity compared to controls. Moreover, results from the histological OARSI OA score method, characterizing cartilage loss, indicated more advanced disease in the BML group²⁶. In contrast, no difference in micro-vessel density was observed in AS patients³¹. Campbell et al. investigated the number and function of mesenchymal stromal cells (MSC) in OA patients, showing alterations in MSC number and gene expression and a lower proliferation rate and mineralization capacity in BMLs compared to non-BML samples. Additionally, the BMLs were associated with areas of increased cartilage damage²⁵.

Heterogeneity between investigated histological features

There was a large variation in reported histological features between the different studies, in particular between the different musculoskeletal disorders. Summarized in Fig. 2 is the percentage of studies, grouped by musculoskeletal disorder, that reported a particular histological feature. None of the studies reported investigation or results of all of the in this review summarized

	OA N=13	RA N=3	AS N=1	DDD N=4
Bone remodeling	85%	33%	0%	25%
Cell death	62%	0%	0%	25%
Fibrosis	85%	0%	0%	0%
Cellular infiltration	0%	67%	100%	75%

Fig. 2. Frequency of reported histological features. The percentage of studies that investigated the specific histological feature was given, grouped by musculoskeletal disorder. OA = osteoarthritis, RA = rheumatoid arthritis, AS = ankylosing spondylitis, DDD = degenerative disc disease.

histological features. Of the 13 included OA studies, 11 studies reported bone remodeling and/or fibrosis, eight studies reported results on cell death, and one reported cellular infiltration. In contrast, in RA only one study reported bone remodeling and findings regarding cell death and fibrosis were not reported. In both RA and AS the focus was on cellular infiltration. In DDD it was more variable which features were studied, both bone remodeling and cell death were reported by one study, while cellular infiltration was reported by three. Remarkably, all of the reported results, except one (cellular infiltration was reported to be not present in the article by Perilli *et al.*³⁵) were positive findings.

Critical appraisal of included studies

The quality of included studies is summarized in Fig. 3. Only one study fulfilled all quality criteria³⁰, and six out of the 21 studies fulfilled no more than two criteria^{15,17,19–21,33}. Patient inclusion criteria were not described in six studies^{16,19,21–23,31}. Only half of the included studies compared the histological features of subchondral bone abnormalities with samples without abnormalities^{20,21,23–27,30,32–34}. Quantification of histological features was very limited and studies differed in quantification method. Appropriate blinding was applied during MRI and histology assessment in only six of the studies^{18,22,28–30,32}. In three studies blinding was only applied during MRI assessment^{25,27,35}, and in six studies only histology was assessed blinded^{16,19,24,26,31,33}. Standardization of sampling for histological evaluation was not stated for most studies. Reproducibility of histology scoring was reported by Muratovic *et al.* and Shabestari *et al.*^{24,26}.

Discussion

This systematic literature review summarizes the available data of the histological substrate of MRI defined subchondral bone abnormalities, so-called BMLs, BME, BMELs or MC, in various musculoskeletal diseases. Included studies showed that subchondral bone abnormalities correspond to a mix of histological features. In OA patients, most commonly reported histological findings were focal areas of fibrosis, apoptosis or necrosis, and increased bone remodeling. Also in RA and DDD an increase in cell death and bone remodeling was shown. However, the focus of most studies investigating other musculoskeletal disorders than OA, including both inflammatory (AS, RA) and non-inflammatory (DDD) disorders, was on inflammatory cell infiltration; none of these studies reported fibrosis. The use of micro-CT allowed for quantitative measurement of bone turnover and remodeling in OA and DDD, which showed significant increase in bone turnover and a thickening of the subchondral plate and trabeculae in both disorders^{16,17,19,24,25,35}. Unfortunately, bone remodeling with micro-CT was not investigated in RA or SpA. The differences in investigated histological features and the lack of quantification of histological results limited comparison between studies.

Despite the differences in study designs, these results stress that to consider subchondral bone abnormalities as merely reflecting increased water content within the bone marrow is an outdated notion. Shabestari *et al.* proposed the hypothesis that the increased water signal on MRI is a result of increased vascularity²⁶. The large variety in histological abnormalities indicates that this is not fully explanatory. However, the hypothesis that increased vascularity, and thus subchondral bone abnormalities, may reflect a reparatory response to inflicted damage is a very interesting one^{26,36}. Considering that subchondral bone abnormalities occur in a vast heterogeneity of diseases with different underlying pathophysiology, the triggering event in these diseases likely varies. However,

	Validated patient inclusion criteria	Comparison non-BML sample	Standardization outcome measures	Blinding MRI scoring	Blinding histology scoring	Topographic correlation
Osteoarthritis						
Bergman 1994	✓	✗	✗	?	?	✓
Zanetti 2000	✗	✓	✓	?	✓	✓
Boutry 2002	✓	✗	✗	?	?	✗
Saadat 2008	✓	✗	✓	✓	✓	✓
Taljanovic 2008	✗	✗	✓	?	✓	?
Hunter 2009	✓	✓	✓	?	?	✓
Ogino 2009	✗	✓	✓	?	?	?
Leydet-Quilici 2010	✗	✗	✓	✓	✓	✓
Kazakia 2013	✗	✓	✓	?	?	✓
Muratovic 2015	✓	✓	✓	?	✓	✓
Campbell 2016	✓	✓	✓	✓	?	✓
Shabestari 2016	✓	✓	✓	?	✓	?
Kuttapitiya 2017	✓	✓	✓	✓	?	✓
Rheumatoid arthritis						
Jimenez-Boj 2007	✓	✗	✓	✓	✓	✓
McQueen 2007	✓	✗	✗	✓	✓	?
Dalbeth 2009	✓	✓	✓	✓	✓	✓
Ankylosing spondylitis						
Appel 2006	✗	✗	✓	?	✓	?
Degenerative disc disease						
Ohtori 2006	✗	✓	✓	✓	✓	?
Wang 2011	✗	✓	✓	?	✓	?
Jiang 2012	?	✓	✓	?	?	?
Perilli 2015	✗	✗	✓	✓	?	✓

Fig. 3. Critical appraisal. Review author's judgment on quality of each included study. Each quality criterion is marked as present (✓), absent (✗) or unclear (?).

subchondral bone abnormalities seem to have in common that they are preceded by some kind of injury, for example mechanical stress, inflammation or ischemia³⁶. The 'repair hypothesis' is supported by studies showing that the natural course of subchondral bone abnormalities is very variable. They can fluctuate in size and might even be able to regress^{37–41} and concurrently increase and decrease

over time within the same joint³⁹. Elaborating on this hypothesis, regression of subchondral bone abnormalities might therefore reflect repair of the initial damage.

The currently available studies show that subchondral bone abnormalities are not solely comprised of increased vascularity, but rather of a mix of histological features. It is conceivable that the histological features differ over the disease course. Possibly, early in the disease process subchondral bone abnormalities reflect relatively more reversible features, such as increased vascularity, with a shift toward more permanent histological features later in disease when the initial damage is not resolved or in the presence of an ongoing damaging stimulus. A likely permanent feature correlated to subchondral bone abnormalities is increased bone density, which has been shown to contribute to cartilage damage⁴². This could explain how, at variance with the 'repair hypothesis', subchondral bone abnormalities can precede radiographic OA⁴³ and their positive correlation with disease progression^{2,6–9,36}. If the underlying process in early disease represents a reversible situation, this might make subchondral bone abnormalities a very interesting target to prevent further damage and progression. Perhaps there might be a time window in which intervention may lead to a higher therapeutic benefit.

Studies investigating the effect of treatment on subchondral bone abnormalities in musculoskeletal disorders other than osteoporosis or osteonecrosis have been limited. However, a number of studies have investigated the effect of treatment with bisphosphonates on subchondral bone abnormalities, leading to BML size reduction^{44,45} and reduction of pain in patients with knee osteoarthritis⁴⁴ and reduction in tender and swollen joints and improvement of function in SpA patients⁴⁵. Also, one study investigating the effect of parenteral iloprost in patients with hip pain and MRI verified BME showed a reduction in BME size and pain at 4 months after treatment in most patients⁴⁶. In addition, tumor necrosis factor inhibitors have also been shown to reduce subchondral bone abnormalities in OA⁴⁷, RA⁴⁸ and psoriatic arthritis patients⁴⁹. Better insight in when and how subchondral bone abnormalities can be targeted might aid future therapeutic research.

Interestingly, although this was beyond the scope of this review, a link between subchondral bone abnormalities with subchondral insufficiency fractures has been described^{50–52}. Subchondral insufficiency fractures can occur under normal biomechanical stress in patients with weakened bone or osteoporosis, which can be a result of underlying medical conditions or treatment⁵³. The patient groups we included may well have received corticosteroid treatment during their disease course, and this, in addition to a change in bone remodeling due to disease activity, might make them susceptible to develop insufficiency fractures. However, as most evidence regarding subchondral bone abnormalities and insufficiency fractures comes from case-reports and case-series, more research will be warranted.

The number of studies investigating the histologic substrate of subchondral bone abnormalities, especially in RA and AS, is limited, and only one of all included studies fulfilled all quality criteria. There was heterogeneity in the histological features reported by the different musculoskeletal disorders. Notably, with the exception of one study investigating cellular infiltration in DDD, all reported results were positive findings. This raises the question if the other histological features were not investigated, or simply not reported, introducing publication bias. This makes current findings less reliable and interferes with comparison of histological findings between different musculoskeletal disorders. Furthermore, a major limitation of the currently published research is that all studies report findings from patients undergoing joint surgery, either joint replacement or arthrodesis. Therefore, these results reflect the situation in end-stage disease. The underlying histological changes

might differ in earlier disease stages. It remains unclear in what stage of the disease these changes arise and when they start to play a role in disease progression. Insight in the occurrence, progression and corresponding histological changes in multiple disease stages would give more insight in the pathophysiological role of subchondral bone abnormalities. Another limitation is that not all studies included a control group, making it difficult to assess if the histological features differ from normal. Also, it is difficult to assess what control group should best be used, since comparison with histologic features of subchondral bone abnormalities from a healthy subject is not feasible.

This review has some limitations. Due to the large heterogeneity of the included study populations and reported histological findings, we were unable to perform a meta-analysis. Furthermore, since the articles could not be fitted into a clinical study design such as a controlled trial or cohort study, we could not use standard validated questionnaires to perform our risk of bias assessment. However, we structured our risk of bias assessment similar to the mostly used risk of bias questionnaires, and included the domains testing the most common types of bias; selection bias, detection bias and measurement bias. Reporting bias was addressed separately. We carefully fitted the quality criteria on the data of the articles included in this review and tested the criteria in a pilot before final assessment by two independent assessors.

In conclusion, current studies suggest that subchondral bone abnormalities correlate to a variety of histological features. Quality criteria were all addressed in only one study, therefore conclusions should be drawn cautiously. Future studies should address these quality issues and should aim to be comprehensive in investigating histological features to allow for better comparison between different disorders. In addition, subchondral bone abnormalities should preferably be studied at different disease stages. A better understanding of the pathological processes underlying subchondral bone abnormalities in various disorders and disease stages may aid in development of new treatment strategies.

Author contribution

ML was the principle investigator and contributed to design of the study, data extraction, risk of bias analysis, data interpretation and drafting of the article. SvB contributed to design of the study, data extraction, risk of bias analysis, data interpretation and critically revising of the article. FPBK and JWS contributed to design of the study, data interpretation and critically revising of the article. JLB, OMD and MR contributed to data interpretation and critically revising of the article. MK contributed to design of the study, data interpretation and drafting the article. All authors give final approval of the submitted article.

Conflict of interest

There are no conflicts of interest to be declared.

Role of the funding source

None.

Acknowledgments

We gratefully acknowledge the contribution of Prof. Dr R. Kandel, chief of the department of Pathology and Laboratory Medicine of the University of Toronto, for comments and suggestions.

Supplementary data

Supplementary data related to this article can be found at <https://doi.org/10.1016/j.joca.2018.05.007>.

References

- Eriksen EF. Treatment of bone marrow lesions (bone marrow edema). *BoneKey Rep* 2015;4:755, <https://doi.org/10.1038/bonekey.2015.124>.
- Tanamas SK, Wluka AE, Pelletier J-P, Pelletier JM, Abram F, Berry PA, et al. Bone marrow lesions in people with knee osteoarthritis predict progression of disease and joint replacement: a longitudinal study. *Rheumatol Oxf Engl* 2010;49(12):2413–9, <https://doi.org/10.1093/rheumatology/keq286>.
- Liu R, Damman W, Reijnierse M, Bloem JL, Rosendaal FR, Kloppenburg M. Bone marrow lesions on magnetic resonance imaging in hand osteoarthritis are associated with pain and interact with synovitis. *Osteoarthr Cartil* 2017;25(7):1093–9, <https://doi.org/10.1016/j.joca.2017.02.790>.
- Zhang YH, Zhao CQ, Jiang LS, Chen XD, Dai LY. Modic changes: a systematic review of the literature. *Eur Spine J* 2008;17:1289–99, <https://doi.org/10.1007/s00586-008-0758-y>.
- Burgers LE, Nieuwenhuis WP, van Steenbergen HW, Newsum EC, Huizinga TW, Reijnierse M, et al. Magnetic resonance imaging-detected inflammation is associated with functional disability in early arthritis—results of a cross-sectional study. *Rheumatol Oxf* 2016;55(12):2167–75, <https://doi.org/10.1093/rheumatology/kew334>.
- Damman W, Liu R, Bloem JL, Rosendaal FR, Reijnierse M, Kloppenburg M. Bone marrow lesions and synovitis on MRI associate with radiographic progression after 2 years in hand osteoarthritis. *Ann Rheum Dis* 2017;76(1):214–7, <https://doi.org/10.1136/annrheumdis-2015-209036>.
- Haavardsholm EA, Bøyesen P, Østergaard M, Schildvold A, Kvien TK. Magnetic resonance imaging findings in 84 patients with early rheumatoid arthritis: bone marrow oedema predicts erosive progression. *Ann Rheum Dis* 2008;67(6):794–800, <https://doi.org/10.1136/ard.2007.071977>.
- Hetland ML, Ejjbjerg B, Hørslev-Petersen K, Jacobsen S, Vestergaard A, Jurik AG, et al. MRI bone oedema is the strongest predictor of subsequent radiographic progression in early rheumatoid arthritis. Results from a 2-year randomised controlled trial (CIMESTRA). *Ann Rheum Dis* 2009;68(3):384–90, <https://doi.org/10.1136/ard.2008.088245>.
- Teichtahl AJ, Cicuttini FM, Abram F, Wang Y, Pelletier J-P, Dodin P, et al. Meniscal extrusion and bone marrow lesions are associated with incident and progressive knee osteoarthritis. *Osteoarthr Cartil* 2017;25(7):1076–83, <https://doi.org/10.1016/j.joca.2017.02.792>.
- Guermazi A, Niu J, Hayashi D, Roemer FW, Englund M, Neogi T, et al. Prevalence of abnormalities in knees detected by MRI in adults without knee osteoarthritis: population based observational study (Framingham Osteoarthritis Study). *Br Med J* 2012;345:e5339.
- Magnus L, van Steenbergen HW, Reijnierse M, van der Helm-van Mil AHM. Magnetic resonance imaging-detected features of inflammation and erosions in symptom-free persons from the general population. *Arthritis Rheumatol Hoboken NJ* 2016;68(11):2593–602, <https://doi.org/10.1002/art.39749>.
- Modic MT, Steinberg PM, Ross JS, Masaryk TJ, Carter JR. Degenerative disk disease: assessment of changes in vertebral body marrow with MR imaging. *Radiology* 1988;166(1):193–9, <https://doi.org/10.1148/radiology.166.1.3336678>.
- Starr AM, Wessely MA, Albastaki U, Pierre-Jerome C, Kettner NW. Bone marrow edema: pathophysiology, differential diagnosis, and imaging. *Acta Radiol* 2008;49(7):771–86.
- Roemer FW, Frobell R, Hunter DJ, Crema MD, Fischer W, Bohndorf K, et al. MRI-detected subchondral bone marrow signal alterations of the knee joint: terminology, imaging appearance, relevance and radiological differential diagnosis. *Osteoarthr Cartil* 2009;17(9):1115–31.
- Bergman AG, Willen HK, Lindstrand AL, Pettersson HT. Osteoarthritis of the knee: correlation of subchondral MR signal abnormalities with histopathologic and radiographic features. *Skeletal Radiol* 1994;23:445–8.
- Zanetti M, Bruder E, Romero J, Hodler J. Bone marrow edema pattern in osteoarthritic knees: correlation between MR imaging and histologic findings. *Radiology* 2000;215:835–40, <https://doi.org/10.1148/radiology.215.3.r00jn05835>.
- Boutry N, Paul C, Leroy X, Fredoux D, Migaud H, Cotten A. Rapidly destructive osteoarthritis of the hip: MR imaging findings. *Am J Roentgenol* 2002;179:657–63, <https://doi.org/10.2214/ajr.179.3.1790657>.
- Saadat E, Jobke B, Chu B, Lu Y, Cheng J, Li X, et al. Diagnostic performance of in vivo 3-T MRI for articular cartilage abnormalities in human osteoarthritic knees using histology as standard of reference. *Eur Radiol* 2008;18:2292–302, <https://doi.org/10.1007/s00330-008-0989-7>.
- Taljanovic MS, Graham AR, Benjamin JB, Gmitro AF, Krupinski EA, Schwartz SA, et al. Bone marrow edema pattern in advanced hip osteoarthritis: quantitative assessment with magnetic resonance imaging and correlation with clinical examination, radiographic findings, and histopathology. *Skeletal Radiol* 2008;37:423–31, <https://doi.org/10.1007/s00256-008-0446-3>.
- Hunter DJ, Gerstenfeld L, Bishop G, Davis AD, Mason ZD, Einhorn TA, et al. Bone marrow lesions from osteoarthritis knees are characterized by sclerotic bone that is less well mineralized. *Arthritis Res Ther* 2009;11:R11, <https://doi.org/10.1186/ar2601>.
- Ogino S, Sasho T, Nakagawa K, Suzuki M, Yamaguchi S, Higashi M, et al. Detection of pain-related molecules in the subchondral bone of osteoarthritic knees. *Clin Rheumatol* 2009;28(12):1395–402.
- Leydet-Quilici H, Le Corroller T, Bouvier C, Giorgi R, Argenson JN, Champsaur P, et al. Advanced hip osteoarthritis: magnetic resonance imaging aspects and histopathology correlations. *Osteoarthr Cartil* 2010;18(11):1429–35.
- Kazakia GJ, Kuo D, Schooler J, Siddiqui S, Shanbhag S, Bernstein G, et al. Bone and cartilage demonstrate changes localized to bone marrow edema-like lesions within osteoarthritic knees. *Osteoarthr Cartil* 2013;21(1):94–101.
- Muratovic D, Cicuttini F, Wluka A, Findlay D, Wang Y, Otto S, et al. Bone marrow lesions detected by specific combination of MRI sequences are associated with severity of osteochondral degeneration. *Arthritis Res Ther* 2015;18:54, <https://doi.org/10.1186/s13075-016-0953-x>.
- Campbell TM, Churchman SM, Gomez A, McGonagle D, Conaghan PG, Ponchel F, et al. Mesenchymal stem cell alterations in bone marrow lesions in hip osteoarthritis. *Arthritis Rheumatol* 2016;68(7):1648–9, <https://doi.org/10.1002/art.39622>.
- Shabestari M, Vik J, Reseland JE, Eriksen EF. Bone marrow lesions in hip osteoarthritis are characterized by increased bone turnover and enhanced angiogenesis. *Osteoarthr Cartil* 2016;24(10):1745–52, <https://doi.org/10.1016/j.joca.2016.05.009>.
- Kuttapitiya A, Assi L, Laing K, Hing C, Mitchell P, Whitley G, et al. Microarray analysis of bone marrow lesions in osteoarthritis demonstrates upregulation of genes implicated in osteochondral turnover, neurogenesis and inflammation. *Ann Rheum Dis* 2017;76(10):1764–73, <https://doi.org/10.1136/annrheumdis-2017-211396>.

28. Jimenez-Boj E, Nobauer-Huhmann I, Hanslik-Schnabel B, Dorotka R, Wanivenhaus AH, Kainberger F, *et al.* Bone erosions and bone marrow edema as defined by magnetic resonance imaging reflect true bone marrow inflammation in rheumatoid arthritis. *Arthritis Rheum* 2007;56:1118–24, <https://doi.org/10.1002/art.22496>.
29. McQueen FM. A vital clue to deciphering bone pathology: MRI bone oedema in rheumatoid arthritis and osteoarthritis. *Ann Rheum Dis* 2007;66:1549–52, <https://doi.org/10.1136/ard.2007.082875>.
30. Dalbeth N, Smith T, Gray S, Doyle A, Antill P, Lobo M, *et al.* Cellular characterisation of magnetic resonance imaging bone oedema in rheumatoid arthritis; implications for pathogenesis of erosive disease. *Ann Rheum Dis* 2009;68:279–82, <https://doi.org/10.1136/ard.2008.096024>.
31. Appel H, Lodenkemper C, Grozdanovic Z, Ehardt H, Dreimann M, Hempfing A, *et al.* Correlation of histopathological findings and magnetic resonance imaging in the spine of patients with ankylosing spondylitis. *Arthritis Res Ther* 2006;8:R143, <https://doi.org/10.1186/ar2035>.
32. Ohtori S, Inoue G, Ito T, Koshi T, Ozawa T, Doya H, *et al.* Tumor necrosis factor-immunoreactive cells and PGP 9.5-immunoreactive nerve fibers in vertebral endplates of patients with discogenic low back Pain and Modic Type 1 or Type 2 changes on MRI. *Spine Phila Pa* 1976 2006;31:1026–31, <https://doi.org/10.1097/01.brs.0000215027.87102.7c>.
33. Wang Y, Videman T, Niemelainen R, Battie MC. Quantitative measures of modic changes in lumbar spine magnetic resonance imaging: intra- and inter-rater reliability. *Spine Phila Pa* 1976 2011;36:1236–43, <https://doi.org/10.1097/BRS.0b013e3181ecf283>.
34. Jiang S, Shen C, Dong F, Zhang J, Li Y. Modic changing and typing of degenerative lumbar and the expression of tumor necrosis factor alpha and matrix metalloproteinase 3. *Chin J Tissue Eng Res* 2012;16(26):4847–51.
35. Perilli E, Parkinson IH, Truong LH, Chong KC, Fazzalari NL, Osti OL. Modic (endplate) changes in the lumbar spine: bone micro-architecture and remodelling. *Eur Spine J* 2015;24:1926–34, <https://doi.org/10.1007/s00586-014-3455-z>.
36. Eriksen EF, Ringe JD. Bone marrow lesions: a universal bone response to injury? *Rheumatol Int* 2012;32(3):575–84.
37. Felson DT, Parkes MJ, Marjanovic EJ, Callaghan M, Gait A, Cootes T, *et al.* Bone marrow lesions in knee osteoarthritis change in 6–12 weeks. *Osteoarthr Cartil* 2012;20:1514–8, <https://doi.org/10.1016/j.joca.2012.08.020>.
38. Felson DT, McLaughlin S, Goggins J, LaValley MP, Gale ME, Totterman S, *et al.* Bone marrow edema and its relation to progression of knee osteoarthritis. *Ann Intern Med* 2003;139(5 Pt 1):330–6.
39. Roemer FW, Guermazi A, Javadi MK, Lynch JA, Niu J, Zhang Y, *et al.* Change in MRI-detected subchondral bone marrow lesions is associated with cartilage loss: the MOST Study. A longitudinal multicentre study of knee osteoarthritis. *Ann Rheum Dis* 2009;68(9):1461–5, <https://doi.org/10.1136/ard.2008.096834>.
40. Kornaat PR, Kloppenburg M, Sharma R, Botha-Scheepers SA, Le Graverand MP, Coene LN, *et al.* Bone marrow edema-like lesions change in volume in the majority of patients with osteoarthritis; associations with clinical features. *Eur Radiol* 2007;17:3073–8, <https://doi.org/10.1007/s00330-007-0711-1>.
41. Nieuwenhuis WP, van Steenberg HW, Stomp W, Stijnen T, Huizinga TWJ, Bloem JL, *et al.* The course of bone marrow edema in early undifferentiated arthritis and rheumatoid arthritis: a longitudinal magnetic resonance imaging study at bone level. *Arthritis Rheumatol Hoboken NJ* 2016;68(5):1080–8, <https://doi.org/10.1002/art.39550>.
42. Zamli Z, Robson Brown K, Tarlton JF, Adams MA, Torlot GE, Cartwright C, *et al.* Subchondral bone plate thickening precedes chondrocyte apoptosis and cartilage degradation in spontaneous animal models of osteoarthritis. *BioMed Res Int* 2014;2014:606870, <https://doi.org/10.1155/2014/606870>.
43. Roemer FW, Kwok CK, Hannon MJ, Hunter DJ, Eckstein F, Fujii T, *et al.* What comes first? Multitissue involvement leading to radiographic osteoarthritis: magnetic resonance imaging-based trajectory analysis over four years in the osteoarthritis initiative. *Arthritis Rheumatol Hoboken NJ* 2015;67(8):2085–96, <https://doi.org/10.1002/art.39176>.
44. Laslett LL, Doré DA, Quinn SJ, Boon P, Ryan E, Winzenberg TM, *et al.* Zoledronic acid reduces knee pain and bone marrow lesions over 1 year: a randomised controlled trial. *Ann Rheum Dis* 2012;71(8):1322–8, <https://doi.org/10.1136/annrheumdis-2011-200970>.
45. Maksymowych WP, Lambert R, Jhangri GS, Leclercq S, Chiu P, Wong B, *et al.* Clinical and radiological amelioration of refractory peripheral spondyloarthritis by pulse intravenous pamidronate therapy. *J Rheumatol* 2001;28(1):144–55.
46. Meizer R, Meraner D, Meizer E, Radda C, Landsiedl F, Aigner N. Outcome of painful bone marrow edema of the femoral head following treatment with parenteral iloprost. *Indian J Orthop* 2009;43(1):36–9, <https://doi.org/10.4103/0019-5413.45321>.
47. Kroon F, Wittoek R, Verbruggen G, Haugen IK, Huizinga TW, Kloppenburg M. Effect of etanercept on synovitis and bone marrow lesions in erosive hand osteoarthritis. *Osteoarthr Cartil* 2017;25:S39–40, <https://doi.org/10.1016/j.joca.2017.02.078>.
48. Hirose W, Nishikawa K, Hirose M, Nanki T, Sugimoto H. Response of early active rheumatoid arthritis to tumor necrosis factor inhibitors: evaluation by magnetic resonance imaging. *Mod Rheumatol* 2009;19(1):20–6, <https://doi.org/10.1007/s10165-008-0114-4>.
49. Marzo-Ortega H, McGonagle D, Rhodes LA, Tan AL, Conaghan PG, O'Connor P, *et al.* Efficacy of infliximab on MRI-determined bone oedema in psoriatic arthritis. *Ann Rheum Dis* 2007;66(6):778–81, <https://doi.org/10.1136/ard.2006.063818>.
50. Miyanishi K, Hara T, Hamada T, Maekawa M, Tsurusaki S, Moro-oka T, *et al.* Co-occurrence of subchondral insufficiency fracture of the femoral head and contralateral femoral neck fracture in a rheumatic patient receiving steroid treatment. *Mod Rheumatol* 2008;18(6):619–22, <https://doi.org/10.1007/s10165-008-0093-5>.
51. Zhao G, Yamamoto T, Ikemura S, Nakashima Y, Mawatari T, Motomura G, *et al.* A histopathological evaluation of a concave-shaped low-intensity band on T1-weighted MR images in a subchondral insufficiency fracture of the femoral head. *Skeletal Radiol* 2010;39(2):185–8, <https://doi.org/10.1007/s00256-009-0750-6>.
52. Yamamoto T, Schneider R, Bullough PG. Subchondral insufficiency fracture of the femoral head: histopathologic correlation with MRI. *Skeletal Radiol* 2001;30(5):247–54.
53. Daffner RH, Pavlov H. Stress fractures: current concepts. *Am J Roentgenol* 1992;159(2):245–52, <https://doi.org/10.2214/ajr.159.2.1632335>.