



Universiteit
Leiden
The Netherlands

Phenotypic spectrum of TGFB3 disease-causing variants in a Dutch-French cohort and first report of a homozygous patient

Marsili, L.; Overwater, E.; Hanna, N.; Baujat, G.; Baars, M.J.H.; Boileau, C.; ... ; Arnaud, P.

Citation

Marsili, L., Overwater, E., Hanna, N., Baujat, G., Baars, M. J. H., Boileau, C., ... Arnaud, P. (2020). Phenotypic spectrum of TGFB3 disease-causing variants in a Dutch-French cohort and first report of a homozygous patient. *Clinical Genetics*, 97(5), 723-730.

doi:10.1111/cge.13700

Version: Publisher's Version




License: [Creative Commons CC BY 4.0 license](https://creativecommons.org/licenses/by/4.0/)

Downloaded from: <https://hdl.handle.net/1887/3184981>

Note: To cite this publication please use the final published version (if applicable).

SHORT REPORT

Phenotypic spectrum of *TGFB3* disease-causing variants in a Dutch-French cohort and first report of a homozygous patient

Luisa Marsili^{1,2}  | Eline Overwater^{2,3} | Nadine Hanna^{4,5} | Geneviève Baujat⁶ | Marieke J.H. Baars³ | Catherine Boileau^{4,5,7} | Dominique Bonneau⁸ | Anne Claire Brehin⁹ | Yline Capri¹⁰ | Ho Y. Cheung³ | Eelco Dulfer¹¹ | Marion Gerard¹² | Laurent Gouya⁷ | Yvonne Hilhorst-Hofstee¹³ | Arjan C. Houweling² | Bertrand Isidor¹⁴ | Lauriane Le Gloan¹⁵ | Leonie A. Menke³ | Sylvie Odent¹⁶ | Fanny Morice-Picard¹⁷ | Clemence Vanlerberghe¹  | Els Voorhoeve² | J. Peter van Tintelen^{3,18} | Alessandra Maugeri² | Pauline Arnaud^{4,5} 

¹Clinique de Génétique, CHU Lille, Lille, France

²Department of Clinical Genetics, Amsterdam UMC, Vrije Universiteit Amsterdam, Amsterdam, The Netherlands

³Department of Clinical Genetics, Amsterdam UMC, University of Amsterdam, Amsterdam, The Netherlands

⁴Département de Génétique, Assistance Publique-Hôpitaux de Paris, Hôpital Bichat, Paris, France

⁵Laboratory for Vascular Translational Science, INSERM U1148, Université Paris Diderot, Hôpital Bichat, Paris, France

⁶Service de Génétique, INSERM U781, Hôpital Necker-Enfants Malades, Institut Imagine, University Sorbonne-Paris-Cité, Paris, France

⁷Assistance Publique-Hôpitaux de Paris, Hôpital Bichat, Faculté Paris Diderot, LVTS INSERM U 1148, Centre de Référence Pour le Syndrome de Marfan et Apparentés, Paris, France

⁸Service de génétique, CHU d'Angers, Angers, France

⁹Department of Genetics, Normandy Centre for Genomic and Personalized Medicine, Normandie University, UNIROUEN, Inserm U1245 and Rouen University Hospital, Rouen, France

¹⁰Department of Genetics, AHP-ROBERT DEBRE University Hospital, Denis Diderot School of Medicine, Paris University, Paris, France

¹¹Department of Medical Genetics, University Medical Center Groningen, Groningen, The Netherlands

¹²Service de Génétique, CHU Caen, Caen, France

¹³Department of Clinical Genetics, Leiden University Medical Center, Leiden, The Netherlands

¹⁴Service de Génétique Médicale, CHU Nantes, Nantes, France

¹⁵Clinique Cardiologique et des Maladies Vasculaires, CHU Nantes, Nantes, France

¹⁶CHU de Rennes, Service de Génétique Clinique, Université Rennes, CNRS UMR6290 IGDR (Institut de Génétique et Développement de Rennes), Rennes, France

¹⁷Service de dermatologie, Unité de Dermato-Pédiatrie du CHU de Bordeaux, Bordeaux, France

¹⁸Department of Genetics, Utrecht University Medical Center, Utrecht University, Utrecht, The Netherlands

Correspondence

Luisa Marsili, CHU Lille, Clinique de Génétique, Hôpital Jeanne de Flandre, Avenue Eugène Avinée 59037, Lille, France.
Email: luisa.marsili@chru-lille.fr

Peer Review

The peer review history for this article is

Abstract

Disease-causing variants in *TGFB3* cause an autosomal dominant connective tissue disorder which is hard to phenotypically delineate because of the small number of identified cases. The purpose of this retrospective cross-sectional multicenter study is to elucidate the genotype and phenotype in an international cohort of *TGFB3* patients. Eleven (eight novel) *TGFB3* disease-causing variants were identified in 32 patients (17 families). Aortic

Alessandra Maugeri and Pauline Arnaud contributed equally to this study.

available at <https://publons.com/publon/10.1111/cge.13700>.

root dilatation and mitral valve disease represented the most common cardiovascular findings, reported in 29% and 32% of patients, respectively. Dissection involving distal aortic segments occurred in two patients at age 50 and 52 years. A high frequency of systemic features (65% high-arched palate, 63% arachnodactyly, 57% pectus deformity, 52% joint hypermobility) was observed. In familial cases, incomplete penetrance and variable clinical expressivity were noted. Our cohort included the first described homozygous patient, who presented with a more severe phenotype compared to her heterozygous relatives. In conclusion, *TGFB3* variants were associated with a high percentage of systemic features and aortic disease (dilatation/dissection) in 35% of patients. No deaths occurred from cardiovascular events or pregnancy-related complications. Nevertheless, homozygosity may be driving a more severe phenotype.

KEYWORDS

aortic dilatation, aortic dissection, connective tissue disorder, Loey-Dietz syndrome, *TGFB3*, transforming growth factor beta 3

1 | INTRODUCTION

A heritable connective tissue disorder due to *TGFB3* variants was first described in 2013 and listed in OMIM as Loey-Dietz syndrome-5 (#615582), although controversy exists regarding this nomenclature.^{1,2} Its clinical manifestations mainly involve the skeletal, ocular and cardiovascular systems.

Given the rarity of the disorder, with no more than 50 cases described so far, a precise delineation of its phenotype is yet to be determined.³⁻¹⁰

Here, we report the clinical and genetic findings of 32 patients from 17 families, and we give an overview of all reported *TGFB3* disease-causing variants. Our aim is to achieve a better understanding of the phenotype related to *TGFB3* disease-causing variants.

2 | METHODS

Patients were identified through the diagnostic laboratories at the Department of Clinical Genetics, Amsterdam UMC, Vrije Universiteit Amsterdam, the Netherlands, and at the Département de Génétique, Hôpital Bichat, Paris, France (Supporting Information). Referring physicians were invited to participate in this study by a written invitation and were mailed questionnaires in order to retrospectively collect clinical data. The data collection period was from April 2018 to May 2019. All genetic and clinical data were acquired during standard patient care. Informed consent for publication was obtained from all patients, or their legal representatives, in accordance with the Declaration of Helsinki and national legal regulations.

In order to obtain an overview of all known disease-causing *TGFB3* variants, databases and previously published articles were consulted (Supporting Information).

3 | RESULTS

3.1 | *TGFB3* variants

Eleven (eight novel) variants were detected in our cohort: seven missense, one nonsense, and three splice site variants (Tables 1 and 2). Four variants (36%) were located in the RKKR motif. According to the AMCG criteria,¹⁰ all variants are classified as pathogenic or likely pathogenic except for p.(Asp303Ala) and p.(Ser359Arg) that are variants of unknown significance (Supporting Information). Twenty-six other variants were extrapolated from databases and literature (Table 2).

3.2 | Clinical data

Our cohort consisted of 32 *TGFB3* patients (56% males) from 17 families. Mean age at last evaluation was 32 years (range 4-60 years).

Aortic dilatation or dissection was observed in 11/31 (35%) of patients and exhibited age-related penetrance (Figure 1). Aortic root dilatation occurred in 9/31 (29%) patients, and was associated with dilatation of distal aorta in three patients. Two patients presented with distal aortic dilatation in the absence of aortic root dilatation. Dissection of the aorta occurred in two patients at age 50 and 52. Two patients underwent preventive aortic surgery, both after age 40. Two patients displayed arterial tortuosity. Mitral valve disease (prolapse and/or insufficiency) and aortic valve insufficiency were observed in 9/28 (32%) and 2/28 (7%) of patients, respectively. Neither atrial/ventricular septal defects nor atrioventricular block were noted. Varices of lower limbs were seen in 5/24 (21%) of patients.

Average height was +1.3 SD (range -1 SD to +4 SD). The most common systemic signs were high-arched palate (65%), arachnodactyly (63%), pes planus (63%), pectus deformity (57%), and joint hypermobility (52%), long face (42%), downslanting palpebral

TABLE 1 Summary of the relevant clinical and genetic features of patients in our cohort

ID	Rel	Sex, age ^a	Cardiovascular feature(s)	Systemic feature(s)	FH	Variant	Effect ^b
1	IC	♀, 52	Dissection (AA, 50y, aortic diameter at dissection appr. 63 mm), dilatation (iliac artery, 51y), tortuosity (internal carotid and vertebral arteries), varices	Height +0.5 SD, retrognathia, myopia (−7 dioptries), DPF, crowded teeth, thin upper lip, pointed nose, kyphosis, color blindness, symptomatic hypokalemia (52y)	+	c.170dup p.(Glu58*)	P (Ic)
2	Si	♀, 50	Tortuosity (internal carotid and vertebral arteries)	Hypertelorism, PE, JH, Ara, PP, EB	+	c.170dup p.(Glu58*)	P (Ic)
3	IC	♀, 51	Dilatation (thoracic aorta, 48y), varices (17y)	Height +4 SD, retrognathia, long face, smooth philtrum, BU, HAP, asymmetric pectus, bilateral coxa valga, Ara, PP, EB	+	c.463C>T p.(Arg155Trp)	LP (II)
4	IC	♀, 16	None	Height +1 SD, HAP, PE, breast asymmetry, scoliosis, Ara	?	c.463C>T p.(Arg155Trp)	LP (II)
5	IC	♂, 21	Dilatation (AoR, 16y)	Height +3.5 DS, dolichocephaly, retrognathia, myopia, DPF, HAP, cleft palate, PC, kyphoscoliosis, JH, Ara, PP, sternoclavicular subluxation, SS, autoimmune thrombocytopenia, chronic diarrhea	?	p.516+1G>A p.?	LP (I)
6	IC	♂, 50	Dilatation (AoR, Bentall procedure 42y), mitral valve insufficiency, DCM, arrhythmia	Midface hypoplasia, HAP, scoliosis, JH, increased AHR, Ara, EB, delayed wound healing, thin translucent skin, soft velvety skin, subcutaneous fat markedly reduced	?	c.517-3_517-2delinsAG p.?	LP (I)
7	IC	♀, 10	Mitral valve prolapse and insufficiency, billowing of the tricuspid valve	Height +1.5 SD, retrognathia, long face, hypertelorism, DPF, prominent eyes, HAP, scoliosis, JH, Ara, PP, camptodactyly, hammertoes, thin translucent skin, subcutaneous fat markedly reduced, decreased muscle mass	De novo	c.889A>G p.(Arg297Gly)	LP (V)
8	IC	♂, 58	Dilatation (AAo, AoR), aortic valve insufficiency, IDavid procedure (57y), varices	Height +3 SD, dolichocephaly, retrognathia, long face, midface hypoplasia, unilateral DPF, HAP, Ara, subcutaneous fat markedly reduced	−	c.898C>T p.(Arg300Trp)	P (IIIb)
9	IC	♂, 6	Mitral valve prolapse	BU, PE, JH, Ara, thoracic kyphosis, foot eversion	De novo	c.898C>T p.(Arg300Trp)	P (IIIb)
10	IC	♂, 27	Upper normal limit of AoR diameter, mitral valve insufficiency, moderate dilatation of the left ventricle	Height +1.5 SD, exotropia, downslanting palpebral fissures, BU, HAP, PC, scoliosis, dolichostenomelia, Ara, PP, SS, dural ectasia	−	c.898C>T p.(Arg300Trp)	P (IIIb)
11	IC	♂, 54	Dissection (Type B extending to the AA, 52y, aortic isthmus diameter at dissection 71 mm), dilatation (AoR, 52y)	Height +1 SD, cataract (bilateral, surgery 52y and 53y), myopia, BU, pneumothorax (14y), JH, PP, hyperelasticity of the skin, subdural hematoma, IH (53y), angioneurotic edema	+	c.898C>T p.(Arg300Trp)	P (IIIb)
12	So	♂, 14	Dilatation (AoR, 14y)	Height +0.5 SD, midface hypoplasia, myopia, BU, HAP, PE, increased AHR, Ara, PP	+	c.898C>T p.(Arg300Trp)	P (IIIb)
13	IC	♀, 12	Mitral valve prolapse	Height +0.5 SD, long face, hypertelorism, blue sclerae, BU,	+	c.898C>T p.(Arg300Trp)	P (IIIb)

(Continues)

TABLE 1 (Continued)

ID	Rel	Sex, age ^a	Cardiovascular feature(s)	Systemic feature(s)	FH	Variant	Effect ^b
				HAP, posterior cleft palate, JH, Ara, PP, EB, delayed wound healing, thin translucent skin, soft velvety skin			
14	Mo	♀, 35	None	Height +0.5 SD, long face, smooth philtrum, hypertelorism, blue sclerae, DPF, HAP, hiatal hernia (18y), JH, increased AHR, Ara, PP, hallux valgus, EB, delayed wound healing, thin translucent skin, soft velvety skin	+	c.898C>T p.(Arg300Trp)	P (IIIb)
15	Si	♀, 6	Mitral valve prolapse	Height +1 SD, metopic ridge, retrognathia, long face, hypertelorism, blue sclerae, DPF, ptosis, HAP, JH, Ara, PP, hallux valgus, EB, delayed wound healing, thin translucent skin, soft velvety skin	+	c.898C>T p.(Arg300Trp)	P (IIIb)
16	MU	♀, 40	Mitral valve prolapse and insufficiency	Height +2.3 SD, long face, hypertelorism, flat cornea, PC, osteoarthritis, kyphoscoliosis, JH, Ara, PP, patellar tendon rupture, fatigue, EB, thin translucent skin, soft velvety skin, skin hyperextensibility	+	c.898C>T p.(Arg300Trp)	P (IIIb)
17	MCo	♂, 8	Mitral valve insufficiency (7y)	Height +2.5 SD, dolichocephaly, long face, blue sclerae, DPF, ptosis, HAP, hypermetropia, strabismus, PE, JH, Ara, PP, genu valgum, EB, thin translucent skin, soft velvety skin, congenital hypotonia, delay of motor development, frequent falls	+	c.898C>T p.(Arg300Trp)	P (IIIb)
18	IC	♂, 30	Incomplete RBBB	Dolichocephaly, BU, PE, scoliosis, JH, increased AHR, Ara, acetabular protrusion, cavus foot, SS, dural ectasia, IH	?	c.898C>T p.(Arg300Trp)	P (IIIb)
19 ^c	IC	♂, 44	Varices	Height +3 SD, PC, JH, increased AHR, clubfeet, coxarthrosis	+	c.899G>A p.(Arg300Gln)	P (IIIb)
20	So	♂, 4	Mitral valve prolapse	Height +2 SD, dolichocephaly, long face, hypertelorism, myopia, BU, high forehead, frontal bossing, short philtrum, PE, JH, PP, congenital hypotonia (mild), delay of motor development	+	c.899G>A p.(Arg300Gln)	P (IIIb)
21	Si	♀, 52	None	Height +3 SD, long face, prominent eyes, PC, bilateral coxa valga, JH, increased AHR, Ara, left pes planus, right pes cavus, clubfeet, EB, soft velvety skin, decreased muscle mass	+	c.899G>A p.(Arg300Gln)	P (IIIb)
22	Ne	♂, 8	None	Height +2 SD, HAP, anomaly of teeth position, PP, IH (unilateral)	+	c.899G>A p.(Arg300Gln)	P (IIIb)
23	IC	♂, 52	Dilatation (AoR, 52y), mitral valve prolapse and insufficiency	Height -0.5 SD, PE, osteoarthritis, increased AHR, osteoporosis (51y), kyphosis, pinching vertebral	-	c.908A>C p.(Asp303Ala)	VUS

(Continues)

TABLE 1 (Continued)

ID	Rel	Sex, age ^a	Cardiovascular feature(s)	Systemic feature(s)	FH	Variant	Effect ^b
				discs, subcutaneous fat markedly reduced			
24	IC	♂, 18	None	Height +2 SD, dolichocephaly, BU, HAP, cleft palate, PE, spondylolisthesis, JH, Ara, PP, decreased muscle mass	De novo	c.952C>T p.(Arg318Cys)	LP (V)
25 ^c	IC	♂, 60	Dilatation (AoR 46 mm, 25y; AoR 55 mm, 57y; AAO 48 mm, 57y), aortic valve insufficiency (25y), paroxysmal supraventricular tachycardia (55y)	Height 0 SD, myopia, amblyopia, DPF, HAP, PP (during childhood), UH	+	c.1075A>C p.(Ser359Arg)	VUS
26	Dau	♀, 33	None	Height -1 SD, hypermetropia	+	c.1075A>C p.(Ser359Arg)	VUS
27	Si	♀, 58	None	Height -0.6 SD, cataract (unilateral, surgery at 49y), myopia	+	c.1075A>C p.(Ser359Arg)	VUS
28	IC	♀, 22	Dilatation (AoR, 17y)	Height +1.5 SD (target height -0.3 SD) retrognathia, long face, hypertelorism, myopia, DPF, prominent eyes, low-set ears, overbite, BU, cleft palate, PE, spondylolisthesis, scoliosis, increased AHR, Ara, PP, thin translucent skin, subcutaneous fat markedly reduced, decreased muscle mass, diaphragmatic hernia, UH	+	c.1081-2A>T ^d p.?	P (lc)
29	Br	♂, 18	NA	Height -1 SD, BU, dental crowding, PP, congenital hip dysplasia	+	c.1081-2A>T p.?	P (lc)
30	Si	♀, 10	None	Height +1 SD, myopia (-5.5/-5.75 dioptres), HAP	+	c.1081-2A>T p.?	P (lc)
31	Mo	♀, 41	None	Height 0 SD, 163.5 cm, DPF, HAP, broad uvula	+	c.1081-2A>T p.?	P (lc)
32	F	♂, 49	Dilatation (AoR 39 mm, 49y), varices	Height -0.5 SD, hypertelorism, cataracts (bilateral, 47y), myopia (-1.6 dioptres), broad uvula, PC (mild), increased AHR, osteoporosis, EB, thin translucent skin, IH (unilateral, 34y), UH	+	c.1081-2A>T p.?	P (lc)

Note: Used TGFB3 RefSeq transcripts (based on Genome build: GRCh37/hg19): NC_000014.8(NM_003239.4).

Abbreviations: AA, abdominal aorta; AAo, ascending aorta; AHR, arm/height ratio; AoA, aortic arch; AoR, aortic root; Ara, arachnodactyly; Br, brother; BU, bifid uvula; Dau, daughter; Dao, descending aorta; DCM, dilated cardiomyopathy; DPF, downslanting palpebral fissures; EB, easy bruising; F, father; FH, family history; HAP, highly arched palate; JH, joint hypermobility; IC, index case; IH, inguinal hernia; LP, likely pathogenic; MA, maternal aunt; MCo, maternal cousin; MFS, Marfan syndrome; Mo, mother; MU, maternal uncle; NA, no information available; Ne, nephew; Ni, niece; P, pathogenic; PA, paternal aunt; PC, pectus carinatum; PE, pectus excavatum; PP, pes plani; Rel, relationship; RBBB, right bundle branch block; Rel, relationship; SD, standard deviation; Si, sister; So, son; SS, skin striae; UH, umbilical hernia; VUS, variant of unknown significance; y, age at diagnosis (years); +, known family history; -, no family history; ?, unknown.

^aAge (in years) at last evaluation.

^bAccording to the AMCG criteria (Richard et al¹¹).

^cThis patient is recently described in literature (Overwater et al⁷).

^dHomozygote.

fissures (39%), bifid uvula (38%), increased arm span (36%), easy bruising (34%), thin translucent skin (32%), myopia (33%), hypertelorism (32%), and scoliosis (30%). Some of the features previously associated with variants in *TGFB3* were not observed (brachycephaly, wide face, ectopia lentis, scapulae alata, cervical spine instability, contractures of fingers, palmar flexion, transient postnatal pes adductus, low birth weight), or were observed in 10% of patients or

less (metopic ridge, midface hypoplasia, smooth philtrum, exotropia, ptosis, cerebral hemorrhage, osteoporosis, camptodactyly of toes, hiatal hernia, osteoarthritis, spondylolisthesis, bilateral coxa valga, congenital hypotonia, delayed motor development, autoimmune disease).

No major vascular or visceral complication occurred in 18 pregnancies (six women).

TABLE 2 Overview of all reported *TGFB3* disease-causing variants

Nucleotide change	Protein change	Domain	gnomAD allele count	Reference(s)
c.106A>T	p.(Lys36*)	LAP	0	Schepers et al ⁸
c.170dup	p.(Glu58*)	LAP	0	Current study
c.321dup	p.(Phe108Ilefs*18)	LAP	0	ClinVar
c.353-1G>C	p.?	LAP	0	ClinVar
c.427A>T	p.(Arg143*)	LAP	0	Ziganshin et al ⁹
c.437del	p.(Leu146Hisfs*68)	LAP	0	Schepers et al ⁸
c.463C>T	p.(Arg155Trp)	LAP	0	Current study
c.516+1G>A	p.?	LAP	0	Current study
c.517-3_517-2delinsAG	p.?	LAP	0	Current study
c.517-1G>C	p.?	LAP	0	ClinVar
c.704del	p.(Asn235Metfs*11)	LAP	0	Bertoli-Avella et al ³
c.754+2T>C	p.Glu216_Lys251del	LAP	0	Bertoli-Avella et al ³
c.787G>C	p.(Asp263His)	LAP	0	Bertoli-Avella et al ³ ; Schepers et al ⁸
c.796C>T ^a	p.(Arg266Cys)	LAP	3	Schepers et al ⁸
c.826C>T	p.(Pro276Ser)	LAP	0	ClinVar
c.883_884del	p.(Gly295Serfs*28)	LAP	1	ClinVar
c.889A>G	p.(Arg297Gly)	RKKR motif	0	Current study
c.898C>T	p.(Arg300Trp)	RKKR motif	0	Bertoli-Avella et al ³ ; Schepers et al ⁸ ; Current study
c.898C>G	p.(Arg300Gly)	RKKR motif	0	Kuechler et al ⁵
c.899G>A	p.(Arg300Gln)	RKKR motif	0	Matyas et al ⁶ ; Kim et al ⁴ ; Schepers et al ⁸ ; Overwater et al ⁷ ; Current study ^b
c.908A>C ^a	p.(Asp303Ala)	Cytokine	4	Current study
c.916del	p.(Tyr306Thrfs*63)	Cytokine	0	ClinVar
c.927-1G>C	p.?	Cytokine	1	ClinVar
c.952C>T	p.(Arg318Cys)	Cytokine	0	Current study
c.965T>C	p.(Ile322Thr)	Cytokine	2	Bertoli-Avella et al ³
c.979G>T	p.(Asp327Tyr)	Cytokine	1	Schepers et al ⁸
c.989G>A	p.(Trp330*)	Cytokine	0	ClinVar
c.1020T>A	p.(Tyr340*)	Cytokine	0	ClinVar
c.1034C>G	p.(Ser345*)	Cytokine	0	ClinVar
c.1075A>C ^a	p.(Ser359Arg)	Cytokine	0	Overwater et al ⁷ ; Current study ^b
c.1081-2A>T ^c	p.?	Cytokine	0	Current study
c.1095C>A	p.(Tyr365*)	Cytokine	0	Bertoli-Avella et al ³
c.1102_1105del	p.(Leu368Thrfs*18)	Cytokine	0	ClinVar
c.1157del	p.(Leu386Argfs*21)	Cytokine	0	Bertoli-Avella et al ³
c.1195G>T	p.(Glu399*)	Cytokine	0	ClinVar
c.1202T>C	p.(Leu401Pro)	Cytokine	0	Bertoli-Avella et al ³ ; Schepers et al ⁸
c.1226G>A	p.(Cys409Tyr)	Cytokine	0	Rienhoff et al ¹

Note: Used *TGFB3* RefSeq transcript (GRCh37/hg19): NC_000014.8(NM_003239.4).

^aVariant of unknown significance.

^bSame patient is reported by Overwater et al⁷ and in the current study.

^cIndex case is homozygote.

3.3 | Homozygous patient

Patient #28 was the first child of consanguineous parents of Moroccan origin. She was born at 38/2 weeks of gestation. Birth weight was 2930 g. Cleft palate, umbilical hernia, and joint contractures (involving

elbows, knees, and feet, which improved significantly over time) were diagnosed shortly after birth. Arachnodactyly and dysmorphic craniofacial features, including micrognathia and low-set ears, were also observed in the neonatal period. She was later diagnosed with a left-sided bochdalek hernia and developed pectus excavatum, L5-S1

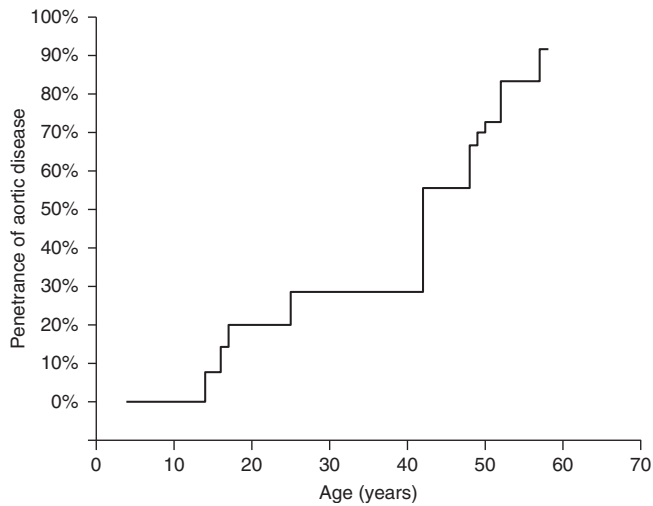


FIGURE 1 Inverted Kaplan–Meier curve indicating the age-related penetrance of aortic disease, with age at first aortic event (dilatation/dissection/surgery) as the survival variable

spondylolisthesis, scoliosis, severe myopia, and dilatation of the aortic root (Z-score 2.14 at age 17 years). She received medroxyprogesterone and ethinylestradiol for anti-growth purposes, and she was treated by long-term nocturnal gastrostomy feedings to improve her nutritional status. Both motor and cognitive developments were normal. Genetic testing revealed a homozygous c.1081-2A>T *TGFB3* variant (Supporting Information). Both parents (patients #31 and #32), a brother (patient #29), and a sister (patient #30) were heterozygous and were less severely affected. Another sibling did not carry the variant and displayed no sign of the disease.

4 | DISCUSSION

Our findings are largely in line with the most comprehensive report on *TGFB3* variants published before.⁸ Aortic disease (dilatation or dissection) affected 35% of patients showing age-related penetrance (Figure 1). No aortic dilatation occurred before the age of 14 years. Arterial dissections occurred at dilated aortic segments after the age of 50 years in two patients who displayed marked systemic features. No deaths related to cardiovascular or pregnancy complications were observed. Men were more likely to be diagnosed with aortic disease, but difference between men and women was not significant. Arterial tortuosity was observed in two patients. Two patients were diagnosed with dural ectasia, a clinical feature which was not previously described in association with *TGFB3* variants. As *TGFB3* patients are not systematically screened for dural ectasia, whether this is a coincidental finding or an underestimated clinical feature remains unclear.

Compared to Schepers et al,⁸ we identified a higher rate of downslanting palpebral fissures (39% vs 15%), and a lower rate of joint hypermobility (52% vs 80%), scoliosis (30% vs 69%), and osteoarthritis (8% vs 46%). Clubfoot was reported by Schepers and colleagues in 25% (3/12) of patients.⁸ Two (7%) related patients in our

cohort presented with clubfoot. However, clubfoot in this family may not be related to the *TGFB3* variant since a family member, who did not have the *TGFB3* variant, exhibited clubfoot in the absence of any other systemic feature (cardiac investigation not performed). Differences in results between previous studies and ours may reflect differences in clinical assessment and/or in reason of referral for genetic testing.

Consistently with data from literature and databases, in our cohort we observed missense, splice site, and truncating variants spanning the entire gene, with a mutation hotspot in the RKKR motif.

Finally, we described the first homozygous *TGFB3* patient, who presented with aortic dilatation at a younger age and more marked systemic features, compared to her heterozygous relatives.

4.1 | Limitations of the study

This study is limited by small patient numbers, relatively young age of patients, possible ascertainment bias due to recruitment, and retrospective nature of the data.

5 | CONCLUSION

No more than 50 patients carrying disease-causing *TGFB3* variants have been reported so far.^{1,3-9} Here, we described genetic and clinical data from 32 *TGFB3* patients from 17 families including the first homozygous individual.

In our cohort, variants in *TGFB3* were associated with a high frequency of systemic features. Aortic disease (dilatation or dissection) was revealed in 35% of patients, but no increased overall mortality nor pregnancy complications were observed. Nevertheless, homozygosity might be associated with a more severe phenotype.

Finally, we suggest that regular surveillance of distal aorta is appropriate in *TGFB3* patients.

CONFLICT OF INTEREST

None.

DATA AVAILABILITY STATEMENT

Data supporting the findings of this study are available from the corresponding author.

ORCID

Luisa Marsili  <https://orcid.org/0000-0002-6691-541X>

Clemence Vanlerberghe  <https://orcid.org/0000-0003-3884-2054>

Pauline Arnaud  <https://orcid.org/0000-0001-9727-1592>

REFERENCE

- Rienhoff HY Jr, Yeo CY, Morissette R, et al. A mutation in *TGFB3* associated with a syndrome of low muscle mass, growth retardation, distal arthrogyrosis and clinical features overlapping with Marfan and Loeys-Dietz syndrome. *Am J Med Genet A*. 2013;161A(8):2040-2046. <https://doi.org/10.1002/ajmg.a.36056>.

2. Pyeritz R, Jondeau G, Moran R, et al. Loeys-Dietz syndrome is a specific phenotype and not a concomitant of any mutation in a gene involved in TGF- β signaling. *Genet Med*. 2014;16(8):641-642. <https://doi.org/10.1038/gim.2014.63>.
3. Bertoli-Avella AM, Gillis E, Morisaki H, et al. Mutations in a TGF- β ligand, TGFB3, cause syndromic aortic aneurysms and dissections. *J Am Coll Cardiol*. 2015;65(13):1324-1336. <https://doi.org/10.1016/j.jacc.2015.01.040>.
4. Kim YM, Lee YJ, Park JH, et al. High diagnostic yield of clinically unidentifiable syndromic growth disorders by targeted exome sequencing. *Clin Genet*. 2017 Dec;92(6):594-605. <https://doi.org/10.1111/cge.13038>.
5. Kuechler A, Altmüller J, Nürnberg P, Kotthoff S, Kubisch C, Borck G. Exome sequencing identifies a novel heterozygous TGFB3 mutation in a disorder overlapping with Marfan and Loeys-Dietz syndrome. *Mol Cell Probes*. 2015;29(5):330-334. <https://doi.org/10.1016/j.mcp.2015.07.003>.
6. Matyas G, Naef P, Tollens M, Oexle K. De novo mutation of the latency-associated peptide domain of TGFB3 in a patient with overgrowth and Loeys-Dietz syndrome features. *Am J Med Genet A*. 2014;164A(8):2141-2143. <https://doi.org/10.1002/ajmg.a.36593>.
7. Overwater E, Marsili L, Baars MJH, et al. Results of next-generation sequencing gene panel diagnostics including copy-number variation analysis in 810 patients suspected of heritable thoracic aortic disorders. *Hum Mutat*. 2018;39(9):1173-1192. <https://doi.org/10.1002/humu.23565>.
8. Schepers D, Tortora G, Morisaki H, et al. A mutation update on the LDS-associated genes TGFB2/3 and SMAD2/3. *Hum Mutat*. 2018;39(5):621-634. <https://doi.org/10.1002/humu.23407>.
9. Ziganshin BA, Bailey AE, Coons C, et al. Routine genetic testing for thoracic aortic aneurysm and dissection in a clinical setting. *Ann Thorac Surg*. 2015;100(5):1604-1611. <https://doi.org/10.1016/j.athoracsur.2015.04.106>.
10. Renard M, Francis C, Ghosh R, et al. Clinical validity of genes for heritable thoracic aortic aneurysm and dissection. *J Am Coll Cardiol*. 2018;72(6):605-615. <https://doi.org/10.1016/j.jacc.2018.04.089>.
11. Richards S, Aziz N, Bale S, et al. Standards and guidelines for the interpretation of sequence variants: a joint consensus recommendation of the American College of Medical Genetics and Genomics and the Association for Molecular Pathology. *Genet Med*. 2015;17(5):405-424. <https://doi.org/10.1038/gim.2015.30>.

SUPPORTING INFORMATION

Additional supporting information may be found online in the Supporting Information section at the end of this article.

How to cite this article: Marsili L, Overwater E, Hanna N, et al. Phenotypic spectrum of *TGFB3* disease-causing variants in a Dutch-French cohort and first report of a homozygous patient. *Clin Genet*. 2020;97:723-730. <https://doi.org/10.1111/cge.13700>