



Universiteit  
Leiden  
The Netherlands

## **Management of multiple secreting paragangliomas in a succinate dehydrogenase subunit D (SDHD) variant carrier**

Rijken, J.A.; Vos, B. de; Leemans, C.R.; Zwezerijnen, G.J.C. ben; Graaf, P. de; Hensen, E.F.; ... ; Symersky, P.

### **Citation**

Rijken, J. A., Vos, B. de, Leemans, C. R., Zwezerijnen, G. J. C. ben, Graaf, P. de, Hensen, E. F., ... Symersky, P. (2020). Management of multiple secreting paragangliomas in a succinate dehydrogenase subunit D (SDHD) variant carrier. *The Annals Of Thoracic Surgery*, 109(2), E87-E90. doi:10.1016/j.athoracsur.2019.05.037

Version: Publisher's Version  
License: [Creative Commons CC BY 4.0 license](#)  
Downloaded from: <https://hdl.handle.net/1887/3184974>

**Note:** To cite this publication please use the final published version (if applicable).

# Management of Multiple Secreting Paragangliomas in a Succinate Dehydrogenase Subunit D (*SDHD*) Variant Carrier



Johannes A. Rijken, MD, Berry de Vos, MD, C. René Leemans, MD, PhD, G. J. C. Ben Zwezerijnen, MD, Pim de Graaf, MD, PhD, Erik F. Hensen, MD, PhD, Koen M. A. Dreijerink, MD, PhD, Chris Dickhoff, MD, PhD, and Petr Symersky, MD, PhD

Department of Otolaryngology/Head and Neck Surgery, Amsterdam University Medical Center, Vrije Universiteit, Amsterdam; Department of Radiology and Nuclear Medicine, Cancer Center Amsterdam, Amsterdam University Medical Center, Vrije Universiteit, Amsterdam; Department of Otolaryngology/Head and Neck Surgery, Leiden University Medical Center, Leiden; Department of Endocrinology, Amsterdam University Medical Center, Vrije Universiteit, Amsterdam; Department of Surgery, Amsterdam UMC, Vrije Universiteit, Amsterdam; and Department of Cardiothoracic Surgery, Amsterdam University Medical Center, Vrije Universiteit, Amsterdam, the Netherlands

**Management of functional intrathoracic sympathetic paragangliomas in succinate dehydrogenase subunit D (*SDHD*) mutation carriers is challenging, and there is no uniform guideline for treatment to date. The risks of potential malignant behavior and long-term cardiovascular morbidity have to be weighed against the risks of treatment complications. We report the multidisciplinary and shared decision-making approach that resulted in successful surgical removal of 3 paragangliomas in a *SDHD* mutation carrier.**

(*Ann Thorac Surg* 2020;109:e87-90)

© 2020 by The Society of Thoracic Surgeons

**I**n patients with familial paraganglioma (PGL) syndrome 1, due to succinate dehydrogenase subunit D (*SDHD*) gene mutations (Online Mendelian Inheritance in Man catalog: 168000), PGLs predominantly arise in the head and neck region (HNPG). HNPGs are of parasympathetic origin and generally nonfunctional.<sup>1,2</sup> Growing insight into the usually indolent natural course of HNPGs and the considerable surgical risk of cranial nerve and vessel damage has resulted in a more conservative management approach.

Less common sympathetic PGLs (sPGLs) in the thorax, abdomen, and pelvis, and pheochromocytomas are of sympathetic origin and may cause catecholamine hypersecretion.<sup>3</sup> Sudden death by stroke or cardiac arrest due to acute catecholamine excess has been

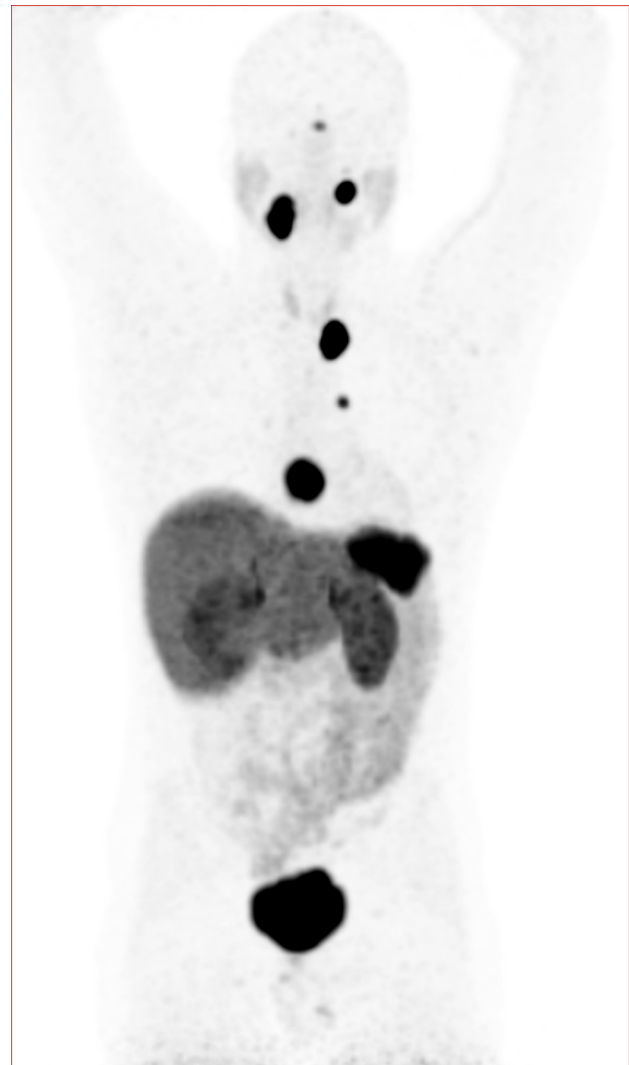

Figure 1. Gallium Ga 68-DOTATATE positron emission tomographic scan (coronal maximum intensity projection) demonstrates 5 somatostatin receptor-expressing paragangliomas located at the right carotid bifurcation, left vagal nerve, left carotid artery, aortopulmonary window, and posterior of the left cardiac atrium. Physiological tracer distribution is seen in the pituitary, salivary glands, thyroid, liver, adrenals, spleen, and in the urinary and gastrointestinal tract.

reported. Prolonged exposure to high catecholamine levels may eventually result in cardiac hypertrophy, myocardial infarction, or heart failure. Therefore, surgical excision is the treatment of choice in functional sPGLs.<sup>3-6</sup> The risks and benefits of PGL surgery warrant a careful multidisciplinary approach, as illustrated by this case presentation.

Accepted for publication May 7, 2019.

Address correspondence to Dr Rijken, Department of Otolaryngology/Head and Neck Surgery, Amsterdam University Medical Centers, VU University Medical Center, De Boelelaan 1117, 1081 HZ Amsterdam, the Netherlands; email: [johannesrijken@hotmail.com](mailto:johannesrijken@hotmail.com).

Dr Leemans discloses a financial relationship with MSD.

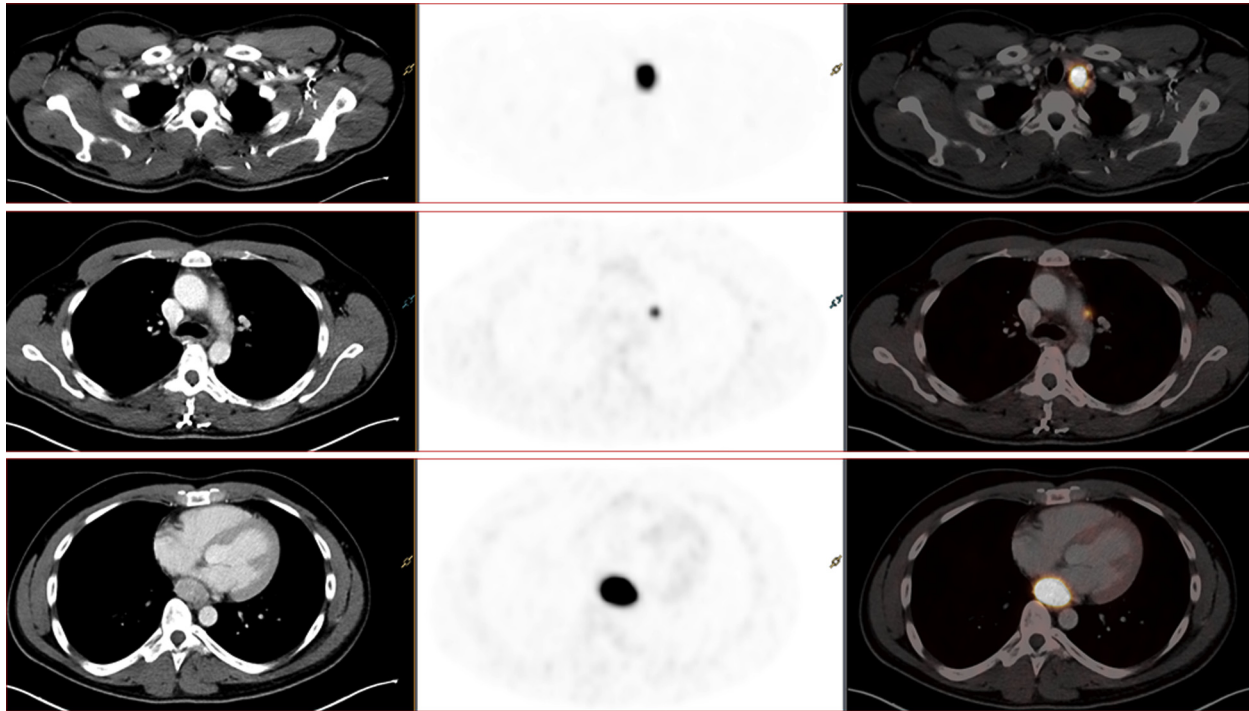


Figure 2. Gallium Ga 68-DOTATATE positron emission tomographic (PET) computed tomographic (CT) scan (axial plane) of the patient presenting the paragangliomas located next to the left carotid artery, aortopulmonary window, and posterior to the left cardiac atrium. (Left column, CT scan; middle column, attenuation corrected PET image; right column, PET-CT fused.)

A 29-year-old man reported a cervical mass and recurrent episodes of severe headache, palpitations, and hyperhidrosis. Clinical examination revealed a right-sided swelling in level II of the neck region measuring 2 × 1.5 cm and hypertension on repeated measurements. The result of flexible laryngoscopy was normal. Magnetic resonance imaging of the head and neck revealed multiple masses suggestive of HNPGL: at the right carotid bifurcation (Shamblin classification type 2), along the left vagal nerve, and at the left carotid artery. The patient's father was a known *SDHD*-linked PGL patient. DNA analysis confirmed the *SDHD* c.416T>C germline mutation.

Blood tests repeatedly showed excess serum normetanephrine (10.00 nmol/L; reference range, 0-0.62 nmol/L) and 3-methoxytyramine levels (1.75 nmol/L; reference range, 0-0.10 nmol/L). Scintigraphy with iodine I 123 (<sup>123</sup>I)-meta-iodobenzylguanidine (MIBG) demonstrated weak tracer accumulation at the left supraclavicular fossa and an additional intense focus in the posterior mediastinum. However, the other lesions could not be detected. Gallium Ga 68-DOTATATE positron emission tomography showed somatostatin receptor expression in the 3 HNPGLs, the aortopulmonary window PGL, and a fifth lesion posterior to the left atrium (Figures 1, 2).

Therapeutic options were discussed in the multidisciplinary tumor board and with the patient, weighing potential risks and benefits of each treatment strategy according to the tumor site. This shared decision-making process initially resulted in a wait-and-see policy for all

tumors. Treatment with  $\alpha$ -adrenoreceptor antagonist was not possible due to medication-related fatigue that interfered with the patient's daily activities.

After 2 years, imaging studies of the thorax showed tumor growth of the retrocardiac lesion, and symptoms of excessive catecholamine production had increased. After consideration of various options, a surgical plan was devised for removal of the intrathoracic lesions. The patient was admitted 2 weeks before surgery for  $\alpha$ -blockade.

Through a transcervical and midsternal approach, the PGLs at the left carotid artery, aortopulmonary window, and posterior of the left cardiac atrium were removed in an uneventful procedure (Figure 3). First, the mass next to the left carotid was explored and removed with sparing of the left carotid artery and the vagal and phrenic nerves. Subsequently, the lesion on the left pulmonary artery was identified and removed.

The third tumor was a highly vascular sessile lesion attached to the posterior wall of the left atrium between the origin of the right interior pulmonary vein and the inferior vena cava. Removal was only possible with the support of extracorporeal circulation and after cardioplegic arrest. Excision resulted in a temporary drop in systemic vascular resistance requiring high doses of epinephrine before the patient could be weaned from bypass.

The patient recovered well and was discharged within 1 week. Six weeks later, the patient's complaints had decreased, and his blood pressure and catecholamine



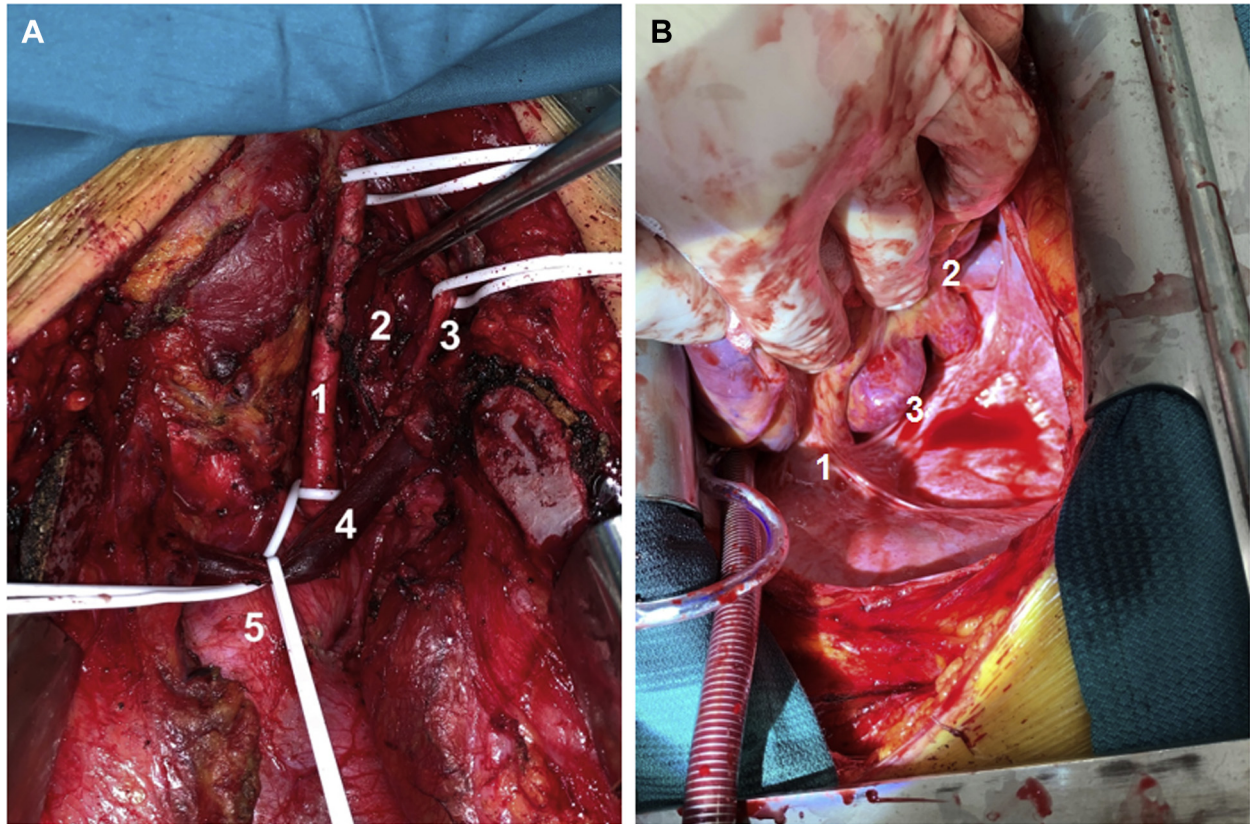


Figure 3. (A) Surgical excision of the paraganglioma located at the left carotid artery, shows the left common carotid artery (1), paraganglioma (2), vagal nerve (3), left brachiocephalic vein (4), and aortic arch (5). (B) Sessile paraganglioma (3) attached to the posterior wall of the left atrium between the left pulmonary veins (2) and the inferior vena cava (1).

levels had normalized. Histopathology confirmed the diagnosis of PGL in all 3 tumors.

### Comment

In this case report, we describe an *SDHD* mutation carrier with symptoms of catecholamine excess in the presence of multiple PGLs. The management of multiple PGLs is challenging, particularly in young patients and when catecholamine hypersecretion is present. The intrathoracic lesions were the likely source(s) of excessive catecholamine secretion.<sup>4</sup> The initial management strategy was active surveillance. However, as a result of tumor growth and progressive symptoms of catecholamine secretion, several alternative options were considered:

- Radiotherapy. The intention would be to stabilize tumor growth; however, the effect of radiotherapy on catecholamine hypersecretion is currently unknown.
- Therapy with <sup>131</sup>I-MIBG. Because of the limited MIBG uptake at scintigraphy, the intrathoracic sPGLs were deemed unlikely to respond to <sup>131</sup>I-MIBG therapy.<sup>7</sup>
- Peptide receptor radionuclide therapy. Targeting the somatostatin receptors in the tumors did not seem appropriate because of the uncertain effect of peptide receptor radionuclide therapy on catecholamine

production and the expected need of prolonged  $\alpha$ -blockade use, which the patient did not tolerate.<sup>8</sup>

- Surgical procedure. Tumor eradication has a predictable positive effect on catecholamine excess production.

The risks of an operation (ie, bleeding, infection, recurrent laryngeal nerve injury), as well as the alternative treatment options, were extensively discussed with patient, who eventually chose a surgical procedure. In addition to the intrathoracic PGLs, the PGL located at the left carotid artery was also planned for surgical resection because of the potential risk of cocontribution of catecholamine hypersecretion by HNPGLs. The operation resulted in successful resection of these 3 PGLs along with a significant decrease of symptoms and catecholamine secretion. The remaining nonfunctional right carotid PGL and left vagal PGL will be closely monitored.

### References

1. Baysal BE, Ferrell RE, Willett-Brozick JE, et al. Mutations in *SDHD*, a mitochondrial complex II gene, in hereditary paraganglioma. *Science*. 2000;287:848-851.
2. van Duinen N, Corssmit EP, de Jong WH, et al. Plasma levels of free metanephrines and 3-methoxytyramine indicate a higher number of biochemically active HNPGL than 24-h urinary excretion rates of catecholamines and metabolites. *Eur J Endocrinol*. 2013;169:377-382.

- van Houtum WH, Corssmit EP, Douwes Dekker PB, et al. Increased prevalence of catecholamine excess and pheochromocytomas in a well-defined Dutch population with SDHD-linked head and neck paragangliomas. *Eur J Endocrinol.* 2005;152:87-94.
- Havekes B, van der Klaauw AA, Weiss MM, et al. Pheochromocytomas and extra-adrenal paragangliomas detected by screening in patients with SDHD-associated head-and-neck paragangliomas. *Endocr Relat Cancer.* 2009;16:527-536.
- Zhang R, Gupta D, Albert SG. Pheochromocytoma as a reversible cause of cardiomyopathy: analysis and review of the literature. *Int J Cardiol.* 2017;249:319-323.
- Gurrieri C, Butz JJ, Weingarten TN, et al. Resection of intrathoracic paraganglioma with and without cardiopulmonary bypass. *Ann Thorac Surg.* 2018;105:1160-1167.
- Lawrence JK, Maher ER, Sheaves R, et al. Familial paraganglioma: a novel presentation of a case and response to therapy with radiolabelled MIBG. *Hormones (Athens).* 2004;3:127-131.
- Makis W, McCann K, McEwan AJ. The challenges of treating paraganglioma patients with (177)Lu-DOTATATE PRRT: catecholamine crises, tumor lysis syndrome and the need for modification of treatment protocols. *Nucl Med Mol Imaging.* 2015;49:223-230.