



Universiteit
Leiden
The Netherlands

**Colonoscopic-assisted laparoscopic wedge resection for colonic lesions
A Prospective Multicenter Cohort Study (LIMERIC-Study) a prospective
multicenter cohort study (LIMERIC-Study)**

Leicher, L.W.; Huisman, J.F.; Grevenstein, W.M.U. van; Didden, P.; Backes, Y.; Offerhaus, G.J.A.; ... ; Westreenen, H.L. van

Citation

Leicher, L. W., Huisman, J. F., Grevenstein, W. M. U. van, Didden, P., Backes, Y., Offerhaus, G. J. A., ... Westreenen, H. L. van. (2022). Colonoscopic-assisted laparoscopic wedge resection for colonic lesions A Prospective Multicenter Cohort Study (LIMERIC-Study): a prospective multicenter cohort study (LIMERIC-Study). *Annals Of Surgery*, 275(5), 933-939. doi:10.1097/SLA.0000000000005417

Version: Publisher's Version
License: [Leiden University Non-exclusive license](#)
Downloaded from: <https://hdl.handle.net/1887/3492268>

Note: To cite this publication please use the final published version (if applicable).

Colonoscopic-assisted Laparoscopic Wedge Resection for Colonic Lesions

A Prospective Multicenter Cohort Study (LIMERIC-Study)

Laura W Leicher, MD, ✉ Jelle F. Huisman, MD,* Wilhelmina M. U. van Grevenstein, MD, PhD, † Paul Didden, MD, PhD, ‡ Yara Backes, MD, PhD, ‡ G. Johan A. Offerhaus, MD, PhD, § Miangela M. Laclé, MD, PhD, § Freek C. P. Moll, MD, ¶ Joost M. J. Geesing, MD, || Niels Smakman, MD, PhD, ** Jochim S. Terhaar Sive Droste, MD, PhD, †† Emiel G. G. Verdaasdonk, MD, PhD, †† Frank ter Borg, MD, PhD, §§ A. Koen Talsma, MD, PhD, ¶¶ G. Willemien Erkelens, MD, |||| Edwin S. van der Zaag, MD, PhD, *** Ruud W. M. Schrauwen, MD, ††† Bob J. van Wely, MD, PhD, ††† Ingrid Schot, MD, §§§ Maarten Vermaas, MD, PhD, ¶¶¶ Jeroen D. van Bergeijk, MD PhD, ||||| Colin Sietses, MD, PhD, **** Wouter L. Hazen, MD, †††† Darczka K. Wasowicz, MD, PhD, †††† Dewkoemar Ramsoekh, MD, PhD, §§§§ Jurriaan B. Tuynman, MD, PhD, ¶¶¶¶ Yasser A. Alderlieste, MD, ||||| Rutger-Jan Renger, MD, ***** Frank A. Oort, MD, PhD, ††††† Ernst Jan Spillenaar Bilgen, MD, PhD, ††††† Frank P. Vleggaar, MD, PhD, † Hans F. A. Vasen, MD, PhD, §§§§§ Wouter H. de Vos tot Nederveen Cappel, MD, PhD,* Leon M. G. Moons, MD, PhD, ‡ and Henderik L. van Westreenen, MD, PhD ¶¶¶¶¶

Objective: The aim of this study was to evaluate the safety and efficacy of a modified CAL-WR.

Summary Background Data: The use of segmental colectomy in patients with endoscopically unresectable colonic lesions results in significant morbidity and mortality. CAL-WR is an alternative procedure that may reduce morbidity.

Methods: This prospective multicenter study was performed in 13 Dutch hospitals between January 2017 and December 2019. Inclusion criteria were (1) colonic lesions inaccessible using current endoscopic resection techniques (judged by an expert panel), (2) non-lifting residual/recurrent adenomatous tissue after previous polypectomy or (3) an undetermined resection margin after endoscopic removal of a low-risk pathological T1 (pT1) colon carcinoma. Thirty-day morbidity, technical success rate and radicality were evaluated.

Results: Of the 118 patients included (56% male, mean age 66 years, standard deviation \pm 8 years), 66 (56%) had complex lesions unsuitable for endoscopic

removal, 34 (29%) had non-lifting residual/recurrent adenoma after previous polypectomy and 18 (15%) had uncertain resection margins after polypectomy of a pT1 colon carcinoma. CAL-WR was technically successful in 93% and R₀ resection was achieved in 91% of patients. Minor complications (Clavien-Dindo i-ii) were noted in 7 patients (6%) and an additional oncologic segmental resection was performed in 12 cases (11%). Residual tissue at the scar was observed in 5% of patients during endoscopic follow-up.

Conclusions: CAL-WR is an effective, organ-preserving approach that results in minor complications and circumvents the need for major surgery. CAL-WR, therefore, deserves consideration when endoscopic excision of circumscribed lesions is impossible or incomplete.

Keywords: colonic polyps, colonoscopic-assisted laparoscopic wedge resection, endoscopically-unresectable, organ preserving surgery

(*Ann Surg* 2022;275:933–939)

From the *Department of Gastroenterology & Hepatology, Isala, Zwolle, The Netherlands; †Department of Surgery, UMC Utrecht, Utrecht, The Netherlands; ‡Department of Gastroenterology & Hepatology, UMC Utrecht, Utrecht, The Netherlands; §Department of Pathology, UMC Utrecht, Utrecht, The Netherlands; ¶Department of Pathology, Isala, Zwolle, The Netherlands; ||Department of Gastroenterology & Hepatology, Diaconessenhuis, Utrecht, The Netherlands; **Department of Surgery, Diaconessenhuis, Utrecht, The Netherlands; ††Department of Gastroenterology & Hepatology, Jeroen Bosch Ziekenhuis, Den Bosch, The Netherlands; †††Department of Surgery, Jeroen Bosch Ziekenhuis, Den Bosch, The Netherlands; §§Department of Gastroenterology & Hepatology, Deventer Ziekenhuis, Deventer, The Netherlands; ¶¶Department of Surgery, Deventer Ziekenhuis, Deventer, The Netherlands; ||||Department of Gastroenterology & Hepatology, Gelre, Apeldoorn, The Netherlands; ***Department of Surgery, Gelre, Apeldoorn, The Netherlands; †††Department of Gastroenterology & Hepatology, Bernhoven, Uden, The Netherlands; ††††Department of Surgery, Bernhoven, Uden, The Netherlands; §§§Department of Gastroenterology & Hepatology, IJsselland Ziekenhuis, Capelle a/d IJssel, The Netherlands; ¶¶¶Department of Surgery, IJsselland Ziekenhuis, Capelle a/d IJssel, The Netherlands; |||||Department of Gastroenterology & Hepatology, Gelderse Vallei, Ede, The Netherlands; ****Department of Surgery, Gelderse Vallei, Ede, The Netherlands; ††††Department of Gastroenterology & Hepatology, Elisabeth-Tweesteden Ziekenhuis, Tilburg, The Netherlands; †††††Department of Surgery, Elisabeth-Tweesteden Ziekenhuis, Tilburg, The Netherlands; §§§§Department of

Gastroenterology & Hepatology, Amsterdam UMC, Amsterdam, The Netherlands; ¶¶¶Department of Surgery, Amsterdam UMC, Amsterdam, The Netherlands; |||||Department of Gastroenterology & Hepatology, Rivas, Gorinchem, The Netherlands; ****Department of Surgery, Rivas, Gorinchem, The Netherlands; ††††Department of Gastroenterology & Hepatology, Rijnstate, Arnhem, The Netherlands; †††††Department of Surgery, Rijnstate, Arnhem, The Netherlands; §§§§§Department of Gastroenterology & Hepatology, Leiden University Medical Center (LUMC), Leiden, The Netherlands; and ¶¶¶¶Department of Surgery, Isala, Zwolle, The Netherlands.

✉l.w.leicher@isala.nl

We received funding for the study from Department of Innovation and Research of the Isala Clinics, the grant number was €80.000.

Data Availability Statements

The datasets generated during and/or analyzed during the present study are not publicly available, but are available from the corresponding author on reasonable request.

Statement of authorship: LW Leicher - planned the study, writing study protocol, submission to the ethics committee, conducted data, analysis of the data, writing of the manuscript, critical revision of the manuscript, submitted the manuscript, give final approval of the version to be published. JF Huisman - Copyright © 2022 Wolters Kluwer Health, Inc. All rights reserved.

ISSN: 0003-4932/22/27505-0933

DOI: 10.1097/SLA.0000000000005417

Because the implementation of a nationwide colorectal screening program in the Netherlands in 2014, the incidence of advanced adenomas and early-stage colorectal cancer (CRC) and the number of patients referred for colorectal resection for high grade polyps has increased.^{1–3} Endoscopic polypectomy is a well-established treatment for noninvasive colonic polyps,⁴ the majority of which can be removed safely with standard polypectomy. For more challenging polyps advanced endoscopic techniques such as endoscopic mucosal resection (EMR), endoscopic submucosal dissection, and endoscopic full-thickness resection (eFTR) have improved local resectability compared with standard polypectomy.^{5–10} Despite the availability of these techniques, large or sessile polyps situated at difficult locations in the colon can still be (technically) difficult to remove endoscopically.¹¹ A meta-analysis concerning endoscopic removal of 6779 polyps of more than 2 cm reported a success rate of 91%, with a morbidity of 8% and a mortality of 0.3%. However, additional surgical resection was required in 9% of the cases, mostly due to an irradical resection.¹² Segmental colectomy is associated with significant morbidity (24%) and mortality (2%), independent of tumor stage,¹³ and a study of surgery referral for benign colonic lesions showed an overall complication rate of 25.5%, subsequent reintervention in 8.1% and a mortality rate of 0.9%.¹⁴ Fortunately, several methods have been developed to act as intermediate and less invasive steps between endoscopic resection and major surgery. Laparoscopic-assisted polypectomy was first described in the early 1990s as an alternative to bowel resection for difficult benign lesions.¹⁵ However, most reported series using this technique are single-center studies and are limited by their retrospective design and small sample size (ranging from 4 to 72 patients).^{16–20} Nevertheless, a combined endoscopic laparoscopic surgical (CELS) approach has gained popularity due to acceptable recurrence rates, a shorter hospital stay, lower morbidity and improved functional outcomes compared with segmental colectomy.^{21–23} The technique we apply here, a modified colonoscopic-assisted laparoscopic wedge resection (CAL-WR), using a linear stapler without making an anastomosis, was previously described in a small cohort of 8 patients and yielded promising results in terms of a low morbidity rate and no observed mortality.¹⁶ However, as this technique has not yet been clinically evaluated, the aim of this large multicenter cohort study was to prospectively evaluate the short-term safety and effectiveness of CAL-WR as a means to avoid segmental colectomy in routine clinical practice.

METHODS

Study Design and Population

This prospective multicenter longitudinal cohort study was performed between January 2017 and December 2019 in 13 Dutch hospitals specialized in CRC care. The study was approved by the relevant medical ethics committee (reference no. 16-827/C) and registered in the Netherlands Trial Register as NTR6364 (<https://www.trialregister.nl/>). The local review board of each participating

hospital independently reviewed the study protocol to assess whether the study was locally feasible. Patient demographics, colonoscopy results and histological outcomes were obtained after written informed consent and registered in a web-based database (Castor EDC, Amsterdam, The Netherlands).²⁴ Patients with the following colonic lesions were eligible for inclusion: a colonic polyp that could not be removed using current endoscopic resection techniques (group 1), the presence of a non-lifting residual/recurrent polyp in a scar after previous polypectomy (group 2) or an undetermined resection margin after endoscopic removal of a low-risk pathological T1 (pT1) colon carcinoma (group 3). The patients in groups 1 and 3 were reviewed by an expert panel before inclusion (see patient selection below). Exclusion criteria were pregnancy, a polyp with more than 50% involvement of the luminal circumference and rectal polyps (less than 15 cm from anal verge endoscopically).

Patient Selection and Definitions

All eligible patients were registered. In cases with an ostensibly endoscopically-unresectable polyp (group 1), a central expert panel consisting of 5 gastroenterologists experienced in EMR/endoscopic submucosal dissection/eFTR working in different participating hospitals assessed resectability and the indication for an en bloc resection based upon 4 endoscopic images of the lesion. Two overview images of the lesion, white light and narrow band imaging (NBI) were used in the assessment, and 2 near focus images of the lesion (white light and NBI). The panel subsequently excluded cases that were considered suitable for endoscopic removal.

Patients who underwent earlier endoscopic removal of a low-risk pT1 colon carcinoma but with uncertain resection margins, were suitable for inclusion in this study (group 3). Before inclusion, histology of all specimens was re-examined by 2 specialized pathologists from 1 center to exclude high-risk features defined as angio-lymphatic invasion, poor differentiation, tumor budding grade 2/3.²⁵

CAL-WR

All participating surgeons were experienced colorectal surgeons with dedicated laparoscopic skills and to ensure uniformity of the procedure were required to complete an e-learning module explaining the CAL-WR technique. Patients were informed about the possibility of CAL-WR failure, in which case the surgeon would convert to a segmental resection or trans-anal minimal invasive surgery during the same procedure. All included patients underwent split-dose bowel preparation. Patients were placed in French position under general anesthesia. The surgeon started with a diagnostic laparoscopy using 3 trocars, the spot in the colon was identified and the concerning section of the colon was mobilized. This approach ensured that the linear stapler could be placed to make CAL-WR possible. Subsequently, colonoscopy using CO₂ for insufflation was performed by the gastroenterologist to indicate the location of the colonic polyp and a suture was laparoscopically placed close to the lesion using intraluminal endoscopic visualization. In the event of a colonic lesion close to the

planned the study, conducted data, analysis of the data, writing of the manuscript, critical revision of the manuscript, give final approval of the version to be published. WMU van Grevenstein, JMJ Geesing, N Smakman, JS Terhaar Sive Droste, EGG Verdaasdonk, F ter Borg, AK Talsma, ES van der Zaag, RWM Schrauwen, BJ van Wely, M Vermaas, JD van Bergeijk, WL Hazen, JB Tuynman, and YA Yasser, EJ Spillenaar Bilgen - locally submitted protocol for local approval, included patients, conducted data, critical revision of the manuscript, give final approval of the version to be published. P Didden - expert panel of gastroenterologists, included patients, conducted data, critical revision of the manuscript, give final approval of the version to be published. Y Backes - planned the study, writing study protocol, submission to the ethics committee, critical revision of the manuscript, give final approval of the version to be published. GJA Offerhaus and MM Lacle - pathological expert panel (conducted data), revision of study protocol, critical

revision of the manuscript, give final approval of the version to be published. FCP Moll - conducted data, revision of study protocol, critical revision of the manuscript, give final approval of the version to be published. GW Erkelens, I Schot, C Sietses, DK Wasowicz, D Ramssoekh, RJ Renger, and FA Oort - included patients, conducted data, critical revision of the manuscript, give final approval of the version to be published. FP Vleggaar, HFA Vasen, WH de Vos tot Nederveen Cappel, LMG Moons, and HL van Westreenen - planned the study, writing study protocol, analysis of the data, writing of the manuscript, critical revision of the manuscript, give final approval of the version to be published.

The authors report no conflicts of interest.

Supplemental digital content is available for this article. Direct URL citations appear in the printed text and are provided in the HTML and PDF versions of this article on the journal's Web site (www.annalsurgery.com).

mesentery, CAL-WR might not be possible but sometimes, the colonic wall can be dissected from the mesentery with preservation of the marginal artery of the colon. Traction was then placed on the suture to enable positioning of the linear stapler. Before stapling the lesion, the patency of the lumen (ie, the colonic lumen or in case of a caecal lesion, the lumen of the ileum) and a completeness of inclusion of the lesion was assessed endoscopically. The resected specimen was removed in an endobag through the 12 mm trocar. The surgeon and the gastroenterologist checked the colon for signs of bleeding or perforation before completing the procedure.¹⁶

Histology

The resected specimen was sent fresh, unfixed and in toto, without manipulation of the staple line by the surgeon, to the pathologist. The pathologist removed the staples, the lateral and serosal margins were inked with different colors, the specimen was then stretched on a paraffin block (or mesh), photographed and fixed for 24 hours at room temperature. After fixation, longitudinal sections of length and width of the whole specimen were made and completely included. Histological diagnosis of polyps and tumors was carried out in accordance with current guidelines. The histological grading, classification and the lesion resection margins in mm (horizontal and vertical) were assessed. In the event of invasive carcinoma, the Kikuchi levels were used for pT1 tumors. A R₀ resection was defined as a complete resection with no residual tumor in the resection plane, with a margin of at least 1 mm. Incomplete (R₁) resection was defined as tumor invasion of margins. When radicality could not be determined due to coagulation artefacts/tangential cut, it was defined as a R_x resection.²⁶ The same classification (R₀, R₁, R_x) was used for benign polyps. Tumor grade and presence/absence of lymph- or blood vessel invasion was addressed specifically, along with tumor budding. When the histological outcome of CAL-WR in group 3 showed no residual neoplastic tissue from the earlier endoscopically incomplete resected low-risk pT1 CRC, the histology of the CAL-WR excision specimen was reviewed by a specialized GI pathologist to ensure that the earlier endoscopically-removed low-risk pT1 scar was resected. When the scar was identified during second reading of the histology and no residual tissue was identified, we considered it a R₀ resection.

Follow-up Endoscopy

A follow-up endoscopy was scheduled 6 months after CAL-WR to evaluate the scar for residual/recurrent adenomatous tissue or cancer. Inspection of the scar was performed with both white light and advanced imaging (NBI or chromo-endoscopy), followed by biopsies even in the absence of visible neoplastic tissue.

Primary and Secondary Outcomes

The primary endpoint was the 30-day morbidity rate after CAL-WR according to the Clavien-Dindo classification.²⁷ Minor morbidity was defined as Clavien-Dindo grade I or II, and major morbidity as Clavien-Dindo grade III or higher. The secondary outcomes were (1) technical success defined as macroscopically-complete wedge resection with a patent lumen, (2) number of radical resections (R₀) defined as free lateral and vertical resection margins of at least 1 mm normal colonic mucosa, (3) recurrence of adenomatous tissue or carcinoma detected by follow-up endoscopy, and (4) long-term morbidity after CAL-WR defined as the development of a symptomatic stenosis of the colon.

Statistical Analyses

The sample size was determined based on a power calculation assuming a morbidity of 5%, with a desired precision estimate of 4% and a 95% confidence interval. Using these parameters, the sample

size was determined to be 115 cases. All analyses were performed using Statistical Package of Social Sciences version 26.0 (SPSS, IBM Corp. Released 2019. IBM SPSS Statistics for Windows, Version 26.0. Armonk, NY: IBM Corp). A *P* value < 0.05 (2 sided) was considered significant. Normality was verified using the Kolmogorov-Smirnov test. Descriptive statistics were reported as medians with range for nonparametric data and as means with standard deviation for parametric data. Normally-distributed continuous data were tested using Student *t* test. Non-parametrical continuous data were compared using the Mann-Whitney *U* test. Categorical data are summarized as frequencies with proportions.

RESULTS

Of the 138 eligible patients, 118 were included in the analysis after assessment by the expert panel and review of the histological specimen, if indicated (Fig. 1). In group 1, 66 of the 80 (85.5%) eligible patients were included. Seven patients were excluded based on expert panel assessment and a further 7 patients withdrew from the study for various reasons (eg, the patient did not undergo CAL-WR or declined to participate in the study). All patients in group 2 were included in the analysis. Of the 24 eligible patients in group 3, 2 patients were excluded after histologic revision and 4 patients withdrew from the study, leaving 18 patients in total.

In 56% of included patients the indication for CAL-WR was an endoscopically-unresectable colonic polyp (group 1), 29% of patients had a residual/recurrent lesion after previous endoscopic removal (group 2) and the remaining patients (15%) had an undetermined resection margin after endoscopic removal of a low-risk pT1 tumor (group 3). The mean age was 66 years (standard deviation ± 8 years), the majority of the patients were male (56%) and most patients (82%) had an American Society of Anesthesiologists physical status of 1 or 2.²⁸ Almost half of the lesions were located in the caecum. The median size of lesions in groups 1 and 2 was 20 mm (range 5–50 mm). An overview of the baseline characteristics is presented in Table 1.

Successful CAL-WR was performed in 110 of the 118 patients (93%). When a lesion was located in the caecum the technical success rate was 96%, and in twenty-seven of the fifty [54% (n = 27/50)] successfully performed CAL-WR procedures, the polyps showed ingrowth into the appendix. CAL-WR was not considered suitable in 8 patients, 3 of whom had lesions in the rectum, in contrast to an earlier endoscopically estimated location in the sigmoid colon. In 2 of these cases transanal minimally invasive surgery was performed, whereas the other patient underwent eFTR during the same procedure. The fourth patient exhibited lesional ingrowth into the ileum, but due to severe comorbidity a CAL-WR was performed in this patient with acceptance of irradicality. Stenosis of the colon was observed in the fifth patient during CAL-WR, due to the earlier endoscopic removal of a colonic polyp. The surgeon, therefore, converted to a segmental colonic resection. During CAL-WR in the sixth patient endoscopic suspicion of a deep invasive carcinoma arose, for which a right hemicolectomy was performed during the procedure. In the seventh patient a colonic polyp was found close to the mesentery, precluding proper positioning of the linear stapler and the surgeon, therefore, decided to perform a hemicolectomy. In the remaining patient the surgeon was not able to tension the suture sufficiently to ensure correct positioning of the linear stapler and the procedure was, therefore, converted to a right-sided hemicolectomy (Table 2).

The patients who successfully underwent a CAL-WR (n = 110) had an overall complication rate of 6%, all of which were minor (Clavien-Dindo grade I-II) and neither reintervention nor mortality was observed. The mean operation time was 58 minutes (range 20–138 minutes) and the overall median length of hospital stay after CAL-

WR was 2 days (range 1 -5 days) (Table 3). One patient had an additional segmental resection 5 weeks after CAL-WR due to complaints of a stenosis of the colon.

Amongst the 110 patients with a successful CAL-WR, 69% (n = 76) had benign histology, 20% (n = 22) malignant histology, all these CRCs were judged benign by the gastroenterologist and the expert panel before surgery. Eleven percent (n = 12) showed no residual tumor (after a previous uncertain margin after endoscopic removal of a low risk pT1 carcinoma). Radical resection was performed in 91% of patients who successfully underwent a CAL-WR (n = 110/118). R1 resection was carried out in 3%. In group 1, radical resection was carried out in 87% and R₁ resection in 5% of patients. In group 2, the radicality rate was 94% and in group 3, 100%. The radicality rate did not differ between lesions up to 30 mm and lesions greater than 30 mm (90% vs 92%, P = 0.78) (Supplemental Digital Content Table 1, <http://links.lww.com/SLA/D688>).

Invasive cancers were diagnosed in 22 patients (20%), 13 of whom had a pT1 tumor, all of which were R₀ resections. T2 carcinomas were found in 7 patients, 5 of which were R₀ resections (71.4%). The remaining 2 patients with invasive cancer showed a T3 carcinoma, both of which were resected with radical margins. Three of the twenty-two aforementioned patients underwent resection of a scar after previous removal of a low-risk pT1 (group 3), so size of the

resected lesion was not applicable and these 3 cases were therefore excluded from the analysis of lesion size. The other 19 cases of invasive lesions were divided, based on size of the colonic polyp, into 2 groups: (1) lesions smaller or equal to 25 mm (n = 12) and (2) lesions larger than 25 mm (n = 7). Although numbers were small, there was no difference in R₀ resection rates (92% vs 86%, P = 1.00) (Supplemental Digital Content Table 1, <http://links.lww.com/SLA/D688>). An additional oncological segmental colon resection was performed in 12 patients. In 10 patients the indication for the resection was based on high-risk features after histological examination. In 1 patient an additional oncological resection was performed due to a carcinoma in another polyp not treated in this study. The remaining patient underwent an additional resection, 5 weeks after CAL-WR, after complaints of a stenosis of the colon (Supplemental Digital Content Table 1, <http://links.lww.com/SLA/D688>).

Of the 110 patients who underwent a successful CAL-WR, 12 required additional oncological surgical resection and, therefore, had no indication for follow-up endoscopy after 6 months. Of the remaining 98 patients with an indication for follow-up endoscopy, follow-up was conducted in 87 (89%). The median interval between CAL-WR and follow-up endoscopy was 9 months (range 2–32 months) and a CAL-WR scar could be identified in almost 80%. In 4 patients (5%) macroscopic recurrent tissue was found during follow-up endoscopy

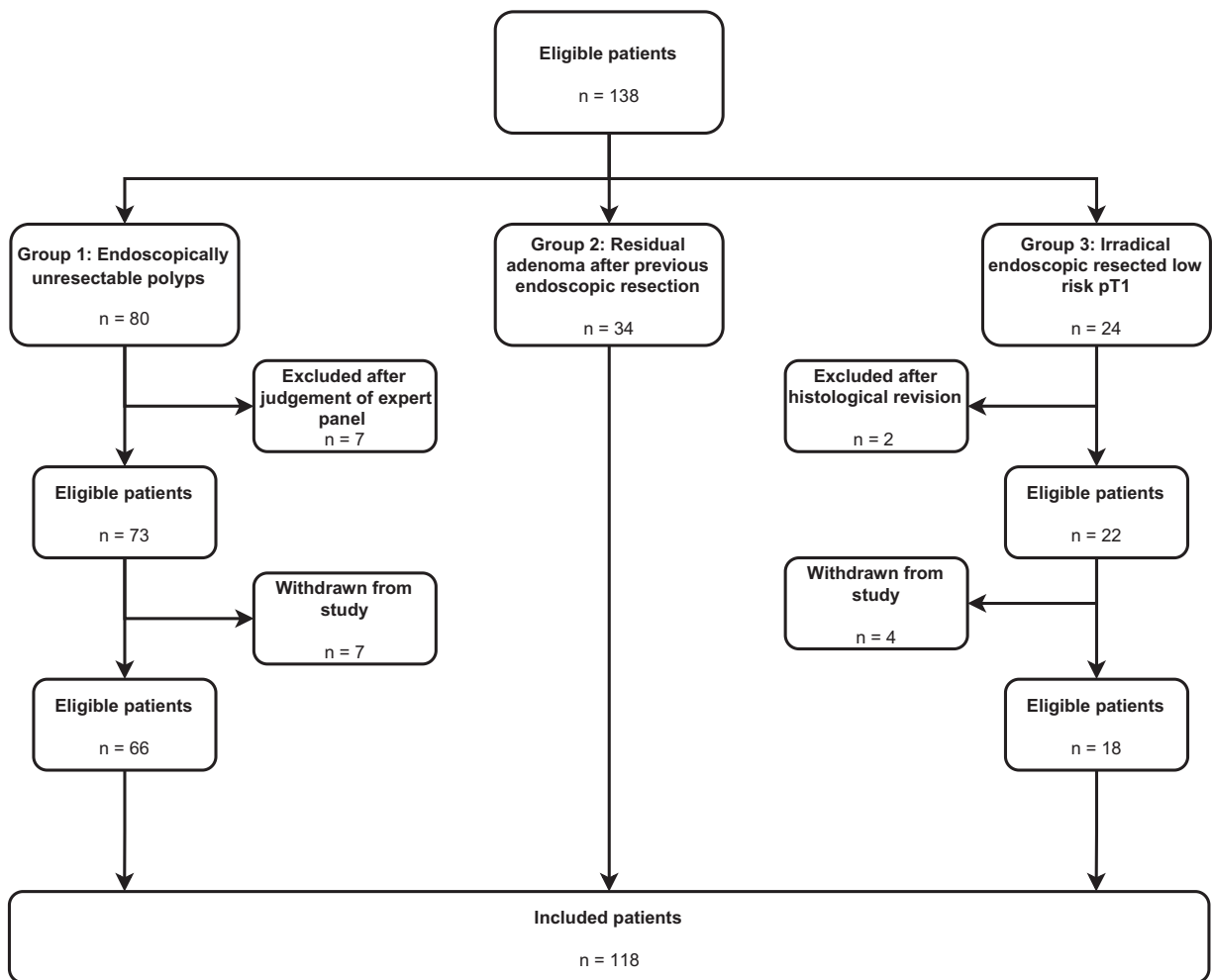


FIGURE 1. Patient enrollment.

TABLE 1. Baseline Characteristics

	n = 118 (%)
Mean age, yr (SD)	66 (± 8)
Sex	
Male	66 (56)
ASA	
1	19 (16)
2	78 (66)
3	21 (18)
Previous abdominal surgery	20 (17)
Indications	
Endoscopically-unresectable polyp	66 (56)
Residual adenomatous tissue after prior polypectomy	34 (29)
Irradical resected low-risk pT1	18 (15)
Localization lesion	
Caecum	52 (44)
Ascending colon and hepatic flexure	27 (23)
Transverse colon	11 (9)
Descending colon and splenic flexure	7 (6)
Sigmoid colon	21 (18)
Size of the lesions, per indication (median with range)	
Endoscopically-unresectable polyp, size in mm	20 (range 5–50)
Residual adenomatous tissue after prior polypectomy	20 (range 5–50)

ASA indicates American Society of Anesthesiologists physical status; SD, standard deviation.

(Table 4) and 3 of these patients underwent R₀ resection of the CAL-WR, 1 of which concerned a lesion with ingrowth into the appendix. In 2 patients the indication for a CAL-WR was a difficult location of the lesion, and in the remaining patient the indication was a non-lifting colonic polyp. All 4 cases with recurrence were confirmed by histological examination of the resected residue. The residue was treated by cold snare EMR in all 4 cases (Table 5).

DISCUSSION

This prospective multicenter study shows that CAL-WR is a safe and feasible technique for the resection of colonic polyps not amenable to conventional endoscopic resection. CAL-WR has a low morbidity rate, with only 6% minor complications, a high technical success rate (93%) and a radical resection rate of 91%. In the present study, recurrent lesions were found in only 4 patients (5%).

The number of advanced adenomas and early T1 cancers with referrals for surgical treatment of these lesions has increased substantially due to the implementation of national CRC screening programs in many countries.³ CAL-WR seems to fill the gap between endoscopic resection and more advanced surgical procedures, which are accompanied by higher morbidity (24%) and mortality (2%) rates.¹³

In the present study only 11% of patients underwent additional oncological segmental resection, indicating that segmental colectomy could be prevented in all other cases. Moreover, CAL-WR seems costeffective compared to laparoscopic segmental resection.²⁹

To date, few studies have described the use of various CELS techniques.^{16–20} Reported technical success rates from available literature range from 95% to 100%,^{16,18–20} comparable to our technical success rate of 93%. Accurate endoscopic judgement regarding lesion location is necessary to select the appropriate patients for CAL-WR, which may in turn result in an even higher technical success rate. In 3 patients in our study, polyps with reported locations in the sigmoid were actually found in the rectum. Furthermore, 1 polyp showed ingrowth into the ileum and another polyp was judged to be suspicious for a deep invasive carcinoma.

A recent systematic review of CELS involving 101 patients showed no intra- or post-operative complications.¹⁷ Another recent retrospective cohort study (n = 115 patients) showed Clavien-Dindo grade I-II complications in 13% of patients after CELS.³⁰ In that study, both CAL-WR and another form of CELS such as laparoscopy-assisted endoscopic resection was performed. Therefore, the

TABLE 2. Technical Success of Colonoscopic-Assisted Laparoscopic Wedge Resection in Patients Scheduled for CAL-WR

	Overall n = 118 (%)	Indication CAL-WR		
		Endoscopically- Unresectable Polyp n = 66 (%)	Residual Adenomatous Tissue n = 34 (%)	Irradical Low Risk pT1 n = 18 (%)
Technical success	110 (93)	63 (95)	31 (91)	16 (89)
Location successful				
CAL-WR				
Caecum	50/52 (96)	35/36 (97)	14/15 (93)	1/1 (100)
Ascending colon and hepatic flexure	25/27 (93)	13/14 (93)	8/9 (89)	4/4 (100)
Transverse colon	10/11 (91)	7/7 (100)	3/4 (75)	–
Descending colon and splenic flexure	7/7 (100)	4/4 (100)	2/2 (100)	1/1 (100)
Sigmoid colon	18/21 (86)	4/5 (80)	4/4 (100)	10/12 (83)
CAL-WR not performed				
Reason:	8 (7)	3 (6)	3 (9)	2 (11)
Rectal lesion	3	1	—	2
Ingrowth in ileum*	1	—	1	—
Stenosis due to prior endoscopic resection	1	—	1	—
Suspicion of carcinoma	1	1	—	—
Lesion close to mesentery	1	—	1	—
No tension on suture possible	1	1	—	—
Converted into:				
TAMIS	2	1	—	1
eFTR	1	—	—	1
LEAWR with acceptance of irradicality	1	—	1	—
Right-sided hemicolectomy	4	2	2	—

*CAL-WR was performed with acceptance of irradicality.

CAL-WR indicates colonoscopic-assisted laparoscopic wedge resection; eFTR, endoscopic full-thickness resection; TAMIS, transanal minimally invasive surgery.

TABLE 3. Clinical Outcome CAL-WR

	n = 110 (%)
Overall complications	7 (6)
Minor complications (CDG I-II)	7 (6)
Urinary retention	2
Urinary tract infection	1
Surgical site infection	1
Readmission due to pain	1
Opioid intoxication	1
Paralytic ileus	1
Major complications (CDG III-IV)	–
Median length of stay (range), d	2 (1–5)
Median operating time (range), min	58 (20–138)

CDG indicates Clavien Dindo Grade of complications.

TABLE 4. Follow-Up Endoscopy

	Overall n = 98* (%)
Follow-up endoscopy	87 (89)
Missing	11
Patient died*	1
Patient refused FU	4
No FU due to COVID-19	4
Lost to follow up	2
Median interval between CAL-WR and FU† (range), mo	9 (2–32)
Scar CAL-WR identified?	
Yes	69/87 (79)
Macroscopic residual tissue	4/87 (5)

*Patient died 2.5months after CAL-WR due to a cerebrovascular accident. FU indicates follow-up endoscopy.

reported 6% morbidity rate in our study seems acceptable, especially in a multicenter design.

Successful CAL-WR in the present study resulted in an overall radical resection rate of 91%, and no significant difference was found in resection rates for lesions < 30 mm or > 30 mm. Radical resection rates after CAL-WR in other studies range from 75% to 100%.^{16,18,20} None of the previous CAL-WR studies reported recurrence at followup endoscopy.^{16,18–20} In our study, recurrent adenomatous tissue was detected at follow-up colonoscopy in 5% of cases. In 1 case the pathologist found loose adenomatous cells in the staple margin, whereas the primary resection margin was free of adenomatous tissue. We hypothesize that manipulation of the lesion in this case, either by placing of the suture and/or closure with the stapler, caused adenomatous cells to become embedded in the staple margin. Careful manipulation of the lesion during CAL-WR and follow-up endoscopy is therefore strongly recommended. A CAL-WR scar could be identified in 80% of the follow-up colonoscopies and placing a tattoo opposite the CAL-WR site would further improve the scar detection at follow-up endoscopy.

eFTR using an over the scope clip is another relatively new full-thickness technique for the treatment of complex colonic neoplasms. The overall technical success rate of eFTR varies between 84% to 94%,^{5,31–34} whereas the complication rate ranges from 9.3% and 14%. The most commonly reported complications are secondary appendicitis, bleeding and traumatic wall lesions. In 2% to 3.5% of cases surgical reintervention is needed to treat complications.^{5,31–34} The reported complication rate of eFTR is higher (9.3%-14%) compared to CAL-WR (6%), as demonstrated by our study. A relatively common complication after eFTR is a secondary appendicitis close to the appendiceal orifice, which requires surgical reintervention. CAL-WR is particularly suitable for these cases, as 27

patients in our study (25%) had a lesion with ingrowth into the appendix, all of which could be treated without complication.

The radical resection rates for eFTR and CAL-WR are similar and vary from 72% to 90% and from 72% to 100%, respectively.^{5,16,18,20,31–34} However, the use of eFTR is restricted to lesions of less than 20 mm by the size of the cap.^{5,31,33,34} In our study, the median size of lesions was 20 mm (range 5–50 mm), indicating that lesion size is less of a limitation compared to eFTR. The recently described Dutch eFTR colorectal registry reported residual/recurrent lesions in 6.4% of patients,⁵ whereas other eFTR studies reported a recurrence/residual rate of between 5.8% and 13.5%.^{31–34} Unfortunately, details on whether the primary resection in these cases was complete (R₀ resection) was not provided in these studies.^{5,33,34}

Strengths of our study included the multicenter prospective design and the relatively large number of included patients, whereas the use of expert panels and follow-up with colonoscopy increased external validity. A limitation of our study was that 11% of follow-up colonoscopies have yet not been performed due to COVID-19-related restrictions. Therefore, the actual recurrence rate might be somewhat higher and the long-term outcome of the study is still awaited. Another limitation can be the location of the polyp close to the mesentery, which may preclude placing of the linear stapler and dissection of the colon from the mesentery should be avoided to prevent necrosis of the colon. Another limitation could be the bowel insufflation during CAL-WR, making the surgery difficult. For this reason, it is important to do the colonic mobilization before insufflation and to use CO₂ because it resolves faster. Future research should focus on the long-term outcomes of CAL-WR, especially concerning malignant neoplasms. Differences in costs between advanced endoscopic removal techniques and CAL-WR should also be taken into account.

TABLE 5. Macroscopic Residual Tissue During Follow-Up Endoscopy

	Indication for CAL-WR	Size of Resected Polyp* (mm)	Location CAL-WR	Histologic Outcome CAL-WR	Histologic Outcomes FU Endoscopy	Treatment of the Recurrence
Case 1	Difficult location of polyp	50	Transverse colon	Adenoma LGD, R _{ce:italic} Oce:italic resection	Adenoma LGD	Cold snare EMR
Case 2	Non-lifting polyp	10	Transverse colon	Adenoma LGD, R _{ce:italic} Oce:italic resection	Adenoma LGD	Cold snare EMR
Case 3	Difficult location of polyp	30	Splenic flexure	Adenoma LGD, R _x resection	Adenoma LGD	Cold snare EMR
Case 4	Growth into appendix	15	Caecum/appendix	SSA/P without dysplasia, R _{ce:italic} Oce:italic resection	SSA/P without dysplasia	Cold snare EMR

*Endoscopically estimated by gastroenterologist.
FU indicates follow-up endoscopy.

In conclusion, CAL-WR is a safe, feasible and organ-preserving technique. CAL-WR should therefore be considered a primary treatment strategy for patients with colonic neoplastic lesions that cannot be removed endoscopically. Furthermore, a specific indication could be polyps with ingrowth into the appendix.

ACKNOWLEDGMENTS

The authors thank the Innovation & Research department at the Isala Clinic for their financial support.

REFERENCES

- Elferink MAG, Toes-Zoutendijk E, Vink GR, et al. National population screening for colorectal carcinoma in the Netherlands: results of the first years since the implementation in 2014. *Ned Tjdschr Geneeskd.* 2018;162:D2283.
- Marres CCM, Buskens CJ, Schriever E, et al. The impact of the national bowel screening program in the Netherlands on detection and treatment of endoscopically unresectable benign polyps. *Tech Coloproctol.* 2017;21:887–891.
- Bosch D, Leicher LW, Vermeer NCA, et al. Referrals for surgical removal of polyps since the introduction of a colorectal cancer screening programme. *Colorectal Dis.* 2021;23:672–679.
- Winawer SJ, Zauber AG, Ho MN, et al. Prevention of colorectal cancer by colonoscopic polypectomy. *N Engl J Med.* 1993;329:1977–1981.
- Zwager LW, Bastiaansen BAJ, Bronzwaer MES, et al. Endoscopic full-thickness resection (eFTR) of colorectal lesions: results from the Dutch colorectal eFTR registry. *Endoscopy.* 2020;52:1014–1023.
- Byeon J-, Yang D-, Kim K-, et al. Endoscopic submucosal dissection with or without snaring for colorectal neoplasms. *Gastrointest Endosc.* 2011;74:1075–1083.
- Bergmann U, Beger HG. Endoscopic mucosal resection for advanced non-polypoid colorectal adenoma and early stage carcinoma. *Surg Endosc.* 2003;17:475–479.
- Conio M, Repici A, Demarquay J-, et al. EMR of large sessile colorectal polyps. *Gastrointest Endosc.* 2004;60:234–241.
- Saito Y, Uraoka T, Yamaguchi Y, et al. A prospective, multicenter study of 1111 colorectal endoscopic submucosal dissections (with video). *Gastrointest Endosc.* 2010;72:1217–1225.
- Yokota T, Sugihara K, Yoshida S. Endoscopic mucosal resection for colorectal neoplastic lesions. *Dis Colon Rectum.* 1994;37:1108–1111.
- Puli SR, Kakugawa Y, Gotoda T, et al. Meta-analysis and systematic review of colorectal endoscopic mucosal resection. *World J Gastroenterol.* 2009;15:4273–4277.
- Hassan C, Repici A, Sharma P, et al. Efficacy and safety of endoscopic resection of large colorectal polyps: a systematic review and meta-analysis. *Gut.* 2016;65:806–820.
- Vermeer NCA, Backes Y, Snijders HS, et al. National cohort study on postoperative risks after surgery for submucosal invasive colorectal cancer. *BJS Open.* 2019;3:210–217.
- Vermeer NCA, de Neree tot Babberich MPM, Fockens P, et al. Multicentre study of surgical referral and outcomes of patients with benign colorectal lesions. *BJS Open.* 2019;3:687–695.
- Beck DE, Karulf RE. Laparoscopic-assisted full-thickness endoscopic polypectomy. *Dis Colon Rectum.* 1993;36:693–695.
- Leicher LW, de Vos Tot Nederveen Cappel WH, van Westreenen HL. Limited endoscopic-assisted wedge resection for excision of colon polyps. *Dis Colon Rectum.* 2017;60:299–302.
- Liu Z-, Jiang L, Chan FS-, et al. Combined endo-laparoscopic surgery for difficult benign colorectal polyps. *J Gastrointest Oncol.* 2020;11:475–485.
- Jang JH, Kirchoff D, Holzman K, et al. Laparoscopic-facilitated endoscopic submucosal dissection, mucosal resection, and partial circumferential (“wedge”) colon wall resection for benign colorectal neoplasms that come to surgery. *Surg Innov.* 2013;20:234–240.
- Wilhelm D, von Delius S, Weber L, et al. Combined laparoscopic-endoscopic resections of colorectal polyps: 10-year experience and follow-up. *Surg Endosc.* 2009;23:688–693.
- Giavarini L, Boni L, Cortellezzi CC, et al. Laparoscopic caecal wedge resection with intraoperative endoscopic assistance. *Int J Surg.* 2013;11(Suppl 1):S58–S60.
- Lee SW, Garrett KA, Shin JH, et al. Dynamic article: Long-term outcomes of patients undergoing combined endolaparoscopic surgery for benign colon polyps. *Dis Colon Rectum.* 2013;56:869–873.
- Lee MK, Chen F, Esrailian E, et al. Combined endoscopic and laparoscopic surgery may be an alternative to bowel resection for the management of colon polyps not removable by standard colonoscopy. *Surg Endosc.* 2013;27:2082–2086.
- Aslani N, Alkhamesi NA, Schlachta CM. Hybrid laparoendoscopic approaches to endoscopically unresectable colon polyps. *J Laparoendosc Adv Surg Tech A.* 2016;26:581–590.
- Castor electronic data capture. Amsterdam. Available at: <https://www.castoredc.com/>. Updated 2019. Accessed January 2017.
- Suh JH, Han KS, Kim BC, et al. Predictors for lymph node metastasis in T1 colorectal cancer. *Endoscopy.* 2012;44:590–595.
- Fleming ID, Cooper JS, Henson DE, et al. *American Joint Committee on Cancer Manual for Staging of Cancer.* 5th ed, Philadelphia, PA: J.B. Lippincott; 1995.
- Dindo D, Demartines N, Clavien PA. Classification of surgical complications: a new proposal with evaluation in a cohort of 6336 patients and results of a survey. *Ann Surg.* 2004;240:205–213.
- Mayhew D, Mendonca V, Murthy BVS. A review of ASA physical status - historical perspectives and modern developments. *Anaesthesia.* 2019;74:373–379.
- Jayaram A, Barr N, Plummer R, et al. Combined endo-laparoscopic surgery (CELS) for benign colon polyps: a single institution cost analysis. *Surg Endosc.* 2019;33:3238–3242.
- Golda T, Lazzara C, Sorribas M, et al. Combined endoscopic-laparoscopic surgery (CELS) can avoid segmental colectomy in endoscopically unresectable colonic polyps: a cohort study over 10 years. *Surg Endosc.* 2022;36:196–205.
- Meier B, Stritzke B, Kuellmer A, et al. Efficacy and safety of endoscopic full-thickness resection in the colorectum: results from the German colonic FTRD registry. *Am J Gastroenterol.* 2020;115:1998–2006.
- Schmidt A, Beyna T, Schumacher B, et al. Colonoscopic full-thickness resection using an over-the-scope device: a prospective multicentre study in various indications. *Gut.* 2018;67:1280–1289.
- Kuellmer A, Mueller J, Caca K, et al. Endoscopic full-thickness resection for early colorectal cancer. *Gastrointest Endosc.* 2019;89:1180–1189.
- Andrisani G, Soriani P, Manno M, et al. Colo-rectal endoscopic full-thickness resection (EFTR) with the over-the-scope device (FTRD((R))) : a multicenter Italian experience. *Dig Liver Dis.* 2019;51:375–381.