



Universiteit  
Leiden  
The Netherlands

## **Diagnosis of chronic thromboembolic pulmonary hypertension after acute pulmonary embolism**

Klok, F.A.; Couturaud, F.; Delcroix, M.; Humbert, M.

### **Citation**

Klok, F. A., Couturaud, F., Delcroix, M., & Humbert, M. (2020). Diagnosis of chronic thromboembolic pulmonary hypertension after acute pulmonary embolism. *European Respiratory Journal*, 55(6). doi:10.1183/13993003.00189-2020

Version: Publisher's Version

License: [Creative Commons CC BY-NC 4.0 license](https://creativecommons.org/licenses/by-nc/4.0/)

Downloaded from: <https://hdl.handle.net/1887/3184892>

**Note:** To cite this publication please use the final published version (if applicable).



# Diagnosis of chronic thromboembolic pulmonary hypertension after acute pulmonary embolism

Fredrikus A. Klok <sup>1</sup>, Francis Couturaud<sup>2</sup>, Marion Delcroix <sup>3</sup> and Marc Humbert <sup>4,5,6</sup>

**Affiliations:** <sup>1</sup>Dept of Thrombosis and Hemostasis, Leiden University Medical Center, Leiden, The Netherlands. <sup>2</sup>Département de Médecine Interne et Pneumologie, Centre Hospitalo-Universitaire de Brest, Univ Brest, Brest, France. <sup>3</sup>Dept of Respiratory Diseases, University Hospitals and Respiratory Division, Dept of Chronic Diseases, Metabolism and Aging, KU Leuven – University of Leuven, Leuven, Belgium. <sup>4</sup>Université Paris-Saclay, Faculté de Médecine, Le Kremlin-Bicêtre, France. <sup>5</sup>Service de Pneumologie et Soins Intensifs Respiratoires, Hôpital Bicêtre, AP-HP, Le Kremlin-Bicêtre, France. <sup>6</sup>INSERM UMR S 999, Hôpital Marie Lannelongue, Le Plessis Robinson, France.

**Correspondence:** Frederikus A. Klok, Dept of Thrombosis and Hemostasis, Leiden University Medical Center, Albinusdreef 2, 2300RC, Leiden, The Netherlands. E-mail: f.a.klok@LUMC.nl

@ERSpublications

**Improving education of PE caretakers, higher awareness for CTEPH and further validation and implementation of clinical/radiological algorithms for earlier CTEPH diagnosis will help ensure earlier referral to expert centres and improved prognosis** <http://bit.ly/2Qb9jOt>

**Cite this article as:** Klok FA, Couturaud F, Delcroix M, *et al.* Diagnosis of chronic thromboembolic pulmonary hypertension after acute pulmonary embolism. *Eur Respir J* 2020; 55: 2000189 [<https://doi.org/10.1183/13993003.00189-2020>].

**ABSTRACT** Chronic thromboembolic pulmonary hypertension (CTEPH) is the most severe long-term complication of acute pulmonary embolism (PE). Untreated CTEPH is fatal, but, if diagnosed in time, successful surgical (pulmonary endarterectomy), medical (pulmonary hypertension drugs) and/or interventional (balloon pulmonary angioplasty) therapies have been shown to improve clinical outcomes, especially in case of successful pulmonary endarterectomy. Early diagnosis has however been demonstrated to be challenging. Poor awareness of the disease by patients and physicians, high prevalence of the post-PE syndrome (*i.e.* persistent dyspnoea, functional limitations and/or decreased quality of life following an acute PE diagnosis), lack of clear guideline recommendations as well as inefficient application of diagnostic tests in clinical practice lead to a reported staggering diagnostic delay >1 year. Hence, there is a great need to improve current clinical practice and diagnose CTEPH earlier. In this review, we will focus on the clinical presentation of and risk factors for CTEPH, and provide best practices for PE follow-up programmes from expert centres, based on a clinical case.

---

Received: 28 Jan 2020 | Accepted after revision: 03 March 2020

Copyright ©ERS 2020

## Introduction

Chronic thromboembolic pulmonary hypertension (CTEPH) is considered to be the most serious long-term complication of acute pulmonary embolism (PE), affecting 2–4% of PE survivors [1–3]. CTEPH is characterised by persistent obstruction of the pulmonary arteries by organised fibrotic thrombi with secondary microvascular remodelling leading to increased pulmonary vascular resistance, pulmonary hypertension (PH) and right heart failure [4, 5]. Of note, since a history of acute PE or deep vein thrombosis is lacking in up to 30% of patients with proven CTEPH, the pathophysiology of CTEPH may not (always) be as “simple” as poorly resolved PE. Other mechanisms could involve recurrent “silent” pulmonary emboli or *in situ* thrombosis [6]. In the latter scenario, the acute clot would not trigger pathological pulmonary artery remodelling, but it would be the other way around.

While historical cohort studies have shown that untreated CTEPH is associated with a considerable mortality, patients nowadays have a much better prognosis due to advanced treatment options, including pulmonary endarterectomy, balloon pulmonary angioplasty and PH drugs [7–10]. Importantly, epidemiological studies have provided convincing arguments for gross underdiagnosis of CTEPH [1]. Moreover, the current diagnostic delay of CTEPH is a staggering 12 months or even longer, reflecting poor awareness for the disease and inefficient application of diagnostic tests [9, 11–13]. Notably, this delay has been associated with a more advanced disease stage at the moment of diagnosis, as well as with higher overall mortality; although this was mainly true for the highest tertile of delay [14]. Hence, there is a great need to improve current clinical practice and diagnose CTEPH earlier.

In this review, we will focus on the clinical presentation of and risk factors for CTEPH and provide current best practices for PE follow-up programmes from expertise centres, based on a clinical case.

## Clinical case

A 46-year-old woman was diagnosed with recurrent acute PE 10 weeks before current presentation. Her medical history was notable for an episode of acute PE after a long-haul flight 6 years ago for which she had received 3 months of anticoagulation therapy, mild COPD and Hashimoto’s thyroiditis treated with thyroid hormones. Medication at the moment of the recurrent PE diagnosis included levothyroxine, ipratropium, salbutamol, pantoprazole and a multivitamin. She had been in her usual state of health until 2 months before the diagnosis of recurrent PE, when progressive exercise-induced dyspnoea developed. Increasing usage of the inhaled salbutamol had no beneficial effect. On the day of the recurrent PE diagnosis, she had woken up with a sharp pleuritic chest pain. She did not have symptoms of deep vein thrombosis and provoking factor for venous thromboembolism were not present. A computed tomography pulmonary angiography (CTPA) had confirmed the diagnosis of unprovoked bilateral lobar PE (figure 1). Because of a sub-optimal oxygen saturation at rest upon presentation (saturation 92% while breathing room air), she was hospitalised for 4 days and treatment with apixaban was initiated.

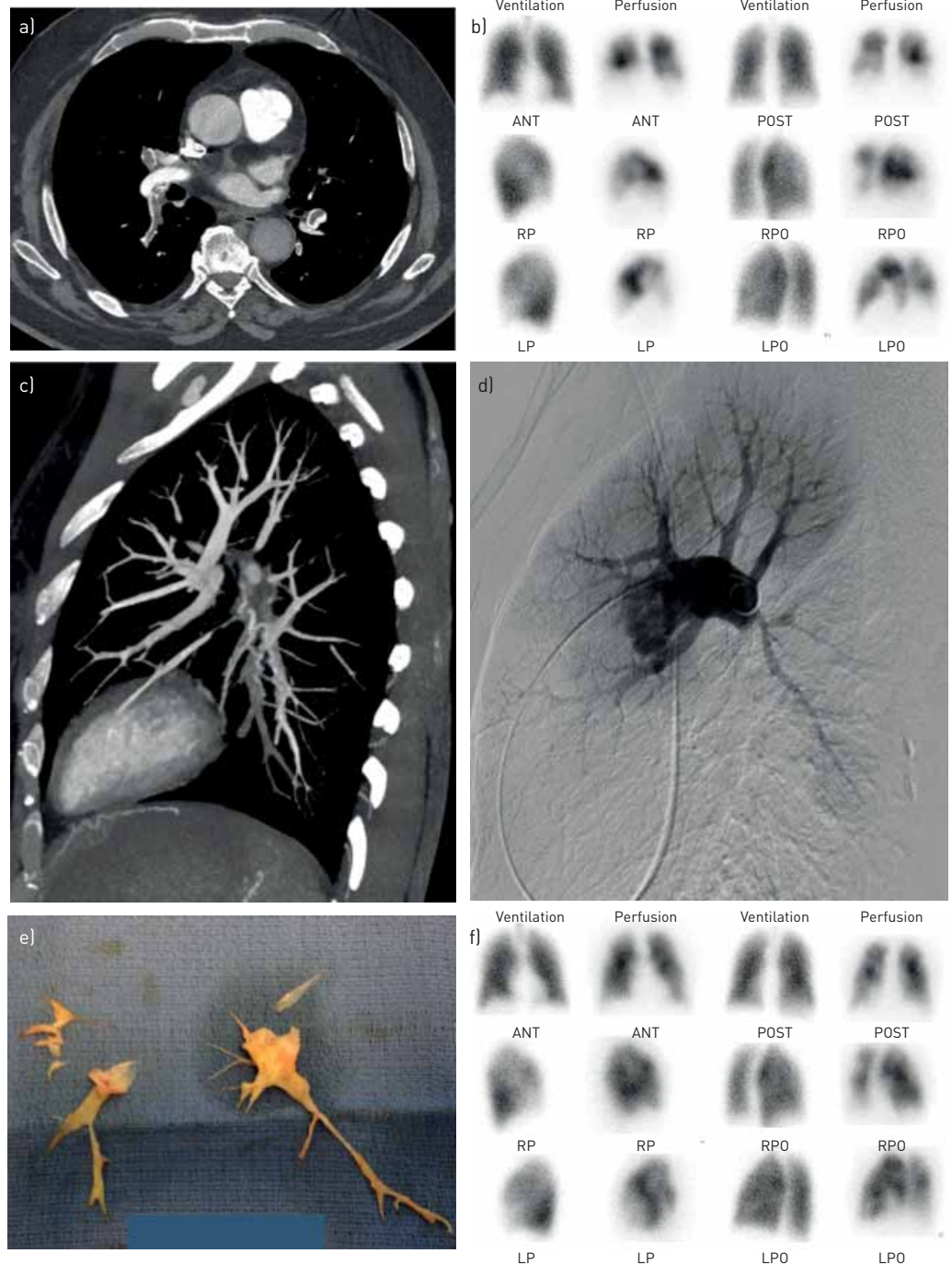
At discharge she felt better, but despite adhering closely to the medication, she had not fully recovered: she was still unable to complete her usual 4-mile morning run in a pace she could be satisfied with, and was unable to work full-time due to persistent chest pain, dyspnoea and anxiety. She had searched the internet and found that her symptoms could fit CTEPH. She now seeks counselling with regard to the possibility of CTEPH. What diagnostic test would be indicated at this point?

## Who and when to test for CTEPH?

### *Natural course of symptom recovery after acute PE*

Several cohort studies have shown that approximately 40–50% of patients report persistent or worsening dyspnoea and functional limitations in the course of adequately treated acute PE, a prevalence of dyspnoea that is higher than expected in the general population and greatly affects quality of life [15–24]. In these studies, dyspnoea was defined as symptoms corresponding to a New York Heart Association (NYHA) functional class  $\geq$ II, with 10–20% of patients categorised as NYHA functional class III or IV [15–18]. Notably, symptoms of dyspnoea and results of a 6-min walking test improve in the majority of patients in the first months following an acute PE diagnosis, although most improvement occurs in the first 3 months. The presence of persistent dyspnoea, functional limitations and/or decreased quality of life following an episode of acute PE has recently been referred to as the “post-PE syndrome” although this entity encompasses heterogeneous aetiologies [25–28].

The most severe cause of persistent dyspnoea after acute PE remains CTEPH. The increase in pulmonary artery pressure characteristic for CTEPH results from increased pulmonary artery resistance caused by fibrotic organisation of unresolved PE. Besides, perfusion diverted to unobstructed lung areas combined to anastomoses of hypertrophic systemic (bronchial) circulation in the obstructed areas, contribute to increase pulmonary artery resistance by inducing microvasculopathy [4]. In addition to PH, ventilation of obstructed areas or dead space ventilation may also limit physical performance [3, 29]. Significant exercise



**FIGURE 1** Radiological studies performed in the presented clinical case. a) Acute pulmonary embolism on spiral computed tomography pulmonary angiography. b) Residual pulmonary vascular obstruction on planar ventilation/perfusion lung scanning at 6 months of anticoagulation of pulmonary embolism before pulmonary endarterectomy. c) Residual pulmonary vascular obstruction on spiral computed tomography pulmonary angiography before pulmonary endarterectomy. d) Residual pulmonary vascular obstruction on catheter pulmonary angiography before pulmonary endarterectomy. e) Sample of the pulmonary endarterectomy specimens (collection of Elie Fadel, Hôpital Marie Lannelongue, Université Paris-Saclay, Paris, France). f) Pulmonary vascular obstruction on planar ventilation/perfusion lung scanning at 6 months after pulmonary endarterectomy. ANT: anterior; POST: posterior; RPO: right posterior oblique; LPO: left posterior oblique; LP: left posterior; RP: right posterior.

limitation can also be observed in patients with chronic pulmonary embolism and normal pulmonary artery pressures at rest. This condition is also referred to as chronic thromboembolic disease (CTED). However, the main factor limiting exercise capacity in CTED is probably PH at exercise [29]. Notably, the (pathophysiological link) between CTED and CTEPH remains unclear as it remains to be determined that

CTED is an early form of CTEPH. Also, a considerable proportion of patients have been shown to display some degree of right ventricular dysfunction, possibly due to an inflammatory response to the acute PE [28]. This inflammatory response is triggered by myocyte stretch, shear forces, decreased perfusion and increased metabolic demand of the right ventricle (RV) due to the acute event [16, 17, 30, 31]. Notably, the most prevalent condition causing the post-PE syndrome is deconditioning after the acute cardiovascular event [24, 25, 32–35].

#### ***Clinical presentation of CTEPH***

Diagnosing CTEPH is challenging because signs of right heart failure only become evident in advanced disease stages and earlier disease stages are characterised by nonspecific or even absence of symptoms. In the International CTEPH Registry, the most common presenting symptom was dyspnoea (99%), followed by oedema (41%), fatigue (32%), chest pain (15%) and syncope (14%) [11]. In some patients, months or even years, *e.g.* the so-called honeymoon period, may pass after an episode of acute PE before clinically significant symptoms manifest. Notably, during this period, chronic pulmonary embolism is already present and progresses through ongoing pulmonary vascular remodelling [36]. Together with the poor awareness among PE caretakers and the high prevalence of post-PE functional impairment, this is likely one of the main contributors of the long diagnostic delay of CTEPH [9, 11]. In the International CTEPH Registry, the median time from last acute PE to CTEPH diagnosis was 13 months (interquartile range 5.7–34 months) [11]. Notably, most patients were in NYHA functional class III or IV at the moment of diagnosis and a post-hoc analysis of the Registry revealed that patients in the highest third of diagnostic delay had a ~4.5 mmHg higher mean pulmonary artery pressure (mPAP) at diagnosis, associated with a 47% higher predicted probability of death [11, 14]. Because of the nonspecific presentation of all conditions that could cause persistent dyspnoea after acute PE, objective tests are necessary to differentiate between deconditioning, CTED and CTEPH.

#### ***Identification of PE patients in whom presence of CTEPH should be evaluated***

CTEPH should be considered in three categories of PE patients: 1) those presenting with symptoms that could indicate CTEPH; 2) those with signs indicative of CTEPH at the moment of the acute PE diagnosis; and 3) those with risk factors or predisposing conditions for CTEPH.

Clearly, progressive signs of right heart failure in the course of acute PE should prompt a dedicated diagnostic work-up of CTEPH [37]. However, with almost half of all PE survivors reporting chronic dyspnoea and considering the low prevalence of CTEPH among those patients (<5%), the treating physician has the challenge to differentiate between CTEPH and -more common- “simple” deconditioning. In the first category, diagnostic tests should be aimed at confirming CTEPH while ruling out CTEPH would be sufficient in the latter category.

Several studies have observed that many CTEPH patients with a history of PE already had signs of CTEPH at the time of acute PE diagnosis (table 1), suggestive for diagnostic misclassification. These signs of CTEPH included estimated systolic pulmonary artery pressure (sPAP) >60 mmHg on Doppler echocardiography or typical radiological signs of CTEPH on the CTPA performed to diagnose acute PE (table 1) [38–43]. Both observations should trigger a high suspicion of CTEPH. In particular, two studies have shown that most patients with CTEPH after PE had several signs of CTEPH on the index CTPA, indicating acute-on-chronic thrombosis [39, 42]. In the first study, seven out of 126 acute PE patients in a French cohort were diagnosed with CTEPH. At the time of the acute PE diagnosis, patients with CTEPH had a higher sPAP and at least two signs of CTEPH on the initial CTPA [39].

The second was a Dutch case–control study. Three blinded expert radiologists scored radiologic signs of CTEPH on initial CTPA scans with confirmed acute PE in 50 patients who were subsequently diagnosed with CTEPH during follow-up (cases), and in 50 patients in whom sequential echocardiograms performed >2 years after the acute PE diagnosis did not show any signs of PH (controls). All controls had signs of RV overload at the moment of the acute PE diagnosis [42]. The overall expert reading yielded a sensitivity of 72% and a specificity of 94%, while multivariate analysis identified six radiologic parameters as independent predictors: intravascular webs; pulmonary artery retraction or dilatation; bronchial artery dilatation; RV hypertrophy; and interventricular septum flattening. The presence of three or more of these parameters was associated with a sensitivity of 70% (95% CI 55–82%) for a future CTEPH diagnosis, a specificity of 96% (95% CI 86–100%) and a c-statistic of 0.92. The notable observation that CTEPH may often be present at the moment of the PE diagnosis preceding the CTEPH diagnosis is highly suggestive of (some) diagnostic misclassification and supports the concept that CTEPH may not always be the “simple” consequence of poorly resolved acute PE. Because of the potential great diagnostic yield, it could be recommended to have all CTPA images of patients with confirmed acute PE evaluated for signs of CTEPH by an expert radiologist, either in the acute phase or shortly thereafter. Notably, signs of chronicity are

TABLE 1 Findings of pre-existing chronic thromboembolic pulmonary hypertension on computed tomography pulmonary angiography

**Direct vascular signs**

Eccentric wall-adherent filling defect(s), which may calcify; different from the central filling defects within a distended lumen, which are the hallmark of acute PE

Abrupt tapering and truncation

Complete occlusion and pouch defects

Intimal irregularity

Linear intraluminal filling defects (intravascular webs and bands)

Stenosis and post-stenotic dilatation

Vascular tortuosity

**Indirect vascular signs**

Significant RV hypertrophy, RA dilatation

Pericardial effusion

Dilatation of pulmonary artery (>29 mm in men and >27 mm in women) and/or calcifications of pulmonary artery

Systemic collateral arterial supply (bronchial arterial collaterals towards pulmonary post-obstructive vessels)

**Parenchymal changes**

Mosaic attenuation of the lung parenchyma resulting in geographical variation in perfusion

PE: pulmonary embolism; RV: right ventricular; RA: right atrial. Data from [37].

found in up to one-third of the patients with acute PE who are not diagnosed with CTEPH during follow-up and less experienced radiologists are unlikely to recognise all signs [42, 44]. Hence, CTPA images can normally not be considered diagnostic for CTEPH without confirmatory tests. The gap between expert reading and reading performed in daily clinical practice may be solved with education of radiologists and chest physicians or artificial intelligence-based software.

The last important patient category in whom CTEPH should be considered is the group of patients with risk factors of CTEPH, indicative of a high pre-test probability of developing this complication. Over the past decade, several risk factors and predisposing conditions have been identified in studies comparing patients with CTEPH to patients with other forms of PH, to patients with acute PE and to healthy population controls (table 2) [1, 11, 45–47]. Due to the design of these studies, the absolute risks associated with single risk factors or risk factor combinations is unknown, which makes them difficult to apply in daily practice. Moreover, some of these risk factors are prevalent and largely nonspecific, e.g. non-O blood group and high FVIII levels. Another way to evaluate the pre-test probability of developing

TABLE 2 Risk factors and predisposing conditions for chronic thromboembolic pulmonary hypertension (CTEPH)

Findings related to the acute PE event <sup>#</sup>	Concomitant chronic diseases and conditions predisposing to CTEPH <sup>¶</sup>
Previous episodes of PE or DVT	Ventriculo-atrial shunts
Large pulmonary arterial thrombi on CTPA	Infected chronic <i>i.v.</i> lines or pacemakers
Echocardiographic signs of PH/RV dysfunction	History of splenectomy
CTPA findings suggestive of pre-existing chronic thromboembolic disease (table 1)	Thrombophilic disorders, particularly antiphospholipid antibody syndrome and high coagulation factor VIII levels
	Non-O blood group
	Hypothyroidism treated with thyroid hormones
	History of cancer
	Myeloproliferative disorders
	Inflammatory bowel disease
	Chronic osteomyelitis

PE: pulmonary embolism; DVT: deep vein thrombosis; CTPA: computed tomographic pulmonary angiography; PH: pulmonary hypertension; RV: right ventricular. <sup>#</sup>: obtained at PE diagnosis; <sup>¶</sup>: documented at PE diagnosis or at 3–6 month follow-up. Reproduced from [37] with permission.

CTEPH at the time of acute PE diagnosis is application of CTEPH prediction scores, in analogy to diagnosing acute PE which is based on assessment of pre-test probability as well [48–51]. A six variable CTEPH prediction score was derived from three large European observational studies and validated in a relatively small cohort of patients with confirmed CTEPH [48, 49]. It should be noted that this CTEPH prediction score has not yet been validated in a prospective outcome study.

#### **Optimal timing for evaluating the presence of CTEPH after acute PE**

The optimal timing of diagnostic tests for CTEPH has never been studied but, in the absence of severe RV failure, is likely to be 3–6 months after the acute PE diagnosis [37]. This point in time is logical because it coincides with the time of routine evaluation of the duration and intensity of anticoagulant treatment and the evaluation of presence of cancer and/or systemic cardiovascular disease [37]. Also, physical recovery of acute PE should be achieved by this time-point and a longer delay may negatively impact the prognosis of patients with CTEPH. Moreover, thrombus resolution is mostly achieved at 3 months with no further benefit thereafter [52]. Finally, a formal CTEPH diagnosis is only possible after a 3-month treatment period with anticoagulation [37, 53].

#### **How to test for CTEPH after acute PE**

##### **Diagnostic work-up of suspected CTEPH**

The traditional diagnostic criteria for CTEPH are: mPAP  $\geq 25$  mmHg with pulmonary artery wedge pressure  $\leq 15$  mmHg; mismatched perfusion defects on ventilation/perfusion scintigraphy; and specific diagnostic signs for CTEPH on CTPA, magnetic resonance imaging or conventional pulmonary angiography [37, 53]. One additional criterion is effective anticoagulation for a period of at least 3 months before the diagnosis is confirmed by right heart catheterisation. Ongoing debate on nomenclature of CTEPH and CTED, as well as a recently published new definition of PH (which is still to be evaluated in CTEPH), will likely result in updated diagnostic criteria for CTEPH in the coming years.

The recommended diagnostic work-up of suspected CTEPH starts with transthoracic Doppler echocardiography. In addition to estimating the peak tricuspid regurgitation velocity, echocardiographic signs related to the ventricles, the pulmonary artery, the inferior vena cava and right atrium suggesting PH are used to assess the probability of PH (table 3) [53]. Conclusions derived from echocardiography should aim to assign a level of probability of PH, which could be judged as “high”, “intermediate” or “low” [53]. In patients without symptoms, a “low” probability result should rule out CTEPH. However, and in contrast, echocardiographic follow-up may be considered despite a “low” echocardiographic probability in patients with otherwise unexplained dyspnoea after excluding other potential aetiologies of dyspnoea, for instance by pulmonary function tests and/or exercise tests. The next diagnostic step for patients at “intermediate” or “high” echocardiographic probability is ventilation/perfusion lung scintigraphy. If normal, CTEPH is ruled out [37, 53, 54]. Importantly, the diagnosis of CTEPH should always be confirmed by right heart catheterisation. Hence patients at “intermediate” or “high” echocardiographic probability in combination with mismatched perfusion defects should be referred for invasive measurements, preferably in a CTEPH expert centre with multidisciplinary teams. The diagnostic work-up is completed with CTPA, magnetic resonance and/or conventional pulmonary angiography to confirm the diagnosis and assess operability or other treatment options (figure 2) [3, 37, 53].

TABLE 3 Echocardiographic probability of pulmonary hypertension (PH) in symptomatic patients with a suspicion of PH

Peak tricuspid regurgitation velocity $\text{m}\cdot\text{s}^{-1}$	Presence of other echocardiographic signs of PH <sup>#</sup>	Echocardiographic probability of PH
$\leq 2.8$ or not measurable	No	Low
$\leq 2.8$ or not measurable	Yes	Intermediate
2.9–3.4	No	Intermediate
2.9–3.4	Yes	High
$> 3.4$	Not required	High

<sup>#</sup>: right ventricle/left ventricle basal diameter ratio  $> 1.0$ , flattening of the interventricular septum (left ventricular eccentricity index  $> 1.1$  in systole and/or diastole), right ventricular outflow doppler acceleration time  $< 105$  ms and/or mid-systolic notching, early diastolic pulmonary regurgitation velocity  $> 2.2$   $\text{m}\cdot\text{s}^{-1}$ , pulmonary artery diameter  $> 25$  mm, inferior cava diameter  $> 21$  mm with decreased inspiratory collapse [ $< 50\%$  with a sniff or  $< 20\%$  with quiet inspiration], right atrial area (end-systole)  $> 18$   $\text{cm}^2$ . Reproduced from [53] with permission.

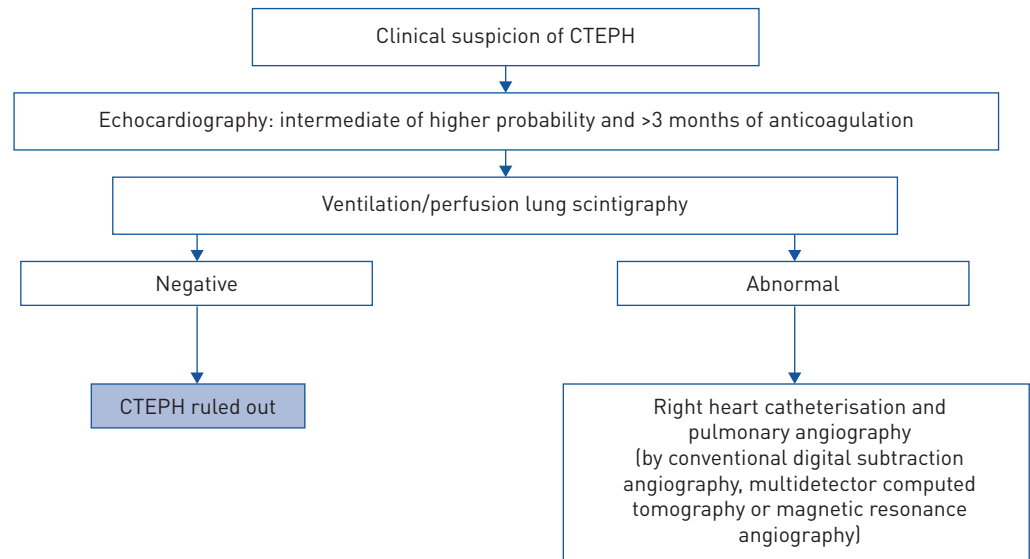


FIGURE 2 Diagnostic algorithm for chronic thromboembolic pulmonary hypertension (CTEPH). Data from [37].

### ***Ruling out CTEPH***

The 2019 European Society of Cardiology (ESC) acute PE guidelines recommend against routine echocardiography in all PE survivors because of the low yield and to prevent excess healthcare costs and overdiagnosis [55]. Instead, it is suggested that further diagnostic evaluation should be considered in patients with persistent or new onset dyspnoea/exercise limitation after acute PE, and may be considered in asymptomatic patients with risk factors for CTEPH [37]. Importantly, since 50% of acute PE patients will present with some degree of persistent symptoms, of which the majority is caused by deconditioning [23, 24], it may be reasonable to apply tests other than echocardiography in the absence of symptoms of heart failure, CT signs indicative of CTEPH at the moment of acute PE diagnosis, or risk factors for CTEPH.

First, a normal ventilation/perfusion lung scintigraphy rules out CTEPH with the highest certainty, although concerns about radiation exposure, costs and availability have been raised [37, 53, 54]. Therefore, ventilation/perfusion scintigraphy is not recommended as a primary test to rule out CTEPH in the majority of patients. Secondly, the combination of a normal ECG and N-terminal pro-brain natriuretic peptide (NT-proBNP) level has been suggested to rule out CTEPH with good certainty. Several ECG abnormalities are suggestive of the presence of PH including right axis derivation, RV hypertrophy, RV strain, right bundle branch block and QTc prolongation, although these lack diagnostic accuracy which would allow application of ECGs as a stand-alone test for ruling out CTEPH [53]. The same holds true for cardiac biomarkers. However, the combination of ECG and biomarker assessment to rule out PH has been successfully applied in several PH detection studies. For instance, ECG assessment and NT-proBNP measurement (threshold  $100 \text{ pg}\cdot\text{mL}^{-1}$ ) are major components of the DETECT score that is applied to identify patients at low risk of systemic sclerosis-associated PH in whom further diagnostic tests are not indicated [56]. In a different setting, it was reported that none of the 251 patients referred for suspicion of pre-capillary PH were diagnosed with PH in the absence of both a RV strain pattern on ECG and elevated NT-proBNP [57]. Finally, in a case-control study, several combinations of ECG characteristics and biomarkers were evaluated to distinguish patients with post-PE persistent dyspnoea without CTEPH from patients with confirmed CTEPH [58]. The optimal combination was named the “CTEPH rule out criteria” and consisted of a normal NT-proBNP test (manufacturer and age dependent threshold) in combination with the absence of specific electrocardiographic characteristics of RV overload. The sensitivity of the “CTEPH rule-out criteria” was 94% and the specificity was 56%. In the practice-based setting of busy PE follow-up clinics, two independent German studies confirmed the high sensitivity of the “CTEPH rule-out criteria” (100% in both studies), with excellent inter-observer agreement (kappa statistic 0.97) [59, 60]. Importantly, neither of these two studies was a prospective outcome study where the “CTEPH rule-out criteria” were used to reject CTEPH without performing additional diagnostic tests.

Cardiopulmonary exercise testing (CPET) holds diagnostic clues to CTEPH as well, and additionally may provide an alternative diagnosis for the clinical presentation, notably deconditioning and chronic underlying cardiac or respiratory diseases [43, 61]. CTEPH typically appears as ineffective ventilation with elevated alveolar-capillary gradients of oxygen and carbon dioxide, reduced peak oxygen uptake and

increased ventilatory equivalent in carbon dioxide (minute ventilation/carbon dioxide production) in the absence of ventilatory limitation. The sensitivity of CPET for CTEPH is reported to be 80% [43, 61]. The absence of signs of CTEPH on CPET cannot be regarded as a definite criterion to rule out CTEPH, although the likelihood of CTEPH is very low in the setting of an established alternative diagnosis. The other way round, typical signs of CTEPH on CPET may necessitate right heart catheterisation in the setting of symptomatic patients with low-probability echocardiography [61]. Hence, because it can reveal several mechanisms of dyspnoea (cardiac, respiratory limitations and deconditioning) CPET deserves a central role next to echocardiography in the diagnostic work-up of patients with the post-PE syndrome.

### Best practices for earlier CTEPH detection after acute PE

In current clinical practice, the diagnostic delay for CTEPH after a PE diagnosis has been reported to be 14–24 months [9, 11, 12, 50]. Although this diagnostic delay was not associated with operability in the European CTEPH registry, a longer diagnostic delay was shown to correlate to higher sPAP at diagnosis and increased risk of death [11, 14]. Even in the short time elapsed between diagnosis of CTEPH and referral to a CTEPH expertise centre (mean 4.4 months), it was observed that cardiac output decreases and mPAP increases slightly [62]. Low awareness among physicians and, until recently, lack of clear guideline recommendations regarding the optimal follow-up of patients with acute PE are the main contributors to the current considerable diagnostic delay [12, 37]. It has even been reported that patients with diagnosed CTEPH in the course of acute PE consulted a median of four different physicians for a median of 13 consultations before the correct diagnosis was made. The observations that echocardiographic results suggestive of CTEPH were not always followed by an adequate work-up and most patients were not subjected to ventilation/perfusion scanning both indicate poor healthcare utilisation and clear room for improvement [12].

The 2019 ESC PE guideline for the diagnosis and management of acute PE proposed a dedicated follow-up strategy after acute PE (figure 3a) [37]. The algorithm starts with the routine assessment of PE patients 3–6 months after the acute episode with evaluation of the presence of persistence (or new onset) dyspnoea or functional limitations. The Medical Research Council scale or the NYHA functional class can be used to standardise the evaluation of dyspnoea [37]. In patients presenting with persisting dyspnoea and/or poor physical performance, Doppler echocardiography is considered to be the next best step to assess the probability of CTEPH. The algorithm indicates that patients with a high echocardiographic probability, and those with intermediate probability combined with elevated NT-proBNP levels or risk factors/predisposing conditions for CTEPH, should follow the recommended diagnostic work-up of CTEPH as described above. The role of CPET in this algorithm is to provide an alternative diagnosis to patients with symptoms but normal echocardiography and/or normal ventilation/perfusion scintigraphy. Non-symptomatic patients with risk factors or predisposing conditions for CTEPH are suggested to either be followed over time for the occurrence of symptoms, or to be subjected to echocardiography.

Alternative strategies have been suggested. For instance, the InShape II algorithm aims to overcome the high number of echocardiograms that would be needed given the high prevalence of dyspnoea in PE survivors [50]. The algorithm combines the CTEPH prediction rule, CTEPH rule-out criteria and symptomatic follow-up of patients with acute PE (figure 3b). At the routine outpatient follow-up visit 3 months after the diagnosis of acute PE, pre-test probability of CTEPH is calculated and patients are assessed for the presence of symptoms suggestive of CTEPH [50]. Patients with either a CTEPH prediction score of >6 points or who report symptoms are subjected to the CTEPH rule-out criteria. If abnormal, patients are referred for echocardiography. This algorithm is currently being evaluated in a prospective, multicentre outcome study in consecutive acute PE patients (NCT02555137; <https://clinicaltrials.gov/>). All patients are managed according to the strategy. Main outcomes are the number and yield of echocardiograms indicated at baseline and the 2-year CTEPH incidence in patients in whom CTEPH was initially considered absent. At baseline, echocardiograms were indicated in only 19% of patients and a CTEPH incidence equivalent to previous literature (2.6%) was found within 6 months after the index PE [63]. This would suggest that application of the algorithm would lead to an early CTEPH diagnosis in a considerable number of patients. Results of ongoing 2-year follow-up will determine the strategy's sensitivity. Importantly, even when the algorithm rules out CTEPH without the need for imaging tests, echocardiography and/or CPET may be indicated to evaluate the presence of alternative diagnoses.

In addition to outpatient follow-up according to a dedicated algorithm, two studies also suggested that centralised telephonic follow-up of patients with acute PE may help to identify patients with CTEPH [64, 65]. In both prospective observational studies, echocardiography was performed in patients who reported symptoms suggestive of CTEPH during a short telephonic interview, with one of the two studies applying CPET in patients with low echocardiographic probability to improve the sensitivity of the diagnostic work-up [61, 64]. In both studies, the expected CTEPH incidence was met.

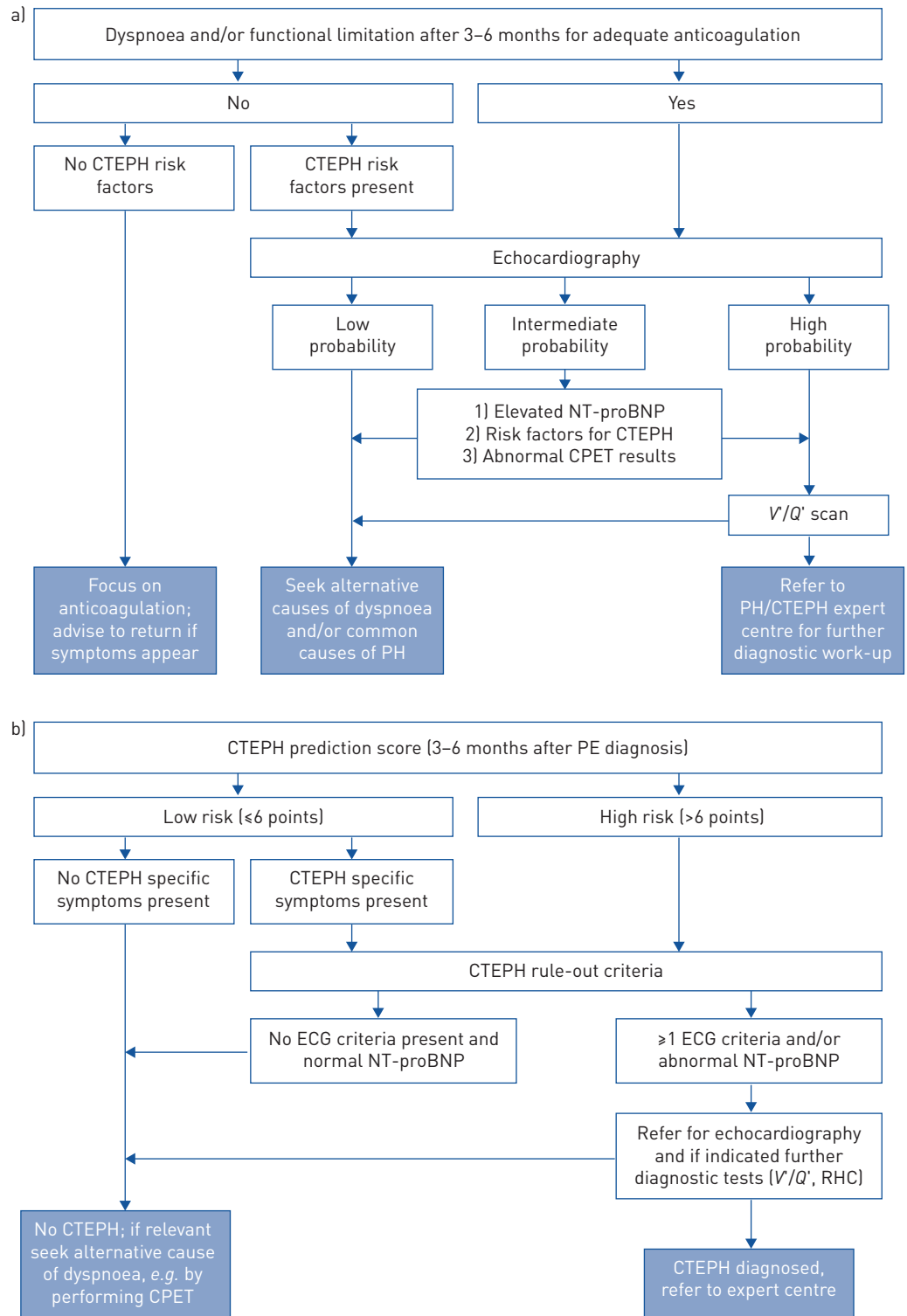


FIGURE 3 a) Follow-up strategy and diagnostic workup for long-term sequelae of pulmonary embolism (PE). Modified from [37] with permission. b) Follow-up strategy for early detection of chronic thromboembolic pulmonary hypertension (CTEPH) after acute PE as applied in the InShape II study (NCT0255137) to overcome the high number of echocardiograms that would be needed given the high prevalence of persistent dyspnoea in PE survivors [50]. NT-proBNP: N-terminal pro-brain natriuretic peptide; CPET: cardiopulmonary exercise testing; V/Q': ventilation/perfusion; PH: pulmonary hypertension; RHC: right heart catheterisation.

### Back to the case

The patient in our case vignette presented with symptoms that could suggest CTEPH. Moreover, she has several predisposing conditions and risk factors for CTEPH, *i.e.* recurrent and now unprovoked PE and

hypothyroidism. Upon close reassessment of the CTPA scan performed to diagnose the recurrent PE, a complete occlusion of the right middle lobe, severe RV overload, and both pulmonary artery and bronchial artery dilatation were noted (figure 1). The ECG showed no signs of RV overload but the NT-proBNP level was  $640 \text{ ng}\cdot\text{L}^{-1}$  (normal value  $<200 \text{ ng}\cdot\text{mL}^{-1}$ ). The patient had a clear indication for Doppler echocardiography, which showed normal RV function but a peak tricuspid regurgitation velocity of  $3.2 \text{ m}\cdot\text{s}^{-1}$  (intermediate probability). The ventilation/perfusion scan showed bilateral mismatched perfusion defects. Right heart catheterisation revealed a mPAP of 32 mmHg with a PVR of  $316 \text{ dyn}\cdot\text{s}^{-1}\cdot\text{cm}^{-5}$ . The patient was diagnosed with CTEPH. After multidisciplinary discussion in an expert centre, her treatment consisted of continuation of the anticoagulation and pulmonary endarterectomy. She was doing well 6 months after the surgery. Upon right heart catheterisation, the mPAP had returned to normal (15 mmHg) with a PVR of  $168 \text{ dyn}\cdot\text{s}^{-1}\cdot\text{cm}^{-5}$ .

## Conclusion

Improving education of PE caretakers, higher awareness for CTEPH and further evaluation, validation and implementation of clinical/radiological algorithms for earlier CTEPH diagnosis will likely help ensure earlier referral to expert centres and improved prognosis. The diagnostic work-up of suspected CTEPH is well established and starts with echocardiography. Other tests could be used to exclude the presence of CTEPH and/or to establish an alternative diagnosis. It may be reasonable to apply these alternative diagnostic tests specified to the individual patient with specific characteristics, especially when the pre-test probability of CTEPH is very low. This would allow for optimal use of healthcare resources and prevention of overdiagnosis.

**Acknowledgements:** The concept of this narrative review was developed with the support of Actelion Pharmaceuticals Ltd. The current paper was drafted, critically reviewed, and edited solely by the authors. All authors contributed to manuscript writing and provided final approval for submission.

**Author contributions:** F.A. Klok drafted the first version of the manuscript. All authors revised the review critically for important intellectual content and agree with the final version.

**Conflict of interest:** F.A. Klok reports research grants from Bayer, Bristol-Myers Squibb, Boehringer Ingelheim, Daiichi-Sankyo, MSD and Actelion, the Dutch Heart foundation and the Dutch Thrombosis association. F. Couturaud reports grants from Pfizer, personal fees from Bayer and Leopharma, personal fees from and has contributed to clinical trials for BMS and AstraZeneca, and has contributed to clinical trials for Boehringer, Daiichi, GSK and Actelion, outside the submitted work. M. Delcroix reports grants and personal fees for research, lectures and consultancy from Actelion/J&J, personal fees for research, lectures and consultancy from Bayer, personal fees for lectures and consultancy from MSD, personal fees for research from Reata, personal fees for research and consultancy from Bellarophon, personal fees for consultancy from Acceleron, outside the submitted work. M. Humbert reports grants and personal fees from Bayer and GSK, personal fees from Acceleron, Actelion, MSD and United Therapeutics, outside the submitted work.

## References

- 1 Delcroix M, Kerr K, Fedullo P. Chronic thromboembolic pulmonary hypertension. epidemiology and risk factors. *Ann Am Thorac Soc* 2016; 13: Suppl. 3, S201–S206.
- 2 Ende-Verhaar YM, Cannegieter SC, Vonk Noordegraaf A, *et al.* Incidence of chronic thromboembolic pulmonary hypertension after acute pulmonary embolism: a contemporary view of the published literature. *Eur Respir J* 2017; 49: 1601792.
- 3 Kim NH, Delcroix M, Jais X, *et al.* Chronic thromboembolic pulmonary hypertension. *Eur Respir J* 2019; 53: 1801915.
- 4 Simonneau G, Torbicki A, Dorfmueller P, *et al.* The pathophysiology of chronic thromboembolic pulmonary hypertension. *Eur Respir Rev* 2017; 26: 160112.
- 5 Dorfmueller P, Gunther S, Ghigna MR, *et al.* Microvascular disease in chronic thromboembolic pulmonary hypertension: a role for pulmonary veins and systemic vasculature. *Eur Respir J* 2014; 44: 1275–1288.
- 6 Egermayer P, Peacock AJ. Is pulmonary embolism a common cause of chronic pulmonary hypertension? Limitations of the embolic hypothesis. *Eur Respir J* 2000; 15: 440–448.
- 7 Madani M, Ogo T, Simonneau G. The changing landscape of chronic thromboembolic pulmonary hypertension management. *Eur Respir Rev* 2017; 26: 170105.
- 8 Aoki T, Sugimura K, Tatebe S, *et al.* Comprehensive evaluation of the effectiveness and safety of balloon pulmonary angioplasty for inoperable chronic thrombo-embolic pulmonary hypertension: long-term effects and procedure-related complications. *Eur Heart J* 2017; 38: 3152–3159.
- 9 Delcroix M, Lang I, Pepke-Zaba J, *et al.* Long-term outcome of patients with chronic thromboembolic pulmonary hypertension: results from an International Prospective Registry. *Circulation* 2016; 133: 859–871.
- 10 Taniguchi Y, Jais X, Jevnikar M, *et al.* Predictors of survival in patients with not-operated chronic thromboembolic pulmonary hypertension. *J Heart Lung Transplant* 2019; 38: 833–842.
- 11 Pepke-Zaba J, Delcroix M, Lang I, *et al.* Chronic thromboembolic pulmonary hypertension (CTEPH): results from an international prospective registry. *Circulation* 2011; 124: 1973–1981.
- 12 Ende-Verhaar YM, van den Hout WB, Bogaard HJ, *et al.* Healthcare utilization in chronic thromboembolic pulmonary hypertension after acute pulmonary embolism. *J Thromb Haemost* 2018; 16: 2168–2174.
- 13 Barco S, Klok FA, Konstantinides SV, *et al.* Sex-specific differences in chronic thromboembolic pulmonary hypertension. Results from the European CTEPH registry. *J Thromb Haemost* 2020; 18: 151–161.

- 14 Klok FA, Barco S, Konstantinides SV, *et al.* Determinants of diagnostic delay in chronic thromboembolic pulmonary hypertension: results from the European CTEPH Registry. *Eur Respir J* 2018; 52: 1801687.
- 15 Klok FA, Tijmensen JE, Haeck ML, *et al.* Persistent dyspnea complaints at long-term follow-up after an episode of acute pulmonary embolism: results of a questionnaire. *Eur J Intern Med* 2008; 19: 625–629.
- 16 Stevinson BG, Hernandez-Nino J, Rose G, *et al.* Echocardiographic and functional cardiopulmonary problems 6 months after first-time pulmonary embolism in previously healthy patients. *Eur Heart J* 2007; 28: 2517–2524.
- 17 Kline JA, Steuerwald MT, Marchick MR, *et al.* Prospective evaluation of right ventricular function and functional status 6 months after acute submassive pulmonary embolism: frequency of persistent or subsequent elevation in estimated pulmonary artery pressure. *Chest* 2009; 136: 1202–1210.
- 18 Klok FA, van Kralingen KW, van Dijk AP, *et al.* Prevalence and potential determinants of exertional dyspnea after acute pulmonary embolism. *Respir Med* 2010; 104: 1744–1749.
- 19 Keller K, Tesche C, Gerhold-Ay A, *et al.* Quality of life and functional limitations after pulmonary embolism and its prognostic relevance. *J Thromb Haemost* 2019; 17: 1923–1934.
- 20 Klok FA, van Kralingen KW, van Dijk AP, *et al.* Quality of life in long-term survivors of acute pulmonary embolism. *Chest* 2010; 138: 1432–1440.
- 21 Tavoly M, Wik HS, Sirnes PA, *et al.* The impact of post-pulmonary embolism syndrome and its possible determinants. *Thromb Res* 2018; 171: 84–91.
- 22 van Es J, den Exter PL, Kaptein AA, *et al.* Quality of life after pulmonary embolism as assessed with SF-36 and PEmb-QoL. *Thromb Res* 2013; 132: 500–505.
- 23 Kahn SR, Akaberi A, Granton JT, *et al.* Quality of life, dyspnea, and functional exercise capacity following a first episode of pulmonary embolism: results of the ELOPE Cohort Study. *Am J Med* 2017; 130: 990e9–99e21.
- 24 Kahn SR, Hirsch AM, Akaberi A, *et al.* Functional and exercise limitations after a first episode of pulmonary embolism: results of the ELOPE Prospective Cohort Study. *Chest* 2017; 151: 1058–1068.
- 25 Huisman MV, Barco S, Cannegieter SC, *et al.* Pulmonary embolism. *Nat Rev Dis Primers* 2018; 4: 18028.
- 26 Klok FA, Barco S. Follow-up after acute pulmonary embolism. *Hamostaseologie* 2018; 38: 22–32.
- 27 Klok FA, van der Hulle T, den Exter PL, *et al.* The post-PE syndrome: a new concept for chronic complications of pulmonary embolism. *Blood Rev* 2014; 28: 221–226.
- 28 Sista AK, Klok FA. Late outcomes of pulmonary embolism: the post-PE syndrome. *Thromb Res* 2018; 164: 157–162.
- 29 Claeys M, Claessen G, La Gerche A, *et al.* Impaired cardiac reserve and abnormal vascular load limit exercise capacity in chronic thromboembolic disease. *JACC Cardiovasc Imaging* 2019; 12: 1444–1456.
- 30 Sista AK, Miller LE, Kahn SR, *et al.* Persistent right ventricular dysfunction, functional capacity limitation, exercise intolerance, and quality of life impairment following pulmonary embolism: systematic review with meta-analysis. *Vasc Med* 2017; 22: 37–43.
- 31 Barco S, Russo M, Vicaut E, *et al.* Incomplete echocardiographic recovery at 6 months predicts long-term sequelae after intermediate-risk pulmonary embolism. A post-hoc analysis of the Pulmonary Embolism Thrombolysis (PEITHO) trial. *Clin Res Cardiol* 2019; 108: 772–778.
- 32 Klok FA, Delcroix M, Bogaard HJ. Chronic thromboembolic pulmonary hypertension from the perspective of patients with pulmonary embolism. *J Thromb Haemost* 2018; 16: 1040–1051.
- 33 Taboada D, Pepke-Zaba J, Jenkins DP, *et al.* Outcome of pulmonary endarterectomy in symptomatic chronic thromboembolic disease. *Eur Respir J* 2014; 44: 1635–1645.
- 34 Fernandes TM, Alotaibi M, Strozza D, *et al.* Dyspnea postpulmonary embolism from the physiological dead space proportion and stroke volume defects during exercise. *Chest* 2020; 157: 936–944.
- 35 Albaghdadi MS, Dudzinski DM, Giordano N, *et al.* Cardiopulmonary exercise testing in patients following massive and submassive pulmonary embolism. *J Am Heart Assoc* 2018; 7: e006841.
- 36 Lang IM, Madani M. Update on chronic thromboembolic pulmonary hypertension. *Circulation* 2014; 130: 508–518.
- 37 Konstantinides SV, Meyer G, Becattini C, *et al.* ESC Guidelines for the diagnosis and management of acute pulmonary embolism developed in collaboration with the European Respiratory Society (ERS): The Task Force for the diagnosis and management of acute pulmonary embolism of the European Society of Cardiology (ESC). *Eur Respir J* 2019; 54: 1901647.
- 38 McIntyre KM, Sasahara AA. The hemodynamic response to pulmonary embolism in patients without prior cardiopulmonary disease. *Am J Cardiol* 1971; 28: 288–294.
- 39 Guerin L, Couturaud F, Parent F, *et al.* Prevalence of chronic thromboembolic pulmonary hypertension after acute pulmonary embolism. Prevalence of CTEPH after pulmonary embolism. *Thromb Haemost* 2014; 112: 598–605.
- 40 Rajaram S, Swift AJ, Condliffe R, *et al.* CT features of pulmonary arterial hypertension and its major subtypes: a systematic CT evaluation of 292 patients from the ASPIRE Registry. *Thorax* 2015; 70: 382–387.
- 41 Nishiyama KH, Saboo SS, Tanabe Y, *et al.* Chronic pulmonary embolism: diagnosis. *Cardiovasc Diagn Ther* 2018; 8: 253–271.
- 42 Ende-Verhaar YM, Meijboom LJ, Kroft LJM, *et al.* Usefulness of standard computed tomography pulmonary angiography performed for acute pulmonary embolism for identification of chronic thromboembolic pulmonary hypertension: results of the InShape III study. *J Heart Lung Transplant* 2019; 38: 731–738.
- 43 Gopalan D, Delcroix M, Held M. Diagnosis of chronic thromboembolic pulmonary hypertension. *Eur Respir Rev* 2017; 26: 160108.
- 44 Rogberg AN, Gopalan D, Westerlund E, *et al.* Do radiologists detect chronic thromboembolic disease on computed tomography? *Acta Radiol* 2019; 60: 1576–1583.
- 45 Lang IM, Simonneau G, Pepke-Zaba JW, *et al.* Factors associated with diagnosis and operability of chronic thromboembolic pulmonary hypertension. A case-control study. *Thromb Haemost* 2013; 110: 83–91.
- 46 Bonderman D, Jakowitsch J, Adlbrecht C, *et al.* Medical conditions increasing the risk of chronic thromboembolic pulmonary hypertension. *Thromb Haemost* 2005; 93: 512–516.
- 47 Bonderman D, Wilkens H, Wakounig S, *et al.* Risk factors for chronic thromboembolic pulmonary hypertension. *Eur Respir J* 2009; 33: 325–331.
- 48 Klok FA, Dzikowska-Diduch O, Kostrubiec M, *et al.* Derivation of a clinical prediction score for chronic thromboembolic pulmonary hypertension after acute pulmonary embolism. *J Thromb Haemost* 2016; 14: 121–128.

- 49 Ende-Verhaar YM, Ruigrok D, Bogaard HJ, *et al.* Sensitivity of a simple noninvasive screening algorithm for chronic thromboembolic pulmonary hypertension after acute pulmonary embolism. *TH Open* 2018; 2: e89–e95.
- 50 Ende-Verhaar YM, Huisman MV, Klok FA. To screen or not to screen for chronic thromboembolic pulmonary hypertension after acute pulmonary embolism. *Thromb Res* 2017; 151: 1–7.
- 51 Huisman MV, Klok FA. How I diagnose acute pulmonary embolism. *Blood* 2013; 121: 4443–4448.
- 52 Nijkeuter M, Hovens MM, Davidson BL, *et al.* Resolution of thromboemboli in patients with acute pulmonary embolism: a systematic review. *Chest* 2006; 129: 192–197.
- 53 Galie N, Humbert M, Vachiery JL, *et al.* 2015 ESC/ERS Guidelines for the diagnosis and treatment of pulmonary hypertension: The Joint Task Force for the Diagnosis and Treatment of Pulmonary Hypertension of the European Society of Cardiology (ESC) and the European Respiratory Society (ERS): Endorsed by: Association for European Paediatric and Congenital Cardiology (AEPC), International Society for Heart and Lung Transplantation (ISHLT). *Eur Heart J* 2016; 37: 67–119.
- 54 Tunariu N, Gibbs SJ, Win Z, *et al.* Ventilation-perfusion scintigraphy is more sensitive than multidetector CTPA in detecting chronic thromboembolic pulmonary disease as a treatable cause of pulmonary hypertension. *J Nucl Med* 2007; 48: 680–684.
- 55 Konstantinides SV, Torbicki A, Agnelli G, *et al.* 2014 ESC guidelines on the diagnosis and management of acute pulmonary embolism. *Eur Heart J* 2014; 35: 3033–3069.
- 56 Coghlan JG, Denton CP, Grunig E, *et al.* Evidence-based detection of pulmonary arterial hypertension in systemic sclerosis: the DETECT study. *Ann Rheum Dis* 2014; 73: 1340–1349.
- 57 Bonderman D, Wexberg P, Martischinig AM, *et al.* A noninvasive algorithm to exclude pre-capillary pulmonary hypertension. *Eur Respir J* 2011; 37: 1096–1103.
- 58 Klok FA, Surie S, Kempf T, *et al.* A simple non-invasive diagnostic algorithm for ruling out chronic thromboembolic pulmonary hypertension in patients after acute pulmonary embolism. *Thromb Res* 2011; 128: 21–26.
- 59 Klok FA, Tesche C, Rappold L, *et al.* External validation of a simple non-invasive algorithm to rule out chronic thromboembolic pulmonary hypertension after acute pulmonary embolism. *Thromb Res* 2015; 135: 796–801.
- 60 Barco S, Mavromanoli A, Klok FA, *et al.* The rule-out criteria for chronic thromboembolic pulmonary hypertension can identify patients without haemodynamic abnormalities and functional limitation 3 and 12 months after acute PE. *Res Pract Thromb Haemost* 2019; 3: 200.
- 61 Held M, Grun M, Holl R, *et al.* Cardiopulmonary exercise testing to detect chronic thromboembolic pulmonary hypertension in patients with normal echocardiography. *Respiration* 2014; 87: 379–387.
- 62 Jensen KW, Kerr KM, Fedullo PF, *et al.* Pulmonary hypertensive medical therapy in chronic thromboembolic pulmonary hypertension before pulmonary thromboendarterectomy. *Circulation* 2009; 120: 1248–1254.
- 63 Boon GJAM, Bavalia R, Delcroix M, *et al.* Early identification of chronic thromboembolic pulmonary hypertension after pulmonary embolism (InShape II Study). *Res Pract Thromb Haemost* 2019; 3: 200.
- 64 Held M, Hesse A, Gott F, *et al.* A symptom-related monitoring program following pulmonary embolism for the early detection of CTEPH: a prospective observational registry study. *BMC Pulm Med* 2014; 14: 141.
- 65 Coquoz N, Weilenmann D, Stolz D, *et al.* Multicentre observational screening survey for the detection of CTEPH following pulmonary embolism. *Eur Respir J* 2018; 51: 1702505.