



Universiteit
Leiden
The Netherlands

Stroke etiology and thrombus computed tomography characteristics in patients with acute ischemic stroke: a MR CLEAN registry substudy

Boodt, N.; Compagne, K.C.J.; Dutra, B.G.; Samuels, N.; Tolhuisen, M.L.; Alves, H.C.B.R.; ... ; MR CLEAN Registry Investigators

Citation

Boodt, N., Compagne, K. C. J., Dutra, B. G., Samuels, N., Tolhuisen, M. L., Alves, H. C. B. R., ... Lugt, A. van der. (2020). Stroke etiology and thrombus computed tomography characteristics in patients with acute ischemic stroke: a MR CLEAN registry substudy. *Stroke*, 51(6), 1727-1735. doi:10.1161/STROKEAHA.119.027749

Version: Publisher's Version
License: [Creative Commons CC BY 4.0 license](https://creativecommons.org/licenses/by/4.0/)
Downloaded from: <https://hdl.handle.net/1887/3184805>

Note: To cite this publication please use the final published version (if applicable).

Stroke Etiology and Thrombus Computed Tomography Characteristics in Patients With Acute Ischemic Stroke

A MR CLEAN Registry Substudy

Nikki Boodt¹ MD; Kars C.J. Compagne, BSc;
 Bruna G. Dutra, MD; Noor Samuels, MD; Manon L. Tolhuisen, MSc; Heitor C.B.R. Alves, MD;
 Manon Kappelhof, MD; Geert J. Lycklama à Nijeholt, MD, PhD;
 Henk. A. Marquering, MSc, PhD; Charles B.L.M. Majoie, MD, PhD;
 Hester F. Lingsma, MSc, PhD; Diederik W.J. Dippel, MD, PhD; Aad van der Lugt, MD, PhD;
 on behalf of the MR CLEAN Registry Investigators*

Background and Purpose—If a relationship between stroke etiology and thrombus computed tomography characteristics exists, assessing these characteristics in clinical practice could serve as a useful additional diagnostic tool for the identification of stroke subtype. Our purpose was to study the association of stroke etiology and thrombus computed tomography characteristics in patients with acute ischemic stroke due to a large vessel occlusion.

Methods—For 1429 consecutive patients enrolled in the MR CLEAN Registry, we determined stroke cause as defined by the TOAST (Trial of ORG 10172 in Acute Stroke Treatment) criteria. The association of stroke etiology with the hyperdense artery sign, clot burden score, and thrombus location was estimated with univariable and multivariable binary and ordinal logistic regression. Additionally, for 367 patients with available thin-section imaging, we assessed the association of stroke etiology with absolute and relative thrombus attenuation, distance from internal carotid artery-terminus to thrombus, thrombus length, and thrombus attenuation increase with univariable and multivariable linear regression.

Results—Compared with cardioembolic strokes, noncardioembolic strokes were associated with presence of hyperdense artery sign (odds ratio, 2.2 [95% CI, 1.6–3.0]), lower clot burden score (common odds ratio, 0.4 [95% CI, 0.3–0.6]), shift towards a more proximal thrombus location (common odds ratio, 0.2 [95% CI, 0.2–0.3]), higher absolute thrombus attenuation (β , 3.6 [95% CI, 0.9–6.4]), decrease in distance from the ICA-terminus (β , –5.7 [95% CI, –8.3 to –3.0]), and longer thrombi (β , 8.6 [95% CI, 6.5–10.7]), based on univariable analysis. Thrombus characteristics of strokes with undetermined cause were similar to those of cardioembolic strokes.

Conclusions—Thrombus computed tomography characteristics of cardioembolic stroke are distinct from those of noncardioembolic stroke. Additionally, our study supports the general hypothesis that many cryptogenic strokes have a cardioembolic cause. Further research should focus on the use of thrombus computed tomography characteristics as a diagnostic tool for stroke cause in clinical practice. (*Stroke*. 2020;51:1727-1735. DOI: 10.1161/STROKEAHA.119.027749.)

Key Words: atrial fibrillation ■ computed tomography angiography ■ endovascular procedures ■ stroke
 ■ thrombectomy ■ thrombosis

Atrial fibrillation (AF) is a common and devastating cardioembolic cause of stroke.¹ Treatment with anticoagulants reduces the risk of recurrent stroke by 39% to 63% compared with treatment with antiplatelet agents.^{2,3} However, because of its paroxysmal nature, AF often goes undetected,^{4,5} leaving a

considerable proportion of patients under suboptimal protection for recurrent stroke.

In patients with acute ischemic stroke (AIS) treated with endovascular treatment (EVT) for a large vessel occlusion, various thrombus characteristics can be assessed on admission

Received September 17, 2019; final revision received March 9, 2020; accepted April 13, 2020.

From the Department of Radiology and Nuclear Medicine (N.B., K.C.J.C., N.S., A.v.d.L.), Department of Neurology (N.B., K.C.J.C., N.S., D.W.J.D.), and Department of Public Health (N.B., N.S., H.F.L.), Erasmus MC, University Medical Center Rotterdam, the Netherlands; Department of Radiology and Nuclear Medicine (B.G.D., M.L.T., H.C.B.R.A., M.K., H.A.M., C.B.L.M.M.) and Department of Biomedical Engineering and Physics (M.L.T., H.A.M.), location AMC, Amsterdam UMC, Academic Medical Center, the Netherlands; and Department of Radiology, Haaglanden Medical Center, The Hague, the Netherlands (G.J.L.à.N.).

*A list of all MR CLEAN Registry investigators is given in the Appendix.

Presented in part at the European Stroke Organisation Conference, Milan, Italy, May 22–24, 2019.

The Data Supplement is available with this article at <https://www.ahajournals.org/doi/suppl/10.1161/STROKEAHA.119.027749>.

Correspondence to: Nikki Boodt, MD, Erasmus MC, Department of Radiology, Doctor Molewaterplein 40, 3015 GD Rotterdam, the Netherlands. Email n.boodt@erasmusmc.nl

© 2020 The Authors. *Stroke* is published on behalf of the American Heart Association, Inc., by Wolters Kluwer Health, Inc. This is an open access article under the terms of the [Creative Commons Attribution Non-Commercial-NoDerivs](https://creativecommons.org/licenses/by-nc-nd/4.0/) License, which permits use, distribution, and reproduction in any medium, provided that the original work is properly cited, the use is noncommercial, and no modifications or adaptations are made.

Stroke is available at <https://www.ahajournals.org/journal/str>

DOI: 10.1161/STROKEAHA.119.027749

computed tomography (CT) and CT angiography (CTA). If a relationship between a cardioembolic stroke cause and thrombus CT characteristics exists, assessing these characteristics in clinical practice could serve as a useful additional tool to identify patients with covert AF or other cardioembolic risk factors for stroke and serve as a reason to intensify diagnostic workup for a cardioembolic source in these patients.

Recent histological studies have described the relationship of stroke cause with the histological composition of retrieved thrombi during EVT for AIS.^{6,7} One of the most important findings of these studies was that fibrin-rich (red blood cell [RBC]-poor) thrombi were associated with a cardioembolic cause of stroke. In addition, thrombus histological composition was shown to be related to thrombus attenuation increase (TAI), a measure for thrombus permeability, which in turn is related to thrombus length and location.^{8–10} Furthermore, earlier work has described the correlation between thrombus RBC-content and thrombus attenuation on CT imaging.¹¹

Evidence of the relationship of stroke cause with thrombus imaging characteristics is limited, and studies, so far, are small and have mainly focused on the hyperdense artery sign (HAS), which is an ill-defined measure with moderate interobserver variability,¹² or on thrombus permeability.^{8,9} Our purpose was to study the relationship between stroke cause and various thrombus CT characteristics in a large, multi-center cohort of patients with ischemic stroke due to an acute large vessel occlusion.

Methods

Study Population

The MR CLEAN Registry (Multicenter Randomized Clinical Trial of Endovascular Treatment for Acute Ischemic Stroke in the Netherlands) is a prospective observational study of all patients that underwent EVT for AIS in the Netherlands.¹³ Enrollment started on 16 March, 2014, directly after the final randomization in the MR CLEAN trial. All patients undergoing EVT (defined as at least entry into the angiography suite and receiving arterial puncture) for AIS in the anterior or posterior circulation, treated in one of the 16 centers performing EVT in the Netherlands, were registered. The central medical ethics committee of the Erasmus Medical Center Rotterdam, the Netherlands evaluated the study protocol and granted permission to carry out the study as a registry (MEC-2014–235). Patients who met the following criteria were included in the present substudy: age 18 years and older and a proximal intracranial vessel occlusion in the anterior circulation, as shown on CTA. Data of consecutive patients treated until 15 June, 2016 was collected and analyzed for this study. Data cannot be made available, as no patient approval has been obtained for sharing coded data. However, syntax files and output of statistical analyses in STATA are available from the corresponding author on reasonable request.

Assessment of Stroke Cause

All patients underwent CTA or magnetic resonance angiography of the cervical arteries and 12-lead ECG followed by ECG-monitoring for at least 24 hours. Additional etiologic work-up was performed in accordance with local protocols. Stroke cause was determined from information in discharge letters and imaging by 2 trained observers, blinded for thrombus imaging characteristics. Each patient was allocated to one of 4 predefined etiologic categories, as defined by the TOAST (Trial of ORG 10172 in Acute Stroke Treatment) criteria¹⁴: large artery atherosclerosis (TOAST 1), cardioembolism (TOAST 2), stroke of other determined cause (TOAST 4), and stroke of undetermined cause (TOAST 5). In our cohort of patients who underwent EVT for AIS, there were no patients with small vessel

disease (TOAST 3). A patient was considered to have large artery atherosclerosis stroke if there was >50% atherosclerotic stenosis or atherosclerotic occlusion at the bifurcation of the carotid artery on the symptomatic side. Patients were considered to have undetermined stroke cause if >1 possible cause was identified, if no cause was identified despite complete work-up as described above (cryptogenic stroke), or if diagnostic workup was incomplete. For most analyses, TOAST 1 and 4 were combined into one category, defined as noncardioembolic strokes.

Image Analysis

An imaging core laboratory consisting of 21 observers (20 interventional neuroradiologists and 1 interventional neurologist, blinded for all clinical information except symptom side) determined presence of HAS, clot burden score (CBS), and thrombus location. CBS ranges from 0 to 10 and describes thrombus extent; a score of 10 is normal, a score of 0 implies complete multisegment vessel occlusion.¹⁵ Thrombus location (internal carotid artery [ICA], ICA-terminus [ICA-T], M1, M2, M3, A1, or A2) was based on the most proximal occluded segment on CTA.

Additionally, 2 neuroradiologists (Dr Dutra and Alves) blinded for stroke cause, determined absolute thrombus attenuation, relative thrombus attenuation, distance from the ICA-T to the thrombus (DT), thrombus length, and TAI in a subset of patients with available thin-section (≤ 2.5 mm) noncontrast computed tomography (NCCT) and CTA imaging, acquired within 30 minutes from each other.¹⁶ All baseline NCCT and CTA images were automatically aligned using rigid registration with Elastix software.¹⁷ In case of suboptimal alignment, adjustments were performed using manual rigid registration with Mevislab (by Dr Dutra). Scans with uncorrectable registration errors, artifacts, excessive noise, or poor contrast opacification on CTA were excluded. To prevent bone artefacts that might interfere with thrombus attenuation measurements, we also excluded patients with an intracranial occlusion restricted to the petrous, cavernous, and clinoid segments of the ICA. Calcified thrombi were excluded because of their higher attenuation values (related to calcium composition) compared with the attenuation values of noncalcified thrombi, and because calcification produces streak and partial volume artifacts, which can cause overestimation of thrombus size. In case of a pseudo-occlusion, the HAS on the co-registered NCCT was used as the proximal thrombus border.

Assessment of absolute attenuation, relative attenuation and TAI was adapted from Santos et al.^{18,19} In short, absolute attenuation was estimated as the mean value of 3 regions of interest on NCCT with a radius of 1 mm in the proximal, middle, and distal part of the thrombus. Subsequently, 3 regions of interest were placed in the contralateral artery. Relative attenuation was calculated by dividing the mean attenuation values of the 3 regions of interests in the thrombus by the mean attenuation of the 3 regions of interests in the contralateral artery. TAI was assessed by subtracting the thrombus' mean attenuation on NCCT from its mean attenuation on CTA. Thereby, TAI represents the permeability of thrombus for contrast material, measured on single-phase imaging.

Thrombus length was assessed on NCCT with the aid of co-registered CTA, using multiplanar reformations, and was estimated by the filling defect in the occluded vessel on CTA. Whenever the proximal or distal part of thrombus could not be depicted on CTA, thrombus length was based on the HAS assessed on the co-registered NCCT. DT was measured manually on CTA and represents the distance from the ICA-T to the beginning of the thrombus. For thrombi located in the supra-clinoid segment of the ICA but not extending into the ICA-T, DT was set to 0.

Statistical Analysis

Clinical characteristics and thrombus imaging characteristics were described using standard statistics. We compared thrombus characteristics (presence of HAS, CBS, thrombus location, absolute attenuation, relative attenuation, DT, length, and TAI) of cardioembolic strokes (reference group) with noncardioembolic strokes and strokes with undetermined cause. The association of stroke cause with HAS was estimated with univariable and multivariable binary logistic

regression and presented as (adjusted) odds ratios (OR) with 95% CI. We estimated the association of stroke cause with CBS and thrombus location with ordinal logistic regression and results were expressed as (adjusted) common OR's (cOR) for shift towards a one-point higher CBS or a more distal thrombus location (ICA; ICA-T; proximal M1; distal M1; M2/M3), respectively. For analyses that involved thrombus location as an ordinal variable, A1/A2-occlusions were left out. The association of stroke cause with absolute attenuation, relative attenuation, DT, length, and TAI was estimated with univariable and multivariable linear regression and was presented as (adjusted) coefficients (β) with 95% CI. We adjusted for potential confounding by including the following characteristics as covariates in the multivariable models: age, sex, administration of intravenous alteplase duration from stroke onset to imaging, and thrombus location. Selection of these variables was based on evidence from previous studies and clinical knowledge. All characteristics with a $P < 0.10$ (in the univariable analysis) were included in the multivariable analysis, except for age and sex, which were included in all multivariable models, based on clinical knowledge. The analyses that involved CBS and DT were not adjusted for thrombus location, because of collinearity.

To increase comparability with other studies, we performed a sensitivity analysis in which we compared patients with cardioembolic stroke (reference) to large-artery atherosclerosis stroke (instead of all noncardioembolic strokes) and cryptogenic stroke (undetermined cause and complete workup). For the regression analyses, missing data were imputed using single imputation. The variables that were imputed are listed in the [Data Supplement](#) (Table I in the [Data Supplement](#)). STATA/SE 15.1 (StataCorp, College Station Texas) was used for all statistical analyses.

Results

Patient Population

Of the 1627 patients enrolled in the MR CLEAN Registry from March 2014 until June 2016, 101 were excluded because of age under 18 years, treatment in a non-MR CLEAN trial hospital, or a posterior circulation occlusion, and 97 patients were excluded because no discharge letter was available. Therefore, 1429 patients were available for analysis of the association between stroke cause, presence of HAS, CBS, and thrombus location (Figure I in the [Data Supplement](#)). The median age was 71 (interquartile range [IQR], 60–80) years, and 762 (53%) were men (Table 1). Median time from stroke onset to admission imaging was 72 minutes (IQR, 53–137) for noncardioembolic strokes, 76 minutes (IQR, 52–146) for cardioembolic strokes, and 76 minutes (IQR, 54–134) for strokes with undetermined cause. There was no significant difference in time from onset to admission imaging between the different stroke subtypes. For the additional measurements, 367 patients with thin-section imaging were available for analysis. Patients with and without available thin-section imaging for thrombus measurements showed similar baseline and imaging characteristics, with the exception of a slightly higher prevalence of a distal M1 occlusion in the thin-section imaging group (Table II in the [Data Supplement](#)).

One-hundred ninety (13%) patients had large artery atherosclerosis, 476 (33%) cardioembolism, 67 (5%) other determined cause (of which 44 carotid artery dissection), and 696 (49%) stroke of undetermined cause. AF was the most common ($n=365$, 84%) cardioembolic cause of stroke. Of the patients with an undetermined stroke cause, 78 had >1 identified cause of stroke, 458 cryptogenic stroke, and 160 incomplete workup.

Imaging Characteristics

HAS was present in 55% of patients. Three hundred-sixty-nine (31%) patients had a CBS of 0 to 4, 499 (42%) of 5 to 7, and 336 (28%) of 8 to 10. Thrombi were most often located in the distal part of the M1-segment of the middle cerebral artery (MCA; $n=442$, 32%), followed by the proximal M1-segment of the MCA ($n=352$, 26%), the ICA-T ($n=308$, 23%), the M2-segment of the MCA ($n=158$, 12%), and the intracranial ICA ($n=83$, 6%). In a small group of patients ($n=21$, 2%), the thrombus was located in the M3-segment of the MCA ($n=6$), in the anterior (A1/A2) cerebral artery ($n=5$), or no definitive occlusion was present according to the core laboratory ($n=10$; Table 1).

The thrombus imaging measurements of this cohort were previously published.¹⁶ Median absolute thrombus attenuation was 52.2 (IQR, 45.9–58.6) HU, the median relative thrombus attenuation was 1.3 (IQR, 1.2–1.5) HU, the median DT was 7.8 (IQR, 0–13.9) mm, the median thrombus length was 13.5 (IQR, 9.3–18.6) mm, and the median TAI was 5.0 (IQR, –0.5 to 11.7) HU (Table 2). Figures 1 and 2 show various thrombus characteristics, stratified by stroke cause.

Cardioembolic Versus Noncardioembolic Strokes

Thrombus CT characteristics of noncardioembolic strokes were different from those of cardioembolic strokes in the unadjusted and adjusted analyses (Tables 3 and 4). In univariable analysis, noncardioembolic strokes were associated with presence of HAS (OR, 2.2 [95% CI, 1.6–3.0]), lower CBS (cOR, 0.4 [95% CI, 0.3–0.6]), shift towards a more proximal thrombus location (cOR, 0.2 [95% CI, 0.2–0.3]), higher absolute thrombus attenuation (β , 3.6 [95% CI, 0.9–6.4]), decrease in DT (β , –5.7 [95% CI, –8.3 to –3.0]), and longer thrombi (β , 8.6 [95% CI, 6.5–10.7]), compared with a cardioembolic cause (Tables 3 and 4). After adjusting for the prespecified variables, all associations remained present, except for the association of a noncardioembolic cause with HAS and higher absolute thrombus attenuation.

Strokes With Undetermined Cause

Thrombus imaging characteristics for strokes with undetermined cause were similar to those of cardioembolic strokes (Tables 3 and 4). There was no difference in presence of HAS (OR, 1.1 [95% CI, 0.8–1.3]), CBS (cOR, 0.9 [95% CI, 0.8–1.1]), absolute thrombus attenuation (β , –1.1 [95% CI, –3.1 to 1.0]), relative thrombus attenuation (β , –0.0 [95% CI, –0.1 to 0.0]), DT (β , –0.3 [95% CI, –2.3 to 1.7]), length (β , 0.3 [95% CI, –1.3 to 1.9]), or TAI (β , 2.4 [95% CI, –1.7 to 6.6]). In the multivariable analyses, none of these results changed. Strokes with undetermined cause were associated with a slightly more proximal thrombus location (cOR, 0.8 [95% CI, 0.6–0.9]). This association was not present in the multivariable analysis.

Sensitivity Analyses

Our sensitivity analysis yielded in general the same results as our main analysis (Tables III and IV in the [Data Supplement](#)). In our main analysis, strokes with undetermined cause were

Table 1. Baseline and Imaging Characteristics of Patients in the MR CLEAN Registry, Stratified by Stroke Cause

Characteristics	Noncardioembolic (n=257)	Cardioembolic (n=476)	Undetermined (n=696)	Total (n=1429)
Median age (IQR), y	67 (58–75)	76 (67–83)	68 (55–78)	71 (60–80)
Men	164 (64)	223 (47)	375 (54)	762 (53)
Median (IQR) NIHSS score	16 (12–20)	16 (12–20)	16 (11–20)	16 (11–20)
Intravenous alteplase treatment	215 (84)	291 (61)	586 (84)	1092 (76)
Median (IQR) time from stroke onset to admission imaging*	72 (53–137)	76 (52–146)	76 (54–134)	76 (53–76)
Median (IQR) time from stroke onset to groin puncture	210 (170–270)	210 (160–270)	210 (160–270)	210 (160–270)
Medical history				
Ischemic stroke	34 (14)	89 (18)	113 (16)	236 (17)
Atrial fibrillation†	0 (0)	281 (61)	46 (7)	327 (24)
Myocardial infarction	29 (12)	77 (17)	110 (16)	216 (15)
Peripheral artery disease	31 (12)	47 (10)	56 (8)	134 (10)
Drug use				
Antiplatelet	81 (32)	146 (31)	236 (34)	463 (33)
Coumarine	4 (2)	150 (32)	36 (5)	190 (13)
Direct-acting oral anticoagulant	1 (0)	27 (6)	9 (1)	37 (3)
Imaging characteristics				
Hyperdense artery sign	171 (70)	229 (51)	337 (51)	737 (55)
Median (IQR) Clot Burden Score	5 (3–6)	6 (5–8)	6 (4–8)	6 (4–8)
Occlusion location				
Intracranial ICA	39 (15)	6 (1)	38 (6)	83 (6)
ICA-terminus	91 (36)	81 (18)	136 (21)	308 (23)
Proximal M1	66 (26)	119 (26)	167 (25)	352 (26)
Distal M1	47 (19)	171 (38)	224 (34)	442 (32)
M2	10 (4)	68 (15)	80 (12)	158 (12)
Other‡	1 (0)	6 (1)	14 (2)	21 (2)

Values are numbers (percentages) of patients unless stated otherwise. ICA indicates internal carotid artery; IQR, interquartile range; MR CLEAN, Multicenter Randomized Clinical Trial of Endovascular Treatment for Acute Ischemic Stroke in the Netherlands; NIHSS, National Institutes of Health Stroke Scale; and M1/M2 middle cerebral artery.

*Admission imaging that was used to assess thrombus imaging characteristics for the current study.

†Forty-six patients with undetermined cause had more than one cause of stroke, of which one was atrial fibrillation.

‡In 6 patients the occlusion location was considered to be in the M2 at the moment endovascular treatment was decided, but the imaging core laboratory observed an M3 occlusion. Five patients had a proximal occlusion in the anterior cerebral artery. Ten patients underwent endovascular treatment without a definitive occlusion on computed tomography angiography according to the core laboratory.

associated with a slightly more proximal thrombus location than cardioembolic strokes (cOR, 0.8 [95% CI, 0.6–0.9]). Reducing this group to cryptogenic strokes only, made this difference disappear (cOR, 0.9 [95% CI, 0.7–1.1]).

Discussion

This study shows that in patients who underwent EVT for AIS, (1) thrombus CT characteristics of cardioembolic stroke are distinct from those of noncardioembolic stroke and that

Table 2. Thrombus Characteristics on Thin-Section (≤ 2.5 mm) Admission Imaging (n=367), Stratified by Stroke Cause; Values Are Medians (IQR)

Characteristics	Noncardioembolic (n=61)	Cardioembolic (n=125)	Undetermined (n=181)	Total (n=367)
Absolute attenuation, HU	57.4 (51.4 to 61.4)	51.9 (46.6 to 57.3)	50.7 (44.1 to 57.7)	52.2 (45.9 to 58.6)
Relative attenuation	1.5 (1.3 to 1.6)	1.4 (1.3 to 1.5)	1.3 (1.2 to 1.5)	1.3 (1.2 to 1.5)
DT, mm	0 (0 to 7.7)	8.6 (0 to 14.4)	9.3 (2.1 to 14.3)	7.8 (0 to 13.9)
Length, mm	21.0 (13.4 to 28.6)	12.3 (9.0 to 16.5)	12.8 (8.7 to 17.2)	13.5 (9.3 to 18.6)
TAI, HU	5.7 (0.2 to 12.5)	3.9 (–1.5 to 11.1)	5.2 (0.8 to 12.0)	5.0 (–0.5 to 11.7)

DT indicates distance from the internal carotid artery-terminus to the thrombus; HU, Hounsfield units; IQR, interquartile range; and TAI, thrombus attenuation increase

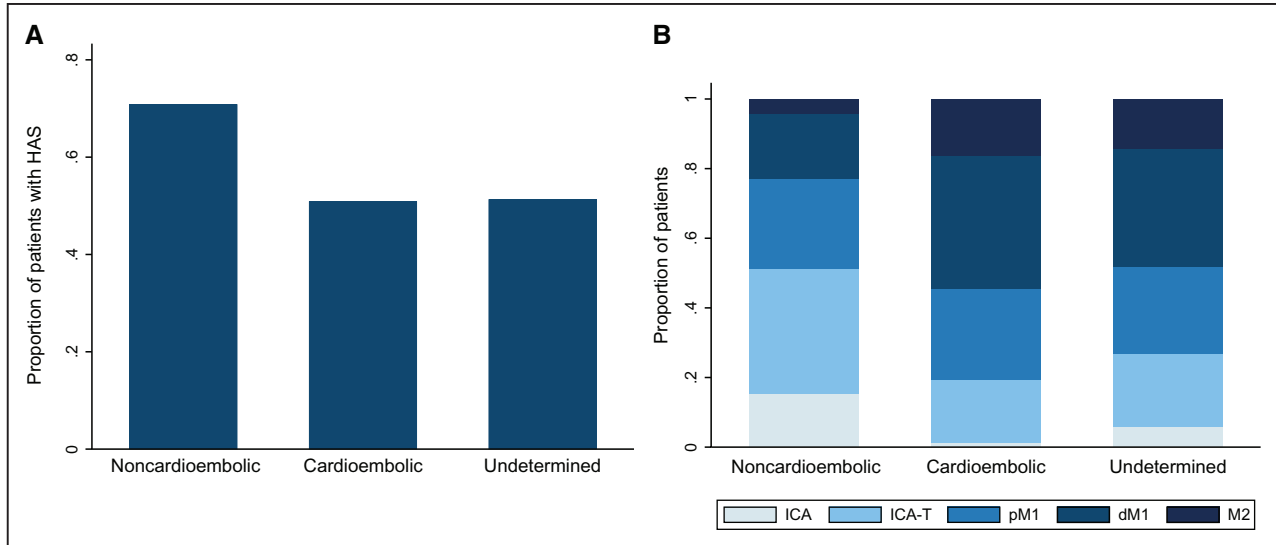


Figure 1. Thrombus characteristics for different stroke etiologies are shown. Patients with noncardioembolic stroke more often had hyperdense artery sign (HAS; **A**) and a proximal thrombus location (**B**) than patients with cardioembolic stroke and undetermined cause stroke. Noncardioembolic indicates large-artery atherosclerosis and other determined cause. ICA indicates internal carotid artery; ICA-T, ICA terminus; pM1, proximal M1 and dM1, distal M1.

(2) there is a similarity between thrombus CT characteristics of cardioembolic stroke and stroke with undetermined cause. To our knowledge, this is the largest study of thrombus CT characteristics with stroke cause so far.

Cardioembolic strokes were associated with absence of HAS and lower absolute thrombus attenuation (Tables 3 and 4). Since the positive correlation of thrombus attenuation with RBC-content is clearly described,^{11,20,21} our findings suggest cardioembolic thrombi tend to be lower in RBC-content. This is in line with results from recent histological studies,^{6,7} which showed that cardioembolic thrombi are high in fibrin-content and low in RBC-content compared with noncardioembolic thrombi. Our results seem to be in contrast with those of a recent review on various histological and imaging characteristics of thrombi,¹¹ in which no relationship between stroke cause and HAS or thrombus attenuation was found. However, a considerable proportion of studies that were included in this

review, did observe a nonsignificant trend towards absence of HAS for patients with cardioembolic stroke.

Compared with cardioembolic thrombi, noncardioembolic thrombi were longer and were found at a more proximal location (Tables 3 and 4). In a previous study, we have reported the correlation between thrombus length and location.¹⁶ One can reason that thrombi, when they are smaller, can travel further into the intracranial circulation. This is in line with the findings of Marder et al,²² who showed that the ultimate destination of the thrombus is related to its width. Even though we assessed thrombus length and not width in the current study, we hypothesize that thrombus length is related to its width and that longer thrombi have more difficulty moving past vascular curves. A possible limitation of the current study could be that assessing thrombus length on imaging might be more difficult for distally located thrombi. However, the relationship between stroke cause

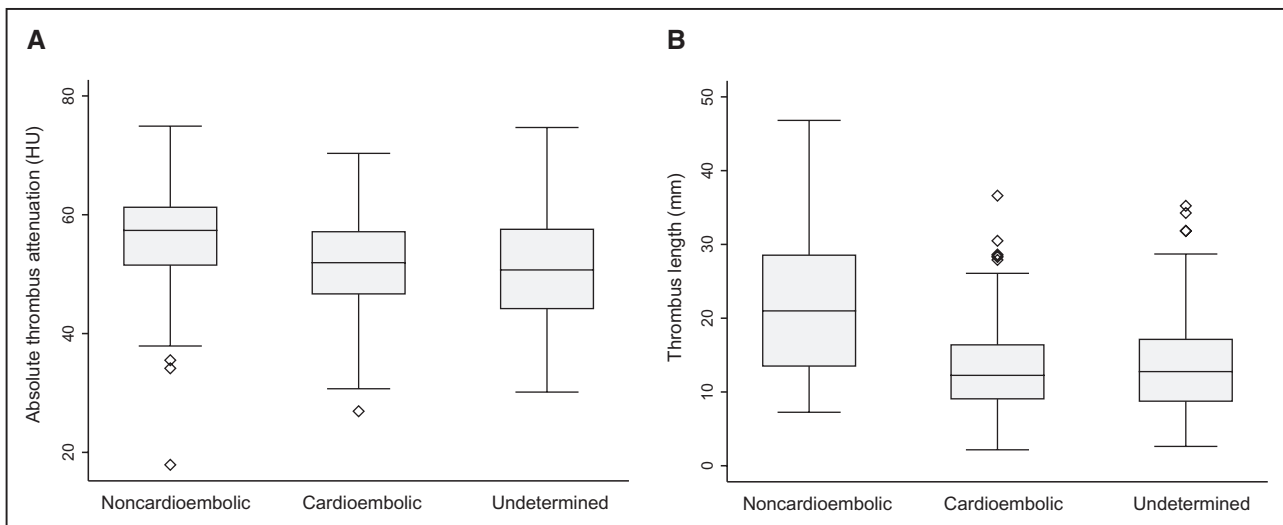


Figure 2. Thrombus characteristics for different stroke etiologies are shown. Noncardioembolic strokes had higher absolute thrombus attenuation in Hounsfield units (**A**) and longer thrombi (**B**), compared with the other etiologies. Noncardioembolic indicates large-artery atherosclerosis and other determined cause.

Table 3. Univariable and Multivariable Binary and Ordinal Logistic Regression for the Relationship of Stroke Cause and Thrombus Characteristics (n=1429)

	HAS		Higher CBS		More Distal Thrombus Location	
	OR (95% CI)	aOR* (95% CI)	cOR (95% CI)	acOR† (95% CI)	cOR (95% CI)	acOR† (95% CI)
Cardioembolic (reference)	1	1	1	1	1	1
Noncardioembolic	2.2 (1.6–3.0)	1.5 (1.0–2.1)	0.4 (0.3–0.6)	0.4 (0.3–0.5)	0.2 (0.2–0.3)	0.3 (0.2–0.3)
Undetermined cause	1.1 (0.8–1.3)	0.9 (0.7–1.2)	0.9 (0.8–1.1)	0.9 (0.8–1.1)	0.8 (0.6–0.9)	0.8 (0.6–1.0)

acOR indicates adjusted common odds ratio; aOR, adjusted odds ratio; CBS, clot burden score; cOR, common odds ratio; HAS, hyperdense artery sign; and OR, odds ratio.
 *Adjusted for age, sex, intravenous r-tPA, and thrombus location.
 †Adjusted for age and sex.

and thrombus length remained significant after adjusting for thrombus location, suggesting an independent relationship of length with cause.

We did not find a relationship between stroke cause and TAI and relative thrombus attenuation, which is in contrast with recent findings of Berndt et al,⁹ who found an association between cardioembolic thrombi and higher thrombus permeability, and those of Puig et al,²³ who found an association between cardioembolic thrombi and higher relative attenuation. Differences in results could have been caused by the fact that both studies include patients with ischemic stroke with an LVO restricted to the MCA; therefore, their results may not be fully comparable to our cohort of patients with LVO of the anterior circulation. Furthermore, both studies have considerable smaller sample size. Finally, the method the authors used to measure relative thrombus attenuation, differed from the one used in our study.

Are Cryptogenic Strokes Cardioembolic Strokes?

We observed a strong similarity between thrombus characteristics of cardioembolic strokes and those of strokes with undetermined cause. These findings complement recent results of histological studies^{6,7,9} that also show a strong similarity between thrombi in patients with cardioembolic strokes and strokes of undetermined cause. Based on these data, it seems considerably likely that many cryptogenic strokes have a cardioembolic origin. This theory is underlined by a recent randomized controlled trial of enhanced and prolonged monitoring for AF after ischemic stroke, which showed substantially higher detection rate of AF in the monitoring group⁴ and by a recent meta-analysis²⁴ that showed similar results.

Implications for Clinical Practice

Currently, between one-third to half of ischemic strokes has no known cause following thorough diagnostic evaluation,²⁵ which complicates effective secondary stroke prevention. The current literature supports the hypothesis that cryptogenic strokes are, for a large part, cardioembolic; however, it is not yet clear which patients with cryptogenic stroke should be submitted to prolonged or enhanced cardiac follow-up. In the current study, we show that thrombus characteristics derived from admission CT imaging are related to stroke cause. Future research should focus on the value of these characteristics as a diagnostic tool for stroke cause, or for the selection of patients with cryptogenic stroke that would benefit most from additional diagnostic workup for a cardioembolic source.

Limitations

Our study has several limitations. First, 49% of patients had an undetermined stroke cause; a large proportion, compared with other studies.²⁶ In part, this can be explained by the absence of patients with small vessel disease in a cohort of patients who underwent EVT for large vessel occlusion. Furthermore, detailed information on rhythm monitoring and echocardiography were unavailable for some patients, and a proportion of patients with undetermined cause may have had an identifiable cardioembolic source; a result of a registry of daily clinical practice. It is important to realize that the overall interrater agreement of the TOAST classification system is regarded as moderate,²⁷ although reliability varies between stroke subtypes. However, this system was most suitable for our registry of clinical practice, and its wide use allowed for comparison of our results with those of other studies.

Second, by studying 8 thrombus characteristics as outcome measures and, therefore, conducting multiple statistical

Table 4. Univariable and Multivariable Linear Regression for the Relationship Between Stroke Cause and Thrombus Characteristics on Thin-Section Imaging (n=367)

	Absolute Attenuation		Relative Attenuation		DT		Length		TAI	
	β (95% CI)	aβ* (95% CI)	β (95% CI)	aβ† (95% CI)	β (95% CI)	aβ‡ (95% CI)	β (95% CI)	aβ* (95% CI)	β (95% CI)	aβ† (95% CI)
Cardioembolic (reference)	0	0	0	0	0	0	0	0	0	0
Noncardioembolic	3.6 (0.9 to 6.4)	1.0 (-1.8 to 3.8)	0.0 (-0.1 to 0.1)	0.0 (-0.1 to 0.1)	-5.7 (-8.3 to -3.0)	-6.1 (-8.8 to -3.4)	8.6 (6.5 to 10.7)	6.2 (4.1 to 8.3)	2.1 (-3.5 to 7.7)	2.8 (-2.8 to 8.5)
Undetermined cause	-1.1 (-3.1 to 1.0)	-1.5 (-3.5 to 0.5)	-0.0 (-0.1 to 0.0)	-0.0 (-0.1 to 0.0)	-0.3 (-2.3 to 1.7)	-1.0 (-3.1 to 1.1)	0.3 (-1.3 to 1.9)	-0.1 (-1.6 to 1.4)	2.4 (-1.7 to 6.6)	2.9 (-1.3 to 7.1)

DT indicates distance from the ICA-terminus to the thrombus; and TAI, thrombus attenuation increase.

*Adjusted for age, sex, and thrombus location.

†Adjusted for age and sex.

‡Adjusted for age, sex, and intravenous alteplase treatment.

tests in this study, we increased our chance of performing type I errors (falsely rejecting a null hypothesis). However, results for interrelated thrombus characteristics and our sensitivity analysis were consistent, and our interpretation was not based on *P* values alone.

For the additional thrombus measurements, the majority of patients were excluded because of absence of suitable thin-section NCCT and CTA, prolonged time between the scanned NCCT and CTA (>30 minutes), poorly co-registered scans and poor image quality. This selection was mostly the result of a large registry of clinical practice, in which thin-section images are acquired but then discarded again after producing the thick-section reconstructions to limit size of stored data and was assumed to be random. Baseline and imaging characteristics for patients with and without suitable imaging for the additional thrombus measurements were similar between groups (Table II in the [Data Supplement](#)), suggesting there was no selection bias caused by this limitation. Furthermore, differences in blood flow caused by the position of the thrombus relative to the lenticulostriate arteries or other branching arteries, could have influenced thrombus length, as thrombus growth could be prevented by maintained blood circulation. In our study, detailed information on this position was not available; however, we did adjust for thrombus location, to partially take this factor into account. Calcified thrombi were excluded in our study because of their disproportionately high attenuation values compared with noncalcified thrombi, possibly affecting outcomes. However, prevalence of calcified thrombus was low in our study (<1%), so power for sufficiently assessing a relationship with stroke cause was lacking. Future research should focus on the relationship of calcified thrombi with stroke cause in more detail.

Conclusions

Thrombus CT characteristics of cardioembolic stroke differ from those of noncardioembolic stroke. Noncardioembolic strokes were associated with presence of HAS, lower CBS, shift towards a more proximal thrombus location, higher absolute thrombus attenuation, decrease in distance from the ICA-T and longer thrombi, compared with cardioembolic strokes. Additionally, our study supports the general hypothesis that many cryptogenic strokes have a cardioembolic cause. Further research should focus on the use of thrombus CT characteristics as a diagnostic tool for stroke cause in clinical practice.

Appendix

Coinvestigators MR CLEAN Registry

Executive Committee

Diederik Dippel, Department of Neurology, Erasmus MC University Medical Center; Aad van der Lugt, Department of Radiology, Erasmus MC University Medical Center; Charles Majoie, Department of Radiology and Nuclear Medicine, Amsterdam UMC, University of Amsterdam, Amsterdam; Yvo Roos, Department of Neurology, Amsterdam UMC, University of Amsterdam, Amsterdam; Robert van Oostenbrugge, Department of Neurology, Maastricht University Medical Center and Cardiovascular Research Institute Maastricht (CARIM); Wim van Zwam, Department of Radiology, Maastricht University Medical Center and Cardiovascular Research Institute Maastricht (CARIM); Jelis Boiten, Department of Neurology,

Haaglanden MC, the Hague; Jan Albert Vos, Department of Radiology, Sint Antonius Hospital, Nieuwegein.

Study Coordinators

Ivo Jansen, Department of Radiology and Nuclear Medicine, Amsterdam UMC, University of Amsterdam, Amsterdam; Maxim Mulder, Department of Neurology, Erasmus MC University Medical Center and Department of Radiology, Erasmus MC University Medical Center; Robert-Jan Goldhoorn, Department of Neurology, Maastricht University Medical Center and Cardiovascular Research Institute Maastricht (CARIM), Department of Radiology, Maastricht University Medical Center and Cardiovascular Research Institute Maastricht (CARIM); Kars Compagne, Department of Radiology, Erasmus MC University Medical Center; Manon Kappelhof, Department of Radiology and Nuclear Medicine, Amsterdam UMC, University of Amsterdam, Amsterdam.

Local Principal Investigators

Wouter Schonewille, Department of Neurology, Sint Antonius Hospital, Nieuwegein; Jan Albert Vos, Department of Radiology, Sint Antonius Hospital, Nieuwegein; Charles Majoie, Department of Radiology and Nuclear Medicine, Amsterdam UMC, University of Amsterdam, Amsterdam; Jonathan Coutinho, Department of Neurology, Amsterdam UMC, University of Amsterdam, Amsterdam; Marieke Wermer, Department of Neurology, Leiden University Medical Center; Marianne van Walderveen, Department of Radiology, Leiden University Medical Center; Julie Staals, Department of Neurology, Maastricht University Medical Center and Cardiovascular Research Institute Maastricht (CARIM); Wim van Zwam, Department of Radiology, Maastricht University Medical Center and Cardiovascular Research Institute Maastricht (CARIM); Jeannette Hofmeijer, Department of Neurology, Rijnstate Hospital, Arnhem; Jasper Martens, Department of Radiology, Rijnstate Hospital, Arnhem; Geert Lycklama à Nijeholt, Department of Radiology, Haaglanden MC, the Hague; Jelis Boiten, Department of Neurology, Haaglanden MC, the Hague; Bob Roozenbeek, Department of Neurology, Erasmus MC University Medical Center; Bart Emmer, Department of Radiology, Erasmus MC University Medical Center; Sebastiaan de Bruijn, Department of Neurology, Haga Hospital, the Hague; Lukas van Dijk, Department of Radiology, Haga Hospital, the Hague; H. Bart van der Worp, Department of Neurology, University Medical Center Utrecht; Rob Lo, Department of Radiology, University Medical Center Utrecht; Ewoud van Dijk, Department of Neurology, Radboud University Medical Center, Nijmegen; Hieronymus Boogaarts, Department of Neurosurgery, Radboud University Medical Center, Nijmegen; Paul de Kort, Department of Neurology, Sint Elisabeth Hospital, Tilburg; Julia van Tuijl, Department of Neurology, Elisabeth-TweeSteden ziekenhuis, Tilburg; Jo Peluso, Department of Radiology, Sint Elisabeth Hospital, Tilburg; Jan van den Berg, Department of Neurology, Isala Klinieken, Zwolle; Boudewijn van Hasselt, Department of Radiology, Isala Klinieken, Zwolle; Leo Aerden, Department of Neurology, Reinier de Graaf Gasthuis, Delft; René Dallinga, Department of Radiology, Reinier de Graaf Gasthuis, Delft; Maarten Uyttenboogaart, Department of Neurology, University Medical Center Groningen; Omid Eshghi, Department of Radiology, University Medical Center Groningen; Reinoud Bokkers, Department of Radiology, University Medical Center Groningen; Tobien Schreuder, Department of Neurology, Atrium Medical Center, Heerlen; Roel Heijboer, Department of Radiology, Atrium Medical Center, Heerlen; Koos Keizer, Department of Neurology, Catharina Hospital, Eindhoven; Lonkeke Yo, Department of Radiology, Catharina Hospital, Eindhoven; Heleen den Hertog, Department of Neurology, Isala Klinieken, Zwolle; Emiel Sturm, Department of Radiology, Medical Spectrum Twente, Enschede.

Imaging Assessment Committee

Charles Majoie, Department of Radiology and Nuclear Medicine, Amsterdam UMC, University of Amsterdam, Amsterdam (chair); Wim van Zwam, Department of Radiology, Maastricht University Medical Center and Cardiovascular Research Institute Maastricht (CARIM); Aad van der Lugt, Department of Radiology, Erasmus

MC University Medical Center; Geert Lycklama à Nijeholt, Department of Radiology, Haaglanden MC, the Hague; Marianne van Walderveen, Department of Radiology, Leiden University Medical Center; Marieke Sprengers, Department of Radiology and Nuclear Medicine, Amsterdam UMC, University of Amsterdam, Amsterdam; Sjoerd Jenniskens, Department of Radiology, Radboud University Medical Center, Nijmegen; René van den Berg, Department of Radiology and Nuclear Medicine, Amsterdam UMC, University of Amsterdam, Amsterdam; Albert Yoo, Department of Radiology, Texas Stroke Institute, Texas, United States of America; Ludo Beenen, Department of Radiology and Nuclear Medicine, Amsterdam UMC, University of Amsterdam, Amsterdam; Alida Postma, Department of Radiology, Maastricht University Medical Center and Cardiovascular Research Institute Maastricht (CARIM); Stefan Roosendaal, Department of Radiology and Nuclear Medicine, Amsterdam UMC, University of Amsterdam, Amsterdam; Bas van der Kallen, Department of Radiology, Haaglanden MC, the Hague; Ido van den Wijngaard, Department of Radiology, Haaglanden MC, the Hague; Adriaan van Es, Department of Radiology, Erasmus MC University Medical Center; Bart Emmer, Department of Radiology, Erasmus MC University Medical Center, Department of Radiology and Nuclear Medicine, Amsterdam UMC, University of Amsterdam, Amsterdam; Jasper Martens, Department of Radiology, Rijnstate Hospital, Arnhem; Lonkeke Yo, Department of Radiology, Catharina Hospital, Eindhoven; Jan Albert Vos, Department of Radiology, Sint Antonius Hospital, Nieuwegein; Joost Bot, Department of Radiology, Amsterdam UMC, Vrije Universiteit van Amsterdam, Amsterdam; Pieter-Jan van Doormaal, Department of Radiology, Erasmus MC University Medical Center.

Writing Committee

Diederik Dippel, Department of Neurology, Erasmus MC University Medical Center (chair); Aad van der Lugt, Department of Radiology, Erasmus MC University Medical Center; Charles Majoie, Department of Radiology and Nuclear Medicine, Amsterdam UMC, University of Amsterdam, Amsterdam; Yvo Roos, Department of Neurology, Amsterdam UMC, University of Amsterdam, Amsterdam; Robert van Oostenbrugge, Department of Neurology, Maastricht University Medical Center and Cardiovascular Research Institute Maastricht (CARIM); Wim van Zwam, Department of Radiology, Maastricht University Medical Center and Cardiovascular Research Institute Maastricht (CARIM); Geert Lycklama à Nijeholt, Department of Radiology, Haaglanden MC, the Hague; Jelis Boiten, Department of Neurology, Haaglanden MC, the Hague; Jan Albert Vos, Department of Radiology, Sint Antonius Hospital, Nieuwegein; Wouter Schonewille, Department of Neurology, Sint Antonius Hospital, Nieuwegein; Jeannette Hofmeijer, Department of Neurology, Rijnstate Hospital, Arnhem; Jasper Martens, Department of Radiology, Rijnstate Hospital, Arnhem; Bart van der Worp, Department of Neurology, University Medical Center Utrecht; Rob Lo, Department of Radiology, University Medical Center Utrecht.

Adverse Event Committee

Robert van Oostenbrugge, Department of Neurology, Maastricht University Medical Center and Cardiovascular Research Institute Maastricht (CARIM) (chair); Jeannette Hofmeijer, Department of Neurology, Rijnstate Hospital, Arnhem; Zwenneke Flach, Department of Radiology, Isala Klinieken, Zwolle.

Trial Methodologist

Hester Lingsma, Department of Public Health, Erasmus MC University Medical Center.

Research Nurses/Local Trial Coordinators

Naziha el Ghannouti, Department of Neurology, Erasmus MC University Medical Center; Martin Sterrenberg, Department of Neurology, Erasmus MC University Medical Center; Corina Puppels and Wilma Pellikaan, Department of Neurology, Sint Antonius Hospital, Nieuwegein; Rita Sprengers, Department of Neurology, Amsterdam UMC, University of Amsterdam, Amsterdam; Marjan Elfink, Department of Neurology, Rijnstate Hospital, Arnhem; Joke de Meris, Department of Neurology, Haaglanden MC, the Hague;

Tamara Vermeulen, Department of Neurology, Haaglanden MC, the Hague; Annet Geerlings, Department of Neurology, Radboud University Medical Center, Nijmegen; Gina van Vemde, Department of Neurology, Isala Klinieken, Zwolle; Tiny Simons, Department of Neurology, Atrium Medical Center, Heerlen; Cathelij van Rijswijk, Department of Neurology, Sint Elisabeth Hospital, Tilburg; Gert Messchendorp, Department of Neurology, University Medical Center Groningen; Hester Bongenaar, Department of Neurology, Catharina Hospital, Eindhoven; Karin Bodde, Department of Neurology, Reinier de Graaf Gasthuis, Delft; Sandra Kleijn, Department of Neurology, Medical Spectrum Twente, Enschede; Jasmijn Lodico, Department of Neurology, Medical Spectrum Twente, Enschede; Hanneke Droste, Department of Neurology, Medical Spectrum Twente, Enschede; M.Wollaert, Department of Neurology, Maastricht University Medical Center and Cardiovascular Research Institute Maastricht (CARIM); D. Jeurissen, Department of Neurology, Maastricht University Medical Center and Cardiovascular Research Institute Maastricht (CARIM); Ernas Bos, Department of Neurology, Leiden University Medical Center; Yvonne Drabbe, Department of Neurology, HAGA Hospital, the Hague; Nicoline Aaldering, Department of Neurology, Rijnstate Hospital, Arnhem; Berber Zweedijk, Department of Neurology, University Medical Center Utrecht; Mostafa Khalilzada, Department of Neurology, HAGA Hospital, the Hague.

PhD/Medical Students

Esme Venema, Department of Public Health, Erasmus MC University Medical Center; Vicky Chalos, Department of Neurology, Erasmus MC University Medical Center and Department of Public Health, Erasmus MC University Medical Center; Ralph Geuskens, Department of Radiology and Nuclear Medicine, Amsterdam UMC, University of Amsterdam, Amsterdam; Tim van Straaten, Department of Neurology, Radboud University Medical Center, Nijmegen; Saliha Ergezen, Roger Harmsma, Daan Muijres, and Anouk de Jong, Department of Neurology, Erasmus MC University Medical Center; Wouter Hinseveld, Department of Neurology, Sint Antonius Hospital, Nieuwegein; Olvert Berkhemer, Department of Neurology, Erasmus MC University Medical Center, Department of Radiology and Nuclear Medicine, Amsterdam UMC, University of Amsterdam, Amsterdam, and Department of Radiology, Maastricht University Medical Center and Cardiovascular Research Institute Maastricht (CARIM); Anna Boers, Department of Radiology and Nuclear Medicine, Amsterdam UMC, University of Amsterdam, Amsterdam and Department of Biomedical Engineering and Physics, Amsterdam UMC, University of Amsterdam, Amsterdam; J. Huguët, P. Groot, Marieke Mens, Katinka van Kranendonk, Kilian Treurniet, Manon Tolhuijsen, and Heitor Alves, Department of Radiology and Nuclear Medicine, Amsterdam UMC, University of Amsterdam, Amsterdam.

Acknowledgments

We would like to thank the MR CLEAN investigators.

Sources of Funding

This study was funded and performed by the Erasmus University Medical Center, the Academic Medical Center Amsterdam, and the Maastricht University Medical Center. The study was additionally funded by the European Union's Horizon 2020 research and innovation programme under grant agreement No. 777072 (IN-SILICO trials for treatment of acute Ischemic STroke; INSIST), which played no role in trial design and patient enrolment, nor in data collection, analysis, or writing of the article.

Disclosures

Erasmus Medical Center received compensation from Stryker, Siemens Healthineers and GE Healthcare for activities of Dr van der Lugt and from Stryker and Bracco Imaging Ltd for activities of Dr Dippel as a consultant. Drs Dippel and van der Lugt report grants from Dutch Heart Foundation, grants from Brain Foundation Netherlands, grants from Health Holland Top Sector Life Sciences & Health, grants from the Netherlands Organisation for Health

Research and Development and unrestricted grants from Stryker European Operations BV, from Penumbra Inc, from Medtronic, from Thrombolytic Science, and from Cerenovus outside the submitted work, all paid to institution. Dr Marquering is co-founder and shareholder of Nico-lab, a company that focuses on the use of artificial intelligence for medical image analysis. Dr Majoie is a recipient of grants from the CVON/Dutch Heart Foundation, Stryker, European Commission, TWIN Foundation, Health Evaluation Netherlands and is shareholder of Nico-lab. The other authors report no conflicts.

References

- Saposnik G, Gladstone D, Raptis R, Zhou L, Hart RG; Investigators of the Registry of the Canadian Stroke Network (RCSN) and the Stroke Outcomes Research Canada (SORCan) Working Group. Atrial fibrillation in ischemic stroke: predicting response to thrombolysis and clinical outcomes. *Stroke*. 2013;44:99–104. doi: 10.1161/STROKEAHA.112.676551
- Hart RG, Pearce LA, Aguilar MI. Meta-analysis: antithrombotic therapy to prevent stroke in patients who have nonvalvular atrial fibrillation. *Ann Intern Med*. 2007;146:857–867. doi: 10.7326/0003-4819-146-12-200706190-00007
- Connolly SJ, Eikelboom J, Joyner C, Diener HC, Hart R, Golitsyn S, et al; AVERROES Steering Committee and Investigators. Apixaban in patients with atrial fibrillation. *N Engl J Med*. 2011;364:806–817. doi: 10.1056/NEJMoA1007432
- Wachter R, Gröschel K, Gelbrich G, Hamann GF, Kermer P, Liman J, et al; Find-AF(randomised) Investigators and Coordinators. Holter-electrocardiogram-monitoring in patients with acute ischaemic stroke (Find-AFRANDOMISED): an open-label randomised controlled trial. *Lancet Neurol*. 2017;16:282–290. doi: 10.1016/S1474-4422(17)30002-9
- Sanna T, Diener HC, Passman RS, Di Lazzaro V, Bernstein RA, Morillo CA, et al; CRYSTAL AF Investigators. Cryptogenic stroke and underlying atrial fibrillation. *N Engl J Med*. 2014;370:2478–2486. doi: 10.1056/NEJMoA1313600
- Sporns PB, Hanning U, Schwindt W, Velasco A, Minnerup J, Zoubi T, et al. Ischemic stroke: what does the histological composition tell us about the origin of the thrombus? *Stroke*. 2017;48:2206–2210. doi: 10.1161/STROKEAHA.117.016590
- Boeckh-Behrens T, Kleine JF, Zimmer C, Neff F, Scheipl F, Pelisek J, et al. Thrombus histology suggests cardioembolic cause in cryptogenic stroke. *Stroke*. 2016;47:1864–1871. doi: 10.1161/STROKEAHA.116.013105
- Benson JC, Fitzgerald ST, Kadirvel R, Johnson C, Dai D, Karen D, et al. Clot permeability and histopathology: is a clot's perviousness on CT imaging correlated with its histologic composition? *J Neurointerv Surg*. 2020;12:38–42. doi: 10.1136/neurintsurg-2019-014979
- Berndt M, Friedrich B, Maegerlein C, Moench S, Hedderich D, Lehm M, et al. Thrombus permeability in admission computed tomographic imaging indicates stroke pathogenesis based on thrombus histology. *Stroke*. 2018;49:2674–2682. doi: 10.1161/STROKEAHA.118.021873
- Kappelhof M, Tolhuisen ML. Thrombus perviousness as a potential patient selection tool for intravenous and endovascular treatment for acute ischemic stroke. Paper presented at European Stroke Organisation Conference; May 17, 2018, Gothenburg; Available at: <https://journals.sagepub.com/doi/full/10.1177/2396987318770127>. Accessed July 17, 2019
- Brinjikji W, Duffy S, Burrows A, Hacke W, Liebeskind D, Majoie CBLM, et al. Correlation of imaging and histopathology of thrombi in acute ischemic stroke with etiology and outcome: a systematic review. *J Neurointerv Surg*. 2017;9:529–534. doi: 10.1136/neurintsurg-2016-012391
- Mair G, Boyd EV, Chappell FM, von Kummer R, Lindley RI, Sandercock P, et al; IST-3 Collaborative Group. Sensitivity and specificity of the hyperdense artery sign for arterial obstruction in acute ischemic stroke. *Stroke*. 2015;46:102–107. doi: 10.1161/STROKEAHA.114.007036
- Jansen IGH, Mulder MJHL, Goldhoorn RB; MR CLEAN Registry investigators. Endovascular treatment for acute ischaemic stroke in routine clinical practice: prospective, observational cohort study (MR CLEAN Registry). *BMJ*. 2018;360:k949. doi: 10.1136/bmj.k949
- Adams HP Jr, Bendixen BH, Kappelle LJ, Biller J, Love BB, Gordon DL, et al. Classification of subtype of acute ischemic stroke. Definitions for use in a multicenter clinical trial. TOAST. Trial of Org 10172 in Acute Stroke Treatment. *Stroke*. 1993;24:35–41. doi: 10.1161/01.str.24.1.35
- Puetz V, Dzialowski I, Hill MD, Subramaniam S, Sylaja PN, Krol A, et al; Calgary CTA Study Group. Intracranial thrombus extent predicts clinical outcome, final infarct size and hemorrhagic transformation in ischemic stroke: the clot burden score. *Int J Stroke*. 2008;3:230–236. doi: 10.1111/j.1747-4949.2008.00221.x
- Dutra BG, Tolhuisen ML, Alves HCBR, Treurniet KM, Kappelhof M, Yoo AJ, et al; MR CLEAN Registry Investigators. Thrombus imaging characteristics and outcomes in acute ischemic stroke patients undergoing endovascular treatment. *Stroke*. 2019;50:2057–2064. doi: 10.1161/STROKEAHA.118.024247
- Klein S, Staring M, Murphy K, Viergever MA, Pluim JP. elastix: a toolbox for intensity-based medical image registration. *IEEE Trans Med Imaging*. 2010;29:196–205. doi: 10.1109/TMI.2009.2035616
- Santos EM, Dankbaar JW, Treurniet KM, Horsch AD, Roos YB, Kappelle LJ, et al; DUST Investigators. Permeable thrombi are associated with higher intravenous recombinant tissue-type plasminogen activator treatment success in patients with acute ischemic stroke. *Stroke*. 2016;47:2058–2065. doi: 10.1161/STROKEAHA.116.013306
- Santos EM, Yoo AJ, Beenen LF, Berkhemer OA, den Blanken MD, Wismans C, et al; MR CLEAN investigators. Observer variability of absolute and relative thrombus density measurements in patients with acute ischemic stroke. *Neuroradiology*. 2016;58:133–139. doi: 10.1007/s00234-015-1607-4
- Niessen JM, van der Schaaf IC, van Dam L, Vink A, Vos JA, Schonewille WJ, et al. Histopathologic composition of cerebral thrombi of acute stroke patients is correlated with stroke subtype and thrombus attenuation. *PLoS One*. 2014;9:e88882. doi: 10.1371/journal.pone.0088882
- Berndt M, Kaesmacher J, Boeckh-Behrens T. Response by berndt et al to letter regarding article, “Thrombus Permeability in Admission Computed Tomographic Imaging Indicates Stroke Pathogenesis Based on Thrombus Histology”. *Stroke*. 2019;50:e36. doi: 10.1161/STROKEAHA.118.024029
- Marder VJ, Chute DJ, Starkman S, Abolian AM, Kidwell C, Liebeskind D, et al. Analysis of thrombi retrieved from cerebral arteries of patients with acute ischemic stroke. *Stroke*. 2006;37:2086–2093. doi: 10.1161/01.STR.0000230307.03438.94
- Puig J, Pedraza S, Demchuk A, Daunis-I-Estadella J, Termes H, Blasco G, et al. Quantification of thrombus Hounsfield units on noncontrast CT predicts stroke subtype and early recanalization after intravenous recombinant tissue plasminogen activator. *AJNR Am J Neuroradiol*. 2012;33:90–96. doi: 10.3174/ajnr.A2878
- Sposato LA, Cipriano LE, Saposnik G, Ruíz Vargas E, Riccio PM, Hachinski V. Diagnosis of atrial fibrillation after stroke and transient ischaemic attack: a systematic review and meta-analysis. *Lancet Neurol*. 2015;14:377–387. doi: 10.1016/S1474-4422(15)70027-X
- Arsava EM, Helenius J, Avery R, Sorgun MH, Kim GM, Pontes-Neto OM, et al. Assessment of the predictive validity of etiologic stroke classification. *JAMA Neurol*. 2017;74:419–426. doi: 10.1001/jamaneurol.2016.5815
- Hart RG, Diener HC, Coutts SB, Easton JD, Granger CB, O'Donnell MJ, et al; Cryptogenic Stroke/ESUS International Working Group. Embolic strokes of undetermined source: the case for a new clinical construct. *Lancet Neurol*. 2014;13:429–438. doi: 10.1016/S1474-4422(13)70310-7
- Meschia JF, Barrett KM, Chukwudelunzu F, Brown WM, Case LD, Kissela BM, et al; Siblings with Ischemic Stroke Study (SWISS) Investigators. Interobserver agreement in the trial of org 10172 in acute stroke treatment classification of stroke based on retrospective medical record review. *J Stroke Cerebrovasc Dis*. 2006;15:266–272. doi: 10.1016/j.jstrokecerebrovasdis.2006.07.001