



Universiteit  
Leiden  
The Netherlands

## **Near-infrared fluorescence imaging compared to standard sentinel lymph node detection with blue dye in patients with vulvar cancer: a randomized controlled trial**


Deken, M.M.; Doorn, H.C. van; Verver, D.; Boogerd, L.S.F.; Valk, K.S. de; Rietbergen, D.D.D.; ... ; Gaarenstroom, K.N.

### **Citation**

Deken, M. M., Doorn, H. C. van, Verver, D., Boogerd, L. S. F., Valk, K. S. de, Rietbergen, D. D. D., ... Gaarenstroom, K. N. (2020). Near-infrared fluorescence imaging compared to standard sentinel lymph node detection with blue dye in patients with vulvar cancer: a randomized controlled trial. *Gynecologic Oncology*, 159(3), 672-680.  
doi:10.1016/j.ygyno.2020.09.044

Version: Publisher's Version  
License: [Creative Commons CC BY 4.0 license](#)  
Downloaded from: <https://hdl.handle.net/1887/3184797>

**Note:** To cite this publication please use the final published version (if applicable).



## Near-infrared fluorescence imaging compared to standard sentinel lymph node detection with blue dye in patients with vulvar cancer – a randomized controlled trial

Marion M. Deken<sup>a</sup>, Helena C. van Doorn<sup>b</sup>, Danielle Verver<sup>c</sup>, Leonora S.F. Boogerd<sup>a</sup>, Kim S. de Valk<sup>a</sup>, Daphne D.D. Rietbergen<sup>d,e</sup>, Mariëtte I.E. van Poelgeest<sup>f</sup>, Cor D. de Kroon<sup>f</sup>, Jogchum J. Beltman<sup>f</sup>, Fijis W.B. van Leeuwen<sup>e</sup>, Hein Putter<sup>g</sup>, Jeffrey P.B.M. Braak<sup>a</sup>, Lioe-Fee de Geus-Oei<sup>d</sup>, Cock J.H. van de Velde<sup>a</sup>, Jacobus Burggraaf<sup>h</sup>, Alexander L. Vahrmeijer<sup>a</sup>, Katja N. Gaarenstroom<sup>f,\*</sup>

<sup>a</sup> Department of Surgery, Leiden University Medical Center, Leiden, the Netherlands

<sup>b</sup> Department of Gynecologic Oncology, Erasmus MC Cancer Institute, Erasmus University Medical Center Rotterdam, Rotterdam, the Netherlands

<sup>c</sup> Department of Surgery, Erasmus MC Cancer Institute, Erasmus University Medical Center Rotterdam, Rotterdam, the Netherlands

<sup>d</sup> Department of Radiology, Section Nuclear Medicine, Leiden University Medical Center, Leiden, the Netherlands

<sup>e</sup> Interventional Molecular Imaging Laboratory, Department of Radiology, Leiden University Medical Center, Leiden, the Netherlands

<sup>f</sup> Department of Gynecology, Leiden University Medical Center, Leiden, the Netherlands

<sup>g</sup> Department of Medical Statistics, Leiden University Medical Center, Leiden, the Netherlands

<sup>h</sup> Centre for Human Drug Research, Leiden, the Netherlands

### ARTICLE INFO

#### Article history:

Received 4 August 2020

Accepted 27 September 2020

Available online 8 October 2020

#### Keywords:

Sentinel lymph node

Vulvar cancer

Near-infrared fluorescence imaging

ICG-<sup>99m</sup>Tc-nanocolloid

Indocyanine green

Randomized controlled trial

### ABSTRACT

**Objective.** The aim of this study was to assess the superiority of ICG-<sup>99m</sup>Tc-nanocolloid for the intraoperative visual detection of sentinel lymph nodes (SLNs) in vulvar squamous cell carcinoma (VSCC) patients compared to standard SLN detection using <sup>99m</sup>Tc-nanocolloid with blue dye.

**Methods.** In this multicenter, randomized controlled trial, VSCC patients underwent either the standard SLN procedure or with the hybrid tracer ICG-<sup>99m</sup>Tc-nanocolloid. The primary endpoint was the percentage of fluorescent SLNs compared to blue SLNs. Secondary endpoints were successful SLN procedures, surgical outcomes and postoperative complications.

**Results.** Forty-eight patients were randomized to the standard ( $n = 24$ ) or fluorescence imaging group ( $n = 24$ ) using ICG-<sup>99m</sup>Tc-nanocolloid. The percentage of blue SLNs was 65.3% compared to 92.5% fluorescent SLNs ( $p < 0.001$ ). A successful SLN procedure was obtained in 92.1% of the groins in the standard group and 97.2% of the groins in the fluorescence imaging group ( $p = 0.33$ ). Groups did not differ in surgical outcome, although more short-term postoperative complications were documented in the standard group ( $p = 0.041$ ).

**Conclusions.** Intraoperative visual detection of SLNs in patients with VSCC using ICG-<sup>99m</sup>Tc-nanocolloid was superior compared to <sup>99m</sup>Tc-nanocolloid and blue dye. The rate of successful SLN procedures between both groups was not significantly different. Fluorescence imaging has potential to be used routinely in the SLN procedure in VSCC patients to facilitate the search by direct visualization.

Clinical Trial Registration: Netherlands Trial Register (Trial ID NL7443).

© 2020 The Author(s). Published by Elsevier Inc. This is an open access article under the CC BY license (<http://creativecommons.org/licenses/by/4.0/>).

### Contents

1.	Introduction . . . . .	673
2.	Methods . . . . .	673
2.1.	Patients . . . . .	673
2.2.	Tracer preparation. . . . .	673
2.3.	Study design and preoperative imaging . . . . .	674

\* Corresponding author at: Leiden University Medical Center, P.O. Box 9600, 2300 RC, Leiden, the Netherlands.  
E-mail address: [K.N.Gaarenstroom@lumc.nl](mailto:K.N.Gaarenstroom@lumc.nl) (K.N. Gaarenstroom).

2.4.	Surgical procedure . . . . .	675
2.5.	Pathological examination . . . . .	675
2.6.	Postoperative complications . . . . .	675
2.7.	Sample size and statistical analysis . . . . .	675
3.	Results . . . . .	675
3.1.	Patient characteristics . . . . .	675
3.2.	Preoperative SLN detection by lymphoscintigraphy . . . . .	675
3.3.	Intraoperative SLN detection . . . . .	675
3.4.	Surgical and pathological outcomes . . . . .	676
3.5.	Short-term and long-term morbidity . . . . .	676
4.	Discussion. . . . .	676
	Authors' contributions. . . . .	679
	Funding . . . . .	679
	Declaration of Competing Interest . . . . .	679
	Acknowledgements . . . . .	679
	Appendix A. Supplementary data . . . . .	679
	References . . . . .	679

## 1. Introduction

The sentinel lymph node (SLN) procedure has been proven to be a reliable and safe method in patients with early-stage vulvar squamous cell carcinoma (VSCC) [1–3]. For unifocal VSCCs, with a diameter of 4 cm or less and without suspected or enlarged groin lymph nodes, the current standard treatment consists of a radical local excision of the tumor and a SLN procedure, ipsilateral or bilateral depending on location of the vulvar tumor and outcome of lymphoscintigraphy [1–5]. A full inguinofemoral lymphadenectomy (IFL) is advised when the SLN is not identified either by lymphoscintigraphy or during surgery. Therefore, the SLN procedure should be optimal to guarantee safety and minimize the need to perform a full IFL.

Standard SLN detection in vulvar cancer patients consists of a preoperative peritumoral injection with  $^{99m}\text{Tc}$ -nanocolloid as a radiotracer, preoperative lymphoscintigraphy and the intraoperative use of radio-guidance and additional blue dye for visual imaging [2–5]. Meta-analyses show that the overall SLN detection rate with the combined use of  $^{99m}\text{Tc}$ -nanocolloid and blue dye is 87–93% per groin [4,6] and 98% per patient [5,6]. Blue dye enables direct visualization of the SLN and facilitates the detection of the SLN during surgery. However, only 63–69% of the SLNs were visualized intraoperatively with the use of blue dye [4–6]. Hence, in more than 30% of the cases, the surgeon has to rely solely on the guidance by the gamma probe to identify the SLN. In such cases, localization of the SLN can be hampered when the background signal originating from the injection spot around the vulvar tumor disturbs the signal of the SLN. Difficult identification of the SLN may result in larger incisions, which might increase the risk of postoperative complications, and prolonged time of surgery. More importantly, if the SLN cannot be identified, an IFL is recommended. This is associated with increased acute and late morbidity such as wound dehiscence, infection, lymphocele formation and lymphedema [2,7,8].

Furthermore, blue dye has the disadvantage that is not visible through the skin or other overlying tissues, but only by direct visualization. In addition, the injection of blue dye results in discolouring of the vulva which may hamper proper sight of the surgical field and could have a negative impact on achieving tumor-free resection margins.

Near-infrared (NIR) fluorescence imaging has emerged as a complementary method for intraoperative visualization of tumor tissue [9] and SLNs [10–19]. By peritumoral injection of indocyanine green (ICG), a FDA approved 800 nm fluorophore, in a complex with  $^{99m}\text{Tc}$ -nanocolloid (ICG- $^{99m}\text{Tc}$ -nanocolloid), SLNs can be visualized in real-time by using a NIR fluorescence imaging system. Indocyanine green is invisible to the naked eye and does not colour the surgical field. Furthermore, use of wavelengths in the NIR spectrum results in a penetration depth of approximately 5–8 mm. With ICG- $^{99m}\text{Tc}$ -nanocolloid, the SLN biopsy procedure became more accurate in patients with various

malignancies such as penile cancer, melanoma, and vulvar cancer, and allowed for superior optical surgical guidance compared to blue dye [11,12,14,15,17].

Several studies showed good feasibility of NIR fluorescence imaging to identify SLNs in vulvar cancer patients using ICG separately and  $^{99m}\text{Tc}$ -nanocolloid for radio-guidance [12,13,16,20] or hybrid ICG- $^{99m}\text{Tc}$ -nanocolloid [14,15,19]. Combining the results of these studies, 96.6% of all SLNs were visualized during surgery by NIR fluorescence imaging compared to 70.6% of the SLNs by blue dye [21]. However, in these studies the different techniques were combined with blue dye in the same patient. Until now, the superiority of ICG- $^{99m}\text{Tc}$ -nanocolloid for the intraoperative visualization of the SLN compared to standard SLN detection has not been studied. Therefore, the aim of this current randomized controlled study was to assess the superiority of ICG- $^{99m}\text{Tc}$ -nanocolloid for the intraoperative visual detection of SLNs compared to the standard SLN procedure using  $^{99m}\text{Tc}$ -nanocolloid and blue dye.

## 2. Methods

This multicenter, randomized controlled superiority trial, was performed at the Leiden University Medical Center (LUMC) in Leiden and the Erasmus Medical Center in Rotterdam, The Netherlands. Fig. 1 presents a flow diagram of the study. The study was centrally approved by the Medical Ethics Committee of the LUMC (CME Leiden P09.001) and registered at the Netherlands Trial Register (Trial ID NL7443).

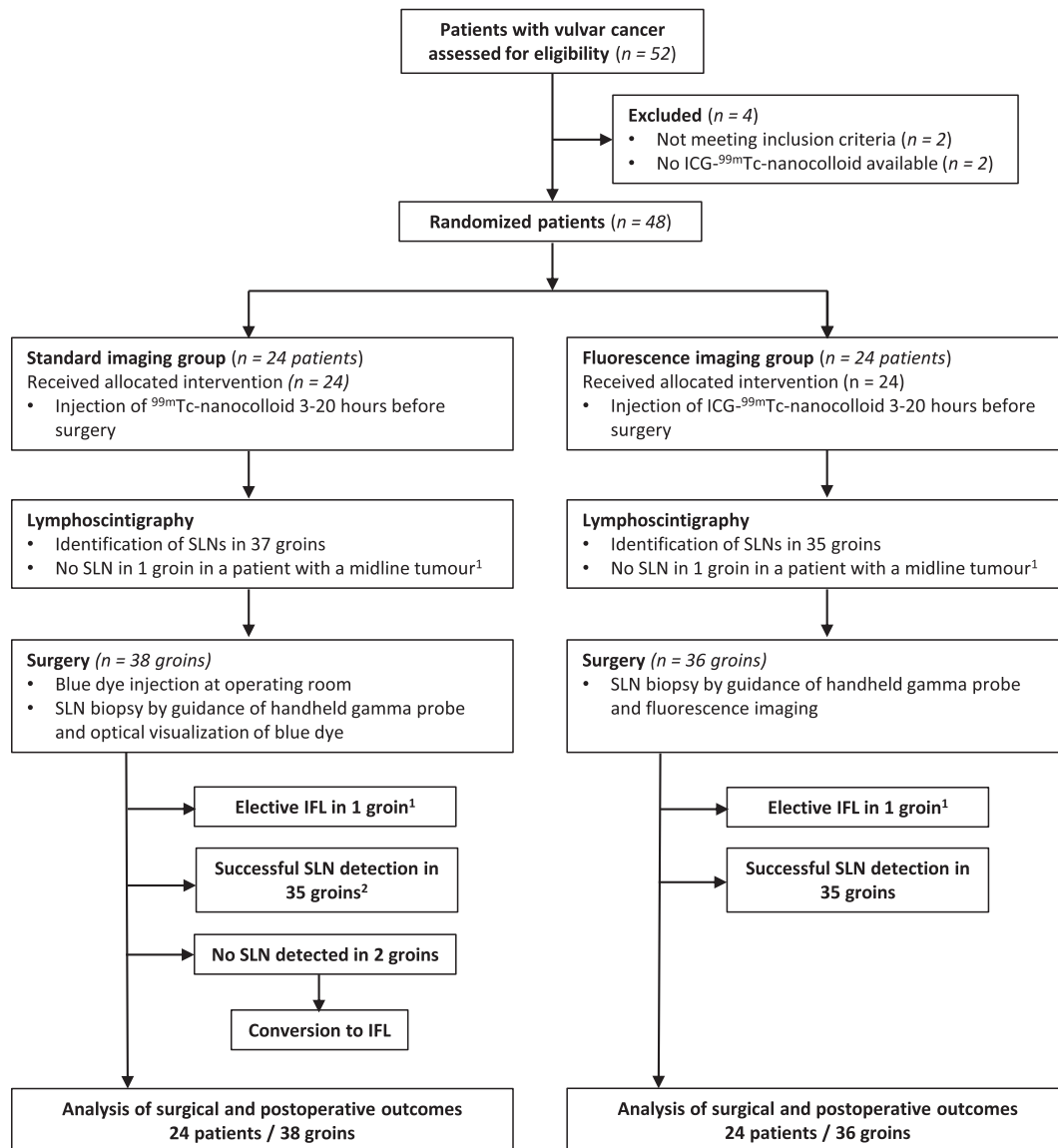
The primary outcome was defined as the percentage of intraoperative visualized SLNs that were fluorescent compared to the percentage of SLNs that coloured blue. Secondary outcomes included: rate of successful SLN procedures per groin, percutaneous visualization of a lymphatic channel or SLN, length of incision, duration of SLN procedure, intra- and postoperative complications, and pathological outcome.

### 2.1. Patients

Eligible patients (age  $\geq 18$  years) had primary VSCC (T1b, FIGO staging 2014), tumor size  $<4$  cm diameter, a depth of invasion of  $>1$  mm and clinically and radiologically nonsuspicious inguinofemoral lymph nodes. Exclusion criteria were multifocal tumors, groin operations that might hamper SLN identification, and an allergy to iodine, patent blue, shellfish or ICG. All patients provided written informed consent.

### 2.2. Tracer preparation

For the patients in the standard group  $^{99m}\text{Tc}$ -nanocolloid was prepared by the Department of Nuclear Medicine according to local protocol [19]. Tracer preparation was performed under Good Manufacturing



**Fig. 1.** Flow diagram of the study. SLN; sentinel node, IFL; inguiofemoral lymphadenectomy<sup>1</sup> In two patients with a midline tumor (one group each), lymphoscintigraphy showed an unilateral SLN and an elective, contralateral IFL was performed. <sup>2</sup> One patient in the standard group with a midline tumor and unilateral SLN identified on lymphoscintigraphy, underwent a bilateral IFL, despite a successful SLN procedure unilateral (i.e. protocol deviation).

Practice (GMP) conditions and under supervision of the institutional pharmacist. For patients in the fluorescence imaging group the tracer ICG-<sup>99m</sup>Tc-nanocolloid was commercially obtained from GE Healthcare Radio pharmacy (Leiderdorp, The Netherlands), in collaboration with the Interventional Molecular Imaging Laboratory of the LUMC. For preparation 25 mg ICG was dissolved in 5 ml sterile water. Fifty  $\mu$ l of this freshly prepared ICG solution (5 mg/ml) was subsequently added to 2.000 MBq <sup>99m</sup>Tc-nanocolloid in 2 ml. From this vial a dose of 52–100 MBq, calibrated at the time of injection, was extracted for injection of the hybrid tracer ICG-<sup>99m</sup>Tc-nanocolloid. The ICG concentration was approximately 161  $\mu$ mol/l, leading to an injected ICG dose of 0.12 mg.

### 2.3. Study design and preoperative imaging

Consecutive patients with VSCC who fulfilled the inclusion criteria and gave consent, were included between June 2016 and September 2019 (Fig. 1). Randomization with a computer-generated random block size was used at a 1:1 ratio. No stratification was done. Patients

were assigned to either the standard group using <sup>99m</sup>Tc-nanocolloid and blue dye or fluorescence imaging group using ICG-<sup>99m</sup>Tc-nanocolloid. Randomization and central data management was performed at the LUMC. Included patients who were excluded before the conduct of study procedures were replaced by consecutive patients.

For the standard SLN [2,3] and fluorescence imaging procedure, 4 peritumoral injections of a total of approximately 0.5 ml 52–100 MBq of respectively <sup>99m</sup>Tc-nanocolloid or the hybrid tracer with ICG-<sup>99m</sup>Tc-nanocolloid, were administered 3–20 h before surgery. In patients in whom the vulvar tumor was already excised, the tracer was intracutaneously injected around the excision scar.

Following administration of the radioactive tracer, an early and late dynamic lymphoscintigraphy was performed (Symbia T6, Siemens, Erlangen, Germany). The number and site of SLNs visualized on lymphoscintigraphy were noted per groin [2,4]. In patients with tumors crossing the midline, in whom a single sided SLN was identified, an IFL was advised on the side in which the SLN was not identified. In case of a lateral tumor, i.e. not crossing the midline, unilateral identification of SLN on lymphoscintigraphy was appropriate.

## 2.4. Surgical procedure

A handheld gamma probe (EuroProbe 3.2, Eurorad, Eckbolsheim, France) was used to identify the location of the SLN(s) for all procedures. In the study group, fluorescence imaging was performed by the Quest Spectrum Imaging System (Quest Medical Imaging, Middenmeer, The Netherlands).

The SLN procedure was performed as described previously [1,2]. In brief, in the standard group, prior to the first groin incision, 1–2 ml of Patent Blue V (Guerbert, France) was injected intracutaneously at 4 peritumoral locations. For each groin the percutaneously identification of a lymphatic channel or SLN with fluorescence imaging or blue dye was determined before incision. The skin incision was made at the point of the greatest radioactive signal and/or the site of percutaneous fluorescence imaging signal. A SLN was defined as a (first) lymph node that showed adequate concentration of tracer agent, i.e. radioactive signal and/or a visible blue or fluorescent node [22]. For each resected SLN, the radioactivity (total gamma count) and/or presence of blue dye or fluorescence (*in* and/or *ex vivo*) was noted. After SLN excision, the wound bed was checked to assure no blue dye, fluorescence or significant radioactive signal was left. In case the remaining radioactive signal was >10% of the signal of the first or most radioactive SLN, the dissection was continued to search for additional SLNs [1,4,6,22]. If more radioactive and/or blue or fluorescent SLNs were resected as identified on lymphoscintigraphy in the respective groin, these were defined as additional SLNs [14]. In case no SLN at all was identified in patients in the fluorescence imaging group, a blue dye injection was advised to offer the standard procedure. In all patients, an IFL was advised if no SLN was detected.

A SLN procedure was defined as successful when at least one SLN was detected during surgery, and remaining tissue showed less than 10% radioactivity compared to the most radioactive SLN [1,4].

The successful SLN procedure rate per groin was calculated as the number of groins in which a SLN was detected, divided by the number of groins in which a SLN should be identified and resected according to tumor location and results of the lymphoscintigraphy [4]. Furthermore, a complete SLN procedure was defined as the intraoperative detection and removal of all SLNs that were identified on lymphoscintigraphy in the respective groin.

The length of groin incision, intraoperative blood loss and complications were listed. Duration of SLN procedure, defined by the time interval between skin incision and final excision of all SLNs was noted. In case of failed SLN detection, time interval between skin incision and completion of IFL was noted.

## 2.5. Pathological examination

The resected specimen of the vulva and resected SLNs and other tissue were examined by the pathologist according to standard protocol in both hospitals. The SLNs were fixed in formalin and embedded in paraffin for haematoxylin, eosin, and immunopathological staining for cytokeratin AE1/AE3 at multiple levels (ultra-staging), with an interval of 250  $\mu\text{m}$  [2,3].

## 2.6. Postoperative complications

Short-term complications (<6 weeks after surgery) of the groin included wound breakdown or infection requiring treatment, and/or lymphocyst formation [7]. Long-term complications (>6 weeks after surgery), such as lymphedema and recurrent erysipelas, requiring any treatment were also registered [7].

## 2.7. Sample size and statistical analysis

The study has been powered using a two independent proportions power analysis. The used outcome was the proportion of fluorescent

SLNs (96.6%) [21] compared to blue coloured SLNs (68.7%) [5]. To perceive a significant difference between the amount of SLNs which are blue and those that are fluorescent, a total of 48 patients should be included ( $\alpha = 0.05$ ;  $\beta = 0.2$ ). For statistical analysis, IBM SPSS Statistics (Version 25, La Jolla, CA, USA) was used. For the secondary outcomes an intention-to-treat analysis was performed. To evaluate the differences between the standard and fluorescence imaging groups *t*-test, Pearson's chi-squared or Fisher's exact test were used.  $P < 0.05$  was considered as significant.

## 3. Results

### 3.1. Patient characteristics

Fifty-two patients with vulvar cancer were assessed for eligibility (Fig. 1). Four patients were excluded due to not meeting the inclusion criteria ( $n = 2$ ) or because ICG- $^{99\text{mTc}}$ -nanocolloid was not available at that time ( $n = 2$ ). After randomization 24 patients were allocated to each group. Patient and tumor characteristics are shown in Table 1. Baseline characteristics did not differ between both groups.

### 3.2. Preoperative SLN detection by lymphoscintigraphy

The schedules of peritumoral injections of the tracer are shown in Table 2. Patients in the fluorescence imaging group received a significantly higher radioactivity dose of  $^{99\text{mTc}}$ -nanocolloid compared to the standard group ( $p < 0.001$ ). In the standard group a total of 52 SLNs were identified on lymphoscintigraphy in 37 groins, compared to 41 SLNs in 35 groins in the fluorescence imaging group (Table 2). In each group, in one patient with a midline tumor, only an unilateral SLN was identified on lymphoscintigraphy. Bilateral SLNs in lateral tumors were identified in five (20.8%) patients in the standard group and in six (25%) patients in the fluorescence imaging group ( $p = 0.745$ ).

### 3.3. Intraoperative SLN detection

A total of 49 SLNs in 37 groins were resected in the standard group compared to 53 SLNs in 35 groins in the fluorescence imaging group

**Table 1**  
Patient and tumor characteristics\*.

Characteristic	$^{99\text{mTc}}$ -nanocolloid + blue dye	ICG- $^{99\text{mTc}}$ -nanocolloid
Number of patients	24	24
Age (years)		
Median (range)	71 (44–88)	68 (51–90)
BMI in $\text{kg}/\text{m}^2$ ( $\pm$ SD)	28.0 $\pm$ 5.2	28.2 $\pm$ 5.4
Location of primary tumor, n (%)		
Lateral	15 (62.5%)	18 (75.0%)
Midline	9 (37.5%)	6 (25.0%)
Tumor diameter (mm)		
Mean (range)	19.0 (8–40)	20.7 (10–40)
Tumor infiltration depth (mm)		
Mean (range)	3.4 (1–10)	2.6 (1–7)
Hospital of surgery		
Leiden University Medical Centre, Leiden	16 (66.7%)	16 (66.7%)
Erasmus Medical Centre, Rotterdam	8 (33.3%)	8 (33.3%)
Planned local treatment		
Wide local excision and SLN procedure	22 (91.7%)	19 (79.2%)
Re-excision and SLN procedure	1 (4.2%)	4 (16.7%)
Only SLN procedure (previously excision of vulva tumor)	1 (4.2%)	1 (4.2%)

ICG; indocyanine green, BMI; Body Mass Index, SLN(s); sentinel lymph node(s).

\* There were no significant differences between the trial groups in any of the variables listed in this Table.

**Table 2**  
Preoperative identification of sentinel lymph nodes on lymphoscintigraphy.

Characteristics, n (%)	<sup>99m</sup> Tc-nanocolloid + blue dye	ICG- <sup>99m</sup> Tc-nanocolloid	P-value
Number of patients	24	24	<b>&lt; 0.001</b>
Injected radioactivity dose and timing of injection	<sup>99m</sup> Tc-nanocolloid	ICG- <sup>99m</sup> Tc-nanocolloid	
4 × 13–15 MBq day of surgery	13 (54.2%)	9 (37.5%)	
4 × 15 MBq day before surgery	11 (45.8%)	1 (4.2%)	
4 × 25 MBq day of surgery	0 (0%)	7 (29.2%)	
4 × 25 MBq day before surgery	0 (0%)	7 (29.2%)	
Result of SLN identification			
Number of groins with at least 1 SLN identified	37	35	
Number of groins with failed SLN identification <sup>1</sup>	1	1	
Outcome specified per patient			
Lateral tumor with unilateral SLN	10 (41.7%)	12 (50.0%)	0.745
Lateral tumor with bilateral SLN	5 (20.8%)	6 (25.0%)	
Midline tumor with unilateral SLN	1 (4.2%)	1 (4.2%)	
Midline tumor with bilateral SLN	8 (33.3%)	5 (20.8%)	
Total number of SLNs identified	52	41	
Mean number of SLNs identified per groin (range)	1.4 (1–3)	1.1 (1–2)	0.094

ICG; indocyanine green, MBq; megabecquerel, SLN(s); sentinel lymph node(s).

<sup>1</sup> Midline tumor with failed identification of bilateral SLNs.

(Table 3). In the standard group, 46 of the 52 (88.5%) SLNs identified on lymphoscintigraphy were resected during surgery. In the fluorescence imaging group, 40 of the 41 (97.5%) SLNs identified on lymphoscintigraphy were resected during surgery ( $p = 0.099$ ). Significant more additional SLNs were removed in the fluorescence imaging group compared to the standard group, 13 (24.5%) versus 3 (6.1%) ( $p = 0.011$ ). The detection of significant more additional SLNs (8/19 vs 5/53 groins,  $p = 0.003$ , Table S1) was related to a higher injected radioactivity dose of ICG-<sup>99m</sup>Tc-nanocolloid of 100 MBq. No significant relationship was found between the number of additional SLNs and time interval between the injection and surgery ( $p = 0.937$ , Table S1).

In the standard group, 32 out of 49 (65.3%) resected SLNs coloured blue, compared to 49 out of 53 (92.5%) fluorescent SLNs in the fluorescence imaging group ( $p < 0.001$ , Table 3). In the standard group in four groins of three patients, only one blue, but not radioactive, SLN was detected. These were considered successful SLN procedures. In the fluorescence imaging group, 49 out of 53 SLNs were both radioactive and fluorescent and 4 SLNs only radioactive.

A successful SLN procedure was achieved in 35/38 (92.1%) of the groins in the standard group and in 35/36 (97.2%) of the groins in the fluorescence imaging group ( $p = 0.331$ , Table 3). In the standard group, four IFLs were performed: one because of failed SLN detection on lymphoscintigraphy, one protocol deviation in an otherwise successful SLN procedure, and two conversions to an IFL, because no SLN was detected during surgery. In the fluorescence imaging group, one IFL was performed because of failed SLN detection on lymphoscintigraphy.

In the standard group a complete SLN procedure was achieved in 31 of the 37 (83.8%) of the groins, compared to 34 of the 35 (97.1%) groins in the fluorescence imaging group ( $p = 0.056$ ) (Table 3). In six groins in the standard group and in one groin in the fluorescence imaging group, not all SLNs that were identified by lymphoscintigraphy, were detected during surgery. No significant relationship was found between either a successful or complete SLN procedure and either the radioactivity dose of (ICG)-<sup>99m</sup>Tc-nanocolloid or time interval between injection and surgery (Table S1).

### 3.4. Surgical and pathological outcomes

In four groins (11.4%) percutaneous fluorescence imaging of a lymphatic channel or SLN was seen, this was not seen in the standard group with blue dye ( $p = 0.051$ ) (Table 4). Fig. 2 shows an example of the percutaneous visualization of a lymphatic channel by fluorescence imaging and was used to determine the location of the incision.

No intraoperative complications occurred. No significant differences were found regarding: the amount of intraoperative blood loss ( $p = 0.403$ ), mean length of incision ( $p = 0.140$ ), and surgical resection times in case of successful SLN procedure, including the removal of additional SLNs ( $p = 0.126$ ), or resection time of (un)successful SLN procedure including IFL ( $p = 0.911$ ). In the standard group, pathological examination showed eight metastases in seven (18.9%) of the 37 groins (Table 4). This included one metastasis in an additional SLN (radioactive and blue). In the fluorescence imaging group, seven metastases were found in five (14.3%) of the 35 groins. These included two metastases in the additional resected SLNs (one SLN both radioactive and fluorescent, and one SLN only radioactive). In the subsequent IFLs, no other positive LNs were found in neither patient group. Local vulvar resections were not radical (R1 resection) in three (13.0%) patients in the standard group versus two (8.7%) patients in the fluorescence group ( $p = 0.636$ ).

### 3.5. Short-term and long-term morbidity

In none of the 48 patients, adverse effects occurred that could be related to the use of blue dye or ICG-<sup>99m</sup>Tc-nanocolloid. The mean follow-up duration was 15 months (range 2–36) in the standard group and 14 months (range 4–35) in the fluorescence imaging group ( $p = 0.535$ ).

In the standard group, six (25%) short-term complications occurred in six patients: three groin infections, two wound breakdown, and one lymphocyst formation (Table 4). Four of these complications (16.7%) were seen after a SLN procedure only. In the fluorescence imaging group one patient (4.2%) developed an infection of the groin after the SLN procedure ( $p = 0.041$ , Table 4).

For analyses of long-term postoperative complications, we excluded nine women who received additional surgery or radiotherapy to the groins, leaving 19/24 patients in the standard group and 20/24 patients of the fluorescence imaging group for analysis. One patient in the standard group, in whom the SLN procedure was converted to an IFL, developed recurrent cellulitis. In the fluorescence imaging group one patient (5.0%) suffered from lymphedema after SLN procedure only ( $p = 0.942$ ).

## 4. Discussion

To our knowledge, this is the first randomized controlled trial regarding the detection of SLNs by NIR fluorescence imaging (using ICG-<sup>99m</sup>Tc-nanocolloid) compared to the standard SLN procedure (using <sup>99m</sup>Tc-nanocolloid and blue dye) in patients with VSCC. We

**Table 3**  
Intraoperative detection of sentinel lymph nodes.

Characteristics, n (%)	<sup>99m</sup> Tc-nanocolloid + blue dye	ICG- <sup>99m</sup> Tc-nanocolloid	P-value
Number of groins with attempted SLN procedure <sup>1</sup>	38	36	
Number of groins with identified SLN on lymphoscintigraphy	37	35	
Total number of resected SLNs during surgery	49	53	
Mean number of SLNs resected per groin (range)	1.3 (0–4)	1.5 (1–5)	0.395
Number of resected SLNs by number of SLNs identified on lymphoscintigraphy <sup>2</sup>	46/52 (88.5%)	40/41 (97.5%)	0.099
Number of additional detected SLNs <sup>3</sup>	3/49 (6.1%)	13/53 (24.5%)	<b>0.011</b>
Proportion of resected SLNs detected by blue dye or fluorescence	32/49 (65.3%)	49/53 (92.5%)	<b>&lt; 0.001</b>
Method of SLN detection			
Radioactive and blue or fluorescent	28/49 (57.1%)	49/53 (92.5%)	
Radioactive only	17/49 (34.7%)	4/53 (7.5%)	
Blue or fluorescent only	4/49 (8.2%)	0/53 (0%)	
Number of groins with successful SLN procedure <sup>4</sup>	35/38 (92.1%)	35/36 (97.2%)	0.331
Groins with failed SLN detection on lymphoscintigraphy	1	1	
Groins with failed SLN detection during surgery	2	0	
Number of groins with complete SLN procedure <sup>5</sup>	31/37 (83.8%)	34/35 (97.1%)	0.056

ICG; indocyanine green, SLN(s); sentinel lymph node(s).

<sup>1</sup> Number of groins with identified SLN on lymphoscintigraphy, including groins with failed SLN identification on lymphoscintigraphy.<sup>2</sup> Number of SLNs that were identified on lymphoscintigraphy and also detected by surgery in the respective groin.<sup>3</sup> Extra resected SLNs, beside the resection of all SLNs that were identified on lymphoscintigraphy in the respective groin.<sup>4</sup> The number of groins with a successful SLN procedure, divided by the number of groins with attempted SLN procedure.<sup>5</sup> The intraoperative detection and removal of all SLNs identified on lymphoscintigraphy, and confirmed as lymphoid tissue by histopathology.

demonstrated that the intraoperative visualization of SLNs using ICG-<sup>99m</sup>Tc-nanocolloid was superior to the standard SLN procedure with blue dye, as significantly more resected SLNs were fluorescent (92.5%) than blue (65.3%). This finding ensures easier intraoperative visual detection of SLNs guided by radio-guidance and fluorescence imaging.

A successful SLN procedure was achieved in respectively, 92.1% and 97.2% of the groins in the standard and fluorescence imaging group. This difference was however, not significant. A trend to a more complete SLN procedure, the opportunity of percutaneous visualization of a lymphatic channel or SLN, and the resection of significantly more additional SLNs was noted in the fluorescence imaging group. No significant differences

were noted between both groups regarding the length of the incision, surgical time of the SLN procedures, intraoperative or postoperative long-term complications. Although, significant more short-term postoperative complications were documented in the standard group.

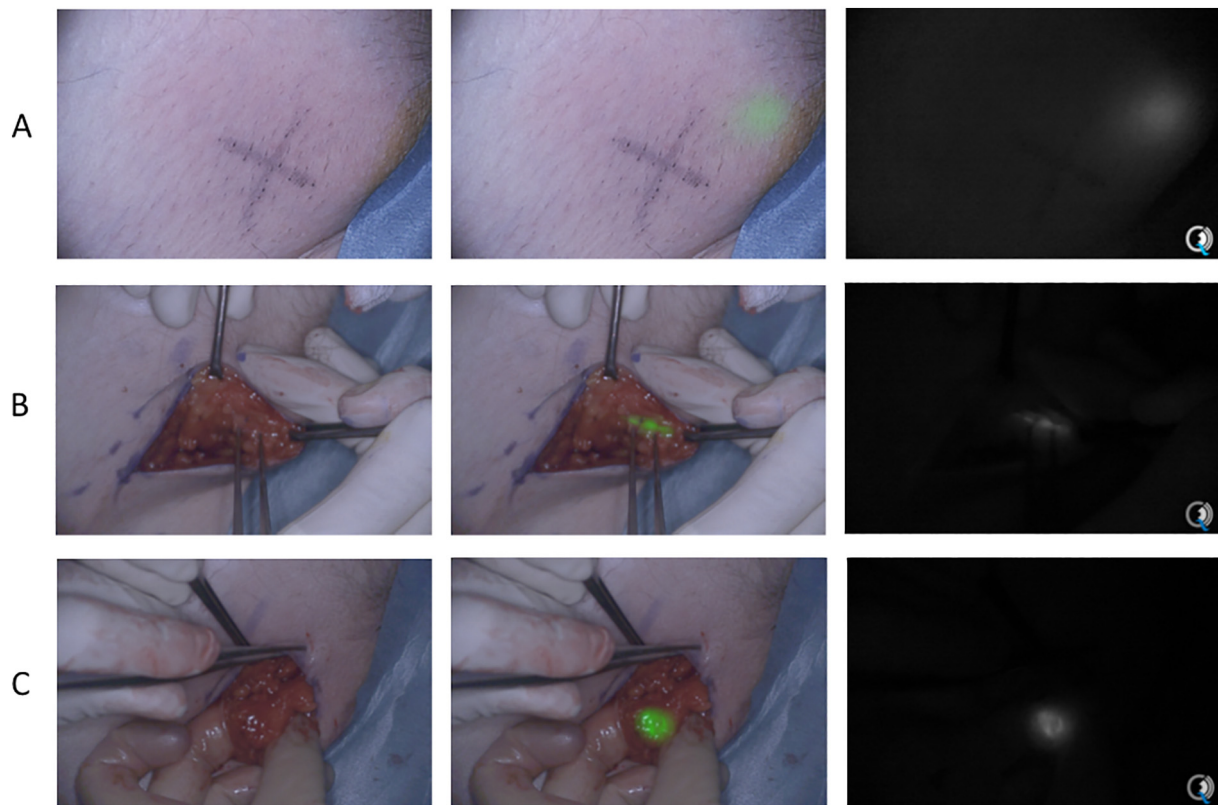
A successful SLN procedure per groin as found in our study of 92.1% with the combined use of <sup>99m</sup>Tc-nanocolloid and blue dye, and a percentage of 65.3% blue SLNs, is comparable to the literature [4,6]. In the standard group, four (8.2%) solely blue, non-radioactive, SLNs were detected. This demonstrates the additional value of the intraoperative visualization of SLNs, as these procedures were regarded as successful and a full IFL could be omitted. A successful SLN identification using fluorescence imaging with ICG-<sup>99m</sup>Tc-nanocolloid has been reported

**Table 4**  
Surgical and pathological outcomes and postoperative morbidity.

Outcome	<sup>99m</sup> Tc-nanocolloid + blue dye	ICG- <sup>99m</sup> Tc-nanocolloid	P-value
Total number of resected SLNs during surgery	49	53	
Pathology			N/A
Lymph node (no tumor)	41 (83.7%)	46 (86.8%)	
Micrometastasis (≤ 2 mm)	5 (10.2%)	2 (3.8%)	
Macrometastasis (> 2 mm)	3 (6.1%)	2 (3.8%)	
Macrometastasis (> 2 mm) with capsular invasion	0 (0%)	3 (5.6%)	
Resection margin vulvar tumour <sup>1</sup>	23	23	0.636
R0 resection	20 (87.0%)	21 (91.3%)	
R1 resection	3 (13.0%)	2 (8.7%)	
Percutaneous visual detection of lymphatic vessel or SLN	0/37 (0%)	4/35 (11.4%)	0.051
Intraoperative blood loss in ml	67.5 (± 56.5)	89.5 (± 95.5)	0.403
Intraoperative complications	0 (0%)	0 (0%)	1.000
Mean length of incision in mm (± SD)	59.1 ± 22.4	52.4 ± 14.1	0.140
Mean surgical time of successful SLN procedures in min <sup>2</sup> (± SD)	16.7 (± 13.4)	22.2 (± 15.5)	0.126
Mean surgical time of successful or failed SLN procedures in min <sup>3</sup> (± SD)	23.8 (± 25.6)	23.2 (± 16.6)	0.911
Mean follow-up in months (range)	15 (2–36)	14 (4–35)	0.535
Short-term morbidity	6/24 (25.0%)	1/24 (4.8%)	<b>0.041</b>
Complications after SLN procedure only	4/17	1/22	0.079
Complications after IFL, with or without previous SLN procedure	2/7	0/2	0.391
Long-term morbidity <sup>4</sup>	1/19 (5.3%)	1/20 (5.0%)	0.942

SLN(s); sentinel lymph node(s), N/A; not applicable, SD; standard deviation, IFL; inguinofemoral lymphadenectomy.

<sup>1</sup> In both groups in one patient, no re-excision of the vulva was performed because of a previous R0 resection at the time of SLN procedure.<sup>2</sup> The time interval between skin incision and resection time of all SLNs (i.e. one or more SLNs, including additional SLNs).<sup>3</sup> The time interval between skin incision and completion of successful SLN procedure or full IFL.<sup>4</sup> For long-term postoperative complications analysis, we excluded 9 women who received additional surgery or radiotherapy to the groins.



**Fig. 2.** Example of the intraoperative detection of a sentinel lymph node by fluorescence imaging after the injection of ICG-<sup>99m</sup>Tc-nanocolloid in a patient with VSCC. Percutaneous visualization of fluorescence medial of the placed cross (A), on which the incision was adjusted. Intraoperative visualization of a lymphatic channel by fluorescence imaging (B), leading to a deeper located fluorescent sentinel lymph node (C). Images in colour (left), green fluorescence overlay (center), and near-infrared fluorescence signal (right). Images acquired by the Quest Spectrum Imaging System in real-time.

in more than 95% of surgical procedures in different malignancies (head and neck, penile, melanoma and vulva) [11,14,17]. Several studies have been published concerning NIR fluorescence imaging using ICG or hybrid ICG-<sup>99m</sup>Tc-nanocolloid to detect SLNs in patients with VSCC [12–16,19,20,23–26]. Most studies were feasibility studies or assessed the effect of different doses of ICG [13], optimal tracer formulation of ICG-<sup>99m</sup>Tc-nanocolloid [16,19], or explored the possibility of robot-assisted SLN procedure using ICG [23,26]. KleinJan et al. [14] used the same hybrid tracer and found that 96% of the SLNs were detected by fluorescence imaging in a series of 21 patients with vulvar cancer. Our results were comparable as 92.5% of the resected SLNs, including the additional SLNs, were fluorescent. In addition, we found in 35 of the 36 groins (97.2%) at least one radioactive and fluorescent SLN.

The variations in the injected radioactivity dose of (ICG)-<sup>99m</sup>Tc-nanocolloid and time interval between injection and surgery in our study were all within the recommended standard procedure [1,2]. It may be hypothesized that the higher injected dose of 100 MBq in the fluorescence imaging group, could contribute to the trend of more complete SLN procedures in the fluorescence imaging group. However, we found no significant relationship between the radioactivity dose of ICG-<sup>99m</sup>Tc-nanocolloid and either a successful or complete SLN procedure, but this may also be because the study was not powered for this comparison. On the other hand, a significant relationship was found between a higher injected dose ICG-<sup>99m</sup>Tc-nanocolloid and the detection of more additional SLNs (24.5%) in the fluorescence imaging group. A percentage up to 24% additional SLNs has been reported previously and corroborates our finding of the synergy using ICG-<sup>99m</sup>Tc-nanocolloid [14]. Furthermore, it is also possible that these additional SLNs were part of a cluster on lymphoscintigraphy or were second-tier nodes. The additional resected SLNs included also nodes with metastatic disease. The resection of additional, metastatic SLNs could

possibly improve the local control in groins as no other positive LNs were found in the subsequent IFLs. However, it is not evident that the resection of additional SLNs is associated with better outcome and it possibly increases the risk of complications such as lymphedema. It may be hypothesized, that a complete SLN procedure (i.e. not leaving a SLN behind which was identified on the lymphoscintigraphy), could contribute to a smaller risk of a false-negative SLN procedure. However, we could not determine the false-negative rate of the performed SLNs procedures, because of a relative short follow-up period and no standard IFL.

In the standard and fluorescence imaging group, in respectively 20.8% and 25.0% of the patients with a lateral tumor, bilateral SLNs were identified on lymphoscintigraphy, which confirms previous findings in literature [27]. Furthermore, failure of bilateral SLN identification on lymphoscintigraphy in case of a midline tumor, has been reported in up to 30% of the cases [27]. In our study this was found in only 4.2% of the cases, one patient in each group.

We documented significant more short-term postoperative complications (25%) in the standard group. Wound breakdown was documented in 8.3% and groin infections in 12.5% of the patients in the standard group. Reported complication rates after a SLN procedure in literature [2,4] are 11.7% for wound breakdown and 4.5% for groin infections. This higher rate of groin infections in our study in the standard group could be a result of the extended surgical procedure, as two of the three groin infections occurred after an IFL. However, because more IFLs were performed in the standard group and the total number of patients was limited, no strong conclusions can be drawn about the complication rate.

As NIR fluorescence imaging with ICG-<sup>99m</sup>Tc-nanocolloid outperformed blue dye in terms of visual guidance during surgery and ICG does not alter the surgical field by dark staining or tattooing the

skin, this technique can be regarded as superior. The goal of the hybrid tracer design is to extend routine radio-guidance with visual imaging by fluorescence-guidance. Radioactive tracers still remain necessary to identify contralateral SLNs on lymphoscintigraphy in case of a lateral tumor, the intraoperative localization of the SLNs and detection of deeper located SLN. However, fluorescence imaging facilitates the identification during surgery by direct visualization and hereby more exact localization of the SLN. In addition, this may be extra beneficial for the surgical learning curve of fellows in gynecologic oncology.

Nevertheless, several requirements should be considered before successful implementation of fluorescence imaging into standard SLN procedure seems possible. This includes accessibility of a fluorescence camera system, training in NIR fluorescence imaging, and convenience with this technique. The presence of the NIR fluorescence camera above the surgical field may interfere with the free space of movement for the surgeon. Getting acquainted with the NIR fluorescence camera system and interpretation of the images, could further improve the use of fluorescence imaging [20], and possibly resulting in a shorter duration of the SLN procedure. On the other hand, clinical implementation of the hybrid ICG-<sup>99m</sup>Tc-nanocolloid into standard of care is possible since it is based on two clinically approved components and because of the low costs of ICG.

In conclusion, we showed that the visual intraoperative identification of SLNs in patients with VSCC using ICG-<sup>99m</sup>Tc-nanocolloid and fluorescence imaging was superior compared to standard blue dye. A successful SLN procedure was achieved in 97.2% of the groins in the fluorescence imaging group versus 92.1% of the groins in the standard group, although this difference was not significant. NIR fluorescence imaging using ICG-<sup>99m</sup>Tc-nanocolloid has the potential to become part of the standard SLN procedure in patients with early-stage VSCC to facilitate the identification of the SLN by direct visualization.

#### Authors' contributions

M.D. coordinated the data collection, performed the analysis, contributed to data interpretation and drafted the manuscript. H.v.D. contributed to the data collection and interpretation of the results and editing of the manuscript. D.V., and K.d.V. contributed to the data collection and editing of manuscript. L.B., D.R., and L-F.d.G-O. contributed to the study design and editing of manuscript. M.v.P., C.d.K., J.B., T.B., and J.B. contributed to data collection and interpretation of the results and editing of the manuscript. F.v.L. contributed to the design of the tracer and editing of the manuscript. H.P. contributed to statistical design and data interpretation. C.v.d.V., J.B., and A.L.V. conceived the study and led on the study design. K.G. conceived the study, contributed to the study design and data collection, interpretation of the results and editing of the manuscript. All authors read and approved the final manuscript.

#### Funding

This project was funded by the European Research Council Advanced Grant project SURVive (grant 323105).

#### Declaration of Competing Interest

The authors declare no conflict of interests.

#### Acknowledgements

The authors would thank Tjalling Bosse for the pathology assessment and Margriet J.G. Löwik, Dorien M.A. Berends-van der Meer, Sandra L. van den Broek-Veldstra, Henricus J.M. Handgraaf, Job K. van Kooten and Marianne Maliepaard for their assistance during the patient inclusion process.

#### Appendix A. Supplementary data

Supplementary data to this article can be found online at <https://doi.org/10.1016/j.ygyno.2020.09.044>.

#### References

- [1] J.A. de Hullu, H. Hollema, D.A. Piers, R.H. Verheijen, P.J. van Diest, M.J. Mourits, et al., Sentinel lymph node procedure is highly accurate in squamous cell carcinoma of the vulva, *Journal of clinical oncology : official journal of the American Society of Clinical Oncology*. 18 (15) (2000) 2811–2816.
- [2] A.G. Van der Zee, M.H. Oonk, J.A. De Hullu, A.C. Ansink, I. Vergote, R.H. Verheijen, et al., Sentinel node dissection is safe in the treatment of early-stage vulvar cancer, *Journal of clinical oncology : official journal of the American Society of Clinical Oncology*. 26 (6) (2008) 884–889.
- [3] N.C. Te Grootenhuis, A.G. van der Zee, H.C. van Doorn, J. van der Velden, I. Vergote, V. Zanagnolo, et al., Sentinel nodes in vulvar cancer: long-term follow-up of the GROningen International study on sentinel nodes in vulvar cancer (GROINSS-V) I, *Gynecol. Oncol.* 140 (1) (2016) 8–14.
- [4] A. Covens, E.T. Vella, E.B. Kennedy, C.J. Reade, W. Jimenez, T. Le, Sentinel lymph node biopsy in vulvar cancer: systematic review, meta-analysis and guideline recommendations, *Gynecol. Oncol.* 137 (2) (2015) 351–361.
- [5] C. Meads, A.J. Sutton, A.N. Rosenthal, S. Malysiak, M. Kowalska, A. Zapalska, et al., Sentinel lymph node biopsy in vulvar cancer: systematic review and meta-analysis, *Br. J. Cancer* 110 (12) (2014) 2837–2846.
- [6] T.A. Lawrie, A. Patel, P.P. Martin-Hirsch, A. Bryant, N.D. Ratnavel, R. Naik, et al., Sentinel node assessment for diagnosis of groin lymph node involvement in vulval cancer, *Cochrane Database Syst. Rev.* 6 (2014), CD010409.
- [7] K.N. Gaarenstroom, G.G. Kenter, J.B. Trimpos, I. Agous, F. Amant, A.A. Peters, et al., Postoperative complications after vulvectomy and inguinofemoral lymphadenectomy using separate groin incisions, *Int. J. Gynecol. Cancer* 13 (4) (2003) 522–527.
- [8] F. Hinten, L.C. van den Einden, J.C. Hendriks, A.G. van der Zee, J. Bulten, L.F. Massuger, et al., Risk factors for short- and long-term complications after groin surgery in vulvar cancer, *Br. J. Cancer* 105 (9) (2011) 1279–1287.
- [9] L.S.F. Boogerd, C.E.S. Hoogstins, D.P. Schaap, M. Kusters, H.J.M. Handgraaf, M.J.M. van der Valk, et al., Safety and effectiveness of SGM-101, a fluorescent antibody targeting carcinoembryonic antigen, for intraoperative detection of colorectal cancer: a dose-escalation pilot study, *Lancet Gastroenterol Hepatol.* 3 (3) (2018) 181–191.
- [10] F.J. Hinsenveld, E.M.K. Wit, P.J. van Leeuwen, O.R. Brouwer, M.L. Donswijk, C.N. Tillier, et al., Prostate-specific membrane antigen positron emission tomography/computed tomography combined with sentinel node biopsy for primary lymph node staging in prostate cancer, *J Nucl Med.* 61 (4) (2020 Apr) 540–545.
- [11] O.R. Brouwer, N.S. van den Berg, H.M. Matheron, H.G. van der Poel, B.W. van Rhijn, A. Bex, et al., A hybrid radioactive and fluorescent tracer for sentinel node biopsy in penile carcinoma as a potential replacement for blue dye, *Eur. Urol.* 65 (3) (2014) 600–609.
- [12] L.M. Crane, G. Themelis, H.J. Arts, K.T. Buddingh, A.H. Brouwers, V. Ntziachristos, et al., Intraoperative near-infrared fluorescence imaging for sentinel lymph node detection in vulvar cancer: first clinical results, *Gynecol. Oncol.* 120 (2) (2011) 291–295.
- [13] M. Hutteman, J.R. van der Vorst, K.N. Gaarenstroom, A.A. Peters, J.S. Mieog, B.E. Schaafsma, et al., Optimization of near-infrared fluorescent sentinel lymph node mapping for vulvar cancer, *Am J Obstet Gynecol.* 206 (1) (2012) 89 e1–5.
- [14] G.H. Kleinjan, E. van Werkhoven, N.S. van den Berg, M.B. Karakullukcu, H. Zijlman, J.A. van der Hage, et al., The best of both worlds: a hybrid approach for optimal pre- and intraoperative identification of sentinel lymph nodes, *Eur. J. Nucl. Med. Mol. Imaging* 45 (11) (2018) 1915–1925.
- [15] H.M. Matheron, N.S. van den Berg, O.R. Brouwer, G.H. Kleinjan, W.J. van Driel, J.W. Trum, et al., Multimodal surgical guidance towards the sentinel node in vulvar cancer, *Gynecol. Oncol.* 131 (3) (2013) 720–725.
- [16] B.E. Schaafsma, F.P. Verbeek, A.A. Peters, J.R. van der Vorst, C.D. de Kroon, M.I. van Poelgeest, et al., Near-infrared fluorescence sentinel lymph node biopsy in vulvar cancer: a randomised comparison of lymphatic tracers, *BJOG.* 120 (6) (2013) 758–764.
- [17] N.S. van den Berg, O.R. Brouwer, B.E. Schaafsma, H.M. Matheron, W.M. Klop, A.J. Balm, et al., Multimodal surgical guidance during sentinel node biopsy for melanoma: combined gamma tracing and fluorescence imaging of the sentinel node through use of the hybrid tracer Indocyanine green-(<sup>99m</sup>Tc-Nanocolloid, *Radiology.* 275 (2) (2015) 521–529.
- [18] J.R. van der Vorst, B.E. Schaafsma, F.P. Verbeek, M. Hutteman, J.S. Mieog, C.W. Lowik, et al., Randomized comparison of near-infrared fluorescence imaging using indocyanine green and <sup>99m</sup>Tc-technetium with or without patent blue for the sentinel lymph node procedure in breast cancer patients, *Ann. Surg. Oncol.* 19 (13) (2012) 4104–4111.
- [19] F.P. Verbeek, Q.R. Tummers, D.D. Rietbergen, A.A. Peters, B.E. Schaafsma, C.J. van de Velde, et al., Sentinel lymph node biopsy in vulvar Cancer using combined radioactive and fluorescence guidance, *Int. J. Gynecol. Cancer* 25 (6) (2015) 1086–1093.
- [20] S. Prader, A. du Bois, P. Harter, E. Breit, S. Schneider, T. Baert, et al., Sentinel lymph node mapping with fluorescent and radioactive tracers in vulvar cancer patients, *Arch Gynecol Obstet.* 301 (3) (2020 Mar) 729–736.
- [21] H.J. Handgraaf, F.P. Verbeek, Q.R. Tummers, L.S. Boogerd, C.J. van de Velde, A.L. Vahrmeijer, et al., Real-time near-infrared fluorescence guided surgery in

- gynecologic oncology: a review of the current state of the art, *Gynecol. Oncol.* 135 (3) (2014) 606–613.
- [22] J.A. de Hullu, E. Doting, D.A. Piers, H. Hollema, J.G. Aalders, H.S. Koops, et al., Sentinel lymph node identification with technetium-99m-labeled nanocolloid in squamous cell cancer of the vulva, *J. Nucl. Med.* 39 (8) (1998) 1381–1385.
- [23] A. Mohammad, M.I. Hunter, Robot-assisted sentinel lymph node mapping and inguinal lymph node dissection using near-infrared fluorescence in vulvar Cancer, *J. Minim. Invasive Gynecol.* 26 (5) (2019) 968–972.
- [24] A. Buda, T. Dell'Anna, F. Vecchione, D. Verri, G. Di Martino, R. Milani, Near-infrared sentinel lymph node mapping with Indocyanine green using the VITOM II ICG exoscope for open surgery for gynecologic malignancies, *J. Minim. Invasive Gynecol.* 23 (4) (2016) 628–632.
- [25] P. Soergel, H. Hertel, A.K. Nacke, R. Klapdor, T. Derlin, P. Hillemanns, Sentinel lymphadenectomy in vulvar Cancer using near-infrared fluorescence from Indocyanine green compared with technetium 99m Nanocolloid, *Int. J. Gynecol. Cancer* 27 (4) (2017) 805–812.
- [26] A. Naldini, G. Vizzielli, E. Perrone, V. Gallotta, G. Scambia, Robotic video endoscopic inguinal lymphadenectomy (R-VEIL) for vulvar cancer with sentinel node mapping using indocyanine green and near-infrared fluorescence imaging technology, *Gynecol. Oncol.* 150 (1) (2018) 203–204.
- [27] B.M. Slomovitz, R.L. Coleman, M.H. Oonk, A. van der Zee, C. Levenback, Update on sentinel lymph node biopsy for early-stage vulvar cancer, *Gynecol. Oncol.* 138 (2) (2015) 472–477.