



Universiteit
Leiden
The Netherlands

Migraine with aura as early disease marker in hereditary Dutch-type cerebral amyloid angiopathy

Koemans, E.A.; Voigt, S.; Rasing, I.; Etten, E.S. van; Zwet, E.W. van; Walderveen, M.A.A. van; ... ; Terwindt, G.M.

Citation

Koemans, E. A., Voigt, S., Rasing, I., Etten, E. S. van, Zwet, E. W. van, Walderveen, M. A. A. van, ... Terwindt, G. M. (2020). Migraine with aura as early disease marker in hereditary Dutch-type cerebral amyloid angiopathy. *Stroke*, 51(4), 1094-1099. doi:10.1161/STROKEAHA.119.028170

Version: Publisher's Version

License: [Creative Commons CC BY-NC-ND 4.0 license](#)

Downloaded from: <https://hdl.handle.net/1887/3184583>

Note: To cite this publication please use the final published version (if applicable).

Migraine With Aura as Early Disease Marker in Hereditary Dutch-Type Cerebral Amyloid Angiopathy

Emma A. Koemans¹ MD; Sabine Voigt, BSc;
Ingeborg Rasing, MD; Ellis S. van Etten, MD; Erik W. van Zwet, PhD;
Marianne A.A. van Walderveen, MD, PhD; Marieke J.H. Wermer, MD, PhD*;
Gisela M. Terwindt² MD, PhD*

Background and Purpose—To determine whether migraine, which has often been described as an inaugural manifestation in monogenic cerebrovascular syndromes, is associated with cerebral amyloid pathology, we assessed migraine and its correlation with magnetic resonance imaging markers in Hereditary Dutch-Type Cerebral Amyloid Angiopathy (D-CAA or Hereditary Cerebral Hemorrhage With Amyloidosis-Dutch type).

Methods—All D-CAA mutation carriers who visited our clinic between 2012 and 2018 were included. Migraine was diagnosed by an interview and classified according to the *International Classification of Headache Disorders*. Magnetic resonance imaging scans were scored for intracerebral hemorrhage (ICH) location(s) and presence of cortical superficial siderosis. Kaplan Meier survival analysis was used for age of ICH onset in carriers with and without migraine. Correlation with ICH location(s) and cortical superficial siderosis were calculated with Poisson regression analysis adjusted for confounders.

Results—We included 86 D-CAA mutation carriers (57% women, mean age 57 years), 48 (56%) suffered from migraine, all with aura. Prevalence was higher than expected compared with the general population (women, $P < 0.05$; men, $P < 0.001$). Migraine was the inaugural symptom in 77% and an isolated symptom in 35% of the carriers. Carriers with and without migraine did not differ for age of first ICH, cortical superficial siderosis prevalence, or occipital ICH. Time between migraine onset and first ICH was 8.5 years. Aura attacks lasting ≥ 60 minutes signaled acute ICH in 55%.

Conclusions—Migraine with aura is an important, often inaugural, symptom in D-CAA. Aura attacks lasting ≥ 60 minutes may signal acute ICH in D-CAA. Migraine with aura may be regarded as an early marker of disease in hereditary CAA preceding the occurrence of symptomatic ICH by several years. (*Stroke*. 2020;51:1094-1099. DOI: 10.1161/STROKEAHA.119.028170.)

Key Words: cerebral amyloid angiopathy ■ cerebral hemorrhage ■ epilepsy ■ migraine ■ siderosis

Cerebral amyloid angiopathy (CAA) is an important cause of intracerebral hemorrhage (ICH) in elderly.¹ Patients with CAA often report transient focal neurological episodes (TFNE), which are typically recurrent stereotyped attacks that are strongly related with cortical superficial siderosis (cSS).² The definitions of TFNE and migraine aura, described as positive, reversible neurological symptoms in a sequential pattern according to the *International Classification of Headache Disorders* third edition (ICHD-3), overlap.³ The relationship between migraine and cerebrovascular disease has long been recognized, but the underlying pathophysiological basis is still not understood.^{4,5} Migraine has been described in rare monogenic cerebrovascular syndromes as an early hallmark or even isolated symptom, for instance in cerebral autosomal dominant

arteriopathy with subcortical infarcts and leukoencephalopathy and retinal vasculopathy with cerebral leukoencephalopathy and systemic manifestations, suggesting a link between migraine and microvascular changes in early stages of angiopathies.⁶⁻⁸

Migraine has been reported in CAA; however, not much is known about the prevalence and characteristics.⁹ Hereditary Dutch-type CAA (D-CAA, also called Hereditary Cerebral Hemorrhage with Amyloidosis-Dutch type) is an hereditary variant of CAA, caused by a mutation in the A β region of the APP (amyloid precursor protein) gene. D-CAA patients suffer from recurrent ICH from the age of 50. The pathophysiology of D-CAA and sporadic CAA are similar, allowing D-CAA to function as a model of CAA, enabling investigation of early disease stages.¹⁰⁻¹³

Received October 24, 2019; final revision received December 13, 2019; accepted January 24, 2020.

From the Department of Neurology (E.A.K., S.V., I.R., E.S.v.E., M.J.H.W., G.M.T.), Department of Radiology (M.A.A.v.W.), and Department of Biomedical Data Sciences (E.W.v.Z.), Leiden University Medical Center, the Netherlands.

*Drs Wermer and Terwindt contributed equally.

Correspondence to Gisela M. Terwindt, MD, PhD, Department of Neurology, Leiden Universitair Medisch Centrum, Albinusdreef 2, 2300 RC Leiden, the Netherlands, Email g.m.terwindt@lumc.nl or Emma A. Koemans, MD, Department of Neurology, Leiden Universitair Medisch Centrum, Albinusdreef 2, 2300 RC Leiden, the Netherlands, Email e.a.koemans@lumc.nl

© 2020 The Authors and Leiden University Medical Center. *Stroke* is published on behalf of the American Heart Association, Inc., by Wolters Kluwer Health, Inc. This is an open access article under the terms of the [Creative Commons Attribution Non-Commercial-NoDerivs](https://creativecommons.org/licenses/by-nc-nd/4.0/) License, which permits use, distribution, and reproduction in any medium, provided that the original work is properly cited, the use is noncommercial, and no modifications or adaptations are made.

Stroke is available at <https://www.ahajournals.org/journal/str>

DOI: 10.1161/STROKEAHA.119.028170

This study investigates migraine prevalence and symptomatology in D-CAA, relating migraine history to ICH onset, ICH location, and presence of cSS on magnetic resonance imaging (MRI).

Methods

For this retrospective study, we retrieved patient files of all D-CAA mutation carriers who visited the Cerebral Hereditary Angiopathy outpatient clinic or the inpatient clinic of our neurology department at the Leiden University Medical Center, the Dutch national referral center for D-CAA, between January 2012 and January 2018. Files were collected in August 2018. All available information up to this date was used for the analysis. The diagnosis D-CAA carrier was made based on DNA analysis of the Glu693Gln mutation in the APP gene, or if no DNA analysis was performed, a medical history with one or more ICHs with CAA characteristics according to the Boston criteria on MRI and a positive family history for D-CAA.¹⁴ In this study, the participants are called ICH carriers if they had at least one symptomatic ICH, and non-ICH carriers if they did not have a symptomatic ICH. All patients underwent a semi-structured headache questionnaire. Patients who had visited our hospital and of whom no information on migraine and headache was available were asked to take this structured headache questionnaire via a telephone interview if they had consented to be contacted for participation in scientific research before. The questionnaire contained questions on migraine and headache characteristics, attack frequency and duration, aura characteristics, and age of onset. Furthermore, it contained questions about TNFE and epilepsy. The presence, time course, and clinical characteristics of migraine were assessed by a neurologist or resident in neurology, and a final diagnosis was made by a neurologist specialized in migraine (Dr Terwindt). Migraine was defined according to the ICHD-3 criteria and classified as definite or probable migraine and the subtypes migraine with aura or migraine without aura. Aura without (migraine) headache was also defined according to the ICHD-3 edition as migraine with aura.³ In addition to migraine history, information on other headache subtypes was captured.

The data set analyzed in this study is not publicly available because of restricted access and privacy legislation, but further information about the data set is available from the corresponding author on reasonable request. Approval for this study has been granted by the local ethics review board of the Leiden University Medical Center, who waived the need for written informed consent from individual participants for the study. The telephone interviews were only conducted in participants who had given previous written informed consent to be contacted for participation in scientific research.

MRI Analysis

All latest available 3 and 1.5 Tesla MRI scans of the brain were retrieved, and presence of cSS and ICH was scored by 2 independent observers (Dr Koemans and S. Voigt). ICH was defined as large, irregular areas of signal void which are visible on T1-weighted and T2-weighted sequences, according to the STRIVE criteria.¹⁵ Location of ICH was classified as occipital or nonoccipital (frontal, parietal, temporal, infratentorial). We looked at occipital ICH specifically since it is known that this lobe is most severely affected with amyloidosis in CAA and Hereditary Cerebral Hemorrhage with Amyloidosis-Dutch type.¹⁶ cSS was defined as linear hemosiderin deposits within the subarachnoid space, leptomeninges, and the superficial layers of the cerebral or cerebellar cortex.² One important criterion for the identification of cSS in sporadic CAA is that it should be separated from any lobar ICH by at least 3 unaffected sulci.¹⁷ However, in D-CAA, due to the large number of ICHs in each individual, this makes the identification of cSS almost impossible. Therefore, in this study, we scored cSS as either ≤ 3 sulci from an ICH or > 3 sulci from an ICH, to prevent under recognition of cSS in D-CAA. cSS was scored on susceptibility-weighted imaging sequences (SWI) or T2*-weighted imaging sequences. In case of nonconcordance, findings were discussed with a third observer with > 15 years of experience in the field (Dr van Walderveen) to achieve consensus.

Statistics

Descriptive statistics were performed. Between carriers with and without migraine, difference in proportion of non-ICH mutation carriers and ICH mutation carriers, occipital ICH and cSS on MRI was assessed by Poisson regression analysis corrected for age and sex. Interobserver variability (κ value) was calculated for the MRI markers occipital ICH and cSS, the grading of interobserver agreement was performed according to the recommendations of Landis and Koch.¹⁸ Relative risks (RR) with 95% CIs were calculated. The difference in age at which the first ICH occurred in mutation carriers with and without migraine, as well as in mutation carriers with early and late-onset migraine, was assessed with a Kaplan Meier survival analysis. Late-onset migraine was defined as occurring after the third decade, based on earlier studies.¹⁹ To compare the prevalence of migraine in D-CAA to the prevalence in the Dutch population, we used data from a large population-based cohort study: the GEM (Genetic Epidemiology of Migraine) study.²⁰ Lifetime prevalence of migraine in D-CAA was calculated separately for men and women. Prevalence of migraine in the general Dutch population was calculated by using the age-specific lifetime prevalence tables of the GEM study for men and women separately. We fitted a logistic regression model to the combined data with main effects for cohort (D-CAA/general Dutch population) and age and their interaction. We did this for men and women separately. In both models, we tested for any difference between the cohorts by means of a χ^2 test.

Results

Between January 2012 and January 2018, 95 D-CAA mutation carriers visited the Leiden University Medical Center, all of whom were included in this study. Of 19 patients, no information on migraine was available, 10 of these 19 patients had given permission to be contacted for participation in scientific research and were contacted and participated in a telephone interview. Of the 9 remaining patients, 5 were deceased and 4 patients had not given permission to be contacted for participation in research. Of the 86 carriers with a known migraine status, the mean age was 57 years, 57 (66%) suffered at least one symptomatic ICH, and 49 (57%) were women (Table 1). Eight patients were deceased at the time of analysis, for these patients age at time of death was used for the age calculation. In 71 carriers, the diagnosis D-CAA was confirmed by DNA analysis. The remaining 15 carriers had at least one ICH with CAA characteristics on MRI in combination with a positive family history of D-CAA.

Migraine Symptoms

Among the 86 carriers with D-CAA and a known migraine status, 48/86 (56%) had a positive history of migraine, the majority of whom were women (29/48, 60%). According to the ICHD-3 criteria, 39/86 (45%) had definite migraine and 9/86 (10%) probable migraine (Table 2). All carriers with migraine suffered from the subtype migraine with aura, all reported visual aura symptoms, 36/86 (42%) patients had visual auras only, 10/86 (12%) additional sensory aura symptoms, and 4/86 (5%) additional aphasia (Table 2). Typical aura without headache occurred in 21/86 (24%) of patients, in 12/86 (14%) of patients this was the only type of migraine attacks they experienced. Of the carriers, 11/86 (13%) reported both attacks with and without aura. The age at onset of migraine with aura showed 2 peaks; one before the third decade and one after the fourth decade (Figure 1). Prevalence of migraine in D-CAA was higher for men ($P < 0.001$) and women ($P = 0.038$) compared with the prevalence in the general Dutch population

Table 1. Demographics and Characteristics

	D-CAA Patients* (n=86)
Mean age, y† (range)	57 (31–84)
Women (%)	49 (57)
DNA proven (%)	71 (83)
Symptomatic ICH (%)	57 (66)
Mean age at first ICH in years (n=57; range)	55 (35–78)
Epilepsy (%)	23 (27)
Generalized	10 (12)
Focal without loss of consciousness	2 (2)
Focal with loss of consciousness	5 (6)
Mixed focal and generalized attacks	5 (6)
Unknown type	1 (1)
Previous or persisting psychiatric or mood disturbances‡ (%)	35 (41)
Transient focal neurological episodes (%)	6 (7)

D-CAA indicates Dutch-type Cerebral Amyloid Angiopathy; and ICH, intracerebral hemorrhage.

*D-CAA patients are defined as (1) DNA proven (positive DNA analysis for codon 693 mutation in the amyloid- β precursor protein [A β PP] gene) or (2) symptomatic lobar ICH with characteristics of CAA on magnetic resonance imaging and positive family history, or (3) both.

†For patients who were deceased at the moment of analysis (n=8) age at time of death was used for the calculation.

‡Including symptoms of depression and anxiety, ADHD, psychosis, PTSS, and burn-out.

(also own data from the GEM study, which found a lifetime prevalence of migraine of 13% in men and 33% in women).²⁰

Carriers with migraine were not older than those without migraine, nor was there a difference in medical history between the groups (Table 3). The majority of carriers with migraine had their first attack before they had the first symptomatic ICH, 37/48 (77%), and for 17/48 (35%) it was an isolated symptom. The median time between migraine onset and first ICH was 8.5 years (range, 3–46). The mean age at which ICH carriers with migraine experienced their first ICH did not differ from those without migraine (Figure 2). Mutation carriers with an onset of migraine on or before the third decade experienced their first ICH at a significantly earlier age compared with mutation carriers with migraine onset after the third decade (Figure 3).

Out of all patients with migraine, 11/48 (23%) had experienced migraine attacks with visual, single aura symptomatology lasting over 60 minutes. For 6/11 (55%) of the cases, this was directly before a symptomatic ICH confirmed on the computed tomography scan. For one mutation carrier of the 6 this was the first experienced migraine attack, for 5 of the carriers this was the first time they experienced an ICH. In 4 of the 6 carriers, the hemorrhage was located in the occipital lobe.

Hemorrhage Location and cSS on MRI

Among the 86 carriers, with D-CAA and a known migraine status, for 62 the presence of cSS could be scored on 1.5 or 3 Tesla MRI with SWI or T2*-weighted images. cSS was found in 27/62 (44%) of the carriers, 16/62 (26%) had cSS only \leq 3

Table 2. Migraine and Headache Characteristics

		D-CAA Patients (n=86)
Lifetime prevalence of migraine (%)*	Probable	9 (10)
	Definite	39 (45)
	In men (n=37)	19 (51)
	In women (n=49)	29 (59)
Mean onset age of migraine, y (range)†		37 (9–69)
Migraine subtypes (%)	Migraine with aura attacks total	48 (56)
	Migraine with aura only	37 (43)
	Migraine with and without aura‡	11 (13)
	Migraine without aura attacks only	0 (0)
	Migraine without headache only	12 (14)
Migraine characteristics (%)	Headache	36 (42)
	Hemicranial	12 (14)
	Pulsatile	10 (12)
	Photophobia	23 (27)
	Phonophobia	19 (22)
	Nausea	23 (27)
	Vomiting	12 (14)
Migraine attack frequency (%)	<1 attack/y	9 (10)
	1–4 attacks/y	7 (8)
	5–7 attacks/y	3 (3)
	8–12 attacks/y	9 (10)
	>12 attacks/y	15 (17)
	Unknown	5 (6)
Migraine attack duration (%)	<1 day	26 (30)
	1–2 days	4 (5)
	3–5 days	6 (7)
	Unknown	12 (14)
Aura subtypes (%)	Visual only	36 (42)
	Visual and sensory only	8 (9)
	Visual and aphasia only	2 (2)
	Visual, sensory, and aphasia	2 (2)
Long-lasting aura‡ (%)		11 (13)
Other headache types (%)	TTH	24 (28)
	Migraine and TTH	11 (13)
	MOH	1 (1)
	Migraine and MOH	1 (1)
	MOH and TTH	6 (7)
	Migraine, MOH, and TTH	4 (5)
	Unclassifiable	2 (2)

D-CAA indicates Dutch-type Cerebral Amyloid Angiopathy; ICHD-3, *International Classification of Headache Disorders*, third edition; MOH, medication-overuse headache; and TTH, tension-type headache.

*Defined according to ICHD-3.

†N=42. Two patients described the onset as during childhood, these were excluded from the calculation.

‡Defined according to ICHD-3 one single aura symptom lasting >60 min.

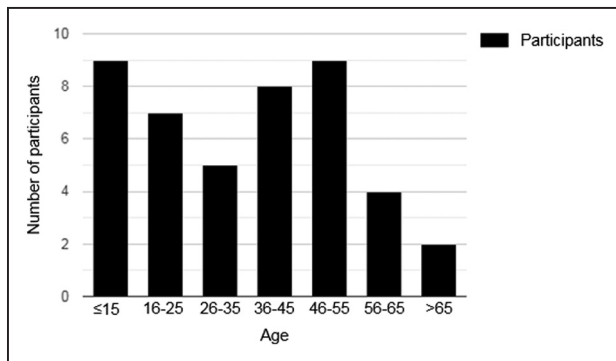


Figure 1. Age at onset of migraine with aura. N=44; 26 women, 18 men (all with known migraine). Four participants were excluded due to unknown age of onset of migraine. Two patients described migraine with aura onset as during childhood, these patients were placed in the ≤15 category.

gyri of ICH, 2/62 (3%) had cSS only >3 gyri of ICH, and 9/62 (15%) carriers had cSS both ≤3 gyri and >3 gyri of ICH (Table 3). The interobserver agreement for cSS was very high ($\kappa=0.91$). There was no difference in the presence of cSS on MRI for patients with migraine compared with those without migraine (RR, 1.17 [95% CI, 0.52–2.64]; $P=0.702$), nor was there a difference if cSS was scored only if it was separated from ICH by at least 3 gyri (RR, 0.57 [95% CI, 0.17–1.92]; $P=0.361$). As the definition of typical aura without headache comes closest to the definition of TFNE, we compared cSS occurrence on MRI in patients with typical aura without headache only, to patients with migraine headache and patients without migraine and did not find a difference (RR, 0.95 [95% CI, 0.33–2.78]; $P=0.931$). In 70 patients, T2 or T1 weighted images were available for analysis of presence and location of ICH. Occipital ICH was found in 42/70 (60%) of the patients. The interobserver agreement for occipital ICH was substantial ($\kappa=0.83$). There was no significant difference in the presence of occipital ICH in patients with or without migraine (RR, 1.23 [95% CI, 0.65–2.31]; $P=0.531$).

Discussion

In this study, we found that more than half of D-CAA patients had migraine, 51% of men and 59% of women, all of them with visual aura. This prevalence is much higher than expected in the general population.^{20–22} Migraine attacks preceded the first symptomatic hemorrhage in the majority of carriers but did not seem to be a predictor for an earlier onset of first hemorrhage. However, migraine onset on or before the third decade was associated with an earlier onset of the first hemorrhage in D-CAA. Single aura symptomatology lasting more than 60 minutes occurred in 23% of the patients with migraine, similar to a recent study that showed prolonged aura to be quite common in the general population.²³ Nevertheless, it was an alarming symptom as it was a sign of acute ICH in 55% of our D-CAA carriers with long-lasting aura. Age of onset of migraine aura in D-CAA occurred in 2 peaks, with more than half of the patients experiencing their first migraine attack after the third decade and a mean age of onset which is higher than expected in the general population.²⁴ Migraine with aura was not related to occipital ICH or cSS on MRI. We have not found any proof that migraine

Table 3. Characteristics of D-CAA Mutation Carriers With Migraine Compared With D-CAA Mutation Carriers Without Migraine

	Migraine* (n=48)	No Migraine (n=38)	RR (95% CI)
Mean age, y† (range)	58 (31–84)	57 (35–75)	
Women (%)	29 (60)	20 (53)	
Symptomatic ICH (%)	31 (65)	26 (68)	1.00 (0.59–1.7)
T1/T2 weighted MRI	(n=40)	(n=30)	
ICH on MRI (%)	32 (80)	22 (73)	1.12 (0.64–1.95)
Occipital ICH (%)	25 (63)	17 (57)	1.23 (0.65–2.31)
SWI/T2*-weighted MRI	(n=38)	(n=24)	
cSS on MRI (%)	17 (45)	10 (42)	1.17 (0.52–2.64)‡
cSS >3 gyri separated from ICH (%)	5 (13)	6 (25)	0.57 (0.17–1.92)

Total number of mutation carriers n=86, for n=16 no T1/T2 weighted MRI data were available, for n=24 no SWI/T2* weighted MRI data were available. cSS indicates cortical superficial siderosis; D-CAA, Dutch-type Cerebral Amyloid Angiopathy; ICH, intracerebral hemorrhage; MRI, magnetic resonance imaging; RR, relative risks; and SWI, susceptibility-weighted imaging.

*Certain+probable migraine.

†For patients who were deceased at the moment of analysis (n=8) age at time of death was used for the calculation.

‡If we compared patients with MA without headache only (n=12): RR, 0.95 (0.33–2.78).

without aura is related to Hereditary Cerebral Hemorrhage with Amyloidosis-Dutch type.

Beside hemorrhagic events and cognitive decline, TFNEs are a common symptom of CAA. TFNEs are defined as recurrent, stereotyped, spreading paraesthesiae, or other transient focal neurological symptoms (such as weakness, dysphasia) which last several minutes.^{25,26} TFNEs with visual disturbances are also described in literature, occurring in 14% to 16% of TFNEs.^{27,28} The definition of aura in migraine overlaps with that of TFNE, which might raise the question whether what is termed as typical migraine aura in D-CAA may also be labelled as TFNE. It is, however, not possible to differentiate between the 2 phenomena based on the symptomatology. TFNE is strongly associated with cSS on MRI, whereas in our study migraine there was no clear association between the presence of cSS. Although criteria for identifying cSS on MRI in sporadic CAA are well known and have been tested multiple times, these criteria are not usable for D-CAA, as due to the large number of ICH in D-CAA, cSS is almost always within 3 gyri of an ICH.^{2,17} We considered it, therefore, necessary to use also an additional scoring system for cSS in D-CAA, to avoid under-diagnosis of cSS in patients with D-CAA.

Migraine aura attacks are thought to be a result of cortical spreading depression.²⁹ Interestingly, migraine with aura is one of the early characteristics of other small vessel diseases such as cerebral autosomal dominant arteriopathy with subcortical infarcts and leukoencephalopathy and retinal vasculopathy with cerebral leukoencephalopathy. In these monogenic angiopathies, the migraine prevalence is higher than in the general population and an early hallmark of the disease, occurring before the first cerebrovascular event.^{6,8} Our study

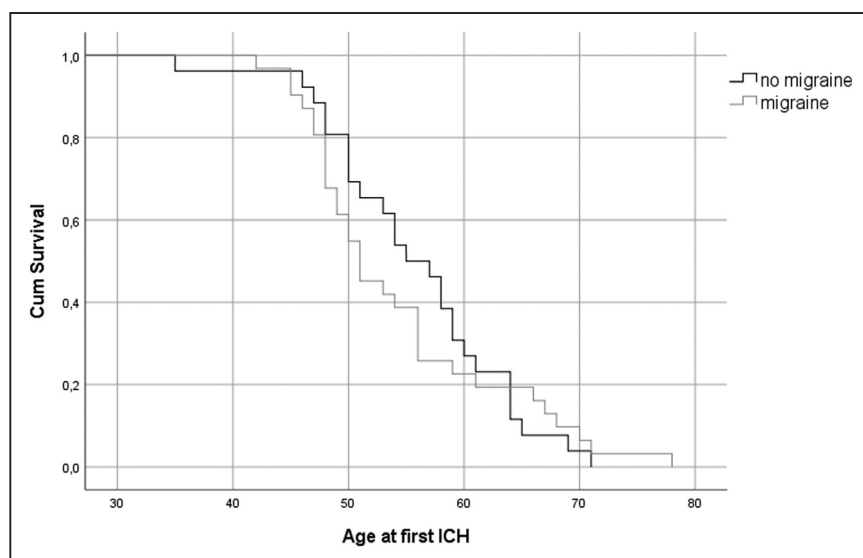


Figure 2. Age at first intracerebral hemorrhage (ICH) for patients with and without migraine. Migraine $n=31$, 31 events, no migraine $n=26$, 26 events. Mean age at first ICH for patients with migraine 54 y (95% CI, 51–58), for patients without migraine 56 y (95% CI, 53–59); $P=0.749$ (log-rank test).

in D-CAA shows 2 peaks in age of onset: a first one before the third decade which is comparable to onset of migraine with aura in the general population, and a second peak occurring after the fourth decade.³⁰ Late-life migraine with aura is also found in cerebral autosomal dominant arteriopathy with subcortical infarcts and leukoencephalopathy and has been described in sCAA, and might be a sign of increasing disease pathology.^{9,19} The high prevalence of migraine with aura in D-CAA might partially be explained by a familial clustering of migraine apart from D-CAA. However, the occurrence of visual aura attacks as a symptom of a new intracranial hemorrhage and the association of early-onset migraine to earlier occurrence of first ICH does suggest a link to CAA pathology. The presence of migraine in angiopathies such as cerebral autosomal dominant arteriopathy with subcortical infarcts and leukoencephalopathy, retinal vasculopathy with cerebral leukoencephalopathy, and D-CAA suggests that it may be caused by vascular changes associated with damage to the intracerebral small vessels leading to impaired vasoreactivity and increased susceptibility for cortical spreading depression, which has been shown in earlier studies in mouse-models.³¹

Further studies on migraine in hereditary cerebral angiopathies might increase the understanding of migraine pathophysiology in general.

Our study has some limitations. Our study population was relatively small due to the rarity of the genetic disease D-CAA. Nevertheless, as D-CAA forms a unique possibility to study the early phases of CAA, research in this relatively small population may provide important insights in the pathophysiology of CAA. Another limitation of this study is that some data were missing as carriers had passed away. Furthermore, as the data were retrieved retrospectively, our data are subjected to recall bias, especially in the D-CAA patients with cognitive symptoms. Therefore, we could not reliably investigate migraine trigger factors in this population. Lastly, the timing of the MRI images did often not correspond to the onset of migraine attacks nor did all carriers get an MRI at the same field strength and around the same time, as scans that were made over the years for clinical reasons. Therefore, our results concerning the relationship between cSS and ICH should be considered with caution. Furthermore, we only investigated the location of ICH and the presence of cSS and did not

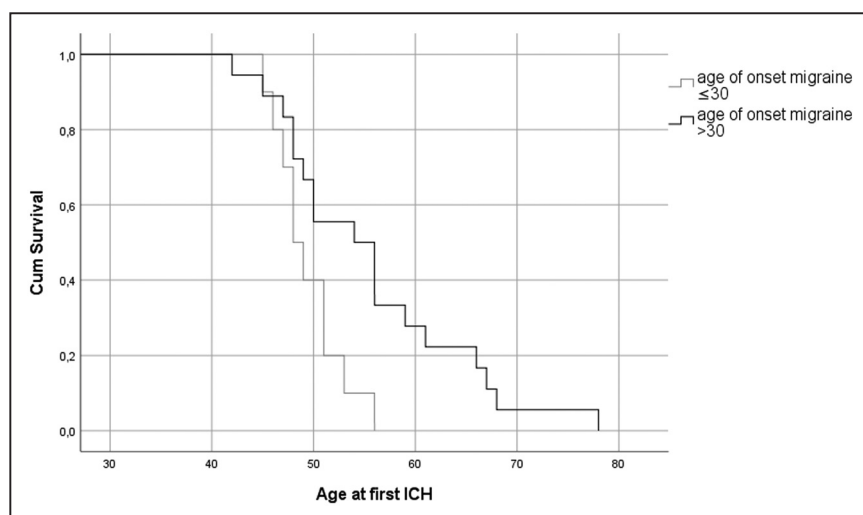


Figure 3. Age at first intracerebral hemorrhage (ICH) for patients with early and late-onset migraine. Early-onset migraine $n=10$, 10 events, late-onset migraine (onset after the age of 30) $n=18$, 18 events. Mean age at first ICH for patients with early-onset migraine 49 y (95% CI, 47–51), for patients with late-onset migraine 56 y (95% CI, 51–60), $P=0.024$ (log-rank test).

investigate the association between migraine and other CAA markers in detail.

Our study shows that migraine with aura may be regarded as an early marker of disease in hereditary CAA. Further prospective studies are needed to confirm our findings, to determine whether migraine with aura is also a frequent symptom in sporadic CAA and to unravel its underlying pathophysiology in relation to small vessel damage.

Sources of Funding

This work was supported by a Clinical Established Investigator grant of the Netherlands Heart Foundation 2016T086 Dr Wermer.

Disclosures

Dr Wermer reports independent support from Nederlandse organisatie voor Wetenschappelijk Onderzoek (NWO) ZonMw (Vidi grant 91717337), the Netherlands Heart Foundation 2016T086, and the Dutch cerebral amyloid angiopathy (CAA) foundation. Dr Terwindt reports independent support from NWO, European Community, the Dutch Heart Foundation, the Dutch Brain Foundation, and the Dutch CAA foundation. The other authors report no conflicts.

References

- Itoh Y, Yamada M, Hayakawa M, Otomo E, Miyatake T. Cerebral amyloid angiopathy: a significant cause of cerebellar as well as lobar cerebral hemorrhage in the elderly. *J Neurol Sci*. 1993;116:135–141. doi: 10.1016/0022-510x(93)90317-r
- Charidimou A, Linn J, Vernooij MW, Opherk C, Akoudad S, Baron JC, et al. Cortical superficial siderosis: detection and clinical significance in cerebral amyloid angiopathy and related conditions. *Brain*. 2015;138(pt 8):2126–2139. doi: 10.1093/brain/awv162
- Headache classification committee of the International Headache Society (IHS) the international classification of headache disorders, 3rd edition. *Cephalalgia*. 2018;38:1–211. doi: 10.1177/0333102417738202
- Bigal ME, Kurth T, Santanello N, Buse D, Golden W, Robbins M, et al. Migraine and cardiovascular disease: a population-based study. *Neurology*. 2010;74:628–635. doi: 10.1212/WNL.0b013e3181d0cc8b
- Schürks M, Rist PM, Bigal ME, Buring JE, Lipton RB, Kurth T. Migraine and cardiovascular disease: systematic review and meta-analysis. *BMJ*. 2009;339:b3914. doi: 10.1136/bmj.b3914
- Burkett JG, Dougherty C. Recognizing CADASIL: a secondary cause of migraine with aura. *Curr Pain Headache Rep*. 2017;21:21. doi: 10.1007/s11916-017-0621-0
- Guey S, Mawet J, Hervé D, Duering M, Godin O, Jouvent E, et al. Prevalence and characteristics of migraine in CADASIL. *Cephalalgia*. 2016;36:1038–1047. doi: 10.1177/0333102415620909
- Stam AH, Kothari PH, Shaikh A, Gschwendter A, Jen JC, Hodgkinson S, et al. Retinal vasculopathy with cerebral leukoencephalopathy and systemic manifestations. *Brain*. 2016;139:2909–2922. doi: 10.1093/brain/aww217
- Samanci B, Coban O, Baykan B. Late onset aura may herald cerebral amyloid angiopathy: a case report. *Cephalalgia*. 2016;36:998–1001. doi: 10.1177/0333102415620253
- Maat-Schieman ML, van Duinen SG, Bornebroek M, Haan J, Roos RA. Hereditary cerebral hemorrhage with amyloidosis-Dutch type (HCHWA-D): II—a review of histopathological aspects. *Brain Pathol*. 1996;6:115–120. doi: 10.1111/j.1750-3639.1996.tb00794.x
- Zhang-Nunes SX, Maat-Schieman ML, van Duinen SG, Roos RA, Frosch MP, Greenberg SM. The cerebral beta-amyloid angiopathies: hereditary and sporadic. *Brain Pathol*. 2006;16:30–39. doi: 10.1111/j.1750-3639.2006.tb00559.x
- Bornebroek M, Haan J, Maat-Schieman ML, Van Duinen SG, Roos RA. Hereditary cerebral hemorrhage with amyloidosis-Dutch type (HCHWA-D): I—a review of clinical, radiologic and genetic aspects. *Brain Pathol*. 1996;6:111–114. doi: 10.1111/j.1750-3639.1996.tb00793.x
- van Etten ES, Verbeek MM, van der Grond J, Zielman R, van Rooden S, van Zwet EW, et al. β -Amyloid in CSF: biomarker for preclinical cerebral amyloid angiopathy. *Neurology*. 2017;88:169–176. doi: 10.1212/WNL.0000000000003486
- Linn J, Halpin A, Demaerel P, Ruhland J, Giese AD, Dichgans M, et al. Prevalence of superficial siderosis in patients with cerebral amyloid angiopathy. *Neurology*. 2010;74:1346–1350. doi: 10.1212/WNL.0b013e3181dad605
- Wardlaw JM, Smith EE, Biessels GJ, Cordonnier C, Fazekas F, Frayne R, et al; STRIVE v1. Neuroimaging standards for research into small vessel disease and its contribution to ageing and neurodegeneration. *Lancet Neurol*. 2013;12:822–838. doi: 10.1016/S1474-4422(13)70124-8
- Makela M, Paetau A, Polvikoski T, Myllykangas L, Tanskanen M. Capillary Amyloid-beta protein deposition in a population-based Study (Vantaa 85+). *J Alzheimers Dis*. 2015;49:149–157. doi: 10.3233/JAD-150241
- Charidimou A, Boulouis G, Roongpiboonsopit D, Auriel E, Pasi M, Haley K, et al. Cortical superficial siderosis multifocality in cerebral amyloid angiopathy: a prospective study. *Neurology*. 2017;89:2128–2135. doi: 10.1212/WNL.0000000000004665
- Landis JR, Koch GG. The measurement of observer agreement for categorical data. *Biometrics*. 1977;33:159–174.
- Vahedi K, Chabriat H, Levy C, Joutel A, Tournier-Lasserre E, Bousser MG. Migraine with aura and brain magnetic resonance imaging abnormalities in patients with CADASIL. *Arch Neurol*. 2004;61:1237–1240. doi: 10.1001/archneur.61.8.1237
- Launer LJ, Terwindt GM, Ferrari MD. The prevalence and characteristics of migraine in a population-based cohort: the GEM study. *Neurology*. 1999;53:537–542. doi: 10.1212/wnl.53.3.537
- Lipton RB, Stewart WF, Diamond S, Diamond ML, Reed M. Prevalence and burden of migraine in the United States: data from the American Migraine Study II. *Headache*. 2001;41:646–657. doi: 10.1046/j.1526-4610.2001.041007646.x
- Stovner LJ, Zwart JA, Hagen K, Terwindt GM, Pascual J. Epidemiology of headache in Europe. *Eur J Neurol*. 2006;13:333–345. doi: 10.1111/j.1468-1331.2006.01184.x
- Viana M, Sances G, Linde M, Nappi G, Khaliq F, Goadsby PJ, et al. Prolonged migraine aura: new insights from a prospective diary-aided study. *J Headache Pain*. 2018;19:77. doi: 10.1186/s10194-018-0910-y
- Pelzer N, Louter MA, van Zwet EW, Nyholt DR, Ferrari MD, van den Maagdenberg AM, et al. Linking migraine frequency with family history of migraine. *Cephalalgia*. 2019;39:229–236. doi: 10.1177/0333102418783295
- Coates R, Bell SM, Coley S, Blackburn DJ. Cerebral amyloid angiopathy: amyloid spells and cortical superficial siderosis. *Pract Neurol*. 2015;15:124–126. doi: 10.1136/practneurol-2014-000952
- Charidimou A, Law R, Werring DJ. Amyloid “spells” trouble. *Lancet*. 2012;380:1620. doi: 10.1016/S0140-6736(12)61333-6
- Greenberg SM, Vonsattel JP, Stakes JW, Gruber M, Finklestein SP. The clinical spectrum of cerebral amyloid angiopathy: presentations without lobar hemorrhage. *Neurology*. 1993;43:2073–2079. doi: 10.1212/wnl.43.10.2073
- Charidimou A, Peeters A, Fox Z, Gregoire SM, Vandermeeren Y, Laloux P, et al. Spectrum of transient focal neurological episodes in cerebral amyloid angiopathy: multicentre magnetic resonance imaging cohort study and meta-analysis. *Stroke*. 2012;43:2324–2330. doi: 10.1161/STROKEAHA.112.657759
- Ferrari MD, Klever RR, Terwindt GM, Ayata C, van den Maagdenberg AM. Migraine pathophysiology: lessons from mouse models and human genetics. *Lancet Neurol*. 2015;14:65–80. doi: 10.1016/S1474-4422(14)70220-0
- Quintana S, Genovese A, Rausa F, Manzoni GC, Torelli P. Migraine with typical aura: clinical features and their relationship with sex and age of onset. Results from the analysis of a large case series. *Neurol Sci*. 2018;39(suppl 1):135–136. doi: 10.1007/s10072-018-3370-x
- Eikermann-Haerter K, Yuzawa I, Dilekoz E, Joutel A, Moskowitz MA, Ayata C. Cerebral autosomal dominant arteriopathy with subcortical infarcts and leukoencephalopathy syndrome mutations increase susceptibility to spreading depression. *Ann Neurol*. 2011;69:413–418. doi: 10.1002/ana.22281