



**Universiteit
Leiden**
The Netherlands

Safety of using the combination of the Wells rule and D-dimer test for excluding acute recurrent ipsilateral deep vein thrombosis

Dam, L.F. van; Gautam, G.; Dronkers, C.E.A.; Ghanima, W.; Gleditsch, J.; Heijne, A. von; ... ; Klok, F.A.

Citation

Dam, L. F. van, Gautam, G., Dronkers, C. E. A., Ghanima, W., Gleditsch, J., Heijne, A. von, ... Klok, F. A. (2020). Safety of using the combination of the Wells rule and D-dimer test for excluding acute recurrent ipsilateral deep vein thrombosis. *Journal Of Thrombosis And Haemostasis*, 18(9), 2341-2348. doi:10.1111/jth.14986

Version: Publisher's Version


License: [Creative Commons CC BY-NC-ND 4.0 license](#)

Downloaded from: <https://hdl.handle.net/1887/3184312>

Note: To cite this publication please use the final published version (if applicable).

ORIGINAL ARTICLE

Safety of using the combination of the Wells rule and D-dimer test for excluding acute recurrent ipsilateral deep vein thrombosis

Lisette F. van Dam¹ | Gargi Gautam² | Charlotte E. A. Dronkers^{1,3} | Waleed Ghanima^{4,5} | Jostein Gleditsch⁶ | Anders von Heijne² | Herman M. A. Hofstee³ | Marcel M. C. Hovens⁷ | Menno V. Huisman¹ | Stan Kolman⁸ | Albert T. A. Mairuhu⁹ | Mathilde Nijkeuter¹⁰ | Marcel A. van de Ree⁸ | Cornelis J. van Rooden¹¹ | Robin E. Westerbeek¹² | Jan Westerink¹⁰ | Eli Westerlund² | Lucia J. M. Kroft¹³ | Frederikus A. Klok¹ 

¹Department of Thrombosis and Hemostasis, Leiden University Medical Center, Leiden, the Netherlands

²Department of Clinical Sciences, Karolinska Institute, Danderyd Hospital, Stockholm, Sweden

³Department of Internal Medicine, Haaglanden Medical Center, The Hague, the Netherlands

⁴Department of Internal Medicine, Østfold Hospital Trust, Østfold, Norway

⁵Department of Haematology, Institute of Clinical Medicine, University of Oslo, Oslo, Norway

⁶Department of Radiology, Østfold Hospital Trust, Østfold, Norway

⁷Department of Internal Medicine, Rijnstate Hospital, Arnhem, the Netherlands

⁸Department of Vascular Medicine, Diaconessenhuis, Utrecht, the Netherlands

⁹Department of Internal Medicine, Haga Teaching Hospital, The Hague, the Netherlands

¹⁰Department of Vascular Medicine, University Medical Center Utrecht, Utrecht, the Netherlands

¹¹Department of Radiology, Haga Teaching Hospital, The Hague, the Netherlands

¹²Department of Radiology, Deventer

Abstract

Background: The diagnostic accuracy of clinical probability assessment and D-dimer testing for clinically suspected recurrent deep vein thrombosis (DVT) is largely unknown.

Aim: To evaluate the safety of ruling out acute recurrent DVT based on an unlikely Wells score for DVT and a normal D-dimer test.

Methods: This was a predefined endpoint of the Theia study in which the diagnostic accuracy of magnetic resonance direct thrombus imaging in acute recurrent ipsilateral DVT was validated. The Wells rule and D-dimer test, performed as part of the study protocol, were not used for management decisions. The primary outcome of this analysis was the incidence of recurrent DVT at baseline or during 3-month follow-up for patients with an unlikely Wells score and a normal D-dimer test.

Results: Results of both Wells score and D-dimer tests were available in 231 patients without anticoagulant treatment. The recurrent DVT prevalence was 45% (103/231). Forty-nine patients had an unlikely Wells score and normal D-dimer test, of whom 3 (6.1%, 95% confidence interval [CI] 1.3%–18%) had recurrent DVT at baseline/follow-up, yielding a sensitivity of 97% (95% CI 92%–99%) and specificity of 36% (95% CI 28%–45%). Thus, if clinical probability scoring and D-dimer testing would have been applied, radiological imaging could have been omitted in 21% of patients with a diagnostic failure rate of 6.1%.

Manuscript handled by: Sabine Eichinger

Final decision: Sabine Eichinger, 16 June 2020

This is an open access article under the terms of the Creative Commons Attribution-NonCommercial-NoDerivs License, which permits use and distribution in any medium, provided the original work is properly cited, the use is non-commercial and no modifications or adaptations are made.

© 2020 The Authors. *Journal of Thrombosis and Haemostasis* published by Wiley Periodicals LLC on behalf of International Society on Thrombosis and Haemostasis

Hospital, Deventer, the Netherlands

¹³Department of Radiology, Leiden University Medical Center, Leiden, the Netherlands

Correspondence

Lisette F. van Dam, Department of Thrombosis and Hemostasis, Leiden University Medical Center, Leiden, the Netherlands; Albinusdreef 2, 2300RC, Leiden, the Netherlands.
Email: L.F.van_Dam@LUMC.nl

Funding information

Dutch Thrombosis Foundation, Grant/Award Number: 2013-01; Bristol-Myers Squibb/Pfizer, Grant/Award Number: CV185-390

Conclusion: By applying clinical probability scoring and D-dimer testing, radiological imaging could be spared in one fifth of patients with suspected recurrent ipsilateral DVT. However, the high failure rate does not support implementation of this strategy in daily practice.

KEYWORDS

clinical decision making, deep vein thrombosis, diagnosis, diagnostic imaging, recurrent

1 | INTRODUCTION

The diagnosis of suspected recurrent deep vein thrombosis (DVT) can be challenging, because there are critical limitations to current diagnostic techniques.¹⁻³ Diagnostic algorithms incorporating the combination of a clinical decision rule (CDR) and D-dimer tests prior to imaging tests have proved to be useful and safe in a first episode of suspected DVT of the leg. However, the diagnostic performance of these algorithms has not been evaluated in large cohorts of patients with suspected recurrent DVT.^{1,2,4} Additionally, due to chronic thrombosis persisting in up to 50% of patients despite adequate anticoagulant treatment, conventional diagnostic imaging tests such as compression ultrasound (CUS) and computed tomography venography are often non-diagnostic in the setting of suspected recurrent ipsilateral DVT. As a result, recurrent DVT cannot be excluded in up to 30% of patients.^{2,5,6}

Magnetic resonance direct thrombus imaging (MRDTI), a non-contrast-enhanced magnetic resonance imaging (MRI) technique, has been shown to accurately distinguish acute recurrent DVT from chronic residual thrombosis.⁷⁻¹⁰ In a recent prospective outcome study (the Theia study), MRDTI was proven to be an accurate, simple, feasible, and reproducible diagnostic test for ruling out acute recurrent ipsilateral DVT.¹¹ Considering both the limited availability and associated costs of MRI and the poor performance of CUS in suspected recurrent ipsilateral DVT, a safe and efficient diagnostic algorithm to reduce the need of diagnostic imaging is an unmet clinical need. We therefore set out to evaluate the diagnostic accuracy of the combination of the Wells rule for DVT and D-dimer measurement for suspected recurrent ipsilateral DVT.

2 | METHODS

2.1 | Study population

In this analysis, we report on a predefined secondary endpoint of the Theia study (NCT02262052). The full details of the study

Essentials

- The diagnostic management of recurrent deep vein thrombosis (DVT) is challenging.
- We studied the diagnostic accuracy of the Wells rule and D-dimer test in suspected recurrent DVT.
- The Wells rule combined with a D-dimer test had a failure rate of 6.1% (95% confidence interval 1.3%-18%).
- Our findings do not support routinely use of the Wells rule and D-dimer test in this setting.

design and results have been published previously.¹¹ In summary, 305 consecutive adult patients with suspected recurrent ipsilateral DVT were managed according the Theia study algorithm with MRDTI as standalone test to guide therapeutic management (Figure 1). The main exclusion criteria were DVT diagnosed by CUS < 6 months before presentation, symptom duration of >10 days, suspected concomitant acute pulmonary embolism, and general contraindications for MRI.¹¹ Patients treated with full-dose anticoagulation initiated \geq 48 hours before eligibility assessment were initially excluded, but allowed later on as they represented a high proportion of the screened population (30%) in the first year after study initiation. According to the Theia study algorithm, patients with a MRDTI negative for DVT were subjected to a standardized CUS examination within 48 hours after the MRDTI; this CUS served as a reference test in case a patient returned with symptoms of DVT recurrence during the follow-up period. However, the management decision was based on the MRDTI results only. Assessment of the Wells rule and measurement of D-dimer was performed in all patients. All study patients received a 3-month follow-up for the outcome of recurrent venous thromboembolism (VTE), anticoagulation-associated major bleeding and all-cause mortality. Finally, all endpoints were adjudicated by an independent committee. For the current analysis, patients

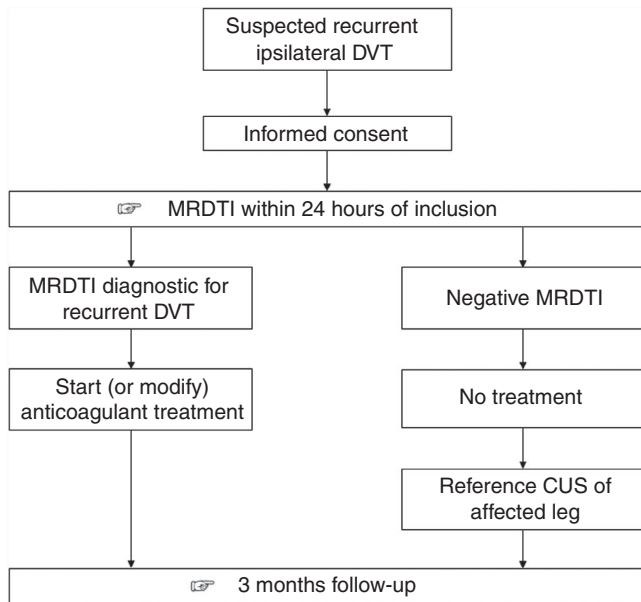


FIGURE 1 The Theia study flowchart in patients with clinically suspected acute recurrent ipsilateral DVT.¹¹ CUS, compression ultrasound; DVT, deep vein thrombosis; MRDTI, magnetic resonance direct thrombus imaging

with unavailable Wells rule scores and/or D-dimer levels were excluded.

2.2 | Wells rule and D-dimer

CDR assessment included both the original and modified Wells rule for DVT, because previous studies have suggested that the modified Wells rule may be more sensitive for recurrent DVT than the original rule.¹² D-dimer levels were measured with an automated, well-validated, high-sensitivity, quantitative D-dimer assay in accordance with local guidelines (STA-Liatest, Diagnostica Stago; Tina-quant, Roche Diagnostics; Innovance, Siemens).

2.3 | Primary and secondary aims

The primary aim of this analysis was to evaluate the safety of ruling out acute recurrent (ipsilateral) DVT among patients without anticoagulant treatment. The incidence of recurrent DVT was evaluated in patients with an unlikely ruling according to the original and modified Wells rule separately, in combination with a normal D-dimer test result at baseline. The incidence of recurrent DVT included both recurrent DVT diagnosed at baseline by a MRDTI positive for DVT as well as recurrent VTE during the 3-month follow-up period in patients with a MRDTI negative for DVT.

Secondary aims were twofold: (a) to evaluate the safety of ruling out acute recurrent DVT based on an unlikely CDR, according the Wells rule and modified Wells rule separately, in combination with a normal D-dimer test in patients who were on anticoagulant treatment at inclusion; and (b) to estimate the number of “spared” diagnostic

TABLE 1 Clinical decision rule according the original and modified Wells rule for deep vein thrombosis (DVT)

Clinical characteristics	Score
Active cancer (Treatment or palliation within 6 months)	1
Bedridden recently > 3 days or major surgery within 12 weeks	1
Calf swelling > 3 cm compared to the other leg	1
Collateral (non-varicose) superficial veins present	1
Entire leg swollen	1
Localized tenderness along the deep venous system	1
Pitting edema, confined to symptomatic	1
Paralysis, paresis or recent plaster immobilization of the lower extremity	1
Previously documented DVT ^a	1
Alternative diagnosis of DVT as likely or more likely	-2

Note: Cut-off points for both original and modified Wells rule: unlikely clinical probability (0-1 point), likely clinical probability (≥ 2 points).

^aCriterion added for the modified Wells rule.

imaging tests (MRDTI and/or CUS) when the original or modified Wells rule and D-dimer test would be applied before imaging tests.

2.4 | Definitions

An unlikely CDR according the Wells rule was defined as a score of <2 points as described in Table 1. In the modified Wells rule one extra point is given to patients with a history of DVT. An abnormal D-dimer test was defined as abnormal according to the assay-dependent threshold, which differed between the different assays used in the study.

We considered different classifications of CUS results: normal/abnormal and positive/negative/inconclusive, reflecting clinical practice for which the presence of a reference CUS is varied. A normal CUS was defined as full compressibility along the venous system. An abnormal CUS was defined as one or more non-compressible venous segments. A positive CUS was defined as a new non-compressible segment or a ≥ 2 -4 mm increase in vein diameter of a previously non-compressible venous segment when compared to a prior reference CUS of the leg.^{2,13} A negative CUS was defined as the absence of any non-compressible segments or the absence of a new non-compressible segment in comparison with a prior reference CUS and a <2 mm increase in vein diameter of a previous non-compressible venous segment. An inconclusive CUS was defined as a non-compressible vein segment in the absence of a prior reference CUS for comparison.

A MRDTI positive for acute recurrent DVT was defined as a high signal intensity in the location of a deep venous segment against the suppressed background greater than that observed in the contiguous segments or corresponding ipsilateral vein. Pulmonary embolism was considered to be present if computed

tomography pulmonary angiography showed at least one filling defect in the pulmonary artery tree and if pulmonary embolism was judged to be a probable cause of unexplained death unless proven otherwise by autopsy.

2.5 | Statistical analysis

Baseline characteristics are described as mean with standard deviation (SD) or median with interquartile range (IQR). The primary outcome was calculated with corresponding exact 95% confidence interval (95% CI). Also, the sensitivity, specificity, positive predictive value (PPV), and negative predictive value (NPV) with corresponding 95% CI of a combination of an unlikely CDR and a normal D-dimer test were calculated. The reference standard for a correct negative ruling by the CDR and the D-dimer test was a negative MRDTI for DVT at baseline and an uneventful 3-month follow-up period. We defined the sensitivity to be adequate if its point estimate would exceed 96%, which was the upper limit of the 95% CI of the sensitivity of D-dimer testing for recurrent DVT in a large multicenter management trial.¹⁴

For the secondary outcome, we repeated the analysis of the primary outcome in patients on anticoagulant treatment at baseline. Next, we evaluated the effect of applying the combination of CDR assessment and D-dimer measurement to the diagnostic work-up of suspected recurrent DVT on the number of required diagnostic imaging tests to three diagnostic algorithms including imaging with MRDTI and/or CUS. Scenario 1-3 included diagnostic algorithms

consisting only of imaging tests. In the first scenario, MRDTI would have been performed in all patients (as was performed in the Theia study population). In the second scenario, all patients with suspected recurrent ipsilateral DVT would have been referred for CUS with MRDTI only to be performed in case of an abnormal CUS. In the third scenario, the same diagnostic algorithm was used, but MRDTI would have been restricted to patients with an inconclusive CUS. In scenario 4-6 the original and modified Wells rule in combination with D-dimer testing was added as initial step of scenarios 1-3 (Figure 2). The difference in the number of required imaging tests between the scenarios was calculated. All analyses were performed with the use of SPSS software, version 25.0.

3 | RESULTS

3.1 | Study population

The Wells rule was calculated in all 305 Theia study patients, of whom 163 (53%) had an unlikely CDR. In 10 patients who had an unlikely CDR according the original Wells rule, D-dimer results were unavailable for unknown reasons. These 10 patients were excluded in this analysis, leaving 295 patients of whom 64 patients (22%) were on anticoagulant treatment \geq 48 hours at study inclusion. The baseline characteristics of the included patients in this analysis are shown in Table 2. The recurrent DVT prevalence was 45% (103/231; 95% CI 36%-54%) in patients without anticoagulant treatment and 22% (14/64; 95% CI 12%-37%) in patients with anticoagulant treatment.

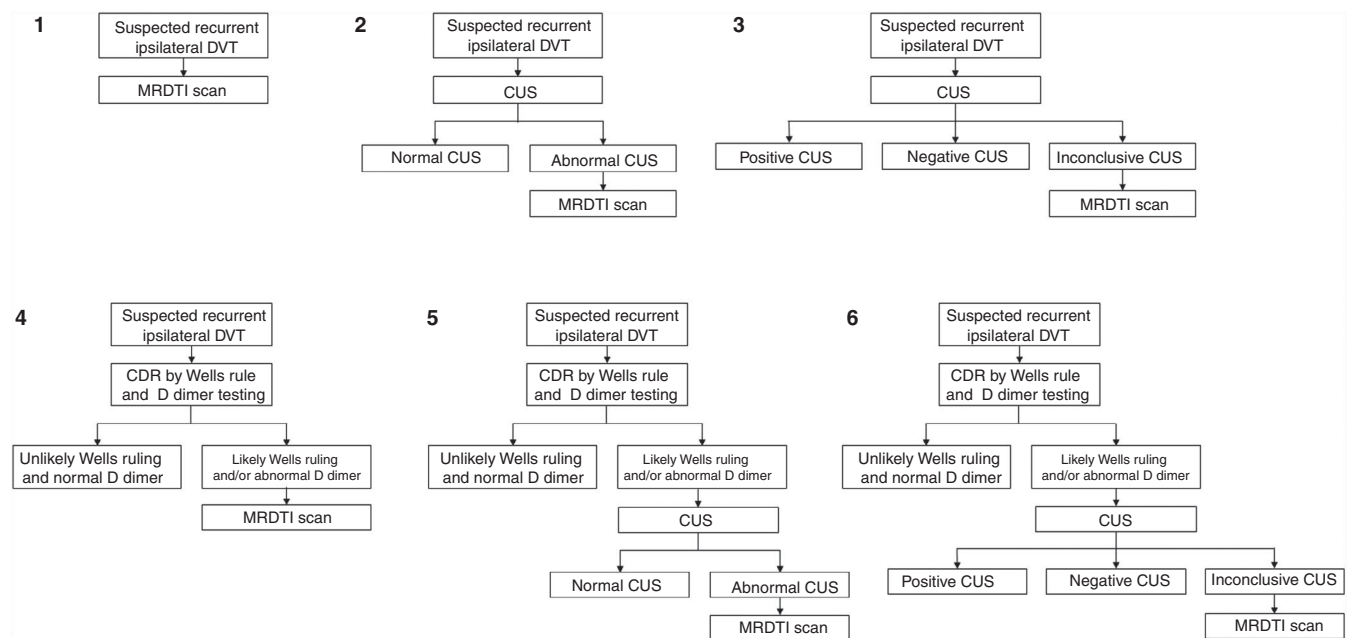


FIGURE 2 Six hypothetical scenarios for the diagnostic management of suspected recurrent ipsilateral deep vein thrombosis (DVT), including a clinical decision rule (CDR) according the Wells rule for DVT, D-dimer testing and diagnostic imaging with compression ultrasound (CUS), and magnetic resonance direct thrombus imaging (MRDTI)

TABLE 2 Baseline characteristics of 295 patients with suspected recurrent ipsilateral DVT of the leg and with results of clinical probability assessment and D-dimer testing available

	Patients without anticoagulant treatment at baseline (n = 231)	Patients treated with anticoagulant treatment at baseline (n = 64)
Mean age (\pm SD) – years	56 (16)	56 (17)
Male – no (%)	109 (53)	38 (59)
Median duration of complaints (IQR) – days	4 (2-7)	4 (2-7)
More than 1 prior VTE episode – no (%)	50 (22)	44 (69)
Mean time since the last DVT episode (\pm SD) – years	6.9 (9.2)	4.6 (7.5)
Active malignancy – no (%)	10 (4.3)	8 (13)
Immobility for > 3 days or recent long travel > 6 hours in the past 4 weeks – no (%)	15 (6.5)	6 (9.4)
Trauma/surgery during the past 4 weeks – no (%)	9 (3.9)	2 (3.1)
Hormone (replacement) therapy – no (%)	5 (2.2)	1 (1.6)
Known genetic thrombophilia – no (%)	18 (7.8)	21 (33)

Abbreviations: DVT, deep vein thrombosis; IQR, interquartile range; no, number of patients; SD, standard deviation; VTE, venous thromboembolism.

3.2 | Primary outcome

Among the 231 patients who were not treated with anticoagulants, 119 patients (52%) had an unlikely CDR according to the original Wells rule, 66 patients (29%) had a normal D-dimer test, and 49 patients (21%) had a combination of an unlikely CDR and a normal D-dimer test. All results of the combination of CDR assessment and D-dimer testing are presented in Appendix S1 in supporting information. Three of 49 patients (6.1%; 95% CI 1.3%-18%) with an unlikely original Wells score and a normal D-dimer test had recurrent DVT at baseline or during 3-month follow-up (Table 3). The combination of the original Wells rule and D-dimer test yielded a sensitivity of 97% (95% CI 92%-99%) and specificity of 36% (95% CI 28%-45%).

When using the modified Wells rule in combination with D-dimer testing, 3 of the 28 patients (11%; 95% CI 2.2%-31%) with an unlikely CDR and a normal D-dimer test had recurrent DVT at baseline or during 3-month follow-up. The sensitivity was 97% (95% CI 92%-99%) and the specificity was 20% (95% CI 14%-27%).

3.3 | Secondary outcomes

The incidence of recurrent DVT in patients treated with anticoagulants at baseline who had an unlikely probability according to the original Wells rule in combination with a normal D-dimer test was 2 of 30 patients (6.7%; 95% CI 0.81%-24%; Table 3). The sensitivity and specificity of the combination of an unlikely probability by

the original Wells rule and a normal D-dimer test for acute recurrent DVT were 86% (95% CI 60%-96%) and 56% (95% CI 42%-69%), respectively. When applying the modified Wells rule, the sensitivity was 93% (95% CI 69%-99%) and the specificity was 32% (95% CI 21%-46%).

The number of required diagnostic imaging tests in the different scenarios for the diagnostic work-up of suspected recurrent DVT are shown in Table 4. Depending on the diagnostic scenario, CUS was needed in 71%-100% of patients and MRDTI in 33%-100% of patients. When CDR assessment in combination with D-dimer testing was applied before diagnostic imaging, CUS was needed in 71%-83% of patients and MRDTI in 33%-83% of patients.

4 | DISCUSSION

In this predefined analysis of the Theia study, we demonstrated that the combination of an unlikely CDR with a normal D-dimer test yielded a sensitivity of 97% (95% CI 92%-99%) and a specificity of 36% (95% CI 28%-45%) for recurrent ipsilateral DVT. Even though the predefined threshold for “adequate” sensitivity was met, a failure rate of 6.1% (95% CI 1.3%-18%) was observed.

Our results are in line with a patient-level meta-analysis, in which it was concluded that an unlikely CDR by the original Wells rule combined with a normal D-dimer was not safe for excluding recurrent DVT (failure rate of 2.5%; 95% CI 1.2%-5.4%) in 941 patients with a history of DVT.¹²

TABLE 3 Overview of patients with confirmed recurrent DVT but unlikely clinical probability and normal D-dimer test at baseline

	Sex	Age (years)	Wells rule (points)	Modified Wells rule (points)	D-dimer concentration	Reference level D-dimer assay	MRDTI result	Outcome
Patients without anticoagulant treatment at baseline:								
Patient 1	Female	25	0	1	<220 ng/mL	<500 ng/mL	Negative	PE at baseline, diagnosed by CTPA
Patient 2	Female	33	0	1	<220 ng/mL	<500 ng/mL	Negative	Proximal recurrent ipsilateral DVT at 22 d of follow-up after immobilization during a long-haul flight; D-dimer elevated (3291 ng/mL)
Patient 3	Female	50	0	1	<220 ng/mL	<500 ng/mL	Positive	DVT at baseline
Patients treated with anticoagulants at baseline:								
Patient 1	Female	52	0	1	<220 ng/mL	<500 ng/mL	Positive	DVT at baseline
Patient 2	Male	66	1	2	<250 ng/mL	250 mg/L	Positive	DVT at baseline

Abbreviations: CTPA, computed tomography pulmonary angiogram; DVT, deep vein thrombosis; PE, pulmonary embolism; VTE, venous thromboembolism.

TABLE 4 Required diagnostic imaging tests (compression ultrasonography [CUS] and/or magnetic resonance direct thrombus imaging [MRDTI]) in the different hypothetical diagnostic scenarios for the diagnostic management of suspected recurrent ipsilateral deep vein thrombosis

Scenario	Wells rule + D-dimer test	CUS	MRDTI	Modified Wells rule + D-dimer test	CUS	MRDTI
Patients without anticoagulant treatment at baseline:						
1	—	—	100%	—	—	100%
2	—	100%	52%	—	100%	52%
3	—	100%	40%	—	100%	40%
4	100%	—	71%	100%	—	83%
5	100%	71%	39%	100%	83%	44%
6	100%	71%	33%	100%	83%	36%
Patients treated with anticoagulants at baseline:						
1	—	—	100%	—	—	100%
2	—	100%	54%	—	100%	54%
3	—	100%	42%	—	100%	42%

The modified Wells rule was created to improve the diagnostic performance of the original Wells rule.¹² However, applying the modified Wells rule to our cohort led to an even higher failure rate of 11% (95% CI 2.2%-31%), mainly because fewer patients were categorized as having an unlikely CDR. These results are in contrast with the above-mentioned meta-analysis, in which the modified Wells rule was associated with an adequately low failure rate of 1.0% (95% CI 0.6%-1.6%).¹² Importantly, the lower 24% recurrent DVT prevalence in this meta-analysis¹² needs to be taken into account when comparing the results with our study (prevalence of 45%). As the failure rate is dependent on the disease prevalence in a population or cohort, the Scientific and Standardization Committee of the International Society on Thrombosis and Haemostasis (ISTH) has suggested a DVT prevalence-dependent

diagnostic safety threshold.^{15,16} The estimated sensitivity of the modified Wells rule in combination with D-dimer testing in the aforementioned meta-analysis was 99%,¹² compared to a sensitivity of 97% in our study cohort. Therefore, our study results are in line with previous literature and place this sensitivity in the context of a large cohort consisting exclusively of patients with suspected recurrent ipsilateral DVT.

It must also be taken into account that for the estimation of the failure rate of an unlikely CDR in combination with a normal D-dimer test, we calculated the incidence of recurrent DVT at baseline and that of recurrent VTE during 3 months of follow-up after a MRDTI negative for DVT. Although it is possible that a recurrent DVT during follow-up was provoked by a newly emerged risk factor (eg, immobilization or surgery), the chosen reference standard

was in accordance with current guidelines in which it is stated that the standard against which all DVT diagnostic management studies should be evaluated is the percentage of patients with VTE during 3 months of follow-up despite a normal venography finding.¹⁷

There are limited data on the utility of D-dimer testing in patients with suspected recurrent DVT while on anticoagulant treatment.¹⁷ It was previously shown that the D-dimer concentration decreases during anticoagulant therapy, which leads to a decrease in sensitivity from 96% to 89%.¹⁸ This was confirmed in our analysis: the sensitivity of the Wells rule/D-dimer combination decreased from 97% to 86% in patients on anticoagulant therapy.

Strengths of the study are the prospective design, the large sample size, the accurate follow-up of the included patients, as well as the adjudication of the endpoints by an independent committee. Also, the study included university and non-university hospitals from several European countries, and different quantitative D-dimer assays were used, all contributing to the external validity of our findings. The main limitation of this analysis is that patients were not managed according to the results of CDR and D-dimer testing. Also, D-dimer levels were not available for all patients. Due to the limited number of study patients our data should be considered to be hypothesis generating. Future studies with a larger study cohort, including an upfront determined sample size calculation, are needed.

In conclusion, although the sensitivity of the (modified) Wells rule in combination with D-dimer testing was sufficient as predefined in the Theia study protocol, we observed a 6.1% diagnostic failure rate. Importantly, the combination of an unlikely CDR and normal D-dimer test was only present in 21% of patients when using the original Wells rule, and 14% when using the modified Wells rule. Our data do not support routine assessment of CDR and D-dimer in the diagnostic workup of suspected recurrent (ipsilateral) DVT. Based on the results of our analysis we suggest imaging in all patients with suspected recurrent (ipsilateral) DVT starting with CUS and a MRDTI scan in patients with an abnormal or inconclusive CUS result.

ACKNOWLEDGMENTS

The Theia study was supported by an unrestricted grant from BMS/Pfizer (CV185-390). Dr Klok and Dr Dronkers are supported by the Dutch Thrombosis Foundation (2013-01). INVENT-VTE (International Network of Venous Thromboembolism Clinical Research Networks) and Dutch Thrombosis Network (DTN) endorsed and supported the Theia study.

CONFLICTS OF INTEREST

We declare no competing interests.

AUTHOR CONTRIBUTIONS

LFvD and FAK had full access to all data in the study and take responsibility for the integrity of the data and the accuracy of the data analysis. Acquisition of the data: LFvD, GG, CEAD, WG, JG, AvH, HMAH, MMCH, MVH, SK, ATAM, MN, MAVdR, CJvR, REW, JW, EW, LJMK, and FAK. Analysis and interpretation of

the data: LFvD, CEAD, GG, EW, and FAK. Drafting of the manuscript: LFvD, GG, FAK. Critical revision of the manuscript: LFvD, GG, CEAD, WG, JG, AvH, HMAH, MMCH, MVH, SK, ATAM, MN, MAVdR, CJvR, REW, JW, EW, LJMK, and FAK. Final approval of the manuscript: LFvD, GG, CEAD, WG, JG, AvH, HMAH, MMCH, MVH, SK, ATAM, MN, MAVdR, CJvR, REW, JW, EW, LJMK, and FAK.

ORCID

Frederikus A. Klok  <https://orcid.org/0000-0001-9961-0754>

REFERENCES

- Bates SM, Jaeschke R, Stevens SM, et al. Diagnosis of DVT: anti-thrombotic therapy and prevention of thrombosis, 9th ed: American college of chest physicians evidence-based clinical practice guidelines. *Chest*. 2012;141(2):e351S-e418S.
- Barco S, Konstantinides S, Huisman MV, Klok FA. Diagnosis of recurrent venous thromboembolism. *Thromb Res*. 2018;163:229-235.
- Huisman MV, Klok FA. Diagnostic management of acute deep vein thrombosis and pulmonary embolism. *J Thromb Haemost*. 2013;11(3):412-422.
- Tan M, van Rooden CJ, Westerbeek RE, Huisman MV. Diagnostic management of clinically suspected acute deep vein thrombosis. *Br J Haematol*. 2009;146(4):347-360.
- Tan M, Velthuis SI, Westerbeek RE, Van rooden CJ, Van der meer FJM, Huisman MV. High percentage of non-diagnostic compression ultrasonography results and the diagnosis of ipsilateral recurrent proximal deep vein thrombosis. *J Thromb Haemost*. 2010;8(4):848-850.
- Piovello F, Crippa L, Barone M, et al. Normalization rates of compression ultrasonography in patients with a first episode of deep vein thrombosis of the lower limbs: association with recurrence and new thrombosis. *Haematologica*. 2002;87(5):515-522.
- Tan M, Mol GC, van Rooden CJ, et al. Ability of magnetic resonance direct thrombus imaging (MRDTI) to differentiate acute recurrent ipsilateral deep vein thrombosis from residual thrombosis. *Blood*. 2014;124(4):623-627.
- Fraser DGW, Moody AR, Morgan PS, Martel AL, Davidson I. Diagnosis of lower-limb deep venous thrombosis: a prospective blinded study of magnetic resonance direct thrombus imaging. *Ann Intern Med*. 2002;136(2):89-98.
- Klok FA, Pruefer D, Rolf A, Konstantinides SV. Magnetic resonance direct thrombus imaging for pre-operative assessment of acute thrombosis in chronic thromboembolic pulmonary hypertension. *Eur Heart J*. 2019;40(11):944.
- Moody AR. Magnetic resonance direct thrombus imaging. *J Thromb Haemost*. 2003;1(7):1403-1409.
- van Dam LF, Dronkers CEA, Gautam G, et al. Magnetic resonance imaging for diagnosis of recurrent ipsilateral deep vein thrombosis. *Blood*. 2020;135(16):1377-1385.
- Geersing GJ, Zuithoff NP, Kearon C, et al. Exclusion of deep vein thrombosis using the Wells rule in clinically important subgroups: individual patient data meta-analysis. *BMJ*. 2014;348(mar10 3):g1340.
- Le Gal G, Kovacs MJ, Carrier M, et al. Validation of a diagnostic approach to exclude recurrent venous thromboembolism. *J Thromb Haemost*. 2009;7(5):752-759.
- Rathbun SW, Whitsett TL, Raskob GE. Negative D-dimer result to exclude recurrent deep venous thrombosis: a management trial. *Ann Intern Med*. 2004;141(11):839-845.
- Dronkers CEA, Ende-Verhaar YM, Kyrle PA, Righini M, Cannegieter SC, Huisman MV, Klok FA, Subcommittee on P, Diagnostic Variables

- in Thrombotic D. Disease prevalence dependent failure rate in diagnostic management studies on suspected deep vein thrombosis: communication from the SSC of the ISTH. *J Thromb Haemost.* 2017;15(11):2270-2273.
16. Dronkers CEA, van der Hulle T, Le Gal G, et al. Towards a tailored diagnostic standard for future diagnostic studies in pulmonary embolism: communication from the SSC of the ISTH. *J Thromb Haemost.* 2017;15(5):1040-1043.
 17. Lim W, Le Gal G, Bates SM, et al. American Society of Hematology 2018 guidelines for management of venous thromboembolism: diagnosis of venous thromboembolism. *Blood Adv.* 2018;2(22):3226-3256.
 18. Couturaud F, Kearon C, Bates SM, Ginsberg JS. Decrease in sensitivity of D-dimer for acute venous thromboembolism after starting anticoagulant therapy. *Blood Coagul Fibrin.* 2002;13(3):241-246.

SUPPORTING INFORMATION

Additional supporting information may be found online in the Supporting Information section.

How to cite this article: van Dam LF, Gautam G, Dronkers CEA, et al. Safety of using the combination of the Wells rule and D-dimer test for excluding acute recurrent ipsilateral deep vein thrombosis. *J Thromb Haemost.* 2020;18:2341-2348. <https://doi.org/10.1111/jth.14986>