



Universiteit
Leiden
The Netherlands

What range of motion is achieved 5 years after external rotationplasty of the shoulder in infants with an obstetric brachial plexus injury?

Sarac, C.; Amghar, H.; Nieuwenhuijse, M.J.; Nagels, J.; Buitenhuis, S.M.; Wolterbeek, R.; Nelissen, R.G.H.H.

Citation

Sarac, C., Amghar, H., Nieuwenhuijse, M. J., Nagels, J., Buitenhuis, S. M., Wolterbeek, R., & Nelissen, R. G. H. H. (2020). What range of motion is achieved 5 years after external rotationplasty of the shoulder in infants with an obstetric brachial plexus injury? *Clinical Orthopaedics And Related Research*, 478(1), 114-123. doi:10.1097/CORR.0000000000000996

Version: Publisher's Version
License: [Creative Commons CC BY-NC-ND 4.0 license](https://creativecommons.org/licenses/by-nc-nd/4.0/)
Downloaded from: <https://hdl.handle.net/1887/3184170>

Note: To cite this publication please use the final published version (if applicable).

Clinical Research

What Range of Motion is Achieved 5 Years After External Rotationplasty of the Shoulder in Infants with an Obstetric Brachial Plexus Injury?

Cigdem Sarac MD, Hassan Amghar BSc, Marc J. Nieuwenhuijse MD, PhD, Jochem Nagels MD, Sonja M. Buitenhuis PT, Ron Wolterbeek MD, Rob G. H. H. Nelissen MD, PhD

Received: 23 January 2019 / Accepted: 23 September 2019 / Published online: 17 October 2019
Copyright © 2019 by the Association of Bone and Joint Surgeons

Abstract

Background Obstetric brachial plexus injuries result from traction injuries during delivery, and 30% of these children have persisting functional limitations related to an external rotation deficit of the shoulder. Little is known about the long-term effect of soft-tissue procedures of the shoulder in patients with obstetric brachial plexus injuries.

Questions/purposes (1) After soft-tissue release for patients with passive external rotation less than 20° and age younger than 2 years and for patients older than 2 years

with good external rotation strength, what are the improvements in passive external rotation and abduction arcs at 1 and 5 years? (2) For patients who underwent staged tendon transfer after soft-tissue release, what are the improvements in active external rotation and abduction arcs at 1 and 5 years? (3) For patients with passive external rotation less than 20° and no active external rotation, what are the improvements in active external rotation and abduction arcs at 1 and 5 years?

Methods This was a retrospective analysis of a longitudinally maintained institutional database. Between 1996 and 2009, 149 children underwent a soft-tissue procedure of the shoulder for an internal rotation contracture. The inclusion criteria were treatment with an internal contracture release and/or tendon transfer, a maximum age of 18 years at the time of surgery, and a minimum follow-up period of 2 years. Six patients were older than 18 years at the time of surgery and 31 children were seen at our clinic until 1 year postoperatively, but because they had good clinical results and lived far away from our center, these children were discharged to physical therapists in their hometown for annual follow-up. Thus, 112 children (59 boys) were available for analysis. Patients with passive external rotation less than 20° and age younger than 2 years and patients older than 2 years with good external rotation strength received soft-tissue release only (n = 37). Of these patients, 17 children did not have adequate active external rotation, and second-stage tendon transfer surgery was performed. For patients with passive external rotation less than 20° with no active external rotation, single-stage contracture release with tendon transfer was performed (n = 68). When no contracture was present (greater than 20° of external rotation) but the patient had an active deficit

Each author certifies that neither he or she, nor any member of his or her immediate family, has funding or commercial associations (consultancies, stock ownership, equity interest, patent/licensing arrangements, etc.) that might pose a conflict of interest in connection with the submitted article.

All ICMJE Conflict of Interest Forms for authors and *Clinical Orthopaedics and Related Research*® editors and board members are on file with the publication and can be viewed on request.

Each author certifies that his or her institution approved the human protocol for this investigation and that all investigations were conducted in conformity with ethical principles of research.

This work was performed at Leiden University Medical Center, Leiden, the Netherlands.

C. Sarac, H. Amghar, M. J. Nieuwenhuijse, J. Nagels, S. M. Buitenhuis, R. G. H. H. Nelissen, Department of Orthopaedics, Rehabilitation and Physical Therapy, Leiden University Medical Center, Leiden, the Netherlands

R. Wolterbeek, Department of Medical Datasciences, Leiden University Medical Center, Leiden, the Netherlands

C. Sarac (✉), Department of Orthopaedics, Rehabilitation and Physical Therapy, Leiden University Medical Center, Albinusdreef 2, 2333 ZA, Leiden, the Netherlands, Email: cigdemsrc@gmail.com

($n = 7$), tendon transfer alone was performed; this group was not analyzed. A functional assessment of the shoulder was performed preoperatively and postoperatively at 6 weeks, 3 months, and annually thereafter and included abduction, external rotation in adduction and abduction, and the Mallet scale.

Results Internal contracture release resulted in an improvement in passive external rotation in adduction and abduction of 29° (95% confidence interval, 21 to 38; $p < 0.001$) and 17° (95% CI, 10 to 24; $p < 0.001$) at 1 year of follow-up and 25° (95% CI, 15-35; $p < 0.001$) and 15° (95% CI, 7 to 24; $p = 0.001$) at 5 years. Because of insufficient strength of the external rotators after release, 46% of the children (17 of 37) underwent an additional tendon transfer for active external rotation, resulting in an improvement in active external rotation in adduction and abduction at each successive follow-up visit. Patients with staged transfers had improved active function; improvements in active external rotation in adduction and abduction were 49° (95% CI, 28 to 69; $p < 0.05$) and 45° (95% CI, 11 to 79; $p < 0.001$) at 1 year of follow-up and 38° (95% CI, 19 to 58; $p < 0.05$) and 23° (95% CI, -8 to 55; $p < 0.001$) at 5 years. In patients starting with less than 20° of passive external rotation and no active external rotation, after single-stage contracture release and tendon transfer, active ROM was improved. Active external rotation in adduction and abduction were 75° (95% CI, 66 to 84; $p < 0.001$) and 50° (95% CI, 43 to 57; $p < 0.001$) at 1 year of follow-up and 65° (95% CI, 50 to 79; $p < 0.001$) and 40° (95% CI, 28 to 52; $p < 0.001$) at 5 years.

Conclusion Young children with obstetric brachial plexus injuries who have internal rotation contractures may benefit from soft-tissue release. When active external rotation is lacking, soft-tissue release combined with tendon transfer improved active external rotation in this small series. Future studies on the degree of glenohumeral deformities and functional outcome might give more insight into the level of increase in external rotation.

Level of Evidence Level III, therapeutic study.

Introduction

Functional deficits after obstetric brachial plexus injuries depend on the extent of the injury (axonotmesis, neurotmesis, or avulsion) and the extent to which the nerve roots from C5 to T1 are involved. Children with involvement of the upper plexus (C5 and C6 lesions) will have problems with the shoulder, including limited abduction and external rotation [7, 12, 19]. Nonsurgical therapy and micro-neurosurgical therapy may improve upper-extremity function, but as the infant ages, functional deficits and anatomic changes may become permanent or even worsen [6, 8, 11, 18, 20, 21, 26]. Limited external rotation of the

shoulder is a common clinical feature in these infants, and it is an indication for secondary surgery (internal contracture release and/or tendon transfer) [17, 27, 29].

However, the outcome of secondary surgery of the shoulder is rarely reported, and most studies either make no distinction between the different types of surgery or describe only one specific type of secondary surgery, obscuring comparisons within a series [23]. Furthermore, contrary to other studies presenting data at one follow-up time point, the current study presents a series of children with secondary soft-tissue procedures of the shoulder for internal rotation contracture during a 5-year follow-up period.

Therefore, we asked: (1) After soft-tissue release for patients with passive external rotation less than 20° and age younger than 2 years and for patients older than 2 years with good external rotation strength, what are the improvements in passive external rotation and abduction arcs at 1 and 5 years? (2) For patients who underwent staged tendon transfer after soft-tissue release, what are the improvements in active external rotation and abduction arcs at 1 and 5 years? (3) For patients with passive external rotation less than 20° and no active external rotation, what are the improvements in active external rotation and abduction arcs at 1 and 5 years?

Patients and Methods

All children with obstetric brachial plexus injuries who underwent an orthopaedic surgical intervention at our institution have been followed in a longitudinal database since 1995. Between 1996 and 2009, 149 children had a soft-tissue procedure of the shoulder for an internal rotation contracture. The inclusion criteria for the present study were treatment with internal contracture release and/or tendon transfer, a maximum age of 18 years at the time of surgery, and a minimum follow-up period of 2 years. Six patients were older than 18 years at the time of surgery and 31 children were seen at our clinic until 1 year postoperatively but had good clinical results and lived far away from our center; these children were discharged to physical therapists in their hometown for annual follow-up visits (see Appendix, Supplemental Digital Content 1, <http://links.lww.com/CORR/A243>). Thus, 75% of the children (112 of 149; 59 boys) were available for analysis (Table 1). The right shoulder was involved in 66 children. Lesion topography was C5 or C6 (67 children), C5 to C7 (37 children), C5 to C8 (four children), and C5 to T1 (four children). The primary treatment consisted of nerve reconstruction in 70 children and neurolysis of the brachial plexus in eight. The remaining 34 children were initially seen at the nerve injury clinic but had functional recovery of the biceps muscle and were initially treated with physical therapy to prevent joint contracture. Our institutional medical ethics committee

Table 1. Patient characteristics in the different treatment groups

Patient characteristics	Release and tendon transfer		Only tendon transfer n = 7
	Release n = 37	n = 68	
Sex, Male: Female	21:16	36:32	2:5
Affected side, left: right	18:19	26:42	2:5
Mean age \pm standard deviation (years)	3 \pm 2.6	5 \pm 3.4	8 \pm 4.5
Type of lesion			
C5-C6	23	40	4
C5-C7	11	23	3
C5-C8	1	3	
C5-T1	2	2	

approved the prospective follow-up of these patients (study number CME 04/14A).

Surgical Intervention

The selection criterion for surgical intervention, either an internal contracture release or transfer of the latissimus dorsi and teres major, was based on preoperative values of passive and active external rotation (Fig. 1). Two techniques were used: only internal rotation contracture release or internal rotation contracture release combined with tendon transfer in the shoulder.

Children with limited passive external rotation and good function of the active external rotators or those who had a chance of recovery underwent only internal contracture release and used a thorax external rotation plaster postoperatively for 4 weeks. If the external rotators had not recovered after release, an additional tendon transfer was performed at a later stage. After tendon transfer, children wore an external rotation plaster of the thorax for 6 weeks. Since 2001, we have only performed release without tendon transfer in children with limited passive external rotation and age younger than 2 years or in older children with limited passive internal external rotation and good strength of the external rotators (a score of at least 4 on the Medical Research Council scale for Muscle Strength).

Children with no active external rotation and passive external rotation in adduction of less than 20° that progressed over time met the indications for anterior release and tendon transfer in one stage. Additionally, children with passive external rotation greater than 20° in adduction and no active external rotation underwent a tendon transfer without soft-tissue release (Fig. 1).

In the 112 included children, the treatment strategy was performed as follows: 37 children (mean age 3 years \pm 2.6

years) underwent internal rotation contracture release and 68 children (mean age 5 years \pm 3.4 years) underwent internal contracture release and tendon transfer for active external rotation in one stage. Seven children (mean age 8 years \pm 4.5 years) received an active external rotation tendon transfer without release, because the mean passive external rotation in adduction was 54° \pm 19°; therefore, this group was not analyzed in detail (Table 1).

Type of Release

Two types of internal contracture release were performed: anterior release (n = 70) and posterior release (n = 35). Posterior release, as described by Carlioz and Brahimy [3], was performed between 1996 and 2001; thereafter, an anterior technique, as developed by the senior author (RGHHN), was used in all children.

Surgical Techniques

All operations were performed by the senior author (RGHHN) with the patient under general anesthesia in a semi-lateral decubital position.

Posterior Release

In 35 children, an incision along the inferior angle and lateral border of the scapula was made to expose the latissimus dorsi-teres major interval. In this interval, the inferior 1/3 of the medial scapular border was identified and incised. The subscapularis was then released posteriorly from the scapula.

Anterior Release

A deltopectoral incision of 5 mm to 7 mm was made to expose the coracoid in 70 children. After identification, an incision was made at the base of the coracoid, and the coracohumeral ligament at the anterior capsule of the shoulder was released at a length of 3 mm in 66 children. In eight children, this gave insufficient external rotation; thus, a deltopectoral incision was used to expose the cranial part of the subscapular tendon, which was also incised over a width of 2 mm to 3 mm of the cranial part of this tendon.

Tendon Transfer

Through a slightly curved incision at the posterior axillar border, the teres major and/or latissimus dorsi tendon was

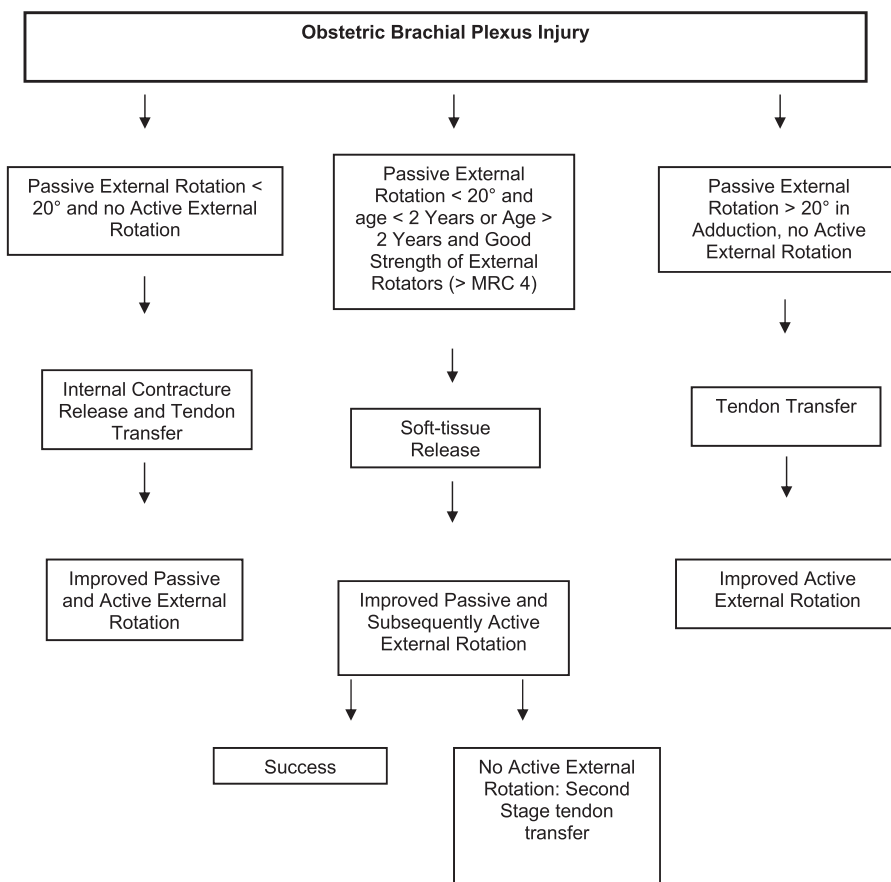


Fig. 1 This flowchart shows the indications for different secondary shoulder procedures.

identified and detached from the humerus (Fig. 2A-B). A second incision was made posterior and cranial to the upper arm, followed by a deltoid split to expose the humeral head (Fig. 2C). The detached latissimus dorsi and teres major were transferred underneath the deltoid muscle to the infraspinatus-supraspinatus footprint area. Both tendons were fixed with transosseous sutures at the greater tuberosity of the humerus. If severe fatty changes of the subscapular muscle existed, as seen on MRI [10], only the teres

major (n = 7) or the latissimus dorsi (n = 1) was transferred to prevent external rotation contracture of the shoulder.

Clinical Assessment Criteria and Follow-up

A prospective functional assessment of the shoulder was performed preoperatively and postoperatively at 6 weeks, 3 months, and annually thereafter, and included active and

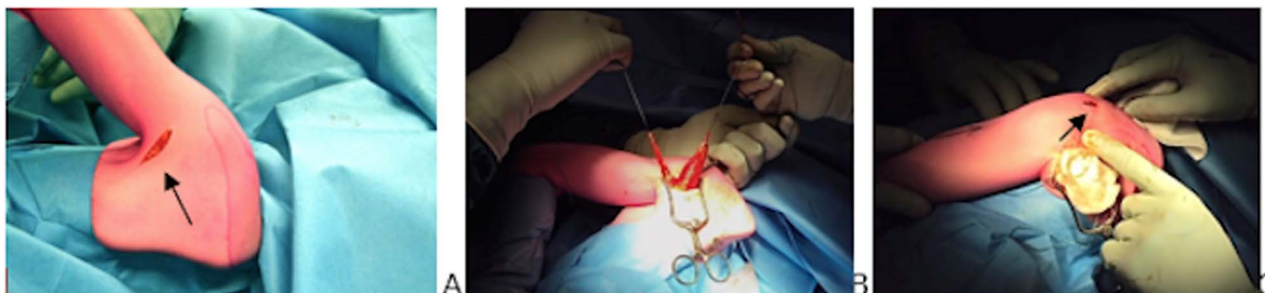

Fig. 2 This figure shows (A) the posterior approach to the posterior axillary line, (B) detachment of the latissimus dorsi and teres major tendons, and (C) the deltoid split for reattachment at the infraspinatus-supraspinatus footprint at the greater tuberosity of the humerus.

passive measurements of abduction, anteflexion, external rotation in adduction and abduction, internal rotation, horizontal adduction, and the Mallet scale [1]. All clinical measurements were made with a goniometer by an orthopaedic surgeon, a trained physical therapist, or a rehabilitation physician. The mean follow-up was 5.3 years \pm 2.7 years.

Loss to Follow-up

There were no differences between children with a limited follow-up duration after the 1-year follow-up interval and children with longer follow-up in terms of passive and active external rotation in adduction and abduction and passive abduction in both the release and the release-and-tendon-transfer in one stage groups ($p > 0.05$) (see Appendix, Supplemental Digital Content 1, <http://links.lww.com/CORR/A243>). Active abduction and elevation were higher in the lost-to-follow-up release group ($p < 0.05$) than in children with longer follow-up, whereas in the release-and-tendon-transfer groups, active abduction was not different ($p > 0.05$).

Statistical Analysis

Measured values are presented as the mean and SD; estimates are presented as the mean and 95% confidence interval. A mixed model (with random intercepts for children) was used to evaluate the correlation between repeated measurements within a child for a single outcome variable.

Because preoperative external rotation is a confounder of the postoperative result, preoperative values of passive and active external rotation were divided in three different classes: I: less than -60° ; II: between -60 and -20° ; and III: at least 20° . A p value < 0.05 was considered significant. Locally estimated scatterplot smoothing was used to visualize the relationship between the variable of follow-up time and the variables of passive and active external rotation in adduction and abduction. The Mann Whitney test was used to compare patient characteristics between different groups. For statistical analysis, the SPSS software package was used (version 17.0; Chicago, IL, USA).

Results

For patients with passive external rotation less than 20° and age younger than 2 years and for patients aged older than 2 years with good external rotation strength after soft-tissue release alone, the mean preoperative passive external rotation in adduction was -8° (standard error 3.7) and was

improved by 29° (95% CI, 21 to 38; $p < 0.05$) at 1 year and by 25° (95% CI, 15 to 35; $p < 0.001$) at 5 years.

The mean preoperative passive external rotation in abduction was 49° (standard error 3) and was improved by 17° (95% CI, 10 to 24; $p < 0.05$) at 1 year and by 15° (95% CI, 7 to 24; $p < 0.001$) at 5 years. Passive external rotation in adduction and abduction showed a linear increase in the first 12 months, then plateaued thereafter (Fig. 3A).

Internal contracture release improved passive external rotation in adduction and abduction at the 1-year and 5-year follow-up intervals (Table 2). Active external rotation in adduction and abduction, active abduction, and the domains of hand-to-head and hand-to-mouth on the Mallet scale all improved at the 1-year and 5-year follow-up intervals (Table 2).

Forty-six percent (17 of 37 patients) with insufficient strength of external rotation after release with second-stage tendon transfers had improved active function. The mean preoperative active external rotation in adduction was -70° (standard error 7.6) and was improved by 49° (95% CI, 28 to 69; $p < 0.05$) at 1 year and by 45° (95% CI, 11 to 79; $p < 0.001$) at 5 years. The mean preoperative active external rotation in abduction was 6° (standard error 7.9) and was improved by 38° (95% CI, 19 to 58; $p < 0.05$) at 1 year and by 23° (95% CI, -8 to 55; $p > 0.05$) at 5 years (Table 3). Active external rotation in adduction and abduction showed a linear increase in the first 12 months, then plateaued thereafter (Fig. 3B).

In patients who initially had less than 20° passive external rotation and no active external rotation after single-stage contracture release and tendon transfer, active ROM was improved. The mean preoperative active external rotation in adduction was -74° (standard error 4.1) and was improved by 75° (95% CI, 66 to 84; $p < 0.05$) at 1 year and by 65° (95% CI, 50 to 79; $p < 0.05$) at 5 years. The mean preoperative active external rotation in abduction was 2° (standard error 3.3) and was improved by 50° (95% CI, 43 to 57; $p < 0.05$) at 1 year and by 40° (95% CI, 28 to 52; $p < 0.05$) at 5 years. Active external rotation in adduction and abduction showed a linear increase in the first 12 months, then plateaued thereafter (Fig. 3C).

Passive external rotation in adduction and abduction, active abduction and elevation, and scores for all domains of the Mallet scale, except for the domain of hand-to-back, improved at 1 and 5 years of follow-up (Table 4).

Complications

Ten complications occurred. Keloid scars developed in four children after surgery and were treated with a self-adhesive gel sheet; one scar was surgically corrected. One child had transient postoperative ulnar nerve compression because of pressure from a postoperative external rotation

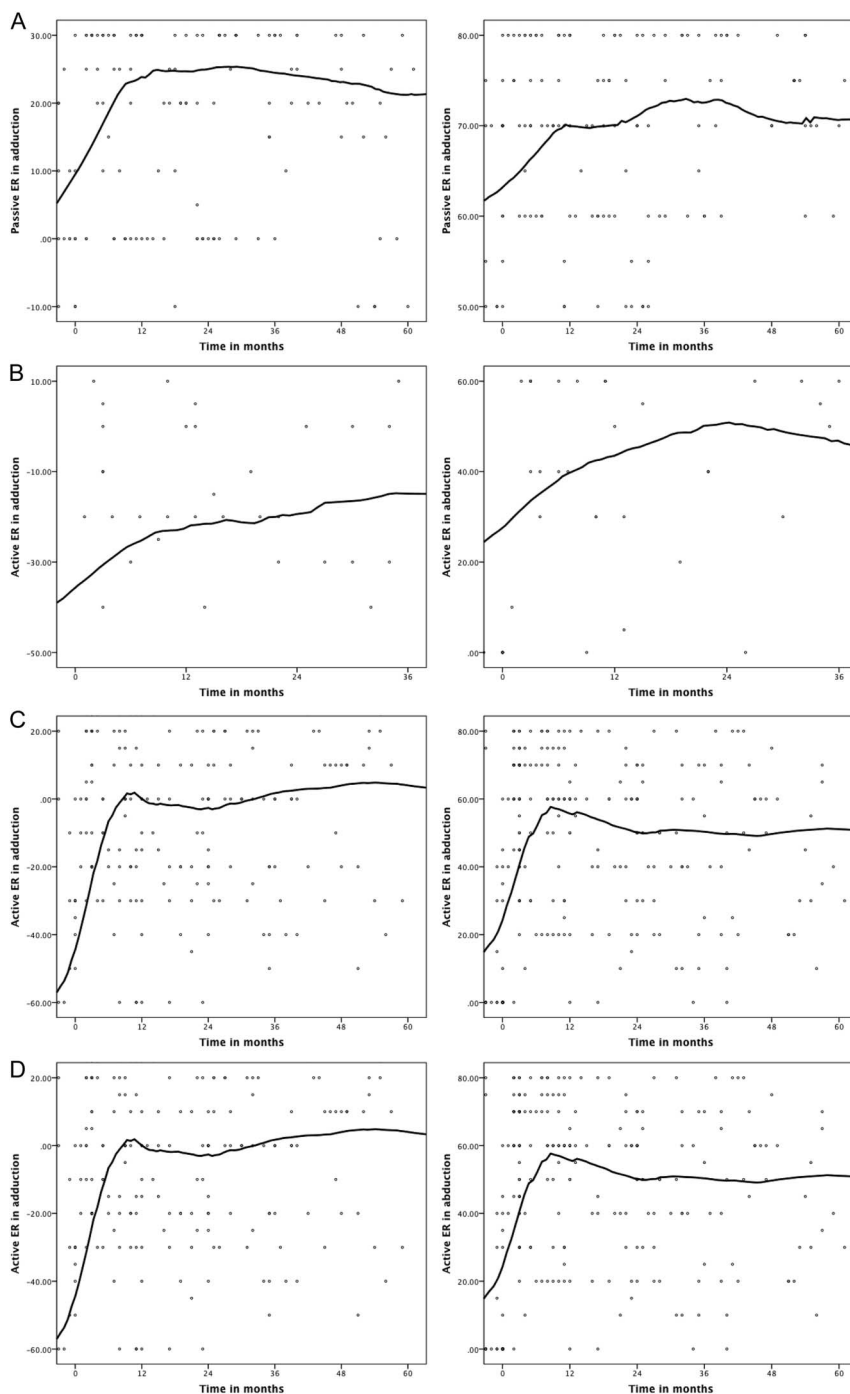


Fig. 3 This figure shows (A) degrees of postoperative passive external rotation in adduction (left) and abduction (right) after internal contracture release in 37 children at the 5-year follow-up timepoint. There was an evident increase in passive external rotation (a locally estimated scatterplot smoothing curve was fitted to measurements of individual patients at different timepoints). (B) This images shows degrees of postoperative active external rotation in adduction (left) and abduction (right) after internal contracture release in 37 children at the 5-year follow-up interval. (C) This images shows degrees of postoperative active external rotation in adduction (left) and abduction (right) after an additional tendon transfer in 17 children after they had an insufficient response to primary internal contracture release during an additional 3-year follow-up period.

Table 2. Preoperative and postoperative ROM of the shoulder in children with an internal contracture release (n = 37)

Internal contracture release	Mean preoperative ROM (°) (standard error)	Mean increase in ROM 1 and 5 years postoperatively (°) (95% CI)
Active external rotation (in adduction)	-46 (7.3)	1 year: 33 (17-47 ^a) 5 years: 35 (17-52 ^a)
Passive external rotation (in adduction)	-8 (3.7)	1 year: 29 (21-38 ^a) 5 years: 25 (15-35 ^a)
Active external rotation (in abduction)	11 (7)	1 year: 24 (8-40 ^b) 5 years: 35 (18-52 ^a)
Passive external rotation (in abduction)	49 (3)	1 year: 17 (10-24 ^a) 5 years: 15 (7-24 ^b)
Active Abduction and elevation	70 (8.6)	1 year: 35 (19-50 ^a) 5 years: 47 (31-63 ^a)
Passive abduction	84 (3.3)	1 year: 4 (3-15 ^b) 5 years: 3 (-3 to 9)
Mallet Abduction	3 (0.5)	1 year: 0.2 (0.9-1.3) 5 years: 0.2 (-1 to 1.4)
Mallet External rotation	1.4 (0.2)	1 year: 0.8 (0.4-1 ^b) 5 years: 0.2 (-0.4 to 0.7)
Mallet Hand-to-head	2 (0.2)	1 year: 1.1 (0.7-1.4 ^a) 5 years: 1.2 (0.9-1.6 ^a)
Mallet Hand-to-back	3 (0.2)	1 year: 0.3 (-0.1 to 0.7) 5 years: 0.1 (-0.3 to 0.5)
Mallet Hand-to-mouth	3 (0.2)	1 year: 0.5 (0.2-0.9 ^b) 5 years: 0.6 (0.2-0.9 ^b)

^ap < 0.001^bp < 0.05.

plaster of the thorax at the medial epicondyle. This resolved after we opened the plaster at the elbow. In four patients, an external rotation contracture with limited internal rotation

(median: 0° [minimum: -40; maximum: 0]) occurred after tendon transfer. In two patients, no additional treatment was performed because these patients had minimal

Table 3. Preoperative and postoperative ROM of the shoulder in children with a tendon transposition after a prior release (n = 17)

Tendon transfer (after prior internal contracture release)	Mean preoperative ROM (°) (standard error)	Mean increase in ROM 1 and 5 years postoperatively (°) (95% CI)
Active external rotation (in adduction)	-70 (7.6)	1 year: 49 (28-69 ^a) 5 years: 45 (11-79 ^b)
Passive external rotation (in adduction)	2 (5.4)	1 year: 14 (2- 27 ^b) 5 years: 5 (-17 to 27)
Active external rotation (in abduction)	6 (7.9)	1 year: 38 (19-58 ^a) 5 years: 23 (-8 to 55)
Passive external rotation (in abduction)	51 (4.2)	1 year: 26 (16-35 ^b) 5 years: 11 (6 to -27)
Active Abduction and elevation	99 (11.8)	1 year: 31 (9- 54 ^b) 5 years: -4 (-40 to 30)
Passive abduction	80 (3.2)	1 year: 4 (-5 to 12) 5 years: 12 (-1 to 25)

^ap < 0.001^bp < 0.05.

Table 4. Preoperative and postoperative ROM of the shoulder in children with a release and tendon transposition in one stage (n = 68)

Release and tendon transfer in one stage	Mean preoperative ROM (°) (95% CI)	Mean increase in ROM 1 and 5 years postoperatively (°) (95% CI)
Active external rotation (in adduction)	-74 (4.1)	1 year: 75 (66-84 ^a) 5 years: 65 (50-79 ^a)
Passive external rotation (in adduction)	-10 (2.7)	1 year: 44 (38-51 ^a) 5 years: 38 (28-48 ^a)
Active external rotation (in abduction)	2 (3.3)	1 year: 50 (43-57 ^a) 5 years: 40 (28-52 ^a)
Passive external rotation (in abduction)	43 (2)	1 year: 32 (27-37 ^a) 5 years: 21 (13-29 ^a)
Active Abduction and elevation	77 (5.8)	1 year: 44 (34-54 ^a) 5 years: 55 (39-72 ^a)
Passive abduction	84 (1.3)	1 year: 5 (2-8 ^a) 5 years: 2 (-2 to 6)
Mallet Abduction	3 (0.1)	1 year: 0.5 (0.3-0.7 ^a) 5 years: 0.6 (0.4-0.9 ^a)
Mallet External rotation	1 (1.4)	1 year: 1.5 (1.2-1.9 ^a) 5 years: 1.1 (0.5-1.6 ^a)
Mallet Hand-to-head	3 (0.1)	1 year: 1.2 (1-1.4 ^a) 5 years: 1.1 (0.8-1.4 ^a)
Mallet Hand-to-back	3 (0.1)	1 year: -0.5 (-0.7 to -0.3 ^a) 5 years: -0.5 (-0.9 to -0.1 ^b)
Mallet Hand-to-mouth	3 (0.1)	1 year: 0.9 (0.7-1.1 ^a) 5 years: 0.8 (0.5-1.1 ^a)

^ap < 0.001^bp < 0.05.

functional limitations. In two patients, the maximum active internal rotation was -20° in adduction (that is, the arm was in external rotation); passive internal rotation in adduction was 0° in one child and -40° in the other. Posterior capsule release and release of the transferred latissimus dorsi and teres major tendon from the posterior side were performed to improve internal rotation. Postoperative data were only available for one child, in whom passive internal rotation in adduction was increased to 50°. One child underwent surgery in September 2012 and this child's postoperative results are not yet available.

Discussion

Children with insufficient, spontaneous functional recovery after obstetric brachial plexus injuries benefit from secondary soft-tissue surgery of the shoulder using the presented treatment strategy if they have an internal rotation contracture of the shoulder. Age and preoperative passive external rotation in adduction and strength of the external rotators were important factors in preoperative decision-making about the type of secondary surgery in

order to improve functionality. When the timing and type of procedure (such as release, tendon transfer, or a combination of the two) are selected carefully based on the preoperative functional status of the child, the child will be able to use his or her arm optimally for daily activities. Because it is important to monitor progression of a deformity, this underscores the importance of following these children in medical centers, which may not only define the impact of treatment (both surgical and nonsurgical) but also address all aspects of the treatment in the development of children with these complex injuries.

An important limitation to this study is that selection bias may have occurred, because children who underwent secondary surgery may have had more limitations to functional use of the upper limb than children who did not undergo additional soft-tissue procedures. However, the aim of our study was to observe the effect of these procedures in children with persistent functional limitations. Another limitation is the proportion of children who were discharged after the 1-year follow-up timepoint (31 of 149 children; 21%). However, all children with insufficient functional improvement during the first year were observed at our center and only children with good functional results

were discharged for local follow-up after 1 year. These children had equivalent or even better results and in case of deterioration of function or other problems with the affected arm, we emphasize that contact should be made. However, if patients experienced deterioration over time, they might have sought medical expertise at another center.

Children with limited passive external rotation but sufficient strength of the external rotators or a high likelihood of recovery of the external rotators (because they were younger than 2 years) underwent only internal contracture release as recommended by Gilbert [5] and Pearl and Edgerton [16]. Soft-tissue release is occasionally performed in older children with limited passive external rotation but good strength of the external rotators (Medical Research Council scale for Muscle Strength Grade 4). Older children can follow instructions during clinical examinations, and active external rotation can therefore be measured more accurately than in younger children. Considering soft-tissue release techniques, there are different methods of lengthening the tendon or treating a contracture. Posterior subscapularis release results in increased global function [14]. However, releasing the subscapular muscle from the ventral scapular blade results in early recurrence of the internal rotation contracture, as found by us and others [2]. Further, this procedure might compromise the subscapular muscle [13]. Thus, we changed our policy for correcting an internal rotation contracture. Without affecting the muscle balance in the shoulder, by only releasing the coracohumeral ligament and leaving the coracoid process and subscapular muscle intact, we achieved similar results to a study that described subscapular release [4], but this technique was inferior to techniques in which the coracoid process was resected [2, 24]. This compromises internal rotation movement by the subscapular muscle and might decrease action of the subscapular muscle above the rotation of the shoulder and thus decrease abduction and elevation [9, 25]. Furthermore, anterior coracohumeral ligament release is associated with better results in terms of passive and active external rotation in adduction, active external rotation in abduction, active abduction, elevation and anteflexion, and the domains of external rotation and hand-to-neck on the Mallet scale than posterior subscapular lengthening. Additionally, the percentage of external rotation contractures in this series (4%; four of 112 patients) is far less than in other series, which reported percentages of external rotation contractures of up to 42% [2, 24]. A description of this technique has been accepted for publication and will be available soon.

Our results show that this strategy led to durable improvement in passive and active external rotation and thus overall functionality of the arm in only 20 of 24 patients, and in 17 of 37 children, internal contracture release led to an additional tendon transfer, after which immediate, relevant, and durable functional improvement occurred. In

retrospect, this should have been an indication for internal contracture release and tendon transfer in one stage. This high percentage of failures invoked a change in treatment strategy, and since 2001, we have only performed release without a tendon transfer in patients with poor passive external rotation (less than 20°) and if the child is younger than 2 years.

Children with limited passive external rotation and weakness of the external rotators who were treated with internal contracture release combined with tendon transfer showed improvement in passive and active external rotation and in active abduction and elevation. This is because of the position of the transferred muscles on the humeral head. A more cranial and lateral position on the humeral head will enhance not only external rotation but also elevation and abduction of the arm. This enhances the force-couple effect on the rotator cuff [17]. Furthermore, children with Class I active external rotation had the largest increase in passive and active abduction and in the domains of abduction and hand-to-neck on the Mallet scale. The greater increase in abduction could be explained by improvement in external rotation after the release procedure, allowing for greater arm abduction by clearing restrictions to ROM because of soft-tissue contractures. This greater increase could also be explained by the stabilizing effect of a centrally positioned long biceps head [1, 22]. Additional improvement in shoulder abduction occurs after the latissimus dorsi muscle is transferred to the greater tuberculum of the humerus because the transfer enhances the stabilizing effect of the rotator cuff, enabling the deltoid to act more effectively.

The child's age remains the subject of debate. Most authors emphasize the importance of early tendon transfer to hinder joint impairment (such as glenohumeral incongruence because of increased glenoid retroversion) [8, 25, 28]. Preoperative information about the glenohumeral joint (for example, the posterior position of the humeral head) might be a reason not to perform release without an active motor (such as latissimus dorsi transfer). Although the median age in our group was 4 years, younger children also had surgery, which is in contrast to Pearl et al. [15] and Phipps and Hoffer [17], who recommended delaying surgery until the child is 3 or 4 years old to wait for further spontaneous recovery. However, rebalancing the muscle coupling at the shoulder level, even at a young age, is important to prevent incongruence of the glenohumeral joint [8, 10]. Thus, the degree of a functional and structural deformity, not age, must guide the indication for surgery.

Young children with obstetric brachial plexus injuries without spontaneous functional recovery of the shoulder benefit from appropriate soft-tissue procedures according to the presented treatment strategy. Improvement in active and passive ROM was clinically relevant and sustained during 5 years of follow-up. Our next step is to perform a

study on glenohumeral deformities and how they affect our treatment strategy and functional outcome.

Acknowledgements We thank the Leiden Brachial Plexus Injury Study Group: J. H. Arendzen, K. S. de Boer, D. Steenbeek (Department of Rehabilitation Medicine, Leiden University Medical Center), M. van der Holst (Department of Physical Therapy, Leiden University Medical Center), W. Pondaag, and M. J. A. Malessy (Department of Neurosurgery Leiden University Medical Center).

References

1. Aydin A, Ozkan T, Onel D. Does preoperative abduction value affect functional outcome of combined muscle transfer and release procedures in obstetrical palsy patients with shoulder involvement? *BMC Musculoskelet Disord.* 2004;5:25.
2. Birch R, Bonney G. Birth lesions of the brachial plexus. In: Birch R, Bonney G, Wynn Parry C, eds. *Surgical Disorders of the Peripheral Nerves*. 1st ed. Edinburgh: Churchill Livingstone; 1998:209-233.
3. Carlioz H, Brahimi L. Place of internal disinsertion of the subscapularis muscle in the treatment of obstetric paralysis of the upper limb in children *Ann Chir Infant.* 1971;12:159-167.
4. El-Gammal TA, Saleh WR, El-Sayed A, Kotb MM, Imam HM, Fathi NA. Tendon transfer around the shoulder in obstetric brachial plexus paralysis: clinical and computed tomographic study. *J Pediatr Orthop.* 2006;26:641-646.
5. Gilbert A. Obstetrical brachial plexus palsy. In: Tubiana R, ed. *The Hand*. Vol. 4. Philadelphia: WB Saunders; 1993:575-601.
6. Hoeksma AF, ter Steeg AM, Dijkstra P, Nelissen RG, Beelen A, de Jong BA. Shoulder contracture and osseous deformity in obstetrical brachial plexus injuries. *J Bone Joint Surg Am.* 2003; 85:316-322.
7. Hoeksma A, ter Steeg A, Nelissen R, van Ouwkerk W, Lankhorst G, de Jong BA. Neurological recovery in obstetric brachial plexus injuries: an historical cohort study. *Dev Med Child Neurol.* 2004;46:76-83.
8. Hogendoorn S, van Overvest KL, Watt I, Duijsens AH, Nelissen RG. Structural changes in muscle and glenohumeral joint deformity in neonatal brachial plexus palsy. *J Bone Joint Surg Am.* 2010;92:935-942.
9. Kadaba MP, Cole A, Wootten ME, McCann P, Reid M, Mulford G, April E, LU Bigliani. Intramuscular wire electromyography of the subscapularis. *J Orthop Res.* 1992;10:394-397.
10. Kon DS, Darakjian AB, Pearl ML, Kosco AE. Glenohumeral deformity in children with internal rotation contractures secondary to brachial plexus birth palsy: intraoperative arthrographic classification. *Radiology.* 2004;231:791-995.
11. Malessy MJ, de Ruitter GC, de Boer KS, Thomeer RT. Evaluation of suprascapular nerve neurotization after nerve graft or transfer in the treatment of brachial plexus traction lesions. *J Neurosurg.* 2004;101:377-389.
12. Malessy MJ, Pondaag W. Obstetric brachial plexus injuries. *Neurosurg Clin N Am.* 2009;20:1-14.
13. Meskers CG, Arwert HJ, Rozing PM. Electromyography of the subscapularis muscle. *J Shoulder Elbow Surg.* 1996;5:42.
14. Ozben H, Atalar AC, Bilsel K, Demirhan M. Transfer of latissimus dorsi and teres major tendons without subscapularis release for the treatment of obstetrical brachial plexus palsy sequela. *J Shoulder Elbow Surg.* 2011;20: 1265-1274.
15. Pearl ML, Edgerton BW, Kazimiroff PA, Burchette RJ, Wong K. Arthroscopic release and latissimus dorsi transfer for shoulder internal rotation contractures and glenohumeral deformity secondary to brachial plexus birth palsy. *J Bone Joint Surg Am.* 2006;88:564-574.
16. Pearl ML, Edgerton BW. Glenoid deformity secondary to brachial plexus birth palsy. *J Bone Joint Surg Am.* 1998;80: 659-667.
17. Phipps GJ, Hoffer MM. Latissimus dorsi and teres major tendon transfer to rotator cuff for Erb's palsy. *J Shoulder Elbow Surg.* 1995;4:124-129.
18. Pondaag W, de Boer R, van Wijlen-Hempel MS, Hofstede-Buitenhuys SM, Malessy MJ. External rotation as a result of suprascapular nerve neurotization in obstetric brachial plexus lesions. *Neurosurgery.* 2005;57:530-537.
19. Pondaag W, Malessy MJ, van Dijk JG, Thomeer RT. Natural history of obstetric brachial plexus palsy: a systematic review. *Dev Med Child Neurol.* 2004;46:138-144.
20. Pondaag W, Malessy MJ. Recovery of hand function following nerve grafting and transfer in obstetric brachial plexus lesions. *J Neurosurg.* 2006;105:33-40.
21. Pondaag W, van Someren PJ, van Dijk JG, Malessy MJ. Intraoperative nerve action and compound motor action potential recordings in patients with obstetric brachial plexus lesions. *J Neurosurg.* 2008;109:946-954.
22. Price AE, Grossman AI. A management approach for secondary shoulder and forearm deformities following obstetrical brachial plexus injury. *Hand Clin.* 1995;11:607-617.
23. van der Holst M, Vlieland TP, Meesters JJ, Bekkering WP, Nagels J, Nelissen RG. Evaluation of shoulder function after secondary surgery in children with neonatal brachial plexus palsy. *J Pediatr Rehabil Med.* 2015;8:187-196.
24. van der Sluijs JA, van Ouwkerk WJ, de Gast A, Nollet F, Winters H, Paul IJ. Treatment of internal rotation contracture of the shoulder in obstetric brachial plexus lesions by subscapular tendon lengthening and open reduction: early results and complications. *J Pediatr Orthop.* 2004;13:218-224.
25. van der Sluijs JA, van Ouwkerk WJ, de Gast A, Wuisman P, Nollet F, Manoliu RA. Retroversion of the humeral head in children with an obstetric brachial plexus lesion. *J Bone Joint Surg Br.* 2002;84:583-587.
26. van Gelein Vitnnga V, van Kooten EO, Jaspers RT, Mullender MG, van Doorn-Loogman MH, van der Sluijs JA. Correction. An MRI study on the relations between muscle atrophy, shoulder function and glenohumeral deformity in shoulders of children with obstetric brachial plexus injury. *J Brachial Plex Peripher Nerve Inj.* 2009;4:9.
27. Terzis JK, Kokkalis ZT. Primary and secondary shoulder reconstruction in obstetric brachial plexus palsy. *Injury.* 2008;39: S5-S14.
28. Waters PM, Bae DS. Effect of tendon transfers and extra-articular soft-tissue balancing on glenohumeral development in brachial plexus birth palsy. *J Bone Joint Surg Am.* 2005;87: 320-325.
29. Waters PM. Update on management of pediatric brachial plexus palsy. *J Pediatr Orthop B.* 2005;14:233-244.