



Universiteit  
Leiden  
The Netherlands

## **The harm of delayed diagnosis of arrhythmogenic cardiac sarcoidosis: a case series**

Hoogendoorn, J.C.; Ninaber, M.K.; Piers, S.R.D.; Riva, M. de; Grauss, R.W.; Bogun, F.M.; Zeppenfeld, K.

### **Citation**

Hoogendoorn, J. C., Ninaber, M. K., Piers, S. R. D., Riva, M. de, Grauss, R. W., Bogun, F. M., & Zeppenfeld, K. (2020). The harm of delayed diagnosis of arrhythmogenic cardiac sarcoidosis: a case series. *Ep Europace*, 22(9), 1376-1383. doi:10.1093/europace/euaa115

Version: Publisher's Version

License: [Creative Commons CC BY-NC 4.0 license](https://creativecommons.org/licenses/by-nc/4.0/)

Downloaded from: <https://hdl.handle.net/1887/3184050>

**Note:** To cite this publication please use the final published version (if applicable).

# The harm of delayed diagnosis of arrhythmogenic cardiac sarcoidosis: a case series

Jarieke C. Hoogendoorn <sup>1</sup>, Maarten K. Ninaber<sup>2</sup>, Sebastiaan R.D. Piers<sup>1</sup>, Marta de Riva<sup>1</sup>, Robert W. Grauss<sup>3</sup>, Frank M. Bogun<sup>4</sup>, and Katja Zeppenfeld<sup>1\*</sup>

<sup>1</sup>Willem Einthoven Center for Cardiac Arrhythmia research and Management, Department of Cardiology, Leiden University Medical Center, (B4-P), P.O. Box 9600, 2300 RC Leiden, The Netherlands; <sup>2</sup>Department of Pulmonology, Leiden University Medical Center, Leiden, The Netherlands; <sup>3</sup>Department of Cardiology, Haaglanden Medical Center, Den Haag, The Netherlands; and <sup>4</sup>Department of Cardiology, Michigan Medicine, MI, USA

Received 7 February 2020; editorial decision 15 April 2020; accepted after revision 17 April 2020; online publish-ahead-of-print 10 July 2020

## Aims

Cardiac sarcoidosis (CS) is a known cause of ventricular tachycardia (VT). However, an arrhythmogenic presentation may not prompt immediate comprehensive evaluation. We aimed to assess the diagnostic and disease course of patients with arrhythmogenic cardiac sarcoidosis (ACS).

## Methods and results

From the Leiden VT-ablation-registry, consecutive patients with CS as underlying aetiology were retrospectively included. Data on clinical presentation, time-to-diagnosis, cardiac function, and clinical outcomes were collected. Patients were divided in early (<6 months from first cardiac presentation) and late diagnosis. After exclusion of patients with known causes of non-ischaemic cardiomyopathy (NICM), 15 (12%) out of 129 patients with idiopathic NICM were ultimately diagnosed with CS and included. Five patients were diagnosed early; all had early presentation with VTs. Ten patients had a late diagnosis with a median delay of 24 (IQR 15–44) months, despite presentation with VT ( $n=5$ ) and atrioventricular block ( $n=4$ ). In 6 of 10 patients, reason for suspicion of ACS was the electroanatomical scar pattern. In patients with early diagnosis, immunosuppressive therapy was immediately initiated with stable cardiac function during follow-up. Adversely, in 7 of 10 patients with late diagnosis, cardiac function deteriorated before diagnosis, and in only one cardiac function recovered with immunosuppressive therapy. Six (40%) patients died (five of six with late diagnosis).

## Conclusion

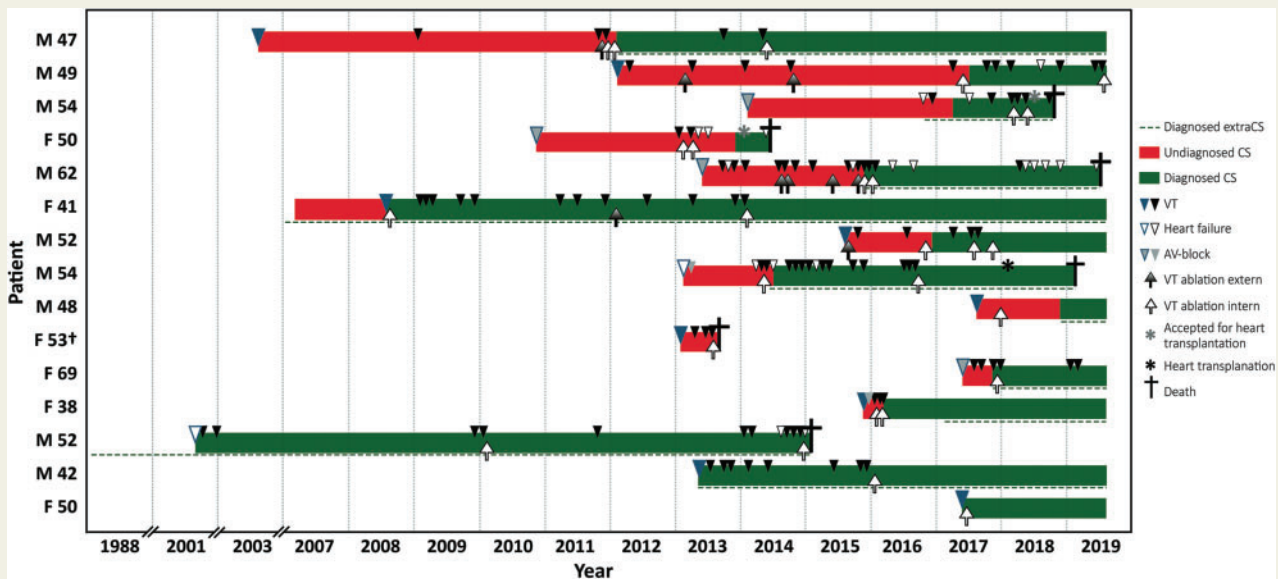
Arrhythmogenic cardiac sarcoidosis is an important differential diagnosis in NICM patients referred for VT ablation. Importantly, the diagnosis is frequently delayed, which leads to a severe disease course, including irreversible cardiac dysfunction and death. Early recognition, which can be facilitated by electroanatomical mapping, is crucial.

\* Corresponding author. Tel: +31 71 52 62020; fax: +31 71 52 66809. E-mail address: k.zeppenfeld@lumc.nl

© The Author(s) 2020. Published by Oxford University Press on behalf of the European Society of Cardiology.

This is an Open Access article distributed under the terms of the Creative Commons Attribution Non-Commercial License (<http://creativecommons.org/licenses/by-nc/4.0/>), which permits non-commercial re-use, distribution, and reproduction in any medium, provided the original work is properly cited. For commercial re-use, please contact [journals.permissions@oup.com](mailto:journals.permissions@oup.com)

## Graphical Abstract



## Keywords

Cardiac sarcoidosis • Ventricular tachycardia • Diagnosis • Mortality • Electroanatomical voltage mapping • Ablation

## What's new?

- Arrhythmogenic cardiac sarcoidosis (ACS) has a prevalence of 12% in an 'idiopathic' non-ischaemic cardiomyopathy ventricular tachycardia (VT)-ablation cohort.
- In 10 of 15 patients (67%) with ACS, the diagnosis is delayed, despite typical presentation with VT or atrioventricular block.
- Cardiac function deteriorated over time in 70% of patients with delayed diagnosis and recovered only in one patient during immunosuppressive therapy.
- The mortality of ACS is 40% after a median follow-up of 55 months.

## Introduction

Cardiac sarcoidosis (CS) is a granulomatous disease of unknown aetiology, histologically characterized by non-necrotizing granulomas.<sup>1</sup> It may be diagnosed in the context of cardiac screening of patients who present with extracardiac sarcoidosis.<sup>2</sup> However, the majority of patients who are diagnosed with CS, presents with cardiac symptoms.<sup>3</sup> The major sequelae of CS are atrioventricular (AV) conduction disturbances, ventricular tachycardia (VT), and heart failure.<sup>3,4</sup>

Diagnosing CS remains challenging. Cornerstones of the diagnosis are either myocardial tissue showing typical non-necrotizing granulomas, or positive myocardial <sup>18</sup>F-FDG-uptake at positron emission tomography (PET).<sup>5,6</sup> Unfortunately, endomyocardial biopsy has a low diagnostic yield due to the patchy involvement of the heart.<sup>5</sup>

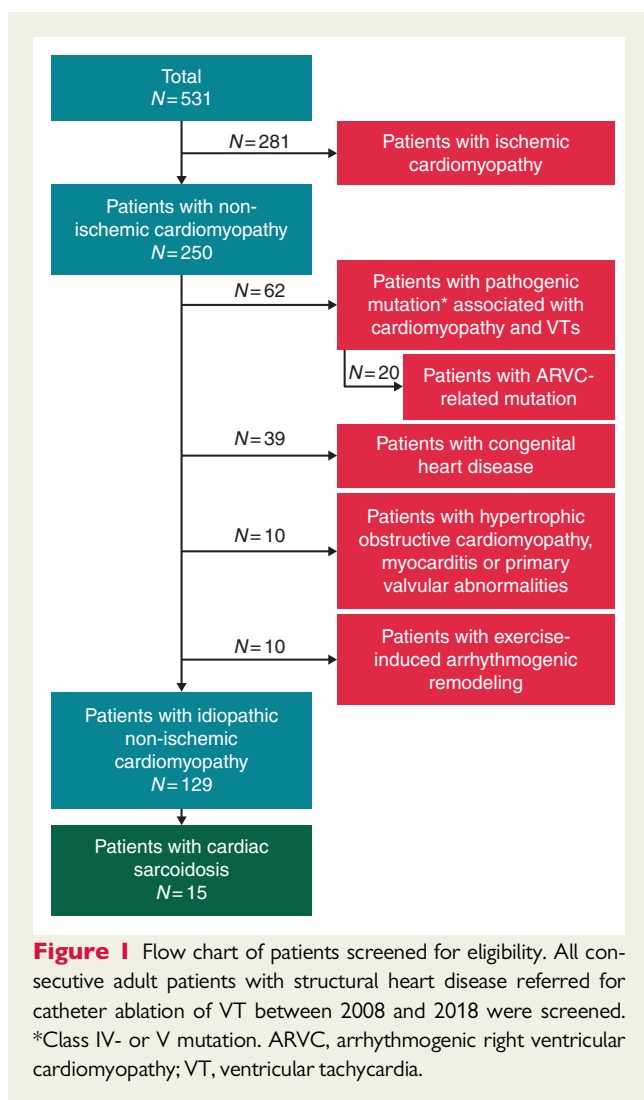
Histologically proven extracardiac sarcoidosis in conjunction with cardiac signs and symptoms also allows for diagnosis of CS. However, extracardiac symptoms are often absent in patients with CS<sup>1,2</sup> and cardiac symptoms and signs may mimic other cardiac diseases.<sup>7,8</sup> Although CS is a known cause of VT, an arrhythmogenic presentation may not prompt immediate and tailored evaluation.<sup>5</sup> This altogether may lead to an important delay in the diagnosis of CS. Early diagnosis of arrhythmogenic cardiac sarcoidosis (ACS) and immediate initiation of immunosuppressive treatment might prevent deterioration of cardiac function and VT recurrence.<sup>9</sup> Both ventricular arrhythmias and severe LV dysfunction are associated with high morbidity and mortality.<sup>4,10,11</sup>

The purpose of this study was to assess the (first) clinical presentation, time-to-diagnosis, and disease course in patients with ACS.

## Methods

## Study population

From the Leiden VT ablation registry, consecutive adult patients from the Netherlands with structural heart disease who underwent VT ablation between 2008 and 2018 were screened for eligibility. After exclusion of patients with other known underlying aetiologies (including coronary artery disease, inherited cardiomyopathy with likely pathogenic or pathogenic variants, congenital heart disease, hypertrophic obstructive cardiomyopathy, myocarditis, primary valve abnormalities, and exercise-induced arrhythmogenic remodelling), 129 of 531 patients were classified as 'idiopathic' non-ischaemic (left- or right-dominant) cardiomyopathy



(Figure 1). Of these 129 patients, 15 patients (12%) were finally diagnosed with CS, according to Japanese or Heart Rhythm Society (HRS) Guidelines,<sup>5,6</sup> and were included. The study was approved by the local ethics committee (G19.005 and C16.010). All patients provided written informed consent. The data underlying this article are available in the article and in its online supplementary material.

## Data collection

Data on symptoms potentially related to cardiac- and extracardiac sarcoidosis (Supplementary material online, Figure S1), presence of cardiac devices, results of electrocardiography (ECG), cardiac imaging studies (including all available echocardiograms, late gadolinium enhancement cardiac magnetic resonance (LGE-CMR), cardiac computed tomography (CT), and <sup>18</sup>F-FDG-PET), and biopsies (both cardiac and extracardiac) were collected from medical records. In addition, documentation of VTs on ECG, Holter or device interrogation were reviewed. Details of VT ablations, pharmacological treatment and clinical outcomes were obtained.

## Data analysis and definitions

First cardiac presentation was defined as first presentation at the cardiology department with symptoms and/or signs compatible with CS. The

date of diagnosis was defined as the moment when diagnostic criteria were fulfilled. Time from first presentation until diagnosis was calculated per patient. Patients were divided into an 'early' and 'late' diagnosis group; 'late' diagnosis was arbitrarily defined as diagnosis later than 6 months after first cardiac presentation or post-mortem diagnosis. Signs, symptoms, and diagnostic tests at first cardiac presentation were compared between patients with early and late diagnosis.

Isolated CS was defined as no signs of extracardiac involvement, after comprehensive evaluation, including whole body <sup>18</sup>F-FDG-PET. Arrhythmogenic CS was defined as CS with ventricular arrhythmias.

## Per patient timeline

Per patient, a timeline was created, including onset of findings potentially related to cardiac sarcoidosis (AV-conduction disturbances, sustained VT, and cardiac dysfunction), time of diagnosis (both cardiac and extracardiac), and clinical outcomes (including VT episodes, admission for VT ablations, admission for heart failure, heart transplantation, and death). Atrioventricular conduction disturbances included 1st degree (PR > 220ms), 2nd and 3rd degree AV-block. Ventricular tachycardias occurring in clusters (within 1 month) were considered as one VT episode. If, however, VT recurred after treatment changes (e.g. change of antiarrhythmic drugs), this was counted as a new VT episode. Ventricular tachycardia ablations included endocardial, epicardial, and surgical ablations. If during the admission a second procedure (e.g. epicardial or surgical) was planned due to mid-myocardial or epicardial substrate, this was considered as one procedure.

## Cardiac function over time

All available echocardiograms were reviewed from the medical records with regard to biventricular function. Both left- (LV) and right ventricular (RV) functions were divided into four categories, namely good function, mildly decreased function, moderately decreased function, and severely decreased function (Supplementary material online, Table S1).

For comparison of cardiac function over time between patients with early and late diagnosis, at least one echocardiogram per year was selected, unless there were treatment changes. As CS may affect the RV, LV, or both, the ventricle with the greatest increase or decrease in function over time was selected for the analysis of change of cardiac function. If cardiac function remained stable, the function of the most severely affected ventricle was reported.

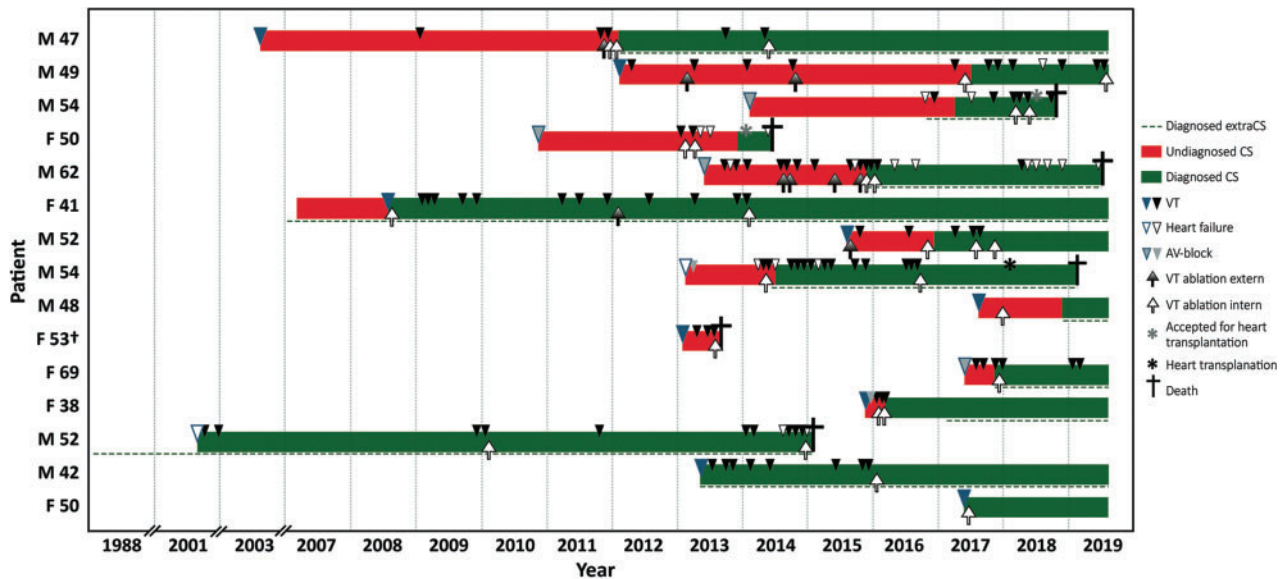
## Statistical analysis

Categorical variables are expressed as numbers and percentages (%) and compared using the Fisher's Exact test. Continuous variables are expressed as mean ± SD or median (IQR) and compared between groups using the Student's *t*-test or Mann-Whitney *U* test. Analysis was performed using IBM SPSS Version 25 (IBM Corporation, New York, USA) and Microsoft Excel (2016). A *P*-value ≤ 0.05 was considered significant.

## Results

### Study population

Fifteen patients were included (60% male, 51 ± 8 years at first presentation). The final diagnosis of CS was based on histology in 10 patients: positive cardiac histology in 6 patients and positive extracardiac histology in conjunction with cardiac signs in 4 patients (HRS guidelines<sup>5</sup>). The remaining five patients did not have histological



**Figure 2** Per patient timeline from first presentation related to (extra)cardiac sarcoidosis until last follow-up or death, ordered by time between first presentation and diagnosis. On the Y-axis gender (M/F) and age at first cardiac presentation (years). †Diagnosed at autopsy. AV, atrioventricular; CS, cardiac sarcoidosis; F, female; M, male; VT, ventricular tachycardia.

confirmation, but they fulfilled clinical and imaging criteria according to the Japanese guidelines.<sup>6</sup>

Isolated CS was present at moment of diagnosis in five patients (33%); three of them had histological confirmation and two patients had a clinical diagnosis. Of note, of the 10 patients with systemic sarcoidosis, only 2 had complaints of extracardiac involvement; the remaining were diagnosed after comprehensive evaluation without symptoms of extracardiac disease. Presence of major diagnostic criteria per patient are listed in [Supplementary material online, Table S2](#).

### Patients with early diagnosis

Five patients were diagnosed early ([Table 1](#) and [Figure 2](#)). All of them had an early arrhythmogenic presentation with VTs, prompting appropriate additional evaluation with biopsy and/or <sup>18</sup>F-FDG-PET.

### Patients with late diagnosis

Ten patients were diagnosed late, with a median delay of 24 (IQR 15–44) months ([Table 1](#) and [Figure 2](#)). One patient with a delayed diagnosis was diagnosed at autopsy. First clinical presentation was VT in five, AV-block in three, and heart failure (in combination with 1st degree AV-block) in one. One patient was known with histologically proven extracardiac sarcoidosis and referred for cardiac evaluation because of an abnormal 12-lead surface ECG.

The most common misdiagnoses in patients with delayed diagnosis was arrhythmogenic right ventricular cardiomyopathy and ischaemic cardiomyopathy despite normal angiogram ([Figure 3A](#)). Of importance, in six patients, the diagnosis of CS was suspected during electroanatomical voltage mapping (EAVM). In these patients, the EAVM scar pattern was not consistent with the diagnosis at referral, leading to additional evaluation with biopsy and/or <sup>18</sup>F-FDG-PET ([Figure 3B](#)).

### Comparison of patients with early vs. late diagnosis

Symptoms of cardiac and extracardiac disease at first cardiac presentation were similar between patients with early and late diagnosis ([Table 1](#)).

However, of importance, <sup>18</sup>F-FDG-PET was performed at first cardiac presentation in four of five patients with early diagnosis, showing focal myocardial FDG-uptake in all of them. On the contrary, <sup>18</sup>F-FDG-PET was not performed in any of the patients with late diagnosis at first presentation. Similarly, in four of five patients with early diagnosis cardiac biopsy was performed, whilst in only one patient with late diagnosis (with a negative result).

There was no difference between early and late diagnosed patients, with regard to the first arrhythmic presentation (electrical storm and/or out of hospital cardiac arrest). Besides, the characteristics of the VT were also not different between groups at first arrhythmic presentation. The cycle length of the VT was available in all early diagnosed patients and 7 (70%) late diagnosed patients and did not differ significantly (median 400 ms vs. 375 ms, respectively;  $P = 0.530$ ).

### Cardiac function over time

Cardiac function over time in patients with early and late diagnosis is shown in [Figure 4](#). All patients with early diagnosis had active disease (on biopsy and/or <sup>18</sup>F-FDG-PET) and were treated with immunosuppressive therapy. Of interest, in all but one patient, cardiac function was mildly decreased at baseline and remained stable during follow-up.

On the contrary, 9 of 10 patients with late diagnosis had a preserved function at baseline (good to mildly decreased). However, 7 of 10 patients with late diagnosis had a decrease in function before diagnosis. Six of seven patients with decrease in function were treated



**Table 1** Patient characteristics and results of diagnostic studies at first cardiac presentation in patients with early ( $\leq 6$  months) and late diagnosis [median time to diagnosis 24 months (IQR 15–44)]

	Early diagnosis (n = 5)	Late diagnosis (n = 10)
Age (years)	50 $\pm$ 12	51 $\pm$ 6
Symptoms		
Palpitations and/or (near) syncope	4 (80)	6 (60)
Dyspnoea	3 (60)	3 (30)
Electrocardiography		
PR-interval $>220$ ms <sup>a</sup>	1 (25)	2 (25)
2nd or 3rd degree AV-block	1 (20)	2 (20)
Ventricular arrhythmia	5 (100)	5 (50)
Sustained VT	5 (100)	4 (80)
OHCA	0 (0)	1 (20)
RBBB like morphology, axis deviation and/or abnormal Q-waves	2 (40)	6 (60)
Imaging		
Echocardiography		
LVEF $< 50\%$	3 (60)	4 (40)
Thinning or WMA of basal/mid septum	5 (100)	3 (30)
Aneurysm or wall thickening	2 (40)	2 (20)
LGE-CMR	4 (80)	5 (50)
LGE present	4 (100)	3 (60)
LGE not assessable	0 (0)	1 (20) <sup>b</sup>
<sup>18</sup> F-FDG-PET	4 (80)	0 (0)
Cardiac uptake	4 (100)	–
Extracardiac uptake	2 (50)	–
Invasive diagnostic tests		
Coronary angiography	5 (100)	6 (60)
No coronary artery disease	5 (100)	6 (100)
Biopsies		
Cardiac biopsy	4 (80)	1 (10)
Positive	3 (75)	0 (0)
Extracardiac biopsy <sup>c</sup>	1 (20)	1 (10)
Positive	1 (100)	1 (100)

Numbers expressed as n (%).

<sup>a</sup>In patients without 2nd or 3rd degree AV-block.

<sup>b</sup>Due to artefacts.

<sup>c</sup>Performed before first cardiac presentation.

AV, atrioventricular; ECG, electrocardiogram; <sup>18</sup>F-FDG-PET, <sup>18</sup>F-fludeoxyglucose positron emission tomography; (LGE-)CMR, (late gadolinium enhancement) cardiac magnetic resonance; IQR: interquartile range; LVEF, left ventricular ejection fraction; OHCA, out of hospital cardiac arrest; RBBB, right bundle branch block; VT, ventricular tachycardia; WMA, wall motion abnormalities.

with immunosuppressive therapy after diagnosis because of active sarcoidosis (biopsy and/or <sup>18</sup>F-FDG-PET), and only in one of them function recovered with immunosuppressive therapy. One patient with a mildly decreased function at baseline and stable function over time died before immunosuppressive therapy, with active sarcoidosis at autopsy.

## Treatment and outcomes

Median follow-up time from first cardiac presentation until last follow-up was 55 (IQR 25–88) months. All patients were implanted with an implantable cardiac defibrillator (ICD); six patients (40%) received cardiac resynchronization therapy (CRT).

With regard to treatment, more than one admission for VT ablation was needed in 10 patients (67%). Notably, median number of VT ablations was 1 (IQR 1–2) in the early diagnosed group, compared to 3 (IQR 2–4) in patients with late diagnosis ( $P = 0.056$ ). Beside, anti-arrhythmic (AAD) therapy was escalated in 11 patients including amiodarone ( $n = 6$ ) and mexiletine ( $n = 3$ ).

Heart failure admission was needed in only one patient with early diagnosis, compared to five patients with late diagnosis.

Six patients died (40%), of which five had a late diagnosis. The cause of death was terminal heart failure ( $n = 3$ ; two awaiting transplant), ventricular arrhythmias unresponsive to ICD therapy ( $n = 1$ ) and infection ( $n = 2$ ) (Figure 2).

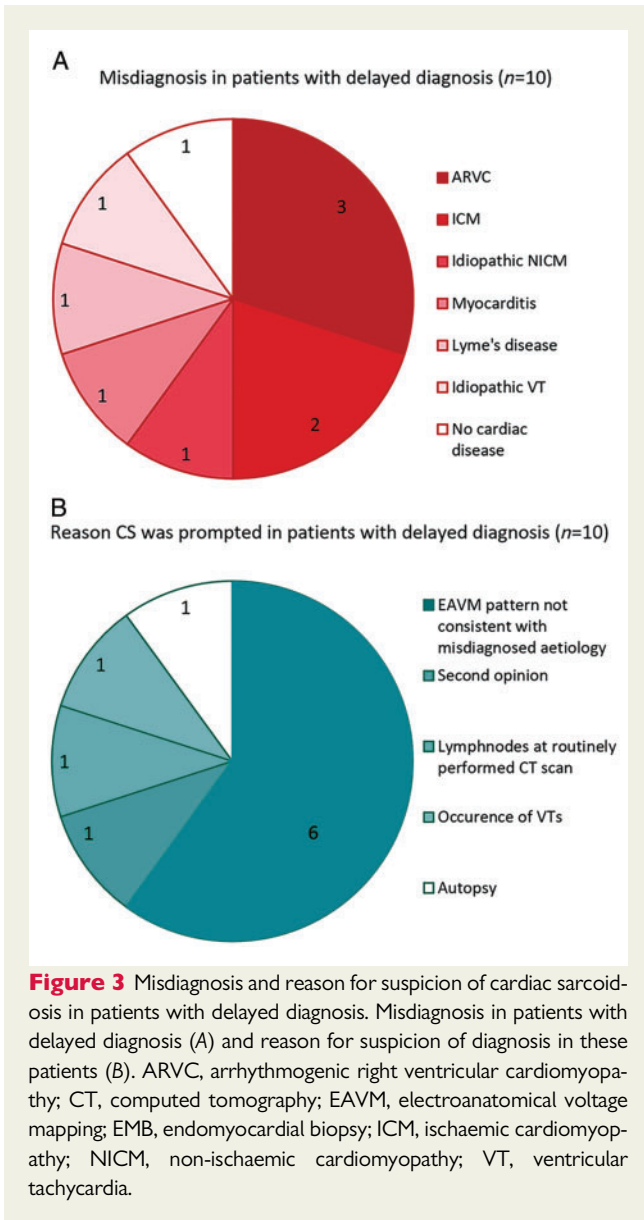
## Discussion

This study aimed to evaluate the diagnostic- and disease course of patients with arrhythmogenic cardiac sarcoidosis. The main findings can be summarized as follows: (i) cardiac sarcoidosis is an important differential diagnosis in patients referred for VT ablation with a prevalence of 12% among patients with ‘idiopathic’ non-ischaemic cardiomyopathy, (ii) in 67% of patients, the diagnosis of ACS was delayed, despite typical presentation with VT or AV-block, (iii) in none of the patients with delayed diagnosis <sup>18</sup>F-FDG-PET was performed at first presentation, (iv) in 60% of patients with delayed diagnosis, CS was suspected after electroanatomical voltage mapping, (v) delayed diagnosis of ACS had harmful consequences, with irreversible deterioration of cardiac function in 60% and a high mortality (50%).

### Cardiac sarcoidosis as underlying aetiology in patients presenting with ventricular tachycardia

Ventricular arrhythmias are a typical clinical manifestation of CS. Retrospective studies have shown a prevalence of 5–8% among patients with non-ischaemic cardiomyopathy (NICM) referred for ablation of ventricular arrhythmias.<sup>12,13</sup> Interestingly, prospective studies performing <sup>18</sup>F-FDG-PET in all patients presenting with monomorphic sustained VT with idiopathic NICM, report a definite diagnosis of CS in up to 17–29% of patients.<sup>14,15</sup> The current study shows a prevalence of 12% in a retrospective idiopathic NICM cohort referred for VT ablation (both left- and right-sided) after exclusion of all other known causes. This is slightly higher than in previous retrospective studies, which can be explained by the comprehensive evaluation of our patients referred for ablation, including genetic testing and detailed EAVM substrate mapping.<sup>16</sup>

Importantly, CS is not only an important differential diagnosis in patients referred for VT ablation, but also in patients presenting with ventricular arrhythmias. In our population, 67% of patients had an early arrhythmogenic presentation, frequently without additional AV conduction abnormalities. This high proportion of patients presenting with VT as initial symptom without previous AV block, can be partly



explained by the inclusion criteria. Atrioventricular block is the most frequent cardiac presentation of CS. Of interest, in a Finnish registry including symptomatic CS patients, 33% presented with ventricular arrhythmias (including sudden cardiac death) without additional AV block,<sup>4</sup> suggesting that VT *without* AV block is not a rare finding. Moreover, in a population more similar to this series, namely a VT ablation population, 74% of patients had a first presentation with ventricular arrhythmias (including premature ventricular complexes (PVCs) and non-sustained VTs)<sup>10</sup>

Strikingly, in the current study, electroanatomical voltage mapping (EAVM) prompted suspicion for CS in 60% of cases with delayed diagnosis. At EAVM, patients with CS seem to have a more patchy and better demarcated scar pattern compared to other aetiologies,<sup>13,17,18</sup> which is in line with autopsy findings.<sup>1</sup> This, together with the high prevalence among patients referred for VT ablation and the frequency of arrhythmias as first presentation, supports the important role of electrophysiologists in diagnosing CS as underlying aetiology.

## Arrhythmogenic cardiac sarcoidosis is initially frequently misdiagnosed

In our cohort, the diagnosis of CS was significantly delayed in 67% of patients with a median time of 24 months, comparable with previous studies in patients with CS. In patients with 2nd or 3rd degree AV block, 56% of patients had a delay in diagnosis of CS, with a median time to diagnosis of 23 months.<sup>4</sup> In a VT-ablation cohort, a median delay of 24 months has been described.<sup>10</sup>

There are several explanations for this important delay. First, CS is known as the great masquerader, which can mimic other cardiac conditions.<sup>7,8</sup> Second, the diagnostic yield of EMB for showing the gold standard for diagnosis, the typical non-necrotizing granulomas,<sup>5,6</sup> is low (although can be increased by cumulative EMB and mapping-guided biopsy).<sup>3,5</sup> However, in 90% of patients with delayed diagnosis in our population, EMB was not performed at first cardiac presentation because CS was not suspected.

Third, with evolving imaging techniques, diagnosis can also be made with <sup>18</sup>F-FDG-PET and/or CMR, but, similarly to biopsy, in none of the studied patients with delayed diagnosis <sup>18</sup>F-FDG-PET was performed. This is comparable with a previous report including CS patients presenting with a complete AV-block, where in none of the patients with delayed diagnosis <sup>67</sup>Ga Scintigraphy and/or <sup>18</sup>F-FDG-PET was performed.<sup>19</sup>

Last, the diagnosis might be confirmed by positive extracardiac histology with cardiac symptoms, but extracardiac symptoms are frequently absent.<sup>3,19</sup> However, despite absence of extracardiac complaints or involvement, it can be worthwhile to perform additional pulmonary diagnostic testing. A mediastinal lymphnode biopsy and/or bronchoalveolar lavage confirmed diagnosis in 84% of patients with suspected CS without extracardiac complaints, regardless of imaging findings.<sup>20</sup>

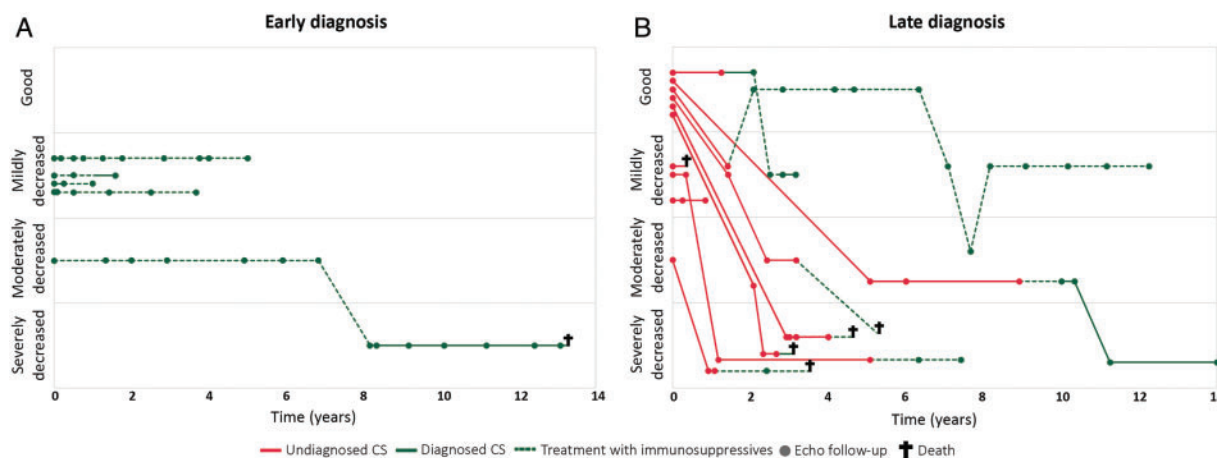
To conclude, a delay in diagnosing CS is not only due to diagnostic challenges, but can be mainly attributed to the fact that diagnostic tests (such as biopsy and/or <sup>18</sup>F-FDG-PET) are not initiated. Therefore, major improvement may be achieved by a comprehensive evaluation of all patients with a VT substrate of unknown aetiology.

## Harmful consequences of delayed diagnosis

Interestingly, patients with early diagnosis had a relatively preserved cardiac function when started on treatment and function remained stable. On the contrary, 60% of patients with delayed diagnosis had already a moderately to severely decreased function at the time of diagnosis, which did not improve despite immunosuppressive treatment.

Previously, in patients with CS presenting with complete AV-block, the same trend was observed with a benefit of early diagnosis.<sup>19</sup> Although patient populations are small, corticosteroid therapy seems to maintain cardiac function in patients with preserved function, improve function in patients with mild-moderate dysfunction and does not have effect in patients with severely decreased function.<sup>21</sup> These findings suggest that there may be a tipping point, after which cardiac function is beyond repair.

Hence, delayed diagnosis of ACS is likely to have harmful consequences leading to irreversible cardiac dysfunction, higher morbidity



**Figure 4** Cardiac function over time. Cardiac function from first cardiac presentation until last follow-up or death in patients with early diagnosis (A) and late diagnosis (B). Red lines indicate undiagnosed cardiac sarcoidosis (CS), green lines indicate diagnosed CS, and dashed lines show treatment with immunosuppressive therapy.

(more VT ablation and heart failure admissions) and higher mortality. Based on our study results, we strongly recommend to perform additional diagnostic tests (LGE-CMR and  $^{18}\text{F}$ -FDG-PET) in every patient presenting with VT of unknown aetiology. If the  $^{18}\text{F}$ -FDG-PET shows extracardiac FDG-uptake, we aim to obtain extracardiac histological confirmation. If there is no extracardiac FDG-uptake, we have currently introduced mapping-guided biopsy.<sup>22</sup>

## Limitations

This is a retrospective case series with a small sample size from a tertiary referral centre. Therefore, the overall prevalence of CS among patients referred for VT ablation might be overestimated. However, the prevalence might also be underestimated, since not all idiopathic NICM patients underwent LGE-CMR,  $^{18}\text{F}$ -FDG-PET and/or biopsies and a negative  $^{18}\text{F}$ -FDG-PET does not exclude the presence of CS. In addition, the included patients were from a highly selected population (referred for VT ablation) and therefore described results cannot be extrapolated to other cohorts.

## Conclusion

Arrhythmogenic CS (ACS) is an important differential diagnosis in patients presenting with VT and/or referred for VT ablation. A delayed diagnosis has harmful consequences, including irreversible deterioration of cardiac function and a high mortality. Early recognition (among electrophysiologists) is highly warranted.

## Supplementary material

Supplementary material is available at *Europace* online.

## Funding

The Department of Cardiology from Leiden University Medical Center receives unrestricted grants from Edwards Lifesciences, Biotronik, Medtronic, Boston Scientific and BioSense Webster.

**Conflict of interest:** none declared.

## References

1. Tavora F, Cresswell N, Li L, Ripple M, Solomon C, Burke A. Comparison of necropsy findings in patients with sarcoidosis dying suddenly from cardiac sarcoidosis versus dying suddenly from other causes. *Am J Cardiol* 2009;**104**:571–7.
2. Mehta D, Lubitz SA, Frankel Z, Wisnivesky JP, Einstein AJ, Goldman M et al. Cardiac involvement in patients with sarcoidosis: diagnostic and prognostic value of outpatient testing. *Chest* 2008;**133**:1426–35.
3. Kandolin R, Lehtonen J, Airaksinen J, Vihinen T, Miettinen H, Ylitalo K et al. Cardiac sarcoidosis: epidemiology, characteristics, and outcome over 25 years in a nationwide study. *Circulation* 2015;**131**:624–32.
4. Nordenswan HK, Lehtonen J, Ekstrom K, Kandolin R, Simonen P, Mayranpaa M et al. Outcome of cardiac sarcoidosis presenting with high-grade atrioventricular block. *Circ Arrhythmia Electrophysiol* 2018;**11**:e006145.
5. Birnie DH, Sauer WH, Bogun F, Cooper JM, Culver DA, Duvernoy CS et al. HRS expert consensus statement on the diagnosis and management of arrhythmias associated with cardiac sarcoidosis. *Heart Rhythm* 2014;**11**:1304–23.
6. Terasaki F, Yoshinaga K. New guidelines for diagnosis of cardiac sarcoidosis in Japan. *Ann Nucl Cardiol* 2017;**3**:42–5.
7. Philips B, Madhavan S, James CA, Te Riele AS, Murray B, Tichnell C et al. Arrhythmogenic right ventricular dysplasia/cardiomyopathy and cardiac sarcoidosis: distinguishing features when the diagnosis is unclear. *Circ Arrhythm Electrophysiol* 2014;**7**:230–6.
8. Roberts WC, Roberts CC, Ko JM, Filardo G, Capehart JE, Hall SA. Morphologic features of the recipient heart in patients having cardiac transplantation and analysis of the congruence or incongruence between the clinical and morphologic diagnoses. *Medicine (Baltimore)* 2014;**93**:211–35.
9. Padala SK, Peaslee S, Sidhu MS, Steckman DA, Judson MA. Impact of early initiation of corticosteroid therapy on cardiac function and rhythm in patients with cardiac sarcoidosis. *Int J Cardiol* 2017;**227**:565–70.
10. Muser D, Santangeli P, Pathak RK, Castro SA, Liang JJ, Magnani S et al. Long-term outcomes of catheter ablation of ventricular tachycardia in patients with cardiac sarcoidosis. *Circ Arrhythmia Electrophysiol* 2016;**9**:e004333.
11. Yazaki Y, Isobe M, Hiroe M, Morimoto M, Hiramitsu S, Nakano T et al. Prognostic determinants of long-term survival in Japanese patients with cardiac sarcoidosis treated with prednisone. *Am J Cardiol* 2001;**88**:1006–10.
12. Koplan BA, Soejima K, Baughman K, Epstein LM, Stevenson WG. Refractory ventricular tachycardia secondary to cardiac sarcoid: electrophysiologic characteristics, mapping, and ablation. *Heart Rhythm* 2006;**3**:924–9.
13. Kumar S, Barbhaiya C, Nagashima K, Choi EK, Epstein LM, John RM et al. Ventricular tachycardia in cardiac sarcoidosis: characterization of ventricular substrate and outcomes of catheter ablation. *Circ Arrhythm Electrophysiol* 2015;**8**:87–93.
14. Tung R, Bauer B, Schelbert H, Lynch JP 3rd, Auerbach M, Gupta P et al. Incidence of abnormal positron emission tomography in patients with



- unexplained cardiomyopathy and ventricular arrhythmias: the potential role of occult inflammation in arrhythmogenesis. *Heart Rhythm* 2015;**12**:2488–98.
15. Nery PB, Mc Ardle BA, Redpath CJ, Leung E, Lemery R, Dekemp R et al. Prevalence of cardiac sarcoidosis in patients presenting with monomorphic ventricular tachycardia. *Pacing Clin Electrophysiol* 2014;**37**:364–74.
  16. Ebert M, Wijnmaalen AP, De Riva M, Van Tintelen JP, Androulakis A, Trines SA et al. The impact of genetic mutations on ventricular tachycardia substrate types and ablation outcome in patients with non ischemic cardiomyopathy. *Europace* 2018;**20**:i99.
  17. Hoogendoorn JC, Sramko M, Venlet J, Siontis KC, Kumar S, Singh R et al. Electroanatomical voltage mapping to distinguish right-sided cardiac sarcoidosis from arrhythmogenic right ventricular cardiomyopathy. *J Am Coll Cardiol* 2020; doi:10.1016/j.jacep.2020.02.008.
  18. Hoogendoorn JC, Sramko M, Venlet J, Siontis KC, Kumar S, Bogun F et al. Endocardial voltage ratio can distinguish right-sided cardiac sarcoidosis from arrhythmogenic right ventricular cardiomyopathy. *Europace* 2019;**21**(Supplement\_2):ii177.
  19. Kaida T, Inomata T, Minami Y, Yazaki M, Fujita T, Iida Y et al. Importance of early diagnosis of cardiac sarcoidosis in patients with complete atrioventricular block. *Int Heart J* 2018;**59**:772–8.
  20. Petek BJ, Rosenthal DG, Patton KK, Behnia S, Keller JM, Collins BF et al. Cardiac sarcoidosis: diagnosis confirmation by bronchoalveolar lavage and lung biopsy. *Respir Med* 2018;**144**:S13–s9.
  21. Sadek MM, Yung D, Birnie DH, Beanlands RS, Nery PB. Corticosteroid therapy for cardiac sarcoidosis: a systematic review. *Can J Cardiol* 2013;**29**:1034–41.
  22. Vaidya VR, Abudan AA, Vasudevan K, Shantha G, Cooper LT, Kapa S et al. The efficacy and safety of electroanatomic mapping-guided endomyocardial biopsy: a systematic review. *J Interv Card Electrophysiol* 2018;**53**:63–71.

## EP CASE EXPRESS

doi:10.1093/europace/eaab109

Online publish-ahead-of-print 13 July 2020

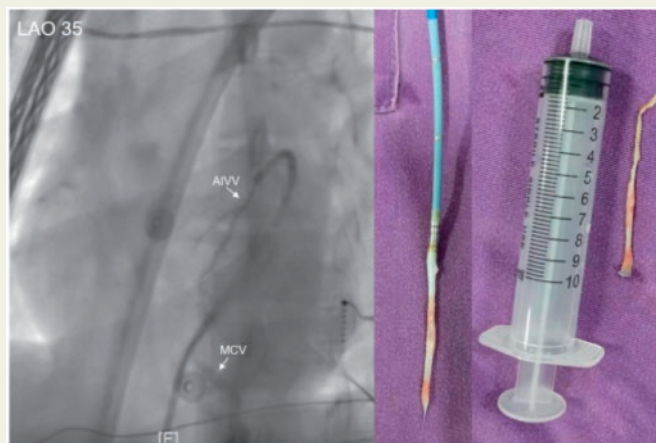
### Avulsion of coronary sinus after mapping in the great cardiac vein

Ligang Ding<sup>1\*</sup>, Shucheng Li<sup>2</sup>, Xiansheng Huang<sup>2</sup>, Chunhui Li<sup>2</sup>, Hong Wang<sup>2</sup>, and Yan Yao<sup>1</sup>

<sup>1</sup>Cardiac Arrhythmia Center, Fuwai Hospital, National Center for Cardiovascular Diseases, Chinese Academy of Medical Sciences and Peking Union Medical College, 167 Beilishi Road, Xicheng, Beijing 100037, China; and <sup>2</sup>Department of Cardiology, Affiliated Hospital of Chengde Medical College, Chengde, Hebei Province, China

\* Corresponding author. Tel: +86-010 88322408. E-mail address: dligang101@163.com

A 21-year-old woman was referred for catheter ablation of a symptomatic premature ventricular contraction (PVC). Twelve-lead electrocardiography of outflow tract PVC showed with an R wave pattern break in the precordial leads V2 suggesting an origin close to the anterior interventricular sulcus. Mapping and ablation were initially performed in right ventricular outflow tract and left coronary cusp using a 3.5-mm tip catheter (ThermoCool SmartTouch; Biosense Webster, Diamond Bar, CA, USA) but had no effect on the PVCs. Then the great cardiac vein (GCV) mapping was performed, the catheter was wedged into the distal GCV and failed to be pulled back. Isosorbide dinitrate and lidocaine were injected repeatedly, but the catheter could not be retracted completely. Sustained traction for 10 min gradually freed the catheter with avulsion of the GCV intima (Figure). The distal coronary sinus could not be visualized by retrograde venography suggesting possible thrombus formation. No pericardial effusions occurred during the observation, and the chest pain improved finally. To our knowledge, this is the first case report about the GCV avulsion due to the stuck catheter.



The full-length version of this report can be viewed at: <https://www.escardio.org/Education/E-Learning/Clinical-cases/Electrophysiology>.

Published on behalf of the European Society of Cardiology. All rights reserved. © The Author(s) 2020. For permissions, please email: [journals.permissions@oup.com](mailto:journals.permissions@oup.com).