



Universiteit
Leiden
The Netherlands

Associations of lumbar scoliosis with presentation of suspected early axial spondyloarthritis

Voirin-Hertz, M.; Alegria, G.C.; Garrigues, F.; Simon, A.; Feydy, A.; Reijnierse, M.; ... ; Saraux, A.

Citation


Voirin-Hertz, M., Alegria, G. C., Garrigues, F., Simon, A., Feydy, A., Reijnierse, M., ... Saraux, A. (2020). Associations of lumbar scoliosis with presentation of suspected early axial spondyloarthritis. *Seminars In Arthritis And Rheumatism*, 50(1), 48-53.
doi:10.1016/j.semarthrit.2019.06.008

Version: Publisher's Version

License: [Creative Commons CC BY 4.0 license](https://creativecommons.org/licenses/by/4.0/)

Downloaded from: <https://hdl.handle.net/1887/3182973>

Note: To cite this publication please use the final published version (if applicable).



Associations of lumbar scoliosis with presentation of suspected early axial spondyloarthritis

Marie Voirin-Hertz^{a,1}, Guillermo Carvajal Alegria^{a,1}, Florent Garrigues^b, Alexandre Simon^c, Antoine Feydy^d, Monique Reijnierse^e, Désirée van der Heijde^f, Damien Loeuille^g, Pascal Claudepierre^{h,i}, Thierry Marhadour^a, Alain Saraux^{a,j,*}

^a Rheumatology Unit, CHU Brest, BP 824, F-29609 Brest Cedex, France

^b Radiology Unit, CHU brest, Brest 29609, France

^c Neurosurgery Unit, CHU Brest, Brest 29609, France

^d Radiology B Department, Paris Descartes University, AP-HP, Cochin Hospital, Paris, France

^e Department of Radiology, Leiden University Medical Center, Leiden, the Netherlands

^f Department of Rheumatology, Leiden University Medical Center, Leiden, the Netherlands

^g Department of Rheumatology, CHU Nancy, France

^h AP-HP, Groupe Hospitalier Henri-Mondor, Service de Rhumatologie, Créteil 94000, France

ⁱ Université Paris Est Créteil, EA 7379 – EpidermE, Créteil 94000, France

^j INSERM 1227, Université de Bretagne Occidentale, LabEx IGO, Brest, France

ARTICLE INFO

Keywords:

Ankylosing spondylitis
Axial spondyloarthritis
Lumbar scoliosis
Lumbar lordosis
Sacral slope
Degenerative disease

ABSTRACT

Objective: Scoliosis may impact the mechanical loading and cause secondary changes of the sacroiliac joints and lumbar spine. Our goal was to look how lumbar scoliosis modify the clinical and imaging-study in patients with recent-onset inflammatory back pain (IBP) suggesting axial spondyloarthritis (axSpA).

Methods: Baseline weight-bearing lumbar-spine radiographs obtained in the DESIR cohort of patients aged 18–50 years and having IBP for at least 3 months but less than 3 years suggesting axSpA were studied. After training on scoliosis detection based on Cobb's angle >10° plus Nash–Moe grade ≥1, readers blinded to patient data measured spine lumbar scoliosis, sacral horizontal angle, lumbosacral angle and lumbar lordosis on the radiograph of the lumbar and scored sacroiliitis on the radiograph of the pelvis. Baseline MRIs T1 and STIR of the lumbar spine and sacroiliac joints were evaluated for respectively degenerative changes and signs of axSpA.

Results: Of the 360 patients (50.8% females) 88.7% had lumbar pain and 69.3% met ASAS criteria for axSpA. Mean Cobb's angle was 3.2° ± 5.0° and 28 (7.7%) patients had lumbar scoliosis. No statistical differences were observed for radiographic sacroiliitis, MRI sacroiliitis, modified Stoke Ankylosing Spondylitis Spinal Score, Pfirrmann score, high-intensity zone, protrusion, extrusion, MODIC score between patients with and without scoliosis. In both groups, degenerative changes by MRI were rare and predominated at L4–L5 and L5–S1.

Conclusion: In patients with early IBP suggesting axSpA, lumbar scoliosis was not associated with inflammatory or degenerative changes.

© 2019 Elsevier Inc. All rights reserved.

Significance and innovations

- A normal to low prevalence of 7.7% lumbar scoliosis is found in patients between 18 and 50 years who had early IBP in the DESIR cohort.
- Lumbar scoliosis is not associated with changes in clinical or imaging-study findings in this context.

- Lumbar scoliosis is not associated with secondary changes to mechanical loading as sclerosis or BME of the sacroiliac joints.
- Lumbar scoliosis has no impact on the MR diagnosis of sacroiliitis on radiographs and MRI sacroiliac joints.

Introduction

Back pain has a lifetime prevalence of 70% in the general population [1,2]. In most patients, back pain is a nonspecific symptom that is related to mechanical factors whose exact cause is identified in fewer than half the cases [3].

Scoliosis [4] is a three-dimensional spinal deformity that can cause back pain. The main diagnosis criterion is a coronal curvature with a

* Corresponding author at: Rheumatology Unit, CHU Brest, Hôpital de la Cavale Blanche, BP 824, F-29609 Brest Cedex, France.

E-mail address: alain.saraux@chu-brest.fr (A. Saraux).

¹ These two authors contributed equally to the work and should be considered co-first authors.

Cobb's angle greater than 10° on the anteroposterior radiograph. In addition, the assessment of pedicle position according to the Nash–Moe technique shows vertebral rotation (Nash–Moe grade >1) [1,5,6]. The prevalence of scoliosis has been estimated at 1–3%. Idiopathic scoliosis accounts for about 80% of all structural coronal deformities, with a prevalence of 1–2% among schoolchildren up to age 15. In adults, the prevalence of idiopathic scoliosis has been reported to increase with age from 8% starting at 25 years to 68% between 60 and 80 years, due in part to the development of degenerative spinal lesions (1) [2,8–14]. Scoliosis causes multifactorial low back pain, whose typically mechanical pattern may be combined with an inflammatory component, for instance in the event of vertebral endplate edema [3,7]. The pain may be chronic or recurrent. Scoliosis also restricts spinal mobility.

Degenerative disease of the spine on radiographs has a high prevalence in the general population with back pain (121 to 274, 44%) and clinical correlation with MR imaging findings is low [15]. These include dehydration of discs and loss of disc height, a high-intensity zone (HIZ) in the posterior annulus of the disk, disk herniation, Modic type vertebral endplate changes, facet-joint osteoarthritis, interspinous bursitis (rare and not scored by us), degenerative spondylolysis [3]. The presence of scoliosis accelerates the development of degenerative changes of the spine. In addition the change the mechanical loading may cause secondary changes in the sacroiliac (SI) joints as reactive sclerosis or bone marrow edema.

In axial spondyloarthritis (axSpA), back pain is a key manifestation. Thus, inflammatory back pain (IBP) in younger patients predominantly suggests axSpA. The early diagnosis of axSpA is challenging and relies on a convergence of evidence from the medical history, physical examination, laboratory tests, and imaging studies [16–19]. Degenerative changes are common in the general population and in axSpA. Thus, in the SPACE cohort, 90% of patients classified as having possible or definite axSpA also had degenerative changes by MRI, which predominated at the lumbar spine [15]. However, the prevalence of lumbar scoliosis in patients with axSpA has not been reported. Furthermore, no data exist on whether scoliosis is associated with differences in the clinical and/or imaging-study presentation of axSpA.

Our objective here was to evaluate whether lumbar scoliosis was associated with differences in clinical manifestations, imaging-study findings, and/or the degree of axSpA diagnosis certainty in the DESIR cohort of patients with recent-onset IBP and suspected axSpA.

Patients and methods

The DESIR cohort

DESIR (DEvenir des Spondyloarthropathies Indifférenciées Récentes) is a French prospective, multicenter, cohort established between October 2007 and April 2010. Adults aged 18 to 50 years were included if they had inflammatory pain in the thoracic spine, lumbar spine, and/or buttock(s) meeting Calin and/or Berlin criteria [16], of more than 3 months' but less than 3 years' duration, leading to a determination by the local investigator that the probability of axSpA was at least 5 on a 0–10 numerical rating scale (0, not suggestive at all; 10, highly suggestive). The baseline characteristics of the patients are described in detail elsewhere [20,21].

The DESIR cohort study complied with good clinical practice guidelines, was registered on ClinicalTrials.gov (NCT0164 8907), and was approved by the appropriate ethics committee (CPP Ile-de-France III, submission number P070302). Before study inclusion, each patient gave written informed consent and permission to publish any individual anonymized data. A detailed description of the study protocol is available online at <http://www.lacohortedesir.fr/desir-in-english/>. The research project was approved by the DESIR scientific committee. For this study, the database was locked in 2014. Standing, weight-bearing, antero-posterior radiographs of the lumbar spine were used.

Assessment of imaging studies

Evaluation of scoliosis

We used Cobb's angle [1,5,6] to quantify spinal curvature in the frontal plane and the Nash–Moe grade to assess vertebral rotation. Cobb's angle is subtended by the line along the superior endplate of the vertebra at the top of the curve and a line along the inferior endplate of the vertebra at the bottom of the curve. The Nash–Moe grade based on pedicle shadow position reflects the degree of rotation of the vertebra at the apex of the curve; the grade can range from 0 (no rotation) to 4 (major rotation) [5,6]. Two rheumatology fellows (MVH and GCA) received training from a spine specialist then evaluated the baseline anteroposterior lumbar-spine radiograph (in DICOM format) of each patient for evidence of scoliosis (Fig. 1), on two separate occasions separated by at least 2 days. Patients with a Cobb's angle $\geq 10^\circ$ and a Nash–Moe grade ≥ 1 were classified as having scoliosis and other patients as being free of scoliosis [1,5,6]. Disagreements between the two readers (scoliosis yes/no) were resolved by having the spine specialist (TM) repeat the measurements.

Evaluation of degenerative disease

As part of the DESIR cohort data collection process, the baseline lumbar-spine radiograph and MRI scan of each patient had been previously assessed for degenerative changes by two readers blinded to all patient data [15]. Radiographic degenerative changes were recorded as present/absent at L3–L4, L4–L5, and L5–S1, as they are the most affected by degenerative changes. The MRI scans were also assessed for disk degeneration, Modic changes, Pfirrmann grade, canal stenosis, disk herniation/extrusion, HIZ, facet-joint osteoarthritis, spondylolysis, and Schmorl's nodes at L3–L4, L4–L5, and L5–S1. For this study, Pfirrmann grades I and II were considered normal and grades III, IV, or V as indicating degenerative disease; disagreements between the two readers were resolved by a third reader.

Angle measurements

For another DESIR cohort substudy [22], two readers used the baseline lateral lumbar-spine radiographs to measure sacral horizontal angle (SH, also known as sacral slope SS) as the angle formed by the line along the upper endplate of S1 and the horizontal plane, Lumbosacral angle (LS) formed by two lines drawn along the lower L5 endplate and upper S1 endplate, lumbar lordosis (LL) formed by the lines drawn along the upper endplates of L1 and S1, [22–24]. The values were used for the present study.

Imaging abnormalities suggesting axSpA

We also compared the right or left curved scoliosis to the right and left sacroiliac joints joint for grade of sclerosis on radiograph and bone marrow edema on sacroiliac MRI. As part of the DESIR cohort data collection process, baseline radiographs of the spine and pelvis were used to assess New-York modified criteria for sacroiliitis [25], the modified Stoke Ankylosing Spondylitis Spinal Score (mSASSS score) [26], and the Bath Ankylosing Spondylitis Radiology Index (BASRI) [27]; baseline MRI scans were evaluated for evidence of sacroiliitis [28] and determination of the sacroiliac and spinal SPondyloARthritis Research Consortium of Canada MRI inflammation (SPARCC) score [29,30]. Ranges of the scoring systems are included in the tables showing the results.

Statistical analysis

Intraobserver repeatability and interobserver reproducibility of the diagnosis of scoliosis were estimated by computing the kappa coefficients, which were interpreted according to Landis and Koch (0.61–0.80, substantial agreement; and 0.81–1, near perfect agreement). Patients with and without scoliosis were compared regarding the clinical presentation (demographics, pain pattern, spinal mobility,

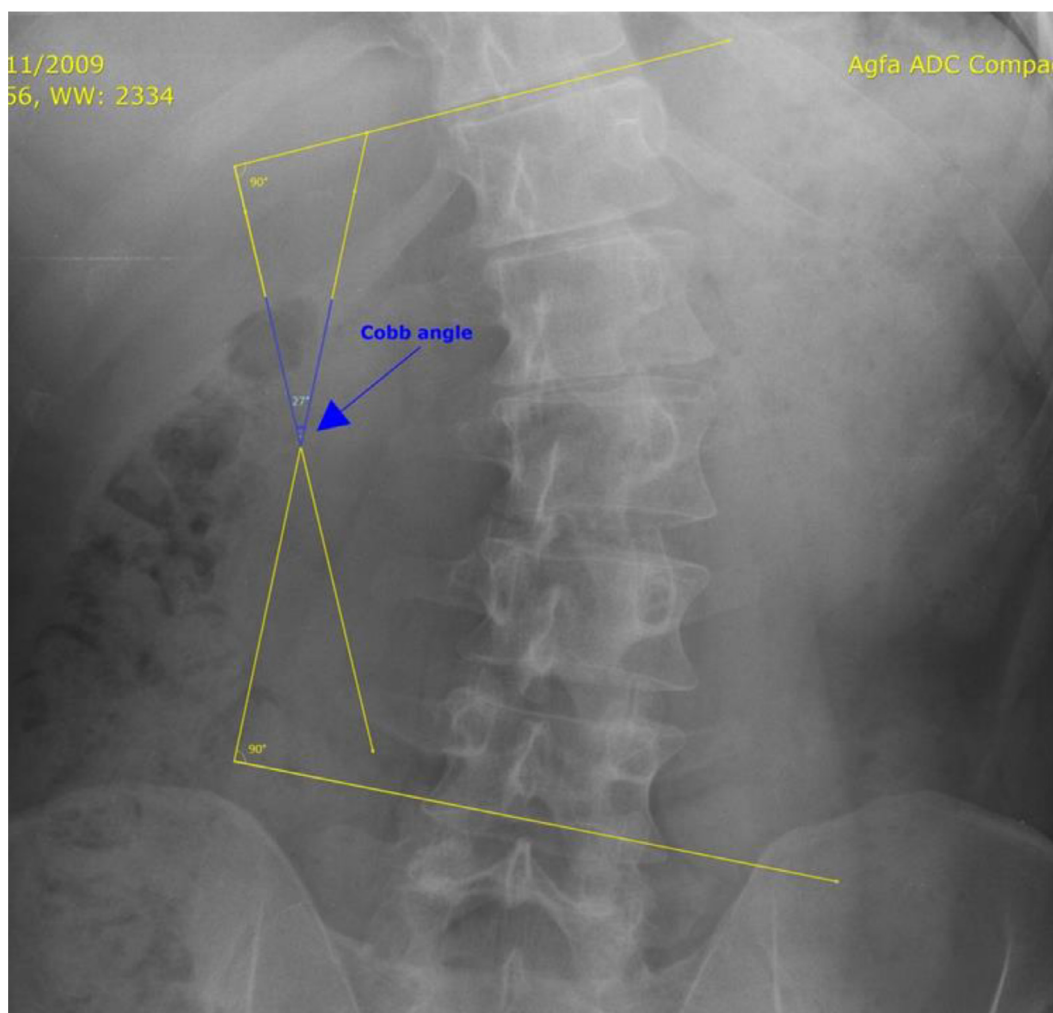


Fig. 1. Cobb's angle measurement on an anteroposterior radiograph of the lumbar spine.

and other features), the prevalence of degenerative disease (presence or absence) visible radiographically and by MRI, and the degree of confidence in a diagnosis of axSpA. All data were evaluated at baseline. Associations between these variables and scoliosis were sought by univariate analysis using the chi-square test (or Fisher's exact test when appropriate) or the Mann–Whitney test. We also verified that Cobb's angle was not correlated to either mSASSS or grade of sacroiliitis on X-rays using the Spearman's coefficient.

With Bonferroni's correction, P values <0.001 were required to indicate significant differences. Statistical analyses were performed using SPSS 23.0 software (IBM, Armonk, NY).

Results

Study group

From the DESIR cohort, 362 patients with available standing, weight-bearing, anteroposterior lumbar-spine radiographs were included in the study. Mean Cobb's angle was $3.2^\circ \pm 5.0^\circ$, with a maximum of 32° . Of the 362 patients, 28 (7.7%) had scoliosis. The Nash–Moe grade was I or II in all patients. No patient had severe scoliosis. In the overall patient population, the intraobserver kappa coefficient was 1, indicating perfect agreement, and the interobserver kappa coefficient was 0.7, indicating substantial agreement.

The baseline characteristics of the 362 patients were similar to those of the entire cohort (supplementary Table 1): mean age was 33.2 ± 8.4 and 50.8% of patients were female; 88.7% of patients had

low back pain and 72.7% had buttock pain. The ASAS classification criteria for axSpA were met by 69.3% of patients at baseline (Table 1). No patient had spondylolysis and very few patients had spondylolisthesis, Modic changes, canal stenosis, or facet-joint osteoarthritis.

Associations of scoliosis with clinical presentation and confidence in a diagnosis of axSpA

Table 2 compared the clinical characteristics in the groups with and without scoliosis. No statistically significant differences were found for demographic data, site or features of the pain, or motion range of the lumbar spine. Neither range of motion of the lumbar spine nor the degree of confidence in a diagnosis of axSpA differed between the two groups.

Associations of scoliosis with imaging-study abnormalities

Table 3 reports the results of tests for associations linking scoliosis to SS and TLA values measured on radiographs and to MRI signs of degenerative disease. Overall, MRI abnormalities were extremely uncommon, with no significant between-group differences; for each abnormality, the numbers were too small for statistical analyses. Except for Schmorl's nodes, the MRI abnormalities predominated at L4–L5 and L5–S1.

TLA was non-significantly greater in the group with scoliosis (58.9° vs. 52.4° , $P=0.009$). SS was non-significantly greater in the group with scoliosis (42.2° vs. 39.0° , $P=0.03$).

Table 1
Main patient characteristics at baseline (n = 362)

Age (years), mean ± SD	33.2 ± 8.4
Males, n (%)	178 (49.2%)
BMI (m/kg ²), mean ± SD	24.1 ± 4.3
Low-back pain, ^a n (%)	321 (88.7%)
Buttock pain, ^a n (%)	263 (72.7%)
Morning stiffness (Berlin criteria), n/N (%)	329 (90.9%)
Nocturnal pain (Berlin criteria), n/N (%)	319 (88.1%)
Modified Schober test (10 + Xcm), mean ± SD	3.7 ± 1.1
Finger-floor distance (cm), mean ± SD	13.0 ± 12.9
HLA B27 positivity, n (%) (n = 674)	224 (61.9%)
ASAS criteria, n (%) (n:669)	251 (69.3%)
Confidence in a diagnosis of SpA at baseline, ^b mean ± SD	7.4 ± 2.1
Sacral horizontal angle, °, mean ± SD	39.3 ± 9.2
Lumbosacral angle, °, mean ± SD	14.6 ± 4.6
Lumbar Lordosis, °, mean ± SD	53.0 ± 13.1
Lumbar scoliosis, n (%)	28 (7.7%)

BMI, body mass index; HLA, human leukocyte antigen; ASAS, Assessment of SpondyloArthritis international Society; SpA, spondyloarthritis.

^aInclusion criterion.

^bAssessed on a 1–10 scale by the investigator at each study center.

Table 2
Associations of scoliosis with the clinical presentation and confidence in a diagnosis of axSpA at baseline; ASAS criteria and confidence in a diagnosis of spondyloarthritis are also reported after 2 years

Characteristics	No scoliosis N = 327	Scoliosis N = 28	P value
Age (years), mean ± SD	33.2 ± 8.4	31.9 ± 7.5	0.49
Males, n (%) (N = 327)	163 (49.8)	12 (42.9)	0.48
Weight (kg), mean ± SD	70.3 ± 13.4	67.0 ± 15.6	0.23
Height (cm), mean ± SD	170.2 ± 9.3	168.6 ± 10.3	0.46
BMI (m/kg ²), mean ± SD	24.1 ± 4.3	24.3 ± 3.4	0.41
Low back pain, n (%) (N = 327)	289 (88.4)	26 (92.9)	0.47
Buttock pain, n (%) (N = 327)	241 (73.7)	18 (62.3)	0.28
Morning stiffness (Berlin criteria), n (%) (N = 327)	301 (92.0)	22 (78.6)	0.02
Nocturnal pain (Berlin criteria), n (%)	287 (87.8)	26 (92.9)	0.42
Modified Schober test (10+Xcm), mean ± SD	3.7 ± 1.1	3.5 ± 1.0	0.18
Finger-floor distance (cm), mean ± SD	12.9 ± 12.8	15.6 ± 14.2	0.23
HLA B27 positivity, n (%)	202 (61.8)	19 (67.8)	0.52
ASAS criteria met at baseline, n (%)	226/325 (69.5)	22 (78.6)	0.32
Confidence in a diagnosis of SpA at baseline, mean ± SD ^a	7.3 ± 2.1	8.0 ± 2.1	0.06

BMI, body mass index; HLA, human leukocyte antigen; ASAS, Assessment of SpondyloArthritis international Society; SpA, spondyloarthritis.

^aInclusion criterion.

^bAssessed on a 1–10 scale by the investigator at each study center.

Scoliosis was not associated with abnormalities suggesting axSpA by radiography (New York criteria, mSASSS score, BASRI score and SPARCC score) or MRI (ASAS criteria and SPARCC score) (Table 4). The Cobb's angle was not correlated to either mSASSS ($r = -0.28$, $p = 0.61$) or grade of sacroiliitis on X-rays (left: $r = 0.60$, $p = 0.26$; right: $r = 0.01$, $p = 0.78$).

Discussion

In this study, lumbar scoliosis was not significantly associated with the clinical or imaging-study features of patients with early IBP. Thus, patients with and without scoliosis did not differ regarding nocturnal pain, morning stiffness according to the Berlin criteria, chronicity of the symptoms, and confidence in a diagnosis of axSpA. Moreover, the proportion of patients meeting ASAS criteria was the same in the two groups, indicating that lumbar scoliosis did not increase the risk of mistakenly diagnosing axSpA in this population of patients in whom the local investigators rated the likelihood of axSpA at 5 or more on a 10-point scale [32].

Lumbar scoliosis might be expected to diminish the range of forward bending. In a study of adolescent idiopathic scoliosis, forward

Table 3
Associations of scoliosis with radiographic sagittal balance and MRI signs of degenerative disease at baseline

Characteristics at baseline	No scoliosis (n = 306)	Scoliosis (n = 27)	P value
Pfirschmann L3–L4 ≥ 3, n (%)	14 (4.6)	2 (7.4)	0.51
Pfirschmann L4–L5 ≥ 3, n (%)	46 (15.0)	2 (7.4)	0.28
Pfirschmann L5–S1 ≥ 3, n (%)	75 (24.5)	6 (22.2)	0.79
HIZ L3–L4, n (%)	5 (1.6)	0 (0.0)	0.5
HIZ L4–L5, n (%)	45 (12.5)	0 (0.0)	0.32
HIZ L5–S1, n (%)	62 (20.3)	3 (11.1)	0.25
Protrusion L3–L4, n/ (%)	6 (2.0)	0 (0.0)	1.00
Protrusion L4–L5, n (%)	21 (6.9)	0 (0.0)	0.39
Protrusion L5–S1, n (%)	39 (12.7)	1 (3.7)	0.22
Extrusion L3–L4, n (%)	2 (0.6)	0 (0.0)	1.00
Extrusion L4–L5, n (%)	18 (5.9)	2 (7.4)	0.67
Extrusion L5–S1, n (%)	26 (8.5)	3 (11.1)	0.72
Modic L3–L4, n (%)			0.09
– 1	2 (0.6)	0 (0.0)	
– 2	1 (0.3)	1 (3.7)	
– 3	0 (0.0)	0 (0.0)	
Modic L4–L5, n (%)			0.70
– 1	4 (1.3)	0 (0.0)	
– 2	4 (1.3)	0 (0.0)	
– 3	0 (0.0)	0 (0.0)	
Modic L5–S1, n (%)			0.41
– 1	7 (2.3)	1 (3.7)	
– 2	3 (1.0)	1 (3.7)	
– 3	0 (0.0)	0 (0.0)	
Sacral horizontal angle, °, mean ± SD	39.0 ± 9.2	42.2 ± 8.9	0.09
Lumbosacral angle, °, mean ± SD	14.6 ± 4.6	14.0 ± 4.6	0.45
Lumbar lordosis, °, mean ± SD	52.4 ± 13.2	58.9 ± 11.4	0.009

HIZ, high-intensity zone; SD, standard deviation.

Table 4
Associations of scoliosis and radiographic and/or MRI signs suggesting axSpA at baseline

	No scoliosis (n = 362)	Scoliosis (n = 28)	P value
Sacroiliac joints			
New York criteria, radiographs	61/327 (18.6%)	8/28 (28.6%)	0.20
ASAS criteria, MRI, mean ± SD	102/322 (31.7%)	12/28 (42.8%)	0.23
SPARCC score, MRI, mean ± SD (n = 640)	3.8 ± 8.0	4.4 ± 7.1	0.20
Spine			
mSASSS score, radiographs, mean ± SD (n = 640)	0.4 ± 1.7	1.2 ± 3.5	0.48
SPARCC score, MRI, mean ± SD (n = 651)	5.0 ± 9.3	6.4 ± 8.9	0.06
BASRI, radiographs mean ± SD (n = 651)	0.2 ± 0.7	0.5 ± 1.2	0.65

SPARCC, SpondyloArthritis Research Consortium of Canada score; mSASSS, modified Stoke Ankylosing Spondylitis Spinal Score; BASRI, Bath Ankylosing Spondylitis Radiology Index.

bending was restricted in proportion to the amount of curvature and rotation [10]. Furthermore, an association has been reported between scoliosis and spinal degenerative disease. However, the modified Schober's test and finger-floor distance were similar in our groups with and without scoliosis. This finding may be ascribable to the characteristics of our patients, who were young, with little evidence of degenerative disease, and whose lumbar scoliosis was usually mild [23].

Sagittal lumbosacral balance as assessed on radiographs did not differ between the groups with and without scoliosis. In patients with scoliosis, total lordosis and SS were non-significantly greater than in patients without scoliosis. In both groups, the SH, LS and LL values were within the normal ranges. Few studies have addressed sagittal lumbosacral balance in patients with scoliosis [31,32]. In 160 patients with adolescent idiopathic scoliosis [34], lumbar lordosis was non-significantly greater in the group with lumbar curves. Some studies suggest that greater lordosis may not be associated with the progression of scoliosis [33,34].

Data on potential associations of lumbar lordosis with degenerative changes and low back pain are conflicting. In a study of 112 females aged 40–72 years, the angle of lordosis was not significantly different in the groups with and without radiographic degenerative disease of the lumbar spine [23]. The LL may be associated with spondylolysis and spondylolisthesis but not with other manifestations of spinal degenerative disease [24].

MRI abnormalities were rare in both groups, suggesting that lumbar scoliosis may not be associated with an increased risk of spinal degenerative disease in adults with early IBP who are younger than 50 years of age. Nevertheless, scoliosis was associated with degenerative disease in many studies, with some parameters correlating with low back pain. Thus, Modic changes were more common or more marked in patients with scoliosis [13,14] and predominated at the curve apex concavity [9,11]. Severe facet-joint degeneration was associated with painful lumbar scoliosis [2,8,10,11]. One study found that Schmorl's nodes were associated with pain in pediatric patients with scoliosis who had Schmorl's nodes [9]. Other degenerative lesions such as foraminal stenosis and spondylolisthesis may correlate with symptoms in patients with lumbar scoliosis [11]. In our study, degenerative changes at the lumbar spine were found in similar proportions of patients with and without lumbar scoliosis. This finding may be ascribable to the relatively young age of the patients and to the mild nature of most of the cases of lumbar scoliosis. Alternatively, any deleterious effects of lumbar scoliosis may have been counterbalanced by an increase in lumbar lordosis. In a study of patients who had two MRI scans of the lumbar spine at a 4-year interval, lordosis was more marked in patients with no degenerative disease progression [14]. Scoliosis was not associated with progression. In the SPACE cohort of patients aged 16–45 years and presenting with chronic back pain, the prevalence of degenerative changes was 89% by MRI and 44% by radiography, with no difference across the groups with and without axSpA; the prevalence of each type of degenerative change was far lower, although HIZ were seen at the lumbar spine in 62.4% of patients [19]. The main strength of this study is the collection of a vast array of data in a large population. In addition, most of the imaging study assessments were done by experienced radiologists. Among the weaknesses is the focus on lumbar scoliosis. We did not obtain standing AP radiograph of the full-spine to quantify spinal curvature in a uniform and comparable method, as recommended by the American Scoliosis Research Society. Patients with low back pain may also have thoracic spinal pain with or without thoracic or thoracolumbar scoliosis. Thoracolumbar scoliosis can be missed and no information is available on S-shaped curve of the spine. Furthermore, Cobb's angle, although the current reference standard for assessing scoliosis, measures a 2D curve, whereas scoliosis is a 3D deformity [5]. However, we also assessed the Nash–Moe grade to evaluate vertebral rotation. Nevertheless, measurement error have been found to result in 2°–7° differences in Cobb's angle values and the Nash–Moe grade can be properly assessed only on a true frontal view. The number of patients with scoliosis is low and the difference of number between the group with and without scoliosis might have decreased the statistical power of the study. Nevertheless, Cobb's angle was not correlated to either mSASSS or grade of sacroiliitis on X-rays.

In conclusion, in a large prospective cohort of patients with early IBP, lumbar scoliosis is infrequently seen and not associated with secondary changes to mechanical loading, sclerosis or bone marrow edema of the sacroiliac joints. Therefore there is no impact on the classification criteria for axSpA. Furthermore, lumbar spine degenerative changes were not more common in the patients with versus without lumbar scoliosis. These results were obtained in patients aged 18–50 years who had early IBP. It would be of interest to assess longitudinal data with AP full spine radiographs from the DESIR cohort with the aim of determining whether lumbar scoliosis is associated with the outcomes of axSpA.

Acknowledgments

The DESIR cohort is managed under the control of the Assistance Publique-Hopitaux de Paris via the Paris-Center Clinical Research Unit and under the umbrella of the French Society of Rheumatology and the INSERM (Institut National de la Santé et de la Recherche Médicale). The database is managed at the Department of Epidemiology and Biostatistics (Prof. Jean-Pierre Daurès, D.I.M., Nîmes, France). An unrestricted grant from Wyeth Pharmaceuticals was allocated for the first 5 years of patient follow-up. We also thank the regional centers that participated in establishing the DESIR cohort: Prof. Maxime Dougados (Paris – Cochin B), Prof. André Kahan (Paris – Cochin A), Prof. Olivier Meyer (Paris – Bichat), Prof. Pierre Bourgeois (Paris – La Pitié-Salpêtrière), Prof. Francis Berenbaum (Paris – Saint Antoine), Prof. Pascal Claudepierre (Créteil), Prof. Maxime Breban (Boulogne Billancourt), Dr Bernadette Saint-Marcoux (Aulnay-sous-Bois), Prof. Philippe Goupille (Tours), Prof. Jean-François Maillefert (Dijon), Dr Xavier Puéchal (Le Mans), Prof. Daniel Wendling (Besançon), Prof. Bernard Combe (Montpellier), Prof. Liana Euller-Ziegler (Nice), Prof. Philippe Orcel (Paris – Lariboisière), Prof. Pierre Lafforgue (Marseille), Dr Patrick Boumier (Amiens), Prof. Jean-Michel Ristori (Clermont-Ferrand), Dr Nadia Mehsen (Bordeaux), Prof. Damien Loeuille (Nancy), Prof. René-Marc Flipo (Lille), Prof. Alain Saraux (Brest), Prof. Corinne Miceli (Le Kremlin Bicêtre), Prof. Alain Cantagrel (Toulouse), and Prof. Olivier Vittecoq (Rouen).

Financial support

The DESIR cohort used for this study is financially supported by unrestricted grants from both the French Society of Rheumatology and Pfizer Ltd France.

Competing interests

The authors have no competing interests to declare.

Fundings

This research did not receive any specific grant from funding agencies in the public, commercial, or not-for-profit sectors.

Supplementary materials

Supplementary material associated with this article can be found in the online version at doi: [10.1016/j.semarthrit.2019.06.008](https://doi.org/10.1016/j.semarthrit.2019.06.008).

References

- [1] Trobisch P, Suess O, Schwab F. Idiopathic scoliosis. *Dtsch Arzteblatt Int* 2010;107:875–83. quiz 884.
- [2] Kostuik JP, Bentivoglio J. The incidence of low-back pain in adult scoliosis. *Spine* 1981;6:268–73.
- [3] Ract I, Meadeb J-M, Mercy G, Cuffe F, Husson J-L, Guillin R. A review of the value of MRI signs in low back pain. *Diagn Interv Imaging* 2015;96:239–49.
- [4] Yaman O, Dalbayrak S. Idiopathic scoliosis. *Turk Neurosurg* 2014;24:646–57.
- [5] Kim H, Kim HS, Moon ES, Yoon CS, Chung TS, Song HT, et al. Scoliosis imaging: what radiologists should know. *Radiographics* 2010;30:1823–42.
- [6] Lam GC, Hill DL, Le LH, Raso JV, Lou EH. Vertebral rotation measurement: a summary and comparison of common radiographic and CT methods. *Scoliosis* 2008;3:16.
- [7] Faundez A, Genevay S. Adult scoliosis: a misknown etiology of low back pain in the elderly population. *Rev Med Suisse* 2010;6:1358–60. 1362.
- [8] Jackson RP, Simmons EH, Stripinis D. Incidence and severity of back pain in adult idiopathic scoliosis. *Spine* 1983;8:749–56.
- [9] Buttermann GR, Mullin WJ. Pain and disability correlated with disc degeneration via magnetic resonance imaging in scoliosis patients. *Eur Spine J* 2008;17:240–9.
- [10] Kao FC, Lai PL, Chang CH, Tsai TT, Fu TS, Niu CC, et al. Influence of lumbar curvature and rotation on forward flexibility in idiopathic scoliosis. *Biomed J* 2014;37:78–83.
- [11] Berjano P, Lamartina C. Classification of degenerative segment disease in adults with deformity of the lumbar or thoracolumbar spine. *Eur Spine J* 2014;23:1815–24.

- [12] Siribumrungwong K, Gupta S, Gupta MC. Unusual presentation of vertebral endplate modic changes in congenital scoliosis associated with pain: a report of two cases. *Eur Spine J* 2016;25(Suppl 1):94–9.
- [13] Wu HL, Ding WY, Shen Y, Zhang YZ, Guo JK, Sun YP, et al. Prevalence of vertebral endplate Modic changes in degenerative lumbar scoliosis and its associated factors analysis. *Spine* 2012;37:1958–64.
- [14] Farshad-Amacker NA, Hughes AP, Aichmair A, Herzog RJ, Farshad M. Determinants of evolution of endplate and disc degeneration in the lumbar spine: a multi-factorial perspective. *Eur Spine J* 2014;23:1863–8.
- [15] de Bruin F, ter Horst S, Bloem HL, van den Berg R, de Hooge M, van Gaalen F, et al. Prevalence of degenerative changes of the spine on magnetic resonance images and radiographs in patients aged 16–45 years with chronic back pain of short duration in the Spondyloarthritis Caught Early (SPACE) cohort. *Rheumatology (Oxford)* 2016;55:56–65.
- [16] Raychaudhuri SP, Deodhar A. The classification and diagnostic criteria of ankylosing spondylitis. *J Autoimmun* 2014;48–49:128–33.
- [17] Rudwaleit M, Metter A, Listing J, Sieper J, Braun J. Inflammatory back pain in ankylosing spondylitis: a reassessment of the clinical history for application as classification and diagnostic criteria. *Arthritis Rheum* 2006;54:569–78.
- [18] Wendling D, Lukas C, Paccou J, Claudepierre P, Carton L, Combe B, et al. Recommendations of the French Society for Rheumatology (SFR) on the everyday management of patients with spondyloarthritis. *Joint Bone Spine* 2014;81:6–14.
- [19] Rudwaleit M, Haibel H, Baraliakos X, Listing J, Märker-Hermann E, Zeidler H, et al. The early disease stage in axial spondylarthritis: results from the German Spondyloarthritis Inception Cohort. *Arthritis Rheum* 2009;60:717–27.
- [20] Dougados M, d'Agostino M-A, Benessiano J, Berenbaum F, Breban M, Claudepierre P, et al. The DESIR cohort: a 10-year follow-up of early inflammatory back pain in France: study design and baseline characteristics of the 708 recruited patients. *Joint Bone Spine* 2011;78:598–603.
- [21] Dougados M, Etcheto A, Molto A, Alonso S, Bouvet S, Daurès J-P, et al. Clinical presentation of patients suffering from recent onset chronic inflammatory back pain suggestive of spondyloarthritis: the DESIR cohort. *Joint Bone Spine* 2015;82:345–51.
- [22] Carvajal Alegria G, Deloire L, Herbette M, Garrigues F, Gossec L, Simon A, Feydy A, Reijnierse M, van der Heijde D, Loeuille D, Claudepierre P, Marhadour T, Saraux A. Spinal-pelvic orientation: potential effect on the diagnosis of spondyloarthritis. *Rheumatology (Oxford)* 2019.
- [23] Papadakis M, Papadokostakis G, Kampanis N, Sapkas G, Papadakis SA, Katonis P. The association of spinal osteoarthritis with lumbar lordosis. *BMC Musculoskeletal Disord* 2010;11:1.
- [24] Been E, Kalichman L. Lumbar lordosis. *Spine J* 2014;14:87–97.
- [25] van der Linden S, Valkenburg HA, Cats A. Evaluation of diagnostic criteria for ankylosing spondylitis: a proposal for modification of the New York criteria. *Arthritis Rheum* 1984;27:361–8.
- [26] Creemers MC, Franssen MJ, van't Hof MA, Gribnau FW, van de Putte LB, van Riel PL. Assessment of outcome in ankylosing spondylitis: an extended radiographic scoring system. *Ann Rheum Dis* 2005;64:127–9.
- [27] MacKay K, Mack C, Brophy S, Calin A. The Bath Ankylosing Spondylitis Radiology Index (BASRI): a new, validated approach to disease assessment. *Arthritis Rheum* 1998;41:2263–70.
- [28] Rudwaleit M, Jurik AG, Hermann K-GA, Landewé R, van der Heijde D, Baraliakos X, et al. Defining active sacroiliitis on magnetic resonance imaging (MRI) for classification of axial spondyloarthritis: a consensual approach by the ASAS/OMERACT MRI group. *Ann Rheum Dis* 2009;68:1520–7.
- [29] Weber U, Lambert RGW, Østergaard M, et al. The diagnostic utility of magnetic resonance imaging in spondylarthritis: an international multicenter evaluation of one hundred eighty-seven subjects. *Arthritis Rheum* 2010;62:3048–58. 30.
- [30] Dougados M, Sepiano A, Molto A, van Lunteren M, Ramiro S, de Hooge M, van den Berg R, Navarro Compan V, Demattei C, Landewé R, van der Heijde D. Sacroiliac radiographic progression in recent onset axial spondyloarthritis: the 5-year data of the DESIR cohort. *Ann Rheum Dis* 2017;76:1823–8.
- [31] Clément J-L, Geoffray A, Yagoubi F, Chau E, Solla F, Oborocianu I, et al. Relationship between thoracic hypokyphosis, lumbar lordosis and sagittal pelvic parameters in adolescent idiopathic scoliosis. *Eur Spine J* 2013;22:2414–20.
- [32] Mac-Thiong JM, Labelle H, Charlebois M, Huot MP, de Guise JA. Sagittal plane analysis of the spine and pelvis in adolescent idiopathic scoliosis according to the coronal curve type. *Spine* 2003;28:1404–9.
- [33] Faraj SSA, Holeyijn RM, van Hooff ML, de Kleuver M, Pellisé F, Haanstra TM. De novo degenerative lumbar scoliosis: a systematic review of prognostic factors for curve progression. *Eur Spine J* 2016;25:2347–58.
- [34] Jimbo S, Kobayashi T, Aono K, Atsuta Y, Matsuno T. Epidemiology of degenerative lumbar scoliosis: a community-based cohort study. *Spine* 2012;37:1763–70.