



Universiteit
Leiden
The Netherlands

Central serous chorioretinopathy: an update on risk factors, pathophysiology and imaging modalities

Kaye, R.; Chandra, S.; Sheth, J.; Boon, C.J.F.; Sivaprasad, S.; Lotery, A.

Citation

Kaye, R., Chandra, S., Sheth, J., Boon, C. J. F., Sivaprasad, S., & Lotery, A. (2020). Central serous chorioretinopathy: an update on risk factors, pathophysiology and imaging modalities. *Progress In Retinal And Eye Research*, 79.

doi:10.1016/j.preteyeres.2020.100865

Version: Publisher's Version

License: [Creative Commons CC BY-NC-ND 4.0 license](#)

Downloaded from: <https://hdl.handle.net/1887/3182900>

Note: To cite this publication please use the final published version (if applicable).



Central serous chorioretinopathy: An update on risk factors, pathophysiology and imaging modalities



Rebecca Kaye (BA(Oxon), BM BCh(Oxon))^a, Shruti Chandra (MD)^b, Jay Sheth (MD, DNB, FVRS)^c, Camiel J.F. Boon (MD, PhD, FEBO)^{d,e}, Sobha Sivaprasad (FRCOphth)^b, Andrew Lotery (MD, FRCOphth)^{a,*}

^a Faculty of Medicine, University of Southampton, University Hospital Southampton, Southampton, SO16 6YD, United Kingdom

^b NIHR Moorfields Biomedical Research Centre, 162, City Road, London, EC1V 2PD, United Kingdom

^c Surya Eye Institute and Research Center, Mumbai, India

^d Leiden University Medical Centre, Department of Ophthalmology, P.O. Box 9600, 2300 RC, Leiden, the Netherlands

^e Amsterdam University Medical Centers, Department of Ophthalmology, Meibergdreef 9, 1105 AZ Amsterdam, The Netherlands

ARTICLE INFO

Keywords:

Central serous chorioretinopathy (CSC)
Choroid
Retinal pigment epithelium (RPE)
Corticosteroids
Choroidal endothelial cells (CECs)
Complement factor H (CFH)
Pachychoroid
Hyperpermeability
Mineralocorticoids
Eplerenone

ABSTRACT

Central serous chorioretinopathy (CSC) is a common form of vision loss, typically seen in working-age men. The pathophysiology behind CSC still eludes us, however significant advances have been made in understanding this disease over the last decade using information from genetic and cell-based studies and imaging modalities. This review aims to give an overview of the current pathophysiology hypotheses surrounding CSC in addition to future directions in cellular work from human induced pluripotent stem cell derived choroidal endothelial cells from CSC patients. Furthermore, this review will provide the reader with an update on the clinical aspects of CSC including risk factors, diagnostic challenges and findings from multimodal imaging.

1. Introduction

Central serous chorioretinopathy (CSC) predominantly affects males of working age, with a reported incidence of 10 per 100,000 men and 2 per 100,000 women (Kitzmann et al., 2008). Clinically CSC is characterized by neuroretinal detachment due to the presence of serous subretinal fluid (SRF), resulting from dysfunction of the retinal pigment epithelium (RPE) and hyperpermeability and thickening of the underlying choroid. Typical presentations include loss of central vision, central scotoma, micropsia or metamorphopsia (Daruich et al., 2017a).

The exact aetiopathogenesis of this condition remains unclear and so the terminology used to define this chorioretinal disorder has evolved. It was first described by Von Graefe in 1886 as central syphilitic retinitis (Graefe, 1866). Since then other descriptions include capillarospastic central retinitis, central angiospastic retinopathy, central serous retinopathy, central serous pigment epitheliopathy; and finally central serous chorioretinopathy, as a result of the predominant choroidal involvement in the disease process (Yannuzzi et al., 1984; Maumenee, 1965). Theories have evolved from CSC being a primary

disorder of the retinal pigment epithelium (RPE) to it being a disease within a pachychoroid spectrum, with increasing evidence pointing to the role of glucocorticoids and mineralocorticoids in the pathogenesis of the condition.

Although the disease is often classified into acute CSC, which typically self-resolves within 4 months, and chronic CSC (cCSC) (Daruich et al., 2017b; Wang et al., 2008), the temporal nature of this classification is based on the time taken for SRF resolution. There is currently no accepted consensus on the exact time scale between the acute and chronic forms. Furthermore, the chronic form initially termed “diffuse retinal epitheliopathy”, was originally described as a variant of CSC (Yannuzzi et al., 1992). Many still see this as a separate disease entity to the acute form. Thus far, there are several unanswered questions on the pathophysiology and clinical presentations of CSC and therefore a clear treatment strategy for CSC remains to be elucidated.

An overarching theme of RPE dysfunction secondary to choroidal changes is resonant throughout hypotheses of CSC pathogenesis. However, there are several unanswered questions that stem from our lack of understanding of the primary pathophysiology. In particular, is

* Corresponding author.

E-mail address: a.j.lotery@soton.ac.uk (A. Lotery).

<https://doi.org/10.1016/j.preteyeres.2020.100865>

Received 5 March 2019; Received in revised form 2 April 2020; Accepted 27 April 2020

Available online 11 May 2020

1350-9462/ © 2020 Elsevier Ltd. All rights reserved.

the pathology primarily at the site of the large choroidal vessels, or is the initial change at the level of the choriocapillaris? Or, is the primary insult at the level of the RPE? Does the site of primary insult determine the phenotype? Or do all phenotypes result from insult to a common primary site but the distinct features are determined by the relative involvement of the other structures? Is CSC a single gene disease or as a result of multiple genes or other derangements that share a common phenotype?

A comprehensive review of CSC was published in this journal in 2015 by Daruich et al., further expanding on the role of corticosteroids in the pathogenesis of disease, and the promise mineralocorticoid antagonists such as spironolactone and eplerenone held for disease treatment (Daruich et al., 2015). Since then, there have been several advancements in studying CSC such as identifying genetic risk factors and high resolution phenotyping studies particularly of the choroid.

This article will therefore focus on key advances and debated issues in risk factors, pathophysiology, clinical spectrum and manifestations of the disease.

2. Risk factors

2.1. Genetics

Genetic risk and protective elements have both been identified in cohorts of CSC patients, but their exact role in the disease pathogenesis remains unclear. Several familial cases have been reported, with one familial study stating 52% of those with cCSC to have a family member with evidence of previously unknown, asymptomatic CSC-like abnormalities on fundal examination (van Dijk et al., 2019).

In an attempt to investigate disease aetiology further there have been a number of candidate gene studies performed in both acute and cCSC. Complement Factor H (*CFH*) was initially chosen as a candidate gene given that it codes for the protein Factor H. Factor H, also known as adrenomedullin-binding protein 1 binds to adrenomedullin which stimulates choroidal dilation: an accepted event in CSC pathogenesis (Miki et al., 2014). Adrenomedullin has many other physiological roles including, but not limited to influencing angiogenesis, the regulation of hormonal secretion and apoptosis (Sim et al., 2015). Factor H is a protein involved in the regulatory arm of the complement system. The complement system comprises a series of more than 20 proteins circulating in the blood and tissue fluids. These proteins are mainly inactive, however once activated by microorganism components an enzyme cascade occurs, resulting in sequential activation. Factor H influences the activation of C3 convertase, the lynch-pin in the complement system through its ability to control the activation of C3 into C3a, which binds to mast-cells causing histamine release, and C3b that opsonises pathogens (Miki et al., 2014).

Several candidate-gene studies have identified single-nucleotide polymorphisms (SNPs) in *CFH* (Table 1). Interestingly, De Jong et al. found certain *CFH* SNPs to display opposite effects between cCSC and age-related macular degeneration (AMD), with those SNPs conferring risk in cCSC patients to be protective in AMD (de Jong et al., 2015). The meaning of this striking observation is as yet unclear; however, this is not the first-time interplay has been suggested between these two diseases.

Further evidence for the role of Factor H comes from a genome-wide association study (GWAS) undertaken in the Netherlands (Schellevis et al., 2018). This study had a case-control design with 521 cCSC cases and 3577 controls. The authors identify a lead SNP, rs1329428 on chromosome 1 in the *CFH* gene to be significantly associated with risk of disease. The lead SNP in the Schellevis et al. GWAS, rs1329428, is located within Intron 15 and is non-coding. In the past it has been associated with CSC in Japanese, Dutch, and Greek populations (Miki et al., 2014; de Jong et al., 2015; Moschos et al., 2016). Association of rs1329428 with CSC has been re-affirmed in a GWAS in a Japanese population with validation studies in independent European and

Japanese cohorts (Hosoda et al., 2019). Although intronic, this does not guarantee that rs1329428 does not influence Factor H protein function nor that of nearby genes. It is possible that the variant is within a regulatory sequence, such as an enhancer or silencer, thereby affecting gene transcription. Furthermore, rs1329428 could impact pre-mRNA splicing if it leads to the introduction of a new donor or acceptor site into intron 15. It will be interesting to evaluate this further in future research.

Following on from this, the role of the complement system in CSC was further evaluated in a study analysing complement activation in the serum of CSC patients (van Dijk et al., 2017d). The results showed no indication of complement activation in CSC patients. This finding is interesting for two reasons: the first is the striking contrast to the aforementioned genetic studies, and the second is the difference with AMD, in which changes in serum complement activation have previously been found (Smailhodzic et al., 2012; Scholl et al., 2008).

A Japanese group have also performed a GWAS in individuals with pachychoroid, a choroidal phenotype associated with CSC (Hosoda et al., 2018). Pachychoroid refers to the appearance of a thickened choroid with dilated vessels. As previously mentioned, it is associated with CSC, given the initial event in disease pathogenesis is thought to be choroidal vessel dilation and hyperpermeability (Guyer et al., 1994). A GWAS on choroidal thickness was undertaken in 3418 individuals, followed by TaqMan assays in 2692 subjects. Although this was not a GWAS of CSC patients, the SNPs identified were then used in a candidate gene study with CSC patients. Again, variants in the *CFH* gene were found to be significantly associated with both pachychoroid and CSC (*CFH* rs800292), in addition to a SNP in a new susceptibility gene, rs3793217 in *VIPR2* (Hosoda et al., 2018). Interestingly, the *CFH* rs800292 A allele conferred an increased risk for a thicker choroid and CSC development in this study. However, the *CFH* rs800292 G allele is known to be a risk allele for AMD. This is not the first-time interplay has been suggested between these two diseases. Discerning cCSC from neovascular AMD can be very difficult, and some patients with cCSC develop choroidal neovascularization. Therefore, it is possible that some cases have been misclassified, which may have influenced results. Nevertheless, there is clearly a relationship between these two discrete diseases, and developments in one may elucidate advances in the other.

It is important to note that all the *CFH* polymorphisms identified to date are in high linkage disequilibrium. Therefore, any SNP or a combination of the above SNPs may harbour a functional effect leading to or aiding CSC development. Nevertheless, there is a suggestion that *CFH* SNPs rs3753394 and rs1329428 could have a significant role in *CFH* gene function. Specifically, rs3753394, which is located in the region of the *CFH* promoter, between a glucocorticoid response element and a possible histone H4 gene-binding site, H4TF-1, that may be a common regulatory element, and hence could influence gene expression (Moschos et al., 2016). Additionally, the rs1329428 polymorphism is known to bind to transcriptional regulatory proteins, which in turn may have downstream consequences (Moschos et al., 2016). Further information on the functional repercussions of identified SNPs is required to ascertain the impact of *CFH* in CSC. Next generation sequencing and specifically deep sequencing of the *CFH* gene should enhance our currently limited understanding of its role in this disease. This strategy has been successful in AMD genetic research (Raychaudhuri et al., 2011; Seddon et al., 2013).

Another notable candidate gene study in CSC focussed on the role of cadherin-5 (*CDH5*), a calcium-binding cell-cell adhesion glycoprotein, important for maintaining endothelial cell intercellular junctions (Fig. 1) (Schubert et al., 2014b). Given the proposed role of choroidal vessels in the disease, 400 acute and cCSC cases and 1400 matched controls were studied for genetic variation in multiple genes including *CDH5* (Schubert et al., 2014b). A significant association was found in four common *CDH5* SNPs in male patients, and subsequent addition of corticosteroid to both a primate choroidal endothelial cell line (RF/6A) and posterior injection in mice revealed a decrease in transcription of

Table 1

Single nucleotide polymorphisms (SNPs) identified in the complement factor H gene (*CFH*) in various populations of central serous chorioretinopathy (CSC) patients. Minor allele frequency (MAF).

SNP	Location & effect	Risk/Protective	MAF CSC	MAF Controls	p-value	Patient group
rs1329428	Intron 15	Risk	0.593	0.449	3.22×10^{-5}	Japanese, Chronic CSC (Miki et al., 2014)
rs1329428	Intron 15	Risk	0.526	0.431	4.6×10^{-4}	Dutch, Chronic CSC (de Jong et al., 2015)
rs1329428	Intron 15	Risk	0.39	0.14	0.004	Greek, Acute & Chronic CSC (Moschos et al., 2016)
rs1329428	Intron 15	Risk	0.506	0.466	0.015	Japanese discovery GWAS, replication in European & Japanese (Hosoda et al., 2019)
rs1065489	Exon 18- benign Glu936Asp substitution	Protective	0.35	0.478	3.28×10^{-4}	Japanese, Chronic CSC (Miki et al., 2014)
rs1065489	Exon 18- benign Glu936Asp substitution	Protective	0.118	0.176	0.003	Dutch Chronic CSC (de Jong et al., 2015)
rs1065489	Exon 18- benign Glu936Asp substitution	Protective	0.366	0.167	0.04	Greek, Acute & Chronic CSC (Moschos et al., 2016)
rs800292	Exon 2	Risk	0.529	0.403	3.38×10^{-4}	Japanese, Chronic CSC (Miki et al., 2014)
rs800292	Exon 2	Risk	0.315	0.235	7.5×10^{-4}	Dutch Chronic CSC (de Jong et al., 2015)
rs3753394	Exon 1	Risk	0.586	0.487	0.0053	Japanese, Chronic CSC (Miki et al., 2014)
rs3753394	Exon 1	Risk	0.512	0.320	0.02	Greek, Acute & Chronic CSC (Moschos et al., 2016)

cadherin-5, suggesting it could be implicated in CSC pathophysiology.

Various other candidate genes and corresponding SNPs have been identified in CSC patients. Two of which are, rs10490924 in *ARMS2*, and rs2070951 in *NR3C2* (van Dijk et al., 2017b; de Jong et al., 2015). Interestingly the variant in *ARMS2* rendered a protective effect for CSC, whereas in AMD, this SNP is highly correlated with disease. The discovery of a SNP in the *NR3C2* gene, which codes for the mineralocorticoid receptor (MR), conveying increased risk for CSC in 336 patients and 1314 controls further highlights the importance of corticosteroids in this condition (van Dijk et al., 2017b). This warrants replication given the large role corticosteroids are presumed to play in disease pathogenesis (Daruich et al., 2016).

Two new loci identified to have an association with increased susceptibility to CSC are rs13278062 at *TNFRSF10A-LOC389641* and rs6061548 near *GATA5*. A large GWAS in a Japanese population was conducted with replication studies in both European and Japanese cohorts (Hosoda et al., 2019). This analysis of 1546 CSC cases and 13,029 controls identified the two aforementioned loci for the first time, in addition to re-affirming the association with rs1329428 in *CFH*.

rs13278062 at *TNFRSF10A* has previously been identified as an at risk locus for AMD (Sun et al., 2013). The exact role of *TNFRSF10A* in CSC is unclear, however interestingly Hosoda et al. also searched two databases that included the gene expression data of the human retina and choroid, The Eye integration database and The Ocular Tissue Database. Both databases showed the expression of *TNFRSF10A* was increased in the adult human RPE/choroid in comparison to the adult human retina. Furthermore, the rs13278062 genotype of *TNFRSF10A* is strongly associated with its expression in the adrenal gland. This in itself is interesting given the evidence suggesting a role of mineralocorticoids, which are secreted by the adrenal gland in CSC. The second new locus identified in the Hosoda et al. GWAS was rs6061548 near *GATA5*. *GATA5* is known to play an important part in the development of the vascular system (Jiang et al., 2013; Stennard et al., 2003; Reiter et al., 1999). Studies have identified *GATA5* expression in microvascular endothelial cells, and shown inactivation of *GATA5* in mice to cause endothelial dysfunction (Messaoudi et al., 2015). *GATA5* is also increased in the adult human RPE/choroid relative to the adult human retina. Interestingly, *GATA5* is reported to be upregulated by *H. pylori*

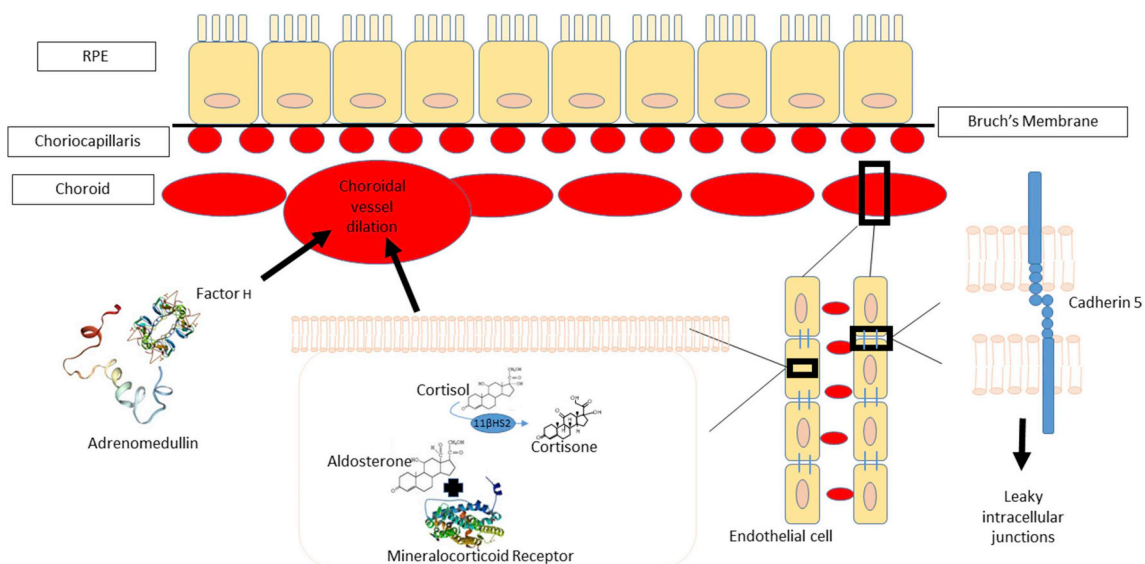


Fig. 1. Schematic demonstrating the interaction of currently identified genetic risk factors for central serous chorioretinopathy (CSC) in the choroid.

Complement Factor H (CFH) is known to bind to adrenomedullin, SNPs in *CFH* are associated with CSC. Adrenomedullin has a vasodilatory effect and could indirectly contribute to the choroidal vasodilation in CSC. Cadherin 5 is an important protein in endothelial cells for both control of cohesion and the organisation of intercellular junctions. SNPs in *CDH5* are associated with CSC. Given the importance cadherin 5 plays in intercellular junctions, it could contribute to the hyper-permeability seen in CSC. Mineralocorticoid receptors (MR) are present within choroidal endothelial cells, binding of aldosterone or cortisol to MR is thought to influence the amount of choroidal vasodilation. Cortisol is converted to cortisone by the enzyme 11β-HSD2 preventing it from binding to the MR.

infection, which has been documented to be a risk factor for CSC (discussed below) (Wen et al., 2010). Both *TNFRSF10A* and *GATA5* may be important targets for furthering our understanding of CSC.

Most of the genetic research in CSC has focussed on the chronic variant, but a candidate gene study in 135 acute CSC patients and 1385 controls revealed three previously reported variants in *CFH* (rs1329428, rs800292 and rs1061170) and differences in Complement 4B (C4b) copy numbers (Mohabati et al., 2019). These results are similar to those seen in cCSC, suggesting that despite their clinical differences, acute and cCSC may share an underlying genetic predisposition.

The number of familial studies conducted in CSC is currently low given the relative rarity of familial CSC cases despite the mounting evidence suggesting genetic variants to be important in disease. Schellevis et al. sequenced the exomes of 72 individuals in 18 families with CSC (Schellevis et al., 2019). The results were complex, in total 11 rare variants were found to segregate in two families, of which one variant in the *PTPRB* gene was homozygous in one individual and the remaining genetic variants identified to be heterozygous. *PTPRB* is interesting as it encodes the vascular endothelial protein tyrosine phosphatase, an important modulator of vascular endothelium morphogenesis and barrier function. The authors suggest familial CSC may be a heterogeneous Mendelian disease caused by variants in many different genes, or alternatively it represents a complex disease with both environmental and genetic contributors.

Identifying genetic variants is a crucial step in understanding the pathophysiology of the disease. So far, all those SNPs associated with CSC involve either non-coding regions of the genome, or seem to cause relatively benign changes, and therefore appear to have no strong functional consequences. However, the effects of these genetic variants may have downstream effects on neighbouring genes that are unknown at present. Alternatively, SNPs may be in linkage disequilibrium with functional genetic variants. For future genetic studies in CSC, more selective control group inclusion criteria would be crucial, specifically removing variations in gender and age, and ensuring all subjects have had a thorough ocular examination. Hopefully, the repercussions of such stringent criteria will unveil more clarity about the genetic elements at play in this disease process.

2.2. Corticosteroids

Corticosteroids are an important focus of CSC research. This well-established risk factor could hold the key to unlocking disease pathogenesis. Both endogenous and exogenous glucocorticoids, including local and systemic corticosteroids, have been described to be associated with CSC. Most evidence suggests a potential role for all corticosteroids, with the exception of those administered directly to the eye to confer increased risk of disease (Nicholson et al., 2018b). Indeed the first reports of a maculopathy secondary to systemic corticosteroids date back to 1966 (Jain and Singh, 1966). Systemic corticosteroids are acknowledged to be an independent risk factor for CSC (Nicholson et al., 2018b), but other routes have also been reported in association with CSC, such as intra-nasal, intra-articular, topical-dermal, inhaled and in some cases ocular use (Bouzas et al., 2002; Karadimas and Bouzas, 2004; Karadimas et al., 2004). There are sparse reports of CSC secondary to intravitreal corticosteroids (Imasawa et al., 2005; Noh et al., 2019), and only one study reporting an association between CSC and use of steroid drops (Chang et al., 2015). This Taiwanese population-based study, conducted over 10 years, examined 2921 CSC patients with 17,526 matched-controls and is the only report to date suggesting an increased risk of CSC with the use of steroid eye drops (Chang et al., 2015).

Systemic corticosteroids are not only associated with the occurrence of CSC, but also prolongation of disease, exacerbation and recurrences (Khairallah et al., 2012). Interestingly, steroid-induced CSC has less male predilection than idiopathic CSC and frequently has a bilateral

and often atypical presentation. There is some suggestion that steroid-induced CSC may be related to an idiosyncratic response in selected vulnerable individuals, rather than a dose-dependent effect, as very low steroid doses can induce CSC episodes, whilst other patients on long-term oral steroids may never develop CSC (van Dijk et al., 2017c). One large retrospective case-control study included 312 cases of acute and cCSC, with age and sex-matched controls (Haimovici et al., 2004). In this study, systemic corticosteroid use alone was included as a risk factor, and found to be significantly associated with CSC. Several other risk factors were also found to be significantly associated with CSC including, uncontrolled hypertension, pregnancy, alcohol use, antibiotics and allergic respiratory disease.

There has been only one study to date that did not support an association between corticosteroid use and CSC. This was a population-based study of 74 cases over 22 years (Kitzmann et al., 2008).

Corticosteroids are abundantly used in both general practice and hospital medicine, and the majority of the general population will undergo stressful periods during their lifetime, thereby increasing their endogenous cortisol levels. Yet the incidence of CSC is only approximately 10 per 100,000 men (Kitzmann et al., 2008). Consequently, the levels of cortisol and other steroids cannot be the only important factor at play in the pathogenesis of CSC. At present it is impossible to predict who will develop CSC as a result of corticosteroid treatment, making it impossible to risk stratify patients. Furthermore, CSC is not well-recognised outside the ophthalmic community as a side effect of corticosteroids.

2.3. Endocrinological abnormalities

Cushing's syndrome, also known as hypercortisolism, occurs due to abnormally high levels of the hormone cortisol. There are several causes, including, but not limited to, use of exogenous corticosteroids, excess endogenous production from pituitary gland tumours, adrenal gland disease, ectopic ACTH secreting tumours and familial Cushing syndrome. Several case reports and case series have been published describing the diagnosis of Cushing syndrome in patients presenting with CSC (van Dijk et al., 2016a; Clarke et al., 2017; Buelens and Dewachter, 2015). In these patients, CSC was the first clinically recognised disease entity, which then led to the diagnosis of Cushing's syndrome. There are many symptoms and signs of Cushing's syndrome, including hypertension, truncal obesity and type 2 diabetes development. These symptoms may be variably present and develop slowly, and therefore could remain unrecognised for some time. Further adding to this evidence is a study published in 2016 by Fragoso et al., who analysed choroidal thickness in the eyes of patients with active Cushing's syndrome in comparison to healthy controls (Abalem et al., 2016). They found a statistically significant increase in the sub-foveal choroidal thickness in this patient group (Abalem et al., 2016). Together the incidence of CSC in the Cushing's patient group, and the crossover between signs of Cushing's and factors associated with CSC, further advances the evidence for an association between CSC and cortisol. Cortisol is of course an endogenous corticosteroid; therefore, the above evidence further strengthens the association between corticosteroids and CSC. Further adding to this association is a study which examined the hair cortisol concentration in 11 patients with acute CSC in comparison to 15 healthy controls (Lenk et al., 2019). Cortisol accumulates in growing hair, therefore hair cortisol concentrations should reflect integrated cortisol secretion over a period of months. The authors report a statistically significant increase in hair cortisol concentration in patients versus controls over a period of three months.

Conn's syndrome, also known as primary hyperaldosteronism, is a term used to describe over-production of the mineralocorticoid aldosterone (van Dijk et al., 2016c). Interest in the role aldosterone plays in CSC pathogenesis has increased after the description of a rat model, in which mineralocorticoid overstimulation resulted in choroidal features reminiscent of CSC (Zhao et al., 2012). It has also been demonstrated

that MR antagonists such as eplerenone and spironolactone may reduce SRF in CSC patients. A cross-sectional study of 13 patients with primary hyperaldosteronism revealed SRF in keeping with CSC in 15% of patients, with 38% displaying RPE alterations characteristic of CSC on multi-modal imaging (van Dijk et al., 2016c). This is the first study examining the incidence of CSC in primary hyperaldosteronism. It is important to note that approximately 50% of the patients in this study were already taking a mineralocorticoid antagonist at the time of their ophthalmic examination, and all patients had been diagnosed with hypertension, which has previously been associated with CSC and is a feature of primary hyperaldosteronism.

2.4. Androgens

CSC has a high predominance in the male working age population (Liew et al., 2013). Female CSC patients are more often post-menopausal, with a number of cases having been reported during pregnancy, especially late pregnancy (Said-Ahmed et al., 2012). Males naturally possess higher levels of androgens such as testosterone than women, but studies examining the role of serum testosterone levels in CSC have until recently found no statistically significant associations (Zakir et al., 2009; Tufan et al., 2013). The link between CSC and testosterone was first proposed by Ahad et al. who reported a case of CSC occurring in a patient on long-term systemic testosterone therapy for hypogonadotropic hypogonadism (Ahad et al., 2005). Since then, a small study of 30 patients and 30 controls has shown a statistically significant increase in total testosterone levels in those with CSC (Ciloglu et al., 2018). Testosterone is a vasoactive hormone, and therefore increases vasodilation, a presumed step in CSC development (Yildiz and Seyrek, 2007). Both the incidence of CSC and levels of androgens decrease after approximately 45 years of age. Further suspicion for the role of androgens in CSC comes from studies showing higher levels of urinary testosterone in patients with type A personalities, a potential risk factor for CSC (Zumoff et al., 1984). However, the role of personality traits in CSC is still up for debate (van Haalen et al., 2019). Androgen receptors are present in the mammalian choroid and human RPE (Wickham et al., 2000), and mRNA for 5- α reductase, the enzyme responsible for the conversion of testosterone to the more potent dihydrotestosterone has also been found (Rocha et al., 2000). Subsequently, one can infer that if androgen receptors are present in the target tissue, then increased levels of androgens could have a local effect, but this needs to be subjected to further research.

An additional association between males, androgens and CSC is the use of anabolic-androgenic steroids (Nudleman et al., 2014). Their use is documented to be higher amongst males than females, however given their often black-market acquisition a database of all users does not exist and patients are unlikely to admit to personal use (Graham et al., 2008). A retrospective case series of patients presenting with blurred vision whilst using exogenous testosterone (mean 14 months) as a treatment for low testosterone levels found all patients to have CSC and increased choroidal thickness. Importantly in this study other known risk factors for CSC, such as corticosteroid use formed part of the exclusion criteria, however this study only included those presenting with blurred vision (Nudleman et al., 2014). Consequently, the incidence of CSC in those using exogenous androgen therapy is currently unknown.

A retrospective cohort study performed over 13 years identified older age at diagnosis, presence of choroidal neovascularization (CNV), prostate disease, diabetes, steroid use and hypertension to be associated with poor visual outcome in CSC patients (Nicholson et al., 2018a). This association with prostate disease is interesting. CSC is predominantly a male disease, with androgens noted to be a risk factor. Diseases of the prostate, such as prostate cancer and benign prostatic hypertrophy typically respond to androgen therapy, therefore the role of androgens in disease prognosis could be of importance.

2.5. Pregnancy

Choroidal thickness has been shown to change during pregnancy, with a statistically significant decrease from the first to the third trimester (Kara et al., 2014; Said-Ahmed et al., 2012; Benfica et al., 2018). Interestingly, CSC occurs more commonly in late pregnancy, when the choroid is thought to be at its thinnest (Said-Ahmed et al., 2012). The choroid is one of the most highly vascularised tissues, with the highest blood flow to tissue volume ratio in the whole body, therefore during pregnancy there is an expectation that it would respond to increased blood flow by increasing its thickness (Alm and Bill, 1972). In fact, one meta-analysis reported the choroidal thickness of healthy pregnant women to be significantly higher than that of non-pregnant women (Jiang et al., 2019). Pregnancy can be a triggering event for CSC, and in both pregnancy and CSC the choroid is thought to be thicker (Liu et al., 2016a). A retrospective case series from Korea found CSC to be the leading cause of acquired retinal/choroidal visual impairment during pregnancy (Park et al., 2017). During pregnancy, endogenous corticosteroid levels increase above basal, a factor that could contribute to CSC development. Additional changes in pregnancy occur in progesterone, testosterone, the renin-angiotensin system and blood volume, all of which are risk factors for CSC.

There is an increase in hypertensive disorders during pregnancy, affecting almost 1 in 10 women (American College of et al. (2013)). Pre-eclampsia is a condition seen in 3–4% of pregnancies where patients experience hypertension and proteinuria, typically in the second half of pregnancy (Abalos et al., 2013). Pre-eclampsia is not only associated with hypertension, but also complement activation. Complement has been shown to be of importance for the development of a normal functioning placenta, with complement gene abnormalities and increased levels of complement activation predisposing to the development of pre-eclampsia (Salmon et al., 2011) (Lokki et al., 2017). Hypertension is a risk factor for CSC, and as previously discussed genetic variants in the complement system have been associated with CSC further intertwining pregnancy and CSC. The relationship between pregnancy and CSC is worthy of further investigation, and may help us to understand the physiological and potential pathological changes occurring in the choroid during pregnancy.

2.6. Other drugs

One interesting note is the link between CSC and erectile dysfunction medication including phosphodiesterase-5 inhibitors, specifically sildenafil, commonly known as Viagra (Fraunfelder and Fraunfelder, 2008). Both sildenafil and tadalafil have been linked with CSC (Smal et al., 2017). These medications cause increased levels of nitric oxide and could theoretically increase choroidal dilation. However, to counter this, there is currently no documented link between CSC and other nitrates, such as glyceryl trinitrate (GTN) spray. This may relate to the male predominance of CSC, as GTN is also used by females, however sildenafil is commonly taken by men. Furthermore, there is not as yet a clear consensus if these medications are a risk factor for CSC. One case-control surveillance study found no increase in prescription exposure to phosphodiesterase-5 inhibitors in CSC patients compared to age-matched control subjects (French and Margo, 2010). Additionally, a prospective study of patients with erectile dysfunction treated with sildenafil for 1 month did not show a significant difference in macular thickness or macular volume and no patients developed CSC (Damar et al., 2013). However, Vance et al. measured the choroidal thickness in healthy controls given sildenafil at both 1 and 3hrs post ingestion and showed a statistically significant change in choroidal thickness (Vance et al., 2011). Increased choroidal thickness is thought to be a risk factor for CSC, therefore one could suggest this to be the mechanism through which there is an association with sildenafil. Increased patient phenotyping may help to answer this questionable association in the future.

2.7. Cardiovascular risk

The notion that CSC is a choroidal disease and that the choroid is a highly vascular tissue may help to explain the increased risk of CSC in those with hypertension (Eom et al., 2012; Chatziralli et al., 2017) (Tittl et al., 1999). Alongside this, patients with CSC are thought to be at an increased risk of both ischaemic heart disease and stroke (Chen and Lian, 2014). This association is still controversial, some groups do not report an association between CSC and cardiovascular disease (Ersoz et al., 2019). It is interesting to note that the recurring theme of cardiovascular risk factors, such as hypertension, can be linked back to CSC in some way.

2.8. Refractive error

Refractive error is a risk factor for CSC, with hyperopia, secondary to reduced axial length producing increased risk. In contrast, myopia, secondary to increased axial length is found to be protective (Chatziralli et al., 2017) (Manayath et al., 2016). An analysis of 811 Turkish patients with CSC found increased spherical equivalent refractive error to be significantly associated with disease when compared to healthy controls ($p < 0.001$) (Ersoz et al., 2019). This association with hypermetropia may be explained by increased choroidal thickness compared to myopes. Choroidal thickness in highly myopic eyes has been demonstrated to be very thin, with further thinning occurring with age and degree of myopia. Fifty-five eyes of highly myopic patients with a mean refractive error of -11.9 D were examined and the mean subfoveal choroidal thickness found to be $93.2 \mu\text{m}$ (Fujiwara et al., 2009). This was significantly less than that seen in emmetropic control eyes. However, there are reports of CSC in myopic patients. Six patients with a refractive error between -3.00 and -9.00 D (mean 5.82 D), were found to have CSC (Yzer et al., 2012). All patients, however, had a thickened choroid relative to their refractive errors. It is important to bear in mind the possibility of CSC in myopic patients, especially in those with thicker than expected choroids for their refractive error.

2.9. Stress & psychological profile

In 1986 Yannuzzi reported an association between “type A personality” and CSC (Yannuzzi, 1986). Type A behavioural pattern was defined using the Jenkins Scale as an individual who has an increased competitive drive, is high achieving, a perfectionist, ambitious and under continuous stress to name a few characteristics. The association with stress, certain personality characteristics and CSC has been repeatedly analysed (Chatziralli et al., 2017; Ji et al., 2018; Kim et al., 2018; Matet et al., 2018; Fok et al., 2011; Lahousen et al., 2016). If those individuals with type A personality are under continuous amounts of stress then one would expect their cortisol levels to be elevated versus those with type B personalities. To date no studies have shown a link between stress reduction and resolution of CSC. Additionally, type A personality is a term that is not well-circumscribed and not often used in psychology nowadays (van Haalen et al., 2018b). Further studies using validated personality questionnaires on personality traits have shown no link with maladaptive personality traits in CSC patients (van Haalen et al., 2019). Our experience from clinical practice does however suggest patients with CSC are often of above-average intelligence.

Further psychosocial factors have been examined including anxiety, stress levels, sleep quality and history of psychiatric illness. The phase of CSC was thought to be linked with anxiety and stress levels, with researchers documenting that patients with active CSC self-reported more stressful events and felt more depressive symptoms than matched controls (Kim et al., 2018) (Lahousen et al., 2016). The severity of the depression was also thought to correlate with the size of choroidal pathology in acute active CSC (Kim et al., 2018). A medical history including adjustment disorder and/or depression has also been linked with an increased risk of CSC recurrence (Fok et al., 2011), in addition

to sleep disorders and shift work (Matet et al., 2018)). A loose association between CSC and sleep quality has been documented, with suggestions of poor sleep quality increasing the risk of CSC (Ji et al., 2018). In practise it is very difficult to undertake an unbiased study assessing the quality of sleep, or anxiety and stress levels. Self-reporting questionnaires are used, which offer a large amount of user variability and subsequent bias, with users often guessing a researchers hypothesis and completing it in line with this.

2.10. *Helicobacter pylori*

Helicobacter pylori (*H. pylori*) is a gastrointestinal infection often leading to stomach ulcers in the host. Previous studies have reported an association between *H. pylori* infection and CSC, but the potential pathophysiology behind this is unknown (Asensio-Sanchez et al., 2008; Casella et al., 2012; Dang et al., 2013). Giusti hypothesised that there might be a link between *H. pylori* infection and atherosclerosis, while a cross reactivity of anti-Cag A antibodies and the presence of IgG antibodies have been considered as risk factors for endothelial dysfunction (Giusti, 2004). One theory surrounds the expression of heat shock proteins by *H. Pylori*, which promote an immune response resulting in cross reactivity with homologous host proteins, such as those in the endothelial vascular wall (Lamb et al., 2003). Overall there is limited evidence surrounding this association and there are several methodological difficulties in the reported studies. Larger study groups are needed to further cement this association.

2.11. Hypoxia & obstructive sleep apnoea

There are case reports of CSC occurring after exposure to hypoxic conditions, such as trainee pilots in hypobaric chambers and those at high-altitude (Ide, 2014). However, it is impossible to distinguish between the hypoxia as a trigger, the stress response resulting from this or if this association is pure coincidence.

Obstructive sleep apnoea has been associated with CSC (Leveque et al. 2005, 2007), thought to be related to the increased sympathetic drive in both conditions leading to endothelial cell dysfunction (Bernasconi et al., 1998). A Greek population study recently showed patients with CSC were five times more likely to have obstructive sleep apnoea than age and sex matched controls (Chatziralli et al., 2017). However, there have been studies where no association has been seen with CSC (Brodie et al., 2015). Given the increase in sympathetic activity, it follows that patients with obstructive sleep apnoea may have increased levels of cortisol, thereby leading to a higher risk of CSC (Kloos et al., 2008). As mentioned, hypoxia may be a risk factor for CSC and could too be the causal factor in this association.

3. Pathogenesis

CSC is often described as an enigmatic disease. This term largely results from our lack of understanding of the primary pathophysiology. There have been several theories suggested to explain the features seen in patients with CSC:

1. Choroidal dysfunction

Guyer and colleagues first suggested that the pathogenesis of CSC may be choroidal vascular hyperpermeability, with and without associated active pigment epithelial leaks or pigment epithelial detachment (Guyer et al., 1994).

2. RPE dysfunction

One of the alternate hypotheses suggests that CSC results from dysfunction of RPE ion pumping, with a reverse in the movement of fluid in a chorioretinal direction (Spitznas, 1986).

3. The mineralocorticoid hypothesis

The mineralocorticoid hypothesis suggests activation of the MR in choroidal endothelial cells by mineralo- and glucocorticoids. Activation of the MR has been demonstrated to promote choroidal vascular dilation through up-regulation of the endothelial vasodilatory calcium-dependent potassium channel $KCa_{2.3}$, and eventual hyperpolarisation of endothelial cells and underlying smooth muscle cells, causing choroidal vascular dilation (Darwich et al., 2015; Zhao et al., 2012).

Below we will further examine these hypotheses with the evidence aligned to each, including recent evidence suggesting CSC to be part of a broader pachychoroid spectrum of disease.

3.1. Choroidal dysfunction

Choroidal dysfunction is considered by many to be the primary abnormality in CSC. Theories of ischaemia of the choriocapillaris leading to RPE damage and eventual SRF accumulation stem back to 1967. Gass first postulated that the basis of CSC originates from an increased permeability of the choriocapillaris leading to increased hydrostatic pressure in the choroid and subsequent RPE dysfunction (Gass, 1967b). It is still undecided as to at which level of the choroid the primary insult occurs. One view is that the primary abnormality is ischaemia mainly at the level of the choriocapillaris resulting in focal or diffuse dysfunction of the RPE and subsequent detachment of the neurosensory retina. The underlying choroidal hyperpermeability is thought to be a functional consequence of choriocapillaris attenuation. Changes in choroidal autoregulation may however, also play a role. This concept is supported by laser Doppler flowmetry studies of the choroidal circulation that found the blood flow in the choriocapillaris of eyes with CSC to be significantly lower than fellow eyes (Kitaya et al., 2003). Angiographic areas of choroidal ischaemia and leakage from the choriocapillaris in CSC patients has also been reported with a definite delay of choroidal filling in localised areas with underlying dilated capillaries and venules (Hayashi et al., 1986; Prunte and Flammer, 1996). Additionally, structural optical coherence tomography (OCT) in these eyes shows marked thinning of the choriocapillaris layer underlying the area of pathology. Multiple causes could trigger the delay in choroidal filling, ranging from increased sympathetic tone resulting in vasoconstriction (sympathetic α -adrenoceptor activation) (Saito et al., 2013, 2015), increased vascular resistance due to arteriosclerosis in older patients (Patwardhan et al., 1970) or as some studies have found increased propensity towards occlusion due to elevated levels of plasminogen activator inhibitor in CSC eyes (Iijima et al., 1999).

Furthermore, one study which analysed the in vivo choroidal circulation and watershed zones highlighted the significance of the macular region as being the meeting point of the watershed zones of vortex veins and posterior ciliary arteries (Hayreh, 1990). It is acknowledged that the area where multiple watershed zones converge is a field of poor vascularity. Based on this, one would surmise that the macular choroid is most vulnerable to ischaemic insult (Hayreh, 1990). Possibly explaining the predominance of SRF at the fovea in CSC.

Aside from choriocapillaris attenuation being the primary event, another frequently accepted view is that hyperpermeability of the larger choroidal vessels may be the inciting stimulus in CSC. Multiple angiographic studies have supported this idea. One ICG-video-angiography study of CSC eyes noted the presence of choroidal hyperpermeability around points of active leakage (Guyer et al., 1992). In contrast, no leakage was seen around the same sites in simultaneous fluorescein angiograms, leading to the suggestion that the site of primary abnormality is the choroid and not the RPE. Additional evidence towards large choroidal vessel hyper-permeability being a triggering event in CSC comes from studies examining the choroidal vascularity index (CVI) of CSC patients. The CVI is calculated by determining a ratio of the total choroidal area to the 'luminal' choroidal area using SD-

OCT EDI scans. The remaining area is dubbed the 'stromal' area, accounting for non-vascular tissue. In comparison to controls, patients with CSC were found to have a higher CVI and a reduced stromal area to choroidal area ratio (Lee et al., 2018). The authors postulate that the reduced stromal: choroidal area ratio is indicative of stromal atrophy resulting from a low-grade inflammation. The proposed hypothesis being unrelenting stress in the form of chronic venous congestion resulting in extravasation of pro-inflammatory factors causing degradation of extracellular matrix and stromal thinning. This theory of extravasation of mediators is reinforced by an aforementioned study showing steroid induced suppression of *CDH5* expression in RPE/choroid human cultures (Schubert et al., 2014a). Cadherin-5 is crucial for cell adhesion suggesting it could contribute to altered vascular permeability and intracellular connections of large choroidal vessels in CSC.

Thus, available evidence may suggest the following sequence of events: delayed choroidal filling, leading to backpressure and chronic venous congestion, causing dilatation of Haller's layer which in turn further compresses the inner choroidal layers, resulting in choriocapillaris ischaemia, with subsequent leakage and capillary drop-out. The overall result is RPE dysfunction, serous neurosensory detachments and atrophic RPE changes. The real question is why does this occur, why are there atrophic RPE changes? Is this due to chronic choroidal dysfunction culminating in RPE dysfunction? Is the leak seen on fluorescein angiography a result of a "blow-out" due to underlying choroidal congestion? Or is this a result of chronic choroidal low-flow causing RPE atrophy? There are other suggestions on the chronology of events, and overall one could liken this to a "chicken and egg" situation i.e. what event came first? Most authors agree that there is hyperpermeability of the choroid with choriocapillaris attenuation and RPE dysfunction, but the nature and cause of the primarily inciting event is still unclear. Recently CSC has been classified into the pachychoroid spectrum of diseases, a concept that must be reviewed when discussing choroidal dysfunction in the context of CSC pathophysiology.

Pachychoroid is an increasingly used term in modern-day ophthalmology. Defined as an abnormal and permanent increase in choroidal thickness, often with dilated choroidal vessels and other structural alterations of the normal choroidal architecture. Arbitrarily, greater than two standard deviations of normative choroidal thickness is often quoted as 'abnormal' choroidal thickness. Subfoveal choroidal thickness in normal subjects has been reported to be between 191 and 350 μm (Lehmann et al., 2015; Margolis and Spaide, 2009; Manjunath et al., 2010). There are multiple factors that can influence choroidal thickness, such as refractive error, accommodation, blood pressure, age and the time of day. Consequently, there is no definitive threshold for an abnormally thick choroid. Although, some investigators would suggest any value above 300 μm to be considered pathological (Dansingani et al., 2016a) (Ersoz et al., 2018b). Several conditions have been described to reside within the pachychoroid disease spectrum, including CSC. Increased choroidal thickness and vessel dilation are widely accepted as being associated with CSC (Fujiwara et al., 2009; Imamura et al., 2009; Lehmann et al., 2015).

Interestingly, the pachychoroid phenotype may have an autosomal-dominant inheritance in some families. Lehmann et al. looked at first or second degree relatives of patients with CSC in a prospective observational study and found circa half of all these eyes had thick choroids (Lehmann et al., 2015). Although choroidal thickening is a component of pachychoroid, within CSC this is a grey area as some patients do not have a clearly thickened choroid. For those patients who do have a pachychoroid, current dogma is that choroidal dysfunction, increased hydrostatic pressure and subsequent leakage from the choroid and/or choriocapillaris are implicated in disease pathogenesis: as observed in indocyanine green angiography (ICGA) abnormalities. However it is not clear if this is the case for those CSC cases who do not have pachychoroid.

3.2. RPE dysfunction

The role of the RPE is still poorly understood in the pathogenesis of CSC. One hypothesis is that RPE dysfunction is the trigger for subretinal and intraretinal fluid accumulation. This is thought to arise following an undefined insult to the RPE. Damage to RPE cells interferes with the functioning of ion channels responsible for keeping the retina dry, such as aquaporins. The reversal of fluid movement in a chorioretinal direction culminates in neurosensory retinal detachment. Marmor et al. hypothesised that damaged RPE cells in areas of leakage overburden the metabolically functioning RPE thereby resulting in the persistence of serous fluid (Marmor, 1988). In a study utilising SD-OCT 3D single-layer RPE analysis, morphological alterations were found in the RPE of nearly all fellow eyes of CSC patients (Gupta et al., 2010). One recent suggestion was that damage to the RPE outer-retinal blood barrier in CSC results in the secondary formation of anti-retinal antibodies, which may affect the clinical course of CSC. Anti-retinal antibodies were found in 54% of CSC patients, versus 17% of healthy controls, but no association between clinical characteristics and the presence of anti-retinal antibodies was found (Ten Berge et al., 2018). Consequently, although it remains controversial whether retinal epitheliopathy precedes choroidopathy or vice versa, the fact remains that RPE integrity has a vital defensive role to play against the elevated choroidal hydrostatic pressure seen in this disease.

3.3. The corticosteroid hypothesis and information from cell biology studies

The corticosteroid hypothesis in CSC has gained increasing support over the last decade. Two classes of corticosteroids, mineralocorticoids and glucocorticoids are believed to be relevant to the development, chronicity and recurrence of CSC. Mineralocorticoids are produced in the adrenal cortex. Aldosterone an important mineralocorticoid regulates the renal balance of salts and water, therefore contributing to blood pressure control, acid-base and fluid balance. Glucocorticoids are the other class of corticosteroids, and in humans the main endogenously produced corticosteroid is cortisol. Initial evidence for the role of corticosteroids in CSC came from observational studies, where corticosteroid use was seen to be significantly associated with CSC (as discussed above). Given the mounting evidence for involvement of corticosteroids in this disease, animal models of CSC were attempted through intravitreal injection of both aldosterone and corticosterone in rats. The choroids of these rats showed vasodilation and vessel hyperpermeability in response to aldosterone, with elongation of RPE microvilli and increased choroidal thickness similarly to CSC (Zhao et al., 2011). On a cellular level intravitreal aldosterone was found to enhance the expression of the epithelial Na⁺ channel (ENaC), the potassium channel Kir4.1 and the aquaporin AQP4, in addition to promoting the localisation of Kir4.1 and AQP4 to the outer limiting membrane (Zhao et al., 2011). The same response was not seen with corticosterone, the main corticosteroid hormone in rats. Following this a conditional double transgenic mouse model was generated, where inducible mineralocorticoid overexpression was restricted to the endothelium. These mice had mild hypertension, with no basal endothelial dysfunction (Nguyen Dinh Cat et al., 2010). Interestingly, the mice did show a spontaneous increase in choroidal thickness and vessel dilation, associated with focal disruption of RPE tight junctions and RPE detachments (Daruich et al., 2015). Further evidence to attest to the role of the mineralocorticoid pathway in CSC pathogenesis comes from studies demonstrating the ability for aldosterone to regulate the endothelium-derived hyperpolarising factor through up-regulation of the calcium activated potassium channel KCa2.3, which is expressed in choroidal endothelial cells (Zhao et al., 2012). This is interesting given the plausible role of the choroidal endothelium in CSC. Endothelial cells are involved in maintaining the integrity of blood vessel walls and

controlling the transfer of molecules. Choroidal endothelial cells have been cultured from human donors and both corticosteroids and mineralocorticoids administered (Brinks et al., 2018). The resultant changes in gene expression were then measured using the reverse-transcriptase polymerase chain reaction (RT-PCR). Cortisol was found to significantly influence the expression of specific steroid-responsive genes (*PER1*, *GILZ-1* & *FKBP5*), however aldosterone did not have the same effect. More recently the transcriptomic regulation of the RPE-choroid complex in rats was evaluated following intravitreal injection of high dose aldosterone (Canonica et al., 2019). A uninephrectomy/aldosterone/salt model was also created in wild-type C57BL/6 mice (Canonica et al., 2019). Authors reported that aldosterone induced posterior segment inflammation on OCT in rats and that RNA sequencing of rat RPE-choroid complexes showed up-regulation of pathways involved in both inflammation and oxidative stress. Chronic aldosterone/salt exposure in the aforementioned mouse model induced retinal oedema, choroidal vasodilation and RPE cell dysfunction and migration. It follows that both glucocorticoids and mineralocorticoids may both exert key effects in CSC and neither role has thus far been fully elucidated.

Patients with cCSC suffer from persistent serous retinal pigment epithelial detachments. SRF from a CSC patient was sampled and its constituents compared to that of two patients with retinal detachments (Kowalczyk et al., 2018). Although only one CSC patient was included, this study found a comparable difference in the SRF from the CSC patient. Protein and metabolites deregulated included those involved in the alternative complement pathway (CFH and CFH related protein), and glucocorticoid and mineralocorticoid systems (aldosterone, angiotensin, and corticosteroid-binding globulin) amongst others. It is difficult to ignore this recurring theme of both the complement pathway and corticosteroids in CSC patients. Access to SRF from patients with CSC is very limited, especially given the often self-resolving nature of the condition. However, if more studies show comparable results the possibility of intravitreal or subretinal treatment strategies could be considered for non-resolving cases.

The evidence towards involvement of the mineralocorticoid pathway in disease pathogenesis was accumulating, not just at a cellular level, but also from studies using mineralocorticoid antagonists to treat patients (see section 7). Unfortunately, the first double-blind placebo controlled randomised control trial on the use of the MR antagonist eplerenone in cCSC has shown no superiority over placebo (Lotery et al., 2020). This is disappointing as mineralocorticoid antagonism was felt to be a relatively safe treatment for CSC. With multiple case studies and series documenting a reduction in SRF with the use of eplerenone it is easy to forget that a significant number of cases of CSC self-resolve. This element of self-resolution can only be accounted for by using a placebo-controlled double blind trial. If mineralocorticoid antagonism is not an effective treatment in cCSC, does this mean the MR is not involved in disease pathogenesis? Answering this question is both beyond the scope of this review and currently unknown. The VICI trial showed that eplerenone was ineffective. However, it is unclear if alternative mineralocorticoid antagonists such as spironolactone might be effective. The results of the VICI trial suggest not but only a similar placebo controlled clinical trial using spironolactone could absolutely confirm this.

We know that corticosteroids are a risk factor for disease, and both glucocorticoids and mineralocorticoids can bind to the MR and the glucocorticoid receptor. Therefore, if MR antagonism isn't enough, possibly the glucocorticoid receptor needs to be targeted e. g with mifepristone (Goldberg and Heier, 2018)?

Or other pathways may need to be targeted. Photodynamic therapy (PDT) has been shown to be a superior and effective treatment to micro-pulse laser in CSC (van Dijk et al., 2018a). PDT is thought to exhibit its effects through binding to cholesterol receptors. Glucocorticoids are

produced from cholesterol. What if the focus needs shifting slightly away from the MR to cholesterol receptors, could statins be of any value in disease? New hypotheses are needed to help further our understanding of both CSC and other related chorioretinal diseases. Perhaps, patient derived induced pluripotent stem cells (iPSCs) could assist in providing such insights.

4. Clinical presentation & multimodal imaging

4.1. Clinical presentation

The term “CSC” covers two distinct entities, classically defined as the acute and chronic forms of the disease. This distinction is somewhat tenuous because it relies on a temporal criterion (the duration of the serous retinal detachment), and on the presence of extended RPE changes.

In the acute form, patients report symptoms related to the localisation of the subretinal detachment (SRD) in the macular area: blurred vision, relative central scotoma, metamorphopsia, moderate dyschromatopsia, hypermetropisation, micropsia and reduced contrast sensitivity.

No consensus exists over the duration threshold that differentiates acute and cCSC, arbitrarily set between 4 and 6 months in most published reports. This limit is critical for therapeutic studies since it determines the appropriate timing for intervention, when self-resolution is no longer to be expected. Wang et al. have postulated that SRF leakage lasting > 4 months may cause retinal atrophy and irreversible visual loss, but little is known about the exact time that has to ensue before chronic SRF accumulation causes photoreceptor degeneration, neuroretinal atrophy, and consequent vision loss (Wang et al., 2002).

Acute CSC has been shown to self-resolve in the large majority of cases, with one retrospective series of 68 eyes demonstrating 57% to resolve without intervention (Gilbert et al., 1984). Recurrence rates are however common, especially in the absence of intervention, ranging from 15 to 50% dependent on study type and length of follow-up (Loo et al., 2002; Yap and Robertson, 1996). Approximately one third of patients will have a second recurrence, often within one year of the first episode (Gass, 1967a; Ficker et al., 1988). Recurrent CSC carries a poorer visual prognosis (Wang et al., 2008). cCSC represents approximately 5% of all CSC cases (Spaide et al., 1996a), with follow-up studies indicating a general progression from acute to cCSC in around 16% of cases (Castro-Correia et al., 1992).

4.1.1. Visual prognosis

Generally the visual prognosis for CSC is good, 35 of 47 untreated eyes with classic CSC had a final visual acuity of 6/6 (Snellen) or better at 1 year follow-up (Gilbert et al., 1984). For those patients who go on to develop chronic, persistent or recurrent disease, the visual prognosis is not so favourable, with varying degrees of permanent vision loss recorded. Severe vision loss is reported to be between 5 and 12.8% in cCSC. Earlier reports suggested a more favourable prognosis. In one series, just 2/37 (5.4%) affected eyes lost vision to the 20/200 level or worse with 11 or more years of follow-up (Yap and Robertson, 1996). In another subset of patients with severe CSC, 8.7% of eyes had vision worse than 20/200 after 10.6 years mean follow-up (Otsuka et al., 2002). However, a more recent study shows up to 12.8% of patients with cCSC may become legally blind (Mrejen et al., 2019). Additionally, there is a significant vision-related reduction in quality of life (Breukink et al., 2017).

It is becoming more evident that visual prognosis is dependent on both the type and chronicity of disease. Additionally our experience has taught us that demonstrating efficacy of a treatment by using visual acuity as an endpoint for cCSC is challenging. Alternatively it could be argued no treatment to date has been found to be so superior to placebo that visual acuity is significantly different with treatment (Lotery et al., 2020) (van Dijk et al., 2018a).

4.2. Disease classification

There is no accepted consensus on the classification of CSC aside from the aforementioned temporal criteria. Furthermore, the spectrum of clinical manifestations of CSC and the array of different terminologies used pose a unique challenge to clinicians in terms of non-uniformity in reporting and prognostication of the disease. Singh et al. recently reviewed the discrepancies present in CSC classification amongst experienced retinal specialists and found a high level of discordance, even amongst those most experienced doctors (Singh et al., 2019). Even when disease was sub-classed into acute, chronic, recurrent, persistent and inactive the discordance still existed. The variety of clinical manifestations and corresponding varied terminologies used in clinical practice highlight the ambiguity in both the diagnosis and management of CSC.

Below, we outline subtypes of CSC and typical complications.

4.2.1. Acute CSC

The acute form is characterized by the presence of SRD, clinically detectable on fundus examination and on OCT, with focal or multifocal RPE alterations that may be limited to small pigment epithelial detachments (PEDs), and leakage through the RPE on fluorescein angiography (FFA). The SRD usually resolves within 3–4 months, leaving in most cases no long-term symptoms, except colour discrimination defects in some patients.

4.2.2. Chronic CSC

Chronic CSC (cCSC) is recognised by widespread tracks of RPE atrophy characterized by their decreased fundus auto-fluorescence (FAF). Symptoms can be permanent (Breukink et al., 2017). General clinical characteristics of chronicity are considered to include ≥ 1 significant multifocal areas of atrophic RPE alterations and/or multifocal areas of leakage. Nevertheless, various clinical presentations exist within cCSC, ranging from mild to severe manifestations with clinical characteristics.

4.2.3. Multifocal CSC

Multifocal CSC may be more often associated with corticosteroid use and is more commonly seen in the Asian population (Mendrinou et al., 2008; How and Koh, 2006). Patients with multifocal CSC have multiple leakage points on FFA (Fig. 2).

Complications of CSC

4.2.4. CSC with fibrin

CSC can be complicated by fibrin deposition (Fig. 3). There are reports of fibrin deposition resulting in increased scar formation, as this fibrinous material is thought to stimulate the RPE to undergo fibrous metaplasia (Schatz et al., 1995). Schatz et al. reported 6 cases with CSC containing fibrin in the subretinal space which developed into a subretinal fibrotic scar. Scar formation was followed by a tenting up of the macula, vascularization of the fibrosis (subretinal neovascularization), or a RPE rip. Four of the seven eyes with subretinal fibrosis had severe visual loss (20/400 or worse).

4.2.5. Complex chronic CSC with choroidal neovascularization

A subset of patients with cCSC develop choroidal neovascularization (CNV), also known as Type 1 macular neovascularization (Type 1 MNV) (Spaide et al., 2020) (Fig. 4). Several recent studies on cCSC combined with type 1 CNV found that these eyes often exhibit a flat, irregular RPE elevation or PED (Hage et al., 2015). The clinical characteristics of type 1 CNV in eyes with CSC was examined in an attempt to distinguish neovascular CSC from non-neovascular CSC before treatment (Shiragami et al., 2018). This retrospective study revealed the presence of CNV in 15.6% eyes with CSC (acute and chronic). CNV was found to be significantly associated with cCSC and choroidal vascular

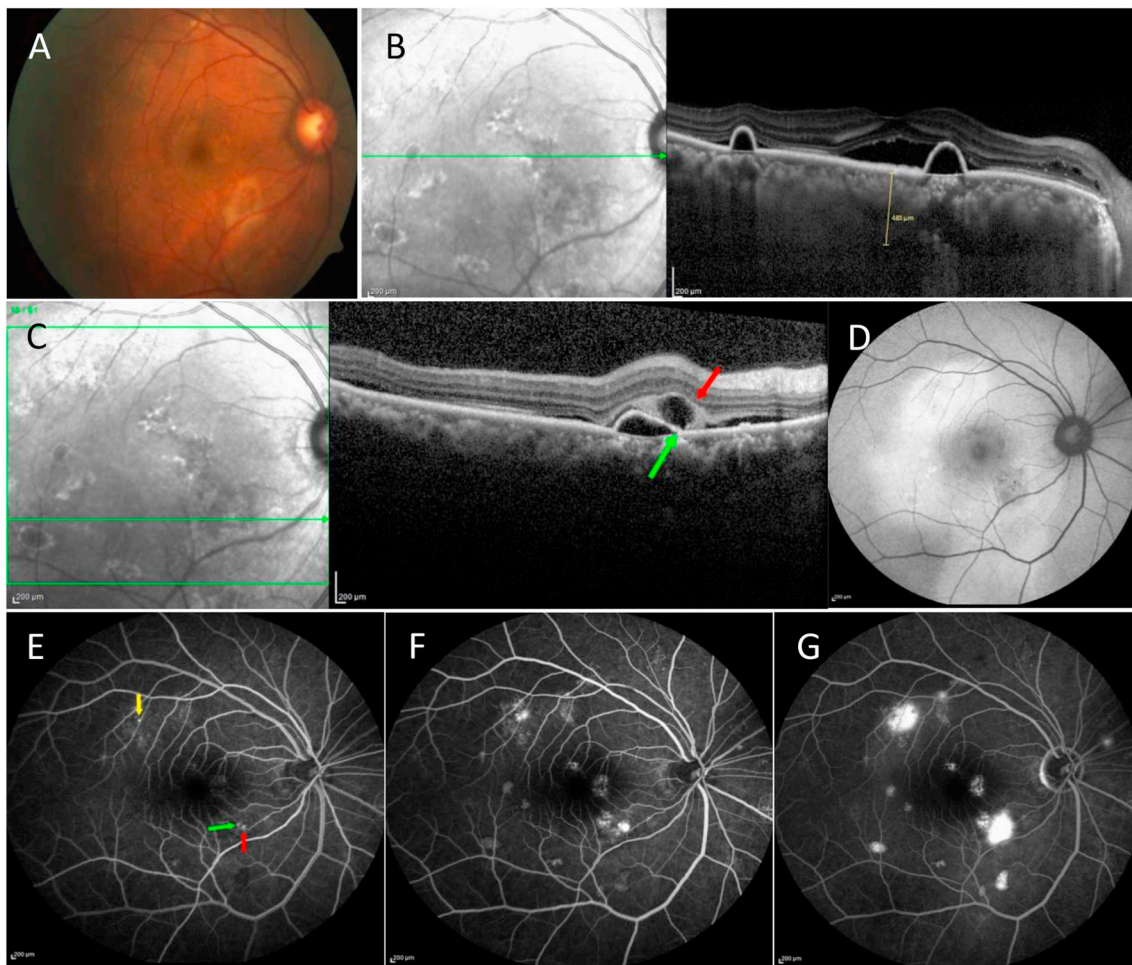


Fig. 2. Multifocal central serous chorioretinopathy. **A** Colour fundus photograph showing sub-macular detachment with fibrin. **B** Spectral domain optical coherence tomography enhanced depth imaging (SD-OCT EDI) scan showing increased subfoveal choroidal thickness, presence of subretinal fluid with multiple small serous pigment epithelial detachment. **C** SD-OCT EDI scan showing a retinal pigment epithelium micro-rip (green arrow) and a corresponding hyporeflective space within the subretinal fibrin “vacuole sign” (red arrow). **D** Fundus autofluorescence shows the presence of gravitational tract. **E, F, G** Sequential fundus fluorescein angiograms showing multifocal leaks (yellow, green and red arrows).

hyperpermeability. There also appeared to be an association with a poor baseline BCVA and female sex.

4.2.6. Subretinal haemorrhage in CSC

Subretinal haemorrhage is a complication of CSC often associated with CNV (Fig. 5). The presence of subretinal haemorrhage should raise suspicion of CNV.

4.2.7. Complex bullous CSC

Bullous CSC is a rare variant of the disease characterized by severe SRD, especially in the inferior quadrants (Fig. 6) (Cebeci et al., 2017; Balaratnasingam et al., 2016). RPE tears are very common, and patients typically have PEDs, often located in the posterior pole with internal hyperreflectivity typically representing turbid fibrin. FFA in this group typically show multifocal leaks and it is commonly misdiagnosed as acute Vogt-Koyanagi-Harada disease (see section 5). A retrospective review of patients with bullous CSC versus cCSC did not reveal any differences between patient age, visual acuity, sex, ethnicity or corticosteroid use (Balaratnasingam et al., 2016). RPE tears were seen in 95% of eyes with bullous CSC. Furthermore, peripheral non-perfusion is reported to be increased in bullous CSC in addition to hyperreflective lesions at the level of the choriocapillaris and in the walls of large choroidal vessels. It remains unclear why such a small subset of eyes with cCSC are complicated by bullous retinal detachment. Increased

diagnosis of this rare variant may enhance our understanding of both the pathophysiology and prognostic indicators for this enigmatic disease.

4.3. Multimodal imaging

With the advent of new, less-invasive imaging modalities such as Spectral Domain Optical Coherence Tomography Enhanced Depth Imaging (SD-OCT EDI) and Optical Coherence Tomography Angiography (OCTA) we can understand more about both the structure of the choroid and the vascular supply of the retina. SD-OCT EDI allows enhanced imaging of the choroid, with more accurate measurements of choroidal thickness and increased diagnosis of pachychoroid. Furthermore, this technology enables more accurate recording and classification of choroidal phenotypes. With the adoption of this technique in more centres, we can increase both the amount of information we have on choroidal phenotypes in CSC and our understanding of them.

4.3.1. Colour fundus photography

The fundus of patients with CSC typically display bullous serous detachments with or without fibrin (Fig. 3). Fibrin is depicted by yellowish subretinal material. Often choroidal tessellations can be visualised. PEDs are seen in both acute and chronic disease and are visible on

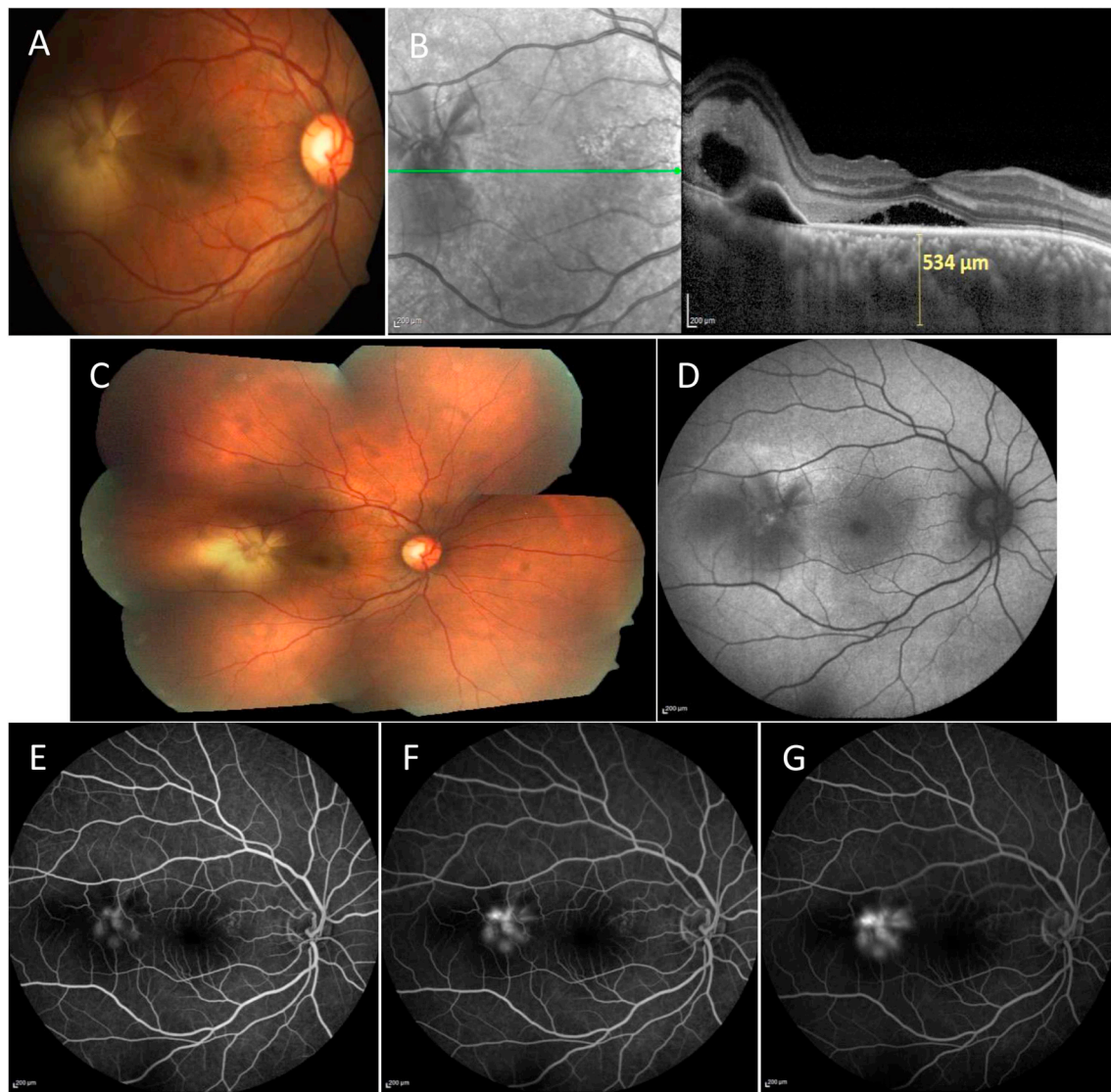


Fig. 3. Central serous chorioretinopathy with subretinal fibrin. **A** Colour fundus photograph showing sub-macular detachment. **B** Spectral domain optical coherence tomography enhanced depth imaging scan showing increased subfoveal choroidal thickness, presence of subretinal fluid, subretinal hyperreflectivity suggestive of fibrin and a serous pigment epithelial detachment. **C** Montage fundus image showing extramacular fibrinous exudate. **D** Fundus autofluorescence showing an area of ill-defined hyperfluorescence with central hypofluorescence. **E, F, G** Sequential fundus fluorescein angiograms.

colour fundus photos. Multiple RPE focal and multi-focal changes can be visualised, however are more often seen in cCSC than acute disease. RPE changes include atrophy, thickening, skip lesions, aggregations and pigmentary changes. RPE degeneration typically forms a teardrop configuration due to the gravitational tracking of fluid. In cCSC significant RPE changes can be visualised often overlying areas of choroidal thickening and dilation.

4.3.2. Multi-colour imaging

Multi-colour images are high-contrast images of the ocular fundus created by three lasers of different wavelengths. Reports state that the boundaries of CSC and areas of neurosensory detachments are visualised more distinctly on multi-colour imaging than colour fundus photos (Tan et al., 2016). Infra-red images can easily visualise neuroretinal detachment in CSC (Remky et al., 1998). One study found multi-colour green-blue enhanced images and infra-red to be superior at visualising abnormalities corresponding to the location of leakage points and RPE damage in CSC than colour fundus photographs (He et al., 2020). Multi-colour images are a useful tool in CSC, however they should always be

accompanied by additional imaging techniques for diagnosis and monitoring of disease.

4.3.3. Optical coherence tomography

Spectral domain-OCT (SD-OCT), Spectral domain enhanced depth imaging-OCT (SD-OCT EDI) and Swept source OCT (SS-OCT).

OCT is the gold standard imaging modality for follow-up of CSC patients. This non-invasive imaging technique provides fast, reproducible, high-quality images of the retina. The most typical feature of CSC is SRF, this can be seen at the macula but may also be multifocal (Figs. 3 and 4). PEDs are commonly seen, more often so in chronic disease and may be associated with SRF. Varying reports of the incidence of PEDs in CSC have been reported between 9% and 100% (Mudvari et al., 2007; Yang et al., 2013). RPE changes, such as a bump in the RPE (94%) and PEDs (11.8%) are also reported to be present in the unaffected eye (Gupta et al., 2010). Many types of PED have been described in CSC including, dome-shaped PEDs which are well-demarcated. Irregular PEDs with hyper-reflective content overlying an intact thin hyper-reflective layer are commonly seen in cCSC. This feature

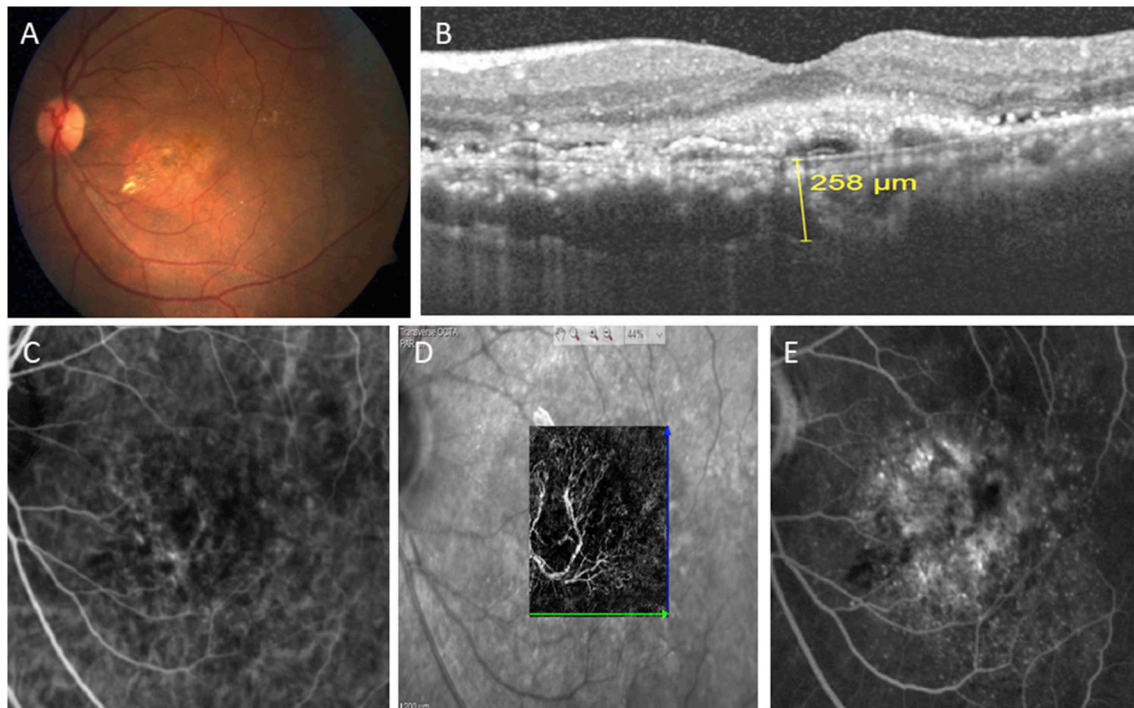


Fig. 4. Complex central serous chorioretinopathy (CSC) with presence of type 1 macular neovascularization (Type 1 MNV). **A** Colour fundus photograph showing patches of retinal pigment epithelial atrophy, faint serous macular detachment and exudates close to fovea in a patient with chronic CSC. **B** Spectral domain optical coherence tomography enhanced depth imaging scan showing dilated vessels in Haller's layer, presence of subretinal fluid, and a hyperreflective double layer sign (DLS) bounded anteriorly by the retinal pigment epithelium and posteriorly by the basement membrane. **C** Indocyanine green angiography shows a faint vascular network which is clearly seen in the **(D)** Optical coherence tomography angiography image. **E** Fundus fluorescein angiography shows speckled hyper- and hypofluorescence corresponding to the area of the network.

creates the double-layer sign (DLS) formed by two hyper-reflective layers separated by a gap: the inner layer is the hyper-reflective irregularly elevated RPE and the outer layer is the inner layer of the Bruch's membrane (Fig. 7c). The DLS was described in 2007 in patients with polypoidal choroidal vasculopathy and the space within the DLS reported to be hyperreflective (Sato et al., 2007). A hyper-reflective space within the DLS is described to be associated with CNV (Chhablani and Mandadi, 2019; Sheth et al., 2018). More recently the space within the DLS in cCSC has been described as hypo, not hyperreflective (Sato et al., 2007; Sheth et al., 2018). Large voluminous dome-shaped PEDs can also develop in CSC, and there are reports of rupture into the vitreous cavity (Daruich et al., 2015). PEDs tend to occur with areas of choroidal vascular abnormalities when visualised on SD-OCT EDI and ICGA. This supports the notion that the choroidopathy in CSC leads to RPE changes due to changes in hydrostatic pressure of the underlying choroid.

Hyperreflective dots have also been described in the neuroretina and subretinal space of CSC eyes, in addition to the choroid (Daruich et al., 2015). They tend to resolve with resolution of SRF. Diffuse RPE changes are often observed in cCSC, specifically in the diffuse pigment epitheliopathy subtype. RPE atrophy and detachment is seen as an absence of signal at the level of the RPE (Ferrara et al., 2014), RPE hypertrophy may also be observed (Yang et al., 2013). RPE microrips are seen in both acute and chronic disease, thought to represent blowouts at the edges of RPE detachments (Schatz et al., 1995) (Goldstein and Pavan, 1987; Lim and Wong, 2008; Parchand et al., 2011; Shanmugam and Bhende, 2000). The presence of hyperreflectivity in the subretinal space corresponding to fibrinous material has been reported in both acute and cCSC. Dipping of the neurosensory retina at the site of fibrin formation has also been observed (Fujimoto et al., 2008; Saxena et al., 2011; Hussain et al., 2006). The presence of fibrin associated with hyporeflectivity overlying RPE defects has been termed "the vacuole sign" (Fig. 2c) (Alshahrani et al., 2014) (Rajesh et al., 2017). The hyperreflectivity of the fibrin is thought to provide a

contrast against the hyporeflective clear fluid (the vacuole) leaking out through the RPE defect. This is reported in both acute and cCSC, however it can only be visualised with the presence of fibrin.

There are several OCT features seen only in cCSC, including posterior cystoid retinal degeneration. In 2003 cystoid macular degeneration was described in CSC and defined as cystoid spaces shown by OCT with no intraretinal fluorescein leakage in the fovea (Iida et al., 2003). Since then cystoid macular degeneration in CSC has been described to involve the fovea in 58.8% of cases with a preferential distribution in the papillomacular region (Piccolino et al., 2008). Cystoid macular degeneration in CSC can be distinguished from other chorioretinal conditions due to the mainly extrafoveal distribution. The pathophysiology behind such changes is hypothesised to result from focal chorioretinal adherence at the site of fluid exudation from the choroid. OCT findings suggest that subretinal fibrosis, as well as laser scars or spontaneous atrophic lesions of the RPE and the choroid, may be sites of chorioretinal adherence and barrier-free areas that facilitate the passage of choroidal fluid into the retina, as well as being zones of resistance to retinal detachment (Piccolino et al., 2008). It has also been hypothesised that cystoid degeneration is caused by RPE deficiency, that the RPE can no longer efficiently pump fluid out of the retina.

Diffuse atrophic RPE alterations are described in cases of severe cCSC, with the area involved tending to expand over time. The development of diffuse RPE atrophy has in fact been related to corticosteroid use (Polak et al., 1995). One study used the area of diffuse atrophic RPE alterations to help define the severity of cCSC, with a cumulative surface area of > 5 disc diameters at the macula thought to represent severe cCSC (Mohabati et al., 2018b). Future research must establish the validity of such severity criteria.

The use of SD-OCT EDI and SS-OCT in CSC are increasing as unlike conventional OCT these imaging modalities allow further analysis of the choroid. Increased choroidal thickness is commonly observed. Interestingly, this is often seen in both eyes, even if the manifestations

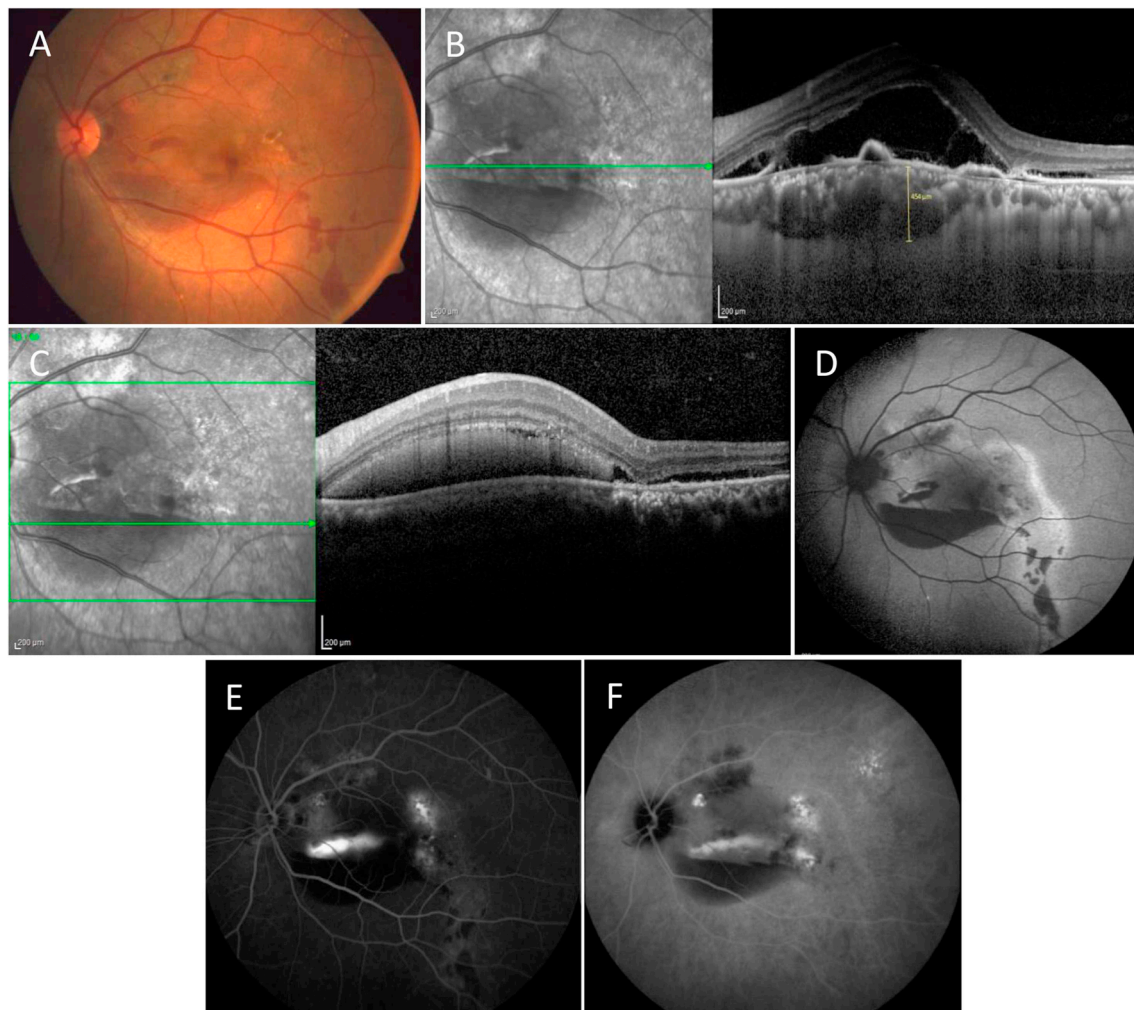


Fig. 5. Subretinal haemorrhage in central serous chorioretinopathy. **A** Colour fundus photograph showing presence of boat shaped subretinal haemorrhage inferior to the fovea, patchy hyperpigmentation along the superior arcade. **B** Spectral domain optical coherence tomography enhanced depth imaging (SD-OCT EDI) scan showing increased subfoveal choroidal thickness, presence of subretinal fluid, free edge of ripped retinal pigment epithelium and shallow pigment epithelial detachment. **C** SD-OCT EDI scan showing subretinal uniform hyperreflectivity with back shadowing suggestive of subretinal haemorrhage. **D** Fundus autofluorescence shows the presence of gravitational tract along with patches of hypoautofluorescence corresponding to areas of haemorrhage on colour fundus image. **E** Fundus fluorescein angiography and **F** Indocyanine green angiography images showing blocked fluorescence due to haemorrhage and hyperfluorescence along the gravitational tract due to window defects.

of CSC are only seen in one eye (Imamura et al., 2009). As previously discussed, choroidal thickness $> 300 \mu\text{m}$ can be assumed to be abnormal, although there are no definitive guidelines on this. A meta-analysis of 397 eyes with CSC, 228 unaffected fellow eyes and 483 normal control eyes revealed a statistically significant increase in the choroidal thickness of affected eyes vs unaffected eyes and controls (Chen et al., 2017). Furthermore, this study also demonstrated a statistically significant increase in the subfoveal choroidal thickness of the fellow eye vs controls. Measures of choroidal thickness are highly variable between observers. With one study reporting an intra- and inter-observer variability of $32 \pm 38 \mu\text{m}$ and $46 \pm 57 \mu\text{m}$, compared to $19 \pm 25 \mu\text{m}$ and $26 \pm 35 \mu\text{m}$ in normal eyes (Kim et al., 2013). This is important to consider when choroidal thickness measurements are used to monitor progress, especially that due to interventions. The inner choroidal layer will often appear thinned in the involved area due to atrophy of the choriocapillaris or compression from dilated outer choroidal vessels (Yang et al., 2013). Choroidal vessel dilation is a commonly reported feature, this can be focal or diffuse (Lee et al., 2017). There are reports of abnormal hyperreflective areas at the level of Bruch's membrane and the choriocapillaris complex, which correlate

to abnormal hypofluorescent areas in the late phase of ICGA (Shinojima et al., 2016).

There is currently no consensus on how to measure the central retinal thickness (CRT) in CSC. A commonly used parameter to gauge treatment response and disease progression. CRT is measured on OCT and has been defined as the distance between the inner and outer retinal surface (Furuta et al., 2009). Automated measurements of CRT often differ between devices depending on the segmentation algorithm used by particular software; for example, one study in normal eyes defined CRT as the distance between the internal limiting membrane (ILM) and Bruch's membrane (Myers et al., 2015), and another used the distance between the ILM and the middle of the RPE hyper-reflective band (von Hanno et al., 2017). Automated measurements of CRT often erroneously include the SRF. A recent study analysing response to PDT in recurrent CSC defined CRT as the distance from the inner border of the inner limiting membrane to the inner border of the ellipsoid zone on SD-OCT (van Rijssen et al., 2018). This was selected as it was thought to approach the true thickness of the neuroretina in most non-resolving CSC cases, which often accumulate subretinal debris. Like choroidal thickness, CRT is described to be influenced by sex, age, ethnicity and

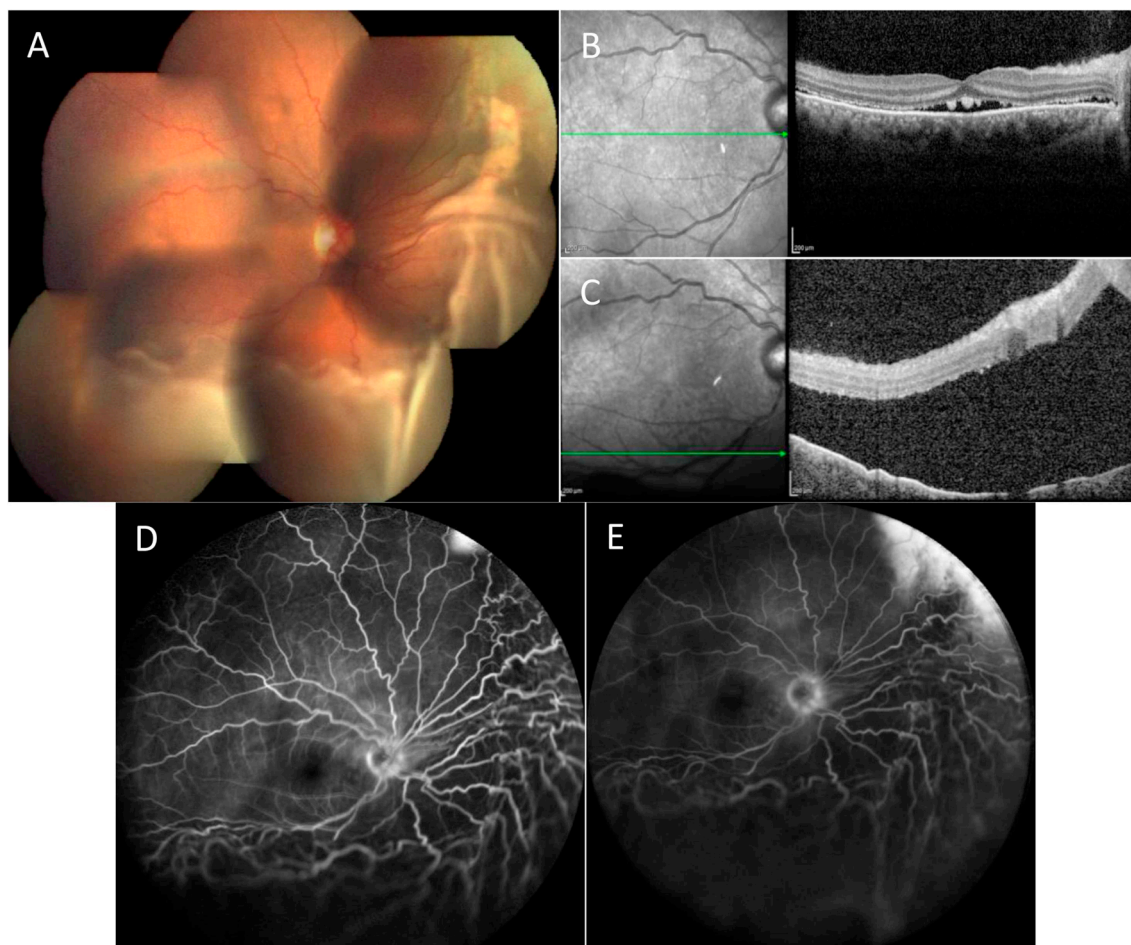


Fig. 6. Bullous central serous chorioretinopathy. A Colour montage image showing the bullous elevated retina inferiorly and nasally. B&C Spectral-domain optical coherence tomography images with shallow subretinal fluid at the fovea, elevated neurosensory retina inferiorly. D&E Fundus fluorescein angiography shows area of hyperfluorescence in the superonasal quadrant increasing in intensity with and size with ill-defined margins in the late phase suggestive of a leak.

refraction (von Hanno et al., 2017; Girkin et al., 2011; Kelty et al., 2008).

SD-OCT, SD-OCT EDI and SS-OCT are incredibly useful tools for both diagnosing and monitoring the progress of CSC.

4.3.4. Fundus autofluorescence (FAF)

FAF is a non-invasive imaging technique producing fast, high-quality images. RPE lipofuscin produces short-wavelength autofluorescence, therefore FAF images provide users with an indication of RPE metabolism. On FAF, features such as areas of granular hypo-autofluorescence and mixed stippled hyper- and hypo-autofluorescence are seen in CSC. Circumferential areas of hyperautofluorescence can be visualised corresponding to areas of SRF. In cCSC, FAF appearance is pathognomonic. Multiple gravitational track marks are seen as granular areas of hyper- and hypo-autofluorescence, often originating from the macula and optic disc (Fig. 2D). Interestingly, a correlation has been shown between the direction of gravitational tracts and the side on which patients sleep (Pang et al., 2014). Ultra-widefield FAF in CSC has helped to confirm involvement of the peripheral retina in disease. One study demonstrated more than 50% of patients to have extensive peripheral retinal involvement (Pang et al., 2014).

4.3.5. Fundus fluorescein angiography

Fundus fluorescein angiography (FFA) is a useful diagnostic test in CSC. Interestingly, the first identified FFA changes at the level of the RPE in CSC patients dates back to 1965 (Mauemenee, 1965). Ever since this description of leakage the use of FFA in CSC has increased

exponentially. Classically now on FFA, CSC is described to show RPE leakage that may have either a “smoke-stack” or an “ink-blot” pattern (Figs. 8 and 9). These leaks can be either solitary or multiple (Prunte and Flammer, 1996; Guyer et al., 1992). Additionally, there may be pooling corresponding to the serous PED while the abnormal RPE areas may illustrate either window-defects or staining. Presence of intraretinal fluid, also known as “cystoid macular degeneration” is indicative of cCSC. FFA in these cases may show presence of indistinct areas of leakage with granular window defects (Fig. 5F). Commonly seen signs in FFA are:

Early phase (up to 3 min).

Hyperfluorescent areas due to increased transmission of the normal choroidal fluorescence, indicating RPE atrophy in addition to early staining.

Intermediate phase (3–8 min).

Hyperfluorescent areas due to window defects, staining and accumulation.

Late phase (> 8 min).

Maintenance of hyperfluorescence in areas of dye staining and pooling.

4.3.6. Indocyanine green angiography (ICGA)

ICGA has become the gold-standard method for imaging the choroid. With the growing consensus that CSC is a choroidal disease ICGA has become an increasingly valuable technique, especially for diagnosing CSC complicated by CNV. Indocyanine green (ICG) is a water-soluble tricarboyanine dye that emits light in the infra-red

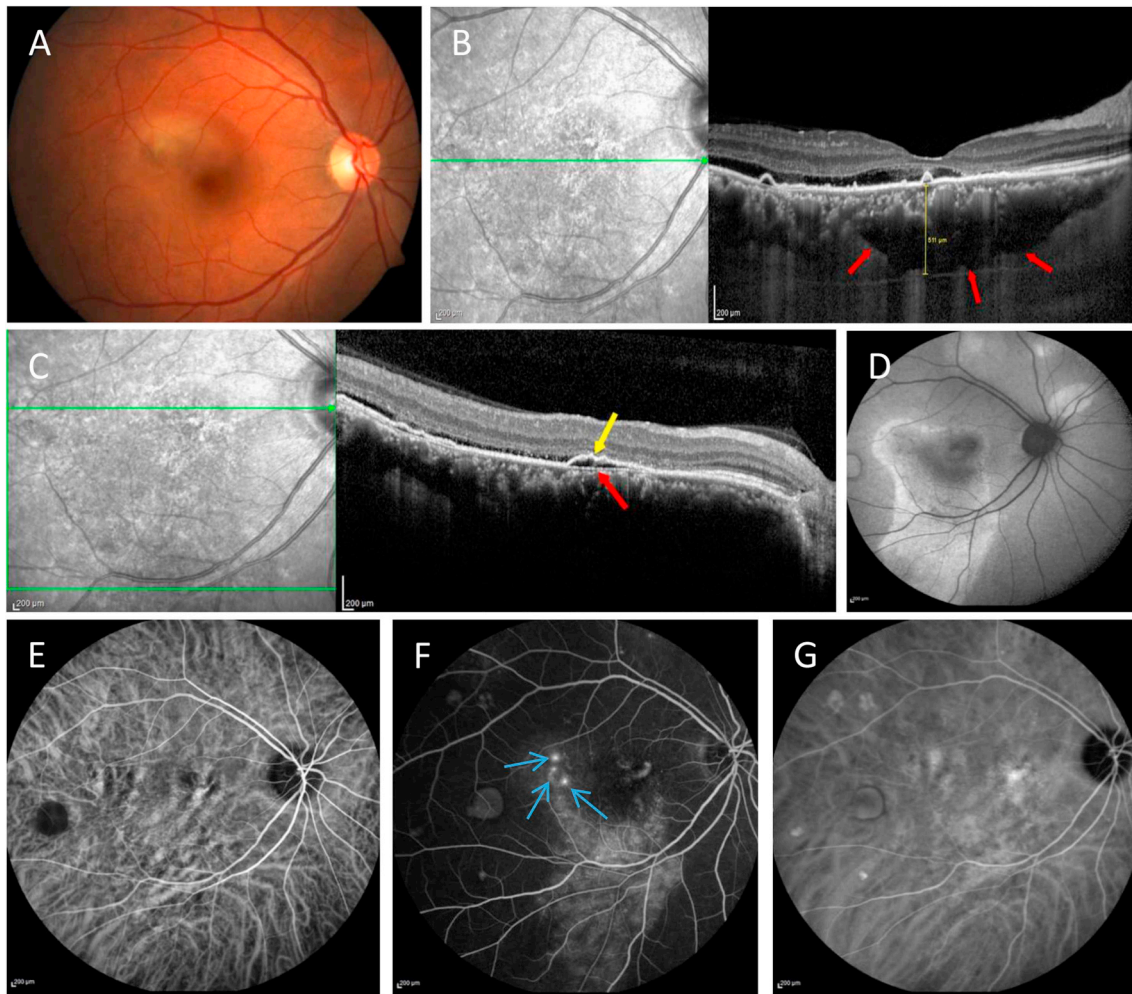


Fig. 7. Chronic central serous chorioretinopathy, multimodal imaging. **A** Colour fundus photograph showing submacular detachment with fibrin. **B** Spectral domain optical coherence tomography (OCT) enhanced depth imaging (SD-OCT EDI) scan showing subfoveal pachyvessels (*red arrows*) with increased subfoveal choroidal thickness, presence of subretinal fluid with multiple small serous pigment epithelial detachment. **C** Characteristic hyporeflective double-layer sign (DLS) bounded anteriorly by the retinal pigment epithelium (*yellow arrow*) and posteriorly by the basement membrane (*red arrow*). **D** Fundus autofluorescence shows the presence of a gravitational tract. **E-G** Indocyanine green and fundus fluorescein angiograms show dilated choroidal vessels with multiple point leaks (*blue arrows*).

portion, with maximum emission of 835 nm. This optical property allows the choroid to be visualised through the RPE. ICG is both lipophilic and hydrophilic, with 98% bound to proteins. This protein binding results in a slow leakage of ICG through fenestrated choroidal vessels allowing choroidal visualisation even in late stages. ICGA can typically be subdivided into early, mid and late phases. The choroidal changes seen in CSC at these time points are:

Early phase (1–3 min): Delayed filling of arteries and choriocapillaris (Prunte and Flammer, 1996). Dilated choroidal vessels (Pang et al., 2014). Hypofluorescent areas secondary to decreased choriocapillaris filling (Kitaya et al., 2003). Widefield ICGA has shown dilated choroidal vessels extend along the entire course of the vessel back to one or more vortex veins' ampulla before exiting the sclera (Pang et al., 2014). Thereby indicating outflow congestion of that draining vortex vein. Hyperfluorescence is seen indicating impaired choroidal permeability due to hyperpermeability.

Mid-phase (3–15 min): Dilatation of large choroidal veins in areas correlating to atrophic or elevated RPE on OCT (Hirami et al., 2007). Geographic areas of hyperfluorescence with blurred contours classically interpreted as choroidal vascular hyperpermeability (Spaide et al., 1996b; Piccolino and Borgia, 1994).

Late phase (15–40 min): Mid-phase hyperfluorescent areas evolve into either persistent hyperfluorescence, wash-out or centrifugal

displacement of the hyperfluorescence, forming hyperfluorescent rings (Tsujiyama et al., 2010). Choroidal hyperpermeability corresponding to areas of altered autofluorescence (Pang et al., 2014). ICGA, both in acute and chronic disease, shows dilated choroidal vessels and choroidal filling defects in early phase, with mid-phase indistinct hyperfluorescence and late staining (Fig. 7). Areas of RPE atrophy appear hypofluorescent on ICGA (Spaide et al., 1996b), and can first be distinguished at approximately 10 min, becoming more prominent in later stages. This hypofluorescence is thought to result from choriocapillaris hypoperfusion.

4.3.7. Optical coherence tomography angiography

Optical coherence tomography angiography (OCTA) is a relatively new imaging technique. It differs from other ocular angiographic techniques, such as FFA ICGA, which are both invasive techniques that measure the flow of plasma. OCTA conversely measures the movement of blood cells and is non-invasive. Furthermore, the ability for depth-resolved analysis allows flow in a specific axial location of the retina/choroid to be analysed. Its use in CSC is still in its infancy.

Multimodal imaging in CSC indicates SRF accumulation results from a thickened, congested, hyper-permeable choroid leaking fluid through a dysfunctional RPE (Filho et al., 2015; Sacconi et al., 2018). Therefore, the ability to image choroidal blood flow in CSC may provide insights

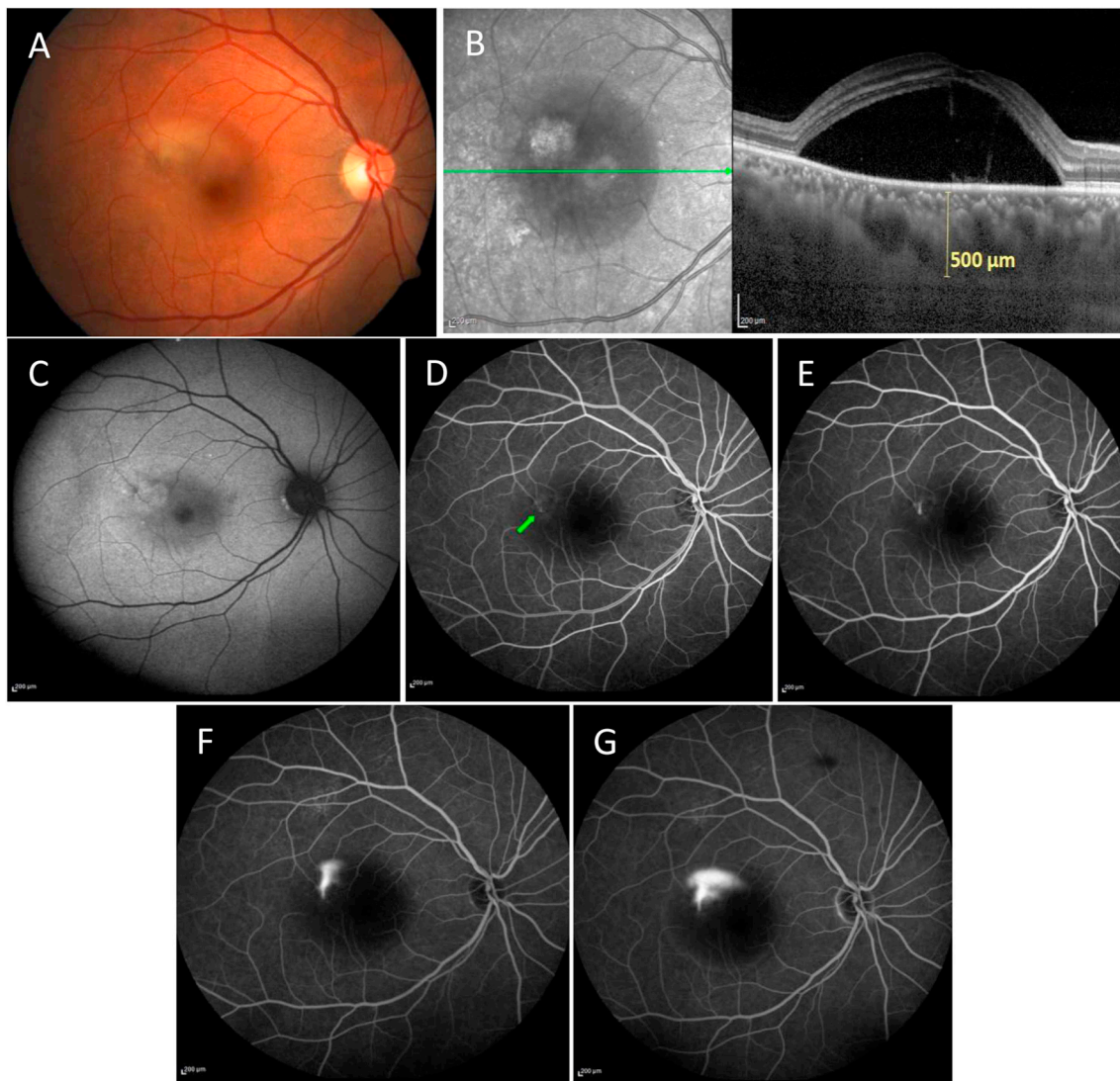


Fig. 8. Central serous chorioretinopathy with smoke stack focal leak. **A** Colour fundus photograph showing serous macular detachment with fibrin. **B** Spectral domain optical coherence tomography enhanced depth imaging scan showing increased subfoveal choroidal thickness and presence of subretinal fluid. **C** Fundus autofluorescence showing a well-defined area of hyperfluorescence with central hypofluorescence. **D, E, F, G** Sequential fundus fluorescein angiograms showing leakage of dye in a smoke stack pattern (*green arrow shows initial focal hyperfluorescence*).

into the disease in addition to helping with monitoring and treatment planning.

There are some reports of the use of OCTA in CSC, with dark spots and dark areas visible at the choriocapillaris and an increased false positive rate of CNV due to the abnormal choroidal vessel architecture seen in CSC patients (Costanzo et al., 2015). The dark areas are described as diffuse or focal, foggy, ill-defined, low-detectable flow areas, while dark spots are described as black, single or multiple, well-delineated areas with no detectable flow at the choriocapillaris level. The dark areas usually correspond to SRF and dark spots to PED, subretinal deposit, choroidal cavitation, choroidal excavation and choroidal fluid (De Bats et al., 2018). Abnormal choroidal vessels are described as distinct, well-delineated, high-flow, tangled pattern areas in the choriocapillaris as well as an abnormal dilation of choroidal vessels. Further reports suggest “white spots” which, correspond with the leaking point on FFA or with hyper-reflective dots (De Bats et al., 2018) and “white filamentous pattern” at the Bruch’s membrane level corresponding to abnormal choroidal neovascular vessels (De Bats et al., 2018).

Published reports suggest OCTA can identify otherwise unknown CNV in cCSC when used in conjunction with FFA (Filho et al., 2015).

Dye-based angiography is the current gold standard for diagnosing CNV, however this can be difficult in CSC where choroidal/retinal abnormalities may obscure CNV. A small series evaluated the use of OCTA in predicting response to eplerenone (Sacconi et al., 2018). The presence of CNV on ICG-A or OCTA was found to predict an unfavourable response to eplerenone (Sacconi et al., 2018). Suggesting that patients with CSC should have an OCTA to help exclude CNV prior to commencing eplerenone therapy, as anti-VEGF may be more effective in these cases. However, the VICI trial found no evidence of an effect of eplerenone in patients for whom CNV had been excluded by FFA and ICGA (Lotery et al., 2020).

OCTA in CSC gives some insights into disease pathogenesis. There are reports of choriocapillary hypoperfusion with reactive hyperperfusion in the surrounding area, which could lead to increased hydrostatic pressure and disruption of the RPE (De Bats et al., 2018). Furthermore, low flow is detected in the choriocapillaris, which may be due to compression by enlarged choroidal vessels. PEDs have been found above dilated vessels indicating a form of mechanical stress on the RPE from underlying compression (De Bats et al., 2018).

OCTA does have its limitations, analysis of deep choroidal vessels is

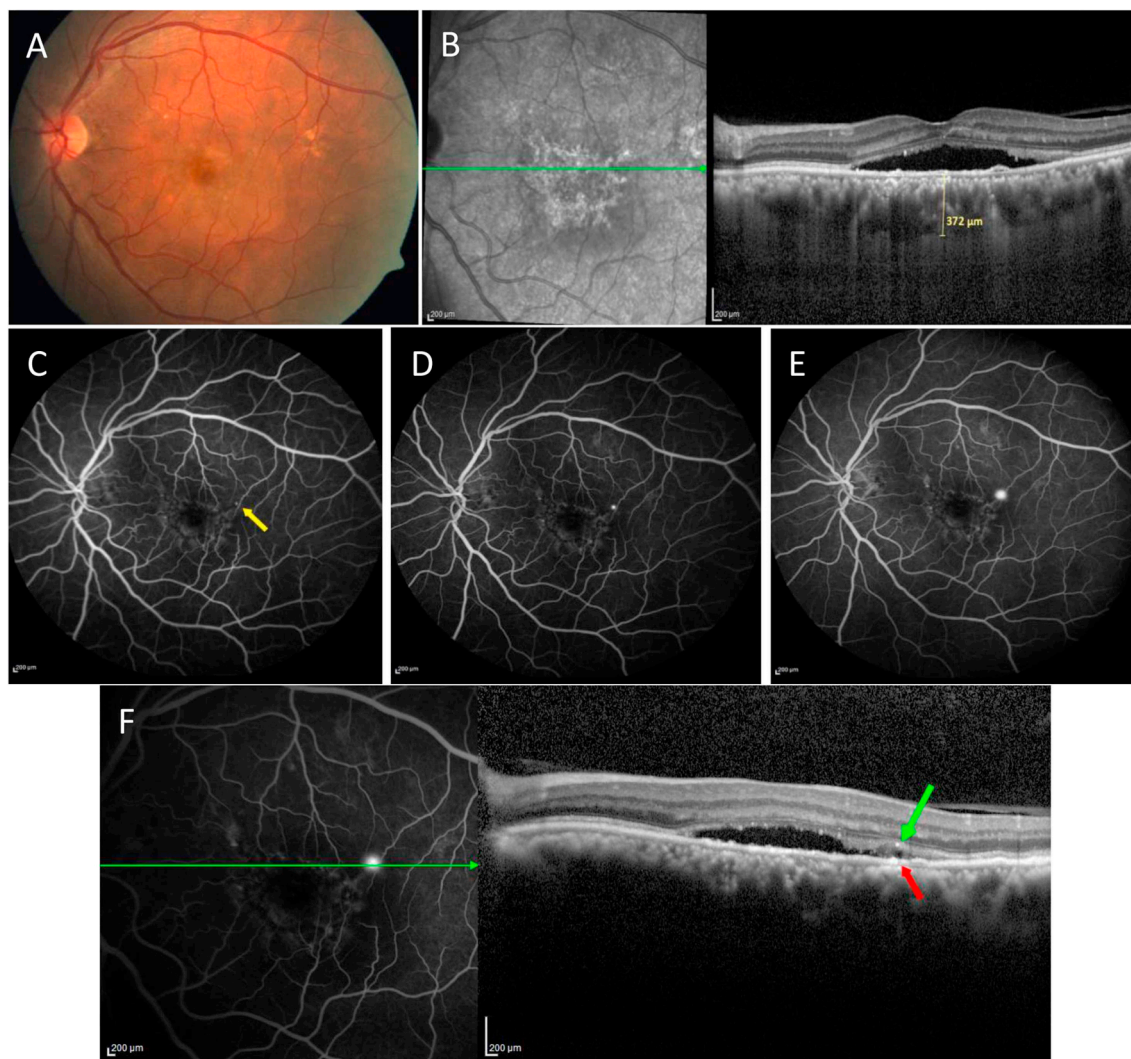


Fig. 9. Central serous chorioretinopathy with ink blot focal leak. **A** Colour fundus photograph showing serous macular detachment. **B** Spectral domain optical coherence tomography (OCT) enhanced depth imaging scan showing increased subfoveal choroidal thickness and presence of subretinal fluid. Undulating retinal pigment epithelium (RPE) is seen subfoveally. **C, D, E** Sequential fundus fluorescein angiograms (FFA) showing leakage of dye in ink blot pattern (*yellow arrow*). **F** FFA and OCT line scan through area of interest shows presence of RPE micro-rip (*red arrow*) and a corresponding hyporeflective space within the hyperreflective subretinal fibrin “vacuole sign” (*green arrow*) corresponding to the leak.

difficult unless there is an overlying area of RPE atrophy. Furthermore, choroidal imaging requires manual segmentation, which some users may not be familiar with.

Improved characterisation of choroidal phenotypes using the aforementioned imaging modalities will give us the potential to combine imaging in the clinic with genetic testing in the laboratory. As both genetic research and choroidal imaging improves, new endophenotypes could be established allowing us to sub-categorise CSC patients. Further categorisation of CSC patients could then result in personalised treatment strategies.

4.3.8. Adaptive optics

Adaptive optics is a relatively new tool that when combined with scanning light ophthalmoscopy (AOSLO) allows the visualisation of individual cone photoreceptors in the living eye. A nonconfocal variation of AOSLO called split-detector has also been developed. This enables visualisation of certain structures that can't be seen with the standard confocal technique, such as cone inner segments (Scoles et al., 2014). The use of adaptive optics in CSC allows both an increased understanding of the disease at the cellular level in addition to a new method of phenotyping patients. Initial AOSLO studies in CSC focused

on patients with resolved CSC, notably Ooto et al. examined 45 eyes with resolved CSC in comparison to 20 control eyes (Ooto et al., 2010). They showed abnormal cone mosaic patterns and reduced cone densities in eyes with resolved CSC, and these abnormalities were associated with VA loss. Confocal and split-detector AOSLO was used to study the intraretinal structures in five patients with active and resolved CSC in comparison to SD-OCT (Vogel et al., 2017). AOSLO showed multiple intraretinal hyperreflective clusters in subjects with CSC in both the inner and outer retina. Detailed appearances of these clusters were visualised using AOSLO, such as size, association with retinal vessels and their relationship with the photoreceptor mosaic. Larger studies using AOSLO are needed to determine the significance of such clusters and their relationship to disease prognosis in CSC.

Adaptive optics has also been used to quantify photoreceptor density in CSC and correlate with retinal layer thickness. Twelve patients with resolved CSC underwent imaging after resolution of SRF and again 12 months after this (Nakamura et al., 2016). Adaptive optics showed a statistically significant increase in the density of cones at 12 months post SRF resolution, coupled with a significant increase in the mean outer retinal layer thickness at 12 months post-resolution.

The use of adaptive optics in day to day practice in CSC is very

limited, and as a new technique its value in the progression of CSC phenotyping and management is still to be discerned.

5. Conditions misdiagnosed as CSC

5.1. Neovascular disease

5.1.1. Macular neovascularization

Type 1 macular neovascularization (Type 1 MNV) can be mistaken as CSC and vice versa. MNV may be an infrequent complication of CSC, with an incidence rate ranging from 2% to 18%, thereby adding to misdiagnoses (Loo et al., 2002) (Spaide et al., 1996a; Fung et al., 2012; Shiragami et al., 2018; Nicholson et al., 2018a). MNV tends to affect an older group of patients and conversely to CSC is more commonly seen in myopic patients (where as CSC is often seen in hyperopes and emmetropes). Both MNV and CSC affect the macula and result from pathology at the level of the choroid and the RPE. MNV typically responds to anti-VEGF, although there have been reports of CSC responding to anti-VEGF (Seong et al., 2009), this may be misdiagnosis in the first instance or CSC complicated by MNV. Clinicians should consider the diagnosis of CSC in those patients with MNV refractory to treatment with anti-VEGF.

5.1.2. Polypoidal choroidal vasculopathy (PCV)

PCV also known as aneurysmal type 1 neovascularization is considered to be part of the pachychoroid disease spectrum, however it also falls under the category of neovascular diseases. Subretinal leakage from type 1 (sub-RPE) neovascularization as a result of pachychoroid neovascularopathy may mimic uncomplicated cCSC (Fung et al., 2012; Pang and Freund, 2015). An in-depth discussion of PCV can be found under the pachychoroid disease section below (6.2).

5.2. Inflammatory disease

There are several inflammatory diseases that can mimic CSC, however a noticeable distinguishing factor is the presence of inflammatory cells.

5.2.1. Vogt-Koyanagi-Harada (VKH)

VKH is a multi-system auto-immune disease affecting pigmented tissues. VKH typically causes blurring of vision and a bilateral panuveitis is often seen. There is a thickening of the posterior choroid seen due to choroidal stromal inflammation, with elevation of the peripapillary retinal choroidal layer and multiple exudative bullous serous retinal detachments (Rao et al., 2010). The acute form of VKH is characterized by the presence of bilateral exudative retinal detachments. Exudative retinal detachment is also a feature of CSC. Consequently, a diagnostic dilemma can occur. CSC may be misdiagnosed as VKH when it presents with bilateral serous retinal detachment and increased choroidal thickness on SD-OCT EDI (Shin et al., 2015; Lin et al., 2014; Aggarwal et al., 2017). VKH and CSC can be differentiated on the basis of history, clinical features and ancillary investigations such as FFA, ICGA and SD-OCT EDI. Both VKH and CSC affect a similar age group, however CSC is predominantly a disease of males and VKH affects more females (Rao et al., 2010). With regard to clinical features the majority of VKH patients display anterior or vitreous cells, however in CSC this is rarely seen. Furthermore, optic disc hyperemia is a recognised feature of VKH, but is not seen in CSC. Corresponding to this FFA in VKH often shows leakage around the disc, this is not typically seen in CSC. In both VKH and CSC multi-focal leakage in late stages of FFA can be seen, but more often so in CSC. ICGA in VKH is reported to demonstrate hypofluorescent dots in the late stages often corresponding to choroidal ischaemia, whereas late phase ICGA in CSC shows choroidal hyperpermeability.

In one series 22% of patients with VKH were initially misdiagnosed as CSC (Yang et al., 2007). Another study reports 14.3% of VKH cases to be misdiagnosed secondary to the absence of a cellular inflammatory

reaction or typical features such as sub-retinal septae and RPE folds on SD-OCT EDI (Shin et al., 2015). Importantly VKH is an inflammatory disease treated with corticosteroids, however as previously described CSC does not respond to corticosteroids, they are in fact a risk factor for disease. These different management strategies make differentiating these two conditions essential, as a treatment for one can worsen the other.

5.2.2. White dot syndromes

White dot syndromes is a term used to describe a group of non-infectious retinal, RPE and choroidal inflammatory conditions characterized by multiple yellow-white lesions evident in the outer retina, RPE or choroid. Similarly to CSC serous neurosensory detachment at the macula can be seen in some white dot syndromes such as acute multifocal placoid pigment epitheliopathy and punctuate inner chorioidopathy (Watzke et al., 1984) (Birnbbaum et al., 2010). These conditions can be differentiated from CSC on the basis of fundus findings, with yellow white lesions seen.

5.3. Malignancy

5.3.1. Solid tumours

5.3.1.1. Choroidal melanoma. Choroidal melanoma is a rare condition that can be misdiagnosed as CSC. Typically presenting with non-specific features, many of which can be seen in CSC such as flashes, floaters, blurred vision and metamorphopsia (Shields et al., 2014). Choroidal melanoma often displays SRF, one series reports it is present in approximately 92% of cases (Shields et al., 2014). SRF is a known feature of CSC. Conversely to CSC SD-OCT EDI will often show a raised lesion in choroidal melanoma, however flat choroidal melanomas do occur. Ultrasound in choroidal melanoma will show a low reflectance choroidal mass in the majority of cases. There are several case reports where choroidal melanoma has been misdiagnosed as CSC, therefore it is important to recognize the cross-over between clinical features and to perform an ultrasound A-scan in atypical cases (Higgins et al., 2016) (Rishi et al., 2016; Scott et al., 2008).

5.3.2. Vascular tumours

5.3.2.1. Choroidal haemangioma. Choroidal haemangioma typically presents with an orange-red lesion in the posterior pole associated with a serous detachment at the macula. It is a benign tumour of the choroid frequently located in the paramacular area. Distinguishing this condition from CSC can be complicated by obscuration of the lesion by SRF. Ultrasound is an incredibly useful test if choroidal haemangioma is suspected, detecting a choroidal mass with acoustic solidity on the B-scan and high internal reflectivity on A-scan (Konana et al., 2018). Furthermore, ICGA in choroidal haemangiomas shows early hyperfluorescence followed by a classic “wash-out phenomenon” during mid- and late phases (Shields et al., 2001). Choroidal haemangioma can be treated with PDT.

5.3.3. Haematological malignancy

5.3.3.1. Primary B-cell lymphoma of the choroid. Proliferation of lymphoid cells in the uveal tract is uncommon. Primary choroidal lymphoma is a rare disease, presenting with a slowly progressing reduction in vision. Patients can display serous retinal detachments in a similar manner to CSC (Mashayekhi et al., 2014). One differentiating factor is the presence of choroidal infiltrates, visualised on fundal examination as creamy-yellow patches at the level of the choroid. Obscuration of the choroidal blood vessels is another feature seen in choroidal lymphoma. The most useful noninvasive diagnostic tool to distinguish this condition is ultrasonography. The typical B-scan appearance is of an acoustically hollow thickening of the choroid.

5.3.3.2. Leukaemia. Acute leukaemia presents with ocular manifestations in approximately 32–80% of people. Central serous retinal detachment is

an uncommon feature, however it has been reported as a clinical manifestation in a number of cases (Moulin et al., 2010) (Gronbech et al., 2014) (Malik et al., 2005; Fackler et al., 2006). FFA in acute lymphoblastic leukaemia demonstrates multiple mid-phase and late dot like areas of hyperfluorescence accompanied by accumulation of fluid in the area of neurosensory detachment in the late phase. FFA does not show the typical smoke-stack or ink-blot features seen in CSC. A concise history is key to differentiation in atypical cases of serous detachment.

5.3.3.3. Waldenström macroglobulinemia. Waldenström macroglobulinemia is a malignant proliferative B-cell disorder. Hyperviscosity syndrome due to overproduction of immunoglobulin type M (IgM), a large pentamer molecule that easily forms aggregates, is a well-known association of Waldenström macroglobulinemia occurring in 17% of patients (Merlini et al., 2003; Thomas et al., 1983). Of those affected with hyperviscosity syndrome 37% exhibit hyperviscosity-related retinopathy, and in a small subset of these patients' serous retinal detachments at the macula have been described (Baker et al., 2013; Thomas et al., 1983). The absence of angiographic leakage within the macular detachment suggests that exudation from the retinal or choroidal vasculature is not the primary mechanism through which SRF accumulates. The angiographically "silent macula" has been recognised as a hallmark of immunogammopathy-induced serous macular detachments, helping to distinguish this from CSC (Ho et al., 2000).

5.4. Genetic

5.4.1. Best's disease

Mutation of the *BEST-1* gene encompasses a spectrum of disease including Best vitelliform macular dystrophy, adult-onset vitelliform macular dystrophy, autosomal dominant vitreoretinopathy and autosomal recessive bestrophinopathy. *BEST-1* codes for bestrophin-1, which functions as a membrane channel in the RPE. All of the aforementioned diseases can present with a neurosensory retinal detachment, similarly to CSC (Boon et al., 2009). Best's disease is often diagnosed with an electro-oculogram, characterized by a decreased Arden ratio, not seen in CSC (Deutman, 1969). Furthermore, many cases are autosomal dominant, therefore examination of family members may reveal the diagnosis, unlike CSC. There are several other clinical features specific to the bestrophinopathies, such as egg yolk-like round lesions affecting the macula in Best vitelliform macular dystrophy that can help to identify these conditions and differentiate them from CSC.

5.4.2. *RP111*-associated retinal dystrophy

Mutations in the retinitis pigmentosa-1-like-1 (*RP111*) gene are a major cause of autosomal dominant occult macular dystrophy. This rare condition causes a slow progressive loss of visual acuity, however sporadic cases have also been reported. There are case reports of mutations presenting with subfoveal retinal detachments (Takahashi et al., 2014), thereby placing it as a differential diagnosis for CSC. Conversely to CSC, FFA and ICGA are typically normal in this condition, and the strong familial component should suggest an inherited retinal dystrophy.

5.5. Anatomical

5.5.1. Optic disc pit

This condition is thought to result from incomplete closure of the superior aspect of the embryonic fissure. Optic disc pits are congenital and seen as focal excavations in the optic disc, often in the infero-temporal aspect. It can be confused with CSC as some patients develop a maculopathy characterized by serous macular detachment. Serous detachments associated with optic disc pits can be differentiated from CSC by the characteristic optic disc appearance and the absence of a leak on FFA and ICGA (Zaidi et al., 2011).

5.5.2. Dome-shaped macula

This term refers to a dome shaped elevation at the macula seen in patients with high myopia. It can be misinterpreted as CSC due to the presence of serous retinal detachment in 50% of cases (Caillaux et al., 2013). Both CSC and dome-shaped macula have similar features on FFA and ICGA. Consequently, differentiating the two can be difficult. Importantly, CSC is rare in myopia and the presence of a bulge at the macula can help to distinguish the two. A vertical line scan on OCT can help identify the presence of a dome shaped maculopathy.

5.6. Medication

5.6.1. Mitogen Activated protein Kinase (MEK) inhibitor associated serous retinopathy (MEKAR)

The RAS/RAF/ERK/MEK pathway is one of the essential pillars of cell biology. This signalling pathway functions to transduce signals from the extracellular milieu to the cell nucleus where specific genes are then activated for cell growth, division and differentiation. Dysregulation of this pathway is a common event in cancer as Ras is the most frequently mutated oncogene in human cancer. Consequently, manipulation of this pathway with (B-Raf) BRAF and MEK inhibitors has demonstrated potential therapeutic value in the treatment of various malignancies including advanced melanoma and low-grade ovarian cancer (Cheng and Tian, 2017). BRAF/MEK inhibitors have many side effects; interestingly, in a subset of patients they appear to cause a serous retinal detachment with some similar features on OCT to CSC (Urner-Bloch et al., 2014; van Dijk et al., 2015; Coutu et al., 2016). Patients report mild visual disturbances and, in all cases, the serous fluid resolves despite continuation of the treatment. This spontaneous resolution may be linked to tachyphylaxis; however, this is still an assumption. The relative frequency with which this occurs has led to the coining of a new diagnosis, MEK inhibitor associated retinopathy 'MEKAR'.

There is however evidence to suggest that MEKAR is a disease mainly caused by RPE dysfunction, unlike CSC, which is largely due to choroidal changes (van Dijk et al. 2015, 2018b; Francis et al., 2017). Furthermore, in contrast to CSC no hot spot leakage is seen on FFA and choroidal changes are not present on ICGA, thereby allowing further differentiation of these two conditions. Reports have also shown that the medication may have a primary effect on the RPE, thereby causing this dysfunction (van Dijk et al., 2016b).

6. CSC within the pachychoroid spectrum

From being first described as a group of disorders having a common clinical feature of "pachy" or thick choroid, the definition now encompasses a range of clinically distinct entities. Current literature indicates that pachychoroid disease spectrum consists of pachychoroid pigment epitheliopathy (PPE), CSC, pachychoroid neovascularopathy (PNV), polypoidal choroidal vasculopathy (PCV), focal choroidal excavation (FCE) and peripapillary pachychoroid syndrome (PPS). The phenotypes of these entities are characterized by presence of pachy-vessels, diffuse or focal areas of increased choroidal thickness and marked attenuation of the choriocapillaris (Warrow et al., 2013; Pang and Freund, 2015; Dansingani et al., 2016a). Apart from the aforementioned common features each of them has distinctive features that, in part, help to explain the diverse pathogenesis and progression of the diseases. The concepts pertaining to the pathophysiology of this spectrum are evolving and at times, conflicting. In particular, it is important to clinically distinguish CSC from PCV.

6.1. Pachychoroid pigment epitheliopathy (PPE)

This is a distinct clinical entity within the spectrum of pachychoroid with characteristic features on multimodal imaging of the macula (Fig. 10), first described by Warrow et al. in 2013 (Warrow et al.,

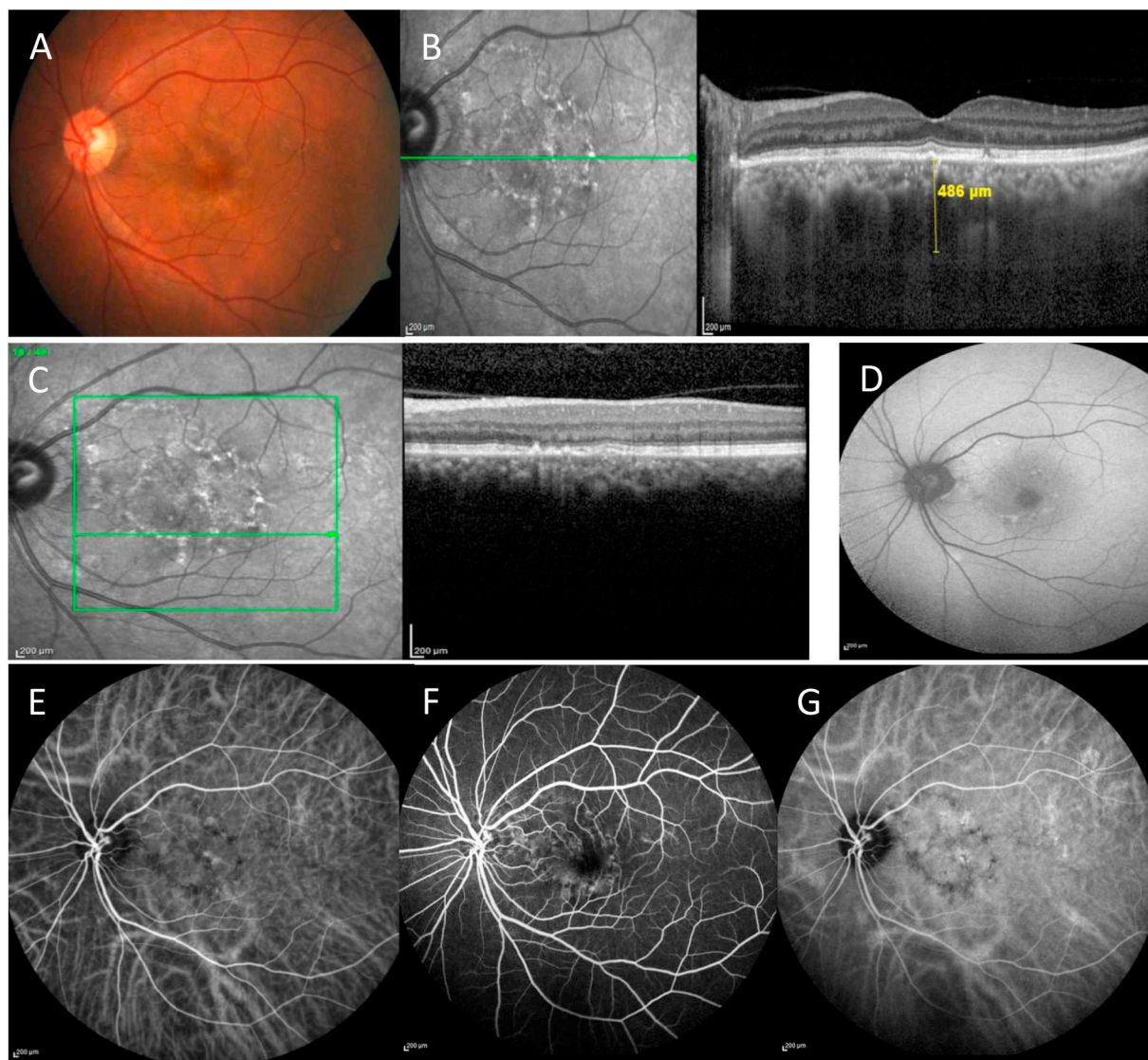


Fig. 10. Pachychoroid pigment epitheliopathy. **A** Colour fundus photograph showing retinal pigment epithelium (RPE) mottling at the macula. **B** Spectral domain optical coherence tomography (OCT) enhanced depth imaging scan with increased subfoveal choroidal thickness and pachyvessels. **C** OCT scan showing RPE disruption and absence of sub-retinal fluid or intra-retinal fluid. **D** Fundus autofluorescence shows annular patchy hyperautofluorescence. **E-G** ICGA and FFA images show dilated choroidal vessels with absence of leaks or polyps.

2013). This entity is distinguished from typical CSC as patients display RPE irregularity without SRF. Thus, PPE has been considered to represent a ‘forme fruste’ of CSC.

Fundoscopic examination often shows an orange reddish appearance and absence of or reduced fundus tessellation that indicates an underlying pachychoroid. In many cases, examination of the apparently uninvolved fellow eyes of patients manifesting unilateral SRF reveals nonspecific RPE changes without a known history of CSC or evidence of prior SRF on multimodal imaging. Imaging findings show the presence of a subfoveal thickened choroid as seen on SD-OCT EDI with a definite absence of SRF. Additional findings on OCT include numerous, scattered small elevations of the RPE representing RPE hyperplasia and sub-RPE drusen-like deposits or “drusenoid RPE lesions”. Occasionally, small serous PEDs are present. The defining feature of PPE on OCT is that of a thick choroid which is usually located directly beneath the clinically apparent RPE change. Large choroidal vessels in the Haller’s layer often approximate Bruch’s membrane without superseding Sattler’s layer (Dansingani et al., 2016a).

6.2. Pachychoroid neovascularopathy and polypoidal choroidal vasculopathy

Pachychoroid Neovascularopathy (PNV) (Fig. 11), is primarily a type 1 MNV without any terminal aneurysms. Dansingani and colleagues proposed the name aneurysmal type 1 neovascularization (AT1) as it points to the true nature of the disease (Dansingani et al., 2018) (Cheung et al., 2018).

Typically, PCV can be suspected clinically with the presence of reddish orange sub-retinal nodules, sero-sanguineous maculopathy and a disproportionate amount of exudation compared to the size of the lesion, haemorrhagic PED/spontaneous submacular haemorrhage or nonresponsiveness of a suspected case of wet AMD to anti-VEGF therapy (Fig. 12).

Based on OCT, PCV can be suspected if there is presence of any one of the following features:

- 1) Thumb-like polyp/sharp peaked PED: denotes polyp
- 2) Tomographic notch in PED: signifies the polypoidal lesion at the margin of the PED

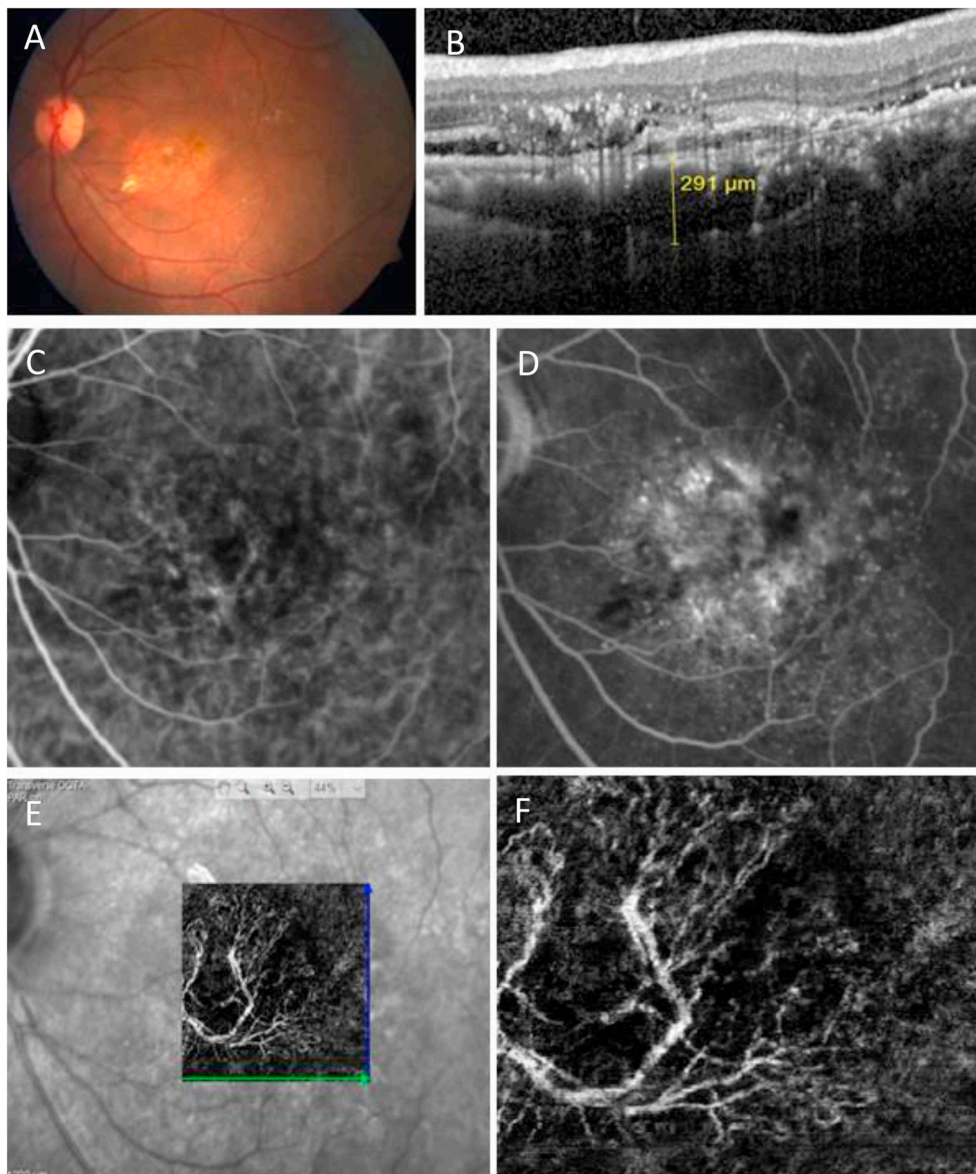


Fig. 11. Pachychoroid neovascularopathy (PNV). **A** Colour fundus photograph shows reduced background tessellation with extrafoveal exudation. **B** Spectral domain optical coherence tomography (SD-OCT) scan shows presence of hyperreflective double layer sign with underlying pachyvessels and presence of SRF. **C** Indocyanine green angiography shows a faint network visible in the macular area. **D** Corresponding area on fundus fluorescein angiogram shows stippled hyperfluorescence suggestive of type 1 neovascularization. **E-F** Optical coherence tomography angiography shows a definite network in the macular area.

- 3) Hyporeflective lumen surrounded by hyperreflective ring attached to under surface of RPE
- 4) DLS: Presence of two hyperreflective lines on SD-OCT representing shallow irregular RPE elevation and Bruch's membrane, signifying abnormal vascular network (De Salvo et al., 2014; Liu et al., 2016b; Anantharaman et al., 2018).

The pathophysiological process behind PCV is thought to surround the thinning of inner choroidal layers and pre-existing reduced vascularity in the macular choroid, which then establishes an ischemic milieu that triggers a vascular endothelial growth factor (VEGF) drive. This leads to neovascularization that develops between the RPE and Bruch's membrane at the site of the pachyvessels and damaged RPE. Angiogenesis in these eyes give rise to pachychoroid neovascularopathy or polypoidal choroidal vasculopathy. Even though these two entail formation of macular neovascularization they differ from neovascular AMD, both in terms of aetiology and thereby in their management strategies. Moreover, even though patients with AMD and those with

pachychoroid neovascularization have been found to have similar genetic profiles with respect to established AMD risk alleles, their frequencies were very low and similar in non-neovascular and neovascular pachychoroid phenotypes (Dansingani et al., 2016b).

6.3. Focal choroidal excavation (FCE)

Focal choroidal excavation (Fig. 13) is defined as a local idiopathic depression in the choroid in patients lacking any systemic cause for choroidal thinning (Obata et al., 2013). Previously considered to be a congenital condition, multiple studies have documented association of focal choroidal excavation with CSC, PCV and PNV (Kobayashi et al., 2012; Suzuki et al., 2014; Phasukkijwatana et al., 2018). Whether CSC leads to excavation or it is a complication in eyes with excavation is yet to be determined. Nevertheless, FCE is now considered an entity among the pachychoroid spectrum of diseases. Choroidal imaging of the FCE shows abnormal underlying choroidal tissue. Also, a frequent occurrence of neovascularization within the excavation endorses the idea

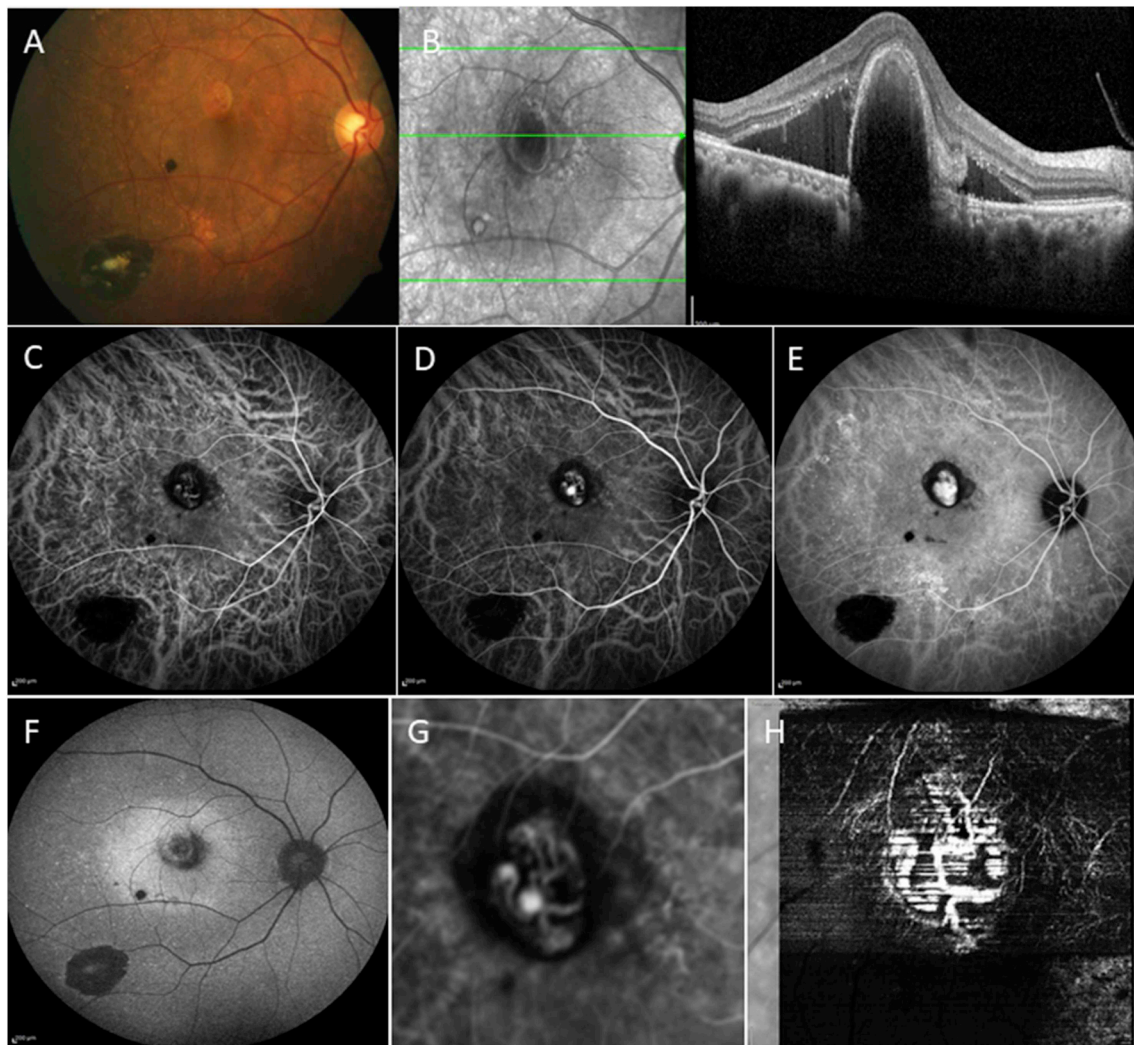


Fig. 12. Polypoidal choroidal vasculopathy. **A** Colour photograph showing RPE mottling along the inferotemporal arcade. **B** Spectral domain optical coherence tomography (SD-OCT) scan shows subfoveal pachyvessels, serous macular detachment and a tall peaked pigment epithelial detachment (PED). **C-E** Sequential indocyanine green angiography (ICGA) images showing gradual filling up of the submacular polypoidal network. **F** Fundus autofluorescence shows a well-defined area of hyperautofluorescence corresponding to the area of subretinal fluid, and a central area of hypoautofluorescence at the site of the PED. **G&H** Combination of ICGA and OCT angiography images showing comparable morphology of the network in both modalities.

that formation of the dip or “inverse PED” further worsens the inner choroidal blood flow. Pro-inflammatory factors that cause degradation of the extracellular matrix may also lead to fibrosis resulting in focal scarring and retraction of RPE (Chung et al., 2017). Eyes with FCE may show non-specific pigmentary changes on fundus examination with reduced fundus tessellation characteristically seen in eyes with pachychoroid. On the basis of SD-OCT, FCE has been divided into a conforming and non-conforming type depending on the absence or presence of a hyporeflective cleft respectively. The subfoveal choroid is thick and there may be a pachyvessel associated with the excavation. Findings on FFA include varying degrees of hyper or hypo fluorescence corresponding to the area of FCE. ICGA shows choroidal hyperpermeability and there may be patches of hypofluorescence corresponding to choriocapillaris atrophy.

6.4. Peripapillary pachychoroid syndrome (PPS)

A recent addition to this spectrum includes peripapillary pachychoroid syndrome (PPS) (Fig. 14), described recently by Phasukkijwatana et al., (2018). In this entity, the primary pathological changes of increased choroidal thickness, with intraretinal and/SRF is present in the peripapillary location, specifically involving the nasal

macular area. Concurrently, there may be the presence of other features of pachychoroidopathy including RPE changes and serous PEDs. FAF may show gravitational tracks. ICGA will demonstrate peripapillary dilated choroidal vessels with mid-phase hyperfluorescence while FFA shows peripapillary staining.

6.5. Pachychoroid with drusen (pachydrusen)

Pachydrusen has recently been described as a unique form of drusen associated with the pachychoroid disease spectrum. Pachydrusen are yellowish white sub-RPE deposits typically sparing the macula centre, with a wider distribution in the peri-papillary area and the posterior pole. They are described as having well-defined margins with a more complex irregular outer contour and tend to occur in isolation or in groups of few. Spaide et al. have described pachydrusen in patients with non-exudative AMD while Lee et al. report presence of pachydrusen in a patient with PCV (Spaide, 2018a, 2018b; Chung et al., 2018). Corresponding to the location of pachydrusen, SD-OCT shows the presence of sub-RPE homogenous hyperreflective material with RPE disturbances in the form of bumps, elevations and irregularities. On FAF, the pachydrusen hyperautofluoresce, whereas staining is observed on ICGA and FFA in areas of pachydrusen.

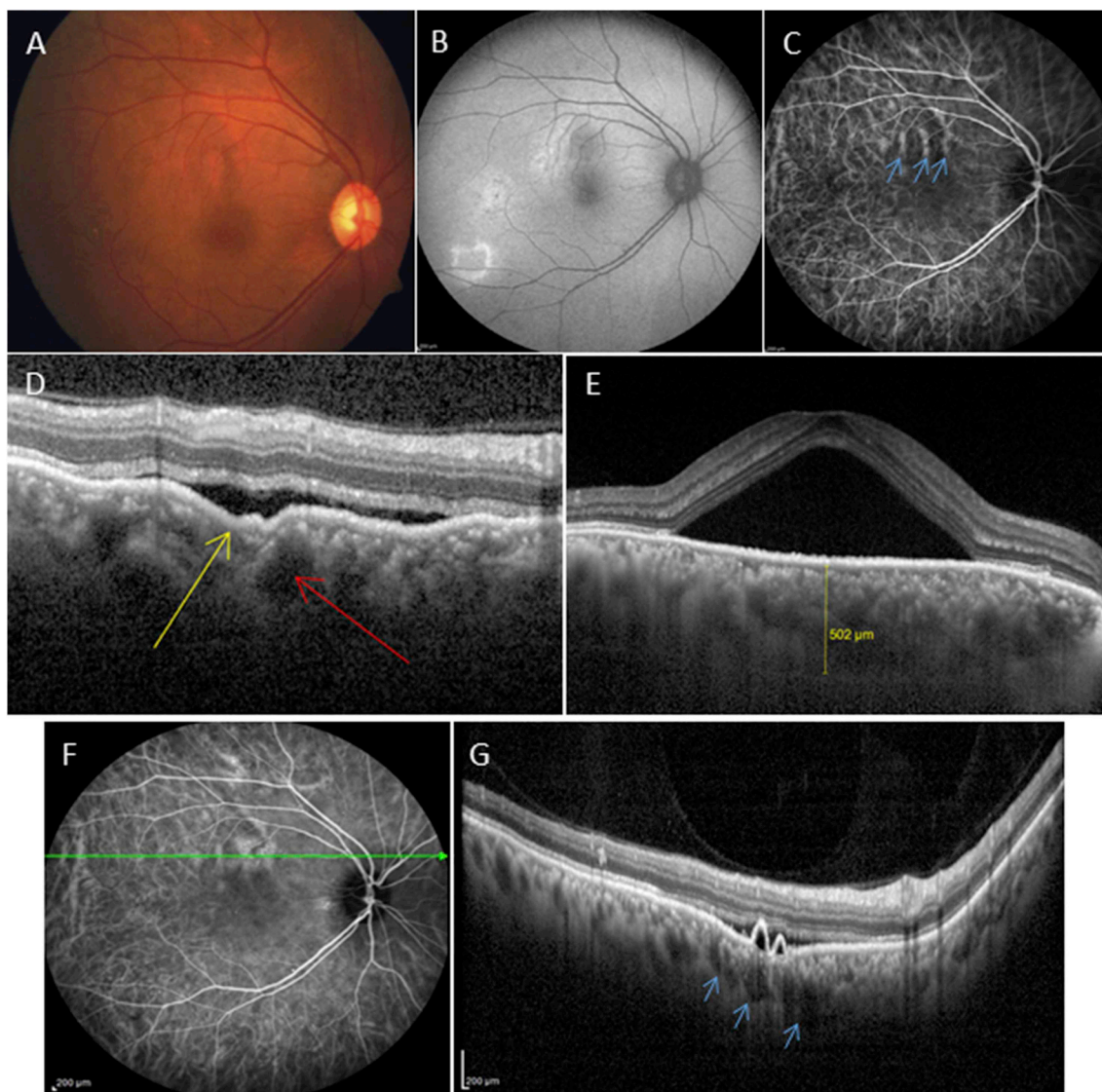


Fig. 13. Focal choroidal excavation (FCE). **A** Colour fundus photo showing reduced background tessellation. **B** Fundus autofluorescence shows multiple extrafoveal areas of hyperautofluorescence and another area of hypoautofluorescence superior to the macula along the superotemporal arcade. **C** Indocyanine green angiography (ICGA) shows dilated choroidal vessels in the same location (*blue arrows*). **D** Spectral domain optical coherence tomography (SD-OCT) scan showing formation of FCE (*yellow arrow*) with an adjacent pachyvessel (*red arrow*). **E** Foveal scan showing serous macular detachment with increased subfoveal choroidal thickness. **F&G** ICGA + widefield OCT scan shows another FCE in the same eye with pigment epithelial detachment and underlying pachyvessels corresponding to the dilated choroidal veins seen along the superotemporal arcade (*blue arrows*).

7. Treatment

The treatment of CSC has long been a subject of controversy, and it still is. However, the recent first large multicentre randomised controlled treatment trials such as the PLACE and VICI trials have significantly added to a more evidence-based treatment of CSC (van Dijk et al., 2018a; Lotery et al., 2020; van Rijssen et al., 2019). A myriad of treatments have been described thus far, while there is still no consensus regarding the classification of CSC and preferred treatment (Mehta et al., 2017; Singh et al., 2019). Also, most treatment studies have thus far had a retrospective design, using different inclusion and exclusion criteria, and variable clinical endpoints for treatment success. Retrospective study designs are especially problematic in CSC: acute and even cCSC cases tend to show spontaneous decrease and resolution of SRF (Lotery et al., 2020). This has resulted in numerous scientifically flawed claims of treatment efficacy in retrospective studies on CSC: one could test any intervention retrospectively and claim improvement (van Rijssen et al. 2019, 2020). Large prospective, randomised, controlled

trials are especially important in CSC, because of the relatively high chance of spontaneous resolution, which can be mistaken for treatment success in small, retrospective studies.

Treatment of acute CSC differs to that of cCSC. Acute CSC classically affects middle-aged working, male individuals, whose working ability may be compromised by the associated visual burden. Because serous retinal detachments resolve spontaneously within six months in most acute CSC episodes, observation without treatment is generally recommended as initial management. For cases with persistent serous retinal detachment or severe vision loss, several treatment options are available. Photocoagulation of extramacular leaking points by direct argon laser can reduce the duration of single episodes (Muller et al., 2018; Chhablani et al., 2014). Half-dose or half-fluence verteporfin PDT may contribute to shortening the episode duration (van Rijssen et al., 2019). However, the ideal timing for these different interventions still remains to be determined. Older age, a higher subfoveal choroidal thickness and a higher degree of RPE alteration at leakage sites were found to be independent factors for longer acute CSC episodes (Darwich

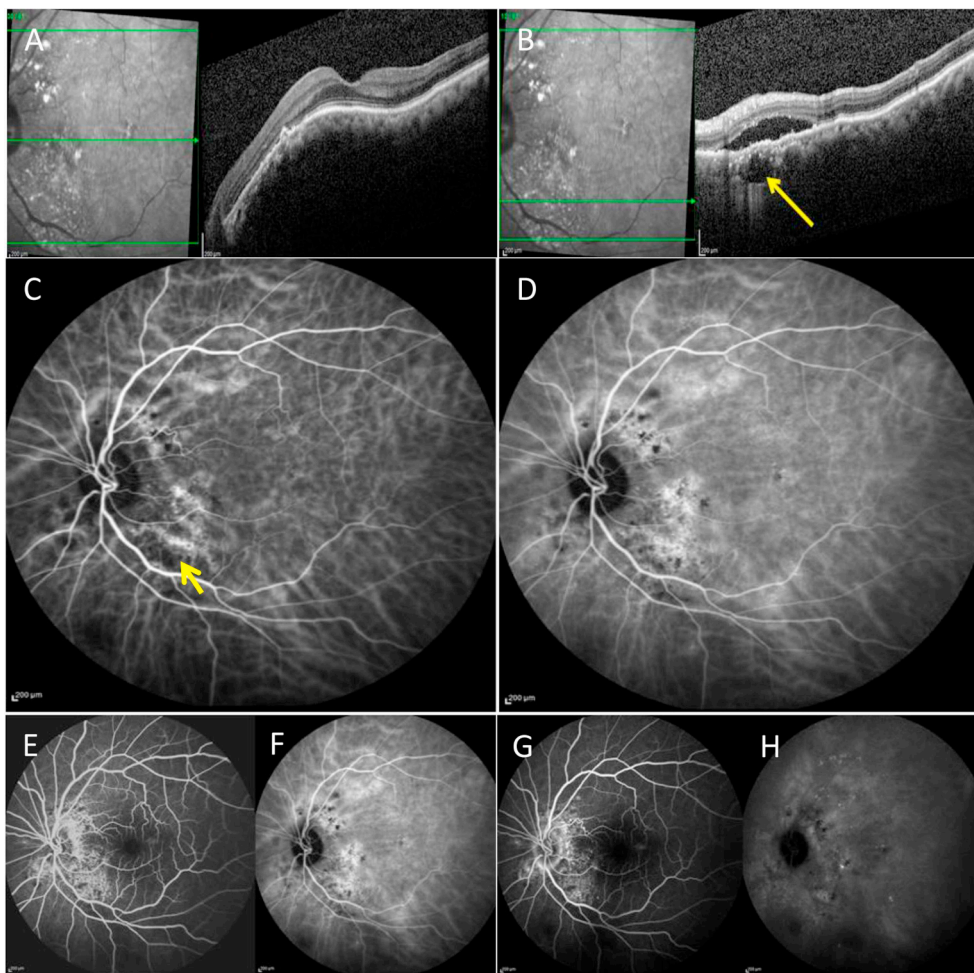


Fig. 14. Peripapillary pachychoroid syndrome (PPS). A&B Spectral domain optical coherence tomography (SD-OCT) image showing presence of peripapillary subretinal fluid with underlying pachyvessel (yellow arrow). The subfoveal choroid lacks pachyvessels. C&D Indocyanine green angiography (ICGA) images in the early and late phase of the angiogram showing dilated vessels in the peripapillary area corresponding to the pachyvessel on OCT. The late phase shows peripapillary hyperfluorescence with patchy areas of hypofluorescence. E-H Simultaneous fundus fluorescein angiography shows stippled hyperfluorescence in the peripapillary area.

et al., 2017b). Specifically, subfoveal choroidal thickness $\geq 500 \mu\text{m}$, RPE elevation $\geq 50 \mu\text{m}$ at leakage sites and age ≥ 40 years. Increasing our understanding of those factors influencing the duration of episodes will allow improved detection and therefore earlier treatment for cases at risk of persistence. Treatment in a timely manner is crucial to prevent the development of photoreceptor and RPE damage because of long-lasting subretinal detachment.

Several treatment options exist for cCSC, similarly to those stated above they include half-dose PDT, argon laser and the possibility of oral MR antagonists. Anti-VEGF agents have also been shown to successfully reduce SRF in a handful of cases, especially when MNV complicates CSC. Presently there is no treatment gold standard. Half-dose PDT was found to be superior to high-density subthreshold micropulse laser treatment in patients with cCSC in the Prospective Randomised Control Treatment Trial for Chronic Central Serous Chorioretinopathy (PLACE trial), a large prospective multicentre randomised controlled trial on the treatment of cCSC (van Dijk et al., 2018a). A subset of patients diagnosed with CSC have been shown to respond to anti-VEGF intravitreal medications (Seong et al., 2009). However, given the often short-lived nature of this disease the numbers in these anti-VEGF studies are small and limited to case reports as no randomised controlled trials have been performed. The success of some of the anti-VEGF studies prior to the era of OCTA may also be due to the inclusion of patients with cCSC complicated by subtle MNV that nowadays may be better detected on OCTA. A more recent evaluation of the use of anti-VEGF in patients with MNV complicating cCSC included patients with MNV diagnosed using multimodal imaging including OCTA (Romdhane et al., 2019). Interestingly they found 45% of patients treated with anti-VEGF to have complete resorption of SRF, whereas 55% had an

incomplete or no response. Furthermore, no improvement in VA was noted. The authors concluded that for those patients with MNV complicating cCSC it is difficult to determine the degree to which the exudation is attributable to the neovascular process or to the underlying cCSC condition.

Other treatment options have been reported in CSC including aspirin, carbonic anhydrase inhibitors, rifampicin, methotrexate, non-steroidal anti-inflammatory medications, finasteride, antioxidants, beta-blockers, ketoconazole, melatonin and *H. pylori* eradication (Caccavale et al., 2010) (Browning, 1993) (Pikkel et al., 2002) (Forooghian et al., 2011) (Rahbani-Nobar et al., 2011; Meyerle et al., 2007; Pandi-Perumal et al., 2008; Abrishami et al., 2015; Alkin et al., 2013; Shulman et al., 2016). The majority of these treatments were evaluated in small, retrospective studies therefore the quality of such evidence is mainly poor. All retrospective studies in CSC should be interpreted with caution given the often self-resolving nature of the disease. For more details and an extensive critical appraisal of the aforementioned treatments see the review “Central serous chorioretinopathy: towards an evidence-based treatment guideline” in this journal (van Rijssen et al., 2019).

7.1. Prospective randomised controlled trials

The clinical efficacy and mechanistic evaluation of eplerenone for Central serous chorio-retinopathy – the VICI trial.

There have been multiple case reports, case series and small randomised controlled trials conducted showing the benefit of the MR antagonist eplerenone in CSC (Schwartz et al., 2017; Rahimy et al., 2018; Zucchiatti et al., 2018). Recently our group in collaboration with

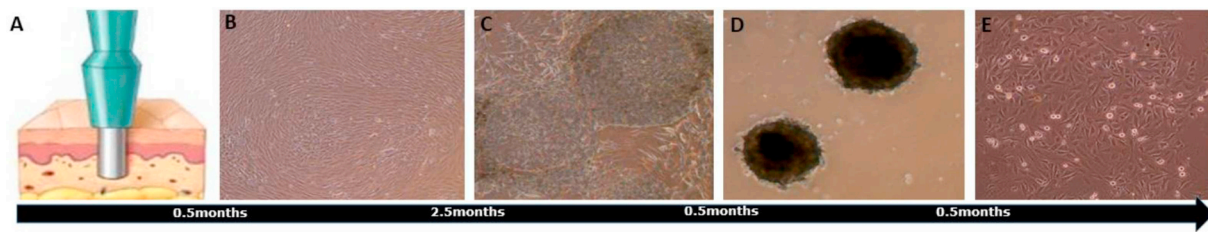


Fig. 15. Development of human induced pluripotent stem cell (hiPSC) patient-derived choroidal endothelial cells (CECs). A Skin punch biopsy. B Fibroblasts. C hiPSCs. D Embryoid bodies. E CECs.

others conducted a large randomised placebo controlled double-blinded trial in the UK, the VICI trial, to assess the efficacy of eplerenone in cCSC (Lotery et al., 2020). As mentioned previously, the VICI trial showed that eplerenone was not superior to placebo for the treatment of cCSC. This result was surprising given the multitude of literature suggesting the MR to be implicated in disease. Furthermore, there was not even a significant reduction in choroidal thickness over 12 months in the placebo nor eplerenone arms (baseline thickness; 460.5 μm and 447.0 μm , respectively), (thickness at 12 months; 444.0 μm , and 495.5 μm , respectively). The fellow eye choroidal thickness was evaluated in The VICI trial and the median found to be $> 395 \mu\text{m}$ in both the placebo and eplerenone groups at 12 months (466.0 μm and 475.0 μm , respectively); in keeping with aforementioned studies where there is increased choroidal thickness in both eyes of patients with CSC.

The VICI trial has further elaborated on the natural history of the disease. With regard to resolution of SRF in the study eye this was very similar at 3 months in both the placebo and eplerenone groups (complete resolution 11% and partial resolution 22%; complete resolution 10% and partial resolution 29%, respectively). At 12 months resolution of SRF in the study eye was again fairly similar across the placebo and eplerenone groups (complete resolution 30% and partial resolution 24%; complete resolution 16% and partial resolution 27%, respectively). This data across the placebo group is in itself very insightful; 30% of patients had complete resolution of SRF after 12 months without treatment. This data reminds clinicians of the nature of this disease with regard to spontaneous SRF resolution, and to be wary of attributing OCT changes with responses to treatment.

The VICI trial used VA as a primary outcome in contrast to other trials, which used structural outcomes such as reduction in SRF. This result is important for many reasons, not only that eplerenone is non-superior to placebo, but also that VA (or low luminance VA, which was a secondary outcome) may not be an optimal outcome measures in CSC studies. Should other functional outcomes be used instead as primary clinical endpoints, or should structural outcomes be used in CSC studies?

Regulators and patients are most interested in functional outcomes so structural outcomes should only be used if they can be confirmed as a suitable and reliable biomarker for a future functional outcome e. g if SRF completely resolves this means that visual function will be

improved. An analogous biomarker would be blood pressure where there is strong epidemiological data that hypertension is a reliable predictor of risk of stroke. Unfortunately, we do not have such robust confirmation for SRF and VA outcomes. Therefore, future studies may consider alternative functional outcomes such as microperimetry.

The Study on half-dose Photodynamic therapy versus Eplerenone in chronic CenTRAL serous chorioretinopathy - the SPECTRA trial.

The Study on half-dose Photodynamic therapy versus Eplerenone in chronic CenTRAL serous chorioretinopathy (SPECTRA trial) is the first prospective, multicentre, randomised controlled trial that compares half-dose PDT with eplerenone treatment with the aim of comparing their ability to achieve complete resolution of SRF, and improve quality of vision <https://clinicaltrials.gov/ct2/show/NCT03079141>. The SPECTRA trial follows on from the PLACE trial (van Dijk et al., 2018a). The primary endpoint of the SPECTRA trial is to assess if there is a difference between half-dose PDT and eplerenone treatment in patients with cCSC, in terms of both complete resolution of SRF on OCT and safety. The outcome of this study should help improve evidence-based treatment in CSC by directing clinicians to an appropriate therapy.

Following the results of the VICI trial, it would be prudent for a comparison of half-dose PDT to placebo.

8. Future directions

The debate as to whether CSC is a disease of the RPE/choroid/both is still unresolved. Neither tissue can be biopsied from CSC patients, thereby hindering our progress into research of the disease. Over the last decade the field of stem cell biology has developed exponentially. Several groups, including our own have successfully generated both choroidal and RPE cells *in vitro* from human induced pluripotent stem cells (hiPSCs) (Songstad et al., 2017). hiPSCs are pluripotent cells derived from adult cells such as fibroblasts and keratinocytes. The use of hiPSCs effectively allows any cell type to be created *in vitro* from a specific donor. For the field of ophthalmology, in particular retinal research, this new technology was a critical turning point, allowing us to overcome our lack of access to primary tissue.

Choroidal endothelial cells (CECs) are thought to be involved in the pathogenesis of CSC, consequently we aimed to produce CECs from cCSC donors. We have successfully differentiated hiPSCs from patients

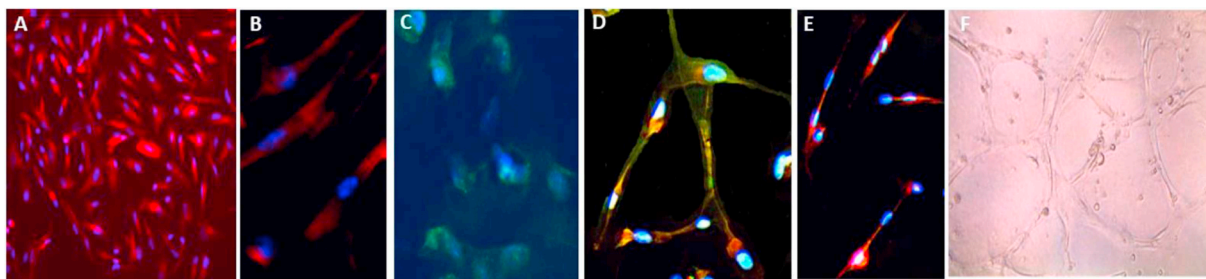


Fig. 16. Characterising human induced pluripotent stem cell (hiPSC) patient-derived choroidal endothelial cells (CECs). A-E Immunocytochemistry nuclear DAPI stain blue. A&B CEC specific marker Carbonic Anhydrase 4 (CA4) red (x10) (x20). C Endothelial marker CD34 green. D&E Dual staining CA4 red, endothelial cell marker CD31 green. F. Form tube-like structures on matrigel.

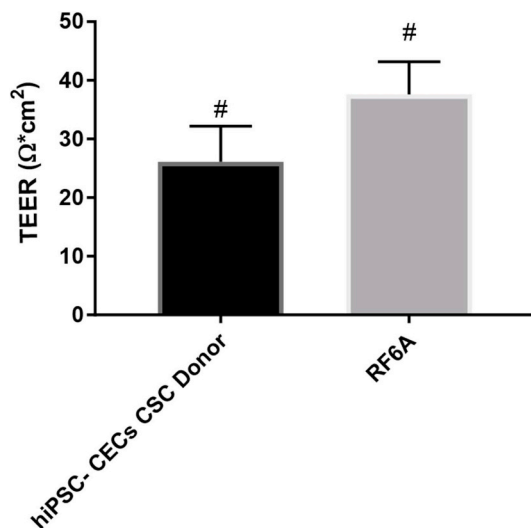


Fig. 17. Human induced pluripotent stem cell (hiPSC) patient-derived choroidal endothelial cells (CECs) trans-endothelial resistance (TEER). hiPSC-derived CECs display endothelial barrier function. Trans-endothelial electrical resistance (TEER) determined as a measure of barrier function. No significant difference in TEER compared to primate choroidal endothelial cell line RF6A. Significantly increased TEER compared to empty control wells (# $P < 0.001$).

with cCSC into CECs *in vitro* (Figs. 15 and 16) to compile preliminary data. Differentiation to CECs was performed for three hiPSC clones from one patient. We used the differentiation protocol described by Songstad et al. 2015, 2017; Fig. 15 illustrates the differentiation process. In short, fibroblasts were cultured and reprogrammed to pluripotency using replication incompetent Sendai virus to induce expression of pluripotency markers (Malik and Rao, 2013). Embryoid bodies (EBs) were formed from hiPSCs and grown in co-culture with the primate choroidal endothelial cell line, RF6A (Songstad et al. 2015, 2017). After 2 weeks cells differentiated into CECs and were sorted for the endothelial cell surface marker CD144. Cells display CEC surface markers and form characteristic tube-like structures when plated on matrigel (Songstad et al., 2015) (Fig. 16). All cells were cultured in steroid free media. The trans-endothelial electrical resistance (TEER) of hiPSC derived CECs was significantly increased relative to empty control wells (Fig. 17). Furthermore, the TEER of hiPSC-derived CECs from CSC patients was not statistically different from the primate CEC line RF6A. TEER is a method of measuring the tightness of a cellular barrier, and it seems CECs derived from CSC patients display normal TEER.

This work is still in the preliminary stage and a comparison to primate choroidal endothelial cells is not ideal, however it does show that seemingly normal CECs can be produced from CSC donors. Future work will compare hiPSC-derived CECs from patients with cCSC to hiPSC-derived CECs from control subjects. The use of pluripotent stem cells to produce choroidal cells from CSC donors is a foundation upon which a new avenue of research into CSC pathophysiology can launch.

9. Conclusions

CSC is likely a choroidal disease with chronicity and complications occurring due to increased involvement of the RPE. Although one of the most common retinal conditions, the exact pathogenesis of this disease still eludes us. Improved patient phenotyping and more succinct disease classification may reveal trends in both prognosis and treatment response. Over the last decade, treatment options for CSC have evolved to include the use of half-dose or half-fluence PDT, and mineralocorticoid antagonists, but the results of recent large multicentre randomised controlled trials, such as the VICI and PLACE trial, have altered our perspectives on the proper role of these therapies. The aetiology of the

disease should be made clearer by further cell biology studies, such as those described for the first time here. In this review, we summarise the advances made in CSC pathophysiology, including a new avenue of research involving stem cells from CSC patients. Furthermore, we surmise that CSC is part of the pachychoroid disease spectrum.

Funders

The Gift of Sight Charity Appeal. The research was supported by the NIHR Biomedical Research Centre at Moorfields Eye Hospital NHS Foundation Trust and UCL Institute of Ophthalmology. Grant support for AL was provided by a NIHR senior investigator award. SS and SC are funded by the GCRF UKRI (MR/P207881/1).

CRediT authorship contribution statement

Rebecca Kaye: Conceptualization, Data curation, Formal analysis, Investigation, Methodology, Visualization, Writing - original draft, Writing - review & editing. **Shruti Chandra:** Data curation, Writing - original draft. **Jay Sheth:** Data curation, Writing - original draft. **Camiel J.F. Boon:** Supervision, Writing - review & editing. **Sobha Sivaprasad:** Supervision, Writing - review & editing. **Andrew Lotery:** Conceptualization, Methodology, Supervision, Writing - review & editing.

Acknowledgements

This work was supported by The Gift of Sight Charity Appeal at the University of Southampton and by the NIHR Biomedical Research Centre at Moorfields Eye Hospital NHS Foundation Trust and UCL Institute of Ophthalmology.

References

- Abalem, M.F., Machado, M.C., Santos, H.N., Garcia, R., Helal Jr., J., Carricondo, P.C., Pimentel, S.L., Monteiro, M.L., Qian, C.X., Bronstein, M.D., Fragoso, M.C., 2016. Choroidal and retinal abnormalities by optical coherence tomography in endogenous cushing's syndrome. *Front. Endocrinol.* 7, 154.
- Abalos, E., Cuesta, C., Grosso, A.L., Chou, D., Say, L., 2013. Global and regional estimates of preeclampsia and eclampsia: a systematic review. *Eur. J. Obstet. Gynecol. Reprod. Biol.* 170 (1), 1–7.
- Abrishami, M., Mousavi, M., Hosseini, S.M., Norouzzpour, A., 2015. Treatment of chronic central serous chorioretinopathy with oral methotrexate. *J. Ocul. Pharmacol. Therapeut.* 31 (8), 468–475.
- Aggarwal, K., Agarwal, A., Deokar, A., Mahajan, S., Singh, R., Bansal, R., Sharma, A., Dogra, M.R., Gupta, V., Group, O.S., 2017. Distinguishing features of acute Vogt-Koyanagi-Harada disease and acute central serous chorioretinopathy on optical coherence tomography angiography and en face optical coherence tomography imaging. *J. Ophthalmic Inflamm Infect* 7 (1), 3.
- Ahad, M.A., Chua, C.N., Evans, N.M., 2005. Central serous chorioretinopathy associated with testosterone therapy. *Eye* 20, 503.
- Alkin, Z., Osmanbasoglu, O.A., Ozkaya, A., Karatas, G., Yazici, A.T., 2013. Topical nepafenac in treatment of acute central serous chorioretinopathy. *Med. Hypothesis, Discov. Innovation (MEHDI) Ophthalmol.* 2 (4), 96–101.
- Alm, A., Bill, A., 1972. The oxygen supply to the retina. II. Effects of high intraocular pressure and of increased arterial carbon dioxide tension on uveal and retinal blood flow in cats. A study with radioactively labelled microspheres including flow determinations in brain and some other tissues. *Acta Physiol. Scand.* 84 (3), 306–319.
- Alshahrani, S.T., Al Shamsi, H.N., Kahtani, E.S., Ghazi, N.G., 2014. Spectral-domain optical coherence tomography findings in polypoidal choroidal vasculopathy suggest a type 1 neovascular growth pattern. *Clin. Ophthalmol.* 8, 1689–1695.
- American College of, O., Gynecologists, Task Force on Hypertension in, P., 2013. Hypertension in pregnancy. Report of the American College of obstetricians and gynecologists' task force on hypertension in pregnancy. *Obstet. Gynecol.* 122 (5), 1122–1131.
- Anantharaman, G., Sheth, J., Bhende, M., Narayanan, R., Natarajan, S., Rajendran, A., Manayath, G., Sen, P., Biswas, R., Banker, A., Gupta, C., 2018. Polypoidal choroidal vasculopathy: pearls in diagnosis and management. *Indian J. Ophthalmol.* 66 (7), 896–908.
- Asensio-Sanchez, V.M., Rodriguez-Delgado, B., Garcia-Herrero, E., Cabo-Vaquera, V., Garcia-Loygorri, C., 2008. [Central serous chorioretinopathy as an extradiagnostic manifestation of Helicobacter pylori gastric infection]. *Arch. Soc. Esp. Oftalmol.* 83 (3), 177–182.
- Baker, P.S., Garg, S.J., Fineman, M.S., Chiang, A., Alshareef, R.A., Belmont, J., Brown, G.C., 2013. Serous macular detachment in Waldenström macroglobulinemia: a report

- of four cases. *Am. J. Ophthalmol.* 155 (3), 448–455.
- Balaratnasingam, C., Freund, K.B., Tan, A.M., Mrejen, S., Hunyor, A.P., Keegan, D.J., Dansingani, K.K., Dayani, P.N., Barbazetto, I.A., Sarraf, D., Jampol, L.M., Yannuzzi, L.A., 2016. Bullous variant of central serous chorioretinopathy: expansion of phenotypic features using multimethod imaging. *Ophthalmology* 123 (7), 1541–1552.
- Benfica, C.Z., Zanella, T., Farias, L.B., Oppermann, M.L.R., Canani, L.H.S., Lavinsky, D., 2018. Comparative analysis of choroidal thickness in third trimester pregnant women. *Int J Retina Vitreous* 4, 6.
- Bernasconi, P., Messmer, E., Bernasconi, A., Tholen, A., 1998. Assessment of the sympatho-vagal interaction in central serous chorioretinopathy measured by power spectral analysis of heart rate variability. *Graefes Arch. Clin. Exp. Ophthalmol.* 236 (8), 571–576.
- Birnbaum, A.D., Blair, M.P., Tessler, H.H., Goldstein, D.A., 2010. Subretinal fluid in acute posterior multifocal placoid pigment epitheliopathy. *Retina-the Journal of Retinal and Vitreous Diseases* 30 (5), 810–814.
- Boon, C.J., Klevering, B.J., Leroy, B.P., Hoyng, C.B., Keunen, J.E., den Hollander, A.I., 2009. The spectrum of ocular phenotypes caused by mutations in the BEST1 gene. *Prog. Retin. Eye Res.* 28 (3), 187–205.
- Bouzas, E.A., Karadimas, P., Pournaras, C.J., 2002. Central serous chorioretinopathy and glucocorticoids. *Surv. Ophthalmol.* 47 (5), 431–448.
- Breukink, M.B., Dingemans, A.J., den Hollander, A.I., Keunen, J.E., MacLaren, R.E., Fauser, S., Querques, G., Hoyng, C.B., Downes, S.M., Boon, C.J., 2017. Chronic central serous chorioretinopathy: long-term follow-up and vision-related quality of life. *Clin. Ophthalmol.* 11, 39–46.
- Brinks, J., van Dijk, E.H.C., Habeeb, M., Nikolaou, A., Tsonaka, R., Peters, H.A.B., Sips, H.C.M., van der Merbel, A.F., de Jong, E.K., Notenboom, R.G.E., Kielbasa, S.M., van der Maarel, S.M., Quax, P.H.A., Meijer, O.C., Boon, C.J.F., 2018. The effect of corticosteroids on human choroidal endothelial cells: a model to study central serous chorioretinopathy. *Invest. Ophthalmol. Vis. Sci.* 59 (13), 5682–5692.
- Brodie, F.L., Charlson, E.S., Aleman, T.S., Salvo, R.T., Gewaily, D.Y., Lau, M.K., Farren, N.D., Engelhard, S.B., Pistilli, M., Brucker, A.J., 2015. Obstructive sleep apnea and central serous chorioretinopathy. *Retina-the Journal of Retinal and Vitreous Diseases* 35 (2), 238–243.
- Browning, D.J., 1993. Nadolol in the treatment of central serous retinopathy. *Am. J. Ophthalmol.* 116 (6), 770–771.
- Buelens, T., Dewachter, A., 2015. Bilateral central serous chorioretinopathy associated with endogenous Cushing's syndrome. *J. Fr. Ophthalmol.* 38 (4), e73–75.
- Caccavale, A., Romanazzi, F., Imparato, M., Negri, A., Morano, A., Ferentini, F., 2010. Low-dose aspirin as treatment for central serous chorioretinopathy. *Clin. Ophthalmol.* 4, 899–903.
- Caillaux, V., Gaucher, D., Gualino, V., Massin, P., Tadayoni, R., Gaudric, A., 2013. Morphologic characterization of dome-shaped macula in myopic eyes with serous macular detachment. *Am. J. Ophthalmol.* 156 (5), 958–967 e951.
- Canonica, J., Mehanna, C., Bonnard, B., Jonet, L., Gelize, E., Jais, J.P., Jaisser, F., Zhao, M., Behar-Cohen, F., 2019. Effect of acute and chronic aldosterone exposure on the retinal pigment epithelium-choroid complex in rodents. *Exp. Eye Res.* 187, 107747.
- Casella, A.M., Berbel, R.F., Bressanim, G.L., Malaguido, M.R., Cardillo, J.A., 2012. *Helicobacter pylori* as a potential target for the treatment of central serous chorioretinopathy. *Clinics* 67 (9), 1047–1052.
- Castro-Correia, J., Coutinho, M.F., Rosas, V., Maia, J., 1992. Long-term follow-up of central serous retinopathy in 150 patients. *Doc. Ophthalmol.* 81 (4), 379–386.
- Cebeci, Z., Oray, M., Bayraktar, S., Tugal-Tutkun, I., Kir, N., 2017. Atypical central serous chorioretinopathy. *Turk J Ophthalmol* 47 (4), 238–242.
- Chang, Y.S., Weng, S.F., Chang, C., Wang, J.J., Wang, J.Y., Jan, R.L., 2015. Associations between topical ophthalmic corticosteroids and central serous chorioretinopathy: a Taiwanese population-based study. *Invest. Ophthalmol. Vis. Sci.* 56 (6), 4083–4089.
- Chatziralli, I., Kabanarou, S.A., Parikakis, E., Chatzirallis, A., Xirou, T., Mitropoulos, P., 2017. Risk factors for central serous chorioretinopathy: multivariate approach in a case-control study. *Curr. Eye Res.* 42 (7), 1069–1073.
- Chen, S.N., Lian, I.B., 2014. Increased risk of coronary heart disease in male patients with central serous chorioretinopathy: results of a population-based cohort study. *Br. J. Ophthalmol.* 98 (7) 997–997.
- Chen, G., Tzekov, R., Li, W., Jiang, F., Mao, S., Tong, Y., 2017. Subfoveal choroidal thickness in central serous chorioretinopathy: a meta-analysis. *PLoS One* 12 (1), e0169152.
- Cheng, Y., Tian, H., 2017. Current development status of MEK inhibitors. *Molecules* 22 (10), 1551.
- Cheung, C.M.G., Lee, W.K., Koizumi, H., Dansingani, K., Lai, T.Y.Y., Freund, K.B., 2018. Pachychoroid disease. *Eye*.
- Chhablani, J., Mandadi, S.K.R., 2019. Commentary: double-layer sign" on spectral domain optical coherence tomography in pachychoroid spectrum disease. *Indian J. Ophthalmol.* 67 (1), 171.
- Chhablani, J., Rani, P.K., Mathai, A., Jalali, S., Kozak, I., 2014. Navigated focal laser photocoagulation for central serous chorioretinopathy. *Clin. Ophthalmol.* 8, 1543–1547.
- Chung, H., Byeon, S.H., Freund, K.B., 2017. Focal choroidal excavation and its association with pachychoroid spectrum disorders: a review of the literature and multimodal imaging findings. *Retina* 37 (2), 199–221.
- Chung, Y.R., Kim, J.W., Choi, S.Y., Park, S.W., Kim, J.H., Lee, K., 2018. Subfoveal choroidal thickness and vascular diameter in active and resolved central serous chorioretinopathy. *Retina* 38 (1), 102–107.
- Ciloglu, E., Unal, F., Dogan, N.C., 2018. The relationship between the central serous chorioretinopathy, choroidal thickness, and serum hormone levels. *Graefes Arch. Clin. Exp. Ophthalmol.* 256 (6), 1111–1116.
- Clarke, C., Smith, S.V., Lee, A.G., 2017. A rare association: Cushing disease and central serous chorioretinopathy. *Can. J. Ophthalmol.* 52 (2), e77–e79.
- Costanzo, E., Cohen, S.Y., Miere, A., Querques, G., Capuano, V., Semoun, O., El Ameen, A., Oubraham, H., Souied, E.H., 2015. Optical coherence tomography angiography in central serous chorioretinopathy. *J. Ophthalmol.* 134783 2015.
- Coutu, A., Farguet, F., Jeannin, G., Chiambaretta, F., 2016. [Multifocal serous chorioretinopathy secondary to the use of MEK inhibitors: illustration and example of management through two case reports]. *J. Fr. Ophthalmol.* 39 (1), 55–63.
- Damar, E., Toklu, Y., Tuncel, A., Balci, M., Aslan, Y., Simsek, S., Atan, A., 2013. Does therapeutic dose of sildenafil citrate treatment lead to central serous chorioretinopathy in patients with erectile dysfunction? *Am. J. Men's Health* 7 (5), 439–443.
- Dang, Y., Mu, Y., Zhao, M., Li, L., Guo, Y., Zhu, Y., 2013. The effect of eradicating *Helicobacter pylori* on idiopathic central serous chorioretinopathy patients. *Therapeut. Clin. Risk Manag.* 9, 355–360.
- Dansingani, K.K., Balaratnasingam, C., Naysan, J., Freund, K.B., 2016a. En face imaging of pachychoroid spectrum disorders with swept-source optical coherence tomography. *Retina* 36 (3), 499–516.
- Dansingani, K.K., Perlee, L.T., Hamon, S., Lee, M., Shah, V.P., Spaide, R.F., Sorenson, J., Klancnik Jr., J.M., Yannuzzi, L.A., Barbazetto, I.A., Barbazetto, M.J., Engelbert, M., Chen, C., Hewitt, A.W., Freund, K.B., 2016b. Risk alleles associated with neovascularization in a pachychoroid phenotype. *Ophthalmology* 123 (12), 2628–2630.
- Dansingani, K.K., Gal-Or, O., Sada, S.R., Yannuzzi, L.A., Freund, K.B., 2018. Understanding aneurysmal type 1 neovascularization (polypoidal choroidal vasculopathy): a lesson in the taxonomy of 'expanded spectra' - a review. *Clin. Exp. Ophthalmol.* 46 (2), 189–200.
- Daruich, A., Matet, A., Dirani, A., Bousquet, E., Zhao, M., Farman, N., Jaisser, F., Behar-Cohen, F., 2015. Central serous chorioretinopathy: recent findings and new pathophysiology hypothesis. *Prog. Retin. Eye Res.* 48, 82–118.
- Daruich, A., Matet, A., Dirani, A., Gallice, M., Nicholson, L., Sivaprasad, S., Behar-Cohen, F., 2016. Oral mineralocorticoid-receptor antagonists: real-life experience in clinical subtypes of nonresolving central serous chorioretinopathy with chronic epitheliopathy. *Transl Vis Sci Technol* 5 (2), 2.
- Daruich, A., Matet, A., Behar-Cohen, F., 2017a. Central serous chorioretinopathy. *Dev. Ophthalmol.* 58, 27–38.
- Daruich, A., Matet, A., Marchionno, L., De Azevedo, J.D., Ambresin, A., Mantel, I., Behar-Cohen, F., 2017b. Acute central serous chorioretinopathy: factors influencing episode duration. *Retina* 37 (10), 1905–1915.
- De Bats, F., Cornut, P.L., Wolff, B., Kodjikian, L., Mauget-Faysses, M., 2018. Dark and white lesions observed in central serous chorioretinopathy on optical coherence tomography angiography. *Eur. J. Ophthalmol.* 28 (4), 446–453.
- de Jong, E.K., Breukink, M.B., Schellevis, R.L., Bakker, B., Mohr, J.K., Fauser, S., Keunen, J.E., Hoyng, C.B., den Hollander, A.I., Boon, C.J., 2015. Chronic central serous chorioretinopathy is associated with genetic variants implicated in age-related macular degeneration. *Ophthalmology* 122 (3), 562–570.
- De Salvo, G., Vaz-Pereira, S., Keane, P.A., Tufail, A., Liew, G., 2014. Sensitivity and specificity of spectral-domain optical coherence tomography in detecting idiopathic polypoidal choroidal vasculopathy. *Am. J. Ophthalmol.* 158 (6), 1228–1238 e1221.
- Deutman, A.F., 1969. Electro-oculography in families with vitelliform dystrophy of the fovea. Detection of the carrier state. *Arch. Ophthalmol.* 81 (3), 305–316.
- Eom, Y., Oh, J., Kim, S.W., Huh, K., 2012. Systemic factors associated with central serous chorioretinopathy in Koreans. *Kor. J. Ophthalmol.* 26 (4), 260–264.
- Ersöz, M.G., Arf, S., Hocaoglu, M., Sayman Muslubas, I., Karacorlu, M., 2019. Patient characteristics and risk factors for central serous chorioretinopathy: an analysis of 811 patients. *Br. J. Ophthalmol.* 103, 725–729.
- Ersöz, M.G., Karacorlu, M., Arf, S., Hocaoglu, M., Sayman Muslubas, I., 2018b. Outer nuclear layer thinning in pachychoroid pigment epitheliopathy. *Retina* 38 (5), 957–961.
- Fackler, T.K., Bearably, S., Odom, T., Fekrat, S., Cooney, M.J., 2006. Acute lymphoblastic leukemia presenting as bilateral serous macular detachments. *Retina* 26 (6), 710–712.
- Ferrara, D., Mohler, K.J., Waheed, N., Adhi, M., Liu, J.J., Grulkowski, I., Kraus, M.F., Bauman, C., Hornegger, J., Fujimoto, J.G., Duker, J.S., 2014. En face enhanced-depth swept-source optical coherence tomography features of chronic central serous chorioretinopathy. *Ophthalmology* 121 (3), 719–726.
- Ficker, L., Vafidis, G., While, A., Leaver, P., 1988. Long-term follow-up of a prospective trial of argon laser photocoagulation in the treatment of central serous retinopathy. *Br. J. Ophthalmol.* 72 (11), 829–834.
- Bonini Filho, M.A., de Carlo, T.E., Ferrara, D., Adhi, M., Bauman, C.R., Witkin, A.J., Reichel, E., Duker, J.S., Waheed, N.K., 2015. Association of choroidal neovascularization and central serous chorioretinopathy with optical coherence tomography angiography. *JAMA Ophthalmol* 133 (8), 899–906.
- Fok, A.C., Chan, P.P., Lam, D.S., Lai, T.Y., 2011. Risk factors for recurrence of serous macular detachment in untreated patients with central serous chorioretinopathy. *Ophthalmol Res.* 46 (3), 160–163.
- Forooghian, F., Meleth, A.D., Cukras, C., Chew, E.Y., Wong, W.T., Meyerle, C.B., 2011. Finasteride for chronic central serous chorioretinopathy. *Retina* 31 (4), 766–771.
- Francis, J.H., Habib, L.A., Abramson, D.H., Yannuzzi, L.A., Heinemann, M., Gouder, M.M., Grisham, R.N., Postow, M.A., Shoushtari, A.N., Chi, P., Segal, N.H., Yaeger, R., Ho, A.L., Chapman, P.B., Catalanotti, F., 2017. Clinical and morphologic characteristics of MEK inhibitor-associated retinopathy: differences from central serous chorioretinopathy. *Ophthalmology* 124 (12), 1788–1798.
- Fraunfelder, F.W., Fraunfelder, F.T., 2008. Central serous chorioretinopathy associated with sildenafil. *Retina* 28 (4), 606–609.
- French, D.D., Margo, C.E., 2010. Central serous chorioretinopathy and phosphodiesterase-5 inhibitors: a case-control postmarketing surveillance study. *Retina* 30 (2), 271–274.
- Fujimoto, H., Gomi, F., Wakabayashi, T., Sawa, M., Tsujikawa, M., Tano, Y., 2008. Morphologic changes in acute central serous chorioretinopathy evaluated by fourier-

- domain optical coherence tomography. *Ophthalmology* 115 (9), 1494–1500. doi:10.1016/j.ophtha.2007.07.012.
- Fujiwara, T., Imamura, Y., Margolis, R., Slakter, J.S., Spaide, R.F., 2009. Enhanced depth imaging optical coherence tomography of the choroid in highly myopic eyes. *Am. J. Ophthalmol.* 148 (3), 445–450.
- Fung, A.T., Yannuzzi, L.A., Freund, K.B., 2012. Type 1 (sub-retinal pigment epithelial) neovascularization in central serous chorioretinopathy masquerading as neovascular age-related macular degeneration. *Retina* 32 (9), 1829–1837.
- Furuta, M., Iida, T., Kishi, S., 2009. Foveal thickness can predict visual outcome in patients with persistent central serous chorioretinopathy. *Ophthalmologica* 223 (1), 28–31.
- Gass, J.D., 1967a. Pathogenesis of disciform detachment of the neuroepithelium. *Am. J. Ophthalmol.* 63 (3), 1–139 Suppl.
- Gass, J.D., 1967b. Pathogenesis of disciform detachment of the neuroepithelium: II. idiopathic central serous choroidopathy. *Am. J. Ophthalmol.* 63 (3), 587/515–615/543.
- Gilbert, C.M., Owens, S.L., Smith, P.D., Fine, S.L., 1984. Long-term follow-up of central serous chorioretinopathy. *Br. J. Ophthalmol.* 68 (11), 815–820.
- Girkin, C.A., McGwin Jr., G., Sinai, M.J., Sekhar, G.C., Fingeret, M., Wollstein, G., Varma, R., Greenfield, D., Liebmann, J., Araie, M., Tomita, G., Maeda, N., Garway-Heath, D.F., 2011. Variation in optic nerve and macular structure with age and race with spectral-domain optical coherence tomography. *Ophthalmology* 118 (12), 2403–2408.
- Giusti, C., 2004. Association of *Helicobacter pylori* with central serous chorioretinopathy: hypotheses regarding pathogenesis. *Med. Hypotheses* 63 (3), 524–527.
- Goldberg, R.A., Heier, J.S., 2018. Short-term oral mifepristone for the treatment of central serous chorioretinopathy (STOMP CSC) - a randomized, placebo-controlled study. *Invest. Ophthalmol. Vis. Sci.* 59 (9).
- Goldstein, B.G., Pavan, P.R., 1987. 'Blow-outs' in the retinal pigment epithelium. *Br. J. Ophthalmol.* 71 (9), 676–681.
- Graefe, V., 1866. Ueber centraler recidivierende retinitis. *Graefes Arch. Clin. Exp. Ophthalmol.* 12, 211–215.
- Graham, M.R., Davies, B., Grace, F.M., Kicman, A., Baker, J.S., 2008. Anabolic steroid use: patterns of use and detection of doping. *Sports Med.* 38 (6), 505–525.
- Gronbech, K.T., Rewes, A., Grauslund, J., 2014. [Chorioretinopathy as the first symptom of acute lymphoblastic leukaemia]. *Ugeskr Laeger* 176 (3A), V07130455.
- Gupta, P., Gupta, V., Dogra, M.R., Singh, R., Gupta, A., 2010. Morphological changes in the retinal pigment epithelium on spectral-domain OCT in the unaffected eyes with idiopathic central serous chorioretinopathy. *Int. Ophthalmol.* 30 (2), 175–181.
- Guyser, D.R., Puliafito, C.A., Mones, J.M., Friedman, E., Chang, W., Verdooner, S.R., 1992. Digital indocyanine-green angiography in chorioretinal disorders. *Ophthalmology* 99 (2), 287–291.
- Guyser, D.R., Yannuzzi, L.A., Slakter, J.S., Sorenson, J.A., Ho, A., Orlock, D., 1994. Digital indocyanine green videography of central serous chorioretinopathy. *Arch. Ophthalmol.* 112 (8), 1057–1062.
- Hage, R., Mrejen, S., Krivosic, V., Quentel, G., Tadayoni, R., Gaudric, A., 2015. Flat irregular retinal pigment epithelium detachments in chronic central serous chorioretinopathy and choroidal neovascularization. *Am. J. Ophthalmol.* 159 (5), 890–903. doi:10.1016/j.ophtha.2015.03.013.
- Haimovici, R., Koh, S., Gagnon, D.R., Lehrfeld, T., Wellik, S., Central Serous Chorioretinopathy Case-Control Study, G., 2004. Risk factors for central serous chorioretinopathy: a case-control study. *Ophthalmology* 111 (2), 244–249.
- Hayashi, K., Hasegawa, Y., Tokoro, T., 1986. Indocyanine green angiography of central serous chorioretinopathy. *Int. Ophthalmol.* 9 (1), 37–41.
- Hayreh, S.S., 1990. In vivo choroidal circulation and its watershed zones. *Eye* 4 (Pt 2), 273–289.
- He, L., Chen, C., Yi, Z., Wang, X., Liu, J., Zheng, H., 2020. Clinical application of multicolor imaging in central serous chorioretinopathy. *Retina* 40 (4), 743–749.
- Higgins, T.P., Khoo, C.T., Magrath, G., Shields, C.L., 2016. Flat choroidal melanoma masquerading as central serous chorioretinopathy. *Oman J. Ophthalmol.* 9 (3), 174–176.
- Hirami, Y., Tsujikawa, A., Gotoh, N., Iwama, D., Yoshimura, N., 2007. Alterations of retinal pigment epithelium in central serous chorioretinopathy treated by laser photocoagulation. *Jpn. J. Ophthalmol.* 51 (6), 477–478.
- Ho, A.C., Benson, W.E., Wong, J., 2000. Unusual immunogammapathy maculopathy. *Ophthalmology* 107 (6), 1099–1103.
- Hosoda, Y., Yoshikawa, M., Miyake, M., Tabara, Y., Ahn, J., Woo, S.J., Honda, S., Sakurada, Y., Shiragami, C., Nakanishi, H., Oishi, A., Ooto, S., Miki, A., Nagahama Study, G., Iida, T., Iijima, H., Nakamura, M., Khor, C.C., Wong, T.Y., Song, K., Park, K.H., Yamada, R., Matsuda, F., Tsujikawa, A., Yamashiro, K., 2018. CFH and VIPR2 as susceptibility loci in choroidal thickness and pachychoroid disease central serous chorioretinopathy. *Proc. Natl. Acad. Sci. U. S. A.* 115 (24), 6261–6266.
- Hosoda, Y., Miyake, M., Schellevis, R.L., Boon, C.J.F., Hoynig, C.B., Miki, A., Meguro, A., Sakurada, Y., Yoneyama, S., Takasago, Y., Hata, M., Muraoka, Y., Nakanishi, H., Oishi, A., Ooto, S., Tamura, H., Uji, A., Miyata, M., Takahashi, A., Ueda-Arakawa, N., Tajima, A., Sato, T., Mizuki, N., Shiragami, C., Iida, T., Khor, C.C., Wong, T.Y., Yamada, R., Honda, S., de Jong, E.K., Hollander, A.I.D., Matsuda, F., Yamashiro, K., Tsujikawa, A., 2019. Genome-wide association analyses identify two susceptibility loci for pachychoroid disease central serous chorioretinopathy. *Commun Biol* 2, 468.
- How, A.C., Koh, A.H., 2006. Angiographic characteristics of acute central serous chorioretinopathy in an Asian population. *Ann. Acad. Med. Singapore* 35 (2), 77–79.
- Hussain, N., Baskar, A., Ram, L.S.M., Das, T., 2006. Optical coherence tomographic pattern of fluorescein angiographic leakage site in acute central serous chorioretinopathy. *Clin. Exp. Ophthalmol.* 34 (2), 137–140.
- Ide, W.W., 2014. Central serous chorioretinopathy following hypobaric chamber exposure. *Aviat Space Environ. Med.* 85 (10), 1053–1055.
- Iida, T., Yannuzzi, L.A., Spaide, R.F., Borodoker, N., Carvalho, C.A., Negrao, S., 2003. Cystoid macular degeneration in chronic central serous chorioretinopathy. *Retina* 23 (1), 1–7 quiz 137–138.
- Iijima, H., Iida, T., Murayama, K., Imai, M., Gohdo, T., 1999. Plasminogen activator inhibitor 1 in central serous chorioretinopathy. *Am. J. Ophthalmol.* 127 (4), 477–478.
- Imamura, Y., Fujiwara, T., Margolis, R., Spaide, R.F., 2009. Enhanced depth imaging optical coherence tomography of the choroid in central serous chorioretinopathy. *Retina* 29 (10), 1469–1473.
- Imasawa, M., Ohshiro, T., Gotoh, T., Imai, M., Iijima, H., 2005. Central serous chorioretinopathy following vitrectomy with intravitreal triamcinolone acetonide for diabetic macular oedema. *Acta Ophthalmol. Scand.* 83 (1), 132–133.
- Jain, I.S., Singh, K., 1966. Maculopathy a corticosteroid side-effect. *J. All India Ophthalmol Soc* 14 (6), 250–252.
- Ji, Y., Li, M., Zhang, X., Peng, Y., Wen, F., 2018. Poor sleep quality is the risk factor for central serous chorioretinopathy. *J. Ophthalmol.* 2018, 9450297.
- Jiang, J.Q., Li, R.G., Wang, J., Liu, X.Y., Xu, Y.J., Fang, W.Y., Chen, X.Z., Zhang, W., Wang, X.Z., Yang, Y.Q., 2013. Prevalence and spectrum of GATA5 mutations associated with congenital heart disease. *Int. J. Cardiol.* 165 (3), 570–573.
- Jiang, M.S., Xu, X.L., Yang, T., Li, F., Zhang, X.D., 2019. Comparison of choroidal thickness in preeclamptic, healthy pregnant, and nonpregnant women: a systematic review and meta-analysis. *Ophthalmic Res.* 62 (1), 1–10.
- Kara, N., Sayin, N., Pirhan, D., Vural, A.D., Araz-Ersan, H.B., Tekirdag, A.I., Yildirim, G.Y., Gulac, B., Yilmaz, G., 2014. Evaluation of subfoveal choroidal thickness in pregnant women using enhanced depth imaging optical coherence tomography. *Curr. Eye Res.* 39 (6), 642–647.
- Karadimas, P., Bouzas, E.A., 2004. Glucocorticoid use represents a risk factor for central serous chorioretinopathy: a prospective, case-control study. *Graefes Arch. Clin. Exp. Ophthalmol.* 42 (9), 800–802.
- Karadimas, P., Kapetanios, A., Bouzas, E.A., 2004. Central serous chorioretinopathy after local application of glucocorticoids for skin disorders. *Arch. Ophthalmol.* 122 (5), 784–786.
- Kelty, P.J., Payne, J.F., Trivedi, R.H., Kelty, J., Bowie, E.M., Burger, B.M., 2008. Macular thickness assessment in healthy eyes based on ethnicity using Stratus OCT optical coherence tomography. *Invest. Ophthalmol. Vis. Sci.* 49 (6), 2668–2672.
- Khairallah, M., Kahloun, R., Tugal-Tutkun, I., 2012. Central serous chorioretinopathy, corticosteroids, and uveitis. *Ocul. Immunol. Inflamm.* 20 (2), 76–85.
- Kim, J.H., Kang, S.W., Kim, J.R., Kim, S.J., 2013. Variability of subfoveal choroidal thickness measurements in patients with age-related macular degeneration and central serous chorioretinopathy. *Eye* 27 (7), 809–815.
- Kim, Y.K., Woo, S.J., Park, K.H., Chi, Y.K., Han, J.W., Kim, K.W., 2018. Association of central serous chorioretinopathy with psychosocial factors is dependent on its phase and subtype. *Kor. J. Ophthalmol.* 32 (4), 281–289.
- Kitaya, N., Nagaoka, T., Hikichi, T., Sugawara, R., Fukui, K., Ishiko, S., Yoshida, A., 2003. Features of abnormal choroidal circulation in central serous chorioretinopathy. *Br. J. Ophthalmol.* 87 (6), 709–712.
- Kitzmann, A.S., Pulido, J.S., Diehl, N.N., Hodge, D.O., Burke, J.P., 2008. The incidence of central serous chorioretinopathy in Olmsted County, Minnesota, 1980–2002. *Ophthalmology* 115 (1), 169–173.
- Kloos, P., Laube, I., Thoelen, A., 2008. Obstructive sleep apnea in patients with central serous chorioretinopathy. *Graefes Arch. Clin. Exp. Ophthalmol.* 46 (9), 1225–1228.
- Kobayashi, W., Abe, T., Tamai, H., Nakazawa, T., 2012. Choroidal excavation with polypoidal choroidal vasculopathy: a case report. *Clin. Ophthalmol.* 6, 1373–1376.
- Konana, V.K., Shanmugam, P.M., Ramanjulu, R., Mishra, K.C.D., Sagar, P., 2018. Optical coherence tomography angiography features of choroidal hemangioma. *Indian J. Ophthalmol.* 66 (4), 581–583.
- Kowalczyk, L., Matet, A., Dor, M., Bararpour, N., Daruich, A., Dirani, A., Behar-Cohen, F., Thomas, A., Turck, N., 2018. Proteome and metabolome of subretinal fluid in central serous chorioretinopathy and rhegmatogenous retinal detachment: a pilot case study. *Transl Vis Sci Technol* 7 (1), 3.
- Lahousen, T., Painold, A., Luxenberger, W., Schienle, A., Kapfhammer, H.P., Ille, R., 2016. Psychological factors associated with acute and chronic central serous chorioretinopathy. *Nord. J. Psychiatr.* 70 (1), 24–30.
- Lamb, D.J., El-Sankary, W., Ferns, G.A., 2003. Molecular mimicry in atherosclerosis: a role for heat shock proteins in immunisation. *Atherosclerosis* 167 (2), 177–185.
- Lee, W.J., Lee, J.W., Park, S.H., Lee, B.R., 2017. En face choroidal vascular feature imaging in acute and chronic central serous chorioretinopathy using swept source optical coherence tomography. *Br. J. Ophthalmol.* 101 (5), 580–586.
- Lee, M., Lee, H., Kim, H.C., Chung, H., 2018. Changes in stromal and luminal areas of the choroid in pachychoroid diseases: insights into the pathophysiology of pachychoroid diseases. *Invest. Ophthalmol. Vis. Sci.* 59 (12), 4896–4908.
- Lehmann, M., Bousquet, E., Beydoun, T., Behar-Cohen, F., 2015. PACHYCHOROID: an inherited condition? *Retina* 35 (1), 10–16.
- Lenk, J., Sandner, D., Schindler, L., Pillunat, L.E., Matthe, E., 2019. Hair cortisol concentration in patients with active central serous chorioretinopathy is elevated - a pilot study. *Acta Ophthalmol.* 97 (4), e568–e571.
- Leveque, T.K., Zacks, D., Chervin, R.D., Musch, D., 2005. Prevalence of sleep apnea in patients with central serous chorioretinopathy. *Invest. Ophthalmol. Vis. Sci.* 46.
- Leveque, T.K., Yu, L., Musch, D.C., Chervin, R.D., Zacks, D.N., 2007. Central serous chorioretinopathy and risk for obstructive sleep apnea. *Sleep Breath.* 11 (4), 253–257.
- Liew, G., Quin, G., Gillies, M., Fraser-Bell, S., 2013. Central serous chorioretinopathy: a review of epidemiology and pathophysiology. *Clin. Exp. Ophthalmol.* 41 (2), 201–214.
- Lim, Z., Wong, D., 2008. Retinal pigment epithelial rip associated with idiopathic central serous chorioretinopathy. *Eye* 22 (3), 471–473.
- Lin, D.S., Chen, W.Q., Zhang, G.H., Huang, H.C., Zhou, Z.T., Cen, L.P., Chen, H.Y., 2014.

- Comparison of the optical coherence tomographic characters between acute Vogt-Koyanagi-Harada disease and acute central serous chorioretinopathy. *BMC Ophthalmol.* 14.
- Liu, R., Kuang, G.P., Luo, D.X., Lu, X.H., 2016a. Choroidal thickness in pregnant women: a cross-sectional study. *Int. J. Ophthalmol.* 9 (8), 1200–1206.
- Liu, R., Li, J., Li, Z., Yu, S., Yang, Y., Yan, H., Zeng, J., Tang, S., Ding, X., 2016b. Distinguishing polypoidal choroidal vasculopathy from typical neovascular age-related macular degeneration based on spectral domain optical coherence tomography. *Retina* 36 (4), 778–786.
- Lokki, A.I., Kaartokallio, T., Holmberg, V., Onkamo, P., Koskinen, L.L.E., Saavalainen, P., Heinonen, S., Kajantie, E., Kere, J., Kivinen, K., Pouta, A., Villa, P.M., Hiltunen, L., Laivuori, H., Meri, S., 2017. Analysis of complement C3 gene reveals susceptibility to severe preeclampsia. *Front. Immunol.* 8, 589.
- Loo, R.H., Scott, I.U., Flynn Jr., H.W., Gass, J.D., Murray, T.G., Lewis, M.L., Rosenfeld, P.J., Smiddy, W.E., 2002. Factors associated with reduced visual acuity during long-term follow-up of patients with idiopathic central serous chorioretinopathy. *Retina* 22 (1), 19–24.
- Lotery, A., Sivaprasad, S., O'Connell, A., Harris, R.A., Culliford, L., Ellis, L., Cree, A., Madhusudhan, S., Behar-Cohen, F., Chakravarthy, U., Peto, T., Rogers, C.A., Reeves, B.C., investigators, V.t., 2020. Eplerenone for chronic central serous chorioretinopathy in patients with active, previously untreated disease for more than 4 months (VICI): a randomised, double-blind, placebo-controlled trial. *Lancet* 395 (10220), 294–303.
- Malik, N., Rao, M.S., 2013. A review of the methods for human iPSC derivation. *Methods Mol. Biol.* 997, 23–33.
- Malik, R., Shah, A., Greaney, M.J., Dick, A.D., 2005. Bilateral serous macular detachment as a presenting feature of acute lymphoblastic leukemia. *Eur. J. Ophthalmol.* 15 (2), 284–286.
- Manayath, G.J., Arora, S., Parikh, H., Shah, P.K., Tiwari, S., Narendran, V., 2016. Is myopia a protective factor against central serous chorioretinopathy? *Int. J. Ophthalmol.* 9 (2), 266–270.
- Manjunath, V., Taha, M., Fujimoto, J.G., Duker, J.S., 2010. Choroidal thickness in normal eyes measured using cirrus HD optical coherence tomography. *Am. J. Ophthalmol.* 150 (3), 325–329.
- Margolis, R., Spaide, R.F., 2009. A pilot study of enhanced depth imaging optical coherence tomography of the choroid in normal eyes. *Am. J. Ophthalmol.* 147 (5), 811–815.
- Marmor, M.F., 1988. New hypotheses on the pathogenesis and treatment of serous retinal detachment. *Graefes Arch. Clin. Exp. Ophthalmol.* 226 (6), 548–552.
- Mashayekhi, A., Shukla, S.Y., Shields, J.A., Shields, C.L., 2014. Choroidal lymphoma: clinical features and association with systemic lymphoma. *Ophthalmology* 121 (1), 342–351.
- Matet, A., Daruich, A., Zola, M., Behar-Cohen, F., 2018. Risk factors for recurrences of central serous chorioretinopathy. *Retina* 38 (7), 1403–1414.
- Maumenee, A.E., 1965. Macular diseases: clinical manifestations. *Trans. Am. Acad. Ophthalmol. Otolaryngol.* 69, 605–613.
- Mehta, P.H., Meyerle, C., Sivaprasad, S., Boon, C., Chhablani, J., 2017. Preferred practice pattern in central serous chorioretinopathy. *Br. J. Ophthalmol.* 101 (5), 587–590.
- Mendrinou, E., Mavrakanas, N., Dang-Burgener, N.P., Pournaras, C.J., 2008. Bilateral multifocal retinal pigment epithelium detachments associated with systemic corticosteroids. *Eur. J. Ophthalmol.* 18 (4), 649–651.
- Merlini, G., Baldini, L., Brogna, C., Comelli, M., Goldaniga, M., Palladini, G., Deliliers, G.L., Gobbi, P.G., 2003. Prognostic factors in symptomatic Waldenström's macroglobulinemia. *Semin. Oncol.* 30 (2), 211–215.
- Messaoudi, S., He, Y., Gutsol, A., Wight, A., Hebert, R.L., Vilmundarson, R.O., Makrigiannis, A.P., Chalmers, J., Hamet, P., Tremblay, J., McPherson, R., Stewart, A.F.R., Touyz, R.M., Nemer, M., 2015. Endothelial Gata5 transcription factor regulates blood pressure. *Nat. Commun.* 6, 8835.
- Meyerle, C.B., Freund, K.B., Bhatnagar, P., Shah, V., Yannuzzi, L.A., 2007. Ketoconazole in the treatment of chronic idiopathic central serous chorioretinopathy. *Retina* 27 (7), 943–946.
- Miki, A., Kondo, N., Yanagisawa, S., Bessho, H., Honda, S., Negi, A., 2014. Common variants in the complement factor H gene confer genetic susceptibility to central serous chorioretinopathy. *Ophthalmology* 121 (5), 1067–1072.
- Mohabati, D., Schellevis, R.L., van Dijk, E.H.C., Altay, L., Fauser, S., Hoyng, C.B., De Jong, E.K., Boon, C.J.F., Yzer, S., 2019. Genetic risk factors in acute central serous chorioretinopathy. *Retina* 39 (12), 2303–2310.
- Mohabati, D., van Rijssen, T.J., van Dijk, E.H., Luyten, G.P., Missotten, T.O., Hoyng, C.B., Yzer, S., Boon, C.J., 2018b. Clinical characteristics and long-term visual outcome of severe phenotypes of chronic central serous chorioretinopathy. *Clin. Ophthalmol.* 12, 1061–1070.
- Moschos, M.M., Gazouli, M., Gatzoufas, Z., Brouzas, D., Nomikarios, N., Sivaprasad, S., Mitropoulos, P., Chatziralli, I.P., 2016. Prevalence of the complement factor H and Gstm1 genes polymorphisms in patients with central serous chorioretinopathy. *Retina* 36 (2), 402–407.
- Moulin, A.P., Bucher, M., Pournaras, J.A., Nguyen, C., Ambresin, A., 2010. Fluorescein and indocyanine green angiography findings in B cell lymphoblastic leukemia mimicking acute central serous chorioretinopathy. *Klin. Monbl. Augenheilkd.* 227 (4), 342–344.
- Mrejen, S., Balaratnasingam, C., Kaden, T.R., Bottini, A., Dansingani, K., Bhavsar, K.V., Yannuzzi, N.A., Patel, S., Chen, K.C., Yu, S., Stoffels, G., Spaide, R.F., Freund, K.B., Yannuzzi, L.A., 2019. Long-term visual outcomes and causes of vision loss in chronic central serous chorioretinopathy. *Ophthalmology* 126 (4), 576–588.
- Mudvari, S.S., Goff, M.J., Fu, A.D., McDonald, H.R., Johnson, R.N., Ai, E., Jumper, J.M., 2007. The natural history of pigment epithelial detachment associated with central serous chorioretinopathy. *Retina* 27 (9), 1168–1173.
- Muller, B., Tatsios, J., Klonner, J., Pilger, D., Joussen, A.M., 2018. Navigated laser photocoagulation in patients with non-resolving and chronic central serous chorioretinopathy. *Graefes Arch. Clin. Exp. Ophthalmol.* 256 (9), 1581–1588.
- Myers, C.E., Klein, B.E., Meuer, S.M., Swift, M.K., Chandler, C.S., Huang, Y., Gangaputra, S., Pak, J.W., Danis, R.P., Klein, R., 2015. Retinal thickness measured by spectral-domain optical coherence tomography in eyes without retinal abnormalities: the Beaver Dam Eye Study. *Am. J. Ophthalmol.* 159 (3), 445–456 e441.
- Nakamura, T., Ueda-Consolvo, T., Oiwake, T., Hayashi, A., 2016. Correlation between outer retinal layer thickness and cone density in patients with resolved central serous chorioretinopathy. *Graefes Arch. Clin. Exp. Ophthalmol.* 254 (12), 2347–2354.
- Nguyen Dinh Cat, A., Griol-Charhbil, V., Loufrani, L., Labat, C., Benjamin, L., Farman, N., Lacolley, P., Henrion, D., Jaisser, F., 2010. The endothelial mineralocorticoid receptor regulates vasoconstrictor tone and blood pressure. *Faseb. J.* 24 (7), 2454–2463.
- Nicholson, B.P., Ali Idris, A.M., Bakri, S.J., 2018a. Central serous chorioretinopathy: clinical characteristics associated with visual outcomes. *Semin. Ophthalmol.* 33 (6), 804–807.
- Nicholson, B.P., Atchison, E., Idris, A.A., Bakri, S.J., 2018b. Central serous chorioretinopathy and glucocorticoids: an update on evidence for association. *Surv. Ophthalmol.* 63 (1), 1–8.
- Noh, G.M., Nam, K.Y., Lee, S.U., Lee, S.J., 2019. Central serous chorioretinopathy following intravitreal dexamethasone implant. *Kor. J. Ophthalmol.* 33 (4), 392–394.
- Nudleman, E., Witmer, M.T., Kiss, S., Williams, G.A., Wolfe, J.D., 2014. Central serous chorioretinopathy in patients receiving exogenous testosterone therapy. *Retina-the Journal of Retinal and Vitreous Diseases* 34 (10), 2128–2132.
- Obata, R., Takahashi, H., Ueta, T., Yuda, K., Kure, K., Kure, K., Yanagi, Y., 2013. Tomographic and angiographic characteristics of eyes with macular focal choroidal excavation. *Retina* 33 (6), 1201–1210.
- Ooto, S., Hangai, M., Sakamoto, A., Tsujikawa, A., Yamashiro, K., Ojima, Y., Yamada, Y., Mukai, H., Oshima, S., Inoue, T., Yoshimura, N., 2010. High-resolution imaging of resolved central serous chorioretinopathy using adaptive optics scanning laser ophthalmoscopy. *Ophthalmology* 117 (9), 1800–1809 e1801-1802.
- Otsuka, S., Ohba, N., Nakao, K., 2002. A long-term follow-up study of severe variant of central serous chorioretinopathy. *Retina* 22 (1), 25–32.
- Pandi-Perumal, S.R., Trakht, I., Spence, D.W., Srinivasan, V., Dagan, Y., Cardinali, D.P., 2008. The roles of melatonin and light in the pathophysiology and treatment of circadian rhythm sleep disorders. *Nat. Clin. Pract. Neurol.* 4 (8), 436–447.
- Pang, C.E., Freund, K.B., 2015. Pachychoroid neovascularopathy. *Retina* 35 (1), 1–9.
- Pang, C.E., Shah, V.P., Sarraf, D., Freund, K.B., 2014. Ultra-widefield imaging with autofluorescence and indocyanine green angiography in central serous chorioretinopathy. *Am. J. Ophthalmol.* 158 (2), 362–371 e362.
- Parchand, S., Gupta, V., Gupta, A., Dogra, M.R., 2011. Bilateral giant retinal pigment epithelial rip in idiopathic central serous chorioretinopathy. *Retina* 31 (9), 1977–1978.
- Park, Y.J., Park, K.H., Woo, S.J., 2017. Clinical features of pregnancy-associated retinal and choroidal diseases causing acute visual disturbance. *Kor. J. Ophthalmol.* 31 (4), 320–327.
- Patwardhan, J.R., Gadgil, R.K., Pandit, Y.K., Velankar, B.B., 1970. Comparative histopathological study of arteriosclerosis of the retina, the brain and the circle of Willis. *J. All India Ophthalmol Soc* 18 (4), 155–161.
- Phasukkijwatana, N., Freund, K.B., Dolz-Marco, R., Al-Sheikh, M., Keane, P.A., Egan, C.A., Randhawa, S., Stewart, J.M., Liu, Q., Hunyor, A.P., Kreiger, A., Nagiel, A., Lalane, R., Rahimi, M., Lee, W.K., Jampol, L.M., Sarraf, D., 2018. Peripapillary pachychoroid syndrome. *Retina* 38 (9), 1652–1667.
- Piccolino, F.C., Borgia, L., 1994. Central serous chorioretinopathy and indocyanine green angiography. *Retina* 14 (3), 231–242.
- Piccolino, F.C., De La Longrais, R.R., Manea, M., Cicinelli, S., 2008. Posterior cystoid retinal degeneration in central serous chorioretinopathy. *Retina* 28 (7), 1008–1012.
- Pikkel, J., Beiran, I., Ophir, A., Miller, B., 2002. Acetazolamide for central serous retinopathy. *Ophthalmology* 109 (9), 1723–1725.
- Polak, B.C., Baarsma, G.S., Snyers, B., 1995. Diffuse retinal pigment epitheliopathy complicating systemic corticosteroid treatment. *Br. J. Ophthalmol.* 79 (10), 922–925.
- Prunte, C., Flammer, J., 1996. Choroidal capillary and venous congestion in central serous chorioretinopathy. *Am. J. Ophthalmol.* 121 (1), 26–34.
- Rahbani-Nobar, M.B., Javadzadeh, A., Ghojzadeh, L., Rafeey, M., Ghorbanhaghjo, A., 2011. The effect of Helicobacter pylori treatment on remission of idiopathic central serous chorioretinopathy. *Mol. Vis.* 17, 99–103.
- Rahimy, E., Pitcher 3rd, J.D., Hsu, J., Adam, M.K., Shahlaee, A., Samara, W.A., Vander, J.F., Kaiser, R.S., Chiang, A., Spirn, M.J., Fineman, M.S., 2018. A randomized double-blind placebo-control pilot study of eplerenone for the treatment of central serous chorioretinopathy (ecselior). *Retina* 38 (5), 962–969.
- Rajesh, B., Kaur, A., Giridhar, A., Gopalakrishnan, M., 2017. Vacuole" sign adjacent to retinal pigment epithelial defects on spectral domain optical coherence tomography in central serous chorioretinopathy associated with subretinal fibrin. *Retina* 37 (2), 316–324.
- Rao, N.A., Gupta, A., Dustin, L., Chee, S.P., Okada, A.A., Khairallah, M., Bodaghi, B., Lehoang, P., Accorinti, M., Mochizuki, M., Prabhupatalong, T., Read, R.W., 2010. Frequency of distinguishing clinical features in vogt-koyanagi-harada disease. *Ophthalmology* 117 (3) 591-U219.
- Raychaudhuri, S., Iartchouk, O., Chin, K., Tan, P.L., Tai, A.K., Ripke, S., Gowrisankar, S., Vemuri, S., Montgomery, K., Yu, Y., Reynolds, R., Zack, D.J., Campochiaro, B., Campochiaro, P., Katsanis, N., Daly, M.J., Seddon, J.M., 2011. A rare penetrant mutation in CFH confers high risk of age-related macular degeneration. *Nat. Genet.* 43 (12), 1232–1236.
- Reiter, J.F., Alexander, J., Rodaway, A., Yelon, D., Patient, R., Holder, N., Stainer, D.Y., 1999. Gata5 is required for the development of the heart and endoderm in zebrafish.

- Genes Dev. 13 (22), 2983–2995.
- Remky, A., Arend, O., Toonen, F., 1998. Infrared imaging of central serous chorioretinopathy: a follow-up study. *Acta Ophthalmol. Scand.* 76 (3), 339–342.
- Rishi, P., Appanraj, R., Sharma, T., 2016. Choroidal melanoma masquerading as multifocal central serous chorioretinopathy. *Oman J. Ophthalmol.* 9 (3), 187–188.
- Rocha, E.M., Wickham, L.A., da Silveira, L.A., Krenzer, K.L., Yu, F.S., Toda, I., Sullivan, B.D., Sullivan, D.A., 2000. Identification of androgen receptor protein and 5 alpha-reductase mRNA in human ocular tissues. *Br. J. Ophthalmol.* 84 (1), 76–84.
- Romdhane, K., Zola, M., Matet, A., Daruich, A., Elalouf, M., Behar-Cohen, F., Mantel, I., 2019. Predictors of treatment response to intravitreal anti-vascular endothelial growth factor (anti-VEGF) therapy for choroidal neovascularisation secondary to chronic central serous chorioretinopathy. *Br. J. Ophthalmol.* <https://doi.org/10.1136/bjophthalmol-2019-314625>.
- Sacconi, R., Baldin, G., Carnevali, A., Querques, L., Rabiolo, A., Marchini, G., Bandello, F., Querques, G., 2018. Response of central serous chorioretinopathy evaluated by multimodal retinal imaging. *Eye* 32 (4), 734–742.
- Said-Ahmed, K., Moustafa, G., Fawzy, M., 2012. Incidence and natural course of symptomatic central serous chorioretinopathy in pregnant women in a maternity hospital in Kuwait. *Middle East Afr. J. Ophthalmol.* 19 (3), 273–276.
- Saito, M., Saito, W., Hashimoto, Y., Yoshizawa, C., Fujiya, A., Noda, K., Ishida, S., 2013. Macular choroidal blood flow velocity decreases with regression of acute central serous chorioretinopathy. *Br. J. Ophthalmol.* 97 (6), 775–780.
- Saito, M., Saito, W., Hirooka, K., Hashimoto, Y., Mori, S., Noda, K., Ishida, S., 2015. Pulse waveform changes in macular choroidal hemodynamics with regression of acute central serous chorioretinopathy. *Invest. Ophthalmol. Vis. Sci.* 56 (11), 6515–6522.
- Salmon, J.E., Heuser, C., Triebwasser, M., Liszewski, M.K., Kavanagh, D., Roumenina, L., Branch, D.W., Goodship, T., Fremeaux-Bacchi, V., Atkinson, J.P., 2011. Mutations in complement regulatory proteins predispose to preeclampsia: a genetic analysis of the PROMISSE cohort. *PLoS Med.* 8 (3), e1001013.
- Sato, T., Kishi, S., Watanabe, G., Matsumoto, H., Mukai, R., 2007. Tomographic features of branching vascular networks in polypoidal choroidal vasculopathy. *Retina* 27 (5), 589–594.
- Saxena, S., Sinha, N., Sharma, S., 2011. Three-dimensional imaging by spectral domain optical coherence tomography in central serous chorioretinopathy with fibrin. *J. Ocul Biol Dis Infor* 4 (4), 149–153.
- Schatz, H., McDonald, H.R., Johnson, R.N., Chan, C.K., Irvine, A.R., Berger, A.R., Folk, J.C., Robertson, D.M., 1995. Subretinal fibrosis in central serous chorioretinopathy. *Ophthalmology* 102 (7), 1077–1088.
- Schellevis, R.L., van Dijk, E.H.C., Breukink, M.B., Altay, L., Bakker, B., Koelman, B.P.C., Kiemeny, L.A., Swinkels, D.W., Keunen, J.E.E., Fauser, S., Hoyng, C.B., den Hollander, A.I., Boon, C.J.F., de Jong, E.K., 2018. Role of the complement system in chronic central serous chorioretinopathy: a genome-wide association study. *JAMA Ophthalmol* 136 (10), 1128–1136.
- Schellevis, R.L., van Dijk, E.H.C., Breukink, M.B., Keunen, J.E.E., Santen, G.W.E., Hoyng, C.B., de Jong, E.K., Boon, C.J.F., den Hollander, A.I., 2019. Exome sequencing in families with chronic central serous chorioretinopathy. *Mol Genet Genomic Med* e576.
- Scholl, H.P., Charbel Issa, P., Walier, M., Janzer, S., Pollok-Kopp, B., Borncke, F., Fritsche, L.G., Chong, N.V., Fimmers, R., Wienker, T., Holz, F.G., Weber, B.H., Oppermann, M., 2008. Systemic complement activation in age-related macular degeneration. *PLoS One* 3 (7), e2593.
- Schubert, C., Pryds, A., Zeng, S., Xie, Y., Freund, K., Merriam, J., Barbazetto, I., Slakter, J., Chang, S., Munch, I., Drack, A., Hernandez, J., Yzer, S., Merriam, J., Linneberg, A., Larsen, M., Yannuzzi, L., Mullins, R., Allikmets, R., 2014a. Cadherin 5 is regulated by corticosteroids and associated with central serous chorioretinopathy. *Hum. Mutat.* 35 (7), 859–867.
- Schubert, C., Pryds, A., Zeng, S., Xie, Y., Freund, K.B., Spaide, R.F., Merriam, J.C., Barbazetto, I., Slakter, J.S., Chang, S., Munch, I.C., Drack, A.V., Hernandez, J., Yzer, S., Merriam, J.E., Linneberg, A., Larsen, M., Yannuzzi, L.A., Mullins, R.F., Allikmets, R., 2014b. Cadherin 5 is regulated by corticosteroids and associated with central serous chorioretinopathy. *Hum. Mutat.* 35 (7), 859–867.
- Schwartz, R., Habet-Wilner, Z., Martinez, M.R., Nutman, A., Goldenberg, D., Cohen, S., Shulman, S., Guzman-Gur, H., Loewenstein, A., Goldstein, M., 2017. Eplerenone for chronic central serous chorioretinopathy—a randomized controlled prospective study. *Acta Ophthalmol.* 95 (7), e610–e618.
- Scodes, D., Sulai, Y.N., Langlo, C.S., Fishman, G.A., Curcio, C.A., Carroll, J., Dubra, A., 2014. In vivo imaging of human cone photoreceptor inner segments. *Invest. Ophthalmol. Vis. Sci.* 55 (7), 4244–4251.
- Scott, A.W., Fekrat, S., Mruthyunjaya, P., Cummings, T.J., Cooney, M.J., 2008. Unusual case of diffuse choroidal melanoma masquerading as atypical central serous chorioretinopathy. *Retin. Cases Brief Rep.* 2 (4), 280–285.
- Seddon, J.M., Yu, Y., Miller, E.C., Reynolds, R., Tan, P.L., Gowrisankar, S., Goldstein, J.I., Triebwasser, M., Anderson, H.E., Zerbib, J., Kavanagh, D., Souied, E., Katsanis, N., Daly, M.J., Atkinson, J.P., Raychaudhuri, S., 2013. Rare variants in CFI, C3 and C9 are associated with high risk of advanced age-related macular degeneration. *Nat. Genet.* 45 (11), 1366–1370.
- Seong, H.K., Bae, J.H., Kim, E.S., Han, J.R., Nam, W.H., Kim, H.K., 2009. Intravitreal bevacizumab to treat acute central serous chorioretinopathy: short-term effect. *Ophthalmologica* 223 (5), 343–347.
- Shanmugam, M.P., Bhende, M., 2000. Retinal pigment epithelial tears associated with idiopathic central serous chorioretinopathy. *Indian J. Ophthalmol.* 48 (4), 315–317.
- Sheth, J., Anantharaman, G., Chandra, S., Sivaprasad, S., 2018. Double-layer sign on spectral domain optical coherence tomography in pachychoroid spectrum disease. *Indian J. Ophthalmol.* 66 (12), 1796–1801.
- Shields, C.L., Honavar, S.G., Shields, J.A., Cater, J., Demirci, H., 2001. Circumscribed choroidal hemangioma: clinical manifestations and factors predictive of visual outcome in 200 consecutive cases. *Ophthalmology* 108 (12), 2237–2248.
- Shields, C.L., Manalac, J., Das, C., Ferguson, K., Shields, J.A., 2014. Choroidal melanoma: clinical features, classification, and top 10 pseudomelanomas. *Curr. Opin. Ophthalmol.* 25 (3), 177–185.
- Shin, W.B., Kim, M.K., Lee, C.S., Kim, H., 2015. Comparison of the clinical manifestations between acute vogt-koyanagi-harada disease and acute bilateral central serous chorioretinopathy. *Kor. J. Ophthalmol.* 29 (6), 389–395.
- Shinojima, A., Fujita, K., Mori, R., Kawamura, A., Yuzawa, M., Yasukawa, T., 2016. Investigation of the etiology of central serous chorioretinopathy using en-face optical coherence tomography and indocyanine green angiography. *Ophthalmologica* 236 (2), 100–107.
- Shiragami, C., Takasago, Y., Osaka, R., Kobayashi, M., Ono, A., Yamashita, A., Hirooka, K., 2018. Clinical features of central serous chorioretinopathy with type 1 choroidal neovascularization. *Am. J. Ophthalmol.* 193, 80–86.
- Shulman, S., Goldenberg, D., Schwartz, R., Habet-Wilner, Z., Barak, A., Ehrlich, N., Loewenstein, A., Goldstein, M., 2016. Oral Rifampin treatment for longstanding chronic central serous chorioretinopathy. *Graefes Arch. Clin. Exp. Ophthalmol.* 254 (1), 15–22.
- Sim, R.B., Ferluga, J., Al-Rashidi, H., Abbaw, H., Schwaebel, W., Kishore, U., 2015. Complement factor H in its alternative identity as adrenomedullin-binding protein 1. *Mol. Immunol.* 68 (1), 45–48.
- Singh, S.R., Matet, A., van Dijk, E.H.C., Daruich, A., Fauser, S., Yzer, S., Peiretti, E., Sivaprasad, S., Lotery, A.J., Boon, C.J.F., Behar-Cohen, F., Freund, K.B., Chhablani, J., 2019. Discrepancy in current central serous chorioretinopathy classification. *Br. J. Ophthalmol.* 103 (6), 737–742.
- Smailhodzic, D., Klaver, C.C., Klevering, B.J., Boon, C.J., Groenewoud, J.M., Kirchhof, B., Dahan, M.R., den Hollander, A.I., Hoyng, C.B., 2012. Risk alleles in CFH and ARMS2 are independently associated with systemic complement activation in age-related macular degeneration. *Ophthalmology* 119 (2), 339–346.
- Smal, C., Lepiece, G., Bonnet, S., 2017. [Central serous chorioretinopathy following the use of phosphodiesterase 5 inhibitors]. *Rev. Med. Liege* 72 (11), 475–477.
- Songstad, A.E., Wiley, L.A., Duong, K., Kaalberg, E., Flamme-Wiese, M.J., Cranston, C.M., Riker, M.J., Levasseur, D., Stone, E.M., Mullins, R.F., Tucker, B.A., 2015. Generating iPSC-derived choroidal endothelial cells to study age-related macular degeneration. *Invest. Ophthalmol. Vis. Sci.* 56 (13), 8258–8267.
- Songstad, A.E., Worthington, K.S., Chirco, K.R., Giacalone, J.C., Whitmore, S.S., Anfinson, K.R., Ochoa, D., Cranston, C.M., Riker, M.J., Neiman, M., Stone, E.M., Mullins, R.F., Tucker, B.A., 2017. Connective tissue growth factor promotes efficient generation of human induced pluripotent stem cell-derived choroidal endothelium. *Stem Cells Transl Med* 6 (6), 1533–1546.
- Spaide, R.F., 2018a. Disease expression in nonexudative age-related macular degeneration varies with choroidal thickness. *Retina* 38 (4), 708–716.
- Spaide, R.F., 2018b. Improving the age-related macular degeneration construct: a new classification system. *Retina* 38 (5), 891–899.
- Spaide, R.F., Campeas, L., Haas, A., Yannuzzi, L.A., Fisher, Y.L., Guyer, D.R., Slakter, J.S., Sorenson, J.A., Orlock, D.A., 1996a. Central serous chorioretinopathy in younger and older adults. *Ophthalmology* 103 (12), 2070–2079 discussion 2079–2080.
- Spaide, R.F., Hall, L., Haas, A., Campeas, L., Yannuzzi, L.A., Fisher, Y.L., Guyer, D.R., Slakter, J.S., Sorenson, J.A., Orlock, D.A., 1996b. Indocyanine green videoangiography of older patients with central serous chorioretinopathy. *Retina* 16 (3), 203–213.
- Spaide, R.F., Jaffe, G.J., Sarraf, D., Freund, K.B., Sadda, S.R., Staurenghi, G., Waheed, N.K., Chakravarthy, U., Rosenfeld, P.J., Holz, F.G., Souied, E.H., Cohen, S.Y., Querques, G., Ohno-Matsui, K., Boyer, D., Gaudric, A., Blodi, B., Bauman, C.R., Li, X., Coscas, G.J., Brucker, A., Singerman, L., Luthert, P., Schmitz-Valckenberg, S., Schmidt-Erfurth, U., Grossniklaus, H.E., Wilson, D.J., Guymer, R.J., Yannuzzi, L.A., Chew, E.Y., Csaky, K., Mones, J.M., Pauleikhoff, D., Tadayoni, R., Fujimoto, J., 2020. Consensus nomenclature for reporting neovascular age-related macular degeneration data: consensus on neovascular age-related macular degeneration nomenclature study group. *Ophthalmology* 127 (5), 616–636.
- Spitznas, M., 1986. Pathogenesis of central serous retinopathy: a new working hypothesis. *Graefes Arch. Clin. Exp. Ophthalmol.* 224 (4), 321–324.
- Stennard, F.A., Costa, M.W., Elliott, D.A., Rankin, S., Haast, S.J., Lai, D., McDonald, L.P., Niederreither, K., Dolle, P., Bruneau, B.G., Zorn, A.M., Harvey, R.P., 2003. Cardiac T-box factor Tbx20 directly interacts with Nkx2-5, GATA4, and GATA5 in regulation of gene expression in the developing heart. *Dev. Biol.* 262 (2), 206–224.
- Sun, Y., Li, S., Li, H., Yang, F., Bai, Y., Zhao, M., Guo, J., Zhao, M., Zhou, P., Khor, C.C., Huang, L., Li, X., 2013. TNFRSF10A-LOC389641 rs13278062 but not REST-C4orf14-POLR2B-IGFBP7 rs1713985 was found associated with age-related macular degeneration in a Chinese population. *Invest. Ophthalmol. Vis. Sci.* 54 (13), 8199–8203.
- Suzuki, M., Gomi, F., Hara, C., Sawa, M., Nishida, K., 2014. Characteristics of central serous chorioretinopathy complicated by focal choroidal excavation. *Retina* 34 (6), 1216–1222.
- Takahashi, H., Hayashi, T., Tsuneoka, H., Nakano, T., Yamada, H., Katagiri, S., Fujino, Y., Noda, Y., Yoshimoto, M., Kawashima, H., 2014. Occult macular dystrophy with bilateral chronic subfoveal serous retinal detachment associated with a novel RP11L1 mutation (p.S1199P). *Doc. Ophthalmol.* 129 (1), 49–56.
- Tan, A.C., Fleckenstein, M., Schmitz-Valckenberg, S., Holz, F.G., 2016. Clinical application of multicolor imaging technology. *Ophthalmologica* 236 (1), 8–18.
- Ten Berge, J., van Dijk, E.H.C., Schreurs, M.W.J., Vermeer, J., Boon, C.J.F., Rothova, A., 2018. Antiretinal antibodies in central serous chorioretinopathy: prevalence and clinical implications. *Acta Ophthalmol.* 96 (1), 56–62.
- Thomas, E.L., Olk, R.J., Markman, M., Braine, H., Patz, A., 1983. Irreversible visual loss in Waldenstrom's macroglobulinemia. *Br. J. Ophthalmol.* 67 (2), 102–106.
- Tittl, M.K., Spaide, R.F., Wong, D., Pilotto, E., Yannuzzi, L.A., Fisher, Y.L., Freund, B., Guyer, D.R., Slakter, J.S., Sorenson, J.A., 1999. Systemic findings associated with

- central serous chorioretinopathy. *Am. J. Ophthalmol.* 128 (1), 63–68.
- Tsujikawa, A., Ojima, Y., Yamashiro, K., Ooto, S., Tamura, H., Nakagawa, S., Yoshimura, N., 2010. Punctate hyperfluorescent spots associated with central serous chorioretinopathy as seen on indocyanine green angiography. *Retina* 30 (5), 801–809.
- Tufan, H.A., Gencer, B., Comez, A.T., 2013. Serum cortisol and testosterone levels in chronic central serous chorioretinopathy. *Graefes Arch. Clin. Exp. Ophthalmol.* 251 (3), 677–680.
- Urner-Bloch, U., Urner, M., Stieger, P., Galliker, N., Winterton, N., Zubeil, A., Moutouh-de Parseval, L., Dummer, R., Goldinger, S.M., 2014. Transient MEK inhibitor-associated retinopathy in metastatic melanoma. *Ann. Oncol.* 25 (7), 1437–1441.
- van Dijk, E.H., van Herpen, C.M., Marinkovic, M., Haanen, J.B., Amundson, D., Luyten, G.P., Jager, M.J., Kapiteijn, E.H., Keunen, J.E., Adamus, G., Boon, C.J., 2015. Serous retinopathy associated with mitogen-activated protein kinase inhibition (binimetinib) for metastatic cutaneous and uveal melanoma. *Ophthalmology* 122 (9), 1907–1916.
- van Dijk, E.H., Dijkman, G., Biermasz, N.R., van Haalen, F.M., Pereira, A.M., Boon, C.J., 2016a. Chronic central serous chorioretinopathy as a presenting symptom of Cushing syndrome. *Eur. J. Ophthalmol.* 26 (5), 442–448.
- van Dijk, E.H., Duits, D.E., Versluis, M., Luyten, G.P., Bergen, A.A., Kapiteijn, E.W., de Lange, M.J., Boon, C.J., van der Velden, P.A., 2016b. Loss of MAPK pathway activation in post-mitotic retinal cells as mechanism in MEK inhibition-related retinopathy in cancer patients. *Medicine (Baltimore)* 95 (18), e3457.
- van Dijk, E.H., Nijhoff, M.F., de Jong, E.K., Meijer, O.C., de Vries, A.P., Boon, C.J., 2016c. Central serous chorioretinopathy in primary hyperaldosteronism. *Graefes Arch. Clin. Exp. Ophthalmol.* 254 (10), 2033–2042.
- van Dijk, E.H.C., Schellevis, R.L., Breukink, M.B., Mohabati, D., Dijkman, G., Keunen, J.E.E., Yzer, S., den Hollander, A.I., Hoyng, C.B., de Jong, E.K., Boon, C.J.F., 2019. Familial central serous chorioretinopathy. *Retina* 39 (2), 398–407.
- van Dijk, E.H.C., Schellevis, R.L., van Bergen, M., Breukink, M.B., Altay, L., Scholz, P., Fauser, S., Meijer, O.C., Hoyng, C.B., den Hollander, A.I., Boon, C.J.F., de Jong, E.K., 2017b. Association of a haplotype in the NR3C2 gene, encoding the mineralocorticoid receptor, with chronic central serous chorioretinopathy. *JAMA Ophthalmol* 135 (5), 446–451.
- van Dijk, E.H.C., Soonawala, D., Rooth, V., Hoyng, C.B., Meijer, O.C., de Vries, A.P.J., Boon, C.J.F., 2017c. Spectrum of retinal abnormalities in renal transplant patients using chronic low-dose steroids. *Graefes Arch. Clin. Exp. Ophthalmol.* 255 (12), 2443–2449.
- van Dijk, E.H.C., Tsonaka, R., Klar-Mohamad, N., Wouters, D., de Vries, A.P.J., de Jong, E.K., van Kooten, C., Boon, C.J.F., 2017d. Systemic complement activation in central serous chorioretinopathy. *PLoS One* 12 (7), e0180312.
- van Dijk, E.H.C., Fauser, S., Breukink, M.B., Blanco-Garavito, R., Groenewoud, J.M.M., Keunen, J.E.E., Peters, P.J.H., Dijkman, G., Souied, E.H., MacLaren, R.E., Querques, G., Downes, S.M., Hoyng, C.B., Boon, C.J.F., 2018a. Half-dose photodynamic therapy versus high-density subthreshold micropulse laser treatment in patients with chronic central serous chorioretinopathy: the PLACE trial. *Ophthalmology* 125 (10), 1547–1555.
- van Dijk, E.H.C., Kruij, W.H.J., Jager, M.J., Luyten, G.P.M., Vingerling, J.R., Boon, C.J.F., 2018b. Pimasertib-associated ophthalmological adverse events. *Acta Ophthalmol.* 96 (7), 712–718.
- van Haalen, F.M., van Dijk, E.H.C., Andela, C.D., Dijkman, G., Biermasz, N.R., Pereira, A.M., Boon, C.J.F., 2019. Maladaptive personality traits, psychological morbidity and coping strategies in chronic central serous chorioretinopathy. *Acta Ophthalmol.* 97 (4), 572–579.
- van Haalen, F.M., van Dijk, E.H.C., Dekkers, O.M., Bizino, M.B., Dijkman, G., Biermasz, N.R., Boon, C.J.F., Pereira, A.M., 2018b. Cushing's syndrome and hypothalamic-pituitary-adrenal axis hyperactivity in chronic central serous chorioretinopathy. *Front. Endocrinol.* 9, 39.
- van Rijssen, T.J., Mohabati, D., Dijkman, G., Theelen, T., de Jong, E.K., van Dijk, E.H.C., Boon, C.J.F., 2018. Correlation between redefined optical coherence tomography parameters and best-corrected visual acuity in non-resolving central serous chorioretinopathy treated with half-dose photodynamic therapy. *PLoS One* 13 (8), e0202549.
- van Rijssen, T.J., van Dijk, E.H.C., Yzer, S., Ohno-Matsui, K., Keunen, J.E.E., Schlingemann, R.O., Sivaprasad, S., Querques, G., Downes, S.M., Fauser, S., Hoyng, C.B., Piccolino, F.C., Chhablani, J.K., Lai, T.Y.Y., Lotery, A.J., Larsen, M., Holz, F.G., Freund, K.B., Yannuzzi, L.A., Boon, C.J.F., 2019. Central serous chorioretinopathy: towards an evidence-based treatment guideline. *Prog. Retin. Eye Res.* 73, 100770.
- van Rijssen, T.J., van Dijk, E.H.C., Scholz, P., Breukink, M.B., Blanco-Garavito, R., Souied, E.H., Keunen, J.E.E., MacLaren, R.E., Querques, G., Fauser, S., Downes, S.M., Hoyng, C.B., Boon, C.J.F., 2020. Reply to: comment on: PLACE trial report No. 3. *Am. J. Ophthalmol.* 212, 187–188.
- Vance, S.K., Imamura, Y., Freund, K.B., 2011. The effects of sildenafil citrate on choroidal thickness as determined by enhanced depth imaging optical coherence tomography. *Retina* 31 (2), 332–335.
- Vogel, R.N., Langlo, C.S., Scoles, D., Carroll, J., Weinberg, D.V., Kim, J.E., 2017. High-resolution imaging of intraretinal structures in active and resolved central serous chorioretinopathy. *Invest. Ophthalmol. Vis. Sci.* 58 (1), 42–49.
- von Hanno, T., Lade, A.C., Mathiesen, E.B., Peto, T., Njolstad, I., Bertelsen, G., 2017. Macular thickness in healthy eyes of adults (N = 4508) and relation to sex, age and refraction: the Tromsø Eye Study (2007–2008). *Acta Ophthalmol.* 95 (3), 262–269.
- Wang, M.S., Sander, B., Larsen, M., 2002. Retinal atrophy in idiopathic central serous chorioretinopathy. *Am. J. Ophthalmol.* 133 (6), 787–793.
- Wang, M., Munch, I.C., Hasler, P.W., Prunte, C., Larsen, M., 2008. Central serous chorioretinopathy. *Acta Ophthalmol.* 86 (2), 126–145.
- Warrow, D.J., Hoang, Q.V., Freund, K.B., 2013. Pachychoroid pigment epitheliopathy. *Retina* 33 (8), 1659–1672.
- Watzke, R.C., Packer, A.J., Folk, J.C., Benson, W.E., Burgess, D., Ober, R.R., 1984. Punctate inner choroidopathy. *Am. J. Ophthalmol.* 98 (5), 572–584.
- Wen, X.Z., Akiyama, Y., Pan, K.F., Liu, Z.J., Lu, Z.M., Zhou, J., Gu, L.K., Dong, C.X., Zhu, B.D., Ji, J.F., You, W.C., Deng, D.J., 2010. Methylation of GATA-4 and GATA-5 and development of sporadic gastric carcinomas. *World J. Gastroenterol.* 16 (10), 1201–1208.
- Wickham, L.A., Gao, J., Toda, I., Rocha, E.M., Ono, M., Sullivan, D.A., 2000. Identification of androgen, estrogen and progesterone receptor mRNAs in the eye. *Acta Ophthalmol. Scand.* 78 (2), 146–153.
- Yang, P., Ren, Y., Li, B., Fang, W., Meng, Q., Kijlstra, A., 2007. Clinical characteristics of Vogt-Koyanagi-Harada syndrome in Chinese patients. *Ophthalmology* 114 (3), 606–614.
- Yang, L., Jonas, J.B., Wei, W., 2013. Optical coherence tomography-assisted enhanced depth imaging of central serous chorioretinopathy. *Invest. Ophthalmol. Vis. Sci.* 54 (7), 4659–4665.
- Yannuzzi, L.A., 1986. Type A behavior and central serous chorioretinopathy. *Trans. Am. Ophthalmol. Soc.* 84, 799–845.
- Yannuzzi, L.A., Shakin, J.L., Fisher, Y.L., Altomonte, M.A., 1984. Peripheral retinal detachments and retinal pigment epithelial atrophic tracts secondary to central serous pigment epitheliopathy. *Ophthalmology* 91 (12), 1554–1572.
- Yannuzzi, L.A., Slakter, J.S., Kaufman, S.R., Gupta, K., 1992. Laser treatment of diffuse retinal pigment epitheliopathy. *Eur. J. Ophthalmol.* 2 (3), 103–114.
- Yap, E.Y., Robertson, D.M., 1996. The long-term outcome of central serous chorioretinopathy. *Arch. Ophthalmol.* 114 (6), 689–692.
- Yildiz, O., Seyrek, M., 2007. Vasodilating mechanisms of testosterone. *Exp. Clin. Endocrinol. Diabetes* 115 (1), 1–6.
- Yzer, S., Fung, A.T., Barbazetto, I., Yannuzzi, L.A., Freund, K.B., 2012. Central serous chorioretinopathy in myopic patients. *Arch. Ophthalmol.* 130 (10), 1339–1340.
- Zaidi, A.A., Brucker, A.J., Johnson, M.W., 2011. Diagnostic and therapeutic challenges. *Retina* 31 (10), 2125–2128.
- Zakir, S.M., Shukla, M., Simi, Z.U., Ahmad, J., Sajid, M., 2009. Serum cortisol and testosterone levels in idiopathic central serous chorioretinopathy. *Indian J. Ophthalmol.* 57 (6), 419–422.
- Zhao, M., Bousquet, E., Valamanesh, F., Farman, N., Jeanny, J.C., Jaisser, F., Behar-Cohen, F.F., 2011. Differential regulations of AQP4 and Kir4.1 by triamcinolone acetonide and dexamethasone in the healthy and inflamed retina. *Invest. Ophthalmol. Vis. Sci.* 52 (9), 6340–6347.
- Zhao, M., Célérier, I., Bousquet, E., Jeanny, J.C., Jonet, L., Savoldelli, M., Offret, O., Curan, A., Farman, N., Jaisser, F., Behar-Cohen, F., 2012. Mineralocorticoid receptor is involved in rat and human ocular chorioretinopathy. *J. Clin. Invest.* 122 (7), 2672–2679.
- Zucchiatti, I., Sacconi, R., Parravano, M.C., Costanzo, E., Querques, L., Montorio, D., Bandello, F., Querques, G., 2018. Eplerenone versus observation in the treatment of acute central serous chorioretinopathy: a retrospective controlled study. *Ophthalmol Ther* 7 (1), 109–118.
- Zumoff, B., Rosenfeld, R.S., Friedman, M., Byers, S.O., Rosenman, R.H., Hellman, L., 1984. Elevated daytime urinary excretion of testosterone glucuronide in men with the type-a behavior pattern. *Psychosom. Med.* 46 (3), 223–225.