



Universiteit  
Leiden  
The Netherlands

## **Crossover to photodynamic therapy or micropulse laser after failure of primary treatment of chronic central serous chorioretinopathy: the REPLACE trial**

Rijssen, T.J. van; Dijk, E.H.C. van; Scholz, P.; Breukink, M.B.; Dijkman, G.; Peters, P.J.H.; ... ; Hoyng, C.B.

### **Citation**

Rijssen, T. J. van, Dijk, E. H. C. van, Scholz, P., Breukink, M. B., Dijkman, G., Peters, P. J. H., ... Hoyng, C. B. (2020). Crossover to photodynamic therapy or micropulse laser after failure of primary treatment of chronic central serous chorioretinopathy: the REPLACE trial. *American Journal Of Ophthalmology*, 216, 80-89. doi:10.1016/j.ajo.2020.04.007

Version: Publisher's Version  
License: [Creative Commons CC BY 4.0 license](https://creativecommons.org/licenses/by/4.0/)  
Downloaded from: <https://hdl.handle.net/1887/3182870>

**Note:** To cite this publication please use the final published version (if applicable).

# Crossover to Photodynamic Therapy or Micropulse Laser After Failure of Primary Treatment of Chronic Central Serous Chorioretinopathy: The REPLACE Trial



THOMAS J. VAN RIJSEN, ELON H.C. VAN DIJK, PAULA SCHOLZ, MYRTE B. BREUKINK, GREET DIJKMAN, PETRUS J.H. PETERS, ROULA TSONAKA, ROBERT E. MACLAREN, SUSAN M. DOWNES, SASCHA FAUSER, CAMIEL J.F. BOON, AND CAREL B. HOYNG

- **PURPOSE:** To assess whether chronic central serous chorioretinopathy (cCSC) patients without a complete resolution of subretinal fluid (SRF) after either half-dose photodynamic therapy (PDT) or high-density subthreshold micropulse laser (HSML) treatment may benefit from crossover treatment.
- **DESIGN:** Multicenter prospective interventional case series.
- **METHODS:** cCSC patients with persistent SRF at the final visit of the PLACE trial were included. Patients received crossover treatment with either half-dose PDT or HSML.
- **RESULTS:** Thirty-two patients received PDT and 10 patients received HSML. At the first evaluation visit (6-8 weeks after treatment), 81% of patients in the PDT group had complete resolution of SRF, while none of the HSML-treated patients had complete resolution of SRF. At final visit (1 year after baseline), 78% ( $P = .030$ ) and 67% ( $P = .109$ ) of the patients, respectively, had a complete resolution of SRF. The mean retinal sensitivity in the PDT group increased from 21.7 dB (standard error [SE]: 0.9) to 23.4 dB (SE: 0.8) at evaluation visit 1 ( $P = .003$ ), to 24.7 dB (SE: 0.8) at final visit ( $P < .001$ ), while there were no significant changes in the HSML group (23.7 dB [SE: 1.6] at baseline, 23.8 dB [SE: 1.4] at evaluation 1, and 23.3 dB [SE: 1.4] at final visit). The mean visual acuity and mean visual quality-

of-life questionnaire score did not change significantly in both groups.

- **CONCLUSIONS:** Crossover to half-dose PDT after previous unsuccessful HSML treatment for cCSC may lead to improved anatomic and functional endpoints, while crossover to HSML after half-dose PDT does not seem to significantly affect these endpoints. (Am J Ophthalmol 2020;216:80–89. © 2020 The Authors. Published by Elsevier Inc. This is an open access article under the CC BY license (<http://creativecommons.org/licenses/by/4.0/>).)

**C**ENTRAL SEROUS CHORIORETINOPATHY (CSC) IS A chorioretinal disease in which subretinal fluid (SRF) accumulates secondary to choroidal abnormalities of unknown origin that induce damage to the outer blood-retina barrier at the level of the retinal pigment epithelium (RPE). CSC is associated with a decrease in visual acuity, scotoma, diminished contrast sensitivity, blurring, and/or metamorphopsia.<sup>1,2</sup> Several risk factors, including male sex, use of corticosteroids, and shift work have been described.<sup>2–5</sup> Based on abnormalities on multimodal imaging and the duration of the disease, CSC can be roughly categorized in acute CSC and chronic CSC (cCSC).<sup>6</sup> While acute CSC usually resolves spontaneously without the need for treatment, cCSC can lead to an irreversible deterioration in visual acuity, contrast vision, and quality of life.<sup>7–9</sup> Many treatment options have been proposed for cCSC, some with very limited and only retrospective evidence.<sup>10</sup> Photodynamic therapy (PDT) and high-density subthreshold micropulse laser (HSML) treatment are 2 prominent treatment modalities described for CSC, with a relatively large body of literature that has been published with regard to their efficacy. PDT mainly targets the choroid by inducing a certain degree of hypoperfusion and consequent remodeling, for which the formation of free radicals has been found to be of importance.<sup>11,12</sup> The exact mechanism of action of HSML is unknown but presumably lies in an effect on the RPE by delivering energy in short pulses, which may lead to a cascade of intracellular changes.<sup>13</sup> The PLACE trial, which

AJO.com

Supplemental Material available at [AJO.com](http://AJO.com).

Accepted for publication Apr 3, 2020.

From the Department of Ophthalmology (T.J.R., E.H.C.D., G.D., C.J.F.B.), Leiden University Medical Center, Leiden, The Netherlands; Department of Ophthalmology, University Hospital of Cologne, Cologne, Germany (P.S., S.F.); Department of Ophthalmology, Radboud University Medical Center, Nijmegen, The Netherlands (M.B.B., C.B.H.); Department of Ophthalmology, Bergman Clinics B.V., Velp, The Netherlands (P.J.H.P.); and Department of Biomedical Data Sciences (R.T.), Leiden University Medical Center, Leiden, The Netherlands; Oxford Eye Hospital, John Radcliffe Hospital, West Wing, Oxford, United Kingdom (R.E.M., S.M.D.); F. Hoffmann-La Roche, Basel, Switzerland (S.F.); and Amsterdam University Medical Center, University of Amsterdam, Amsterdam, The Netherlands (C.J.F.B.).

Inquiries to Camiel J.F. Boon, Department of Ophthalmology, Leiden University Medical Center, P.O. Box 9600, 2300 RC Leiden, The Netherlands; e-mail: [c.j.f.boon@lumc.nl](mailto:c.j.f.boon@lumc.nl)

was the first large investigator-initiated multicenter randomized controlled treatment trial on cCSC, has shown superiority of indocyanine green angiography (ICGA)-guided half-dose PDT over ICGA-guided HSML regarding both a complete resolution of SRF on optical coherence tomography (OCT), as well as functional endpoints.<sup>14</sup> In the PLACE trial, 67% of cCSC patients treated with half-dose PDT and 29% of the cCSC patients treated with HSML had a complete resolution of SRF on OCT at 7-8 months after treatment, which was a statistically significant difference in favor of PDT. In addition, the increase of the retinal sensitivity on microperimetry and, at the first evaluation visit, the increase of the best-corrected visual acuity (BCVA) were significantly higher in the half-dose PDT group as compared to the HSML group in the PLACE trial. Although the efficacy of half-dose PDT has been described to be superior to HSML for primary treatment of treatment-naïve patients with cCSC in the PLACE trial, it is unknown to what extent patients without a complete resolution of SRF after initial half-dose PDT or HSML monotherapy may benefit from a crossover treatment. Information on the outcome of crossover treatment would provide essential clinical information for ophthalmologists and cCSC patients who have persistent SRF on OCT after the previous administration of a single treatment modality, and the usefulness of subsequently trying the other treatment. The aim of this prospective, multicenter (Re-half-dose Photodynamic therapy versus re-high-density sub-threshold micropulse LASer treatment in patients with chronic Central serous chorioretinopathy: REPLACE) trial was to investigate the effect of crossover treatment (either from HSML to half-dose PDT or vice versa) regarding functional and anatomic outcome measures in cCSC patients.

---

## METHODS

THIS STUDY IS A PROSPECTIVE MULTICENTER TREATMENT study that included patients from the PLACE trial. The protocol and results of the PLACE trial have previously been published.<sup>14,15</sup> Patients from 4 academic medical centers located in Cologne (Germany), Leiden (the Netherlands), Nijmegen (the Netherlands), and Oxford (United Kingdom) were included in this study. This study adhered to the tenets of the Declaration of Helsinki and written informed consent was obtained from all participants. Institutional Review Board/Ethics Committee approval was obtained from all participating centers before the start of the study (NL-number: NL50642.091.14). The PLACE trial was registered at [clinicaltrials.gov](https://clinicaltrials.gov) (NCT01797861).

In this study, patients in whom SRF on OCT had persisted at final visit of the PLACE trial were enrolled. Included patients previously received 1 or 2 treatments

with either half-dose PDT, or 1 or 2 HSML treatments. The PLACE trial, and therefore also the current REPLACE trial, included both male and female cCSC patients aged 18 years or older with a BCVA of >20/200 and presence of foveal SRF for at least 6 weeks at baseline visit of the PLACE trial. At this baseline visit, on fluorescein angiography (FA) at least 1 hyperfluorescent area of leakage with RPE window defects typical for cCSC and hyperfluorescent abnormalities on ICGA had to be present. Patients in whom complete resolution of foveal SRF had occurred and who presented with only extrafoveal SRF at the final visit of the PLACE trial were also included in the REPLACE trial, as this was considered to be persistence of disease.<sup>16-18</sup> Patients who had received previous CSC treatments and patients who had posterior cystoid retinal degeneration, myopia of more than 6 diopters, and evidence of other causes of SRF or prolonged (>18 months) accumulation of SRF were excluded. Patients who were currently treated with corticosteroids, patients who had received this type of medication within the last 3 months prior to screening, and patients with contraindications to receive either FA or ICGA, or PDT were also excluded.

In the PLACE trial, cCSC patients were randomized to receive either half-dose PDT or HSML treatment. When there was persistence of SRF at evaluation visit 1, 6-8 weeks later, patients received an additional treatment, which had to be the same treatment as the first treatment they were randomized to. Final follow-up was 7-8 months after the first treatment visit. The final visit of the PLACE trial was considered to be the baseline visit of the REPLACE trial. At the baseline visit of the REPLACE trial, Early Treatment of Diabetic Retinopathy Study (ETDRS) BCVA, retinal sensitivity on microperimetry, and 25-Item National Eye Institute Visual Functioning Questionnaire (NEI-VFQ-25) were all obtained according to a standard protocol, along with Spectralis OCT, fundus photography, fundus autofluorescence (FAF), FA, and ICGA (Heidelberg Engineering, Heidelberg, Germany) in order to determine the area to be treated. In this REPLACE trial, patients with persistent SRF at the final visit of the PLACE trial received a crossover treatment. Patients who were previously treated with HSML in the PLACE trial received a crossover treatment to half-dose PDT and vice versa in this study. This crossover treatment had to be performed within 4 weeks after the baseline evaluation of the REPLACE trial. In the case of persistent (foveal or extrafoveal) SRF on OCT at evaluation visit 1 (6-8 weeks after first crossover treatment) patients received an additional treatment that had to be the same as the first crossover treatment. The final evaluation visit was scheduled at 1 year after the baseline visit of the REPLACE trial. The flow chart of the REPLACE trial is depicted in [Figure 1](#).

• **HALF-DOSE PHOTODYNAMIC THERAPY:** Eye drops with 1.0% tropicamide and 2.5% phenylephrine were

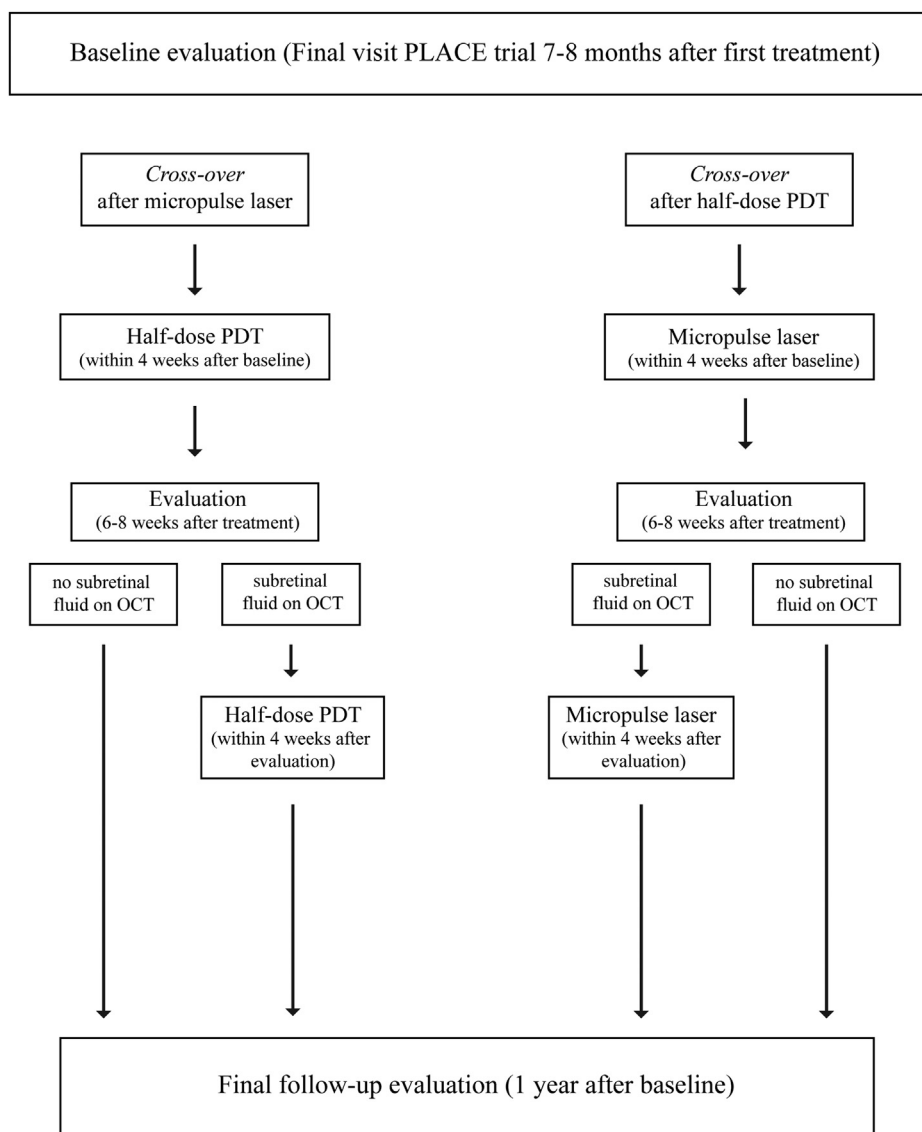


FIGURE 1. Flow chart of the REPLACE trial, in which chronic central serous chorioretinopathy patients received a crossover treatment with either high-density subthreshold micropulse laser (HSML) or half-dose photodynamic therapy (PDT). OCT = optical coherence tomography.

administered to the eye to be treated in order to achieve mydriasis. Subsequently, an intravenous infusion of 3 mg/m<sup>2</sup> (half-dose) verteporfin (Visudyne; Novartis, Basel, Switzerland) was administered within 10 minutes. An eye drop was administered (oxybuprocaine 0.4% or equivalent) to anesthetize the eye to be treated, after which a contact lens (Volk PDT lens) was positioned on the anesthetized eye at 15 minutes after the start of verteporfin infusion. For a duration of 83 seconds, laser therapy with a standard fluency (50 J/cm<sup>2</sup>) and a wavelength of 689 nm was applied to the area that was chosen based on the hyperfluorescent abnormalities on mid-phase ICGA, as these areas have previously been shown to be characteristic for cCSC.<sup>19</sup>

• **HIGH-DENSITY SUBTHRESHOLD MICROPULSE LASER TREATMENT:** First, eye drops with 1.0% tropicamide and 2.5% phenylephrine were used to dilate the pupil of the eye to be treated. After mydriasis was achieved, oxybuprocaine 0.4% (or equivalent) was used to anesthetize the eye, and a contact glass (for instance, a Volk area centralis lens) was positioned on the eye to be treated. Subsequently, keeping a distance of at least 500 μm from the foveal center, HSML treatment with an 810 nm diode laser was performed. The area that received treatment was chosen based on hyperfluorescent areas on mid-phase ICGA. The settings of the HSML laser included power of 1800 mW, duty cycle of 5%, frequency of 500 Hz, exposure time of 0.2 seconds per shot, and spot size of 125 μm.

**TABLE.** Baseline Characteristics of Chronic Central Serous Chorioretinopathy Patients Who Received a Crossover Treatment With Either Half-Dose Photodynamic Therapy or High-Density Subthreshold Micropulse Laser

	Half-Dose PDT (n = 32)	HSML (n = 10)	P Value
	Mean (SD)	Mean (SD)	
Age (years)	50.5 ± 8.6	50.7 ± 9.8	.771
Best-corrected visual acuity (ETDRS letters)	80.2 ± 8.0 (n = 30)	80.7 ± 6.6	.646
NEI-VFQ-25 composite score (points)	86.0 ± 12.7 (n = 30)	83.8 ± 18.4	.749
Retinal sensitivity (dB)	21.4 ± 5.3 (n = 29)	23.3 ± 4.1 (n = 9)	.302
Sex			
Male	26	7	.449
Female	6	3	

ETDRS = Early Treatment of Diabetic Retinopathy Study; HSML = high-density subthreshold micropulse laser; NEI-VFQ-25 = 25-Item National Eye Institute Visual Functioning Questionnaire; PDT = photodynamic therapy; SD = standard deviation

The power was reduced with steps of 300 mW when retinal discoloration was observed after a test shot outside the macular region at a power of 1800 mW, until the power with which no discoloration occurred after laser use was found.

• **OUTCOMES AND SAFETY:** The primary endpoint of the REPLACE trial was a complete resolution of SRF on OCT. Additionally, secondary outcome measures reflecting visual function included BCVA in ETDRS letters, retinal sensitivity on microperimetry, and the NEI-VFQ-25 score. The presence of SRF on OCT and BCVA were obtained at baseline, at evaluation visit 1, evaluation visit 2, and final visit (if available). Retinal sensitivity on microperimetry was obtained at baseline, evaluation visit 1, and final visit. The NEI-VFQ-25 score was obtained at baseline and final visit. The NEI-VFQ-25 responses were converted to a score from 0 to 100, using a previously described method.<sup>20</sup> Severe adverse events, if applicable, were reported to the principal investigator and the data safety monitoring board within 24 hours in order to evaluate the nature of the event, with an option to terminate the study if deemed necessary.

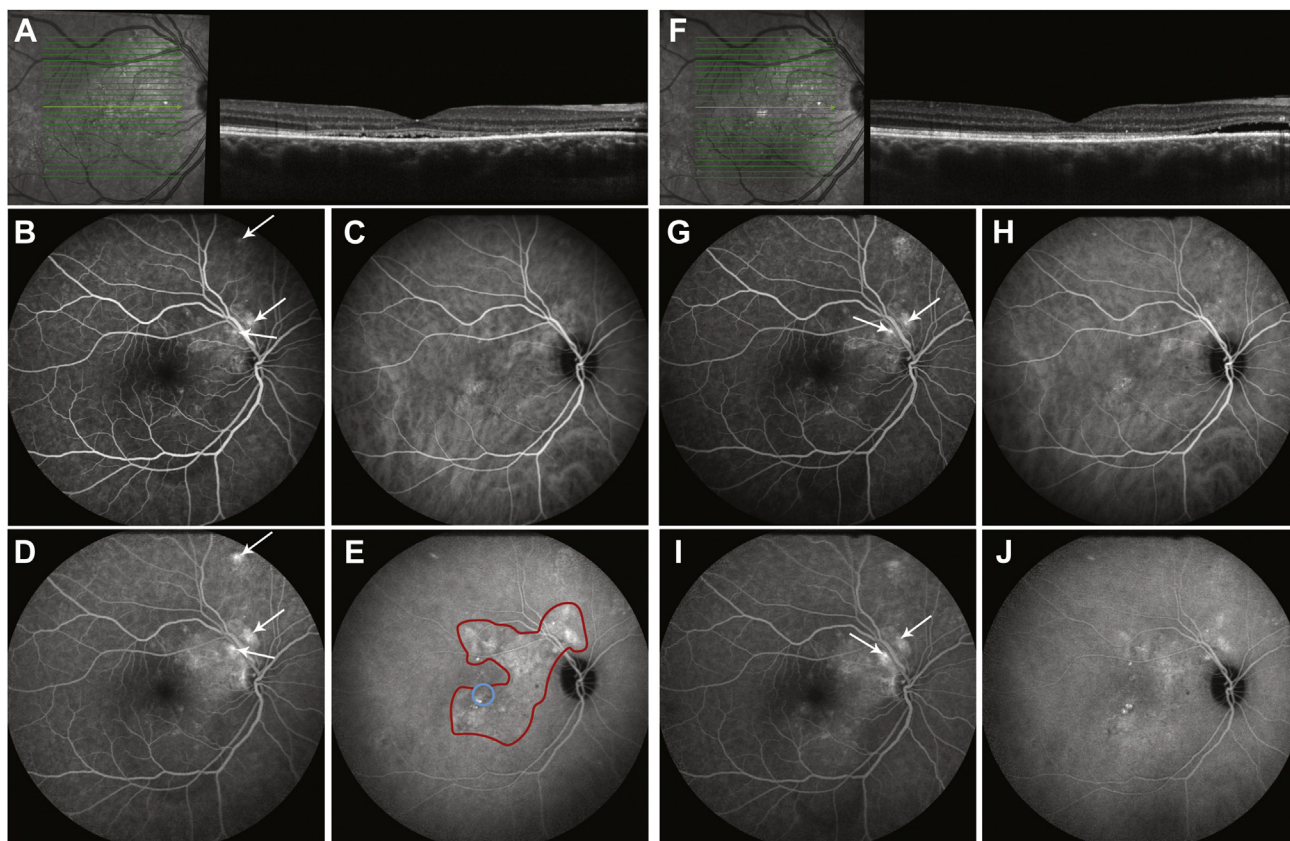
• **STATISTICS:** Statistical analyses were performed using SPSS statistics (version 23.0; IBM Corp, Armonk, New York, USA) and R version 3.5.3. (R Foundation for Statistical Computing, Vienna, Austria). For the binary longitudinal outcome SRF, mixed-effects logistic regression has been used to model the change in the percentage of patients with SRF resolution after crossover treatment in both groups. This analysis was performed using the function `mixed_model(.)` from the R package `GLMMadaptive`. In particular, the log odds of resolution is modeled as a function of the main effect of treatment, visiting occasions (taken as categorical), and their interaction. For the continuous longitudinal endpoints BCVA, retinal sensitivity on microperimetry, and NEI-VFQ-25 score, marginal multivariate regression models have been used to model the

mean progression per group. As in the mixed-effects logistic regression, the mean outcome is modeled as a function of the main effect of treatment, visiting occasions (taken as categorical), and their interaction. Hypothesis testing was done using Wald and F tests where appropriate.

## RESULTS

OUT OF THE 179 PATIENTS THAT WERE INCLUDED IN THE PLACE trial, 42 patients (33 male, 9 female) could be included in the REPLACE trial owing to persistence of SRF at final visit of the PLACE trial (4 patients in Cologne, 20 in Leiden, 14 in Nijmegen, and 4 in Oxford). Out of these 42 patients, 32 patients were initially treated with HSML in the PLACE trial and received a crossover treatment with half-dose PDT in the current REPLACE trial. There were 10 patients who were initially treated with half-dose PDT and subsequently received a crossover treatment to HSML in the REPLACE trial. Baseline characteristics for the REPLACE trial were not available for 2 patients who received a crossover to half-dose PDT. This was because these patients insisted on prompt crossover treatment, directly after evaluation visit 1 in the PLACE trial, which was scheduled before the end of the PLACE trial. However, the follow-up visits of these patients were included in the analyses. There were 16 patients (38%) who received an additional treatment in the REPLACE trial because of persistent SRF on OCT at 6-8 weeks after the first crossover treatment, according to the study protocol (Figure 1). These 16 patients included 6 patients out of the 32 patients (19%) who received crossover treatment to PDT, while all 10 patients who received crossover treatment to HSML required a second HSML treatment in this study because of persistent SRF on OCT at the first evaluation visit. A total of 40 patients could be evaluated at final visit (2 patients were lost to follow-up). There were no significant differences in baseline characteristics





**FIGURE 2.** Optical coherence tomography (OCT; A, F), fluorescein angiography (FA; early phase: B, G; late phase: D, I), and indocyanine green angiography (ICGA; early phase: C, H; late phase: E, J) of a 46-year-old man affected with chronic central serous chorioretinopathy. This patient received half-dose photodynamic therapy (PDT) in the PLACE trial, but had persistence of subretinal fluid at final visit of this study (A). Multiple focal leakage points on FA are shown by the white arrows (B, D). Hyperfluorescent areas can be observed on ICGA, which represents dysfunction of the choroid (C, E). Owing to the persistence of subretinal fluid at baseline visit and evaluation visit 1 of the REPLACE trial (A-E), this patient received a total of 2 crossover treatments with high-density subthreshold micropulse laser (HSML). The hyperfluorescent area on ICGA within the red line (E) was treated with HSML, with the exception of the fovea, which is represented by the blue circle. At final visit (F-J), the subretinal fluid had resolved subfoveally, but had increased temporally of the fovea (F). Moreover, focal leakage points were still present after crossover to HSML (G, I), and the degree and size of hyperfluorescence on ICGA had not considerably changed after HSML treatment (H, J).

between each group (Table). Multimodal imaging examples of cCSC patients who received crossover treatment to half-dose PDT and crossover treatment to HSML are depicted in Figures 2 and 3, respectively.

• **CROSSOVER TO HALF-DOSE PHOTODYNAMIC THERAPY GROUP:** Out of the total of 32 patients who received a crossover to half-dose PDT after previous HSML treatment, 28 patients (88%) had already received HSML treatment twice according to the PLACE trial protocol. The remaining 4 patients initially had a complete resolution of SRF at evaluation visit 1 after the first HSML of the PLACE trial, but displayed recurrence of SRF at final visit of the PLACE trial. At the first evaluation visit of this subgroup of the REPLACE trial at 6-8 weeks after crossover treatment with half-dose PDT, SRF had resolved in 26 out of 32 patients (81%;  $P = .036$ ). At final visit, there was a complete resolution of SRF in 25 out of 30 patients

(78%;  $P = .030$ ). The mean BCVA in ETDRS letters was 80.0 (standard error [SE]: 1.4) at baseline ( $n = 30$ ), which increased to 82.1 (SE: 1.6) at evaluation visit 1 ( $n = 32$ ;  $P = .810$ ) and to  $82.4 \pm$  (SE: 1.9) at final visit ( $n = 30$ ;  $P = .157$ ). Mean retinal sensitivity on microperimetry was 21.7 dB (SE: 0.9) at baseline ( $n = 29$ ), 23.4 dB (SE: 0.8) at evaluation visit 1 ( $n = 18$ ;  $P = .003$ ), and 24.7 dB (SE: 0.8) at final visit ( $n = 27$ ;  $P < .001$ ). At baseline, mean NEI-VFQ-25 was 86.1 (SE: 2.5) points ( $n = 30$ ), which increased to 87.9 (SE: 2.2) points at final visit ( $n = 30$ ;  $P = .132$ ).

• **CROSSOVER TO HIGH-DENSITY SUBTHRESHOLD MICROPULSE LASER GROUP:** Out of the 10 patients who received a crossover to HSML treatment after previous half-dose PDT, there were 7 patients (70%) who had already received a second half-dose PDT within the PLACE trial. The remaining 3 patients initially had a complete

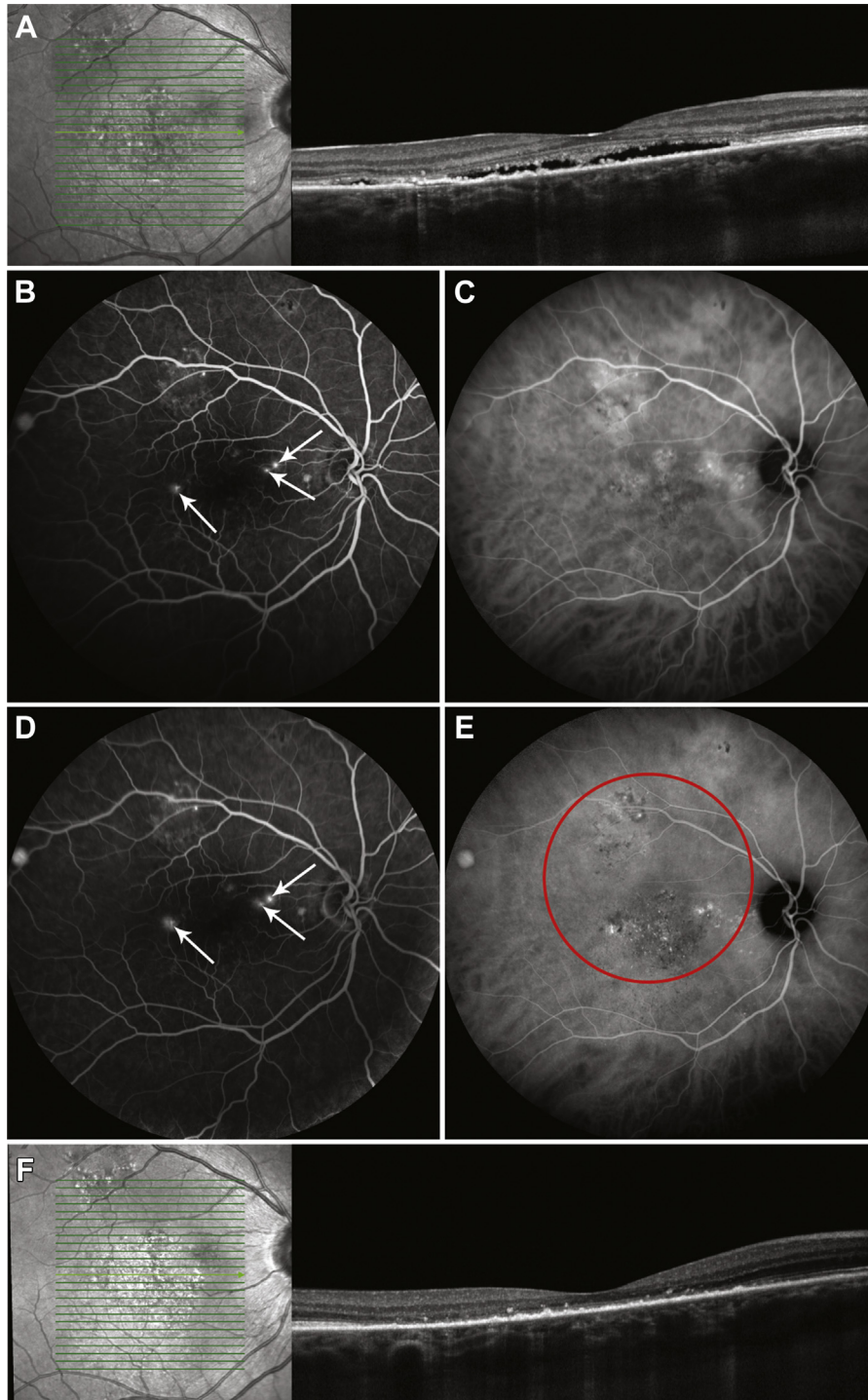


FIGURE 3. Optical coherence tomography (OCT; A), fluorescein angiography (FA; B, D), and indocyanine green angiography (ICGA; C, E) of a 43-year-old man with chronic central serous chorioretinopathy. After treatment with high-density subthreshold micropulse laser within the PLACE trial at the final visit of this study (A-E) subretinal fluid was still present (A), together with focal leakage points on early FA (B) and late FA (D), and hyperfluorescent changes on ICGA (C, E). A crossover treatment to half-dose photodynamic therapy (PDT) was performed. The area within the red circle (E) was treated with the PDT laser (single laser spot of 7,200  $\mu\text{m}$ ). After half-dose PDT, there was a complete resolution of subretinal fluid on OCT (F). As the subretinal fluid had resolved, no additional FA and ICGA images were obtained, according to the study protocol.

resolution of foveal SRF at evaluation visit 1 of the PLACE trial, but displayed recurrence of foveal SRF at final visit of the PLACE trial. Out of the 10 patients who received HSML in the REPLACE trial, none of the patients had complete resolution of SRF at evaluation visit 1, while 6 out of 9 patients had a complete resolution of SRF at final visit ( $P = .109$ ). One patient was lost to follow-up at final visit, as the patient was abroad and was not able to come for the final visit. Because all patients had persistence of SRF on OCT after the first HSML crossover treatment, all these patients were treated with HSML a second time according to the protocol of the REPLACE trial. The mean BCVA was 80.7 (SE: 2.5) ETDRS letters at baseline ( $n = 10$ ), 80.9 (SE: 2.8) at evaluation visit 1 ( $n = 10$ ;  $P = .720$ ), and 80.0 (SE: 3.5) at final visit ( $n = 9$ ;  $P = .822$  compared to baseline). The mean retinal sensitivity on microperimetry was 23.7 dB (SE: 1.6) at baseline ( $n = 9$ ), 23.8 dB (SE: 1.4) at evaluation visit 1 ( $n = 5$ ;  $P = .429$ ), and 23.3 dB (SE: 1.4) ( $P = .491$  compared to baseline) at final visit ( $n = 9$ ). The mean NEI-VFQ-25 score was 83.8 (SE: 4.4) points at baseline ( $n = 10$ ), which changed to 83.5 (SE: 4.0) points at final visit ( $n = 9$ ;  $P = .877$ ).

- **SAFETY:** A severe adverse event occurred in 1 patient in the crossover to half-dose PDT group (minor stroke of the right medial cerebral artery, 11 months after treatment). This event has been communicated with the drug safety monitoring board, and was reported to the manufacturer of verteporfin (Novartis). Because this patient had an extensive cardiovascular history and the stroke occurred 11 months after half-dose PDT, this event was not considered to be related to half-dose PDT. No treatment-related (severe) adverse events were observed in both groups.

---

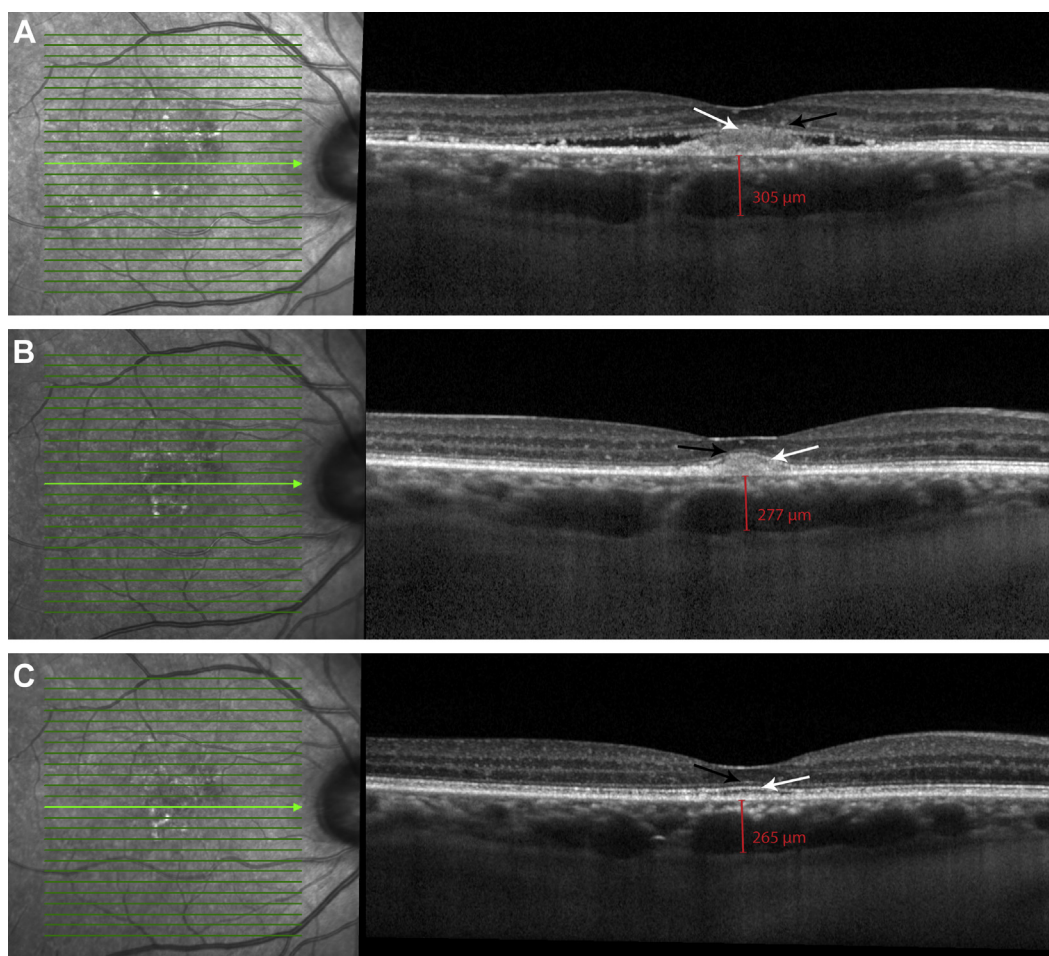
## DISCUSSION

IN THE PLACE TRIAL, WHICH STUDIED TREATMENT-NAIVE cCSC patients, a statistically significant difference in treatment response was seen in favor of half-dose PDT, with 67% of PDT-treated patients achieving a complete resolution of SRF on OCT, as compared to 29% of HSML-treated patients at 7-8 months after treatment. After second half-dose PDT in the PLACE trial, when the first half-dose PDT treatment did not result in a complete resolution of SRF, 32.4% had a complete resolution of SRF, as compared to 15.4% in the patients who needed a second HSML treatment, which was not significantly different.<sup>14</sup> In addition, at the first evaluation visit of the PLACE trial a significantly higher increase in retinal sensitivity on microperimetry was observed in PDT-treated patients as compared to HSML-treated patients.<sup>14</sup> The REPLACE trial describes the outcome of crossover treatment to either ICGA-guided half-dose PDT or HSML in cCSC patients with persistence of SRF at 7-8 months after 1 or 2 ICGA-

guided half-dose PDT or HSML treatments within the PLACE trial.<sup>14</sup>

In the current study, a complete resolution of SRF on OCT was achieved at final follow-up in 78% of patients after crossover to half-dose PDT, which indicates that half-dose PDT may be an effective treatment in patients who did not respond to previous HSML. As in the PLACE trial, we found a significant improvement in retinal sensitivity after half-dose PDT crossover treatment, without a significant improvement in BCVA or NEI-VFQ-25 questionnaire outcome, in contrast to the patients in the HSML group who did not show improvement in any of the functional parameters, including microperimetry.<sup>14</sup> It has been previously suggested that retinal sensitivity may be a more sensitive parameter than BCVA to detect retinal treatment effects for instance in CSC, since BCVA is often relatively preserved in cCSC patients.<sup>21,22</sup> Therefore, potential differences in functional endpoints between the crossover groups may first be detected as a difference in retinal sensitivity. The additional effect of half-dose PDT after HSML in these cases may lie in the fact that PDT targets the choroid, which is presumed to be the primarily affected tissue in CSC. PDT induces choroidal vascular changes and remodeling, a decrease of choroidal thickening to near-normal levels, and an associated decrease in extravascular leakage.<sup>11,23,24</sup> This significantly increases the likelihood of restoration of the balance between the (pumping function of) RPE and the choroid, with subsequent resorption of SRF. Consequently, a gradual restoration of photoreceptor-RPE interaction may occur, reflected in a gradually increased restoration and visibility of the external limiting membrane and ellipsoid lines on OCT (Figure 4). This restoration of the photoreceptor-RPE interface generally leads to a slow decrease in visual symptoms over the following months in cases without foveal atrophic changes that are too advanced. Half-dose PDT in cCSC patients with in particular hypofluorescent changes on ICGA has recently been found to be less effective. An explanation may lie in the fact that this hypofluorescence on ICGA indicates inadequate perfusion of the choriocapillaris, which may result in inadequate verteporfin delivery at the area in need of treatment.<sup>25</sup> Also, hypofluorescent choroidal characteristics on ICGA in a phenotype that is otherwise typical for cCSC may indicate end-stage disease that has become relatively insensitive to PDT treatment. Hypofluorescence on ICGA was present in only 1 out of 5 patients with persistent SRF after crossover to half-dose PDT in the current study, indicating that other unknown mechanisms may also be involved. For HSML, the mechanism of treatment response is less clear, but the melanin in the RPE mainly absorbs the laser light, which has been assumed to subsequently trigger the formation of heat shock proteins, which may stimulate the pumping function of the RPE.<sup>26</sup> The difference in efficacy between PDT and HSML may be closely related to the fact that HSML does not directly address the main underlying





**FIGURE 4.** Optical coherence tomography (OCT) imaging of a 60-year-old man diagnosed with chronic central serous chorioretinopathy. Because of persistent subretinal fluid (SRF) after 2 high-density subthreshold micropulse laser treatments in the PLACE trial, this patient received crossover treatment with half-dose photodynamic therapy (PDT) in the REPLACE trial. At baseline visit of the REPLACE trial (before half-dose PDT), both the ellipsoid zone (EZ; A, white arrow) and external limiting membrane (ELM; A, black arrow) were discontinuous and difficult to distinguish from the hyperreflectivity in the subretinal space (A). At 8 weeks after half-dose PDT, SRF had disappeared and the EZ (white arrow) and ELM (black arrow) outlines became more evident (B). At final visit of the REPLACE trial (1 year after treatment), the EZ (white arrow) and ELM (black arrow) layers had returned to normal (C). A reduction of the choroidal thickness occurred simultaneously to the restoration of the EZ and ELM layers (A, B, C).

choroidal pathology, which is also reflected in the observation that focal leakage and choroidal congestion and hyperpermeability may persist after HSML treatment, as seen on FA and ICGA (Figure 2). Multiple HSML treatments are often necessary before a resolution of SRF can be seen in patients, with persistent and potentially damaging SRF being present in the meantime.

Since none of the cross-over to HSML patients in the current study had a complete resolution of SRF at the first evaluation visit, all these patients received a second HSML treatment. Remarkably, 6 out of 9 crossover-to-HSML patients had a complete resolution of SRF at final visit. It should be noted that, in contrast to the crossover to half-dose PDT group, this subgroup of crossover HSML-treated patients did not show an improvement in any functional outcome parameters at final follow-up of this study.

A possible explanation may be that these patients already had a prolonged presence of SRF throughout the course of the PLACE and REPLACE trial, which may have caused irreversible photoreceptor damage.<sup>16,27</sup> Breukink and associates previously reported a complete resolution of SRF in only 1 out of 10 cCSC patients at 7 weeks after crossover treatment from half-dose PDT to HSML, and in 2 out of 10 patients at a mean of 73 weeks after baseline.<sup>28</sup> The discrepancy between the observations of Breukink and associates and the findings of our study at final visit may be explained by differences in inclusion criteria. For instance, in the REPLACE trial, patients were not allowed to have received treatment with steroids within 3 months before inclusion in the PLACE trial or previous CSC treatment(s) before inclusion, which is in contrast to the study of Breukink and associates; more severe, recalcitrant cCSC

patients may have been included in their study. Scholz and associates reported a significant decrease in the automatically calculated central retinal thickness after a crossover to HSML treatment in cCSC patients who had persistent SRF after PDT.<sup>29</sup> However, this automatic measurement erroneously included the SRF height.<sup>18</sup> Other studies have reported that 9%-80% of cCSC patients treated with HSML require more than 1 HSML treatment until complete resolution of SRF.<sup>30,31</sup> Chen and associates reported that multiple HSML treatments may especially be needed in cCSC patients with more diffuse, extensive leakage, compared to those with focal leakage.<sup>32</sup> However, we have shown previously that the percentage of cCSC patients with a complete resolution of SRF after treatment is still higher in those treated with half-dose PDT compared to HSML treatment, regardless of the presence of focal or diffuse leakage.<sup>33,34</sup> Mohabati and associates have found that half-dose PDT is also effective in more severe cCSC phenotypes, and that these severe patients may still have a relatively favorable visual prognosis.<sup>8,35</sup> The resolution of SRF in 6 out of 9 HSML patients at the final visit of the REPLACE trial can be a direct, late effect of the 2 performed HSML crossover treatments, but may also be (partly) due to the natural course of CSC, which has a tendency to wax and wane even in chronic cases. However, the sample size seems to be too small to draw firm conclusions based on this small and very specific subgroup of patients who previously did not respond to half-dose PDT and subsequently underwent HSML. This again underlines the importance of prospective randomized controlled trials studying the treatment of CSC.

This study has limitations. First, by design, only patients included in the PLACE trial and with persistent SRF at final visit were eligible for enrollment, which led to a

limited number of patients that could be included in this study, especially in the crossover to HSML group. Not all patients that were enrolled to the PLACE trial and had persistent SRF at final visit could be included in the REPLACE trial. There were 44 patients in the PLACE trial who already had their final study visit before the REPLACE trial commenced. Moreover, some patients started to use steroids during the PLACE trial, or were lost to follow-up. Because of this limited number of patients, the REPLACE trial was not powered for the assessed endpoints (including resolution of SRF on OCT, BCVA, retinal sensitivity, and NEI-VFQ-25 score). Even though this trial was not considered to be powered to detect statistically significant differences in these parameters, we found a statistically significant increase in the percentage of patients with a complete resolution of SRF on OCT, as well as a significantly increased retinal sensitivity on microperimetry, within the patient group that underwent a crossover to half-dose PDT. There were 2 patients in the crossover to half-dose PDT group for whom no REPLACE baseline visit was available, because they insisted on early crossover treatment before the final follow-up visit of the PLACE trial. However, the follow-up visits of these patients were included in the mixed-model analyses, since they may provide additional information to these models.

In conclusion, half-dose (or half-fluence) PDT is the treatment of choice for cCSC, and cCSC patients with persistence of SRF after primary HSML can benefit from half-dose PDT, which can induce a complete resolution of SRF in many patients, together with an improvement in retinal sensitivity. In cCSC patients with persistence of SRF after half-dose PDT, HSML can be considered, although it may lead to resolution of SRF only in the long run, without a significant improvement in functional outcomes.

---

FUNDING/SUPPORT: THIS RESEARCH WAS SUPPORTED BY THE FOLLOWING FOUNDATIONS: STICHTING MACULA FONDS; RETINA Nederland Onderzoek Fonds; Stichting Blinden-Penning; Algemene Nederlandse Vereniging ter Voorkoming van Blindheid; Landelijke Stichting voor Blinden en Slechtzienden, which contributed through UitZicht (Delft, the Netherlands); Rotterdamse Stichting Blindenbelangen (Rotterdam, the Netherlands); Stichting Leids Oogheelkundig Ondersteuningsfonds (Leiden, the Netherlands); Haagse Stichting Blindenhulp (The Hague, the Netherlands); Stichting Ooglijders (Rotterdam, the Netherlands); the Oxford NIHR Biomedical Research Centre (Oxford, United Kingdom); the Gisela Thier Fellowship of Leiden University, Leiden, the Netherlands (C.J.F.B.); and the Netherlands Organization for Scientific Research (VENI grant to C.J.F.B.). These funding organizations provided unrestricted grants and had no role in the design, conduct, or publication of this research. This investigator-initiated study received funding from Novartis Pharma B.V. (Arnhem, the Netherlands) solely for the purchase of verteporfin (Visudyne), to enable photodynamic therapy at the Oxford site, because photodynamic therapy currently is not reimbursed routinely by the United Kingdom National Health Service for treating central serous chorioretinopathy. Novartis Pharma B.V. had no role in funding, designing, conducting, or evaluating the study, nor in the writing of this manuscript. Financial Disclosures: Sascha Fauser is an employee of Hoffman-La Roche, Basel, Switzerland. The following authors have no financial disclosures: Thomas J. van Rijssen, Elon H.C. van Dijk, Paula Scholz, Myrte B. Breukink, Greet Dijkman, Petrus J.H. Peters, Roula Tsonaka, Robert E. MacLaren, Susan M. Downes, Sascha Fauser, Camiel J.F. Boon, and Carel B. Hoyng. All authors attest that they meet the current ICMJE criteria for authorship.

---

## REFERENCES

1. Wong KH, Lau KP, Chhablani J, et al. Central serous chorioretinopathy: what we have learnt so far. *Acta Ophthalmol* 2016; 94:321–325.
2. Daruich A, Matet A, Dirani A, et al. Central serous chorioretinopathy: recent findings and new physiopathology hypothesis. *Prog Retin Eye Res* 2015;48:82–118.
3. Bousquet E, Dhundass M, Lehmann M, et al. Shift work: a risk factor for central serous chorioretinopathy. *Am J Ophthalmol* 2016;165:23–28.
4. Carvalho-Recchia CA, Yannuzzi LA, Negrao S, et al. Corticosteroids and central serous chorioretinopathy. *Ophthalmology* 2002;109:1834–1837.
5. Haimovici R, Koh S, Gagnon DR, Lehrfeld T, Wellik S. Risk factors for central serous chorioretinopathy:

- a case-control study. *Ophthalmology* 2004;111:244–249.
6. Yannuzzi LA, Shakin JL, Fisher YL, Altomonte MA. Peripheral retinal detachments and retinal pigment epithelial atrophic tracts secondary to central serous pigment epitheliopathy. *Ophthalmology* 1984;91:1554–1572.
  7. Breukink MB, Dingemans AJ, den Hollander AI, et al. Chronic central serous chorioretinopathy: long-term follow-up and vision-related quality of life. *Clin Ophthalmol* 2017;11:39–46.
  8. Mohabati D, van Rijssen TJ, van Dijk EH, et al. Clinical characteristics and long-term visual outcome of severe phenotypes of chronic central serous chorioretinopathy. *Clin Ophthalmol* 2018;12:1061–1070.
  9. Mrejen S, Balaratnasingam C, Kaden TR, et al. Long-term visual outcomes and causes of vision loss in chronic central serous chorioretinopathy. *Ophthalmology* 2019;126:576–588.
  10. van Rijssen TJ, van Dijk EHC, Yzer S, et al. Central serous chorioretinopathy: towards an evidence-based treatment guideline. *Prog Retin Eye Res* 2019;73:100770.
  11. Chan WM, Lam DS, Lai TY, et al. Choroidal vascular remodelling in central serous chorioretinopathy after indocyanine green guided photodynamic therapy with verteporfin: a novel treatment at the primary disease level. *Br J Ophthalmol* 2003;87:1453–1458.
  12. Schlotzer-Schrehardt U, Viestenz A, Naumann GO, et al. Dose-related structural effects of photodynamic therapy on choroidal and retinal structures of human eyes. *Graefes Arch Clin Exp Ophthalmol* 2002;240:748–757.
  13. Yu AK, Merrill KD, Truong SN, et al. The comparative histologic effects of subthreshold 532- and 810-nm diode micropulse laser on the retina. *Invest Ophthalmol Vis Sci* 2013;54:2216–2224.
  14. van Dijk EHC, Fauser S, Breukink MB, et al. Half-dose photodynamic therapy versus high-density subthreshold micropulse laser treatment in patients with chronic central serous chorioretinopathy: the PLACE trial. *Ophthalmology* 2018;125:1547–1555.
  15. Breukink MB, Downes SM, Querques G, et al. Comparing half-dose photodynamic therapy with high-density subthreshold micropulse laser treatment in patients with chronic central serous chorioretinopathy (the PLACE trial): study protocol for a randomized controlled trial. *Trials* 2015;16:419.
  16. Loo RH, Scott IU, Flynn HW Jr, et al. Factors associated with reduced visual acuity during long-term follow-up of patients with idiopathic central serous chorioretinopathy. *Retina* 2002;22:19–24.
  17. Haga F, Maruko R, Sato C, et al. Long-term prognostic factors of chronic central serous chorioretinopathy after half-dose photodynamic therapy: a 3-year follow-up study. *PLoS One* 2017;12:e0181479.
  18. van Rijssen TJ, Mohabati D, Dijkman G, et al. Correlation between redefined optical coherence tomography parameters and best-corrected visual acuity in non-resolving central serous chorioretinopathy treated with half-dose photodynamic therapy. *PLoS One* 2018;13:e0202549.
  19. Yannuzzi LA, Slakter JS, Gross NE, et al. Indocyanine green angiography-guided photodynamic therapy for treatment of chronic central serous chorioretinopathy: a pilot study. *Retina* 2003;23:288–298.
  20. Mangione CM, Lee PP, Gutierrez PR, et al. Development of the 25-item National Eye Institute Visual Function Questionnaire. *Arch Ophthalmol* 2001;119:1050–1058.
  21. Ehrlich R, Mawer NP, Mody CH, Brand CS, Squirrell D. Visual function following photodynamic therapy for central serous chorioretinopathy: a comparison of automated macular microperimetry versus best-corrected visual acuity. *Clin Exp Ophthalmol* 2012;40:e32–e39.
  22. Toonen F, Remky A, Janssen V, Wolf S, Reim M. Microperimetry in patients with central serous retinopathy. *Ger J Ophthalmol* 1995;4:311–314.
  23. Schmidt-Erfurth U, Hasan T. Mechanisms of action of photodynamic therapy with verteporfin for the treatment of age-related macular degeneration. *Surv Ophthalmol* 2000;45:195–214.
  24. Maruko I, Iida T, Sugano Y, et al. Subfoveal choroidal thickness after treatment of central serous chorioretinopathy. *Ophthalmology* 2010;117:1792–1799.
  25. van Rijssen TJ, van Dijk EHC, Dijkman G, Boon CJF. Clinical characteristics of chronic central serous chorioretinopathy patients with insufficient response to reduced-settings photodynamic therapy. *Graefes Arch Clin Exp Ophthalmol* 2018;256:1395–1402.
  26. Pollack JS, Kim JE, Pulido JS, Burke JM. Tissue effects of subclinical diode laser treatment of the retina. *Arch Ophthalmol* 1998;116:1633–1639.
  27. Wang MS, Sander B, Larsen M. Retinal atrophy in idiopathic central serous chorioretinopathy. *Am J Ophthalmol* 2002;133:787–793.
  28. Breukink MB, Mohr JK, Ossewaarde-van Norel A, et al. Half-dose photodynamic therapy followed by diode micropulse laser therapy as treatment for chronic central serous chorioretinopathy: evaluation of a prospective treatment protocol. *Acta Ophthalmol* 2016;94:187–197.
  29. Scholz P, Ersoy L, Boon CJ, Fauser S. Subthreshold micropulse laser (577 nm) treatment in chronic central serous chorioretinopathy. *Ophthalmologica* 2015;234:189–194.
  30. Malik KJ, Sampat KM, Mansouri A, Steiner JN, Glaser BM. Low-intensity/high-density subthreshold micropulse diode laser for chronic central serous chorioretinopathy. *Retina* 2015;35:532–536.
  31. Kretz FT, Beger I, Koch F, et al. Randomized clinical trial to compare micropulse photocoagulation versus half-dose verteporfin photodynamic therapy in the treatment of central serous chorioretinopathy. *Ophthalmic Surg Lasers Imaging Retina* 2015;46:837–843.
  32. Chen SN, Hwang JF, Tseng LF, Lin CJ. Subthreshold diode micropulse photocoagulation for the treatment of chronic central serous chorioretinopathy with juxtafoveal leakage. *Ophthalmology* 2008;115:2229–2234.
  33. van Rijssen TJ, van Dijk EHC, Scholz P, et al. Focal and diffuse chronic central serous chorioretinopathy treated with half-dose photodynamic therapy or subthreshold micropulse laser: PLACE trial report no. 3. *Am J Ophthalmol* 2019;205:1–10.
  34. van Rijssen TJ, van Dijk EHC, Scholz P, et al. Patient characteristics of untreated chronic central serous chorioretinopathy patients with focal versus diffuse leakage. *Graefes Arch Clin Exp Ophthalmol* 2019;257:1419–1425.
  35. Mohabati D, van Dijk EH, van Rijssen TJ, et al. Clinical spectrum of severe chronic central serous chorioretinopathy and outcome of photodynamic therapy. *Clin Ophthalmol* 2018;12:2167–2176.