



Universiteit  
Leiden  
The Netherlands

## **Retinal oximetry is altered in eyes with choroidal melanoma but not in eyes with choroidal nevi**

Brouwer, N.J.; Marinkovic, M.; Bleeker, J.C.; Filali, M. el; Stefansson, E.; Luyten, G.P.M.; Jager, M.J.

### **Citation**

Brouwer, N. J., Marinkovic, M., Bleeker, J. C., Filali, M. el, Stefansson, E., Luyten, G. P. M., & Jager, M. J. (2020). Retinal oximetry is altered in eyes with choroidal melanoma but not in eyes with choroidal nevi. *Retina, The Journal Of Retinal And Vitreous Diseases*, 40(11), 2207-2215. doi:10.1097/IAE.0000000000002719

Version: Publisher's Version

License: [Creative Commons CC BY-NC-ND 4.0 license](https://creativecommons.org/licenses/by-nc-nd/4.0/)

Downloaded from: <https://hdl.handle.net/1887/3182828>

**Note:** To cite this publication please use the final published version (if applicable).

# RETINAL OXIMETRY IS ALTERED IN EYES WITH CHOROIDAL MELANOMA BUT NOT IN EYES WITH CHOROIDAL NEVI

NIELS J. BROUWER, MD,\* MARINA MARINKOVIC, MD,\* JACO C. BLEEKER, MD,\* MARIAM EL FILALI, MD,† EINAR STEFANSSON, MD,‡ GREGORIUS P. M. LUYTEN, MD,\* MARTINE J. JAGER, MD\*

---

**Purpose:** To compare retinal vessel oxygenation in eyes with an untreated choroidal nevus or choroidal melanoma.

**Methods:** The affected and fellow eye of patients with an untreated choroidal nevus ( $n = 42$ ) or choroidal melanoma ( $n = 45$ ) were investigated using noninvasive retinal oximetry (Oxymap T1). Oxygen saturation of arterioles (ArtSat) and venules (VenSat) was determined, together with the arteriovenous difference (AV-difference).

**Results:** In choroidal nevus patients, retinal oximetry did not differ between the affected and fellow eye: the mean ArtSat was 94.5% and 94.2% ( $P = 0.56$ ), the VenSat was 60.5% and 61.3% ( $P = 0.35$ ), and the AV-difference was 34.0% and 32.9% ( $P = 0.18$ ), respectively. In choroidal melanoma patients, alterations were detected: the mean ArtSat was 94.8% and 93.2% ( $P = 0.006$ ), the VenSat was 58.0% and 60.0% ( $P = 0.014$ ), and the AV-difference was 36.8% and 33.2% ( $P < 0.001$ ), respectively. The largest increase in AV-difference was observed between the retinal halves without the lesion in melanoma eyes compared with the corresponding half in the fellow eye (37.5% vs. 32.1%,  $P < 0.001$ ).

**Conclusion:** Although retinal oximetry was not significantly altered in eyes with a choroidal nevus, eyes with choroidal melanoma showed an increased ArtSat and decreased VenSat, leading to an increased AV-difference. These changes may be caused by inflammation and a higher metabolism, with larger oxygen consumption, leading to altered blood flow and intraocular oxygen relocation.

RETINA 40:2207–2215, 2020

---

Although both arise from ocular melanocytes, a choroidal nevus (CN) is a benign ocular tumor, whereas a choroidal melanoma (CM) is a malignancy. A choroidal nevus is rather common, with a prevalence of 4.7 per 100 in the United States<sup>1</sup> and up to 6.5 per 100 in Australia.<sup>2</sup> Choroidal melanoma is more rare, with an incidence of 4.3 per million,<sup>3</sup> but forms the majority (>70%) of all ocular melanoma.<sup>3</sup> Both lesions occur more often in Caucasians and are associated with a phenotype of light skin and light eye color. Choroidal nevi are generally without symptoms and can remain untreated, although occasionally (in about 1%) treatments, including laser treatment or anti-vascular endothelial growth factor injections, are necessary to treat subretinal fluid or choroidal neovascular membranes.<sup>4</sup> Typical symptoms of CM are flashes, floaters, and a decrease in visual acuity or visual field defects. Despite treatment, including proton beam irradiation, brachytherapy, or enucleation, up to 50% of CM patients will die from metastases.<sup>5</sup>

In the development of CM, angiogenesis is an important parameter because growing tumors require new vessels to satisfy their demand to obtain oxygen and nutrients. An increased (histological) microvascular density of the tumor was found to relate to a worse prognosis in choroidal and ciliary body melanoma<sup>6,7</sup> and has been associated with the presence of monosomy 3, which is a major risk factor for metastasis formation.<sup>8</sup>

Vascular changes are not restricted to the tumor tissue in CM. Using modern optical coherence tomography angiography (OCTA) technology, retinal changes were identified in eyes with untreated CM. These changes include enlargement of the deep foveal avascular zone and a decrease of the capillary vascular density, suggesting tumor-related parafoveal microvascular ischemia.<sup>9</sup> These retinal changes were not observed in a study on eyes containing a CN.<sup>10</sup>

A new technique to study retinal disease is through analysis of retinal vessel oxygenation by

noninvasive retinal oximetry.<sup>11</sup> Vessel oximetry provides information on the oxygen levels in arteries and veins and the difference between them. A recent review describes findings in various (retinal) disorders, including diabetic retinopathy and central retinal vein occlusion.<sup>12</sup> After treatment for CM, altered levels of retinal arterial and venous oxygenation were detected in patients with radiation retinopathy.<sup>13</sup> No pretreatment values were determined however, although such information might help to understand why some eyes develop radiation retinopathy and others do not. To the best of our knowledge, no studies on retinal oximetry in untreated melanoma or nevus eyes have as yet been reported.

In this study, retinal oxygenation was investigated in eyes with untreated CM or choroidal nevi. The aim was to identify whether the presence of a benign or malignant choroidal tumor affects the retinal vessels and, if so, to elucidate the mechanisms responsible. We hypothesized that eyes with CM show increased oxygen consumption compared with nondiseased eyes due to the tumor's metabolism, with a lesser effect in eyes with choroidal nevi.

## Methods

### Study Population

Patients with an untreated CM or CN were included in this study at the Leiden University Medical Center (Leiden, the Netherlands), between September 2017 and May 2018. Patients were examined by an experienced oncologic ophthalmologist, using clinical

---

From the \*Department of Ophthalmology, Leiden University Medical Center, Leiden, The Netherlands; †Department of Ophthalmology, Reinier de Graaf Gasthuis, Delft, The Netherlands; and ‡Department of Ophthalmology, Landspítali University Hospital, University of Iceland, Reykjavik, Iceland.

N. J. Brouwer is the recipient of a MD/PhD programme grant of the Leiden University Medical Center. Financial support for acquisition of the Oxymap T1 Device was provided by Mr. O. Roell and the Stichting Nederlands Oogheelkundig Onderzoek (SNOO). The sponsors had no role in the design or conduct of the study.

E. Stefansson is patent holder and shareholder in Oxymap ehf (Reykjavic, Iceland), which produces retinal oximeters. The remaining authors have no conflicting interests to disclose.

Supplemental digital content is available for this article. Direct URL citations appear in the printed text and are provided in the HTML and PDF versions of this article on the journal's Web site ([www.retinajournal.com](http://www.retinajournal.com)).

This is an open-access article distributed under the terms of the Creative Commons Attribution-Non Commercial-No Derivatives License 4.0 (CCBY-NC-ND), where it is permissible to download and share the work provided it is properly cited. The work cannot be changed in any way or used commercially without permission from the journal.

Reprint requests: Martine J. Jager, MD, Department of Ophthalmology, Leiden University Medical Center, P.O. Box 9600, 2300 RC Leiden The Netherlands; e-mail: [m.j.jager@lumc.nl](mailto:m.j.jager@lumc.nl)

examination, ultrasound investigation, and commonly fluorescein angiography.

Patients had to be 18 years or older at the moment of inclusion. Exclusion criteria were as follows: a melanoma or nevus in the fellow eye, previous removal (enucleation or exenteration) of the fellow eye, retinal disease in any eye (including age-related macular degeneration, central retinal vein occlusion, branch retinal vein occlusion, and diabetic retinopathy), previous ocular treatment with anti-vascular endothelial growth factor medication in either eye, severe cataract, other opacities, or patient-related factors limiting the investigation. The study was approved by the Institutional Medical Ethics Committee of the LUMC (approval P17.134) and adhered to the tenets of the Declaration of Helsinki. Written informed consent was obtained from all participants.

### Clinical Examination

Lesion size was evaluated using ultrasound and color fundus photography. Thickness measurements included the sclera. Flat lesions with no measurable thickness on ultrasound were assigned a default thickness of 1.50 mm for the purpose of analysis. The location of lesions was scored as "central" if the lesion was fully between the arcades (or extended to the area between the arcades), as "arcades" if it was not central but touching the arcades or optic disc, or as "peripheral" if it was fully outside of the arcades and not touching the optic disc. Visual acuity was measured with Snellen charts. All ocular symptoms were recorded, including (but not limited to) decrease of visual acuity, flashes, floaters, pain, redness of the eye, or metamorphopsia. Both the affected (melanoma or nevus containing) and fellow eye were investigated. Pupils were dilated for clinical examination with eye drops of tropicamide 0.5% and phenylephrine 5%. Melanomas were staged according to the eighth edition of the AJCC TNM classification.<sup>14</sup>

The presence of risk factors for growth of choroidal nevi was determined. These are a thickness of >2 mm, subretinal fluid, clinical symptoms, orange pigment, a margin within 3 mm of the optic disc, absence of halo, absence of drusen, and ultrasound hollowness.<sup>15</sup>

### Retinal Oximetry

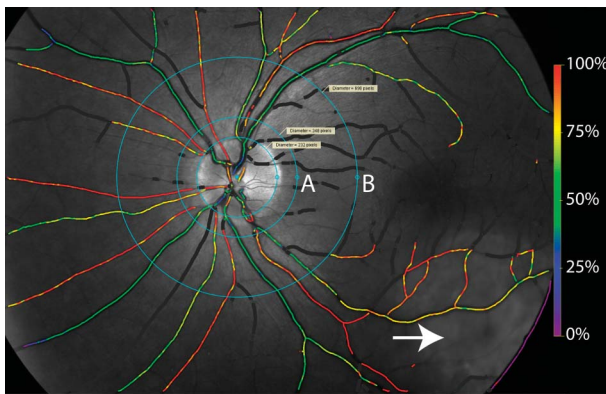
Retinal oximetry was performed with the Oxymap T1 device (Oxymap, ehf., Reykjavik, Iceland). This non-invasive retinal oximeter is composed of two digital cameras, mounted on a fundus camera. The device simultaneously takes two fundus images with different wavelengths of light, at 570 nm and 600 nm. Specialized software automatically selects measurement points on the images and calculates the so-called "optical density." The optical density of hemoglobin is sensitive to

oxygenation at 600 nm but not at 570 nm; the ratio of the optical densities has a relationship to oxygen saturation. A pseudo color fundus map is automatically generated. The reliability and reproducibility of the Oxymap technique have been demonstrated before.<sup>11</sup>

Images were analyzed with the Oxymap Analyzer software version 2.5.2. An adapted version of the protocol by Geirsdottir et al<sup>16</sup> was used to select vessel segments. In short, a retinal image centered on the optic disc was used for analysis (Figure 1). Oxygen saturation was determined by the software in all retinal vessels in the area between two concentric circles of 1.5 and 3 optic disc diameters around the optic disc. Vessel segments were manually selected with a width of at least eight pixels (approx. 74  $\mu\text{m}$ ) and a length of at least 50 pixels. Vessel crossings or areas with extremes in background brightness (due to e.g., undetected nearby vessels, scars, or hemorrhages) were excluded from the analysis.

The mean width of selected arterial and venous vessel segments was reported (1 pixel corresponds to approx. 9  $\mu\text{m}$ ). The Oxymap Analyzer software provided an overall image quality score (0 low, 10 high) based on focus and contrast.

The overall retinal saturation of arteries (ArtSat), venules (VenSat), and the difference between these (AV-difference) was calculated. The affected eye was compared with the fellow eye of the same individual; the difference between two AV-differences was termed “relative AV-difference” (Rel-AVdiff). A secondary analysis was performed on the saturation of the vessels in the retinal half overlying or not overlying the lesion (Figure 2).



**Fig. 1.** Pseudo color fundus map of a CM eye. The image is centered on the optic disc. In this specific case the CM is visible at the lower right (arrow). The Oxymap software automatically calculates vessel saturation and produces a color map (values correspond to the scale bar on the right side, ranging from 0% [purple] to 100% [red]). Vessel segments between the concentric circles at 1.5 (A) and 3 (B) disc diameters are manually selected for analysis. Vessels that are dark gray on the color map were too thin to acquire reliable measurements and are not included in the analysis.

## Statistics

Nominal data were analyzed with the chi-square test or Fisher exact test. Continuous data were analyzed with the independent *t*-test, paired *t*-test, or Kruskal–Wallis test, as appropriate. Linear univariate regression analysis was performed, and hazard ratios with 95% confidence intervals were provided. Study data were analyzed with SPSS software version 23. *P* values < 0.05 were considered statistically significant.

## Results

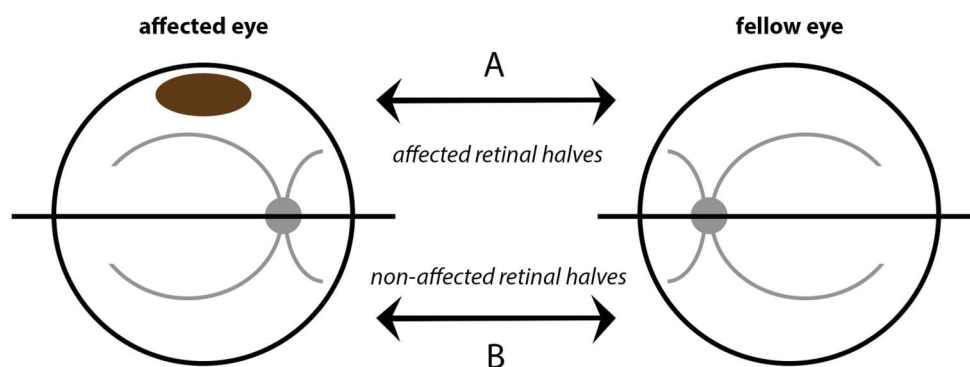
### Patient Characteristics

A total of 45 patients with CM and 42 patients with CN were included. The mean age of the CM patients was 65.5 years, and this was 66.0 years for the patients with CN (*P* = 0.85). The melanomas had a mean thickness of 4.0 mm and a mean largest basal diameter (LBD) of 11.9 mm; the nevi had a mean thickness of 1.8 mm (*P* < 0.001) and a mean LBD of 6.4 mm (*P* < 0.001). Choroidal melanoma lesions were staged T1 (14 cases, 31%), T2 (21 cases, 47%), T3 (7 cases, 16%), or T4 (3 cases, 7%). The general medical history showed that 18 (40%) of the CM patients had a cardiovascular disease (including diabetes, hypertension, hypercholesterolemia, and atrial fibrillation) as did 18 (43%) of the CN patients (*P* = 0.79). Of the CM patients, 9 (20%) had mild cataract in both eyes, versus 11 (26%) of CN patients (*P* = 0.49). None of the studied patients had marked exudative retinal detachment. The mean visual acuity of CM patients was 0.89 (20/22) for the affected eye and 1.09 (20/18) for the fellow eye (*P* = 0.001). For CN patients, this was 1.06 (20/19) and 1.08 (20/19), respectively (*P* = 0.58). Table 1 shows the characteristics of the CM and CN patients.

### Retinal Oximetry

We compared oximetry values between melanoma- or nevus-containing eyes with their fellow eyes. In CM patients, a difference was noticed between the affected and fellow eye: the overall ArtSat of the affected versus fellow eye was 94.8% versus 93.2% (*P* = 0.006), the overall VenSat was 58.0% versus 60.0% (*P* = 0.014), and the AV-difference was 36.8% versus 33.2% (*P* < 0.001). In CN patients, the affected and fellow eye did not differ significantly: The overall ArtSat of the affected versus fellow eye was 94.5% versus 94.2% (*P* = 0.57), the overall VenSat was 60.5% versus 61.3% (*P* = 0.35), and the AV-difference was 34.0% versus 32.9% (*P* = 0.18) (Table 2).

**Fig. 2.** Comparison of retinal halves. In eyes with a CM or nevus, one retinal half can be defined containing the lesion (“affected halves”) and one retinal half without the lesion (“nonaffected halves”). These halves were compared with the corresponding halves in the fellow eye (visualized by “A” and “B”). Retinal halves were divided by a horizontal or vertical line, seen from the optic disc, fitting the most appropriate division according to the location of the melanoma or nevus.



When we compared affected CM eyes to affected CN eyes, the AV-difference was found to be significantly higher in melanoma-containing eyes (36.8% for CM and 34.0% for CN,  $P = 0.04$ ), although the separate ArtSat ( $P = 0.77$ ) or VenSat ( $P = 0.14$ ) did not differ significantly.

Venous vessel segments of affected CM eyes were thicker compared with their fellow eyes (15.5 pixels vs. 14.9 pixels,  $P = 0.019$ ), whereas venous segments of the affected CN eyes were equally thick compared with their fellow eyes (15.3 pixels vs. 15.3 pixels,  $P = 0.83$ ). There were no significant differences in image

Table 1. Baseline Characteristics of Patients With a Choroidal Melanoma or Nevus

	Melanoma Patients	Nevus Patients	<i>P</i>
	Cases (%)	Cases (%)	
Total	45 (100)	42 (100)	
Sex			
Male	27 (60)	14 (33)	0.013*
Female	18 (40)	28 (67)	
Age			
Mean ± SD	65.5 ± 14.2	66.0 ± 10.6	0.85†
Side			
OD	19 (42)	23 (55)	0.24*
OS	26 (58)	19 (45)	
Location			
Central	9 (20)	8 (19)	0.26‡
Arcade	12 (27)	18 (43)	
Peripheral	24 (53)	16 (38)	
Thickness			
Mean ± SD	4.0 ± 1.6	1.8 ± 0.5	<0.001†
Largest basal diameter			
Mean ± SD	11.9 ± 3.1	6.4 ± 2.7	<0.001†
TNM, T group (8th)			
T1	14 (31)	N.A.	N.A.
T2	21 (47)		
T3	7 (16)		
T4	3 (7)		
COMS size			
Small	14 (31)	N.A.	N.A.
Medium	27 (60)		
Large	4 (9)		
Tumor pigmentation			
Pigmented	36 (80)	34 (81)	1.00*
Amelanotic/mixed	9 (20)	8 (19)	

\*Pearson chi-square test.

†Independent-samples *t*-test.

‡Fisher exact test.

TNM, AJCC TNM classification; N.A., not applicable.

Table 2. Outcome of Retinal Oximetry in Eyes With a Choroidal Melanoma or Nevus Versus the Contralateral Eyes

	Melanoma Patients (n = 45)			Nevus Patients (n = 42)		
	Affected Eye	Fellow Eye	P	Affected Eye	Fellow Eye	P
ArtSat (%)	94.8 ± 4.8	93.2 ± 4.9	0.006	94.5 ± 4.2	94.2 ± 3.6	0.56
VenSat (%)	58.0 ± 8.4	60.0 ± 9.3	0.014	60.5 ± 7.2	61.3 ± 6.7	0.35
AV-diff (%)	36.8 ± 6.3	33.2 ± 7.0	<0.001	34.0 ± 6.0	32.9 ± 5.5	0.18
Art. Diam. (pixels)*	12.0 ± 1.2	12.0 ± 1.0	0.98	12.1 ± 1.2	12.1 ± 1.1	0.80
Ven. Diam. (pixels)*	15.5 ± 1.6	14.9 ± 1.5	0.019	15.3 ± 1.5	15.3 ± 1.4	0.83
Image quality (score)†	7.6 ± 0.8	7.8 ± 0.8	0.19	7.9 ± 0.6	7.9 ± 0.6	0.87

Values are reported as mean ± SD.

All P values were obtained using the paired-samples t-test.

\*One pixel width corresponds to approx. 9 µm.

†Overall image quality as provided by the Oxymap Analyzer software (scale: 0 = low, 10 = high).

ArtSat, arterial saturation; VenSat, venous saturation; AV-diff, arteriovenous difference; Art. Diam., arterial diameter; Ven. Diam., venous diameter.

quality between affected and fellow eyes for both CM and CN patients (P = 0.19 and P = 0.87, respectively) (Table 2).

To determine whether the presence of a tumor affected the whole eye, we compared the affected and nonaffected retinal halves with their corresponding half in the fellow eye. A visual representation of these comparisons is provided in Figure 2. When we compared the affected retinal halves in CM patients with the corresponding halves in their fellow eye, a significant increase in ArtSat (94.9% vs. 93.1%, P = 0.027) was observed in the CM eye. There were no differences in VenSat or AV-difference (P = 0.92 and P = 0.096, respectively). A comparison of the nonaffected retinal halves in CM patients demonstrated a significant increase in ArtSat in the affected eye (94.5% vs. 93.0%, P = 0.02), with additionally a significant decrease in VenSat (57.0% vs. 60.8%, P = 0.001) and a significant increase in AV-difference

(37.5% vs. 32.1%, P < 0.001) In CN patients, no significant differences in ArtSat, VenSat, or AV-difference were detected between the affected and nonaffected retinal halves of affected and fellow eyes (Table 3).

We wondered whether patient- or tumor-related factors contributed to the observed oximetry values in CM and CN patients. We noticed that a correlation existed between the AV-differences of the affected and the fellow eye in both groups: The Pearson correlation for CM patients was 0.77 (P < 0.001) and for CN patients was 0.57 (P < 0.001). This implies that further analyses should be performed using the relative AV-difference, as this parameter indicates the difference between the two eyes in one individual and, therefore, yields the overall effect of the presence of either a CM or CN.

In CM patients, a significant relation was found between older age and a higher Rel-AVdiff (linear

Table 3. Outcomes of Retinal Oximetry per Retinal half

	Melanoma Patients (n = 45)			Nevus Patients (n = 42)		
	Affected Eye	Fellow Eye	P	Affected Eye	Fellow Eye	P
<b>(A) Comparison of affected retinal halves</b>						
ArtSat (%)	94.9 ± 5.8	93.1 ± 5.1	0.027	95.4 ± 6.0	93.9 ± 4.4	0.079
VenSat (%)	58.3 ± 9.7	58.4 ± 11.7	0.92	60.9 ± 8.4	60.4 ± 8.1	0.65
AV-diff (%)	36.6 ± 8.4	34.7 ± 9.2	0.096	34.5 ± 7.6	33.5 ± 6.6	0.41
<b>(B) Comparison of nonaffected retinal halves</b>						
ArtSat (%)	94.5 ± 5.3	93.0 ± 6.3	0.020	93.5 ± 4.1	94.3 ± 3.9	0.093
VenSat (%)	57.0 ± 9.6	60.8 ± 9.1	0.001	59.5 ± 8.2	61.4 ± 7.2	0.10
AV-diff (%)	37.5 ± 7.3	32.1 ± 7.7	<0.001	34.0 ± 6.8	32.9 ± 6.6	0.33

ArtSat, arterial saturation; VenSat, venous saturation; AV-diff, arteriovenous difference.

Values are reported as mean ± SD.

All P values were obtained using the paired-samples t-test.

Reported is the saturation of the affected versus similar retinal half in the fellow eye (A), and the saturation of the nonaffected versus similar half in the fellow eye (B). A schematic explanation of the comparisons is provided in Figure 2.

regression,  $B = 0.19$ , 95% CI 0.11–0.27,  $P < 0.001$ ). None of the other parameters (including tumor thickness and location of the lesion in relation to the macula, arcades, or periphery) was found to correlate significantly with the Rel-AVdiff (see **Table, Supplemental Digital Content 1**, <http://links.lww.com/IAE/B156>).

In CN patients, right eyes were related to a higher Rel-AVdiff ( $P = 0.002$ ), as was absence of ultrasound hollowness ( $P = 0.015$ ). None of the other parameters, including the presence of multiple risk factors for melanoma progression, was found to correlate significantly with the Rel-AVdiff (see **Table, Supplemental Digital Content 2**, <http://links.lww.com/IAE/B157>).

### Discussion

In this study, we compared retinal oximetry of eyes with untreated CM or choroidal nevi with their fellow eye. We identified alterations in ArtSat and VenSat with a higher AV-difference in eyes with CM, whereas this was not observed in eyes with CN. In CM patients, older age was related to a higher Rel-AVdiff, comparing affected and fellow eyes. As far as we know, these are new observations in CM, implicating that the presence of a melanoma is related to widespread retinal changes.

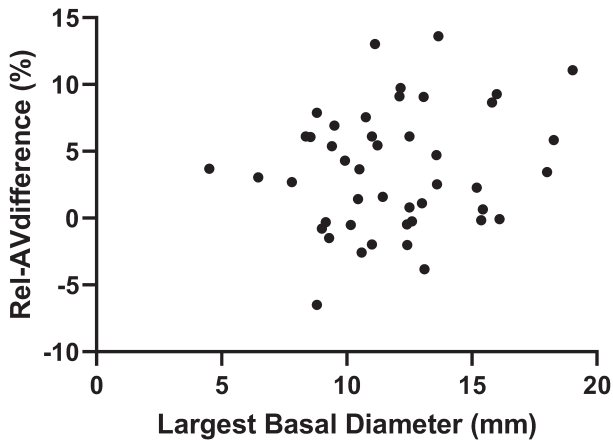
We hypothesize that multiple events contribute to the increased AV-difference in CM eyes. The increased oxygen demand of active tumor cells is the first step. Because CM is considered to be mainly fed by vessels from the choroid, this would imply a role in tumor nourishment for the retinal vasculature that was investigated in this study. Because there is interaction between the choroidal and retinal circulation<sup>17</sup> and oxygen can diffuse within these layers,<sup>18</sup> this can be plausible although it should be noted that we are unaware of studies that examined the retinal contribution to nourishment of choroidal lesions. There must be a second step, however, as regional differences in oxygenation also occurred in the nonmelanoma-containing part of the retina in CM eyes. This means that the presence of a tumor affects a large part of the eye. We did not observe a relation between oximetry values, obtained from vessels around the optic disc, and the location of the tumor as being central, near the arcades, or periphery. This contributes to the idea of a generalized involvement of the eye.

Central to overall retinal changes in CM eyes may be the presence of inflammation. Melanoma eyes contain higher concentrations of vascular endothelial growth factor-A in both the aqueous and vitreous fluid,<sup>19,20</sup> and several other inflammatory cytokines

and chemokines (including IL-6, IL-10, TNF- $\alpha$ ) were found to be elevated in the vitreous as well.<sup>21</sup> Supporting the relation between inflammation and retinal oximetry, aberrant retinal oximetry values were correlated with the presence of various inflammatory markers of the aqueous humor in patients with diabetic retinopathy.<sup>22</sup> In diabetic retinopathy, as well as other ischemic retinopathies, inflammation and angiogenesis are known to be linked.<sup>23,24</sup> The production of vascular endothelial growth factor-A in eyes with UM, as measured in aqueous humor, was positively related to UM tumor diameter and originated from both the tumor and overlying retinal tissue.<sup>19</sup> Because these cytokines reach other parts of the retina besides the tumor-overlying tissue, metabolic changes (which can be measured with the retinal oximetry) can be expected there as well.

An increased AV-difference of the nonaffected retinal halves in melanoma eyes may additionally be explained by oxygen relocation. Because the melanoma needs an increased amount of blood, a relative decrease in flow can be expected in the nonaffected retinal parts. A larger AV-difference would thereby reflect the increased extraction of oxygen from the reduced amount of available blood. This mechanism would be comparable to eyes with ischemic disease as central retinal vein occlusion, similarly detecting an increased overall AV-difference in the area with diminished flow.<sup>25</sup>

Another factor that may be of importance to the amount of oxygen in retinal vessels of melanoma eyes is the Warburg effect. This effect describes the phenomenon that cancer cells use anaerobic glycolysis for nourishment rather than aerobic pathways, despite the presence of oxygen.<sup>26</sup> This effect underlies modern-day positron emission tomography scans, using the enhanced glucose uptake to demonstrate the presence of malignancies. As mentioned before, there is interaction between the choroidal and retinal circulation,<sup>17,18</sup> although the magnitude of this interaction is not known for CM eyes. Implying a role for the Warburg effect in ocular melanoma, the relation between tumor presence and oxygen uptake may be complicated (as both an increased oxygen uptake due to tumor activity or a decreased oxygen uptake due to altered metabolism can be expected). This effect may explain the absence of a relation between tumor size and AV-difference in our study, as larger tumors would not necessarily require more oxygen (Figure 3). Even more, it may add to the mechanism of increased oxygen uptake in the nonaffected retinal half, as the affected retinal half demonstrates an aberrant metabolism relying more on glucose than on oxygen.



**Fig. 3.** Relative AV-difference versus largest basal tumor diameter in CM patients. The relative AV-difference (i.e., the AV-difference of the affected eye minus the AV-difference of the fellow eye) is plotted against the largest basal diameter of the tumor in CM patients. The correlation is not statistically significant, with a correlation coefficient of 0.180 ( $P = 0.24$ ). This implies that in our study, no relation exists between tumor size and the relative AV-difference.

Older age was related to a larger Rel-AVdiff in CM patients. This means that the effect of melanoma presence on retinal oximetry is larger in older patients than in younger patients. We hypothesize that increased vessel wall stiffness in older patients limits flow alterations to account for increased oxygen demand, resulting in a larger extraction of oxygen from the available blood. In addition, tumor infiltrate may be involved because murine experiments demonstrated a relationship between older age and an increase of macrophages<sup>27,28</sup>; which have been suggested to be relevant for differences in tumor angiogenesis.<sup>8,29</sup>

In this study, we detected retinal oxygen imaging changes in CM eyes but not in CN eyes. This is in line with findings using OCTA, demonstrating foveal changes in melanoma eyes but not in nevi.<sup>10</sup> Differences may be due to a lower metabolic activity in nevi and to less local inflammation. Also, because of slow growth and a longer presence, recovery mechanisms may be more pronounced in nevi eyes, limiting differences in oximetry. Lesion size may be relevant as well, as it may act as a barrier between the choroidal and retinal vasculature, and choroidal nevi are often smaller than melanoma. However, because lesion size did not relate to retinal oximetry within both the groups of melanoma or nevi in this study (Figure 3), this effect may be of limited concern.

Retinal oximetry has been described in many (ischemic) retinal diseases<sup>12,30</sup> but, as far as we know, not in untreated CM or nevi. In a small study of eight patients with radiation retinopathy after treatment for CM, a reduced blood flow with increased ArtSat and VenSat was identified in affected eyes.<sup>13</sup> No pretreat-

ment values were reported however. An interesting comparison can be made with studies on retinal vasculature in treatment-naïve melanoma and nevi using OCTA. It was found that the deep foveal avascular zone was larger in macular melanoma compared with healthy eyes. This was not the case for extramacular melanoma or nevi. Capillary vessel density was reduced in melanoma eyes but not in nevi eyes.<sup>10</sup> The authors hypothesized that parafoveal ischemia occurred due to tumor-related ischemia and intraocular leakage of cytokines. Our results on whole-eye involvement of saturation changes are in line with this finding, although we did not detect a difference between tumors located close to the macula and extramacular lesions. Another study detected higher ocular (choroidal) blood flow in eyes with uveal melanoma compared with the fellow eye, in line with the theory of increased demand due to the presence of a tumor.<sup>31</sup>

Our study is the first study to report on retinal oximetry in treatment-naïve melanoma and nevi. This provides baseline values for CM and CN, without the influence of earlier treatments. Because both eyes of each patient were examined in our study, a good comparison could be made, adjusting for patient-related parameters as systemic disease and age. Also, we could compare similar areas between the affected and fellow eyes, as it is known that oxygen levels are different for various areas of the retina, hampering comparisons within one eye.<sup>11</sup>

Because image quality and presence of comorbidity were similar between affected and fellow eyes, we feel that it is unlikely that our results are due to measurement artifacts. Even more, low image quality or presence of cataract would lead to lower values of saturation in both arteries and venules,<sup>32,33</sup> although we detected a higher ArtSat in melanoma eyes; an additional mechanism is therefore needed to explain our findings.

It could be hypothesized that co-occurring retinal detachment, a condition that might cause retinal non-perfusion, may influence the AV-difference in our study. None of the studied patients had marked exudative retinal detachment, however, so it is not expected that this has biased the conclusions. Even so, the presence of subretinal fluid (which was more prevalent in melanoma eyes) could be hypothesized to have influenced the results. To test this, we compared melanoma eyes without subretinal fluid ( $n = 19$ ) to nevi eyes with subretinal fluid ( $n = 3$ ), as this should force effects into opposite directions. We found that the AV-difference in melanoma eyes remained higher compared with nevi eyes (mean 37.3%, SD 4.9 vs. 35.8%, SD 6.8;  $P = 0.66$ ) although this was not statistically significant. However, the small number of nevi eyes hampers a statistical comparison. Although we observed that right eyes in

CN patients were related to a higher Rel-AVdiff, we believe that this was by chance only and not reflecting a relevant pathophysiological mechanism.

Currently, fluorescein angiography is a commonly used imaging technique to help differentiate CM from other lesions as hemangioma or nevi. This is an invasive technique, requiring the intravenous injection of a contrast agent. Although no pathognomonic pattern exists for CM, the characteristics include intrinsic circulation (due to abnormal vessels), hot spots (due to pinpoint leaks from the retinal pigment epithelium), and late leakage.<sup>34</sup> Our study identifies a new parameter that differs between CM and CN (i.e., increased oxygen use). Because the observed differences between eyes with CM and CN are small, this will currently not be of use as a diagnostic criterion, but it demonstrates that melanoma-related vascular alterations are present. An interesting future project would be to investigate whether retinal oximetry identifies patients with a higher risk of developing radiation retinopathy after radiation therapy, which could then have clinical implications to detect or follow selected patients, allowing for early treatment. Also, knowledge obtained by retinal oximetry may aid in the understanding of other imaging techniques, such as OCTA.

Concluding, our current study demonstrates that the presence of a CM influences the vessel oxygenation of the whole eye, which is probably due to an increased oxygen metabolism; this was not observed in eyes with CN. Future projects may test the value of oximetry in the identification and follow-up of patients with radiation retinopathy and may guide future studies into antiangiogenic therapies.

**Key words:** choroidal nevi, choroidal melanoma, oxygen metabolism, oxygen saturation, retinal oximetry.

### Acknowledgments

The authors thank Katinka Emmanouilidis-van der Spek and Wouter B.H.J. Vehmeijer (Leiden University Medical Center, the Netherlands) for their support with data acquisition and software analysis.

### References

1. Qiu M, Shields CL. Choroidal nevus in the United States adult population: racial disparities and associated factors in the national health and nutrition examination survey. *Ophthalmology* 2015;122:2071–2083.
2. Sumich P, Mitchell P, Wang JJ. Choroidal nevi in a white population: the blue mountains eye study. *Arch Ophthalmol* 1998;116:645–650.
3. McLaughlin CC, Wu XC, Jemal A, et al. Incidence of noncutaneous melanomas in the U.S. *Cancer* 2005;103:1000–1007.
4. Shields CL, Furuta M, Mashayekhi A, et al. Clinical spectrum of choroidal nevi based on age at presentation in 3422 consecutive eyes. *Ophthalmology* 2008;115:546–552 e542.
5. Damato B. Progress in the management of patients with uveal melanoma: the 2012 Ashton Lecture. *Eye (Lond)* 2012;26:1157–1172.
6. Makitie T, Summanen P, Tarkkanen A, Kivela T. Microvascular density in predicting survival of patients with choroidal and ciliary body melanoma. *Invest Ophthalmol Vis Sci* 1999;40:2471–2480.
7. Foss AJ, Alexander RA, Jefferies LW, et al. Microvessel count predicts survival in uveal melanoma. *Cancer Res* 1996;56:2900–2903.
8. Bronkhorst IH, Ly LV, Jordanova ES, et al. Detection of M2-macrophages in uveal melanoma and relation with survival. *Invest Ophthalmol Vis Sci* 2011;52:643–650.
9. Li Y, Say EA, Ferenczy S, et al. Altered parafoveal microvasculature in treatment-naïve choroidal melanoma eyes detected by optical coherence tomography angiography. *Retina* 2017;37:32–40.
10. Valverde-Megias A, Say EA, Ferenczy SR, Shields CL. Differential macular features on optical coherence tomography angiography in eyes with choroidal nevus and melanoma. *Retina* 2017;37:731–740.
11. Pálsson O, Geirsdóttir A, Hardarson SH, et al. Retinal oximetry images must be standardized: a methodological analysis. *Invest Ophthalmol Vis Sci* 2012;53:1729–1733.
12. Stefánsson E, Ólafsdóttir OB, Einarsdóttir AB, et al. Retinal oximetry discovers novel biomarkers in retinal and brain diseases. *Invest Ophthalmol Vis Sci* 2017;58: BIO227–BIO233.
13. Rose K, Krema H, Durairaj P, et al. Retinal perfusion changes in radiation retinopathy. *Acta Ophthalmol* 2018;96:e727–e731.
14. Kivela T, Simpson ER, Grossniklaus HE, et al. Uveal melanoma. In: Amin MB, Edge S, Green F, eds. *AJCC Cancer Staging Manual*, 8th ed. New York, NY: Springer, 2017:805–817.
15. Shields CL, Furuta M, Berman EL, et al. Choroidal nevus transformation into melanoma: analysis of 2514 consecutive cases. *Arch Ophthalmol* 2009;127:981–987.
16. Geirsdóttir A, Pálsson O, Hardarson SH, et al. Retinal vessel oxygen saturation in healthy individuals. *Invest Ophthalmol Vis Sci* 2012;53:5433–5442.
17. Yu PK, McAllister IL, Morgan WH, et al. Inter-relationship of arterial supply to human retina, choroid, and optic nerve head using micro perfusion and labeling. *Invest Ophthalmol Vis Sci* 2017;58:3565–3574.
18. Nickla DL, Wallman J. The multifunctional choroid. *Prog Retin Eye Res* 2010;29:144–168.
19. Missotten GS, Notting IC, Schlingemann RO, et al. Vascular endothelial growth factor a in eyes with uveal melanoma. *Arch Ophthalmol* 2006;124:1428–1434.
20. Boyd SR, Tan D, Bunce C, et al. Vascular endothelial growth factor is elevated in ocular fluids of eyes harbouring uveal melanoma: identification of a potential therapeutic window. *Br J Ophthalmol* 2002;86:448–452.
21. Nagarkatti-Gude N, Bronkhorst IH, van Duinen SG, et al. Cytokines and chemokines in the vitreous fluid of eyes with uveal melanoma. *Invest Ophthalmol Vis Sci* 2012;53:6748–6755.
22. Tayyari F, Khuu LA, Sivak JM, et al. Retinal blood oxygen saturation and aqueous humour biomarkers in early diabetic retinopathy. *Acta Ophthalmol* 2019;97:e673–e679.
23. Semeraro F, Cancarini A, dell’Omo R, et al. Diabetic retinopathy: vascular and inflammatory disease. *J Diabetes Res* 2015;2015:582060.

24. Rivera JC, Dabouz R, Noueihed B, et al. Ischemic retinopathies: oxidative stress and inflammation. *Oxid Med Cell Longev* 2017;2017:3940241.
25. Traustason S, la Cour M, Larsen M. Retinal vascular oximetry during ranibizumab treatment of central retinal vein occlusion. *Br J Ophthalmol* 2014;98:1208–1211.
26. Dell'Antone P. Energy metabolism in cancer cells: how to explain the Warburg and Crabtree effects? *Med Hypotheses* 2012;79:388–392.
27. Ashcroft GS, Horan MA, Ferguson MW. Aging is associated with reduced deposition of specific extracellular matrix components, an upregulation of angiogenesis, and an altered inflammatory response in a murine incisional wound healing model. *J Invest Dermatol* 1997;108:430–437.
28. Ly LV, Baghat A, Versluis M, et al. In aged mice, outgrowth of intraocular melanoma depends on proangiogenic M2-type macrophages. *J Immunol* 2010;185:3481–3488.
29. Jager MJ, Klaver CCW. Macrophages feel their age in macular degeneration. *J Clin Invest* 2007;117:3182–3184.
30. Rilven S, Torp TL, Grauslund J. Retinal oximetry in patients with ischaemic retinal diseases. *Acta Ophthalmol* 2017;95:119–127.
31. Yang YC, Kent D, Fenerty CH, et al. Pulsatile ocular blood flow in eyes with untreated choroidal melanoma. *Eye (Lond)* 1997;11:331–334.
32. Chen H, Lin H, Chen W, et al. Preoperative and postoperative measurements of retinal vessel oxygen saturation in patients with different grades of cataracts. *Acta Ophthalmol* 2017;95:e436–e442.
33. Hardarson SH, Jonsson BA, Karlsson RA, et al. Image quality affects measurements of retinal vessel oxygen saturation. *Invest Ophthalmol Vis Sci* 2015;56:3316.
34. Bakri SJ, Sculley L, Singh AD. Diagnostic techniques. In: Singh AD, Damato BE, Pe'er J, et al, eds. *Clinical Ophthalmic Oncology*. Edinburgh, United Kingdom: Elsevier-Saunders, 2007:175–180.