



Universiteit  
Leiden  
The Netherlands

## **Inverse correlation between serum complement component C1q levels and whole blood type-1 interferon signature in active tuberculosis and QuantiFERON-positive uveitis: implications for diagnosis**

Schrijver, B.; Dijkstra, D.J.; Borggreven, N.V.; Nora, R.L.; Huijser, E.; Versnel, M.A.; ... ; Dik, W.A.

### **Citation**



Schrijver, B., Dijkstra, D. J., Borggreven, N. V., Nora, R. L., Huijser, E., Versnel, M. A., ... Dik, W. A. (2020). Inverse correlation between serum complement component C1q levels and whole blood type-1 interferon signature in active tuberculosis and QuantiFERON-positive uveitis: implications for diagnosis. *Clinical & Translational Immunology*, 9(10). doi:10.1002/cti2.1196

Version: Publisher's Version  
License: [Creative Commons CC BY-NC-ND 4.0 license](https://creativecommons.org/licenses/by-nc-nd/4.0/)  
Downloaded from: <https://hdl.handle.net/1887/3182235>

**Note:** To cite this publication please use the final published version (if applicable).

## ORIGINAL ARTICLE

# Inverse correlation between serum complement component C1q levels and whole blood type-1 interferon signature in active tuberculosis and QuantiFERON-positive uveitis: implications for diagnosis

Benjamin Schrijver<sup>1†</sup> , Douwe J Dijkstra<sup>2†</sup>, Nicole V Borggrevén<sup>2</sup>, Rina La Distia Nora<sup>3</sup> , Erika Huijser<sup>4</sup>, Marjan A Versnel<sup>4</sup>, P Martin van Hagen<sup>1,5</sup>, Simone A Joosten<sup>6</sup>, Leendert A Trouw<sup>2</sup> & Willem A Dik<sup>1,5</sup>

<sup>1</sup>Department of Immunology, Laboratory Medical Immunology, Erasmus MC University Medical Center Rotterdam, Rotterdam, The Netherlands

<sup>2</sup>Department of Immunoematology and Blood Transfusion, Leiden University Medical Center, Leiden, The Netherlands

<sup>3</sup>Department of Ophthalmology, Faculty of Medicine, University of Indonesia and Cipto Mangunkusumo Hospital, Jakarta, Indonesia

<sup>4</sup>Department of Immunology, Erasmus MC University Medical Center Rotterdam, Rotterdam, The Netherlands

<sup>5</sup>Department of Internal Medicine, Division Clinical Immunology, Erasmus MC University Medical Center Rotterdam, Rotterdam, The Netherlands

<sup>6</sup>Department of Infectious Diseases, Leiden University Medical Center, Leiden, The Netherlands

## Correspondence

WA Dik, Department of Immunology,  
Laboratory Medical Immunology, Erasmus  
MC University Medical Center, PO Box 2040,  
3000 CA, Rotterdam, The Netherlands.  
E-mail: w.dik@erasmusmc.nl

<sup>†</sup>Shared first author.

Received 24 April 2020;

Revised 20 August and 25 September 2020;

Accepted 25 September 2020

doi: 10.1002/cti2.1196

*Clinical & Translational Immunology*  
2020; 9: e1196

## Abstract

**Objectives.** To examine the relation between serum C1q levels and blood type-1 interferon signature (type-1 IFN signature) in active pulmonary tuberculosis (APT<sub>B</sub>) and to determine whether combined measurement of serum C1q and type-1 IFN signature may add to the diagnosis of QuantiFERON-positive (QFT<sup>+</sup>) patients with uveitis of unknown cause. **Methods.** C1q was determined (ELISA) in serum from two distinct Indonesian cohorts, and in total, APT<sub>B</sub> ( $n = 72$ ), QFT<sup>+</sup> uveitis of unknown aetiology ( $n = 58$ ), QFT<sup>-</sup> uveitis ( $n = 51$ ) patients and healthy controls (HC;  $n = 73$ ) were included. The type-1 IFN signature scores were previously determined. **Results.** Serum C1q was higher in APT<sub>B</sub> than HC ( $P < 0.001$ ). APT<sub>B</sub> patients with uveitis had higher serum C1q than APT<sub>B</sub> patients without uveitis ( $P = 0.0207$ ). Serum C1q correlated inversely with type-1 IFN signature scores in APT<sub>B</sub> ( $P = 0.0036$ ,  $r^2 = 0.3526$ ), revealing that these biomarkers for active TB disease can be mutually exclusive. Stratification of QFT<sup>+</sup> patients with uveitis of unknown cause, by serum C1q and type-1 IFN signature, yielded four groups with different likelihood of suffering from active TB uveitis. **Conclusion.** Serum C1q is elevated in APT<sub>B</sub>, especially in those cases with uveitis. We propose that combined measurement of blood type-1 IFN signature and serum C1q may provide added value in the diagnosis of active TB disease. Combined measurement of type-1 IFN signature and serum C1q in QFT<sup>+</sup> patients without signs of active TB disease, but suffering from uveitis of unknown cause, may be of help to identify cases

with low or high likelihood of having active TB uveitis, which may facilitate clinical management decisions.

**Keywords:** C1q, complement, extrapulmonary tuberculosis, QuantiFERON, type-1 interferon signature, uveitis

## INTRODUCTION

Tuberculosis (TB) is an airborne infectious disease caused by *Mycobacterium tuberculosis* (*Mtb*) bacilli.<sup>1</sup> To date, TB remains a major global health threat and leading cause of death from a single infectious agent. The World Health Organization (WHO) estimates that a quarter of the world's population is infected with *Mtb*. Most of these individuals remain asymptotically latently infected (LTBI), while ~5–10% develop clinically active TB disease during their lifetime.<sup>2</sup> The WHO estimated that ~10 million new TB cases emerged in 2018, with increasing TB notifications especially in India and Indonesia.<sup>2</sup>

Although primarily a pulmonary pathogen, *Mtb* can disseminate from the primary focus of infection throughout the body via blood and lymphatic system, infecting other organs, including the eyes.<sup>3</sup> Ocular involvement has a prevalence between ~1.5 and 18% in pulmonary TB patients, but may also occur without pulmonary involvement and/or other signs of TB.<sup>4–9</sup> Timely diagnosis of active TB infection is crucial as it contributes to swift treatment initiation and thereby pathogen eradication, minimising disease burden and curtailing *Mtb* transmission.<sup>2</sup>

Sputum smear microscopy and culture-based methods are the standard diagnostic laboratory tests for active TB, but PCR-based techniques are also used to directly identify the pathogen.<sup>10–12</sup> All these tests are hampered by sensitivity and/or specificity issues and are often time consuming. Initiation of an adaptive immune response after *Mtb* exposure usually results in memory T-helper (Th)1-cell formation. These Th1 cells become activated upon re-exposure to *Mtb* antigens, which is typically exploited by *in vitro* interferon gamma (IFN- $\gamma$ ) release assays (e.g. QuantiFERON-TB Gold test; QFT) or tuberculin skin test (TST). Although these tests provide evidence of existing immunological memory towards *Mtb*, by no means do they discriminate between active TB disease and LTBI. The diagnosis of ocular TB is especially difficult to achieve because access to intraocular tissues is

limited. Moreover, only a few *Mtb* bacilli may invade the intraocular environment, where they especially infect the retinal pigment epithelium (RPE).<sup>13–15</sup> Yet, rapid initiation of anti-tuberculosis treatment (ATT) in TB-associated uveitis is important as substantial vision loss, or even blindness, can occur if left untreated.<sup>16,17</sup> Especially in high TB-endemic areas, the association between QFT positivity and uveitis might be coincidental. Therefore, it is important to identify those QFT+ uveitis patients suffering from active TB disease, especially when there are no other signs of active TB infection. Consequently, QFT+ uveitis patients with LTBI could be prevented from undergoing overzealous ATT treatment. Altogether, this indicates the urgent need for biomarkers that discriminate active TB from LTBI, especially in those areas where TB is highly endemic.

Several reports have indicated that patients suffering from active TB disease display a peripheral blood transcriptome that is highly enriched for type-1 IFN-stimulated genes (ISGs).<sup>18–21</sup> In line with this, we recently reported a whole blood transcriptional signature of 10 ISGs (type-1 IFN signature) that was associated with active pulmonary TB (APT) in Indonesian patients. In addition, we demonstrated that this type-1 IFN signature stratified QFT+ patients with uveitis of undetermined cause into distinct groups. We proposed that type-1 IFN signature-positive patients were more likely to suffer from active TB-associated uveitis.<sup>22</sup> Furthermore, increased expression of mRNA for complement component C1q has been described in peripheral blood cells from active TB patients.<sup>23–25</sup> More recently, Lubbers *et al.* reported elevated serum C1q levels in APTB as compared to LTBI, healthy controls, and disease controls.<sup>23</sup> Consequently, serum C1q was proposed as biomarker to detect active TB disease.<sup>23</sup> However, Lubbers *et al.* did not explore serum C1q levels in relation to TB-associated uveitis. Also, no correlations with peripheral blood type-1 IFN signatures were determined. However, the latter is of special interest as C1q has been shown to attenuate IFN- $\alpha$  production by peripheral blood mononuclear cells.<sup>26,27</sup>

Therefore, in our current study, we examined the following: (1) serum C1q levels in two independently collected cohorts of Indonesian patients with APTB and healthy controls, (2) the correlation between serum C1q levels and the type-1 IFN signature score in active TB and systemic autoimmune diseases [primary Sjögren’s syndrome (pSS), systemic lupus erythematosus (SLE) and systemic sclerosis (SSc)], and (3) whether the combination of serum C1q level and peripheral blood type-1 IFN signature may improve stratification of QFT+ patients with uveitis of unknown cause, into groups highly likely, or less likely, to suffer from active TB-associated uveitis.

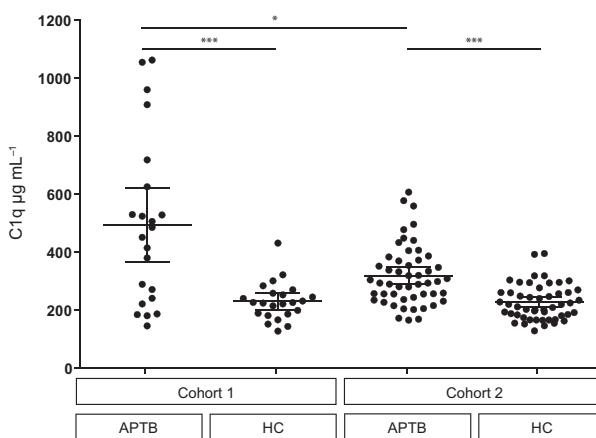
## RESULTS

### Increased serum C1q levels in active pulmonary TB patients

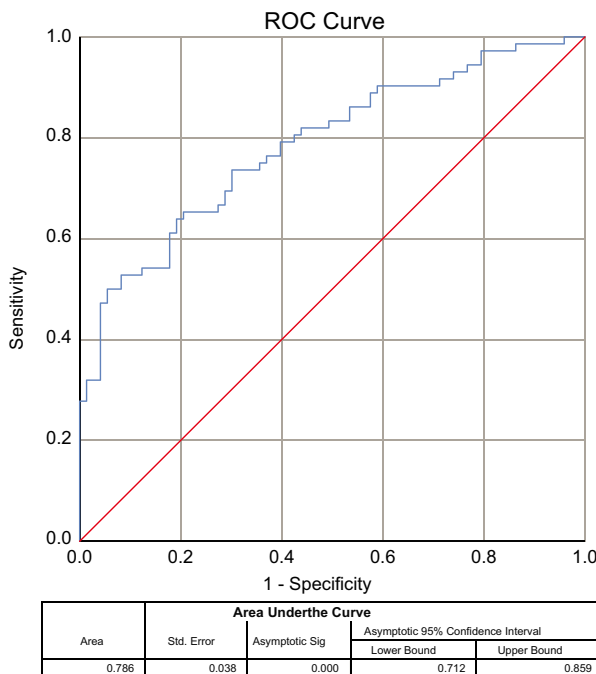
In both independently collected Indonesian cohorts, serum C1q levels were significantly increased in APTB patients ( $P < 0.001$ ) as compared to healthy controls (Figure 1). Furthermore, serum C1q levels were significantly increased in APTB patients from cohort 1 ( $P = 0.0305$ ) as compared to cohort 2, while no statistically significant difference in serum C1q level was observed between the healthy control groups (Figure 1). The capacity of serum C1q to discriminate APTB from healthy controls was analysed using receiver operating characteristic (ROC) curve analysis on all APTB cases ( $n = 72$ ) versus all healthy controls ( $n = 73$ ) and revealed an area under the curve of 0.786 ( $P < 0.001$ ; 95% CI 0.712–0.859; Figure 2). Diagnostic performance, as calculated by maximum Youden’s index, revealed a sensitivity of 65.3% and specificity of 79.5%, when a cut-off value for serum complement C1q of  $\geq 271.1 \mu\text{g mL}^{-1}$  was used (Supplementary table 2).

### Inverse correlation between serum C1q levels and peripheral blood type-1 IFN signature scores in active pulmonary TB patients

In APTB patients (cohort 1,  $n = 22$ ), serum C1q levels displayed a significant inverse correlation with the type-1 IFN signature scores ( $r^2 = 0.3526$ ;  $P = 0.0036$ , Figure 3a). Substantial subsets of patients with pSS, SLE and SSc also display a positive type-1 IFN signature.<sup>28–31</sup> Therefore, to



**Figure 1.** Increased serum C1q levels in active pulmonary tuberculosis (APTB). Comparison of serum C1q levels in APTB patients and healthy controls from Indonesian cohort 1 (left, APTB  $n = 22$ , healthy controls  $n = 23$ ) and Indonesian cohort 2 (right, APTB  $n = 50$ , healthy controls  $n = 50$ ). APTB, active pulmonary tuberculosis; HC, healthy control. Horizontal lines represent the group mean, and error bars indicate the 95% confidence interval (CI). Statistical analysis was performed on the transformed data set in GraphPad Prism 5.0, and Welch’s  $t$ -test was used to compare groups. \* $P < 0.05$ , \*\*\* $P < 0.001$ .



**Figure 2.** Receiver operating characteristics curve analysis of the ability of serum C1q to distinguish APTB patients (cohort 1 + 2;  $n = 72$ ) from healthy controls (cohort 1 + 2;  $n = 73$ ). Statistical analysis was performed on the transformed data set in SPSS 25.

determine whether the inverse correlation between serum C1q and peripheral blood type-1 IFN gene signature might be TB specific or

represents a more general phenomenon, we also determined the relation between serum C1q levels and peripheral blood type-1 IFN signature scores in pSS, SLE and SSc patients. Serum C1q did not show any correlation with the peripheral blood type-1 IFN signature scores in any of these systemic autoimmune diseases (Supplementary figure 1).

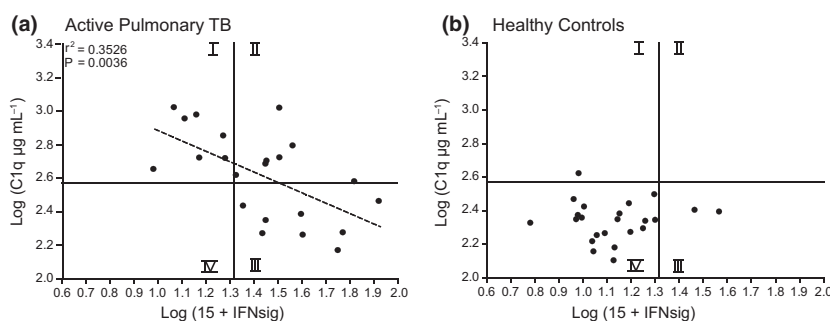
On the basis of all Indonesian healthy controls ( $n = 73$ , cohorts 1 and 2), the upper limit of the 95% reference range was used as a cut-off value for serum C1q levels. This yielded a cut-off value of 2.57 ( $\log(\text{C1q } \mu\text{g mL}^{-1})$ ), indicated by the horizontal line in Figure 3. We also applied a log transformation on the previously reported type-1 IFN signature score cut-off value for positivity,<sup>22</sup> yielding a value of 1.31, as indicated by the vertical line in Figure 3. This generated four quadrants based on serum C1q and type-1 IFN signature score. Most importantly, application of these quadrants clearly demonstrated that although both increased serum C1q level and a positive blood type-1 IFN signature have been suggested as potential biomarker for active TB, they can be mutually exclusive [Figure 3a: quadrants I (elevated serum C1q and negative type-1 IFN signature score) and III (normal serum C1q and positive type-1 IFN signature score)]. Twenty out of 23 (87%) healthy controls located to quadrant IV (normal serum C1q and negative type-1 IFN gene signature; Figure 3b), while none of the APTB cases located to this quadrant (Figure 3a).

### Increased serum C1q levels in QFT<sup>+</sup> patients with uveitis of unknown cause

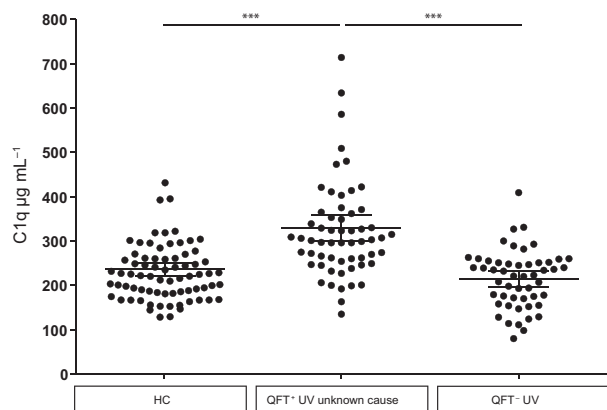
C1q levels were significantly elevated in serum from QFT<sup>+</sup> patients with uveitis of unknown aetiology ( $n = 58$ ) as compared to QFT<sup>-</sup> uveitis patients ( $P < 0.001$ ) and healthy controls ( $P < 0.001$ ). Serum C1q levels were comparable between QFT<sup>-</sup> uveitis patients and healthy controls (Figure 4). Comparison between infectious and non-infectious uveitis within the QFT<sup>-</sup> uveitis group revealed no difference in serum C1q levels (Figure 5a). Interestingly, APTB patients with uveitis displayed significantly higher serum C1q levels than APTB patients without uveitis ( $P = 0.0207$ ; Figure 5b). Furthermore, APTB patients with uveitis had significantly ( $P < 0.001$ ) elevated serum C1q levels as compared to QFT<sup>-</sup> patients suffering from uveitis because of infection with the obligate intracellular parasite *Toxoplasma gondii*. Serum C1q levels in Toxoplasmosis-associated uveitis patients were comparable to levels in healthy controls (Figure 5c).

### The combination of serum C1q and peripheral blood type-1 IFN signature distinguishes four distinct groups within QFT<sup>+</sup> uveitis patients

Applying the combination of serum C1q and the type-1 IFN signature score cut-off values to the QFT<sup>+</sup> patients with uveitis of unknown cause ( $n = 58$ ) differentiated these patients into four distinct groups (Figure 6). The majority of patients



**Figure 3.** Correlation between serum C1q levels and whole blood transcriptional signature score, consisting of 10 type-1 interferon-stimulated genes (type-1 IFN signature). The vertical line represents the previously reported<sup>22</sup> type-1 IFN signature score cut-off value for active TB. The horizontal line represents the serum C1q cut-off value based on the 95% reference interval for healthy controls (cohort 1 + 2;  $n = 73$ ). **(a)** Inverse correlation between serum C1q level and type-1 IFN signature score in APTB patients (cohort 1;  $n = 22$ ). None of the patients located to the left lower quadrant IV (normal serum C1q and a negative type-1 IFN signature). **(b)** No correlation between serum C1q levels and type-1 IFN signature score in healthy controls (cohort 1,  $n = 23$ ). Twenty of the 23 healthy controls located to the lower left quadrant IV (normal serum C1q and a negative type-1 IFN signature). Statistical analysis was performed in GraphPad Prism 5.0, and correlation coefficient was determined with Pearson's  $r$  test.



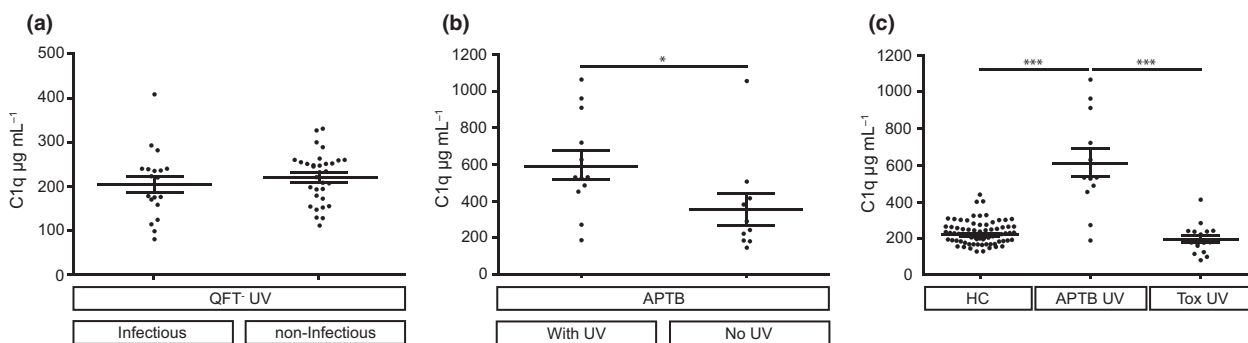
**Figure 4.** Increased serum C1q levels are associated with QuantiFERON-Tb Gold (QFT)-positive uveitis of unknown cause. Comparison of serum C1q levels in QFT<sup>+</sup> patients with uveitis of unknown cause (cohort 1; *n* = 58), QFT<sup>-</sup> patients with uveitis (cohort 1; *n* = 51) and healthy controls (cohort 1 + 2; *n* = 73). UV, uveitis. Horizontal lines represent the group mean, and error bars indicate the 95% CI. Statistical analysis was performed on the transformed data set in SPSS 25, and multiple comparison was performed by analysis of variance (ANOVA) followed by Dunnett’s T3 post hoc testing. \*\*\**P* < 0.001.

(*n* = 30; 52%) located to quadrant IV (normal serum C1q and a negative type-1 IFN signature), 17 patients (29%) located to quadrant III (normal serum C1q and a positive type-1 IFN signature), six patients (10%) located to quadrant II (elevated serum C1q and a positive type-1 IFN signature), and five patients (9%) located to quadrant I (elevated serum C1q and a negative type-1 IFN signature).

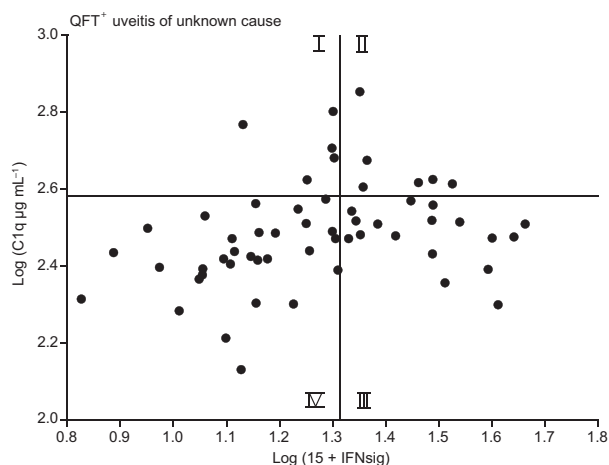
## DISCUSSION

In our current study, we established an association between APTB (with or without uveitis) and elevated serum C1q levels in two, independently collected, Indonesian cohorts. ROC analysis displayed the diagnostic value of serum C1q. Serum C1q diagnostic performance, as calculated by maximum Youden’s index (0.4473), revealed a sensitivity of 65.3% and specificity of 79.5% to discriminate APTB patients from geographically matched healthy controls. These findings confirm the previous study by Lubbers *et al.* that reported increased serum C1q levels in APTB patients from distinct geographical locations (Italy, Gambia, Korea and South Africa) as compared to geographically matched healthy controls, LTBI and clinically relevant diseases (e.g. sarcoidosis, leprosy and pneumonia).<sup>23</sup> Our study is limited in the sense that not all included healthy controls were examined for the presence of LTBI, which could have served as a separate control group. However, equal serum C1q levels in LTBI and healthy controls have previously been observed.<sup>23</sup> Therefore, our data support the notion that elevated serum C1q measurement may provide added value in the diagnosis of active TB infections.

We, and others, previously demonstrated that APTB is associated with overexpression of ISGs in peripheral blood cells and that this may represent a biomarker for active TB, progression from LTBI to active TB, or to monitor treatment efficacy.<sup>18–20,22</sup> Interestingly, associations between



**Figure 5.** Increased serum C1q levels in APTB patients with uveitis. **(a)** Comparison of serum C1q levels between infectious and non-infectious uveitis amongst QFT<sup>-</sup> patients (cohort 1; *n* = 51). **(b)** Comparison of serum C1q levels in APTB patients with uveitis (cohort 1; *n* = 12) and APTB patients without uveitis (cohort 1; *n* = 10). **(c)** Comparison between serum C1q levels in APTB patients with uveitis (cohort 1; *n* = 12), QFT<sup>-</sup> patients with *Toxoplasmosis gondii*-associated uveitis (cohort 1; *n* = 16) and healthy controls (cohort 1 + 2; *n* = 73). Tox, *Toxoplasmosis gondii*. Horizontal lines represent the group mean, and error bars indicate the 95% CI. Statistical analysis was performed on the transformed data set in SPSS 25, and multiple comparison was performed by ANOVA followed by Dunnett’s T3 post hoc testing. \**P* < 0.05, \*\*\**P* < 0.001.



**Figure 6.** Application of serum C1q and type-1 IFN signature score to QFT<sup>+</sup> patients with uveitis of unknown cause. The type-1 IFN signature score cut-off value is indicated by the vertical line, and the serum C1q level cut-off value is indicated by the horizontal line. From the QFT<sup>+</sup> patients with uveitis of unknown cause (cohort 1;  $n = 58$ ), 30 patients located to quadrant IV (normal serum C1q and a negative type-1 IFN signature) and might be considered as unlikely to suffer from uveitis because of active TB. Five patients located to quadrant I, six patients located to quadrant II, and 17 patients located to quadrant III. The patients within quadrants I, II and III are more likely to suffer from uveitis because of active TB.

C1q deficiency and exacerbated IFN- $\alpha$  responses have been reported.<sup>27</sup> Moreover, C1q was noted to inhibit immune complex-induced IFN- $\alpha$  production by plasmacytoid dendritic cells, while hepatitis C virus core protein was found to downregulate inflammatory cytokine production via C1q receptor (gC1qR) ligation.<sup>26,27,32</sup> These findings indicate that C1q-gC1qR interactions may regulate cytokine responses, including IFN- $\alpha$ . Therefore, we determined the relation between serum C1q levels and type-1 IFN signature scores in active TB disease, as both have been proposed as biomarker to identify active TB. We observed a clear inverse correlation between serum C1q levels and type-1 IFN signature scores in APTB patients, indicating that both these proposed biomarkers for active TB disease can be mutually exclusive. We propose that the combined measurement of type-1 IFN signature and serum C1q may provide added value in the diagnosis of active TB disease.

Positive blood type-1 IFN gene signatures also occur in substantial numbers of patients with systemic autoimmune disease, including pSS, SLE or SSc.<sup>28–31</sup> We did not observe a correlation between the disease-specific type-1 IFN gene signature score and serum C1q level in systemic

autoimmune disease (pSS, SLE or SLE). Several studies did identify transcriptional differences, as well as similarities, in type-1 IFN-inducible gene signatures between various autoimmune diseases, TB, and normal immune responses, supporting the use of disease-specific IFN gene signatures.<sup>33,34</sup> Thus, although the genes underlying the type-1 IFN gene signature differed between our TB cohort and the systemic autoimmune disease cohort, our data support a role for C1q in regulating type-1 IFN signalling during active TB disease. How this relates to disease pathology, duration, activity or progression is still unclear and should be investigated in future studies.

Interestingly, APTB patients with uveitis displayed higher serum C1q levels than APTB patients without uveitis. The exact reason for this is currently unknown. However, C1q can modulate T-cell responses by attenuating the activity of CD8<sup>+</sup> T cells, Th1 and Th17 cells and enhancing regulatory T-cell activity.<sup>35,36</sup> Furthermore, serum analysis of rhesus macaques with pulmonary TB revealed a further increase in serum C1q level in those macaques that were unable to control disease, while levels remained stable at pre-infection levels in macaques that did control the infection.<sup>23,37</sup> This further supports a potential immune dampening effect of C1q that hampers *Mtb* control (within the lungs), thereby leading to pulmonary disease progression and potential systemic *Mtb* spread. Moreover, increased serum C1q levels, during TB infection, are accompanied by an increase in the expression of SERPING1, the main inhibitor of the C1-complex.<sup>23,38</sup> This may suggest the presence of a TB-specific immune-escape mechanism in which the immune-suppressive effect of C1q on T-cell biology is achieved without increased classical complement pathway activation. At the same time, immune dampening by C1q might limit immunopathology, which might be beneficial at vital and vulnerable anatomical locations such as the eyes.

Previously, we did not observe increased expression of *C1QA*, *C1QB* or *C1QC* mRNA transcripts in *Mtb*-infected RPE cells.<sup>39</sup> This suggests that *Mtb*-infected RPE cells most likely do not directly contribute to the high serum C1q levels we observed in TB-associated uveitis. Potentially, RPE-derived molecules stimulate other cell types (e.g. monocytes, macrophages and/or dendritic cells) within and/or outside the eye to produce C1q. Transcriptional and immunohistochemical analysis on enucleated eye

structures of patients suffering from TB-associated uveitis would be of great interest to identify any C1q-producing cells in the eye.

Swift diagnosis of TB-associated uveitis is crucial to minimise disease burden and optimise treatment outcome.<sup>10</sup> However, QFT and TST do not discriminate between a current active *Mtb* infection and past exposure. Moreover, especially in TB-endemic countries, the association between a positive QFT and/or TST test with uveitis might be coincidental. In such areas, over-diagnosis of active TB-associated uveitis is a recognised problem that may result in overzealous treatment of QFT<sup>+</sup> uveitis patients with highly toxic anti-TB drugs.<sup>40</sup> This underlines the need for new biomarkers, or combinations thereof, to stratify especially QFT<sup>+</sup> patients with uveitis of unknown cause, into those that are less likely, or highly likely, to suffer from uveitis because of an active *Mtb* infection.<sup>41–44</sup> Previously, we proposed that QFT<sup>+</sup> uveitis patients with a negative type-1 IFN signature had a low risk of suffering from uveitis because of an active TB infection.<sup>22</sup> However, our current data indicate that active TB can exist in the context of a negative type-1 IFN signature, in the presence of elevated serum C1q levels. Therefore, based on our current finding, we propose that QFT<sup>+</sup> patients with uveitis of unknown cause, that have a negative type-1 IFN signature and normal serum C1q levels (quadrant IV, Figure 6), are least likely to suffer from uveitis because of an active TB infection. These patients might, for instance, suffer from autoimmune uveitis, either related or unrelated to past *Mtb* infection, or from uveitis of another (unidentified) cause.<sup>45,46</sup> In contrast, TB-associated uveitis is highly likely in patients falling into one of the other quadrants (quadrants I, II and III; Figure 6). Combined type-1 IFN signature and serum C1q measurement could therefore aid in the diagnostic workup of QFT<sup>+</sup> uveitis patients to optimise treatment choice and potentially prevent unnecessary treatment with highly toxic anti-TB drugs in a substantial number of patients (quadrant IV; Figure 6).

A limitation of our study is that we had no data on outcome/treatment response available. Such data would have been of additional value to further support our hypothesis that QFT<sup>+</sup> uveitis patients that fall into quadrants I, II or III are likely to display a beneficial response to ATT, while patients falling into quadrant IV most likely do not. Therefore, studies that explore the

relation between peripheral blood type-1 IFN signature and serum C1q level in relation to the efficacy of ATT in QFT<sup>+</sup> uveitis patients are warranted.

In conclusion, in this study we confirm the recently published association between active TB disease and elevated serum C1q levels. Our study is the first to reveal an inverse correlation between serum C1q level and type-1 IFN signature score in active TB disease. Importantly, our data clearly demonstrate that increased serum C1q levels or a positive type-1 IFN signature are individually not sufficient to detect active TB disease. We propose that the combined measurement of peripheral blood type-1 IFN signature and serum C1q level is of added value in the diagnosis of active TB disease. This is further supported by ROC analysis on cohort 1, where predicted probabilities calculated by binary logistic regression on the combined measurement of serum C1q and type-1 IFN signature score yielded a sensitivity of 100% and specificity of 87%, thus outperforming the diagnostic accuracy of serum C1q or type-1 IFN signature score alone (Supplementary figure 2). However, additional studies using higher numbers of patients are required to confirm this observation.

Moreover, we expect that combined measurement of both these biomarkers will improve the stratification of patients that are suspected of active TB-associated uveitis into groups with either a low or high risk of having uveitis because of an active TB infection. Such a stratification could form the basis for future diagnostic and treatment studies in QFT<sup>+</sup> uveitis patients.

## METHODS

### Patients and controls

Sera from three previously collected cohorts, two TB cohorts from Indonesia (from now on designated as cohort 1<sup>47</sup> and 2<sup>48</sup>) and one cohort consisting of systemic autoimmune patients from mainly Caucasian origin (from now on designated as cohort 3<sup>28–30</sup>), were included in this study. All individuals from cohorts 1 and 3 and all TB patients from cohort 2 were HIV negative, and healthy controls from cohort 2 were largely untested. A detailed description of the patient cohorts is given in Table 1. All included individuals provided their written informed consent. The study was approved by the local medical ethics committees of the Faculty of Medicine University of Indonesia (cohort 1, FMUI: 268/H2.F1/ETIK/2014), The Eijkman Institute research ethics committee, Jakarta (cohort

**Table 1.** Patient characteristics

(Sub)Group	Mean Age (SD)	Male-to-Female ratio	Sputum positive	QFT positive (> 0.35 IU mL <sup>-1</sup> )	Type I IFN signature score positive (> 5.6)
Cohort 1 (n = 154)					
Healthy Control (n = 23)	31.0 (9.4)	0.4	n/a	0/23	2/23
APT <sub>B</sub> w/o uveitis (n = 10)	41.3 (15.7)	2.3	10/10	7/10	10/10
APT <sub>B</sub> -assoc. uveitis (n = 12)	42.0 (17.2)	2.0	2/12	10/12	5/12
QFT <sup>+</sup> Uveitis of unknown aetiology (N = 58)	46.3 (13.2)	0.4	n/a	58/58	23/58
QFT <sup>-</sup> Uveitis (N = 51)	39.9 (16.5)	1.6	n/a	0/51	21/58
Cohort 2 (n = 100)					
Healthy Control (n = 50)	34.6 (12.6)	0.9	0/50	n/a	n/a
APT <sub>B</sub> uveitis unknown (n = 50)	31.4 (9.5)	2.1	50/50	n/a	n/a
Cohort 3 (n = 139)					
Primary Sjögren's syndrome (n = 86)	60.2 (13.2)	0.1	n/a	n/a	n/a
Systemic lupus erythematosus (n = 30)	46.8 (13.6)	0.1	n/a	n/a	n/a
Systemic sclerosis (n = 23)	59.5 (10.9)	0.2	n/a	n/a	n/a

APT<sub>B</sub>, active pulmonary tuberculosis; IFN, interferon; QFT, QuantiFERON-TB Gold test; SD, standard deviation.

2<sup>48</sup>), and Erasmus MC, University Medical Center, Rotterdam, the Netherlands (cohort 3, MEC-2011-116). This study was conducted in coherence with the tenets of the Declaration of Helsinki.

### Tuberculosis, QFT<sup>+</sup> uveitis and QFT<sup>-</sup> uveitis

Cohort 1 was previously described and originates from Jakarta (n = 131 patients and n = 23 healthy controls<sup>47</sup>). Cohort 1 contained 10 sputum smear-positive APT<sub>B</sub> patients without uveitis, 12 clinically diagnosed APT<sub>B</sub> patients with uveitis of whom two were sputum smear positive, 58 QuantiFERON-Tb Gold test (QFT)-positive (> 0.35 IU mL<sup>-1</sup>) uveitis patients without any signs of active TB and no alternative determined uveitis cause, 51 QFT<sup>-</sup> uveitis patients [infectious origin (n = 19), related to systemic disease (n = 5), ocular syndromes (n = 12) or uveitis of unknown aetiology (n = 15)], and 23 healthy Indonesian controls. Cohort 2 also originates from Jakarta and consisted of 50, sputum smear and culture positive, APT<sub>B</sub> patients and 50 healthy Indonesian controls. Diagnostic information concerning the presence of uveitis in these patients was not available.<sup>48</sup>

### Systemic autoimmune disease

Cohort 3 consists of sera from patients with pSS (n = 86), SLE (n = 30) and SSc (n = 23) that were included at the Erasmus MC, University Medical Center, Rotterdam, the Netherlands.

### Serum C1q ELISA

Serum C1q levels were determined by ELISA, as described previously.<sup>23,49</sup> In short, MaxiSorp (Nunc, Rochester, NY, USA) plates were coated overnight at 4°C with mouse anti-human C1q antibody (Department of Nephrology, Leiden University Medical Center, the Netherlands) in coating buffer (0.1 m Na<sub>2</sub>CO<sub>3</sub>, 0.1 m NaHCO<sub>3</sub>, pH 9.6). The next

day, plates were washed and blocked with PBS/1% BSA for 1 h at 37°C. After washing, the plates were incubated for 1 h at 37°C with serum samples serially diluted in PBS/1% BSA/0.05% Tween. Subsequently, the plates were washed and incubated (1 h, 37°C) with rabbit anti-human C1q antibody (DAKO, Jena, Germany). Hereafter, the plates were washed and incubated (1 h, 37°C) with horseradish peroxidase (HRP)-labelled goat-anti-rabbit antibody (DAKO). As substrate, 2,2'-azino-bis(3-ethylbenzothiazoline-6-sulphonic acid) (ABTS; Sigma, Saint Louis, MO, USA) was used to optically visualise HRP activity, which was quantified by measuring the optical density at 415 nm. Wash steps were performed with PBS/0.05% Tween. All serum sample measurements within the linear range of the reference curve were averaged, and reference curve dilutions were analysed in duplicate.

### Peripheral blood type-1 IFN gene signatures

From patients and healthy controls included in cohort 1, the TB-related peripheral blood type-1 IFN gene signature scores were previously determined in blood obtained at the same time as serum used for C1q analysis in our current study.<sup>22</sup> In addition, from cohort 3, the systemic autoimmune disease-related peripheral blood type-1 IFN signature scores were available and determined as previously described.<sup>28-30</sup> Genes comprising the disease-related type-1 IFN signatures, as well as the formula used to calculate the type-1 IFN signature score, are provided in Supplementary table 1.

### Statistical analysis

Data distribution of all groups was determined with the D'Agostino-Pearson normality test. As most of the data were not normally distributed within the groups, a log transformation was applied on the complete data set. C1q values were transformed by log (C1q μg mL<sup>-1</sup>), while the type-1 IFN signature scores were transformed by log (15 + type-1 IFN signature).

Comparison between two groups was performed with an unpaired Student's *t*-test. If group variances differed significantly (*F*-test), an unpaired Welch's *t*-test was used instead. Correlations were determined with Pearson's *r* test. Multiple comparison testing was performed by analysis of variance (ANOVA) followed by Dunnett's T3 post hoc testing. Statistical analysis was performed in GraphPad Prism 5.0 and SPSS 25. A *P*-value < 0.05 was considered significant.

## ACKNOWLEDGMENTS

We are grateful to all participants who donated blood for these studies. We acknowledge the efforts of Professor Drs R Sitompul, M Susiyanti, L Edwar, S Sjamsoe (Department of Internal Medicine, Respiriology and Critical Illness Division, University of Indonesia & Cipto Mangunkusumo Hospital Kirana, Jakarta, Indonesia), Dr G Singh (Department of Internal Medicine, Respiriology and Critical Illness Division, University of Indonesia & Cipto Mangunkusumo Hospital Kirana, Jakarta, Indonesia) and Dr RR Diah Handayani (Department of Pulmonology, Persahabatan Hospital, Jakarta, Indonesia) for patient inclusion and sample collection of cohort 1. We also acknowledge Dr B Alisjahbana (Department of Internal Medicine, Hasan Sadikin General Hospital, Bandung, Indonesia, & Infectious Disease Research Center, Faculty of Medicine, Universitas Padjadjaran, Bandung, Indonesia) and his team for patient inclusion and sample collection of cohort 2.

## CONFLICT OF INTEREST

The authors have no conflicts of interests to disclose.

## REFERENCES

- Dheda K, Barry CE 3rd, Maartens G. Tuberculosis. *Lancet* 2016; **387**: 1211–1226.
- WHO. Global Tuberculosis Report, 2019. <https://apps.who.int/iris/bitstream/handle/10665/329368/9789241565714-eng.pdf?ua=1>
- Barrios-Payan J, Saqui-Salces M, Jeyanathan M et al. Extrapulmonary locations of *Mycobacterium tuberculosis* DNA during latent infection. *J Infect Dis* 2012; **206**: 1194–1205.
- Donahue HC. Ophthalmologic experience in a tuberculosis sanatorium. *Am J Ophthalmol* 1967; **64**: 742–748.
- Bouza E, Merino P, Munoz P, Sanchez-Carrillo C, Yanez J, Cortes C. Ocular tuberculosis. A prospective study in a general hospital. *Medicine (Baltimore)* 1997; **76**: 53–61.
- Mansour AM, Haymond R. Choroidal tuberculomas without evidence of extraocular tuberculosis. *Graefes Arch Clin Exp Ophthalmol* 1990; **228**: 382–383.
- Alvarez S, McCabe WR. Extrapulmonary tuberculosis revisited: a review of experience at Boston City and other hospitals. *Medicine (Baltimore)* 1984; **63**: 25–55.
- Cimino L, Herbort CP, Aldigeri R, Salvarani C, Boiardi L. Tuberculous uveitis, a resurgent and underdiagnosed disease. *Int Ophthalmol* 2009; **29**: 67–74.
- Morimura Y, Okada AA, Kawahara S et al. Tuberculin skin testing in uveitis patients and treatment of presumed intraocular tuberculosis in Japan. *Ophthalmology* 2002; **109**: 851–857.
- Pai M, Behr MA, Dowdy D et al. Tuberculosis. *Nat Rev Dis Primers* 2016; **2**: 16076.
- Harries AD, Kumar AMV. Challenges and progress with diagnosing pulmonary tuberculosis in low- and middle-income countries. *Diagnosics (Basel)* 2018; **8**: 78.
- Zeka AN, Tasbakan S, Cavusoglu C. Evaluation of the GeneXpert MTB/RIF assay for rapid diagnosis of tuberculosis and detection of rifampin resistance in pulmonary and extrapulmonary specimens. *J Clin Microbiol* 2011; **49**: 4138–4141.
- Rao NA, Saraswathy S, Smith RE. Tuberculous uveitis: distribution of *Mycobacterium tuberculosis* in the retinal pigment epithelium. *Arch Ophthalmol* 2006; **124**: 1777–1779.
- Pandey O, Paudyal B, Basnyat B. Gene-Xpert: diagnosis of pulmonary tuberculosis in a sputum smear negative patient. *J Nepal Health Res Coun* 2019; **17**: 125–127.
- Albert D, Raven M. Ocular tuberculosis. *Microbiol Spectr* 2016; **4**: 10.1128/microbiolspec.TNMI7-0001-2016.
- Thompson MJ, Albert DM. Ocular tuberculosis. *Arch Ophthalmol* 2005; **123**: 844–849.
- Dalvin LASW. Intraocular manifestation of *Mycobacterium tuberculosis*: a review of the literature. *J Clin Tuberc Other Mycobact Dis* 2017; **7**: 13–21.
- Berry MP, Graham CM, McNab FW et al. An interferon-inducible neutrophil-driven blood transcriptional signature in human tuberculosis. *Nature* 2010; **466**: 973–977.
- Zak DE, Penn-Nicholson A, Scriba TJ et al. A blood RNA signature for tuberculosis disease risk: a prospective cohort study. *Lancet* 2016; **387**: 2312–2322.
- Ottenhoff TH, Dass RH, Yang N et al. Genome-wide expression profiling identifies type 1 interferon response pathways in active tuberculosis. *PLoS One* 2012; **7**: e45839.
- Moreira-Teixeira L, Mayer-Barber K, Sher A, O'Garra A. Type I interferons in tuberculosis: foe and occasionally friend. *J Exp Med* 2018; **215**: 1273–1285.
- La Distia Nora R, Sitompul R, Bakker M et al. Type 1 interferon-inducible gene expression in QuantiFERON Gold TB-positive uveitis: a tool to stratify a high versus low risk of active tuberculosis? *PLoS One* 2018; **13**: e0206073.
- Lubbers R, Sutherland JS, Goletti D et al. Complement component C1q as serum biomarker to detect active tuberculosis. *Front Immunol* 2018; **9**: 2427.
- Cai Y, Yang Q, Tang Y et al. Increased complement C1q level marks active disease in human tuberculosis. *PLoS One* 2014; **9**: e92340.
- Cliff JM, Lee JS, Constantinou N et al. Distinct phases of blood gene expression pattern through tuberculosis treatment reflect modulation of the humoral immune response. *J Infect Dis* 2013; **207**: 18–29.
- Lood C, Gullstrand B, Truedsson L et al. C1q inhibits immune complex-induced interferon- $\alpha$  production in plasmacytoid dendritic cells: a novel link between C1q deficiency and systemic lupus erythematosus pathogenesis. *Arthritis Rheum* 2009; **60**: 3081–3090.

27. Santer DM, Hall BE, George TC et al. C1q deficiency leads to the defective suppression of IFN- $\alpha$  in response to nucleoprotein containing immune complexes. *J Immunol* 2010; **185**: 4738–4749.
28. Huijser E, van Helden-Meeuwse CG, Groot N et al. MxA is a clinically applicable biomarker for type I interferon activation in systemic lupus erythematosus and systemic sclerosis. *Rheumatology (Oxford)* 2019; **58**: 1302–1303.
29. Wahadat MJ, Bodewes ILA, Maria NI et al. Type I IFN signature in childhood-onset systemic lupus erythematosus: a conspiracy of DNA- and RNA-sensing receptors? *Arthritis Res Ther* 2018; **20**: 4.
30. Brkic Z, Versnel MA. Type I IFN signature in primary Sjogren's syndrome patients. *Expert Rev Clin Immunol* 2014; **10**: 457–467.
31. Brkic Z, van Bon L, Cossu M et al. The interferon type I signature is present in systemic sclerosis before overt fibrosis and might contribute to its pathogenesis through high BAFF gene expression and high collagen synthesis. *Ann Rheum Dis* 2016; **75**: 1567–1573.
32. Song X, Yao Z, Yang J et al. HCV core protein binds to gC1qR to induce A20 expression and inhibit cytokine production through MAPKs and NF- $\kappa$ B signaling pathways. *Oncotarget* 2016; **7**: 33796–33808.
33. Aune TM, Maas K, Parker J, Moore JH, Olsen NJ. Profiles of gene expression in human autoimmune disease. *Cell Biochem Biophys* 2004; **40**: 81–96.
34. Maas K, Chan S, Parker J et al. Cutting edge: molecular portrait of human autoimmune disease. *J Immunol* 2002; **169**: 5–9.
35. Ling GS, Crawford G, Buang N et al. C1q restrains autoimmunity and viral infection by regulating CD8<sup>+</sup> T cell metabolism. *Science* 2018; **360**: 558–563.
36. Clarke EV, Tenner AJ. Complement modulation of T cell immune responses during homeostasis and disease. *J Leukoc Biol* 2014; **96**: 745–756.
37. Dijkman K, Lubbers R, Borggreven NV et al. Systemic and pulmonary C1q as biomarker of progressive disease in experimental non-human primate tuberculosis. *Sci Rep* 2020; **10**: 6290.
38. Lubbers R, Sutherland JS, Goletti D et al. Expression and production of the SERPING1-encoded endogenous complement regulator C1-inhibitor in multiple cohorts of tuberculosis patients. *Mol Immunol* 2020; **120**: 187–195.
39. La Distia Nora R, Walburg KV, van Hagen PM et al. Retinal pigment epithelial cells control early *Mycobacterium tuberculosis* infection via interferon signaling. *Invest Ophthalmol Vis Sci* 2018; **59**: 1384–1395.
40. Gupta A, Sharma A, Bansal R, Sharma K. Classification of intraocular tuberculosis. *Ocul Immunol Inflamm* 2015; **23**: 7–13.
41. Elkington P, Tebruegge M, Mansour S. Tuberculosis: an infection-initiated autoimmune disease? *Trends Immunol* 2016; **37**: 815–818.
42. Spratt A, Key T, Vivian AJ. Chronic anterior uveitis following bacille Calmette-Guerin vaccination: molecular mimicry in action? *J Pediatr Ophthalmol Strabismus* 2008; **45**: 252–253.
43. Garip A, Diedrichs-Mohring M, Thureau SR, Deeg CA, Wildner G. Uveitis in a patient treated with Bacille-Calmette-Guerin: possible antigenic mimicry of mycobacterial and retinal antigens. *Ophthalmology* 2009; **116**(2457–2462): e2451–2452.
44. Koth LL, Solberg OD, Peng JC, Bhakta NR, Nguyen CP, Woodruff PG. Sarcoidosis blood transcriptome reflects lung inflammation and overlaps with tuberculosis. *Am J Respir Crit Care Med* 2011; **184**: 1153–1163.
45. Tagirasa R, Parmar S, Barik MR, Devadas S, Basu S. Autoreactive T cells in immunopathogenesis of TB-associated uveitis. *Invest Ophthalmol Vis Sci* 2017; **58**: 5682–5691.
46. Schrijver B, Hardjosantoso H, Ten Berge J et al. No evidence for circulating retina specific autoreactive T-cells in latent tuberculosis-associated uveitis and sarcoid uveitis. *Ocul Immunol Inflamm* 2020; **1–7**. <https://doi.org/10.1080/09273948.2019.1698752> [Epub ahead of print].
47. La Distia Nora R, Sitompul R, Bakker M et al. Tuberculosis and other causes of uveitis in Indonesia. *Eye (Lond)* 2018; **32**: 546–554.
48. Vrieling F, Alisjahbana B, Sahiratmadja E et al. Plasma metabolomics in tuberculosis patients with and without concurrent type 2 diabetes at diagnosis and during antibiotic treatment. *Sci Rep* 2019; **9**: 18669.
49. van Schaarenburg RA, Magro-Checa C, Bakker JA et al. C1q deficiency and neuropsychiatric systemic lupus erythematosus. *Front Immunol* 2016; **7**: 647.

## Supporting Information

Additional supporting information may be found online in the Supporting Information section at the end of the article.



This is an open access article under the terms of the Creative Commons Attribution-NonCommercial-NoDerivatives License, which permits use and distribution in any medium, provided the original work is properly cited, the use is non-commercial and no modifications or adaptations are made.