



Universiteit  
Leiden  
The Netherlands

## **Transvenous revision of leads with cardiac perforation following device implantation-Safety, outcome, and complications**

Doring, M.; Mussigbrodt, A.; Ebert, M.; Bode, K.; Lucas, J.; Dagues, N.; ... ; Richter, S.

### **Citation**

Doring, M., Mussigbrodt, A., Ebert, M., Bode, K., Lucas, J., Dagues, N., ... Richter, S. (2020). Transvenous revision of leads with cardiac perforation following device implantation-Safety, outcome, and complications. *Pacing And Clinical Electrophysiology*, 43(11), 1325-1332. doi:10.1111/pace.14056

Version: Publisher's Version

License: [Creative Commons CC BY-NC 4.0 license](#)

Downloaded from: <https://hdl.handle.net/1887/3232590>

**Note:** To cite this publication please use the final published version (if applicable).

# Transvenous revision of leads with cardiac perforation following device implantation—Safety, outcome, and complications

Michael Döring MD\*  | Andreas Müssigbrodt MD\* | Micaela Ebert MD, PhD |  
 Kerstin Bode MD | Johannes Lucas MD | Nikolaos Dargès MD | Gerhard Hindricks MD  
 | Sergio Richter MD

Department of Electrophysiology, Heart Center, University of Leipzig, Leipzig, Germany

## Correspondence

Michael Döring, MD, Department of Electrophysiology, Heart Centre, University of Leipzig, Strümpellstr, 39, 04289 Leipzig, Germany.  
 Email: [michael.doering@medizin.uni-leipzig.de](mailto:michael.doering@medizin.uni-leipzig.de)

\*Michael Döring and Andreas Müssigbrodt contributed equally to this work.

## Abstract

**Introduction:** Cardiac perforation is a rare complication of cardiac implantable electronic device (CIED) implantation. Transvenous revision of perforated leads is associated with the risk of cardiac tamponade and death. Little is known about periprocedural complications and outcome of these patients.

**Methods and results:** All patients referred to our department with evidence or suspicion of cardiac perforation following CIED implantation underwent chest X-ray, transthoracic echocardiography, device interrogation, and, if necessary, a cardiac computed tomography (CT)-scan to diagnose lead perforation and associated complications. Transvenous lead revision (TLR) was performed in all patients with evidence of lead perforation. Patient characteristics, procedural complications, and outcome were recorded and analyzed.

Fifty-six patients ( $75 \pm 10$  years, 43% male) were diagnosed with cardiac perforation, 34 patients (61%) early within 30 days post-implantation, and 22 patients (39%) thereafter. The most frequent perforation site was the right ventricular (RV) apex (75%), followed by the RV free wall (16%) and the right atrial appendage (9%). A total of 16 patients (29%) presented with severe complications; 12 patients (21%) with pericardial effusion treated by pericardiocentesis before lead revision and four patients (7%) with hemothorax requiring drainage. Late perforations showed significantly more frequent cardiac tamponades ( $P = .041$ ). TLR was performed without further complications in 54 patients (96%). None of the patients required surgical treatment or experienced in-hospital death.

**Conclusions:** Cardiac perforation following CIED implantation is associated with severe complications in nearly one-third of the cases. Transvenous revision of the perforated lead can safely be performed with a very low complication rate.

This is an open access article under the terms of the [Creative Commons Attribution-NonCommercial](https://creativecommons.org/licenses/by-nc/4.0/) License, which permits use, distribution and reproduction in any medium, provided the original work is properly cited and is not used for commercial purposes.

© 2020 The Authors. *Pacing and Clinical Electrophysiology* published by Wiley Periodicals LLC

**KEYWORDS**

cardiac perforation, defibrillator lead, pacemaker lead, transvenous lead extraction

## 1 | INTRODUCTION

Cardiac implantable electronic devices (CIEDs) have become indispensable in the treatment of cardiac rhythm disorders and systolic heart failure and are being used to an increasing extent.<sup>1-3</sup> The implantation is safe and feasible, but placement of transvenous leads in particular can be associated with a variety of complications. In a large population-based cohort study, 9.5% of all patients experienced at least one complication following device surgery.<sup>4</sup> Cardiac perforation with one of the leads is rare with a cumulative incidence of 0.5-1.5% at 6 months, but can be associated with severe complications such as pneumothorax, hemothorax, and a substantial risk of cardiac tamponade and death.<sup>5,6</sup> The frequency of pericardial effusion requiring pericardiocentesis has been described with up to 0.5%.<sup>7</sup> Major device-related complications result in prolonged hospitalization and increased costs and are associated with worse outcomes and increased mortality.<sup>8</sup> In general, perforated leads have to be revised to relieve the patient's symptoms and restore device function, and limited data on feasibility and outcomes of both surgical and percutaneous revisions have been reported previously.<sup>5,9</sup> Transvenous extraction of perforated leads with subsequent reimplantation of a new lead is less invasive compared to the surgical approach and therefore may represent a considerable treatment option, but data on complication rates and outcome of patients undergoing this intervention are scarce.<sup>10</sup>

Therefore, we aimed to evaluate the clinical course, outcome, and complications in patients undergoing transvenous revision of leads with cardiac perforation.

## 2 | METHODS

### 2.1 | Study population

All consecutive patients with cardiac perforation following CIED implantation were included in a prospectively designed registry. This database contains information about patient history, including baseline characteristics, indication for device implantation, and lead revision, as well as data about the procedure, complications, in-hospital mortality, and follow-up. All patients underwent chest X-ray, transthoracic echocardiography (TTE), and device interrogation to confirm the diagnosis of lead perforation and to identify the culprit lead and associated complications. During interrogation, a doubling of the pacing threshold and a change of more than 30% in amplitude and impedance of the perforated electrode were considered significant. A cardiac computed tomography (CT)-scan was performed at the discretion of the treating cardiologist. Patient characteristics, clinical course, and complications were analyzed and compared between patients with early

( $\leq 30$  days) and late ( $> 30$  days) perforations. The study was approved by the institutional review board, and all subjects gave written informed consent.

### 2.2 | Lead-revision procedure

Lead revision was performed by at least one experienced device specialist in local anesthesia in the electrophysiology laboratory following standard operating procedures as described previously.<sup>11</sup> Preprocedural pericardial effusion was drained in hemodynamically compromised patients with subxiphoidal puncture, and a pigtail catheter was left in place during transvenous lead revision (TLR). All remaining patients were prepared for potential pericardiocentesis, and surgical backup was always available. Patients were monitored with invasive blood pressure, ECG, oxygen saturation, and frequent blood gas analysis. Transesophageal echocardiographic imaging was not routinely used. A new lead was placed in a different location in the right atrial appendage or at the interventricular septum to achieve adequate values for sensing, impedance, and pacing threshold. After retraction of the helix in active fixation leads, manual traction with the aid of a regular stylet was performed with the aim of complete lead extraction. At the first postoperative day, TTE, chest X-ray, and device interrogation were performed to confirm adequate device function and lead position and to exclude pericardial effusion, hemothorax, or pneumothorax.

### 2.3 | Data analysis

All data were tested for normal (Gaussian) distribution using the Kolmogoroff-Smirnov test. Continuous variables were expressed as mean  $\pm$  SD. Categorical variables are presented as number and percentage of patients. Continuous variables were compared by means of Student's *t*-test and categorical variables by chi-square test. A two-tailed *P* value  $< .05$  was considered statistically significant. All analyses were performed using SPSS for Windows, V. 22 (SPSS Inc., Chicago, IL).

## 3 | RESULTS

### 3.1 | Patient characteristics

Fifty-six patients with lead-related cardiac perforation ( $75 \pm 10$  years, 43% male, 59% referred from other hospitals) were treated in our department between July 2009 and August 2018. Cardiac perforation was diagnosed early in the first 30 days following the index operation in 34 patients (61%) and later after 30 days in 22 patients (39%). The

**TABLE 1** Clinical characteristics, procedural and follow-up data compared between patients with early ( $\leq 30$  days) and late ( $> 30$  days) perforation

	All patients	Early perforation	Late perforation	P-value
Number of patients, n (%)	56 (100)	34 (61)	22 (39)	
Age, years	75 $\pm$ 10	74 $\pm$ 12	77 $\pm$ 7	.335
Male, n (%)	24 (43)	14 (41)	10 (46)	.788
BMI, kg/m <sup>2</sup>	27 $\pm$ 4	27 $\pm$ 4	27 $\pm$ 3	.484
Medication with steroids, n (%)	1 (2)	1 (3)	0 (0)	1.0
Anticoagulation, n (%)				.994
None	12 (21)	7 (21)	5 (23)	
Antiplatelet treatment	16 (28)	10 (33)	6 (27)	
Oral anticoagulation	20 (35)	12 (35)	8 (36)	
Low-molecular-weight heparin	8 (14)	5 (15)	3 (14)	
Use of temporary pacing wire, n (%)	2 (4)	1 (3)	1 (5)	1.0
Pericardial effusion, n (%)				.041
None	33 (59)	23 (68)	10 (45)	
Not requiring puncture	10 (18)	7 (21)	3 (14)	
Tamponade	13 (23)	4 (12)	9 (41)	
Leading symptom, n (%)				.003
Thoracic pain	19 (34)	17 (50)	2 (9)	
Dyspnea	13 (23)	3 (9)	10 (46)	
Pain and phrenic nerve stimulation	7 (13)	4 (12)	3 (14)	
Phrenic nerve stimulation	6 (11)	2 (6)	4 (18)	
Bradycardia	3 (5)	3 (9)	0 (0)	
No symptoms	8 (14)	5 (15)	3 (14)	
Site of perforation, n (%)				.406
RV-apex	42 (75)	26 (77)	16 (73)	
RV-free wall	9 (16)	4 (12)	5 (23)	
RA-appendage	5 (9)	4 (12)	1 (5)	
Lead fixation, n (%)				.289
Active fixation lead	52 (93)	33 (97)	19 (86)	
Passive fixation lead	4 (7)	1 (3)	3 (14)	
Time to revision, days	48 $\pm$ 11*	9 $\pm$ 1*	107 $\pm$ 22*	<.001

Abbreviations: BMI, body mass index; RA, right-atrial; RV, right ventricular.

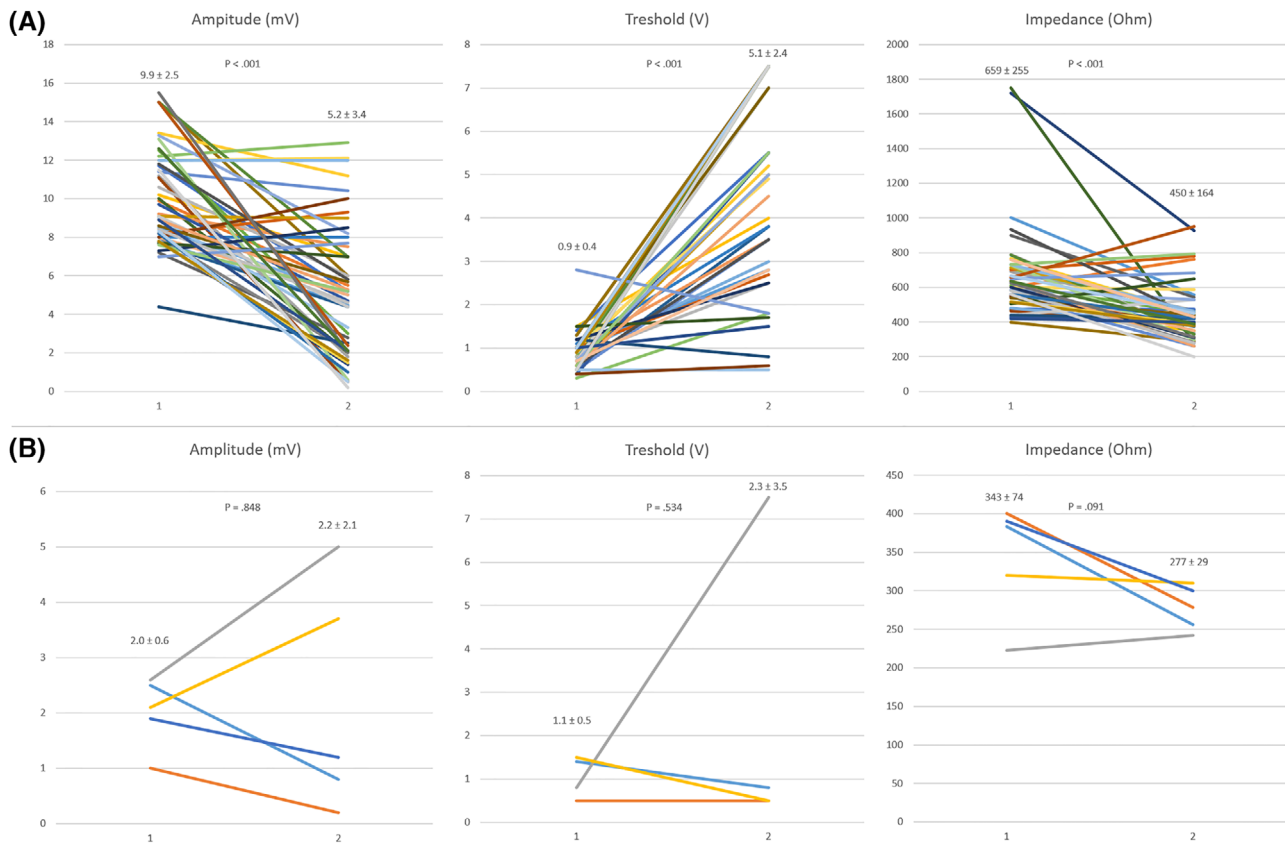
Clinical characteristics, procedural and follow-up data compared between patients with early ( $\leq 30$  days) and late ( $> 30$  days) perforation. Values are mean  $\pm$  SD (\*standard error of the mean) or n (%).

majority of patients (86 %) reported symptoms such as thoracic pain (19, 34%), dyspnea (13, 23%), phrenic nerve stimulation (13, 23%), or bradycardia (3, 5%). Patients with late perforation had significantly more pericardial effusions requiring puncture (9, 41% vs 4, 12%;  $P = .041$ ) and were more likely to present with shortness of breath as the leading symptom (10, 46% vs 3, 9%;  $P = .003$ ). Irrespective of this, there were no relevant differences between patients with early or late perforation, neither in the location of the perforation nor in the type or diameter of the perforated lead. Thirteen patients (23%) developed hemodynamically relevant pericardial effusion. Compared to the group without the need for pericardiocentesis, these patients presented significantly later after the index procedure (77 [12, 121]

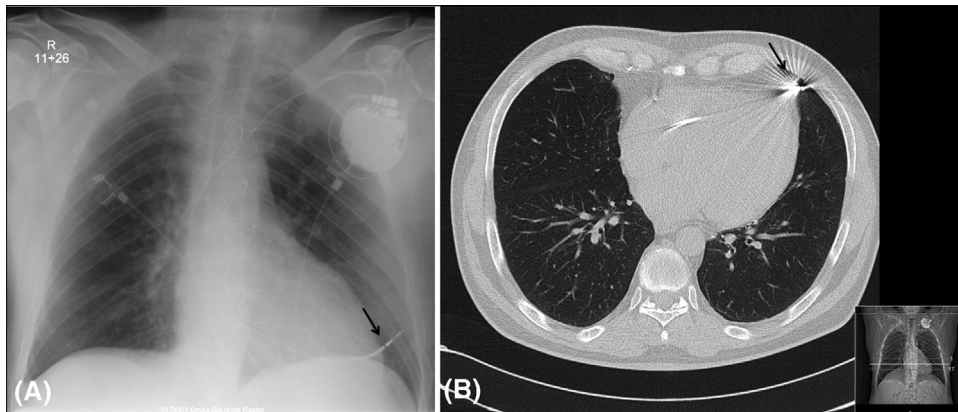
vs 13 [5, 41] days,  $P = .007$ ) and had significantly more often dyspnea as the leading symptom (85 vs 5%,  $P < .001$ ). For detailed patient characteristics, see Table 1.

### 3.2 | Diagnosis of cardiac perforation

The vast majority of patients (93%) showed electrical abnormalities during device interrogation. Looking at all right ventricular (RV) electrodes, highly significant changes in amplitude ( $9.9 \pm 2.5$  vs  $5.2 \pm 3.4$  mV;  $P < .001$ ), pacing threshold ( $0.9 \pm 0.4$  vs  $5.1 \pm 2.4$ V;  $P < .001$ ), and impedance ( $659 \pm 255$  vs  $450 \pm 164$  ohms;  $P < .001$ ) between



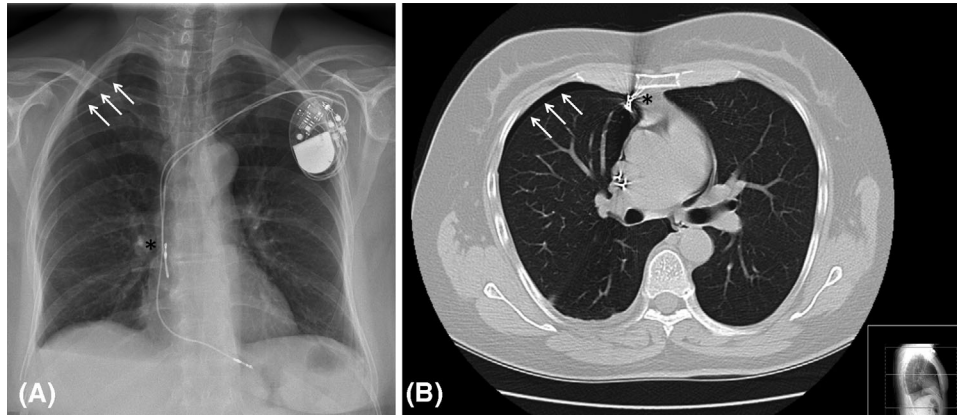
**FIGURE 1** Electrical measurements of the perforated right ventricular (A) and atrial (B) leads during implantation (1) and after perforation (2) [Color figure can be viewed at [wileyonlinelibrary.com](http://wileyonlinelibrary.com)]



**FIGURE 2** Various findings of lead perforations after implantation of a CIED. A single-chamber ICD for primary prevention was implanted in a 59-year-old male patient with the active fixation single-coil ICD lead implanted at the free wall of the right ventricle. Two weeks later, the patient was admitted with pleuritic chest pain. The chest X-ray (A) and CT-scan (B) showed a perforation of the lead through the pericardium and left lung into the thoracic wall (→). A pericardial effusion or pneumothorax was not present

implantation and time of perforation were observed. The five atrial electrodes showed no significant difference in the measured values before and after perforation (Figure 1). A total of 45 patients (80%) had an increase in pacing threshold or exit block of the perforated lead, 40 patients (71%) showed a significant decrease in sensing values and

29 patients (52%) in lead impedance. While all patients received chest X-ray, TTE, and device interrogation, only 21 patients (38%) with suspicion of cardiac perforation underwent a cardiac CT-scan (Figures 2 and 3). The crucial diagnostic tools to confirm cardiac perforation were chest X-ray in 30 patients (54%), cardiac CT-scan in 21 patients (38



**FIGURE 3** Various findings of lead perforations after implantation of a CIED. Postoperative chest X-ray (A) after left-sided implantation of a dual-chamber pacemaker in a 78-year-old female patient showed a contralateral pneumothorax (→). The suspicion of a perforation of the atrial lead (\*) could be confirmed in CT-scan (B)

%), device-interrogation in four patients (7%), and echocardiography in one patient (2%).

### 3.3 | Site of perforation and complications

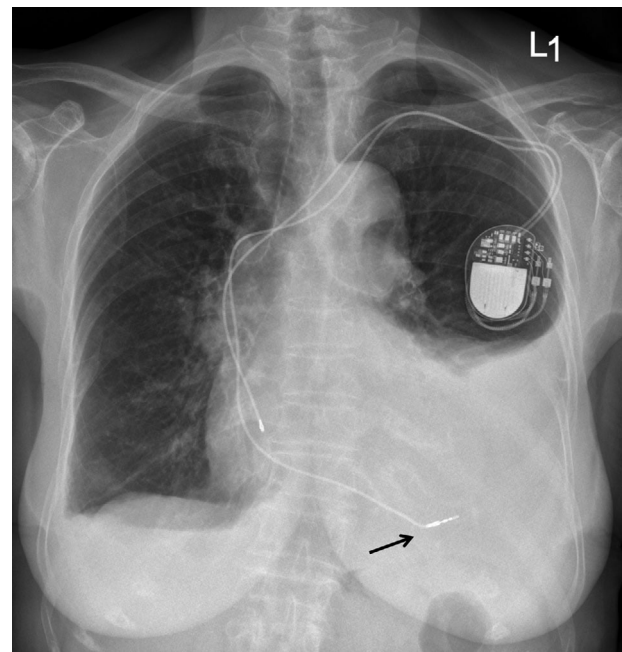
The most frequent perforation site was the RV apex in 42 patients (75%), followed by the RV free wall in nine patients (16%) and the right atrial appendage in five patients (9%). Pericardial effusion was present in 23 patients (41%). Therapeutic pericardiocentesis due to hemodynamical compromise was necessary and performed before lead revision in 12 patients (21%) and after lead revision in one patient (2%). In patients with need for pericardiocentesis, the RV free wall and the right atrial appendage were significantly more often the sites of perforation compared with patients without relevant pericardial effusion (31 vs 12% and 23 vs 5%, respectively,  $P = .019$ ). Four patients (7%) presented with hemothorax and were successfully treated with pleural drainage (Figure 4).

### 3.4 | Lead-revision procedure

TLR with extraction of the perforated lead and subsequent reimplantation of a new lead was performed without any complications in 54 patients (96%). One patient developed pericardial tamponade during lead extraction, while the other patient suffered from a repeat perforation of the right atrial lead and underwent a second revision with no further complications during follow-up. No patient required surgical treatment or died during the lead revision procedure.

### 3.5 | Outcome and follow-up

Correct device function was restored in all patients. No in-hospital death occurred. In patients presenting with tamponade requiring pericardiocentesis, hospitalization was significantly prolonged ( $10 \pm 8$  days



**FIGURE 4** Various findings of lead perforations after implantation of a CIED. A 69-year-old female patient complained of left-sided thoracic pain 3 weeks after implantation of a dual-chamber pacemaker. Chest X-ray showed a clear perforation of the right ventricular apex with the right ventricular lead (→) and a left-sided hemothorax

vs  $5 \pm 3$  days,  $P = .001$ ). During long-term follow-up of  $17 \pm 29$  months, no device- or lead-related complications occurred, and no patient experienced cardiac device-related infection.

## 4 | DISCUSSION

To the best of our knowledge, the present study is the largest to report on outcome data of transvenous lead extraction in patients with

cardiac perforation following CIED implantation. Our study allows the following statements:

- Lead-related cardiac perforation is associated with severe complications (such as pericardial effusion, cardiac tamponade, hemothorax, and pneumothorax) requiring further interventions in over one-third of patients.
- Transvenous revision of leads with cardiac perforation is safe and feasible with a very low complication rate.
- Patients with late perforation have significantly more pericardial effusions that need to be drained and more often present with shortness of breath as the leading symptom.

Cardiac perforation following CIED-implantation is a rare complication and should be treated with revision of the perforated leads. Conservative treatment of lead-related cardiac perforation is associated with an increased complication rate mainly driven by the appearance of cardiac tamponade during follow-up.<sup>12</sup> Lead-related cardiac perforation can be diagnosed when at least the tip of a passive fixation or the screw of an active fixation lead penetrates the myocardium and enters the pericardial space, which may lead to changes in sensing, impedance, and pacing threshold of the perforated lead.<sup>13</sup> This complication can manifest clinically within 30 days after the index operation or delayed.<sup>14,15</sup>

Following the market introduction of active-fixation leads, some observers were concerned about a seemingly rising number of lead-related cardiac perforations.<sup>5,13,15</sup> One large and most recently published case series with 31 patients showed that cardiac perforation occurred only after use of an active-fixation lead.<sup>16</sup> By contrast, our study reported perforation of passive fixation leads in four of 56 patients (7%). Considering the exclusive use of active-fixation leads in our department and primary use of such leads in other referring hospitals, this low percentage is not surprising. This finding is corroborated by another study in which the fixation mechanism had no effect on the incidence of cardiac perforation.<sup>17</sup> Further factors associated with cardiac perforation in other studies were the use of temporary pacemakers and steroids, advanced age, female sex, and low body weight.<sup>7,9,18–21</sup>

However, the place of fixation in the cardiac chambers seems to influence the risk of perforation, as the majority of perforated leads in our study were implanted in the RV free wall or apex (Figures 2 and 4). This is not surprising, as the thickness of the RV wall in these regions is only 3–5 mm.<sup>22</sup> In addition, an RV systolic pressure >35 mm Hg, probably associated with an increase in wall thickness, was identified as the only protective factor in another study.<sup>18</sup> Fixation of RV leads at the interventricular septum seems to be associated with a significantly lower perforation risk due to the thicker myocardium.<sup>5,23</sup> Therefore, this appears to be the preferred place of implantation.<sup>17,24,25</sup>

The typical history of patients with delayed perforation includes breath-dependent thoracic pain. Usually, the pain has a sudden onset at the time of lead perforation, which can be associated with symptomatic phrenic nerve stimulation in a larger proportion of patients (30% in our

study), stimulation of the chest wall, or loss of capture with corresponding symptoms.<sup>26</sup> These complaints typically occur within the first 30 days after implantation. Since the perforated lead acts as a “plug” and the myocardium of the RV has self-sealing properties to some amount, pericardial effusion is rare in these patients. On the other hand, most of the patients (69% in our study) with pericardial effusion presented later than 30 days after the primary implantation. In these patients the predominant symptom was shortness of breath, which had developed slowly over weeks—a sudden pain event was usually not reported. This indicates that the pericardial effusion has increased slowly, and that other mechanisms are likely to be involved in its progression, such as inflammation of the pericardium by the tip of the lead screw.

In addition to a detailed medical history, device interrogation, chest X-ray, and TTE should all be performed to confirm the diagnosis if perforation is suspected. These readily available examinations allow the correct diagnosis in more than two thirds of the patients. Device interrogation typically shows a rise in threshold and/or fall in impedance and sensing at the perforated electrode, even a complete loss of capture resulting in symptomatic bradycardia can occur (Figure 1). The cardiac CT-scan can be a valuable tool when other imaging modalities are non-diagnostic, as it has a high accuracy in diagnosing lead-related cardiac perforation (Figures 2 and 3).<sup>27,28</sup> However, the occurrence of significant artifacts in the course of the leads renders the accurate assessment of the lead tip very difficult. As a result, the perforation rate is likely to be significantly overestimated in cardiac CT-scans.<sup>29</sup> Therefore, incidentally detected apparently perforated leads in asymptomatic patients without evidence of pericardial effusion or abnormalities during device interrogation should not be revised in our opinion.

A cardiac tamponade as a late complication after device implantation is extremely rare. In case of hemodynamic relevance, a pericardiocentesis should be performed. The closed pericardiocentesis with insertion of a 6F pigtail catheter for drainage was the appropriate treatment for all patients in our study. A surgical intervention should be considered in case of rapid progression of the pericardial effusion, other visceral injuries, or if closed pericardiocentesis failed. After the intervention, close hemodynamic and echocardiographic monitoring is required in order to recognize repeat tamponade in a timely manner. If tamponade is treated promptly and successfully, there are no long-term consequences for the patient.<sup>30</sup>

Older case reports described the management of cardiac perforation in different scenarios, where mostly surgical extraction of the leads was used.<sup>26</sup> However, nowadays transvenous lead extraction is the preferred method for removing nonfunctioning or infected leads. This approach has shown to significantly reduce the patient's morbidity as compared to open surgical extraction and may also be applied in the management of leads with cardiac perforation.<sup>31–34</sup> None of the patients in our study required cardiac surgery, and only one patient suffered from a significant pericardial effusion after extraction of the perforated lead. Therefore, the results of our study clearly show that transvenous extraction of leads with cardiac perforation is safe and feasible and should be the preferred treatment.

## 5 | LIMITATIONS

Patients were not prospectively randomized to either treatment, which is difficult to perform if not impossible. Furthermore, we cannot calculate the risk of perforation because many patients were referred from peripheral hospitals, and we do not know the total number of implantations. As such, it is not possible to define risk factors for cardiac perforation or the occurrence of cardiac tamponade.

## 6 | CONCLUSIONS

Cardiac perforation following CIED implantation is a rare complication but associated with severe complications in nearly one third of the patients. Transvenous revision of the perforated lead is safely feasible with a very low complication rate. The RV apex and free wall, as the most frequent perforated sites, should be avoided for RV lead implantation.

### ACKNOWLEDGMENTS

Open access funding enabled and organized by Projekt DEAL.

### CONFLICT OF INTEREST

Michael Döring, Andreas Müssigbrodt, Micaela Ebert, Kerstin Bode, Johannes Lucas, Nikolaos Dagres, Gerhard Hindricks, and Sergio Richter report research grants from Abbott, Biotronik, Boston Scientific, and Medtronic to the institution without personal financial benefits.

### ORCID

Michael Döring MD  <https://orcid.org/0000-0003-1372-3438>

### REFERENCES

1. Brignole M, Auricchio A, Baron-Esquivias G, et al. 2013 ESC guidelines on cardiac pacing and cardiac resynchronization therapy: the task force on cardiac pacing and resynchronization therapy of the European Society of Cardiology (ESC). Developed in collaboration with the European Heart Rhythm Association (EHRA). *Eur Heart J*. 2013;34:2281-2329.
2. Priori SG, Blomstrom-Lundqvist C, Mazzanti A, et al. 2015 ESC guidelines for the management of patients with ventricular arrhythmias and the prevention of sudden cardiac death: the task force for the management of patients with ventricular arrhythmias and the prevention of sudden cardiac death of the European Society of Cardiology (ESC). Endorsed by: Association for European Paediatric and Congenital Cardiology (AEPC). *Eur Heart J*. 2015;36:2793-252867.
3. Ponikowski P, Voors AA, Anker SD, et al. 2016 ESC guidelines for the diagnosis and treatment of acute and chronic heart failure: the task force for the diagnosis and treatment of acute and chronic heart failure of the European Society of Cardiology (ESC). Developed with the special contribution of the Heart Failure Association (HFA) of the ESC. *Eur Heart J*. 2016;37:2129-2200.
4. Kirkfeldt RE, Johansen JB, Nohr EA, Jorgensen OD, Nielsen JC. Complications after cardiac implantable electronic device implantations: an analysis of a complete, nationwide cohort in Denmark. *Eur Heart J*. 2014;35:1186-1194.
5. Sterlinski M, Przybylski A, Maciag A, et al. Subacute cardiac perforations associated with active fixation leads. *Europace*. 2009;11:206-212.
6. Ohlow MA, Lauer B, Brunelli M, Geller JC. Incidence and predictors of pericardial effusion after permanent heart rhythm device implantation: prospective evaluation of 968 consecutive patients. *Circ J*. 2013;77:975-981.
7. Cano O, Andres A, Alonso P, et al. Incidence and predictors of clinically relevant cardiac perforation associated with systematic implantation of active-fixation pacing and defibrillation leads: a single-centre experience with over 3800 implanted leads. *Europace*. 2017;19:96-102.
8. Silva KR, Albertini CM, Crevelari ES, et al. Complications after surgical procedures in patients with cardiac implantable electronic devices: results of a prospective registry. *Arq Bras Cardiol*. 2016;107:245-256.
9. Maziarz A, Zabek A, Malecka B, Kutarski A, Lelakowski J. Cardiac chambers perforation by pacemaker and cardioverter-defibrillator leads. Own experience in diagnosis, treatment and preventive methods. *Kardiol Pol*. 2012;70:508-510.
10. Bongiorni MG, Burri H, Deharo JC, et al. 2018 EHRA expert consensus statement on lead extraction: recommendations on definitions, endpoints, research trial design, and data collection requirements for clinical scientific studies and registries: endorsed by APHRS/HRS/LAHS. *Europace*. 2018;20:1217.
11. Bode K, Whittaker P, Lucas J, et al. Deep sedation for transvenous lead extraction: a large single-centre experience. *Europace*. 2019;21:1246-1253.
12. Rav Acha M, Rafael A, Keaney JJ, et al. The management of cardiac implantable electronic device lead perforations: a multicentre study. *EP Europace*. 2019;21:937-943.
13. Sivakumaran S, Irwin ME, Gulamhusein SS, Senaratne MP. Post-pacemaker implant pericarditis: incidence and outcomes with active-fixation leads. *Pacing Clin Electrophysiol*. 2002;25:833-837.
14. Piekarz J, Lelakowski J, Rydlewska A, Majewski J. Heart perforation in patients with permanent cardiac pacing - pilot personal observations. *Arch Med Sci*. 2012;8:70-74.
15. Khan MN, Joseph G, Khaykin Y, Ziada KM, Wilkoff BL. Delayed lead perforation: a disturbing trend. *Pacing Clin Electrophysiol*. 2005;28:251-253.
16. Huang XM, Fu HX, Zhong L, et al. Outcomes of lead revision for myocardial perforation after cardiac implantable electronic device placement. *J Cardiovasc Electrophysiol*. 2014;25:1119-1124.
17. Migliore F, Zorzi A, Bertaglia E, et al. Incidence, management, and prevention of right ventricular perforation by pacemaker and implantable cardioverter defibrillator leads. *Pacing Clin Electrophysiol*. 2014;37:1602-1609.
18. Mahapatra S, Bybee KA, Bunch TJ, et al. Incidence and predictors of cardiac perforation after permanent pacemaker placement. *Heart Rhythm*. 2005;2:907-911.
19. Akyol A, Aydin A, Erdinler I, Oguz E. Late perforation of the heart, pericardium, and diaphragm by an active-fixation ventricular lead. *Pacing Clin Electrophysiol*. 2005;28:350-351.
20. Hsu JC, Varosy PD, Bao H, Dewland TA, Curtis JP, Marcus GM. Cardiac perforation from implantable cardioverter-defibrillator lead placement: insights from the national cardiovascular data registry. *Circ Cardiovasc Qual Outcomes*. 2013;6:582-590.
21. Lin YS, Hung SP, Chen PR, et al. Risk factors influencing complications of cardiac implantable electronic device implantation: infection, pneumothorax and heart perforation: a nationwide population-based cohort study. *Medicine (Baltimore)*. 2014;93:e213.
22. Prakash R. Determination of right ventricular wall thickness in systole and diastole. Echocardiographic and necropsy correlation in 32 patients. *Br Heart J*. 1978;40:1257-1261.
23. Kondoh H, Funatsu T, Taniguchi K. Late left ventricular perforation by active fixation pacemaker lead implanted in the right ventricular septum. *J Cardiothorac Surg*. 2012;27:530-531.

24. Schwerg M, Stockburger M, Schulze C, et al. Clinical, anatomical, and technical risk factors for postoperative pacemaker or defibrillator lead perforation with particular focus on myocardial thickness. *Pacing Clin Electrophysiol*. 2014;37:1291-1296.
25. Iribarne A, Sangha RS, Bostock IC, Rothstein ES, McCullough JN. Right ventricular lead perforation through the septum, left ventricle, and pleura, managed by an open surgical approach. *HeartRhythm Case Rep*. 2018;4:397-400.
26. Refaat MM, Hashash JG, Shalaby AA. Late perforation by cardiac implantable electronic device leads: clinical presentation, diagnostic clues, and management. *Clin Cardiol*. 2010;33:466-475.
27. Rajkumar CA, Claridge S, Jackson T, et al. Diagnosis and management of iatrogenic cardiac perforation caused by pacemaker and defibrillator leads. *Europace*. 2017;19:1031-1037.
28. Henrikson CA, Leng CT, Yuh DD, Brinker JA. Computed tomography to assess possible cardiac lead perforation. *Pacing Clin Electrophysiol*. 2006;29:509-511.
29. Hirschl DA, Jain VR, Spindola-Franco H, Gross JN, Haramati LB. Prevalence and characterization of asymptomatic pacemaker and ICD lead perforation on CT. *Pacing Clin Electrophysiol*. 2007;30:28-32.
30. Polin GM, Zado E, Nayak H, et al. Proper management of pericardial tamponade as a late complication of implantable cardiac device placement. *Am J Cardiol*. 2006;98:223-225.
31. Kusumoto FM, Schoenfeld MH, Wilkoff BL, et al. HRS expert consensus statement on cardiovascular implantable electronic device lead management and extraction. *Heart Rhythm*. 2017;14:e503-e551.
32. Wilkoff BL, Love CJ, Byrd CL, et al. Transvenous lead extraction: Heart Rhythm Society expert consensus on facilities, training, indications, and patient management: this document was endorsed by the American Heart Association (AHA). *Heart Rhythm*. 2009;6:1085-1104.
33. Rusanov A, Spotnitz HM. A 15-year experience with permanent pacemaker and defibrillator lead and patch extractions. *Ann Thorac Surg*. 2010;89:44-50.
34. Camboni D, Wollmann CG, Loher A, Gradaus R, Scheld HH, Schmid C. Explantation of implantable defibrillator leads using open heart surgery or percutaneous techniques. *Ann Thorac Surg*. 2008;85:50-55.

**How to cite this article:** Döring M, Müssigbrodt A, Ebert M, et al. Transvenous revision of leads with cardiac perforation following device implantation—Safety, outcome, and complications. *Pacing Clin Electrophysiol*. 2020;43:1325–1332. <https://doi.org/10.1111/pace.14056>