



Universiteit
Leiden
The Netherlands

SELNET clinical practice guidelines for soft tissue sarcoma and GIST

Blay, J.Y.; Hindi, N.; Bollard, J.; Aguiar, S.; Angel, M.; Araya, B.; ... ; Martin-Broto, J.

Citation


Blay, J. Y., Hindi, N., Bollard, J., Aguiar, S., Angel, M., Araya, B., ... Martin-Broto, J. (2022). SELNET clinical practice guidelines for soft tissue sarcoma and GIST. *Cancer Treatment Reviews*, 102. doi:10.1016/j.ctrv.2021.102312

Version: Publisher's Version

License: [Creative Commons CC BY 4.0 license](#)

Downloaded from: <https://hdl.handle.net/1887/3276578>

Note: To cite this publication please use the final published version (if applicable).



Tumour Review



SELNET clinical practice guidelines for soft tissue sarcoma and GIST

J.Y. Blay^{a,*}, N. Hindi^b, J. Bollard^a, S. Aguiar Jr.^c, M. Angel^d, B. Araya^e, R. Badilla^e, D. Bernabeu^f, F. Campos^c, C.H.S. Caro-Sánchez^g, B. Carvajal^h, A. Carvajal Montoya^e, S. Casavilca-Zambranoⁱ, V. Castro-Olidenⁱ, M. Chacón^d, M. Clara^g, P. Collini^j, R. Correa Genoroso^k, F.D. Costa^c, M. Cuellar^h, A.P. dei Tos^l, H.R. Dominguez Malagon^g, D. Donati^m, A. Dufresne^a, M. Erikssonⁿ, M. Farias-Lozaⁱ, P. Fernandez^o, A.M. Frezza^j, T. Frisoni^m, D.Y. Garcia-Ortega^g, H. Gelderblom^p, F. Gouin^a, M.C. Gómez-Mateo^q, A. Gronchi^j, J. Haroⁱ, L. Huancaⁱ, N. Jimenez^e, M. Karanian^a, B. Kasper^r, B.B. Lopes David^j, A. Lopez-Pousa^s, G. Lutter^d, H. Martinez-Said^t, J. Martinez-Tlahuel^g, C.A. Mello^c, J. Morales Pérez^u, S. Moura David^u, A.G. Nascimento^c, E.J. Ortiz-Cruz^v, E. Palmerini^m, S. Patel^w, Y. Pfluger^d, S. Provenzano^j, A. Righi^m, A. Rodriguez^d, R. Salas^h, T.T.G. Santos^c, K. Scotlandi^m, T. Soule^d, S. Stacchiotti^j, C. Valverde^x, F. Waisberg^d, E. Zamora Estrada^e, J. Martin-Broto^b

^a Léon Bérard Center, 28 rue Laennec 69373 Lyon Cedex 08, France

^b Research Health Institute Fundación Jimenez Diaz (IIS/FJD), 28015 Madrid, Spain; Hospital Fundación Jimenez Diaz University Hospital, 28040 Madrid, Spain; General de Villalba University Hospital, 28400 Madrid, Spain

^c A.C. Camargo Cancer Center, Rua prof Antonio Prudente, 211 - Liberdade, São Paulo - SP 01509-010, Brazil

^d Instituto Alexander Fleming, Av. Cramer 1180. CP C1426ANZ, Buenos Aires, Argentina

^e Hospital Dr. R. A. Calderón Guardia, 7-9 Av, 15-17 St, Aranjuez, San José, Costa Rica

^f Hospital Universitario La Paz, Paseo de la Castellana, 261, 28046 Madrid, Spain

^g Instituto Nacional de Cancerología. Torre Nueva de Hospitalización, primer piso. Av. San Fernando 86, Colonia Niño Jesús. CP 14080, Tlalpan Mexico

^h Fundación GIST México, Altagena 59, Nápoles, Benito Juárez, 03810 Ciudad de Mexico, CDMX, Mexico

ⁱ Instituto Nacional de Enfermedades Neoplásicas, Av. Angamos Este 2520, Lima 34, Peru

^j Fondazione IRCCS Istituto Nazionale dei Tumori, Via Giacomo Venezian, 1, 20133 Milano, Italy

^k Hospital Clínico Universitario Virgen de la Victoria, Campus Universitario de Teatinos s/n, 29010 Malaga, Spain

^l Treviso General Hospital Treviso, University of Padua, Padova, Italy

^m IRCCS Istituto Ortopedico Rizzoli, University of Bologna, Via Pupilli, 1, 40136 Bologna, Italy

ⁿ Skane University Hospital and Lund University, Lund, Sweden

^o Fundación GIST Chile

^p Leiden University Medical Center, Leiden, the Netherlands

^q Hospital Universitario Miguel Servet, Paseo Isabel la Católica, 1-3, 50009 Zaragoza, Spain

^r University of Heidelberg, Mannheim Cancer Center, Theodor-Kutzer-Ufer 1-3, 68167 Mannheim, Germany

^s Hospital de la Santa Creu i Sant Pau, Carrer de Sant Quintí, 89, 08041 Barcelona, Espagne

^t Centro Oncológico Integral, Hospital Medica Sur, Planta Baja Torre III - Cons. 305, Col. Toriello Guerra, Deleg. Tlalpan. C.P. 14050, Mexico, D.F

^u Hospital Universitario Virgen del Rocío, Av Manuel Siurot s/n, 41013 Sevilla, Spain

^v Hospital Universitario La Paz, MD Anderson Cancer Center, Calle de Arturo Soria, 270 28033 Madrid, Spain

^w UT MD Anderson Cancer Center, Houston, TX, USA

^x Vall d'Hebrón University Hospital, Passeig de la Vall d'Hebrón, 119, 08035 Barcelona, Spain

Introduction

Soft tissue sarcoma (STS) is a heterogeneous group of neoplasms, encompassing > 80 different histologic subtypes. Approximately three

quarter of sarcoma arise from soft-tissue, about 15% are gastrointestinal stromal tumours (GISTs) and bone sarcoma represent the remaining 10%. The current guidelines will focus on soft-tissue and GIST, excluding Kaposi sarcoma and non-pleomorphic rhabdomyosarcoma.

* Corresponding author at: Centre Léon Bérard, 28 rue Laennec, 69373 Lyon Cedex 08, France.

E-mail address: jean-yves.blay@lyon.unicancer.fr (J.Y. Blay).

<https://doi.org/10.1016/j.ctrv.2021.102312>

Received 20 October 2021; Accepted 30 October 2021

Available online 14 November 2021

0305-7372/© 2022 The Authors. Published by Elsevier Ltd. This is an open access article under the CC BY license (<http://creativecommons.org/licenses/by/4.0/>).

Bone sarcomas are covered in a different paper.

General statements

- Management of soft tissue, visceral, and bone sarcoma should be carried out within multidisciplinary reference centres for sarcoma [III, A] [1]. Multidisciplinary tumour boards (MDTB) should include at least the following specialties: medical oncology, paediatrics (if paediatric patients are discussed), radiology, surgery, pathology and radiation oncology.
- A MDTB cannot be defined only by the volume of patients followed, but also by the periodicity of meeting (weekly MDTB is recommended), its contribution to clinical trials and scientific production and its participation in national or international guidelines. These MDTB should ideally be periodically audited to ensure quality.
- All diagnostic procedures and therapeutic decisions should be discussed within a MDTB.
- Several reports indicate better clinical results and better cost-effectiveness if sarcoma or presumptive sarcoma patients are managed in sarcoma reference centres with MDTB discussion [III, A] [2–5].

Soft tissue sarcoma

Incidence

Soft tissue sarcomas are rare tumours, with an estimated incidence of approximately 9 new cases/100,000 inhabitants/ year in Europe [6]. Incidence in other areas, such as Latin-American countries is difficult to estimate due to the lack of registries [7,8].

Diagnosis and pathology/molecular biology

All diagnostic procedures in patients with suspicion of soft-tissue sarcoma should be discussed within a multidisciplinary tumour board (MDTB).

During the diagnostic course, in patients with superficial lesions > 5 cm and deep lesions of any size, imaging and biopsy before surgery are strongly recommended. For primary tumours of the limb, trunk wall and pelvis, MRI is the preferred recommended imaging test. CT scan is recommended for any other site, or as a MRI alternative [III, A]. A core needle biopsy is recommended for the diagnosis of soft tissue or visceral lesions > 3 cm [III, A]. An adequate procedure to perform biopsies should include imaging guidance to avoid any suspected area of necrosis, use of G14 or G16 needles with coaxial introducer for a single skin entrance, and 4 to 6 cores varying the angle into the tumour [III, A]. Pathological diagnosis should be made according to the most recent WHO classification and histological grading should be based on the FNCLCC system [III, A]. Central pathological review by an expert sarcoma pathologist is strongly recommended [III, A]. Cases should be referred to molecular pathology tests whenever morphology and immunohistochemistry are not enough for a precise diagnosis and/or when additional prognostic/predictive information is required [III, A]. Grade should be established always prior to treatment based on the core biopsy. When neoadjuvant treatment is administered, pathological findings should be quantified and reported in terms of residual viable (stainable) tumour cells and their mitotic index, and percentage of post-treatment changes (necrosis, sclerothyalinosis, fibrosis, fibrohistiocytic reaction, haemorrhage). Percentage of hypercellular/round cell component and adipocytic maturation should be noted in case of myxoid liposarcoma [9].

Staging and risk assessment

Imaging studies to evaluate the presence of distant metastasis are mandatory. To assess the presence of lung metastases, a chest CT scan is

recommended [III, A]. An abdominal and pelvic CT scan is recommended to rule out metastasis in special histologic subtypes with high metastatic potential (myxoid liposarcoma, epithelioid sarcoma, angiosarcoma, leiomyosarcoma, small-cell sarcomas) [III, A] [10]. Currently, spine and pelvic MRI is preferred in myxoid liposarcoma [IV, A], and a baseline brain MRI should be considered in alveolar soft-part sarcoma (ASPS), angiosarcoma and clear cell sarcoma [IV, A] due to their high risk of central nervous system spread. PET/CT scan and/or bone scintigraphy are optional and are advised in case of equivocal images and/or clinical bone involvement suspicion.

Risk stratification is assessed using composite tools which may vary according to histological subtype after central review, grade, primary site (see GIST section), tumour size and presence of metastasis [IV, A]. Nomograms are available for several locations [11–13] and those with reported validation studies (retroperitoneal and limb soft tissue sarcomas) should be used.

Management of local disease

For patients with an adult type localized STS, surgery is the standard treatment. This procedure must be performed by a surgeon, specifically trained for the treatment of this group of diseases [1]. Surgery should always be preceded by an expert sarcoma MDTB discussion. The standard surgical procedure is a wide excision (*en bloc* resection) with negative margins (R0) [II, A] [14] and limb salvage procedure whenever feasible. In some special situations, reconstructive surgery should be taken into account and plastic surgery can facilitate the reconstruction of wide soft-tissue sarcoma surgeries. When despite of neo- or adjuvant treatments the achievement of an adequate margin with a functional limb is not feasible, amputation should be considered and discussed in a specialized MDTB [III, A] [14]. Pathologically confirmed or clinically evident lymph nodes should be resected but elective node dissection is not recommended. Adjuvant RT or chemotherapy (ChT) do not compensate for an improper first or second surgery. Re-excision by an expert team should be discussed in a MDTB in this situation, especially when surgery was performed outside a reference centre [III, A]. Local re-staging has to be performed in order to plan an adequate re-excision. Postoperative hematoma is considered a tumour contamination and must be included in the surgical tumour bed of re-excision. In the case of R2 surgery (macroscopic residual tumour after surgery), re-operation is mandatory, and preoperative treatments should be considered when adequate oncology margins cannot be achieved, depending on the histological subtype. Re-excision should be discussed when the oncological margins are not satisfactory even after planned surgeries. However, if it is impossible to obtain a greater or better margin, due to its anatomical location, radiotherapy (RT) should be considered. Marginal resections with microscopically positive margins (R1) may be appropriate for extracompartmental atypical lipomatous tumours. Wide excision procedure is followed by RT as the standard treatment in cases with at least one of the following risk factors: high-grade (G2-3), deep, >5 cm lesions [II, A] [15–17]. Exception may be made after MDTB discussions considering site and comorbidities [II, A] [16]. RT may be avoided for G1, R0, <5cm, superficial tumours of the limbs and trunk wall [IV, B]. In cases of G1, > 5 cm and deep tumours, RT should be validated with a MDTB [18]. Preoperative or postoperative RT are equally acceptable with different side-effect profile in a mid and long-term [II, A] [19]. In some locations (e.g. head and neck), postoperative RT is preferred. As for surgery, preoperative RT should always be discussed on MDTB [18]. The time frame between end of preoperative RT and surgery or surgery and the initiation of adjuvant RT should be 4–6 weeks, though longer intervals may be needed in case of clinical constraints (delayed wound healing) [IV, D] [20,21].

Adjuvant ChT is not a standard treatment and is not recommended in chemotherapy non-responsive histologic subtypes (for example, ASPS, clear cell sarcoma, well/dedifferentiated liposarcoma) [22]. There are conflicting results in literature regarding its value, mainly in relation to

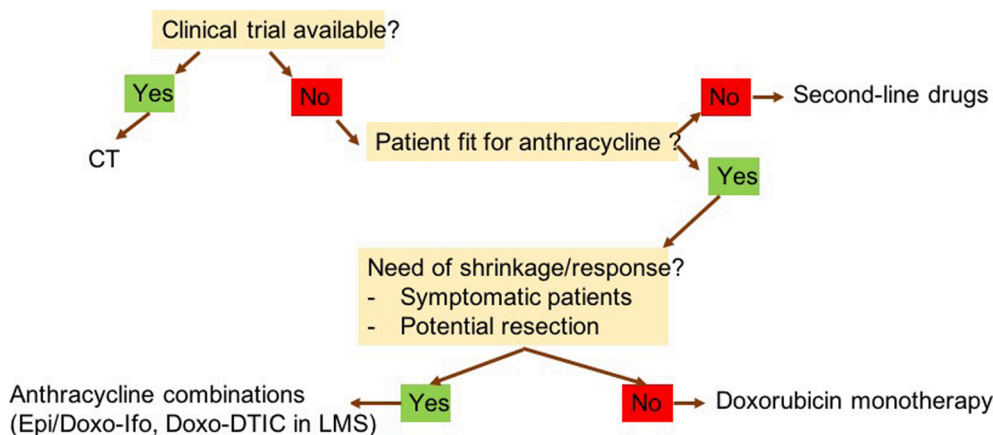


Fig. 1. Algorithm for selection of first line therapy in advanced STS CT: clinical trial; Epi: epirubicin; Doxo: doxorubicin; Ifo: ifosfamide.

the poor selection of high-risk patients and inadequate use of dose intensity in the administered regimens. The application of validated nomograms in a negative large randomized trial evaluating the role of adjuvant ChT [23], virtually converted it into a positive study, showing a significant benefit in disease-free survival and overall survival (OS) in the high-risk population [24].

Those randomized trials selecting high-risk localized limb or trunk-wall STS with the highest dose intensity of the two most active drugs (anthracyclines and ifosfamide) consistently showed a 5-y OS above 70% [22,25,26]. A meta-analysis that incorporated comparative trials with these drugs reported statistically significant survival benefit favouring ChT arm. Yet, this meta-analysis was not based on individual data [27].

Perioperative ChT (preferably neoadjuvant) should be considered in the context of patients with high-risk localized STS of limbs and trunk-wall [II, A] [22,25,28,29]. Tumours > 5 cm, G3 and deep located have been used as high-risk population criteria. However, high-risk could be more precisely defined by validated nomograms as death risk higher than 40% [26]. The combination of anthracycline and ifosfamide at full doses with G-CSF and MESNA support is the recommended scheme being three cycles as effective as five in a randomized trial [II, A] [22]. Further randomized clinical trials evaluating the role of perioperative ChT are needed, and patient participation is strongly encouraged.

Management of advanced/metastatic disease

The presence of distant metastasis is a poor prognostic factor for OS, ranging currently 18–20 months [30,31]. However, a fraction of patients with advanced sarcoma could benefit from long term remission, especially those reaching a complete response and a smaller percentage of those obtaining partial response after first line of treatment for advanced disease [32].

Supportive care and quality of life evaluation should be included in the early management of all patients with advanced sarcoma [33]. When complete excision of all lesions is feasible, surgery can be a preferable treatment option for metachronous (disease-free interval ≥ 1 year) metastatic appearance when the number of nodes is limited (i.e. 3–5) and without extrapulmonary disease [IV, B]. This strategy could also be offered to patients with oligometastatic disease located at others sites (liver, soft tissue) [V, B] [34], after discussion in MDTB. In selected cases, stereotactic radiotherapy might also be recommended in this setting after discussion in MDTB [IV, C] [35].

First-line standard ChT treatment is based on anthracyclines [I, A]. In particular subtypes, with greater sensitivity to ifosfamide, such as synovial sarcoma and undifferentiated pleomorphic sarcoma (UPS), and/or when a tumour response could be potentially advantageous, and in

Table 1

Recommendations on second line options in advanced STS based on histologic subtype UPS: undifferentiated pleomorphic sarcoma; HDIFO: high-dose ifosfamide; MPNST: Malignant peripheral nerve sheath tumour.

HISTOLOGIC SUBTYPE	PREFERENTIAL OPTIONS	LESS PREFERENTIAL SUBTYPE
LEIOMYOSARCOMA	Gemcitabine combinations, Trabectedin, Pazopanib	Ifosfamide
UPS	Gemcitabine combinations, Trabectedin, Ifosfamide	Pazopanib
SYNOVIAL SARCOMA	HDIFO, Trabectedin	Gemcitabine combinations, Pazopanib
WD/DD LIPOSARCOMA	Eribulin, Trabectedin, HDIFO	Gemcitabine combinations
MYXOID LIPOSARCOMA	Trabectedin, Eribulin	Gemcitabine combinations, Ifosfamide
MPNST	Ifosfamide-etoposide, HDIFO	Trabectedin, Gemcitabine, Pazopanib
ANGIOSARCOMA	Taxanes, Gemcitabine, Pazopanib	Trabectedin

patients with good performance status multi-agent ChT with adequate-dose anthracyclines plus ifosfamide may be the preferential treatment option [I, B]. [36,37]. For leiomyosarcoma, doxorubicin and dacarbazine could be considered, instead of anthracyclines plus ifosfamide, since this latter could be even detrimental in this specific subtype according to retrospective comparisons. [IV, B] [38]. The combination of gemcitabine plus docetaxel is not recommended as a first-line option for the treatment of advanced STS [39]. The inclusion of patients with advanced STS in clinical trials should be encouraged whenever available (Fig. 1).

Beyond first-line, there are several second-line options (Table 1, Fig. 2):

- High-dose ifosfamide (12–14 g/m²/cycle, administered in 6 days or in 14 days with G-CSF and MESNA support) can circumvent the tumour resistance to regimens with moderate doses of ifosfamide [I, D] [40].
- If available, trabectedin can be used for second line in pretreated STS, especially but not exclusively in liposarcoma, leiomyosarcoma and translocation-related sarcomas [II, B] [41–43]. Nevertheless, the EU approval does not limit its use to these entities since it can be active in other histological subtypes [44].
- The combination of trabectedin and low dose of radiation therapy has been observed to be feasible and active [45]. This could be taken into account when shrinkage is crucial to palliate symptoms in second line [III, A].

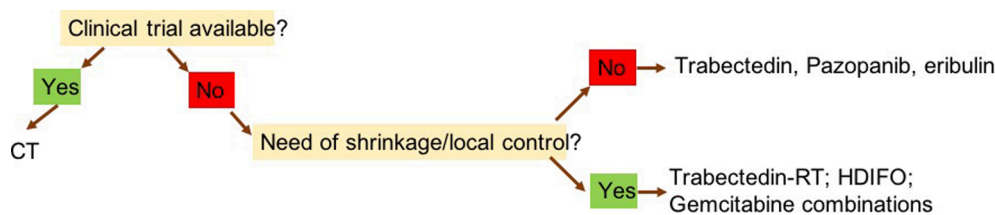


Fig. 2. Algorithm for selection of second line therapies in advanced STS CT: clinical trial; RT: radiotherapy; HDIFO: high-dose ifosfamide.

- Pazopanib is an option except for adipogenic STS after progression to standard chemotherapy [II, E] [46].
- For patients with extraskeletal myxoid chondrosarcoma [47], solitary fibrous tumour [48,49], and other anti-angiogenic sensitive histotypes such as ASPS [50], pazopanib, if available, could be considered as upfront therapy. If it is not available as first line, it should be considered for second line [III, A].
- Eribulin is a therapeutic option in second-lines for the treatment of patients with liposarcomas who have progressed after doxorubicin [II, B] [51].
- Despite not formally approved for sarcomas, the combination of gemcitabine and dacarbazine or gemcitabine and docetaxel are options in doxorubicin-pretreated patients especially, but not exclusively, in leiomyosarcoma and UPS [II, B] [52,53].
- Imatinib is standard medical therapy for those rare patients with locally advanced, unresectable or metastatic dermatofibrosarcoma protuberans [III, A] [55].
- Regorafenib is an option in doxorubicin-pretreated advanced, non-adipogenic STS patients, even after pazopanib [II, B] [56,57].
- There is some evidence, from non-randomized trials, that several molecular targeted agents are active in specific rare histologies. If available, the use of these agents could be an option after discussion in MDTB:
 - o mTOR inhibitors in malignant PEComas [III, B] [58–60];
 - o Crizotinib in inflammatory myofibroblastic tumours preferably associated with ALK translocations [III, B] [61,62];
 - o If available, NTRK inhibitors (entrectinib, larotrectinib) are an active option for advanced sarcomas with NTRK fusions [III, A] [63–65].
- Weekly paclitaxel [III, B] [66] and liposomal doxorubicin [IV, B] [67] are active options in angiosarcoma. The combination of propranolol plus vinblastine [IV, B] [68] has also shown some activity.
- Pazopanib, sorafenib or regorafenib are recommended as second line in vascular sarcomas [III, B] [56,69,70].
- Gemcitabine has shown single agent activity for both angiosarcoma and leiomyosarcoma [54]. It was equivalent to the gemcitabine/docetaxel combination in leiomyosarcoma -LMS- in a single clinical trial [II, C] [71].
- Immune checkpoint inhibitors (anti-PD1) should be used in the context of clinical trials. Nevertheless, notorious activity has been described in the context of advanced ASPS. In sarcoma, predictive biomarkers for these drugs are still lacking. Physicians should be encouraged to enrol patients into clinical trials to further refine their indications.

Special presentation and entities

- **Retroperitoneal sarcomas (RPS).** Patients with suspicion of RPS must be referred to centres with multidisciplinary teams and expertise in the management of RPS [III, A] [72]. Surgery (compartmental or *en bloc* resection) is the cornerstone for the treatment [73,74]. Based on a recently reported negative clinical trial on preoperative RT, this strategy is not recommended outside of a clinical trial [II, C] [75]. Ad-hoc analysis of STRASS study found a significant local control favouring RT administration in low-grade liposarcoma. Ongoing

studies are assessing the efficacy of preoperative ChT or Ch-RT. Postoperative RT should be avoided [IV, D].

- **Uterine sarcomas.** Uterine sarcomas include several sub-entities (LMS, endometrial stromal sarcoma -ESS-, undifferentiated uterine sarcoma) with completely different natural history. Pathology review and molecular biology tests are recommended. In localized disease, morcellation should be avoided [III, E] [76,77], and *en bloc* total hysterectomy is the standard local treatment. Adjuvant RT is not recommended as routine treatment [II, C] [78]. Adjuvant ChT is not recommended as routine treatment either but might be proposed by specialized MDTB in specific situations based on histologic subtype, clinical presentation or in case of tumour fragmentation [IV, C] [79,80]. For low-grade unresectable ESS, endocrine therapy such as aromatase inhibitors are recommended as first-line treatment [IV, B] [81,82]. These treatments should be proposed in clinical trials.
- **Desmoid-type fibromatosis (DF).** A wait-and-see policy can be advised in tumours which are not life threatening or asymptomatic [III, B] [83]. Surgery might be indicated for selected cases after discussion in MDTB. In symptomatic or progressive patients, if systemic therapy is feasible, sorafenib and pazopanib can be recommended as an option after MDTB discussion [II, B], as both showed to improve progression-free survival (PFS) over placebo and methotrexate-vinblastine respectively in 2 randomized trials [84,85]. NSAIDs, tamoxifen, toremifene, cytotoxics (methotrexate plus vinca alkaloids, anthracyclines) and imatinib can be options in view of prospective uncontrolled clinical trials [III, B] [86–90]. Radiotherapy is an option that has demonstrated long term tumour control in prospective and retrospective series [III, C] [91]. Symptomatic improvement and dimensional responses were reported after cryoablation, in small series after short follow-up [IV, C] [92].
- **Tenosynovial Giant Cell Tumour (TGCT).** Surgery represents the standard treatment in patients with localized and diffuse TGCT [III, A] [93,94]. Local relapse after surgery is common in diffuse-type TGCT, with reduced recurrence rates after open access approach as compared with arthroscopy in patients with knee TGCT [III, A] [95]. For unresectable patients, follow-up is an option. For symptomatic patients or to avoid surgical morbidities, imatinib [III, B], nilotinib [III, B] and pexidartinib [II, B] are recommended, if available [96–98].
- **Dermatofibrosarcoma protuberans:** Surgical removal is the mainstay of DFSP management. Mohs surgery is recommended when possible; large tumours may require wide local excision (margins of 3 cm) and reconstruction [99,100]. DFSP often present translocation involving a ligand of platelet-derived growth factor receptor (PDGFR). PDGFRs kinase inhibitor imatinib is the standard medical therapy for patients with DFSP not candidate for a mutilating surgery or with distant metastases [III, A] [55 101].

Follow-up

There is limited published evidence on the best follow-up program in resected localized STS. The main site of distant metastasis of STS is lung. Follow-up should include a physical examination, especially of the primary tumour site to rule out local relapse. Imaging studies of the local site should be preferably MRI in limb, trunk-wall and pelvic primary

tumours, and CT scan in abdominal and pulmonary primary tumours. Chest X-ray or thoracic CT scan usually are enough to rule out distant metastasis. In selected subtypes (see staging section), abdominal CT scan is included also.

The recommended follow-up policy after treatment completion is different between low-grade and high-grade STS. For high grade STS visits every 3–4 month for the first 2–3 years are recommended, then every 6 months for the fourth and fifth year, and then yearly at least up to the tenth year. For low grade STS patients, follow-up could be performed every 6 months for 5 years and annually thereafter [101].

Gastrointestinal stromal tumours (Gists)

Incidence

GISTs are rare tumours, with an estimated incidence of 1–2.8 new cases/100 000 inhabitants/year in Europe [102–104], but data on their incidence in other areas, such as Latin-American countries is unknown. GIST is the most frequent sarcoma in the gastrointestinal tract, being more frequent in stomach (50–60%), followed by ileum and jejunum (20–30%), duodenum (3–5%), rectum-anus (2–4.4%) and other sites (<2%). Extra-gastrointestinal GIST cases have been anecdotally described [105].

Diagnosis and pathology/molecular biology

If accessible, endoscopic ultrasound assessment should be carried out in patients with oesophagogastric or duodenal nodules < 2 cm. If not accessible, follow-up by CT scan is the initial standard approach [III, A]. The exception is rectal GIST, in which a biopsy and further local treatment should always be considered, irrespectively of size [III, A]. Biopsy (with transperitoneal microbiopsy) or excision is the standard approach to tumours ≥ 2 cm in size [III, A] [106]. Mitotic count (expressed if possible as the number of mitoses per 5 mm²), size, site and intra-abdominal tumour rupture need to be assessed and included in pathological report for risk stratification [III, A] [107]. KIT and platelet-derived growth factor alpha (PDGFRA) mutational analysis should always be considered especially for patients under treatment or who are candidates to systemic therapy [III, A] [105,108,109].

Staging and risk assessment

Endoscopy ultrasound is recommended for the initial assessment of oesophagogastric and duodenal nodules. Abdominal and pelvic CT scan (at least biphasic at baseline for a better detection of liver metastasis) and chest X-ray or CT scan, are recommended in addition to histological and molecular diagnosis [III,A]. MRI is recommended for pelvic and rectal GIST, and for the rare forms of oesophageal GIST [IV, B]. PET scan is not mandatory and could be an option for unknown primary, equivocal images, and anticipated evaluation of response to neoadjuvant treatment [IV, B] [110]. Chest CT scan (in addition to abdominal CT scan) is recommended in case of syndromic GIST [IV, B].

Risk assessment following heat maps are the recommended classification risk to take decisions. A higher than 40% recurrence risk should be taken into account to offer adjuvant imatinib [111]. The worse prognostic impact of some mutation types (i.e. deletions involving 557 and/or 558 in exon 11 of *KIT* gene) [112], could be also considered.

Management of local disease

The standard treatment of localized GISTs is complete surgical excision of the lesion (*en bloc* resection with no rupture), with no dissection of clinically negative lymph nodes [III, A]. Whenever possible, sparing surgery is recommended. If laparoscopic excision is planned by an expert surgical team, the technique needs to follow the principles of surgical oncology [III, A] [113,114]. When R0 surgery

implies major functional sequelae, and preoperative medical treatment is not effective, the decision can be made with the patient to accept the possibility of a R1 resection [IV, B]. Neoadjuvant imatinib is the standard treatment for locally advanced GIST for which upfront surgery with major sequelae cannot be avoided and/or R0 surgery is not feasible [115,116]. The optimal duration of neoadjuvant treatment is not known but the recommendation ranges between 6 and 12 months, based on emerging time of resistant clones [III, C]. Close monitoring of the response is recommended to avoid delayed local therapy in case of lack of response to neoadjuvant therapy [110,115,116]. Adjuvant therapy with imatinib for 3 years improves overall survival for patients with a significant risk of relapse [I, A] [117,118]. In case of neoadjuvant and postoperative imatinib, the overall duration of treatment should be completed up to 3 years. Wild-Type GIST, PDGFRA D842V-mutated GIST, succinate dehydrogenase (SDH)-deficient GIST and Neurofibromatosis (NF-1)-related GIST have not demonstrated to experience benefit from imatinib treatment. Thus, adjuvant imatinib in these contexts should be avoided. In patients with KIT exon 9 mutation, only a dose of 400 mg/d has been prospectively tested in the adjuvant setting [III, C] [119,120]. Given the data from advanced disease, the utility of adjuvant treatment at 800 mg/d should be considered within the MDTB and discussed with the patient, explaining potential risks and benefits of this strategy.

Management of advanced/metastatic disease

Tumour genotyping for driver molecular alterations (at least of KIT and PDGFRA) is strongly recommended [IV, A] [107,114].

Imatinib, at 400 mg daily, is the standard upfront treatment of locally advanced inoperable and metastatic disease, [I, A] [121,122]. Imatinib is also the standard treatment for patients with completely resected metastatic disease, although surgery is not recommended as a primary approach in the metastatic setting. Standard treatment of patients with KIT exon 9 mutation is 800 mg daily of imatinib [III, B] [123,124]. In the metastatic setting, treatment with imatinib should be indefinitely continued up to progression, intolerance or specific patient interruption request [I, A] [125]. Dose reductions (i.e. 300 mg or even lower doses) in the context of intolerance and efficacious treatment should be explored. A randomized clinical trial exploring the utility of surgical rescue of residual metastatic disease after imatinib was interrupted due to poor accrual [II, C]. Hence, this option should be individualized after the decision-making process with the patient [126,127]. Interventional techniques (radiosurgery, radiofrequency ablation -RFA-) are options in selected cases [IV, C] [128,129]. In the case of tumour progression on 400 mg of imatinib, the dose can be increased to 600–800 mg daily if accessible [III, B] (with the exception of insensitive mutations) [123,130].

In the case of confirmed progression or rare intolerance to imatinib, standard second-line treatment is sunitinib (50 mg/d, 4 weeks of therapy/2 weeks off) [I, A] [131]. The continuous dosing of 37.5 mg/d is an alternative option, although there is no formal prospective comparison with the intermittent dosing [132].

Regorafenib, at the dose of 160 mg daily for 3 out of every 4 weeks, is the standard third-line therapy for patients progressing on or failing to respond to imatinib and sunitinib [I, A] [133,134]. Treatment schedule (dose, duration, interruption) should be adapted to patient's tolerability. Rechallenge with imatinib could be an option with limited activity in patients progressing to all approved tyrosin-kinase inhibitors (TKI) options. [II, B] [135,136]. Some evidence exists that continuing a treatment with TKI is effective even in the context of slow progression. If available, ripretinib is recommended as 4th line for GIST progressing after imatinib, sunitinib and regorafenib [II, A] [137].

If available, avapritinib is recommended for PDGFRA D842V-mutated GIST [III, A] [138].

Table 2

Levels of evidence and grades of recommendations (adapted from the Infectious Disease Society of America-United States Public Health Service Grading System).

LEVELS OF EVIDENCE	DEFINITION
I	Evidence from <i>meta</i> -analyses (based on well conducted clinical trials) or at least one large randomized controlled trial with low potential for bias)
II	Small randomised trial or large randomized trials/ <i>meta</i> -analyses with suspicion of bias or heterogeneity
III	Prospective cohort studies
IV	Case-control or retrospective cohort studies
V	Case reports, expert opinions, studies without control group
GRADES OF RECOMMENDATION	
A	Strong evidence for efficacy and meaningful clinical benefit: strongly recommended.
B	Strong or moderate evidence for efficacy but restricted clinical benefit: generally recommended
C	Inadequate evidence for efficacy or clinical benefit not exceeding risks: optional
D	Moderate evidence against efficacy or poor outcome: generally not recommended
E	Strong evidence against efficacy or poor outcome: never recommended or contraindicated

Follow-up

Evidence on the optimal follow-up procedures of resected localized GIST is lacking. Liver and peritoneum are the most frequent sites of metastatic spread, being lymph nodes, bone and lungs much more infrequent sites, and usually associated to heavily pretreated patients or with syndromic GIST. Thus, follow-up has to include abdominal CT scan or MRI. Follow-up procedures should be adapted to risk. High-risk patients are at a higher risk of relapse in the first 3 years after completion of adjuvant therapy. We recommend follow-up with an abdominal CT scan or MRI every 3–6 months during adjuvant therapy and then, after completion of adjuvant therapy, CT scan or MRI every 3 months for 2–3 years, then every 6 months until the fifth year from adjuvant completion, and then annually. For low-risk tumours, the utility of a periodic follow-up is unknown. We recommend, if possible, abdominal CT scan or MRI, every 6–12 months for 5 years.

Methodology

The Sarcoma European Latin-American Network (SELNET) aims to improve clinical outcome in sarcoma care, with a special focus in Latin-American countries.

These Clinical Practice Guidelines (CPG) have been agreed by a multidisciplinary group of the SELNET consortium, with representatives of all partner entities including patient's advocacy groups (SPAEN). These guidelines are conceived to provide the standard approach to diagnosis, treatment and follow-up in STS and GISTs in the Latin-American context. The previous recommendations are based on evidence are supported by published medical peer-reviewed data. Hence, the recommendations should be considered 'standard' approaches, and were supported by the highest level of evidence. Several virtual meetings were held to elaborate a draft of the guidelines and an on-site consensus meeting was celebrated in Lyon (France). Final version of the guidelines was circulated and agreed by all CPG working group members.

The levels of evidence and grades of recommendation have been followed and applied using the system presented in Table 2. For those recommendations hardly supported or non-supported by evidence, a multidisciplinary consensus was reached in accordance to professional expertise.

Declaration of Competing Interest

The authors declare that they have no known competing financial interests or personal relationships that could have appeared to influence the work reported in this paper.

Acknowledgements

The authors would like to thank the SELNET project, which has received funding from the EU Horizon 2020 research and innovation programme (grant number 825806). JMB, NH, JB, APDT, AMF, SS, HG, FG, AG, MK, JYB, EP, are also supported by EURACAN ERN (EC 739521).

References

- Casali PG, Abecassis N, Aro HT, Bauer S, Biagini R, Bielack S, et al. Soft tissue and visceral sarcomas: ESMO-EURACAN Clinical Practice Guidelines for diagnosis, treatment and follow-up. *Ann Oncol* 2018;29:iv268–9. [10.1093/annonc/ndy321](https://doi.org/10.1093/annonc/ndy321).
- Perrier L, Buja A, Mastrangelo G, Vecchiato A, Sandonà P, Ducimetière F, et al. Clinicians' adherence versus non adherence to practice guidelines in the management of patients with sarcoma: a cost-effectiveness assessment in two European regions. *BMC Health Serv Res* 2012;12(1). <https://doi.org/10.1186/1472-6963-12-82>.
- Martin-Broto J, Hindi N, Cruz J, Martinez-Trufero J, Valverde C, De Sande LM, et al. Relevance of Reference Centers in Sarcoma Care and Quality Item Evaluation: Results from the Prospective Registry of the Spanish Group for Research in Sarcoma (GEIS). *Oncologist* 2019;24(6). <https://doi.org/10.1634/theoncologist.2018-0121>.
- Blay J-Y, Honoré C, Stoeckle E, Meeus P, Jafari M, Gouin F, et al. Surgery in reference centers improves survival of sarcoma patients: a nationwide study. *Ann Oncol Off J Eur Soc Med Oncol* 2019;30:1407. <https://doi.org/10.1093/annonc/mdz170>.
- Trovik CS. Scandinavian Sarcoma Group Project. Local recurrence of soft tissue sarcoma. A Scandinavian Sarcoma Group Project. *Acta Orthop Scand Suppl* 2001; 72:1–31.
- de Pinieux G, Karanian M, Le Loarer F, et al. Nationwide incidence of sarcomas and connective tissue tumors of intermediate malignancy over four years using an expert pathology review network. *PLoS One*. 2021;16:e0246958. <https://doi.org/10.1371/journal.pone.0246958>.
- Chávez M, Ziegler G, Cotrina J, Galarreta J, de la Cruz M, Mantilla R. Current situation of soft tissue sarcomas: Registry of a Latin American cancer institute. *Cirugia Espanola* 2019;97(4):203–12. <https://doi.org/10.1016/j.cireng.2019.04.001>.
- García-Ortega DY, Clara-Altamirano MA, Martín-Tellez KS, Caro-Sánchez CHS, Álvarez-Cano A, Lino-Silva LS, et al. Epidemiological profile of soft tissue sarcomas of the extremities: Incidence, histological subtypes, and primary sites. *J Orthop* 2021;25:70–4. <https://doi.org/10.1016/j.jor.2021.03.021>.
- Wardelmann E, Haas RL, Bovée JVMG, Terrier Ph, Lazar A, Messiou C, et al. Evaluation of response after neoadjuvant treatment in soft tissue sarcomas; the European Organization for Research and Treatment of Cancer-Soft Tissue and Bone Sarcoma Group (EORTC-STBSG) recommendations for pathological examination and reporting. *Eur J Cancer Oxf Engl* 2016;53:84–95. <https://doi.org/10.1016/j.ejca.2015.09.021>.
- Rosenthal J, Cardona K, Sayyid SK, Perricone AJ, Reimer N, Monson D, et al. Nodal metastases of soft tissue sarcomas: risk factors, imaging findings, and implications. *Skeletal Radiol* 2020;49(2):221–9. <https://doi.org/10.1007/s00256-019-03299-6>.
- Callegaro D, Miceli R, Bonvalot S, Ferguson P, Strauss DC, Levy A, et al. Development and external validation of two nomograms to predict overall survival and occurrence of distant metastases in adults after surgical resection of localised soft-tissue sarcomas of the extremities: a retrospective analysis. *Lancet Oncol* 2016;17(5):671–80. [https://doi.org/10.1016/S1470-2045\(16\)00010-3](https://doi.org/10.1016/S1470-2045(16)00010-3).
- Gronchi A, Miceli R, Shurell E, Eilber FC, Eilber FR, Anaya DA, et al. Outcome prediction in primary resected retroperitoneal soft tissue sarcoma: histology-specific overall survival and disease-free survival nomograms built on major sarcoma center data sets. *J Clin Oncol* 2013;31(13):1649–55. <https://doi.org/10.1200/JCO.2012.44.3747>.
- Callegaro D, Miceli R, Bonvalot S, Ferguson PC, Strauss DC, van Praag VVM, et al. Development and external validation of a dynamic prognostic nomogram for primary extremity soft tissue sarcoma survivors. *EclinicalMedicine* 2019;17: 100215. <https://doi.org/10.1016/j.eclinm.2019.11.008>.
- Rosenberg SA, Tepper J, Glatstein E, Costa J, Baker A, Brennam M, et al. The Treatment of Soft-tissue Sarcomas of the Extremities: Prospective Randomized Evaluations of (1) Limb-sparing surgery Plus Radiation Therapy Compared with Amputation and (2) the Role of adjuvant Chemotherapy. *Ann Surg* 1982;196(3):305–15.
- Pisters PW, Harrison LB, Leung DH, Woodruff JM, Casper ES, Brennan MF. Long-term results of a prospective randomized trial of adjuvant brachytherapy in soft

- tissue sarcoma. *J Clin Oncol* 1996;14(3):859–68. <https://doi.org/10.1200/JCO.1996.14.3.859>.
- [16] Beane JD, Yang JC, White D, Steinberg SM, Rosenberg SA, Rudloff U. Efficacy of adjuvant radiation therapy in the treatment of soft tissue sarcoma of the extremity: 20-year follow-up of a randomized prospective trial. *Ann Surg Oncol* 2014;21(8):2484–9. <https://doi.org/10.1245/s10434-014-3732-4>.
- [17] Yang JC, Chang AE, Baker AR, Sindelar WF, Danforth DN, Topalian SL, et al. Randomized prospective study of the benefit of adjuvant radiation therapy in the treatment of soft tissue sarcomas of the extremity. *J Clin Oncol* 1998;16(1):197–203. <https://doi.org/10.1200/JCO.1998.16.1.197>.
- [18] Cahlon O, Brennan MF, Jia X, Qin LX, Singer S, Alektiar KM. A postoperative nomogram for local recurrence risk in extremity soft tissue sarcomas after limb-sparing surgery without adjuvant radiation. *Ann Surg* 2012;255:343–7. <https://doi.org/10.1097/SLA.0b013e3182367aa7>.
- [19] DAVIS A, OSULLIVAN B, TURCOTTE R, BELL R, CATTON C, CHABOT P, et al. Late radiation morbidity following randomization to preoperative versus postoperative radiotherapy in extremity soft tissue sarcoma. *Radiother Oncol J Eur Soc Ther Radiol Oncol* 2005;75(1):48–53. <https://doi.org/10.1016/j.radonc.2004.12.020>.
- [20] Al Yami A, Griffin AM, Ferguson PC, Catton CN, Chung PWM, Bell RS, et al. Positive surgical margins in soft tissue sarcoma treated with preoperative radiation: is a postoperative boost necessary? *Int J Radiat Oncol Biol Phys* 2010;77(4):1191–7. <https://doi.org/10.1016/j.ijrobp.2009.06.074>.
- [21] O'Sullivan B, Davis AM, Turcotte R, Bell R, Catton C, Chabot P, et al. Preoperative versus postoperative radiotherapy in soft-tissue sarcoma of the limbs: a randomised trial. *Lancet* 2002;359(9325):2235–41. [https://doi.org/10.1016/S0140-6736\(02\)09292-9](https://doi.org/10.1016/S0140-6736(02)09292-9).
- [22] Gronchi A, Frustaci S, Mercuri M, Martin J, Lopez-Pousa A, Verderio P, et al. Short, full-dose adjuvant chemotherapy in high-risk adult soft tissue sarcomas: a randomized clinical trial from the Italian Sarcoma Group and the Spanish Sarcoma Group. *J Clin Oncol Off J Am Soc Clin Oncol* 2012;30(8):850–6. <https://doi.org/10.1200/JCO.2011.37.7218>.
- [23] Woll PJ, Reichardt P, Le Cesne A, Bonvalot S, Azzarelli A, Hoekstra HJ, et al. Adjuvant chemotherapy with doxorubicin, ifosfamide, and lenograstim for resected soft-tissue sarcoma (EORTC 62931): a multicentre randomised controlled trial. *Lancet Oncol* 2012;13(10):1045–54. [https://doi.org/10.1016/S1470-2045\(12\)70346-7](https://doi.org/10.1016/S1470-2045(12)70346-7).
- [24] Pasquali S, Pizzamiglio S, Touati N, Litiere S, Marreaud S, Kasper B, et al. The impact of chemotherapy on survival of patients with extremity and trunk wall soft tissue sarcoma: revisiting the results of the EORTC-STBSG 62931 randomised trial. *Eur J Cancer Oxf Engl* 2019;109:51–60. <https://doi.org/10.1016/j.ejca.2018.12.009>.
- [25] Frustaci S, Gherlizoni F, De Paoli A, Bonetti M, Azzarelli A, Comandone A, et al. Adjuvant chemotherapy for adult soft tissue sarcomas of the extremities and girdles: results of the Italian randomized cooperative trial. *J Clin Oncol* 2001;19(5):1238–47. <https://doi.org/10.1200/JCO.2001.19.5.1238>.
- [26] Gronchi A, Palmerini E, Quagliuolo V, Martin Broto J, Lopez Pousa A, Grignani G, et al. Neoadjuvant Chemotherapy in High-Risk Soft Tissue Sarcomas: Final Results of a Randomized Trial From Italian (ISG), Spanish (GEIS), French (FSG), and Polish (PSG) Sarcoma Groups. *J Clin Oncol Off J Am Soc Clin Oncol* 2020;38(19):2178–86. <https://doi.org/10.1200/JCO.19.03289>.
- [27] Pervaiz N, Colterjohn N, Farrokhfar F, Tozer R, Figueredo A, Ghert M. A systematic meta-analysis of randomized controlled trials of adjuvant chemotherapy for localized resectable soft-tissue sarcoma. *Cancer* 2008;113(3):573–81. <https://doi.org/10.1002/cncr.v113:310.1002/cncr.23592>.
- [28] Gronchi A, Ferrari S, Quagliuolo V, Broto JM, Pousa AL, Grignani G, et al. Histotype-tailored neoadjuvant chemotherapy versus standard chemotherapy in patients with high-risk soft-tissue sarcomas (ISG-ST5 1001): an international, open-label, randomised, controlled, phase 3, multicentre trial. *Lancet Oncol* 2017;18(6):812–22. [https://doi.org/10.1016/S1470-2045\(17\)30334-0](https://doi.org/10.1016/S1470-2045(17)30334-0).
- [29] Lu E, Perlewitz KS, Hayden JB, Hung AY, Doung Y-C, Davis LE, et al. Epirubicin and ifosfamide with Preoperative Radiation for High-Risk Soft Tissue Sarcomas. *Ann Surg Oncol* 2018;25(4):920–7. <https://doi.org/10.1245/s10434-018-6346-4>.
- [30] Tap WD, Jones RL, Van Tine BA, Chmielowski B, Elias AD, Adkins D, et al. Olaratumab and doxorubicin versus doxorubicin alone for treatment of soft-tissue sarcoma: an open-label phase 1b and randomised phase 2 trial. *Lancet Lond Engl* 2016;388(10043):488–97. [https://doi.org/10.1016/S0140-6736\(16\)30587-6](https://doi.org/10.1016/S0140-6736(16)30587-6).
- [31] Italiano A, Mathoulin-Pelissier S, Cesne AL, Terrier P, Bonvalot S, Collin F, et al. Trends in survival for patients with metastatic soft-tissue sarcoma. *Cancer* 2011;117(5):1049–54. <https://doi.org/10.1002/cncr.25538>.
- [32] Blay J-Y, van Glabbeke M, Verweij J, van Oosterom AT, Le Cesne A, Oosterhuis JW, et al. Advanced soft-tissue sarcoma: a disease that is potentially curable for a subset of patients treated with chemotherapy. *Eur J Cancer Oxf Engl* 2003;39(1):64–9. [https://doi.org/10.1016/S0959-8049\(02\)00480-X](https://doi.org/10.1016/S0959-8049(02)00480-X).
- [33] Hudgens S, Forsythe A, Kontoudis I, D'Adamo D, Bird A, Gelderblom H. Evaluation of Quality of Life at Progression in Patients with Soft Tissue Sarcoma. *Sarcoma* 2017;2017:1–8. <https://doi.org/10.1155/2017/2372135>.
- [34] Blackmon SH, Shah N, Roth JA, Correa AM, Vaporciyan AA, Rice DC, et al. Resection of pulmonary and extrapulmonary sarcomatous metastases is associated with long-term survival. *Ann Thorac Surg* 2009;88(3):877–85. <https://doi.org/10.1016/j.athoracsur.2009.04.144>.
- [35] Falk AT, Moureau-Zabotto L, Ouali M, Penel N, Italiano A, Bay J-O, et al. Effect on survival of local ablative treatment of metastases from sarcomas: a study of the French sarcoma group. *Clin Oncol R Coll Radiol G B* 2015;27(1):48–55. <https://doi.org/10.1016/j.clon.2014.09.010>.
- [36] Judson I, Verweij J, Gelderblom H, Hartmann JT, Schöffski P, Blay J-Y, et al. Doxorubicin alone versus intensified doxorubicin plus ifosfamide for first-line treatment of advanced or metastatic soft-tissue sarcoma: a randomised controlled phase 3 trial. *Lancet Oncol* 2014;15(4):415–23. [https://doi.org/10.1016/S1470-2045\(14\)70063-4](https://doi.org/10.1016/S1470-2045(14)70063-4).
- [37] Antman K, Crowley J, Balcerzak SP, Rivkin SE, Weiss GR, Elias A, et al. An intergroup phase III randomized study of doxorubicin and dacarbazine with or without ifosfamide and mesna in advanced soft tissue and bone sarcomas. *J Clin Oncol* 1993;11(7):1276–85. <https://doi.org/10.1200/JCO.1993.11.7.1276>.
- [38] Kasper B. The challenge of finding new therapeutic avenues in soft tissue sarcomas. *Clin Sarcoma Res* 2019;9:5. <https://doi.org/10.1186/s13569-019-0115-4>.
- [39] Seddon B, Strauss SJ, Whelan J, Leahy M, Woll PJ, Cowie F, et al. Gemcitabine and docetaxel versus doxorubicin as first-line treatment in previously untreated advanced unresectable or metastatic soft-tissue sarcomas (GeDDiS): a randomised controlled phase 3 trial. *Lancet Oncol* 2017;18(10):1397–410. [https://doi.org/10.1016/S1470-2045\(17\)30622-8](https://doi.org/10.1016/S1470-2045(17)30622-8).
- [40] Le Cesne A, Antoine E, Spielmann M, Le Chevalier T, Brain E, Toussaint C, et al. High-dose ifosfamide: circumvention of resistance to standard-dose ifosfamide in advanced soft tissue sarcomas. *J Clin Oncol* 1995;13(7):1600–8. <https://doi.org/10.1200/JCO.1995.13.7.1600>.
- [41] Demetri GD, Chawla SP, von Mehren M, Ritch P, Baker LH, Blay JY, et al. Efficacy and safety of trabectedin in patients with advanced or metastatic liposarcoma or leiomyosarcoma after failure of prior anthracyclines and ifosfamide: results of a randomized phase II study of two different schedules. *J Clin Oncol* 2009;27(25):4188–96. <https://doi.org/10.1200/JCO.2008.21.0088>.
- [42] Demetri GD, von Mehren M, Jones RL, Hensley ML, Schuetz SM, Staddon A, et al. Efficacy and Safety of Trabectedin or Dacarbazine for Metastatic Liposarcoma or Leiomyosarcoma After Failure of Conventional Chemotherapy: Results of a Phase III Randomized Multicenter Clinical Trial. *J Clin Oncol* 2016;34(8):786–93. <https://doi.org/10.1200/JCO.2015.62.4734>.
- [43] Kawai A, Araki N, Sugiura H, Ueda T, Yonemoto T, Takahashi M, et al. Trabectedin monotherapy after standard chemotherapy versus best supportive care in patients with advanced, translocation-related sarcoma: a randomised, open-label, phase 2 study. *Lancet Oncol* 2015;16(4):406–16. [https://doi.org/10.1016/S1470-2045\(15\)70098-7](https://doi.org/10.1016/S1470-2045(15)70098-7).
- [44] Buonadonna A, Benson C, Casanova J, Kasper B, López Pousa A, Mazzeo F, et al. A noninterventional, multicenter, prospective phase IV study of trabectedin in patients with advanced soft tissue sarcoma. *Anticancer Drugs* 2017;28:1157–65. <https://doi.org/10.1097/CAD.0000000000000560>.
- [45] Martin-Broto J, Hindi N, Lopez-Pousa A, Peinado-Serrano J, Alvarez R, Alvarez-Gonzalez A, et al. Assessment of Safety and Efficacy of Combined Trabectedin and Low-Dose Radiotherapy for Patients With Metastatic Soft-Tissue Sarcomas: A Nonrandomized Phase 1/2 Clinical Trial. *JAMA Oncol* 2020;6(4):535. <https://doi.org/10.1001/jamaoncol.2019.6584>.
- [46] van der Graaf WTA, Blay J-Y, Chawla SP, Kim D-W, Bui-Nguyen B, Casali PG, et al. Pazopanib for metastatic soft-tissue sarcoma (PALETTE): a randomised, double-blind, placebo-controlled phase 3 trial. *Lancet Lond Engl* 2012;379(9829):1879–86. [https://doi.org/10.1016/S0140-6736\(12\)60651-5](https://doi.org/10.1016/S0140-6736(12)60651-5).
- [47] Stacchiotti S, Ferrari S, Redondo A, Hindi N, Palmerini E, Vaz Salgado MA, et al. Pazopanib for treatment of advanced extraskelletal myxoid chondrosarcoma: a multicentre, single-arm, phase 2 trial. *Lancet Oncol* 2019;20(9):1252–62. [https://doi.org/10.1016/S1470-2045\(19\)30319-5](https://doi.org/10.1016/S1470-2045(19)30319-5).
- [48] Martin-Broto J, Stacchiotti S, Lopez-Pousa A, Redondo A, Bernabeu D, de Alava E, et al. Pazopanib for treatment of advanced malignant and dedifferentiated solitary fibrous tumour: a multicentre, single-arm, phase 2 trial. *Lancet Oncol* 2019;20(1):134–44. [https://doi.org/10.1016/S1470-2045\(18\)30676-4](https://doi.org/10.1016/S1470-2045(18)30676-4).
- [49] Martin-Broto J, Cruz J, Penel N, Le Cesne A, Hindi N, Luna P, et al. Pazopanib for treatment of typical solitary fibrous tumours: a multicentre, single-arm, phase 2 trial. *Lancet Oncol* 2020;21(3):456–66. [https://doi.org/10.1016/S1470-2045\(19\)30826-5](https://doi.org/10.1016/S1470-2045(19)30826-5).
- [50] Stacchiotti S, Mir O, Le Cesne A, Vincenzi B, Fedenko A, Maki RG, et al. Activity of Pazopanib and Trabectedin in Advanced Alveolar Soft Part Sarcoma. *Oncologist* 2018;23(1):62–70. <https://doi.org/10.1634/theoncologist.2017-0161>.
- [51] Schöffski P, Chawla S, Maki RG, Italiano A, Gelderblom H, Choy E, et al. Eribulin versus dacarbazine in previously treated patients with advanced liposarcoma or leiomyosarcoma: a randomised, open-label, multicentre, phase 3 trial. *Lancet* 2016;387(10028):1629–37. [https://doi.org/10.1016/S0140-6736\(15\)01283-0](https://doi.org/10.1016/S0140-6736(15)01283-0).
- [52] García-del-Muro X, López-Pousa A, Maurel J, Martín J, Martínez-Trufero J, Casado A, et al. Randomized phase II study comparing gemcitabine plus dacarbazine versus dacarbazine alone in patients with previously treated soft tissue sarcoma: a Spanish Group for Research on Sarcomas study. *J Clin Oncol* 2011;29(18):2528–33. <https://doi.org/10.1200/JCO.2010.33.6107>.
- [53] Maki RG, Wathen JK, Patel SR, Priebe DA, Okuno SH, Samuels B, et al. Randomized phase II study of gemcitabine and docetaxel compared with gemcitabine alone in patients with metastatic soft tissue sarcomas: results of sarcoma alliance for research through collaboration study 002 [corrected]. *J Clin Oncol Off J Am Soc Clin Oncol* 2007;25(19):2755–63. <https://doi.org/10.1200/JCO.2006.10.4117>.
- [54] Stacchiotti S, Palassini E, Sanfilippo R, Vincenzi B, Arena MG, Bochicchio AM, et al. Gemcitabine in advanced angiosarcoma: a retrospective case series analysis from the Italian Rare Cancer Network. *Ann Oncol* 2012;23(2):501–8. <https://doi.org/10.1093/annonc/mdr066>.
- [55] Rutkowski P, Klimczak A, Ługowska I, Jagielska B, Wądrodzki M, Dębicz-Rychter M, et al. Long-term results of treatment of advanced

- dermatofibrosarcoma protuberans (DFSP) with imatinib mesylate - The impact of fibrosarcomatous transformation. *Eur J Surg Oncol* 2017;43(6):1134–41. <https://doi.org/10.1016/j.ejso.2017.03.011>.
- [56] Berry V, Basson L, Bogart E, Mir O, Blay J-Y, Italiano A, et al. REGOSARC: Regorafenib versus placebo in doxorubicin-refractory soft-tissue sarcoma-A quality-adjusted time without symptoms of progression or toxicity analysis. *Cancer* 2017;123(12):2294–302. <https://doi.org/10.1002/cncr.v123.1210.1002/cncr.30661>.
- [57] Mir O, Brodowicz T, Italiano A, Wallet J, Blay J-Y, Bertucci F, et al. Safety and efficacy of regorafenib in patients with advanced soft tissue sarcoma (REGOSARC): a randomised, double-blind, placebo-controlled, phase 2 trial. *Lancet Oncol* 2016;17(12):1732–42. [https://doi.org/10.1016/S1470-2045\(16\)30507-1](https://doi.org/10.1016/S1470-2045(16)30507-1).
- [58] Benson C, Vitfell-Rasmussen J, Maruzzo M, Fisher C, Tunariu N, Mitchell S, et al. A retrospective study of patients with malignant PEComa receiving treatment with sirolimus or temsirolimus: the Royal Marsden Hospital experience. *Anticancer Res* 2014;34:3663–8.
- [59] Wagner AJ, Malinowska-Kolodziej I, Morgan JA, Qin W, Fletcher CDM, Vena N, et al. Clinical activity of mTOR inhibition with sirolimus in malignant perivascular epithelioid cell tumors: targeting the pathogenic activation of mTORC1 in tumors. *J Clin Oncol* 2010;28(5):835–40. <https://doi.org/10.1200/JCO.2009.25.2981>.
- [60] Wagner AJ, Ravi V, Riedel RF, Ganjoo KN, Van Tine BA, Chugh R, et al. Long-term follow-up for duration of response (DoR) after weekly nab-sirolimus in patients with advanced malignant perivascular epithelioid cell tumors (PEComa): Results from a registrational open-label phase II trial, AMPECT. *J Clin Oncol* 2020;38:11516–11516. 10.1200/JCO.2020.38.15_suppl.11516.
- [61] Butrynski JE, D'Adamo DR, Hornick JL, Dal Cin P, Antonescu CR, Jhanwar SC, et al. Crizotinib in ALK-rearranged inflammatory myofibroblastic tumor. *N Engl J Med* 2010;363(18):1727–33. <https://doi.org/10.1056/NEJMoa1007056>.
- [62] Schöffski P, Sufliarsky J, Gelderblom H, Blay J-Y, Strauss SJ, Stacchiotti S, et al. Crizotinib in patients with advanced, inoperable inflammatory myofibroblastic tumours with and without anaplastic lymphoma kinase gene alterations (European Organisation for Research and Treatment of Cancer 90101 CREATE): a multicentre, single-drug, prospective, non-randomised phase 2 trial. *Lancet Respir Med* 2018;6(6):431–41. [https://doi.org/10.1016/S2213-2600\(18\)30116-4](https://doi.org/10.1016/S2213-2600(18)30116-4).
- [63] Cocco E, Scaltriti M, Drilon A. NTRK fusion-positive cancers and TRK inhibitor therapy. *Nat Rev Clin Oncol* 2018;15(12):731–47. <https://doi.org/10.1038/s41571-018-0113-0>.
- [64] Demetri GD, Antonescu CR, Bjerkehagen B, Bovée JVMG, Boye K, Chacón M, et al. Diagnosis and management of tropomyosin receptor kinase (TRK) fusion sarcomas: expert recommendations from the World Sarcoma Network. *Ann Oncol Off J Eur Soc Med Oncol* 2020;31(11):1506–17. <https://doi.org/10.1016/j.annonc.2020.08.2232>.
- [65] Doebele RC, Drilon A, Paz-Ares L, Siena S, Shaw AT, Farago AF, et al. Entrectinib in patients with advanced or metastatic NTRK fusion-positive solid tumours: integrated analysis of three phase 1–2 trials. *Lancet Oncol* 2020;21:271–82. [https://doi.org/10.1016/S1470-2045\(19\)30691-6](https://doi.org/10.1016/S1470-2045(19)30691-6).
- [66] Penel N, Bui BN, Bay J-O, Cupissol D, Ray-Coquard I, Piperno-Neumann S, et al. Phase II trial of weekly paclitaxel for unresectable angiosarcoma: the ANGIOTAX Study. *J Clin Oncol Off J Am Soc Clin Oncol* 2008;26(32):5269–74. <https://doi.org/10.1200/JCO.2008.17.3146>.
- [67] Skubitz KM, Haddad PA. Paclitaxel and pegylated-liposomal doxorubicin are both active in angiosarcoma. *Cancer* 2005;104(2):361–6. [https://doi.org/10.1002/\(ISSN\)1097-0142.1002/cncr.v104.210.1002/cncr.21140](https://doi.org/10.1002/(ISSN)1097-0142.1002/cncr.v104.210.1002/cncr.21140).
- [68] Pasquier E, André N, Street J, Chougule A, Rekhi B, Ghosh J, et al. Effective Management of Advanced Angiosarcoma by the Synergistic Combination of Propranolol and Vinblastine-based Metronomic Chemotherapy: A Bench to Bedside Study. *EBioMedicine* 2016;6:87–95. <https://doi.org/10.1016/j.ebiom.2016.02.026>.
- [69] Chevreau C, Le Cesne A, Ray-Coquard I, Italiano A, Cioffi A, Isambert N, et al. Sorafenib in patients with progressive epithelioid hemangioendothelioma: a phase 2 study by the French Sarcoma Group (GSF/GETO). *Cancer* 2013;119(14):2639–44. <https://doi.org/10.1002/cncr.281109>.
- [70] Kollár A, Jones RL, Stacchiotti S, Gelderblom H, Guida M, Grignani G, et al. Pazopanib in advanced vascular sarcomas: an EORTC Soft Tissue and Bone Sarcoma Group (STBSG) retrospective analysis. *Acta Oncol Stockh Swed* 2017;56(1):88–92. <https://doi.org/10.1080/0284186X.2016.1234068>.
- [71] Pautier P, Floquet A, Penel N, Piperno-Neumann S, Isambert N, Rey A, et al. Randomized multicenter and stratified phase II study of gemcitabine alone versus gemcitabine and docetaxel in patients with metastatic or relapsed leiomyosarcomas: a Federation Nationale des Centres de Lutte Contre le Cancer (FNCLCC) French Sarcoma Group Study (TAXOGEM study). *Oncologist* 2012;17:1213–20. <https://doi.org/10.1634/theoncologist.2011-0467>.
- [72] Gronchi A, Strauss DC, Miceli R, Bonvalot S, Swallow CJ, Hohenberger P, et al. Variability in Patterns of Recurrence After Resection of Primary Retroperitoneal Sarcoma (RPS): A Report on 1007 Patients From the Multi-institutional Collaborative RPS Working Group. *Ann Surg* 2016;263:1002–9. 10.1097/SLA.0000000000001447.
- [73] Bonvalot S, Rivoire M, Castaing M, Stoeckle E, Le Cesne A, Blay JY, et al. Primary retroperitoneal sarcomas: a multivariate analysis of surgical factors associated with local control. *J Clin Oncol Off J Am Soc Clin Oncol* 2009;27(11):31–7. <https://doi.org/10.1200/JCO.2008.18.0802>.
- [74] Gronchi A, Miceli R, Colombo C, Stacchiotti S, Collini P, Mariani L, et al. Frontline extended surgery is associated with improved survival in retroperitoneal low- to intermediate-grade soft tissue sarcomas. *Ann Oncol* 2012;23(4):1067–73. <https://doi.org/10.1093/annonc/mdr323>.
- [75] Bonvalot S, Gronchi A, Pechoux CL, Swallow CJ, Strauss DC, Meeus P, et al. STRASS (EORTC 62092): A phase III randomized study of preoperative radiotherapy plus surgery versus surgery alone for patients with retroperitoneal sarcoma. *J Clin Oncol* 2019;37:11001–11001. 10.1200/JCO.2019.37.15_suppl.11001.
- [76] Kho KA, Nezhat CH. Evaluating the risks of electric uterine morcellation. *JAMA* 2014;311:905–6. <https://doi.org/10.1001/jama.2014.1093>.
- [77] Raspagliesi F, Maltese G, Bogani G, Fucà G, Lepori S, De Iaco P, et al. Morcellation worsens survival outcomes in patients with undiagnosed uterine leiomyosarcomas: A retrospective MITO group study. *Gynecol Oncol* 2017;144(1):90–5. <https://doi.org/10.1016/j.ygyno.2016.11.002>.
- [78] Reed NS, Mangioni C, Malmström H, Scarfone G, Poveda A, Pecorelli S, et al. Phase III randomised study to evaluate the role of adjuvant pelvic radiotherapy in the treatment of uterine sarcomas stages I and II: an European Organisation for Research and Treatment of Cancer Gynaecological Cancer Group Study (protocol 55874). *Eur J Cancer* 2008;44(6):808–18. <https://doi.org/10.1016/j.ejca.2008.01.019>.
- [79] Hensley ML, Ishill N, Soslow R, Larkin J, Abu-Rustum N, Sabbatini P, et al. Adjuvant gemcitabine plus docetaxel for completely resected stages I-IV high grade uterine leiomyosarcoma: Results of a prospective study. *Gynecol Oncol* 2009;112(3):563–7. <https://doi.org/10.1016/j.ygyno.2008.11.027>.
- [80] Hensley ML, Wathen JK, Maki RG, Araujo DM, Sutton G, Priebe DA, et al. Adjuvant therapy for high-grade, uterine-limited leiomyosarcoma: results of a phase 2 trial (SARC 005). *Cancer* 2013;119(8):1555–61. <https://doi.org/10.1002/cncr.27942>.
- [81] Rauh-Hain JA, del Carmen MG. Endometrial stromal sarcoma: a systematic review. *Obstet Gynecol* 2013;122(3):676–83. <https://doi.org/10.1097/AOG.0b013e3182a189ac>.
- [82] Dahhan T, Fons G, Buist MR, ten Kate FJW, van der Velden J. The efficacy of hormonal treatment for residual or recurrent low-grade endometrial stromal sarcoma. A retrospective study. *Eur J Obstet Gynecol Reprod Biol* 2009;144(1):80–4. <https://doi.org/10.1016/j.ejogrb.2009.02.005>.
- [83] Kasper B, Baumgarten C, Garcia J, Bonvalot S, Haas R, Haller F, et al. An update on the management of sporadic desmoid-type fibromatosis: a European Consensus Initiative between Sarcoma Patients EuroNet (SPAEN) and European Organization for Research and Treatment of Cancer (EORTC)/Soft Tissue and Bone Sarcoma Group (STBSG). *Ann Oncol Off J Eur Soc Med Oncol* 2017;28(10):2399–408. <https://doi.org/10.1093/annonc/mdx323>.
- [84] Toulmonde M, Pulido M, Ray-Coquard I, Andre T, Isambert N, Chevreau C, et al. Pazopanib or methotrexate-vinblastine combination chemotherapy in adult patients with progressive desmoid tumours (DESMOPAZ): a non-comparative, randomised, open-label, multicentre, phase 2 study. *Lancet Oncol* 2019;20(9):1263–72. [https://doi.org/10.1016/S1470-2045\(19\)30276-1](https://doi.org/10.1016/S1470-2045(19)30276-1).
- [85] Gounder MM, Mahoney MR, Van Tine BA, Ravi V, Attia S, Deshpande HA, et al. Sorafenib for Advanced and Refractory Desmoid Tumors. *N Engl J Med* 2018;379(25):2417–28. <https://doi.org/10.1056/NEJMoa1805052>.
- [86] Palassini E, Frezza AM, Mariani L, Lalli L, Colombo C, Fiore M, et al. Long-term Efficacy of Methotrexate Plus Vinblastine/Vinorelbine in a Large Series of Patients Affected by Desmoid-Type Fibromatosis. *Cancer J* 2017;23:86–91. 10.1097/ppo.0000000000000254.
- [87] de Camargo VP, Keohan ML, D'Adamo DR, Antonescu CR, Brennan MF, Singer S, et al. Clinical outcomes of systemic therapy for patients with deep fibromatosis (desmoid tumor). *Cancer* 2010;NA-. <https://doi.org/10.1002/cncr.25089>.
- [88] Skapek SX, Anderson JR, Hill DA, Henry D, Spunt SL, Meyer W, et al. Safety and efficacy of high-dose tamoxifen and sulindac for desmoid tumor in children: Results of a Children's Oncology Group (COG) Phase II Study. *Pediatr Blood Cancer* 2013;60(7):1108–12. <https://doi.org/10.1002/pbc.24457>.
- [89] Constantinidou A, Jones RL, Scurr M, Al-Muderis O, Judson I. Pegylated liposomal doxorubicin, an effective, well-tolerated treatment for refractory aggressive fibromatosis. *Eur J Cancer* 2009;45(17):2930–4. <https://doi.org/10.1016/j.ejca.2009.08.016>.
- [90] Kasper B, Gruenwald V, Reichardt P, Bauer S, Rauch G, Limprecht R, et al. Imatinib induces sustained progression arrest in RECIST progressive desmoid tumours: Final results of a phase II study of the German Interdisciplinary Sarcoma Group (GISG). *Eur J Cancer* 2017;76:60–7. <https://doi.org/10.1016/j.ejca.2017.02.001>.
- [91] Keus RB, Nout RA, Blay J-Y, de Jong JM, Hennig I, Saran F, et al. Results of a phase II pilot study of moderate dose radiotherapy for inoperable desmoid-type fibromatosis—an EORTC STBSG and ROG study (EORTC 62991–22998). *Ann Oncol Off J Eur Soc Med Oncol* 2013;24(10):2672–6. <https://doi.org/10.1093/annonc/mdt254>.
- [92] Kurtz J-E, Buy X, Deschamps F, Sauleau E, Bouhamama A, Toulmonde M, et al. CRYODESMO-O1: A prospective, open phase II study of cryoablation in desmoid tumour patients progressing after medical treatment. *Eur J Cancer Oxf Engl* 2021;143:78–87. <https://doi.org/10.1016/j.ejca.2020.10.035>.
- [93] Verspoor FGM, Mastboom MJL, Hannink G, van der Graaf WTA, van de Sande MAJ, Schreuder HWB. The effect of surgery in tenosynovial giant cell tumours as measured by patient-reported outcomes on quality of life and joint function. *Bone Jt J* 2019;101-B(3):272–80. <https://doi.org/10.1302/0301-620X.101B3.BJJ-2018-0804.R1>.
- [94] Mastboom MJL, Staals EL, Verspoor FGM, Rueten-Budde AJ, Stacchiotti S, Palmerini E, et al. Surgical Treatment of Localized-Type Tenosynovial Giant Cell Tumors of Large Joints: A Study Based on a Multicenter-Pooled Database of 31

- International Sarcoma Centers. *J Bone Jt Surg Am* 2019;101(14):1309–18. <https://doi.org/10.2106/JBJS.18.01147>.
- [95] Quaresma MB, Portela J, Brito JS do. Open versus arthroscopic surgery for diffuse tenosynovial giant-cell tumours of the knee: a systematic review. *EFORT Open Rev* 2020;5:339–46. 10.1302/2058-5241.5.200005.
- [96] Cassier Philippe A, Gelderblom Hans, Stacchiotti Silvia, Thomas David, Maki Robert G, Kroep Judith R, et al. Efficacy of imatinib mesylate for the treatment of locally advanced and/or metastatic tenosynovial giant cell tumor/pigmented villonodular synovitis. *Cancer* 2012;118(6):1649–55. <https://doi.org/10.1002/cncr.v118.6.1002/cncr.26409>.
- [97] Gelderblom Hans, Cropet Claire, Chevreau Christine, Boyle Richard, Tattersall Martin, Stacchiotti Silvia, et al. Nilotinib in locally advanced pigmented villonodular synovitis: a multicentre, open-label, single-arm, phase 2 trial. *Lancet Oncol* 2018;19(5):639–48. [https://doi.org/10.1016/S1470-2045\(18\)30143-8](https://doi.org/10.1016/S1470-2045(18)30143-8).
- [98] Tap William D, Gelderblom Hans, Palmerini Emanuela, Desai Jayesh, Bauer Sebastian, Blay Jean-Yves, et al. Pexidartinib versus placebo for advanced tenosynovial giant cell tumour (ENLIVEN): a randomised phase 3 trial. *Lancet* 2019;394(10197):478–87. [https://doi.org/10.1016/S0140-6736\(19\)30764-0](https://doi.org/10.1016/S0140-6736(19)30764-0).
- [99] Foroozan M, Sei J-F, Amini M, Beauchet A, Saiag P. Efficacy of Mohs micrographic surgery for the treatment of dermatofibrosarcoma protuberans: systematic review. *Arch Dermatol* 2012;148:1055–63. <https://doi.org/10.1001/archdermatol.2012.1440>.
- [100] Kimmel Z, Ratner D, Kim JYS, Wayne JD, Rademaker AW, Alam M. Peripheral excision margins for dermatofibrosarcoma protuberans: a meta-analysis of spatial data. *Ann Surg Oncol* 2007;14:2113–20. 10.1245/s10434-006-9233-3.
- [101] Cipriano Cara A, Jang Eugene, Tyler Wakenda. *Sarcoma Surveillance: A Review of Current Evidence and Guidelines*. *J Am Acad Orthop Surg* 2020;28(4):145–56. <https://doi.org/10.5435/JAAOS-D-19-00002>.
- [102] Rubió J, Marcos-Gragera R, Ortiz MR, Miró J, Vilardell L, Gironès J, et al. Population-based incidence and survival of gastrointestinal stromal tumours (GIST) in Girona. *Spain Eur J Cancer Oxf Engl* 2007;43(1):144–8. <https://doi.org/10.1016/j.ejca.2006.07.015>.
- [103] Nilsson Bengt, Bümbling Per, Meis-Kindblom Jeanne M, Odén Anders, Dortok Aydin, Gustavsson Bengt, et al. Gastrointestinal stromal tumors: the incidence, prevalence, clinical course, and prognostication in the preimatinib mesylate era—a population-based study in western Sweden. *Cancer* 2005;103(4):821–9. <https://doi.org/10.1002/cncr.20862>.
- [104] Cuccaro Francesco, Burgio Lo Monaco Maria Giovanna, Rashid Ivan, Bisceglia Lucia, Caputo Enrico, Melcarne Anna, et al. Population-based incidence of gastrointestinal stromal tumors in Puglia. *Tumori* 2021;107(1):39–45. <https://doi.org/10.1177/0300891620931944>.
- [105] Miettinen Markku, Lasota Jerzy. Gastrointestinal stromal tumors: pathology and prognosis at different sites. *Semin Diagn Pathol* 2006;23(2):70–83. <https://doi.org/10.1053/j.semdp.2006.09.001>.
- [106] Ford SJ, Gronchi A. Indications for surgery in advanced/metastatic GIST. *Eur J Cancer* 2016;63:154–67. <https://doi.org/10.1016/j.ejca.2016.05.019>.
- [107] Casali PG, Abecassis N, Aro HT, Bauer S, Biagini R, Bielack S, et al. Gastrointestinal stromal tumours: ESMO-EURACAN Clinical Practice Guidelines for diagnosis, treatment and follow-up. *Ann Oncol* 2018;29:iv267. 10.1093/annonc/mdy320.
- [108] Fletcher Christopher DM, Berman Jules J, Corless Christopher, Gorstein Fred, Lasota Jerzy, Longley BJack, et al. Diagnosis of gastrointestinal stromal tumors: A consensus approach. *Hum Pathol* 2002;33(5):459–65. <https://doi.org/10.1053/hupa.2002.123545>.
- [109] JD B, MK G, (eds) WC. *TNM Classification of Malignant Tumours*, 8th edn. Oxford: John Wiley & Sons, Inc.; 2016.
- [110] Kalkmann Janine, Zeile Martin, Antoch Gerald, Berger Frank, Diederich Stefan, Dinter Dietmar, et al. Consensus report on the radiological management of patients with gastrointestinal stromal tumours (GIST): recommendations of the German GIST Imaging Working Group. *Cancer Imaging Off Publ Int Cancer Imaging Soc* 2012;12(1):126–35. <https://doi.org/10.1102/1470-5206.2012.0013>.
- [111] Joensuu Heikki, Vehtari Aki, Riihimäki Jaakko, Nishida Toshirou, Steigen Sonja E, Brabec Peter, et al. Risk of recurrence of gastrointestinal stromal tumour after surgery: an analysis of pooled population-based cohorts. *Lancet Oncol* 2012;13(3):265–74. [https://doi.org/10.1016/S1470-2045\(11\)70299-6](https://doi.org/10.1016/S1470-2045(11)70299-6).
- [112] Martín Javier, Poveda Andrés, Llobart-Bosch Antonio, Ramos Rafael, López-Guerrero José A, del Muro Javier García, et al. Deletions affecting codons 557–558 of the c-KIT gene indicate a poor prognosis in patients with completely resected gastrointestinal stromal tumors: a study by the Spanish Group for Sarcoma Research (GEIS). *J Clin Oncol Off J Am Soc. Clin Oncol* 2005;23(25):6190–8. <https://doi.org/10.1200/JCO.2005.19.554>.
- [113] Ohtani H, Maeda K, Noda E, Nagahara H, Shibutani M, Ohira M, et al. Meta-analysis of laparoscopic and open surgery for gastric gastrointestinal stromal tumor. *Anticancer Res* 2013;33:5031–41.
- [114] Demetri GD, von Mehren M, Antonescu CR, DeMatteo RP, Ganjoo KN, Maki RG, et al. NCCN Task Force report: update on the management of patients with gastrointestinal stromal tumors. *J Natl Compr Cancer Netw JNCCN* 2010;8 Suppl 2:S1-41; quiz S42-44. 10.6004/jnccn.2010.0116.
- [115] Rutkowski Piotr, Gronchi Alessandro, Hohenberger Peter, Bonvalot Sylvie, Schöffski Patrick, Bauer Sebastian, et al. Neoadjuvant imatinib in locally advanced gastrointestinal stromal tumors (GIST): the EORTC STBSG experience. *Ann Surg Oncol* 2013;20(9):2937–43. <https://doi.org/10.1245/s10434-013-3013-7>.
- [116] Eisenberg Burton L, Harris Jonathan, Blanke Charles D, Demetri George D, Heinrich Michael C, Watson James C, et al. Phase II trial of neoadjuvant/adjuvant imatinib mesylate (IM) for advanced primary and metastatic/recurrent operable gastrointestinal stromal tumor (GIST): early results of RTOG 0132/ACRIN 6665. *J Surg Oncol* 2009;99(1):42–7. <https://doi.org/10.1002/jso.v99.1.10.1002/jso.21160>.
- [117] Joensuu Heikki, Eriksson Mikael, Sundby Hall Kirsten, Reichardt Annette, Hartmann Jörg T, Pink Daniel, et al. Adjuvant Imatinib for High-Risk GI Stromal Tumor: Analysis of a Randomized Trial. *J Clin Oncol* 2016;34(3):244–50. <https://doi.org/10.1200/JCO.2015.62.9170>.
- [118] DeMatteo Ronald P, Ballman Karla V, Antonescu Cristina R, Maki Robert G, Pisters Peter WT, Demetri George D, et al. Adjuvant imatinib mesylate after resection of localised, primary gastrointestinal stromal tumour: a randomised, double-blind, placebo-controlled trial. *Lancet Lond Engl* 2009;373(9669):1097–104. [https://doi.org/10.1016/S0140-6736\(09\)60500-6](https://doi.org/10.1016/S0140-6736(09)60500-6).
- [119] Joensuu Heikki, Wardelmann Eva, Sihto Harri, Eriksson Mikael, Sundby Hall Kirsten, Reichardt Annette, et al. Effect of KIT and PDGFRA Mutations on Survival in Patients With Gastrointestinal Stromal Tumors Treated With Adjuvant Imatinib: An Exploratory Analysis of a Randomized Clinical Trial. *JAMA Oncol* 2017;3(5):602. <https://doi.org/10.1001/jamaoncol.2016.5751>.
- [120] Corless Christopher L, Ballman Karla V, Antonescu Cristina R, Kolesnikova Violetta, Maki Robert G, Pisters Peter WT, et al. Pathologic and molecular features correlate with long-term outcome after adjuvant therapy of resected primary GI stromal tumor: the ACOSOG Z9001 trial. *J Clin Oncol Off J Am Soc Clin Oncol* 2014;32(15):1563–70. <https://doi.org/10.1200/JCO.2013.51.2046>.
- [121] Blanke Charles D, Rankin Cathryn, Demetri George D, Ryan Christopher W, von Mehren Margaret, Benjamin Robert S, et al. Phase III randomized, intergroup trial assessing imatinib mesylate at two dose levels in patients with unresectable or metastatic gastrointestinal stromal tumors expressing the kit receptor tyrosine kinase: S0033. *J Clin Oncol* 2008;26(4):626–32. <https://doi.org/10.1200/JCO.2007.13.4452>.
- [122] Verweij Jaap, Casali Paolo G, Zalcberg John, LeCesne Axel, Reichardt Peter, Blay Jean-Yves, et al. Progression-free survival in gastrointestinal stromal tumours with high-dose imatinib: randomised trial. *Lancet* 2004;364(9440):1127–34. [https://doi.org/10.1016/S0140-6736\(04\)17098-0](https://doi.org/10.1016/S0140-6736(04)17098-0).
- [123] Zalcberg John R, Verweij Jaap, Casali Paolo G, Le Cesne Axel, Reichardt Peter, Blay Jean-Yves, et al. Outcome of patients with advanced gastro-intestinal stromal tumours crossing over to a daily imatinib dose of 800 mg after progression on 400 mg. *Eur J Cancer* 2005;41(12):1751–7. <https://doi.org/10.1016/j.ejca.2005.04.034>.
- [124] *Clin Oncol* 2010;28:1247–53. <https://doi.org/10.1200/JCO.2009.24.2099>.
- [125] Le Cesne Axel, Ray-Coquard Isabelle, Bui Binh Nguyen, Adenis Antoine, Rios Maria, Bertucci François, et al. Discontinuation of imatinib in patients with advanced gastrointestinal stromal tumours after 3 years of treatment: an open-label multicentre randomised phase 3 trial. *Lancet Oncol* 2010;11(10):942–9. [https://doi.org/10.1016/S1470-2045\(10\)70222-9](https://doi.org/10.1016/S1470-2045(10)70222-9).
- [126] Raut Chandrajit P, Posner Matthew, Desai Jayesh, Morgan Jeffrey A, George Suzanne, Zahrieh David, et al. Surgical management of advanced gastrointestinal stromal tumors after treatment with targeted systemic therapy using kinase inhibitors. *J Clin Oncol* 2006;24(15):2325–31. <https://doi.org/10.1200/JCO.2005.05.3439>.
- [127] Bauer S, Rutkowski P, Hohenberger P, Miceli R, Fumagalli E, Siedlecki JA, et al. Long-term follow-up of patients with GIST undergoing metastasectomy in the era of imatinib – analysis of prognostic factors (EORTC-STBSG collaborative study). *Eur J Surg Oncol* 2014;40(4):412–9. <https://doi.org/10.1016/j.ejso.2013.12.020>.
- [128] Yoon In Sun, Shin Ji Hoon, Han Kichang, Kim Pyo Nyun, Kim Ki Hun, Kang Yoon-Koo, et al. Ultrasound-Guided Intraoperative Radiofrequency Ablation and Surgical Resection for Liver Metastasis from Malignant Gastrointestinal Stromal Tumors. *Korean J Radiol* 2018;19(1):54. <https://doi.org/10.3348/kjr.2018.19.1.54>.
- [129] Jung Jin-Hee, Won Hyung Jin, Shin Yong Moon, Kim Pyo Nyun. Safety and Efficacy of Radiofrequency Ablation for Hepatic Metastases from Gastrointestinal Stromal Tumor. *J Vasc Interv Radiol JVIR* 2015;26(12):1797–802. <https://doi.org/10.1016/j.jvir.2015.09.002>.
- [130] Casali Paolo G, Zalcberg John, Le Cesne Axel, Reichardt Peter, Blay Jean-Yves, Lindner Lars H, et al. Ten-Year Progression-Free and Overall Survival in Patients With Unresectable or Metastatic GI Stromal Tumors: Long-Term Analysis of the European Organisation for Research and Treatment of Cancer, Italian Sarcoma Group, and Australasian Gastrointestinal Trials Group Intergroup Phase III Randomized Trial on Imatinib at Two Dose Levels. *J Clin Oncol* 2017;35(15):1713–20. <https://doi.org/10.1200/JCO.2016.71.0228>.
- [131] Demetri George D, van Oosterom Allan T, Garrett Christopher R, Blackstein Martin E, Shah Manisha H, Verweij Jaap, et al. Efficacy and safety of sunitinib in patients with advanced gastrointestinal stromal tumour after failure of imatinib: a randomised controlled trial. *Lancet* 2006;368(9544):1329–38. [https://doi.org/10.1016/S0140-6736\(06\)69446-4](https://doi.org/10.1016/S0140-6736(06)69446-4).
- [132] George S, Blay JY, Casali PG, Le Cesne A, Stephenson P, DePrimo SE, et al. Clinical evaluation of continuous daily dosing of sunitinib malate in patients with advanced gastrointestinal stromal tumour after imatinib failure. *Eur J Cancer Oxf Engl* 2009;45(11):1959–68. <https://doi.org/10.1016/j.ejca.2009.02.011>.
- [133] Demetri George D, Reichardt Peter, Kang Yoon-Koo, Blay Jean-Yves, Rutkowski Piotr, Gelderblom Hans, et al. Efficacy and safety of regorafenib for advanced gastrointestinal stromal tumours after failure of imatinib and sunitinib (GRID): an international, multicentre, randomised, placebo-controlled, phase 3 trial. *Lancet* 2013;381(9863):295–302. [https://doi.org/10.1016/S0140-6736\(12\)61857-1](https://doi.org/10.1016/S0140-6736(12)61857-1).

- [134] Zhang Z, Jiang T, Wang W, Piao D. Efficacy and safety of regorafenib for advanced gastrointestinal stromal tumor after failure with imatinib and sunitinib treatment: A meta-analysis. *Med Baltim* 2017;96:e8698. <https://doi.org/10.1097/md.00000000000008698>.
- [135] Vincenzi B, Nannini M, Badalamenti G, Grignani G, Fumagalli E, Gasperoni S, et al. Imatinib rechallenge in patients with advanced gastrointestinal stromal tumors following progression with imatinib, sunitinib and regorafenib. *Ther Adv Med Oncol* 2018;10:1758835918794623. [10.1177/1758835918794623](https://doi.org/10.1177/1758835918794623).
- [136] Sawaki Akira, Kanda Tatsuo, Komatsu Yoshito, Nishida Toshirou. Impact of rechallenge with imatinib in patients with advanced gastrointestinal stromal tumor after failure of imatinib and sunitinib. *Gastroenterol Res Pr* 2014;2014:1–6. <https://doi.org/10.1155/2014/342986>.
- [137] Nemunaitis John, Bauer Sebastian, Blay Jean-Yves, Choucair Khalil, Gelderblom Hans, George Suzanne, et al. Intrigue: Phase III study of ripretinib versus sunitinib in advanced gastrointestinal stromal tumor after imatinib. *Future Oncol* 2020;16(1):4251–64. <https://doi.org/10.2217/fon-2019-0633>.
- [138] Smrke Alannah, Gennatas Spyridon, Huang Paul, Jones Robin L. Avapritinib in the treatment of PDGFRA exon 18 mutated gastrointestinal stromal tumors. *Future Oncol* 2020;16(22):1641–8. <https://doi.org/10.2217/fon-2020-0348>.