



Universiteit
Leiden
The Netherlands

Ultrasound measurements of brain structures differ between moderate-late preterm and full-term infants at term equivalent age

Boswinkel, V.; Sok, F.I.; Kruse-Ruijter, M.F.; Nijholt, I.M.; Jansen, F.A.R.; Haak, M.C.; ... ; Wezel-Meijler, G. van

Citation

Boswinkel, V., Sok, F. I., Kruse-Ruijter, M. F., Nijholt, I. M., Jansen, F. A. R., Haak, M. C., ... Wezel-Meijler, G. van. (2021). Ultrasound measurements of brain structures differ between moderate-late preterm and full-term infants at term equivalent age. *Early Human Development*, 160. doi:10.1016/j.earlhumdev.2021.105424

Version: Publisher's Version

License: [Creative Commons CC BY-NC-ND 4.0 license](https://creativecommons.org/licenses/by-nc-nd/4.0/)

Downloaded from: <https://hdl.handle.net/1887/3277726>

Note: To cite this publication please use the final published version (if applicable).



Ultrasound measurements of brain structures differ between moderate-late preterm and full-term infants at term equivalent age

Vivian Boswinkel^{a,b,*}, Femke I. Sok^a, Martine F. Krüse-Ruijter^a, Ingrid M. Nijholt^c, Fenna A. R. Jansen^d, Monique C. Haak^d, Martijn F. Boomsma^c, Linda S. de Vries^e, Sylke J. Steggerda^f, Gerda van Wezel-Meijler^a

^a Department of Neonatology, Women and Children's Hospital, Isala, Dokter van Heesweg 2, 8025 AB Zwolle, the Netherlands

^b University Medical Center Utrecht Brain Center, Utrecht University, Universiteitsweg 100, 3584 CG Utrecht, the Netherlands

^c Department of Radiology, Isala, Dokter van Heesweg 2, 8025 AB Zwolle, the Netherlands

^d Department of Obstetrics – Division of Prenatal Diagnosis and Fetal Medicine, Leiden University Medical Center, Albinusdreef 2, 2333 ZA Leiden, the Netherlands

^e Department of Neonatology, Wilhelmina Kinderziekenhuis, University Medical Center Utrecht, Lundlaan 6, 3584 EA Utrecht, the Netherlands

^f Department of Neonatology, Willem Alexander Children's Hospital, University Medical Center Leiden, Albinusdreef 2, 2333 ZA Leiden, the Netherlands

ARTICLE INFO

Keywords:

Moderate-late preterm infants
Cranial ultrasound
Cerebral development
Brain measurements
Reference values

ABSTRACT

Background: Brain growth in moderate preterm (MP; gestational age (GA) 32⁺⁰–33⁺⁶ weeks) and late preterm infants (LP; GA 34⁺⁰–36⁺⁶ weeks) may be impaired, even in the absence of brain injury.

Aims: The aims of this study were to assess brain measurements of MP and LP infants, and to compare these with full-term infants (GA > 37 weeks) using linear cranial ultrasound (cUS) at term equivalent age (TEA).

Study design: cUS data from two prospective cohorts were combined. Two investigators performed offline measurements on standard cUS planes. Eleven brain structures were compared between MP, LP and full-term infants using uni- and multivariable linear regression. Results were adjusted for postmenstrual age at cUS and corrected for multiple testing.

Results: Brain measurements of 44 MP, 54 LP and 52 full-term infants were determined on cUS scans at TEA. Biparietal diameter and basal ganglia-insula width were smaller in MP (−9.1 mm and −1.7 mm, $p < 0.001$) and LP infants (−7.0 mm and −1.7 mm, $p < 0.001$) compared to full-term infants. Corpus callosum – fastigium length was larger in MP (+2.2 mm, $p < 0.001$) than in full-term infants. No significant differences were found between MP and LP infants.

Conclusions: These findings suggest that brain growth in MP and LP infants differs from full-term infants. Whether these differences have clinical implications remains to be investigated.

1. Introduction

Each year more than 15 million infants are born preterm, i.e. before 37 weeks of gestation. More than 80% of the preterm population is born moderate to late preterm (MLPT) at a gestational age (GA) of 32–36 weeks [1]. Overall, these infants more often demonstrate motor and cognitive delays than full-term infants [2–4]. Within the MLPT population, neurodevelopmental problems are more frequently seen in moderate preterm (MP; GA 32⁺⁰–33⁺⁶ weeks) than late preterm (LP; GA 34⁺⁰–36⁺⁶ weeks) infants [5,6]. Why and how MLPT infants develop

these neurodevelopmental delays needs to be further elucidated.

During the third trimester of pregnancy, essential growth and development of the fetal brain take place [7,8]. This includes major organizational events (e.g. establishment of connectivity and remodeling by synaptogenesis and apoptosis), cortical folding and myelination [9–11]. In case of preterm birth, the brain is vulnerable to ischemia and inflammation during this period of impressive growth and development. This injury includes (cystic) periventricular leukomalacia and neuronal/axonal disease, for which the overall term ‘encephalopathy of prematurity’ has been introduced [12]. Other reported injuries are germinal

Abbreviations: cUS, Cranial ultrasound; GA, Gestational age; ICC, Intraclass correlation coefficient; LP, Late preterm; MP, Moderate preterm; MRI, Magnetic resonance imaging; PMA, Postmenstrual age; TEA, Term equivalent age; MLPT, Moderate to late preterm.

* Corresponding author at: Isala Women and Children's Hospital, Department of Neonatology (V.4.4.), PO Box 10400, 8000 GK Zwolle, the Netherlands.

E-mail address: v.boswinkel@isala.nl (V. Boswinkel).

<https://doi.org/10.1016/j.earlhumdev.2021.105424>

Received 20 May 2021; Received in revised form 29 June 2021; Accepted 6 July 2021

Available online 14 July 2021

0378-3782/© 2021 The Authors.

Published by Elsevier B.V. This is an open access article under the CC BY-NC-ND license

(<http://creativecommons.org/licenses/by-nc-nd/4.0/>).

matrix hemorrhage – intraventricular hemorrhage [13] and cerebellar hemorrhage [14].

Although during the last decades, more knowledge has been reported on brain injury in MLPT infants [7,9,15], most information on encephalopathy of prematurity and its associations with neurodevelopmental delay is obtained from the very preterm population (GA < 32 weeks). In very preterm infants with encephalopathy of prematurity, reduced volumes of the white matter, cerebral cortex and deep gray matter have been described [16,17]. In several studies, smaller brain sizes at term equivalent age (TEA) were related to poorer neurodevelopmental outcome at two years of age [18–21].

Studies investigating brain measurements in MLPT infants are scarce. To the best of our knowledge, only Walsh et al. performed linear brain measurements in MLPT infants. Using magnetic resonance imaging (MRI), they demonstrated that MLPT birth was associated with smaller brain sizes [22]. No distinction was made between MP and LP infants.

Although MRI is the golden standard for detecting neonatal brain injury, cranial ultrasound (cUS) is the standard neuro-imaging modality in neonatal practice. cUS can be performed at the bedside with little disturbance to the infant and is therefore more patient friendly. In addition, cUS is a relatively inexpensive technique to evaluate development and growth of the neonatal brain [14]. Whether smaller brain sizes in MLPT infants can be detected using simple linear cUS measurements is unknown.

The aims of this study were therefore 1) to measure sizes of several brain structures in MP and LP infants using cUS; 2) to compare brain measurements between MP, LP and full-term infants at TEA.

2. Methods

2.1. Study population

cUS data from two prospective cohorts were combined. The first cohort consisted of 65 MP (GA 32⁺⁰–33⁺⁶ weeks) and 101 LP infants (GA 34⁺⁰–35⁺⁶ weeks) enrolled in the study ‘Brain Imaging in Moderate to late Preterm infants (BIMP)’ between August 2017 and November 2019 at Isala Women and children’s hospital (IVKC), Zwolle, The Netherlands [23]. The second cohort consisted of 59 full-term infants born between August 2014 and May 2016 at the Leiden University Medical Center (LUMC), Leiden, The Netherlands. These full-term infants were recruited as a control group for a study investigating brain abnormalities in infants with prenatally detected congenital heart defects [24]. Written informed consent was obtained from all parents. The present study, in which we compare linear cUS brain measurements, was filed as amendment and ethical approval was given by the Central Committee in Research Involving Human Subjects, The Hague, The Netherlands (NL52323.075.15).

Only infants in whom cUS was performed between a postmenstrual age (PMA) of 38 to 42 weeks were included. Infants with moderate-severe brain injury, as defined by Boswinkel et al., were excluded [23].

Baseline characteristics such as sex, GA, birth weight and head circumference at birth were collected from medical charts. In MP and LP infants, weight and head circumference were measured on the day of the cUS appointment. As almost all full-term infants were scanned within a week after birth, these measurements were not repeated at the cUS appointment, and weight and head circumference at birth were used. Birth weight percentile was calculated using the ‘Perined Hoftiezer’ Dutch birth weight charts [25].

2.2. Cranial ultrasound

cUS was performed around TEA (preferably at PMA of 38–42 weeks) by one of the investigators (IVKC: VB (research physician) or MKR (pediatrician); LUMC: FARJ (resident obstetrics & gynecology) or SJS (pediatrician-neonatologist). VB, MKR and FARJ were all intensively

trained in neonatal cUS prior to the start of the initial studies. cUS in IVKC was performed under supervision of GvWM (with >25 years of experience in neonatal neuroimaging) and in LUMC under supervision of SJS (with >15 years of experience in neonatal neuroimaging). In IVKC an Aloka Prosound Alpha 7 Premier ultrasound system (Hitachi Medical Systems Holding AG, Switzerland) was used. In LUMC, cUS was performed with an Aloka Alpha 10 ultrasound system (Hitachi Medical Systems Holding AG, Switzerland) or a Toshiba Aplio 400 system (Canon Medical Systems Europe BV, The Netherlands). Images were recorded in six coronal and five sagittal planes using the anterior fontanelle window and at least one coronal and one axial plane using the mastoid fontanelle window [14]. Scans were assessed during and immediately after the procedure by the investigator, checking for lesions with likely clinical consequences. On both locations, all images were digitally stored.

2.3. Linear cUS brain measurements

In both cohorts, all linear cUS brain measurements were performed offline and on site by one investigator (FIS). FIS had been trained to perform cUS measurements by VB and GvWM. The investigator was blinded to patient details. To establish the intra-observer reliability, measurements were repeated in 20 (13% of total) randomly selected scans. A second investigator (VB), blinded to the previous results, repeated measurements in 30 (20% of total) randomly selected scans for inter-observer reliability. Measurements were performed using the software program Clinical Assistant (RCV Medical IT BV Baarn, The Netherlands).

The following measurements were obtained using standard cUS planes (see Fig. 1):

- 1) Anterior fontanelle – coronal plane:
Ventricular index [26], anterior horn width [27], interhemispheric distance [28], basal ganglia width [29], basal ganglia-insula width, biparietal diameter [21,30];
- 2) Anterior fontanelle – sagittal plane:
Corpus callosum length [29], corpus callosum – fastigium length [31], vermis height [29], vermis anterior-posterior diameter [29];
- 3) Mastoid fontanelle – coronal plane:
Transcerebellar diameter [32].

2.4. Statistics

To estimate if our sample size would be sufficient for the intended analysis we conducted a sample size calculation. This calculation was performed in MedCalc Statistical Software version 19.0.5 (MedCalc Software bvba, Ostend, Belgium). No previous studies performed linear cUS measurements in MP and LP infants and thus we based the calculation on the results of the study by Walsh et al. [22]. We took the biparietal diameter as representative measurement. In the study by Walsh et al. the biparietal diameter was 83.6 mm (SD ±4.4) in MLPT infants and 87.8 mm (SD ±4.7) in term infants [22]. Using these results for our sample size calculation, with an alpha of 0.05 and a power of 0.90, we need a sample with 26 infants per group.

Data analyses were performed using SPSS software (version 26.0; SPSS inc, Chicago, Illinois, USA). Continuous variables were assessed for normality and summarized with means (SD), or in case of non-normal distribution, with median (minimum – maximum). Frequency counts and percentages were given for categorical variables. Group differences in baseline characteristics were compared using ANOVA or Kruskal-Wallis for continuous and X²-test or Fishers exact test for categorical variables. Inter- and intra-rater reliability were estimated with intraclass correlation coefficients (ICC). An ICC value of ≥0.90 was considered excellent, values between 0.75 and 0.89 good, between 0.50 and 0.74 moderate and < 0.50 poor [33]. Correlations between confounding factors of interest were investigated using Person correlation

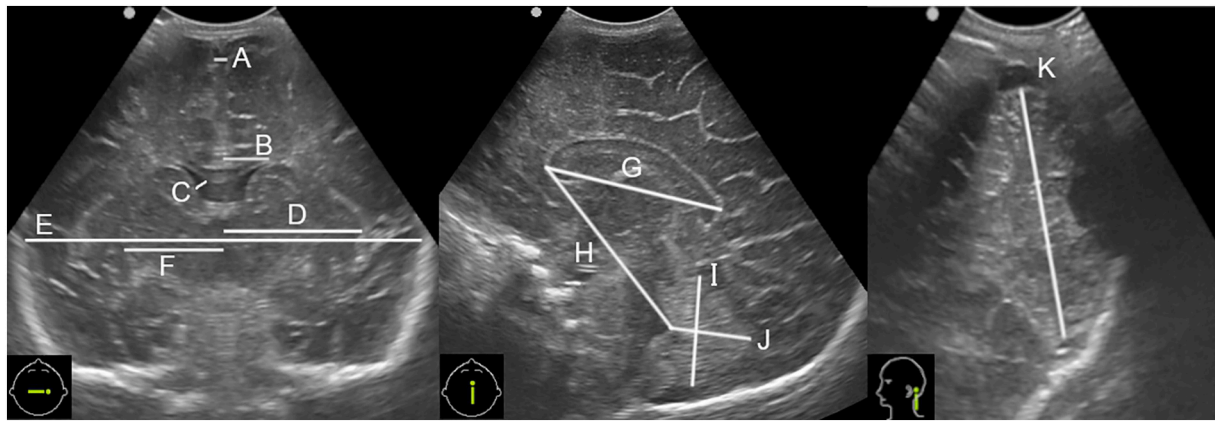


Fig. 1. Overview of linear cUS brain measurements.

A) Interhemispheric distance; B) Ventricular index; C) Anterior horn width; D) Basal ganglia-insula width; E) Biparietal diameter; F) Basal ganglia width; G) Corpus callosum length; H) Corpus callosum - fastigium length; I) Vermis height; J) Vermis anterior-posterior diameter; K) Transcerebellar diameter.

coefficients. Using linear regression differences in linear cUS brain measurements were explored between 1) MP and full-term infants; 2) LP and full-term infants; and 3) MP and LP infants. We corrected for potential confounders using multivariable linear regression. A p -value <0.05 was considered significant. We corrected for multiple testing using Holm-Bonferroni [34].

3. Results

3.1. Study population

In total, 225 infants were enrolled in the two prospective cohort studies combined. Of these, 69 infants did not have a cUS between PMA 38 and 42 weeks. In addition, six MLPT infants were excluded due to presence of moderate-severe brain lesions: one infant with periventricular hemorrhagic infarction, one with arterial infarction, one with ex-vacuo dilatation (ventricular index >15 mm), and three infants with ≥ 6 punctate white matter lesions. Of the remaining 150 infants, 44 were MP, 54 LP and 52 full term infants (Fig. 2). Mean PMA at cUS for all groups was 39.97 (SD 0.99) weeks. PMA at time of cUS was slightly higher in LP infants compared to MP and full-term infants ($p = 0.04$). Percentile birth weight and percentage male infants were not

significantly different between groups (Table 1).

3.2. Inter- and intra-observer reliability

Inter- and intra-observer reliability were good to excellent for most measurements. For the interhemispheric distance, basal ganglia, vermis height and vermis anterior-posterior diameter reliability was moderate (Table 2).

3.3. Multivariable analysis

All baseline characteristics with a p -value <0.20 were assumed potential confounding factors and were investigated. As (birth) weight, head circumference and Perined Hoftiezer birth weight percentile had a high correlation coefficient (>0.50), only the Perined Hoftiezer birth weight percentile was used in the analysis. In addition, PMA at cUS was investigated. The latter was the only confounder observed in the association between infant group (MP, LP or full-term) and the linear cUS brain measurements. Unadjusted and adjusted differences between 1) MP and full-term infants; 2) LP and full-term infants; and 3) MP and LP infants are shown in Supplemental tables 1–3.

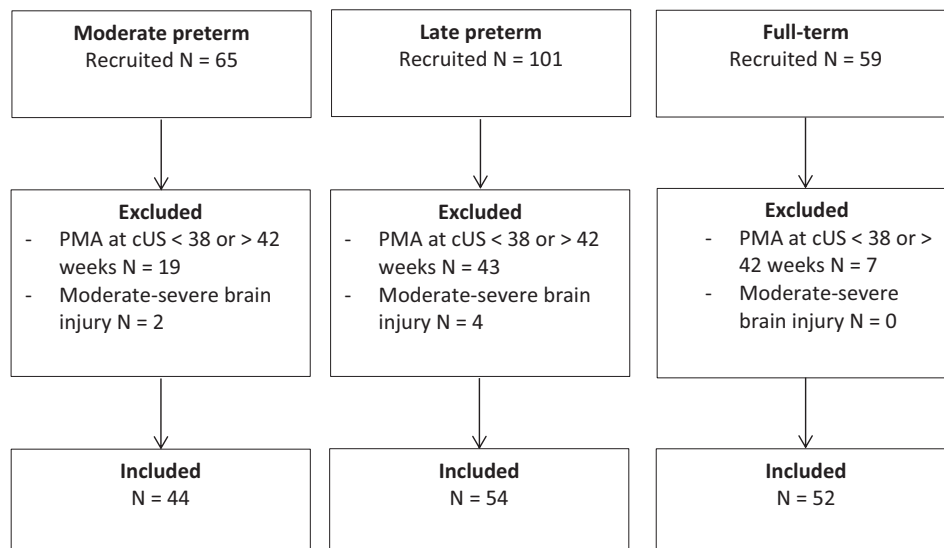


Fig. 2. Inclusion flow chart for study population.

cUS = cranial ultrasound; PMA = postmenstrual age; TEA = term equivalent age.

Table 1
Baseline characteristics.

	Moderate preterm N = 44	Late preterm N = 54	Full-term N = 52	p-Value
GA in weeks, mean (SD)	33.08 (0.5)	34.80 (0.5)	39.81 (1.02)	<0.01
Male, N (%)	25 (56.8)	29 (53.7)	24 (46.2)	0.55
Birth weight in grams, mean (SD)	1996 (458)	2347 (413)	3495 (364)	<0.01
Perined Hofstiezer birth weight percentile	0.39	0.41	0.49	0.17
Weight at cUS in grams, mean (SD)	3256 (467)	3371 (520)	3495 (364) ^b	0.03
Head circumference at birth in cm, mean (SD) ^a	30.79 (1.8)	31.96 (1.4)	35.15 (1.07)	<0.01
Head circumference at cUS in cm, mean (SD)	35.4 (1.5)	35.5 (1.4)	35.15 (1.07) ^b	0.47
PMA at cUS in weeks, mean (SD)	40.09 (0.9)	40.57 (0.9)	40.34 (1.01)	0.04
Age at cUS in days, median, (min. – max.)	49 (36–63)	40 (21–56)	3 (1–11)	<0.01
cUS within 24 h after birth, N (%)	NA	NA	10 (19%)	NA

GA = gestational age; cUS = cranial ultrasound; NA = not applicable; PMA = postmenstrual age.

^a Missing in 12 infants (3 MP, 5 LP and 4 full-term infants).

^b Same as at birth.

Table 2
Inter- and intra-rater correlation coefficients.

	Inter-rater N = 30		Intra-rater N = 20	
	ICC	95% CI	ICC	95% CI
Anterior fontanelle – Coronal plane				
Biparietal diameter	0.83	0.66–0.91	0.93	0.83–0.97
Interhemispheric distance	0.68	0.38–0.84	0.63	0.27–0.84
Ventricular index				
Right	0.86	0.73–0.93	0.97	0.92–0.99
Left	0.88	0.76–0.94	0.81	0.57–0.92
Anterior horn width				
Right	0.78	0.44–0.91	0.95	0.87–0.98
Left	0.83	0.40–0.94	0.91	0.73–0.96
Basal ganglia width				
Right	0.63	0.35–0.81	0.67	0.33–0.86
Left	0.66	0.40–0.82	0.74	0.46–0.89
Basal ganglia – insula width				
Right	0.72	0.49–0.86	0.95	0.87–0.98
Left	0.67	0.28–0.85	0.82	0.58–0.92
Anterior fontanelle – Sagittal plane				
Corpus callosum length	0.87	0.74–0.93	0.89	0.76–0.96
Corpus callosum – fastigium length	0.86	0.73–0.93	0.84	0.62–0.93
Vermis height	0.79	0.58–0.90	0.63	0.26–0.84
Vermis anterior-posterior diameter	0.55	0.19–0.77	0.65	0.12–0.87
Mastoid fontanelle – Coronal plane				
Transcerebellar diameter	0.93	0.83–0.97	0.97	0.92–0.99

ICC = intraclass correlation coefficient; CI = confidence interval.

3.4. Linear cUS brain measurements at TEA

The ranges of the sizes of several brain structures in MP, LP and full-term infants are shown in Fig. 3.

3.5. Comparison of linear cUS brain measurements between MP and full-term infants

MP infants had a significantly smaller mean biparietal diameter compared to full-term infants (79.2 mm vs 88.5 mm, adjusted difference: -9.1 mm; $p < 0.001$). Both mean basal ganglia width and mean basal ganglia-insula width were also significantly smaller in MP infants (19.3 mm and 29.0 mm versus 20.6 mm and 30.7 mm in full-term infants,

adjusted differences between -1.3 mm and -1.7 mm; $p < 0.001$ for all). Mean corpus callosum – fastigium length was larger in MP infants (52.3 mm vs 50.4 mm, adjusted difference: $+2.2$ mm; $p < 0.001$). See Fig. 3 and Supplemental Table 1.

3.6. Comparison linear cUS brain measurements between LP and full-term infants

LP infants had a significantly smaller mean biparietal diameter compared to full-term infants (81.6 mm vs 88.5 mm, adjusted difference: -7.0 mm; $p < 0.001$). Both mean basal ganglia width and mean basal ganglia-insula width were also smaller in LP infants (19.7 mm and 29.0 mm vs 20.6 mm and 30.7 mm in full-term infants, adjusted differences between -1.0 and -1.7 mm, $p \leq 0.001$ for all). See Fig. 3 and Supplemental Table 2.

3.7. Comparison linear cUS brain measurements between MP and LP infants

Small differences in linear cUS brain measurements were seen between MP and LP, but none of these were significantly different after Holm-Bonferroni correction. See Fig. 3 and Supplemental Table 3.

4. Discussion

We reported linear cUS brain measurements in MP and LP infants and demonstrated differences in the size of several brain structures between MP, LP and full-term infants. MP and LP infants had smaller biparietal diameter, basal ganglia width and basal ganglia-insula width compared to full-term infants. No significant differences were found between MP and LP infants.

To our knowledge, this is the first study reporting brain measurements for MP and LP infants at TEA using cUS. Although cUS is so far not routinely performed in this population, it is the primary neonatal neuroimaging modality. Given the good to excellent (≥ 0.75) inter- and intrarater reliability of the biparietal diameter, ventricular index, anterior horn width, corpus callosum and transcerebellar diameter, the measurements give a good indication of the reference values of these structures at TEA in MP and LP infants.

In agreement with the MRI-study by Walsh et al., we found a smaller mean biparietal diameter and basal ganglia width in MP and LP infants compared to full-term infants [22]. However, our differences in biparietal diameter (respectively -9.1 mm for MP and -7.0 mm for LP infants) were larger than the difference reported by Walsh et al. (respectively -3.0 mm for MLPT infants compared to full-term infants). This difference might be partially explained by differences in study samples and methods. While Walsh et al. also included infants born between 36⁺⁰ and 36⁺⁶ weeks' gestation, these infants were not included in our study, as these infants are not routinely admitted at IVKC. Infants born within this GA window may have larger brain structures at TEA, which may reduce the difference with the full-term population. In addition, the use of different imaging techniques (cUS versus MRI) may partly explain the differences. Even though Leijser et al. demonstrated that most structural linear cUS measurements were comparable with MRI, small differences between cUS and MRI measurements were found [29]. Unfortunately, they did not measure the biparietal diameter. Likewise, the difference in basal ganglia width was larger in our study than in the study by Walsh et al. [22]. However, as Walsh et al. measured the basal ganglia width in a different way (i.e. on a T2-weighted axial plane, while we measured this distance in a coronal plane), a reliable comparison between the results of that study and our study is not possible. Interestingly, our reported mean differences in biparietal diameter (respectively -9.1 mm for MP and -7.0 mm for LP compared to full-term infants) were similar to the reported mean difference in biparietal diameter for very preterm infants compared to full-term infants in other studies [30,35].

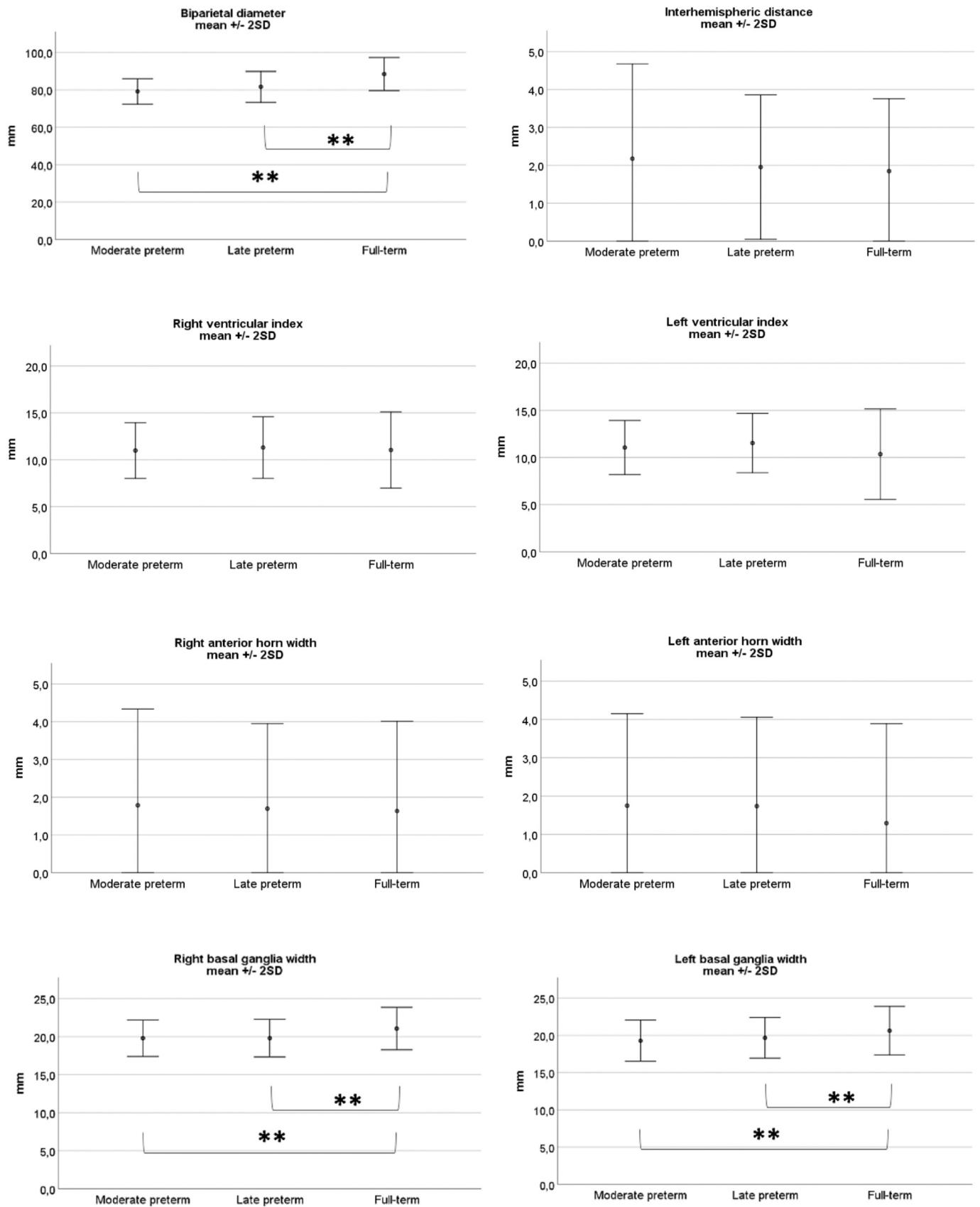


Fig. 3. Comparison of linear cUS brain measurements between MP, LP and full-term infants in mm (mean, error bars: ± 2 SD).

** p-value is significantly different after adjustment for PMA at cUS and Holm-Bonferroni correction.

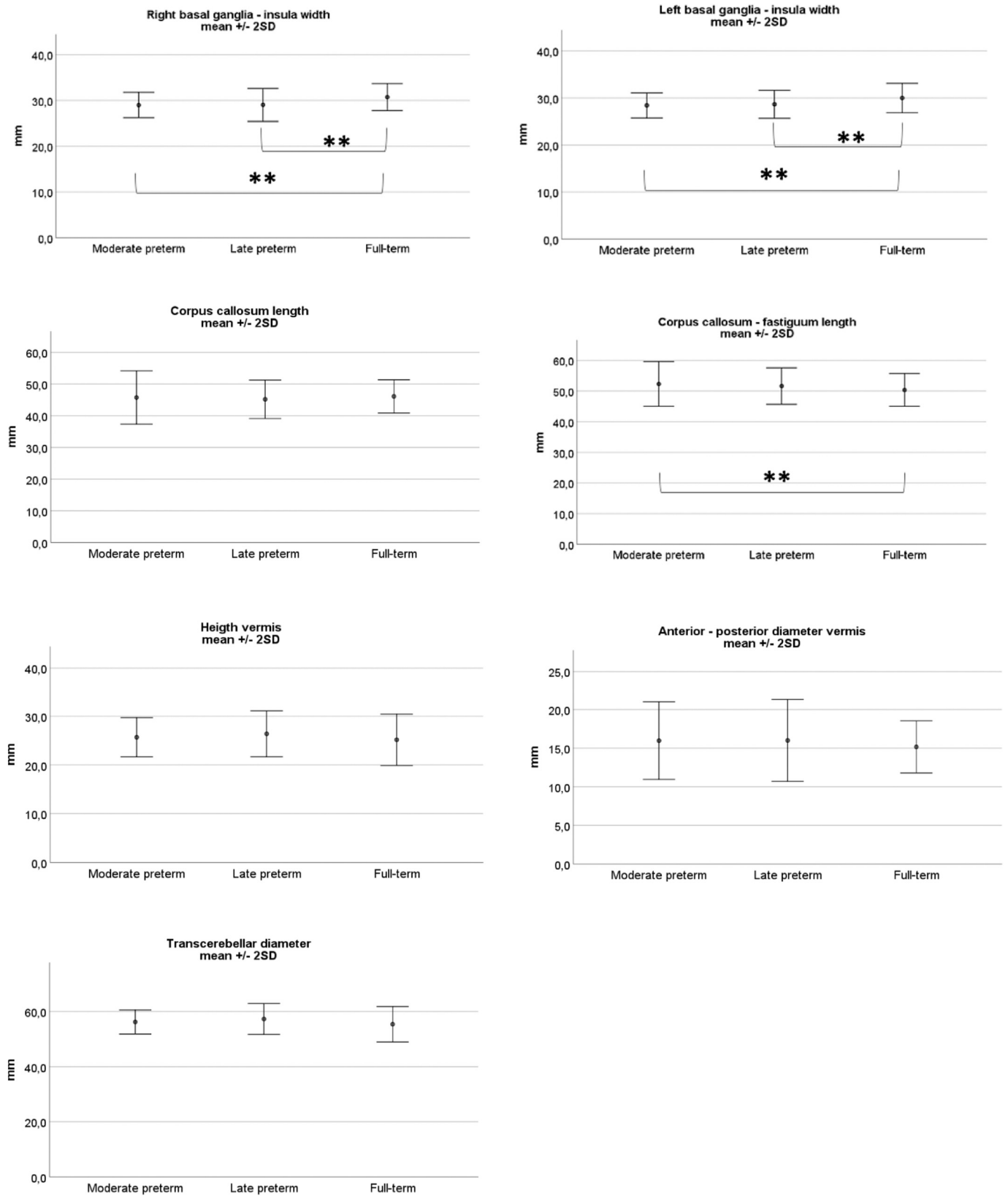


Fig. 3. (continued).

While we expected that most brain structures would be larger in full-term infants, we found one measurement to be smaller in full-term infants. The corpus callosum – fastigium length was significantly larger in MP infants than in full-term infants (mean difference + 2.2 mm). A

possible explanation for this finding and for the smaller biparietal diameter and basal ganglia-insula width might be that positioning of the preterm infant's head plays a role in the direction of growth. Preterm infants are frequently positioned in prone position with their head

rotated to either side, improving respiratory stability [36]. This might reduce growth in the left-right direction and may be compensated by growth in cranial-caudal direction and thus a larger corpus – callosum fastigium length. Graça et al. proposed a method to control for the differences in head shape between preterm and full-term infants [30]. They used the biparietal diameter, occipito-frontal diameter and cranial height in a tri-dimensional ellipsoid model to estimate intracranial and cerebral volumes. They found a smaller biparietal diameter, larger occipito-frontal diameter and larger cranial height in preterm infants, but found no difference in intracranial volume between preterm and full-term infants. However, after adjustment for extracerebral space they demonstrated a significantly smaller cerebral tissue volume in preterm infants compared to full-term infants. Unfortunately, we were not able to measure the occipito-frontal diameter as (at IVKC) only images with a restricted field of view in the midsagittal plane were saved offline and thus, were not able to calculate the cerebral volume nor the extracerebral space.

In very preterm infants, a smaller biparietal diameter measured at TEA was related to poorer cognitive and psychomotor outcome at two years of age [18,20,21]. This might indicate that differences in head shape are probably not the only explanation for the differences we found between MP and LP versus full-term infants, and a smaller biparietal diameter may be of clinical significance in this population as well. Follow-up is required to investigate whether an association between biparietal diameter and outcome also exists in MP and LP infants.

Another essential point is that we did not find a significant difference in cerebellar diameter between MP, LP and full-term infants. This is in contrast to the study of Walsh et al. who reported a smaller cerebellar diameter in MLPT infants compared to full-term infants after making adjustments for sex and PMA at MRI [22]. However, conflicting results are reported when comparing the cerebellar diameter at TEA between very preterm and full-term infants [35,37–40]. Again, intracranial and extracerebral volume may play a key role. Nguyen The Tich et al. found a significant difference in transcerebellar diameter between very preterm and full-term infants on MRI, but did not correct for intracranial volume [38]. Graça et al. found a smaller transcerebellar diameter in very preterm infants on cUS, but also a larger cerebellar vermis volume. When they made adjustments for intracranial volume (i.e. head shape), the differences disappeared. This might indicate a relative preservation of the cerebellar size in very preterm infants [40].

We acknowledge several limitations of our study. Firstly, the group of LP infants was limited to infants born between 34⁺⁰ and 35⁺⁶ weeks. Secondly, although we used the standard coronal and sagittal planes to measure brain structures, even for well-trained sonographers it is difficult to capture the exact identical coronal or sagittal plane in each infant. This may have resulted in small differences between infants. In addition, a few structures had a moderate inter- and intra-rater reliability. Agreements for these structures were likely moderate because the borders were often only vaguely visible, making it difficult to distinguish them from surrounding structures. Using a probe with higher frequencies and thus obtaining a higher near field resolution could have contributed to more precise measurements of some nearby structures, such as the interhemispheric distance and ventricular measurements. Furthermore, we used two-dimensional linear cUS measurements to represent three-dimensional structures and were not able to estimate brain tissue volumes. This should be taken into account while interpreting our data. However, Nguyen the Tich et al. previously reported a good correlation between biparietal diameter and total cerebral tissue volume (both measured using MRI), suggesting that this linear measurement can be used to get a good impression of the actual volume [38]. Finally, we did not look at important markers for brain development such as gyration, which is not easy to quantify on CUS and myelination (not depicted by cUS).

Our findings suggest that not only in very preterm infants but also in MP and LP infants some brain structures have a different growth trajectory compared to full-term infants. The differences with full-term

infants were smaller in LP infants than in MP infants. This is not surprising, since the brain has only reached 65% of full-term weight at 34 weeks of gestation. Accelerated growth in the last weeks of gestation makes the brain potentially vulnerable to events that may interfere with normal brain development e.g. suboptimal environmental factors or cerebral ischemia/reperfusion [7,9,12]. Whether the reported smaller brain structures for MP and LP infants in our study are true reflections of suboptimal growth or rather related to differences in head shape and whether there is an effect on long-term neurodevelopmental outcome remains to be investigated.

5. Conclusions

In conclusion, biparietal diameter and basal ganglia width were significantly smaller in MP and LP infants compared with full-term infants. No significant differences between MP and LP infants were found. Some of the reported linear cUS brain measurements (i.e. those with good and excellent ICC values) obtained in MP and LP infants without moderate-severe brain injury can be considered reference values for brain sizes in this population.

Ethics approval and consent to participate

Written informed consent was obtained from all parents. Ethical approval was given by the Central Committee in Research Involving Human Subjects, The Hague, The Netherlands (NL52323.075.15).

Financial support

The BIMP study (acronym for ‘Brain Imaging in Moderate to late Preterm infants’) was supported by the Isala Science and Innovation Fund (Isala Hospital, Zwolle, the Netherlands), the Dr. C.J. Vaillant Fund (Landelijke Vereniging van Crematoria, Almere, the Netherlands), and Nutricia Specialized Nutrition (Nutricia Nederland BV, Zoetermeer, the Netherlands). Aloka-Hitachi provided a Prosound Alpha 7 Premier system for the cranial ultrasound examinations. The sponsors had no role in the design and conduct of the study, collection, management, analysis, and interpretation of the data, or in the preparation, review, approval of the manuscript, or decision to submit the manuscript for publication.

CRedit authorship contribution statement

All authors contributed to the conception and design of this work and the writing and revision phases of the manuscript. All authors read and approved the final manuscript.

Declaration of competing interest

None.

Acknowledgements

The authors would like to thank all infants and their parents for their participation. We are grateful to our colleagues, (research-) nurses and radiology technicians involved in this study for their contribution.

Appendix A. Supplementary data

Supplementary data to this article can be found online at <https://doi.org/10.1016/j.earlhumdev.2021.105424>.

References

- [1] S. Chawanpaiboon, J. Vogel, A. Moller, P. Lumbiganon, M. Petzold, D. Hogan, et al., Global, regional, and national estimates of levels of preterm birth in 2014: a systematic review and modelling analysis, *Lancet Glob. Health* 7 (1) (2019) e37–e46.

- [2] J. Cheong, L. Doyle, A. Burnett, K. Lee, J. Walsh, C. Potter, et al., Association between moderate and late preterm birth and neurodevelopment and social-emotional development at age 2 years, *JAMA Pediatr.* 171 (4) (2017), e164805.
- [3] J. Kerstjens, A. de Winter, I. Bocca Tjeertes, E.M.J. ten Vergert, S. Reijneveld, A. Bos, developmental delay in moderately preterm-born children at school entry, *J. Pediatr.* 159 (1) (2011) 92–98.
- [4] S. Martínez-Nadal, L. Bosch, Cognitive and learning outcomes in late preterm infants at school age: a systematic review, *Int. J. Environ. Res. Public Health* 18 (2021).
- [5] L. Chyi, H. Lee, S. Hintz, J. Gould, T. Sutcliffe, School outcomes of late preterm infants: special needs and challenges for infants born at 32 to 36 weeks gestation, *J. Pediatr.* 153 (1) (2008) 25–31.
- [6] H.S. Lipkind, M.E. Slopren, M.R. Pfeiffer, K.H. McVeigh, School-age outcomes of late preterm infants in New York City, *Obstet Gynecol* 3 (206(3)) (2012) 1–6.
- [7] H. Kinney, The near-term (late preterm) human brain and risk for periventricular leukomalacia: a review, *Semin. Perinatol.* 30 (2) (2006) 81–88.
- [8] A.M. Guihard-Costa, J.C. Larroche, Growth velocity of some fetal parameters. I. Brain weight and brain dimensions, *Biol. Neonate* 62 (5) (1992) 309–316.
- [9] R.L. Haynes, L.A. Sleeper, J.J. Volpe, H.C. Kinney, Neuropathologic studies of the encephalopathy of prematurity in the late preterm infant, *Clin. Perinatol.* 40 (4) (2013 Dec) 707–722.
- [10] S. Budday, P. Steinmann, E. Kuhl, Physical biology of human brain development, *Front. Cell. Neurosci.* 9 (2015) 257.
- [11] I. Kostović, G. Sedmak, M. Judaš, Neural histology and neurogenesis of the human fetal and infant brain, *Neuroimage* 188 (2019 Mar) 743–773.
- [12] J. Volpe, Brain injury in premature infants: a complex amalgam of destructive and developmental disturbances, *Lancet Neurol.* 8 (1) (2009) 110–124.
- [13] J.J. Volpe, Intraventricular hemorrhage in the premature infant—current concepts. Part II, *Ann. Neurol.* 25 (2) (1989) 109–116.
- [14] G. Meijler, S.J. Steggerda, *Neonatal Cranial Ultrasonography*, 3rd ed., Springer, Cham, 2019.
- [15] V. Boswinkel, J. Nijboer-Oosterveld, I.M. Nijholt, M.A. Edens, Tollenaar Mulder - de, M. Susanne, M.F. Boomsma, et al., A systematic review on brain injury and altered brain development in moderate-to-late preterm infants, *Early Hum. Dev.* 148 (2020) 5–28.
- [16] E.T. Inder Terrie, Abnormal cerebral structure is present at term in premature infants, *Pediatrics* 2 (115(2)) (2005) 286–294.
- [17] K. Keunen, K.J. Kersbergen, F. Groenendaal, I. Isgum, L.S. de Vries, M.J. Benders, Brain tissue volumes in preterm infants: prematurity, perinatal risk factors and neurodevelopmental outcome: a systematic review, *J. Matern. Fetal Neonatal Med.* 25 (Suppl. 1) (2012 Apr) 89–100.
- [18] S. Nguyen The Tich, P.J. Anderson, R.W. Hunt, K.J. Lee, L.W. Doyle, T.E. Inder, Neurodevelopmental and perinatal correlates of simple brain metrics in very preterm infants, *Arch. Pediatr. Adolesc. Med.* 165 (3) (2011 Mar 7) 216–222.
- [19] H.W. Park, H. Yoon, S.B. Han, B.S. Lee, I.Y. Sung, K.S. Kim, et al., Brain MRI measurements at a term-equivalent age and their relationship to neurodevelopmental outcomes, *Am. J. Neuroradiol.* 35 (3) (2014 Mar) 599–603.
- [20] M. Hammerl, M. Zagler, M. Zimmermann, E. Griesmaier, T. Janjic, E.R. Gizewski, et al., Supratentorial brain metrics predict neurodevelopmental outcome in very preterm infants without brain injury at age 2 years, *Neonatology* 117 (3) (2020) 287–293.
- [21] R. Cuzzilla, A.J. Spittle, K.J. Lee, S. Rogerson, F.M. Cowan, L.W. Doyle, et al., Postnatal brain growth assessed by sequential cranial ultrasonography in infants born 30 Weeks' gestational age, *Am. J. Neuroradiol.* 39 (6) (2018) 1170–1176.
- [22] J. Walsh, L. Doyle, P. Anderson, K. Lee, J.L.Y. Cheong, Moderate and late preterm birth: effect on brain size and maturation at term-equivalent age, *Radiology* 273 (1) (2014) 232–240.
- [23] V. Boswinkel, M.F. Krüse-Ruijter, J. Nijboer-Oosterveld, I.M. Nijholt, M.A. Edens, Tollenaar Mulder - de, M. Susanne, et al., Incidence of brain lesions in moderate-to-late preterm infants assessed by cranial ultrasound and MRI: The BIMP-study, *Eur. J. Radiol.* 136 (2021) 109500.
- [24] F.A.R. Jansen, M.C. Haak, M.S. van Wesemael, A.D.J.D. ten Harkel, J.M.M. van Lith, N.A. Blom, et al., A low incidence of preoperative neurosonographic abnormalities in neonates with heart defects, *Early Hum. Dev.* 148 (2020 Sep) 105097.
- [25] L. Hoftiezer, M.H.P. Hof, J. Dijks-Elsinga, M. Hogeveen, C.W.P.M. Hukkelhoven, R. A. van Lingen, From population reference to national standard: new and improved birthweight charts, *Obstet. Gynecol.* 220 (4) (2019) 1–383.
- [26] M.I. Levene, Measurement of the growth of the lateral ventricles in preterm infants with real-time ultrasound, *Arch. Dis. Child.* 56 (12) (1981) 900–904.
- [27] M.W. Davies, M. Swaminathan, S.L. Chuang, F.R. Betheras, Reference ranges for the linear dimensions of the intracranial ventricles in preterm neonates, *Fetal and Neonatal* 82 (3) (2000) 218–223.
- [28] C.F. Hagmann, N.J. Robertson, D. Acolet, N. Nyombi, S. Ondo, M. Nakakeeto, et al., Cerebral measurements made using cranial ultrasound in term Ugandan newborns, *Early Hum. Dev.* 87 (5) (2011) 341–347.
- [29] L. Leijser, L. Srinivasan, M. Rutherford, S. Counsell, J. Allsop, F. Cowan, Structural linear measurements in the newborn brain: accuracy of cranial ultrasound compared to MRI, *Pediatr. Radiol.* 37 (7) (2007) 640–648.
- [30] A.M. Graça, K.R. Cardoso, J.M. da Costa, F.M. Cowan, Cerebral volume at term age: comparison between preterm and term-born infants using cranial ultrasound, *Early Hum. Dev.* 89 (9) (2013 Sep) 643–648.
- [31] J.A. Roelants, I.V. Koning, M.M.A. Raets, S.P. Willemsen, M.H. Lequin, R.P. M. Steegers-Theunissen, et al., A new ultrasound marker for bedside monitoring of preterm brain growth, *Am. J. Neuroradiol.* 37 (8) (2016 Aug 1) 1516–1522.
- [32] M.W. Davies, M. Swaminathan, F.R. Betheras, Measurement of the transverse cerebellar diameter in preterm neonates and its use in assessment of gestational age, *Australas. Radiol.* 45 (3) (2001) 309–312.
- [33] T.K. Koo, M.Y. Li, A guideline of selecting and reporting Intraclass correlation coefficients for reliability research, *J. Chiropr. Med.* 15 (2) (2016) 155–163.
- [34] S. Holm, A simple sequentially Rejective multiple test procedure, *Scand. J. Stat.* 6 (2) (1979) 65–70.
- [35] H. Kidokoro, J. Neil, T. Inder, New MR imaging assessment tool to define brain abnormalities in very preterm infants at term, *Am. J. Neuroradiol.* 34 (11) (2013) 2208–2214.
- [36] W. Picheansathian, P. Woragidpoonpol, C. Baosoung, Positioning of preterm infants for optimal physiological development: a systematic review, *JBI Lib. Syst. Rev.* 7 (7) (2009) 224–259.
- [37] Y. Wu, C. Stoodley, M. Brossard-Racine, K. Kapse, G. Vezina, J. Murnick, et al., Altered local cerebellar and brainstem development in preterm infants, *Neuroimage* 213 (2020) 116702.
- [38] S. Nguyen The Tich, P.J. Anderson, J.S. Shimony, R.W. Hunt, L.W. Doyle, T. E. Inder, A novel quantitative simple brain metric using MR imaging for preterm infants, *Am. J. Neuroradiol.* 1 (30(1)) (2009) 125–131.
- [39] L. Srinivasan, J. Allsop, S.J. Counsell, J.P. Boardman, A.D. Edwards, M. Rutherford, Smaller cerebellar volumes in very preterm infants at term-equivalent age are associated with the presence of supratentorial lesions, *Am. J. Neuroradiol.* 27 (3) (2006) 573–579.
- [40] A.M. Graça, A.F. Geraldo, K. Cardoso, F.M. Cowan, Preterm cerebellum at term age: ultrasound measurements are not different from infants born at term, *Pediatr. Res.* 74 (6) (2013 Dec) 698–704.