



Universiteit
Leiden
The Netherlands

Implantation of an iris-fixated phakic intraocular lens for the correction of hyperopia: 15-year follow-up

Rijn, G.A. van; Gaurisankar, Z.S.; Saxena, R.; Gibbes, D.; Jongman, H.P.; Haasnoot, G.W.; ... ; Luyten, G.P.M.

Citation

Rijn, G. A. van, Gaurisankar, Z. S., Saxena, R., Gibbes, D., Jongman, H. P., Haasnoot, G. W., ... Luyten, G. P. M. (2021). Implantation of an iris-fixated phakic intraocular lens for the correction of hyperopia: 15-year follow-up. *Journal Of Cataract And Refractive Surgery*, 47(6), 748-758. doi:10.1097/j.jcrs.0000000000000532

Version: Publisher's Version
License: [Creative Commons CC BY-NC-ND 4.0 license](https://creativecommons.org/licenses/by-nc-nd/4.0/)
Downloaded from: <https://hdl.handle.net/1887/3213210>

Note: To cite this publication please use the final published version (if applicable).

Implantation of an iris-fixated phakic intraocular lens for the correction of hyperopia: 15-year follow-up



Gwyneth A. van Rijn, MD, Zoraida S. Gaurisankar, MD, Ruchi Saxena, MD, PhD, Destiny Gibbes, MD, Henri P. Jongman, MD, Geert W. Haasnoot, BSc, Yanny Y. Y. Cheng, MD, PhD, Jan-Willem M. Beenakker, PhD, Gregorius P.M. Luyten, MD, PhD

Purpose: To assess the predictability, efficacy, stability, and safety of implantation of an Artisan iris-fixated phakic intraocular lens (IF-pIOL) for the correction of hyperopia with a follow-up of up to 15 years.

Setting: Leiden University Medical Center, the Netherlands.

Methods: Patients operated by a single surgeon up to 2007 were identified, and data on refraction, corrected distance visual acuity (CDVA), uncorrected distance visual acuity, endothelial cell (EC) density, and complications were collected.

Results: A total of 61 eyes (32 patients) were analysed. The mean spherical equivalent decreased from $+6.43 \pm 1.78$ diopters (D) preimplantation to -0.22 ± 0.57 D at 1 year postimplantation and remained stable throughout follow-up. A stable CDVA with safety indices ranging from 0.91 to 1.10 and efficacy indices between 0.43 and 0.86 were observed. Follow-up time had a

significant effect on EC density with an estimated annual decline of 58 cells/mm² after IF-pIOL implantation. IF-pIOL explantation was performed in a 10 eyes (16.4%) after 8.13 ± 5.11 years. The main reason for IF-pIOL explantation was EC loss (4 eyes [6.6%]). Pigment dispersion was the most encountered complication, observed in 9 eyes (14.8%).

Conclusions: Visual and refractive results after implantation of an IF-pIOL to correct hyperopia show favorable and stable results with long-term follow-up. Lifelong monitoring of EC counts is mandatory. Pigment dispersion might be a problem in hyperopic eyes implanted with an IF-pIOL; a shallower anterior chamber depth and a convex iris configuration might be predisposing factors.

J Cataract Refract Surg 2021; 47:748–758 Copyright © 2021 The Author(s). Published by Wolters Kluwer Health, Inc. on behalf of ASCRS and ESCRS

Phakic intraocular lens (pIOL) implantation offers some well-defined advantages over the more popular corneal refractive surgery, such as its reversibility and its broader treatment range. The pIOLs can be classified according to their site of implantation, in the anterior or in the posterior chamber of the eye. A further categorization of anterior chamber pIOLs can be made based on the fixation method: iris-fixated or angle-supported pIOLs. Of these IOLs, only the Artisan (Ophtec BV) iris-fixated pIOL (IF-pIOL) and the Visian ICL (STAAR Surgical Company) posterior chamber pIOL are currently available for the correction of hyperopia. Alshamrani and Alharbi recently reviewed literature on hyperopic refractive errors corrected with a pIOL. They found only a limited number of studies on IF-pIOLs.^{1–10}

Although the first IF-pIOL for the correction of hyperopia was implanted in 1986, studies with a follow-up of more than 5 years after implantation of an IF-pIOL are either lacking or outdated; only 1 preliminary study of the first-generation IF-pIOLs with a follow-up up to 120 months has been published in 1998, and surgical techniques, IOL design, and safety considerations have advanced greatly since.¹⁰ We describe the results of a cohort of 61 hyperopic eyes in 32 patients implanted with an Artisan IF-pIOL with a 15-year follow-up.

METHODS

Study Population

This is a retrospective observational cohort study where charts were searched to identify patients who had undergone Artisan IF-

Submitted: July 14, 2020 | Final revision submitted: October 27, 2020 | Accepted: November 18, 2020

From the Department of Ophthalmology, Leiden University Medical Center, Leiden, the Netherlands (van Rijn, Gaurisankar, Gibbes, Jongman, Cheng, Beenakker, Luyten); Department of Ophthalmology, The Hague Medical Center, The Hague, the Netherlands (Saxena); Department of Immunohematology and blood transfusion, Leiden University Medical Center, Leiden, The Netherlands (Haasnoot); Department of Radiology, Leiden University Medical Center, Leiden, the Netherlands (Beenakker).

Supported by Ophtec BV and Stichting Blindenhulp and by the following foundations through UitZicht: ANVVB and LSBS. The funding organizations provided unrestricted grants and had no role in the design or conduct of this research.

Corresponding author: Gwyneth A. van Rijn, MD, Department of Ophthalmology, Leiden University Medical Center, Albinusdreef 2, Leiden 2333 ZA, the Netherlands. Email: g.a.van_rijn@lumc.nl.

pIOL implantations (model 203) and 32 patients were identified who had been treated by 1 surgeon (G.P.M.L.) with an IF-pIOL for the correction of hyperopic refractive error from 1997 to 2007. The study was conducted in accordance with the Declaration of Helsinki, and informed consent was obtained from all participating patients. The study was approved by the Medical Ethics Committee of the Leiden University Medical Center. Follow-up visits took place 1 month, 3 months, and 6 months postoperatively and yearly thereafter. To assess predictability, efficacy, safety, stability, and complication rate, data on corrected distance visual acuity (CDVA) and uncorrected distance visual acuity (UDVA), refraction, endothelial cell (EC) count, complications, and secondary surgical interventions were collected. EC measurements were acquired with 3 models of the Topcon SP-series corneal specular microscope (CSM; Topcon Medical Systems, Inc.): SP1000, SP2000P, and SP3000P, because of changes in equipment throughout the years. To increase reliability of the EC counts, converting factors were calculated to improve the interchangeability of EC counts. Details are described elsewhere.¹¹ Central corneal thickness (CCT) measurements were preoperatively acquired with the Topcon SP-series corneal specular microscope. Postoperative CCT measurements were acquired with Pentacam (OCULUS Optikgeräte GmbH).

As per safety guidelines of the manufacturer, at the time of implantation, all patients had (1) to be of general good health, (2) a minimum of 18 years of age, (3) to have had a stable hyperopic refraction for at least 1 year, (4) a central EC density (ECD) of more than 2000 cells/mm², and (5) an anterior chamber depth (ACD) of at least 2.6 mm (first 8 patients). After 1998, eligibility criteria were adjusted to a minimum ACD of 3.0 mm (measured from the corneal epithelium), and a convex iris configuration was considered an exclusion criterion. Other exclusion criteria for IF-pIOL implantation were a mesopic pupil size of 5.0 mm or greater and an intraocular pressure more than 21 mm Hg and/or glaucoma.

The pIOL power calculations were performed by Ophtec BV with the Van der Heijde formula.¹² This formula uses the mean corneal curvature (mean keratometry [Km]), the adjusted ACD, and the manifest refraction spherical equivalent (MRSE) at a vertex distance of 12.0 mm. A factor of 0.6 for the effective lens position was applied. The surgical procedure as described by Saxena et al. was used for all eyes.⁸

Statistical Analysis

Outcome variables were tested for normality with the Shapiro-Wilks test. A paired *t* test was used to compare preoperative to postoperative data. One-way analysis of variance with post-hoc Tukey honestly significance difference was applied to compare the differences between follow-up periods. When the distribution of

data were nonparametric or the number of eyes was less than 10, a Wilcoxon signed-rank test was used to compare preoperative and postoperative data, and a Kruskal-Wallis test with post hoc Mann-Whitney *U* test was applied to compare the differences between follow-up periods. In addition, a linear mixed model was applied to examine the development over time of our main parameters of interest: CDVA, UDVA, MRSE, and EC counts. As fixed effect in the model, follow-up time was measured in years. As random effects, patient and eye within patient were entered to estimate an intercept of each eye within each patient. A *P* value less than 0.05 was considered statistical significant. When using multiple comparisons, a Bonferroni adjustment was applied. Statistics were performed using IBM SPSS Statistics for Windows software (version 23, IBM Corp.).

The MRSE was calculated by using the subjective refraction according to the formula: MRSE in diopters (D) = Sphere + (0.5 × Cylinder). Data on visual acuity was converted to logarithmic angle of minimum resolution units for calculation purposes. The efficacy index is the ratio of mean postoperative UDVA (decimal) to mean preoperative CDVA (decimal). The safety index is the ratio of mean postoperative CDVA (decimal) to mean preoperative CDVA (decimal). To allow for comparisons with previously published literature, EC change was defined as the paired difference between the preoperative and postoperative examination and expressed as an annual change in percentage from the preoperative cell density. Amblyopic eyes, defined as a preoperative CDVA of less than 0.40 Snellen or a difference of more than 2 Snellen lines in CDVA compared with the fellow eye with a recorded history of strabismus, in an ametropic but otherwise normal eye, were excluded for analysis for visual and refractive outcomes but were included in the analysis for EC change and complication rates.

RESULTS

Study Population

Thirty-two patients were included in this study of which 17 were men (32 eyes, 52.5%) and 15 were woman (29 eyes, 47.5%). A total of 61 eyes were implanted with an IF-pIOL, of which 30 were right eyes and 31 left eyes. In 3 patients, only 1 eye was included for analysis because the fellow eye was implanted with a toric IF-pIOL (2 eyes), and 1 patient had undergone unilateral IF-pIOL implantation. The baseline characteristics are listed in Table 1. Three patients (9.4%) were lost to follow-up, and 2 patients (6.3%) died during the study. Thirteen eyes (21.3%) met the criteria for amblyopia. These 13 eyes were excluded for analysis for

Table 1. Baseline Characteristics.

Preoperative demographics	N	Mean	SD	Range (min–max)	Percentiles		
					25	50	75
Age at implantation (y)	61	41.60	8.71	25.34, 59.54	35.07	41.89	47.12
MRSE (D)	61	6.64	1.85	1.88, 10.50	5.38	6.88	7.88
Implanted IF-pIOL (D)	61	8.47	2.45	2.50, 12.00	6.50	9.00	10.25
Axial length (mm)	61	21.25	0.76	19.47, 22.96	20.87	21.23	21.59
ACD (mm)	61	3.30	0.28	2.70, 3.91	3.08	3.30	3.48
IOP (mm Hg)	61	14.97	3.08	7.00, 20.00	12.00	15.00	18.00
CDVA (LogMAR)	61	0.09	0.21	–0.18, 1.00	0.00	0.00	0.10
Follow-up time (y)	61	10.55	3.92	0.00, 15.09	9.13	10.93	13.96
EC density (cells/mm ²)	50	2818	410	2009, 3721	2500	2821	3188

ACD = anterior chamber depth including corneal pachymetry; CDVA = corrected distance visual acuity; EC = endothelial cell; IF-pIOL = iris-fixed phakic intraocular lens; IOP = intraocular pressure; MRSE = manifest refraction spherical equivalent

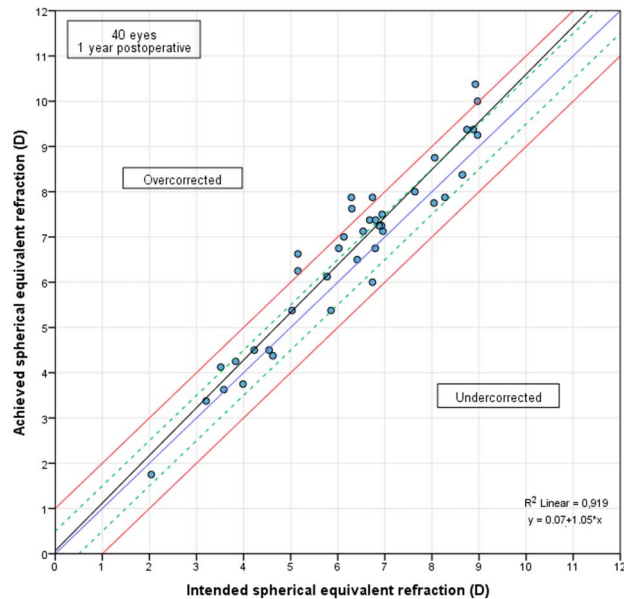


Figure 1. Predictability, deviation from intended correction 1 year after implantation of an Artisan iris-fixed phakic intraocular lens in hyperopic eyes in diopters. The red line represents 1.00 D deviation from intended correction, the green line represents 0.50 D deviation from intended correction, the blue line shows that $x = y$, and the black line is the interpolation line.

visual and refractive outcomes but were included in the analysis for EC change and complication rates.

Refractive Results

A total of 83% of eyes were within ± 1.00 D from intended correction at 1 year follow-up. All eyes outside of this range were overcorrected (average overcorrection 0.40 ± 0.56 D); 90% of eyes were within ± 1.00 D from emmetropia at 1 year follow-up (Figures 1 and 2).

The MRSE decreased significantly after implantation of the IF-pIOL from $+6.43 \pm 1.87$ D preoperative to -0.22 ± 0.57 D at 1 year postimplantation ($P < .001$). The postoperative MRSE remained stable, with no statistically significant change throughout the follow-up period (Tables 2 and 3 and Figure 3).

Visual Acuity

At 1 year, 5 years, 10 years, and 15 years after implantation the efficacy indexes were 0.73, 0.69, 0.66, and 0.72, respectively (Table 4 and Figure 4). The UDVA is plotted against time in Figure 5, A. Post hoc testing with Bonferroni adjustment from 5 years postoperatively showed no statistically significant difference in UDVA at the different follow-up periods compared with that of the 1-year follow-up period. More details on UDVA can be found in Table 5. In addition, linear regression showed no statistically significant effect of time on UDVA (Table 3).

At 1 year, 5 years, 10 years, and 15 years after implantation the safety indexes were 0.98, 0.99, 1.10, and 1.02, respectively (Table 4). At 1 year postoperatively, the

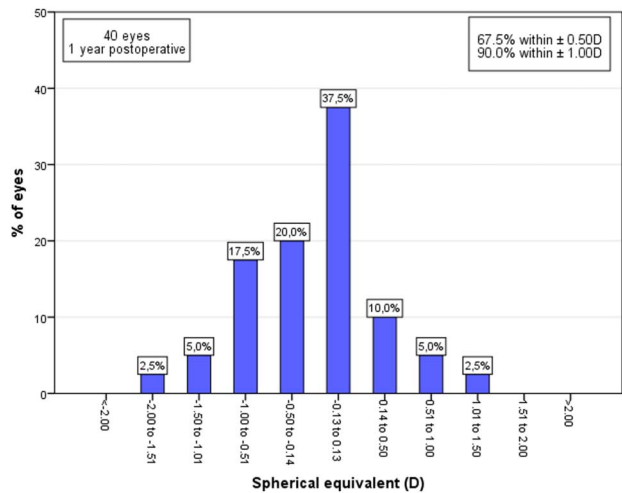


Figure 2. Deviation from emmetropia 1 year after implantation in hyperopic eyes implanted with an Artisan iris-fixed phakic intraocular lens.

mean change of CDVA compared with preoperative was 0.01 ± 0.05 logarithmic angle of minimum resolution units, with 97.5% having no change in CDVA and no eye losing 2 or more lines in CDVA (Figure 6). At the final individual follow-up visit, 3 eyes (6.3%) had a decrease in CDVA of more than 2 Snellen lines, all due to cataract. The Kruskal-Wallis test revealed no statistically significant difference in CDVA between the different follow-up periods ($P = .085$). Similar to the UDVA, linear regression showed no statistically significant effect of time on CDVA. More details on CDVA can be found in Tables 3 and 6 and Figure 5, B.

Complications

Cataract In 15 eyes (24.6%), a degree of cataract formation was noted, of which 73% was classified as nuclear. The mean time to cataract formation was 11.10 years (SD 2.17 years; range 8.44 to 14.55 years). The mean age at cataract formation was 55.70 years (SD 7.17; range 43.77 to 67.43 years). The cataract was clinically significant enough in 3 eyes (2 nuclear and 1 cortical combined with posterior capsule cataract) that phacoemulsification with concomitant IF-pIOL explantation and pseudo-phakic IOL implantation was performed, after 9.2 years, 13.1 years, and 12.6 years, respectively. The age of the patients at the time of explantation was 44.3, 61.5 years, and 62.2 years.

Pigment Dispersion and Inflammation Several degrees of inflammation and pigment dispersion with concomitant posterior synechiae formation were observed. Formation of posterior synechiae was noted in 11 eyes (18%) of 8 patients. Two eyes had an early uncontrollable inflammatory reaction that was unresponsive to medical therapy, which led to IF-pIOL explantation. In the other 9 eyes (14.8%), posterior synechiae formation occurred quietly, without active signs of inflammation, which led to explantation in 1 eye (Figure 7, A); none of the other 8 eyes experienced

Table 2. MRSE in Hyperopic Eyes Implanted With an Artisan IF-pIOL.

Follow-up period	N	Mean (D)	SD	Range, min, max	95% CI	P value ^a
Preop	48	6.43	1.87	1.88, 9.63	5.88, 6.97	<.001
1 mo	44	-0.30	0.65	-2.00, 1.63	-0.50, -0.10	1.000
3 mo	39	-0.47	0.67	-2.00, 0.88	-0.69, -0.26	.999
6 mo	29	-0.45	0.70	-1.75, 1.50	-0.72, -0.18	1.000
1 y	40	-0.22	0.57	-1.63, 1.13	-0.40, -0.03	—
2 y	31	-0.26	0.73	-1.75, 1.00	-0.53, 0.01	1.000
3 y	27	-0.24	0.64	-1.63, 0.88	-0.50, 0.01	1.000
4 y	18	-0.23	0.49	-1.50, 0.50	-0.48, 0.02	1.000
5 y	20	-0.23	0.73	-1.50, 1.38	-0.57, 0.12	1.000
6 y	17	-0.11	0.67	-1.88, 0.88	-0.45, 0.23	1.000 ^b
7 y	19	-0.06	0.71	-1.50, 1.00	-0.40, 0.28	1.000
8 y	12	-0.21	0.90	-1.88, 0.88	-0.78, 0.36	1.000
9 y	19	0.05	1.03	-2.00, 1.38	-0.45, 0.54	.999
10 y	12	-0.54	0.81	-2.00, 0.38	-1.05, -0.02	.999
11 y	14	-0.38	0.76	-2.00, 0.63	-0.82, 0.05	1.000
12 y	11	-1.01	1.23	-2.81, 1.00	-1.83, -0.18	.167
13 y	8	-0.87	1.14	-2.81, 0.63	-1.82, 0.08	1.000 ^b
14 y	6	-1.13	1.11	-2.63, 0.50	-2.29, 0.04	.306 ^b
15 y	5	-0.45	0.94	-1.50, 1.00	-1.62, 0.72	1.000 ^b

IF-pIOL = iris-fixated phakic intraocular lens; MRSE = manifest refraction spherical equivalent; preop = preoperatively;

^aAnalysis of variance post hoc Tukey honestly significance difference compared with 1 year postop

^bMann-Whitney *U* compared with 1 year postop with Bonferroni adjustment

secondary elevation of intraocular pressure or loss of CDVA, and they are monitored strictly. The mean time to synechiae formation was 88.66 ± 65.77 months (range 0.62 to 161.05 months). The group with synechiae formation had a significantly shallower preoperative ACD compared with that of the group without synechiae formation: 3.09 ± 0.19 mm compared with 3.34 ± 0.28 mm ($P = .006$, *t* test).

EC Change Figure 8 displays the EC change for all eyes during the different follow-up periods. A trend toward EC loss might be noticed from the box plot although the range per period is wide. Paired comparison (paired *t* test) between preoperative and postoperative EC values are listed in Table 7. There is a statistically significant difference between preoperative ECD and 6 years, 7 years, 9 years, and 11 years postoperatively. Linear regression analysis showed a statistically significant effect of follow-up time on EC loss, indicating a decline in ECD of 58 cells/mm² per year (Table 3). Six eyes (9.8%) had an ECD of below 1500 cells/mm² at final individual visit after a mean of 10.63 ± 3.15 years. There was no statistically significant difference in preoperative ECD ($P = .327$), but the median preoperative and

postoperative ACD in the group with less than 1500 cells/mm² was statistically significantly shallower compared with the eyes with an ECD of more than 1500 cells/mm² ($P = .044$ and $P = .016$, respectively) (Table 8). Four eyes have undergone IF-pIOL explantation due to EC loss, and 2 eyes are closely monitored with additional follow-up visits every 4 to 6 months. Overall, there was a mean increase of 38.81 ± 13.07 μ m (range 17.00 to 73.00 μ m) in CCT from 10 years postoperatively compared with preoperative values ($P < .001$, paired *t* test). The reason for this increase is believed to be a measurement inconsistency caused by difference in measurement devices used for preoperative measurements and postoperative measurement of CCT (corneal specular microscope vs Pentacam). There was no statistically significant difference in CCT between the group with an ECD less than 1500 cells/mm² and the group with an ECD more than 1500 cells/mm² at the last postoperative visit ($P = .139$) (Table 8).

Other Complications At the last follow-up visit, no eye had developed glaucoma or ocular hypertension. No retinal complications developed.

Table 3. Estimated Time Slopes for Main Interest Variables.

Variable	β -Time	95% CI	P value ^a
MRSE postimplantation (D)	-0.005	-0.018, 0.007	.391
CDVA (logMAR)	-0.001	-0.002, 0.000	.068
UDVA (logMAR)	-0.003	0.000, 0.005	.061
EC change (cells/mm ²)	-57.776	-63.246, -52.305	<.001

β -time = regression coefficient of follow-up time in years; CDVA = corrected distance visual acuity; EC = endothelial cell; MRSE = manifest refraction spherical equivalent; UDVA = uncorrected distance visual acuity

^aLinear mixed model, a *P* value of <0.05 was considered statistically significant

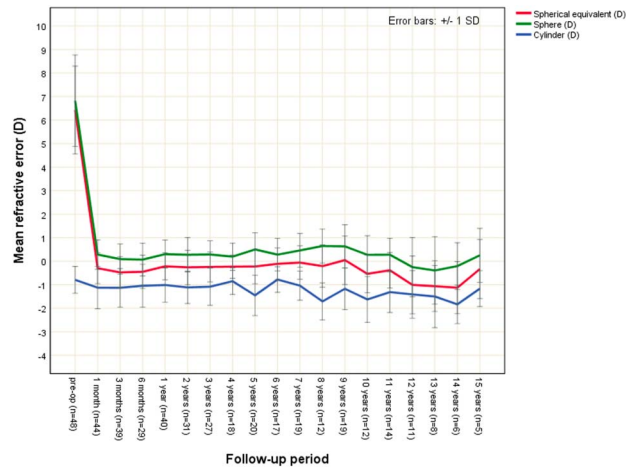


Figure 3. Stability of refractive error over time in hyperopic eyes with an Artisan iris-fixated intraocular lens.

Secondary Surgical Interventions

Repositioning One IF-pIOL (1.6%) was repositioned 6 years after implantation to enlarge the iris enclavation site to prevent lens dislocation.

Explantation IF-pIOL explantation with concomitant phacoemulsification and posterior chamber IOL implantation was performed after a mean of 8.13 ± 5.11 years (range 0.14 to 13.14 years) in 10 eyes of 7 patients (16.4%). A total of 4 IF-pIOLs (6.6%) were explanted due to EC loss after a mean of 10.77 ± 1.52 years, 3 (4.9%) due to early postoperative uncontrollable inflammatory reactions or pigment dispersion after a mean of 1.06 ± 1.29 years, and another 3 (4.9%) due to clinically significant cataract after a mean of 11.67 ± 2.14 years. Of the 4 eyes requiring explantation due to EC loss, all eyes had a postexplantation CDVA of 1.00 or better, no lines CDVA were lost compared with pre-IF-pIOL implantation, and corneal clarity is

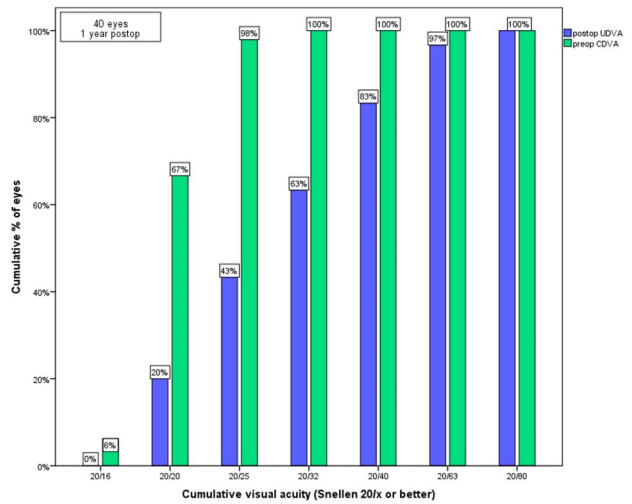


Figure 4. Efficacy at 1 year postimplantation of an Artisan iris-fixated intraocular lens in hyperopic eyes. The cumulative percentage of eyes with a preoperative CDVA (green bars) and postoperative UDVA (blue bars) is shown.

maintained. Of the 3 eyes explanted due to early uncontrollable inflammation of pigment dispersion, 1 eye lost 1 line of CDVA, and the other 2 eyes returned to baseline CDVA. The CDVA of all 3 eyes explanted due to cataract returned to baseline. At 10 years, 85% of the IF-pIOLs was still in situ, and after 15 years, 72% of the IF-pIOLs was still in situ. Figure 9 shows the survival curve of the Artisan hyperopic IF-pIOL of the study cohort.

DISCUSSION

The past 2 decades have shown that refractive errors can be successfully corrected with implantation of IF-pIOLs.^{3,9,13-16} Most of the findings, however, concern myopic correction. To date, there is a paucity of studies

Table 4. Safety and Efficacy Index Per Follow-Up Period.

Period	N	Safety index (min-max)	N	Efficacy index (min-max)
1 mo	43	0.94 (0.53, 1.20)	44	0.75 (0.33, 1.20)
3 mo	39	0.93 (0.50, 1.20)	39	0.69 (0.36, 1.20)
6 mo	29	0.94 (0.76, 1.20)	29	0.69 (0.38, 1.00)
1 y	40	0.98 (0.72, 1.20)	40	0.73 (0.42, 1.11)
2 y	31	0.96 (0.70, 1.20)	29	0.72 (0.30, 1.20)
3 y	27	1.00 (0.70, 1.20)	29	0.73 (0.40, 1.00)
4 y	18	0.98 (0.80, 1.26)	19	0.81 (0.42, 1.26)
5 y	20	0.99 (0.70, 1.20)	22	0.69 (0.30, 1.06)
6 y	18	1.02 (0.80, 1.33)	22	0.81 (0.50, 1.09)
7 y	19	1.00 (0.83, 1.27)	19	0.79 (0.50, 1.02)
8 y	14	1.05 (0.83, 1.27)	12	0.74 (0.42, 1.11)
9 y	19	1.04 (0.63, 1.33)	18	0.77 (0.38, 1.15)
10 y	12	1.10 (0.80, 1.64)	11	0.66 (0.41, 0.83)
11 y	14	1.06 (0.72, 1.45)	11	0.86 (0.41, 1.22)
12 y	11	0.94 (0.63, 1.15)	8	0.54 (0.22, 0.91)
13 y	8	0.91 (0.63, 1.15)	6	0.65 (0.34, 1.00)
14 y	6	0.99 (0.91, 1.05)	4	0.43 (0.37, 0.48)
15 y	5	1.02 (0.80, 1.45)	5	0.72 (0.32, 1.15)

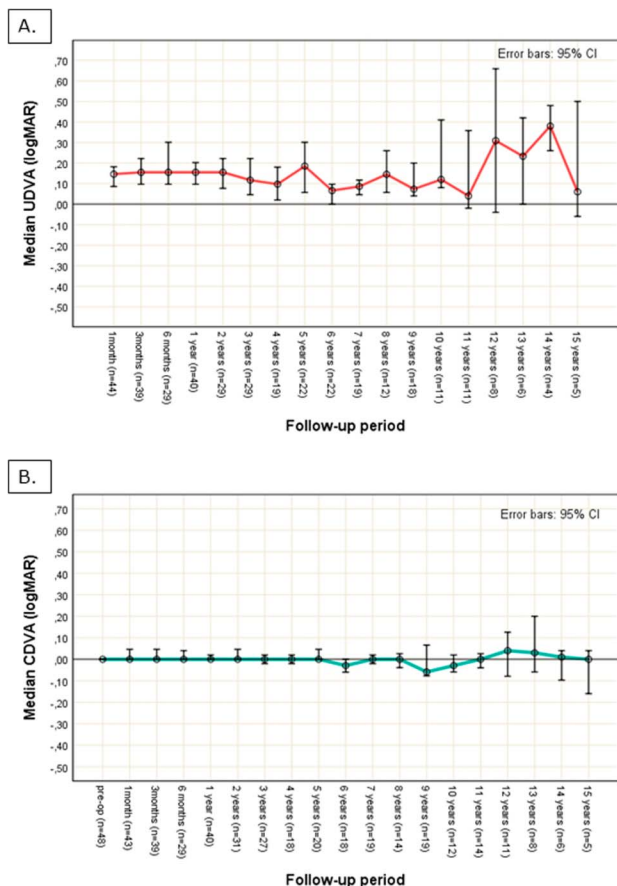


Figure 5. Stability over time of the (A) UDVA and (B) CDVA in hyperopic eyes implanted with an Artisan iris-fixated intraocular lens.

reporting long-term outcomes in hyperopic patients. In this study, we report the results of a cohort of 61 hyperopic eyes implanted with an Artisan IF-pIOL with a follow-up of up to 15 years. This is the first study, to our knowledge, to report such long-term results for the correction of hyperopic refractive error with an Artisan IF-pIOL.

The refractive predictability was good, with 90% of eyes having a postimplantation MRSE within ± 1.00 D from emmetropia at the 1-year follow-up, without statistically significant changes during the follow-up period. Our results are comparable with previously published papers in predictability where rates between 64% and 97% have been reported to be within ± 1.00 D of attempted correction.^{2,3,5,9}

Visual results were favorable. We found a stable CDVA throughout the follow-up of up to 15 years, with concomitant good safety indices between 0.91 and 1.10. These high safety indices indicate that the expected minification effect of the retinal image after hyperopic correction did not significantly influence the CDVA, comparable with findings of the study by Alio et al.² Regarding efficacy, we found a wide range of UDVA from 0.42 to 0.91 Snellen. There was no statistically significant change in UDVA during follow-up. Although there is no statistically significant change in MRSE, there is a slight trend toward myopisation of the MRSE from 10 years onward (Figure 3). Age-related crystalline lens changes might lead to a change in MRSE, although it should be considered that this tendency toward myopisation might have been caused by a patient selection effect.

Table 5. Details of UDVA in Hyperopic Eyes Implanted With an Artisan iris-fixated pIOL.

Follow-up period	N	Median UDVA logMAR (decimal)	Percentile 25	Percentile 75	Range, min, max	P value ^a
Preop	48	—	—	—	—	—
1 mo	44	0.15 (0.71)	0.03	0.23	0.50, -0.08	—
3 mo	39	0.16 (0.70)	0.10	0.30	0.52, -0.09	—
6 mo	29	0.16 (0.70)	0.05	0.30	0.50, -0.08	—
1 y	40	0.16 (0.70)	0.04	0.22	0.42, -0.08	—
2 y	29	0.16 (0.70)	0.05	0.22	0.52, -0.08	—
3 y	29	0.12 (0.76)	0.05	0.28	0.42, -0.08	—
4 y	19	0.10 (0.80)	0.02	0.18	0.38, -0.10	—
5 y	22	0.19 (0.65)	0.06	0.30	0.52, -0.02	1.000
6 y	22	0.07 (0.86)	0.00	0.10	0.30, -0.08	.200
7 y	19	0.09 (0.82)	0.05	0.12	0.32, 0.00	1.000
8 y	12	0.15 (0.72)	0.07	0.23	0.34, 0.00	1.000
9 y	18	0.07 (0.85)	0.04	0.20	0.52, 0.00	1.000
10 y	11	0.12 (0.76)	0.09	0.40	0.48, 0.02	1.000
11 y	11	0.04 (0.91)	0.00	0.24	0.48, -0.06	1.000
12 y	8	0.31 (0.49)	0.06	0.51	0.66, -0.04	1.000
13 y	6	0.23 (0.58)	0.06	0.41	0.42, 0.00	1.000
14 y	4	0.38 (0.42)	0.29	0.46	0.48, 0.26	.051
15 y	5	0.06 (0.87)	0.04	0.20	0.50, -0.06	1.000

pIOL = phakic intraocular lens; Preop = preoperatively; UDVA = uncorrected distance visual acuity

^aMann-Whitney U test compared with 1-year postop with Bonferroni adjustment

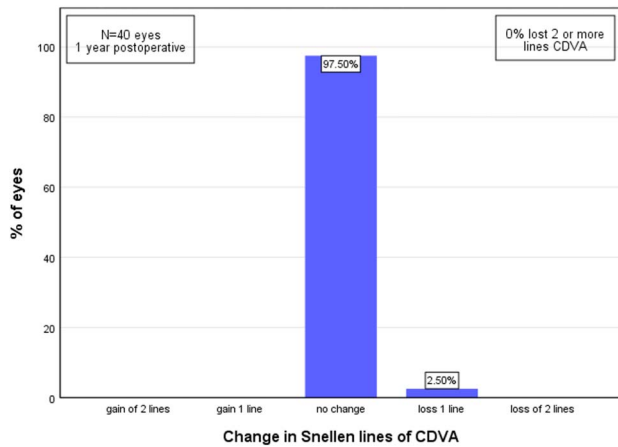


Figure 6. Bar graph demonstrating the change in Snellen lines of CDVA 1 year post-implantation compared with preoperative in hyperopic eyes with an iris-fixated phakic intraocular lens. One Snellen line change in CDVA equals 0.10 logMAR.

Clinically significant cataract formation occurred in 4.9% of eyes, which is in line with previously published articles.¹⁷ Anterior capsular cataract could be a result of surgical trauma during enclavation or intermittent touch with the pIOL and crystalline lens; none of the eyes in this study developed anterior capsular cataract. This is in contrast with studies regarding the posterior chamber phakic implantable collamer lens (ICL) where anterior subcapsular cataract was described more often.^{18,19} Similar to previously published literature on the IF-pIOL, the cataract in the patient population of this study was mainly of the nuclear sclerotic type.²⁰ Long-term population-based follow-up studies have provided evidence to support that

hyperopia might increase the risk for nuclear cataract development compared with emmetropic eyes.²¹ Earlier cataract formation in IF-pIOL-implanted hyperopic eyes vs unoperated hyperopic eyes might be related to various factors such as the material of the IF-pIOL itself, metabolic effects, intermittent touch, or sterile intraocular (sub-clinical) inflammation processes.

This study showed a decrease of EC density over time and a wide range of data and an increasingly smaller sample size in later follow-up periods. Caution should be exercised in interpreting results because statistical tests might have limited power. In an earlier review and meta-analysis by us in hyperopic eyes, we found estimated annual loss of 65.5 cells/mm². Jonker et al. reported an annual decline of 48 cells/mm² and 61 cells/mm² in a myopic and toric IF-pIOL groups, respectively.^{22,23} We found a comparable estimated overall decline of 58 cells/mm² per follow-up year after implantation of an IF-pIOL. The studies by Saxena et al. and Güell et al. reported on EC changes from 5.4% to 11.7% in the period of 2 to 4 years after IF-pIOL implantation in hyperopic eyes.^{3,8} Literature on myopic eyes implanted with an IF-pIOL, with a follow-up of more than 7 years, reported an EC loss from 4.9% to 22.5%.^{13,23–25} The result of this study, with a cumulative EC loss at 10 years of 17.5%, is comparable with these previously published articles.

EC loss seems a bigger concern with anterior chamber pIOLs compared with posterior chamber pIOLs because of the location of the pIOL and the proximity to the endothelium. It seems that, with ICL implantation EC loss occurs mainly during the first postoperative period and stabilizes thereafter.^{18,26} With the IF-pIOL, EC loss might accelerate during long follow-up because the ACD might become shallower with increasing age. In this study, the

Table 6. Details on CDVA in Hyperopic Eyes Implanted With an Artisan iris-fixated pIOL.

Follow-up period	N	Median CDVA logMAR (decimal)	Percentile 25	Percentile 75	Range, min–max	P value ^a
Preop	48	0.00 (1.00)	−0.03	0.04	0.12, −0.18	—
1 mo	43	0.00 (1.00)	0.00	0.09	0.22, −0.08	—
3 mo	39	0.00 (1.00)	0.00	0.07	0.30, −0.09	—
6 mo	29	0.00 (1.00)	0.00	0.08	0.22, −0.08	—
1 y	40	0.00 (1.00)	−0.01	0.05	0.10, −0.10	—
2 y	31	0.00 (1.00)	−0.02	0.05	0.16, −0.08	—
3 y	27	0.00 (1.00)	−0.04	0.02	0.16, −0.08	—
4 y	18	0.00 (1.00)	−0.02	0.02	0.12, −0.14	—
5 y	20	0.00 (1.00)	0.00	0.06	0.16, −0.08	—
6 y	18	−0.03 (1.07)	−0.06	0.00	0.10, −0.20	1.000
7 y	19	0.00 (1.00)	−0.02	0.02	0.08, −0.08	1.000
8 y	14	0.00 (1.00)	−0.04	0.02	0.05, −0.16	1.000
9 y	19	−0.06 (1.15)	−0.08	0.07	0.20, −0.10	1.000
10 y	12	−0.03 (1.07)	−0.06	0.02	0.10, −0.22	1.000
11 y	14	0.00 (1.00)	−0.04	0.02	0.14, −0.16	1.000
12 y	11	0.04 (0.91)	−0.06	0.07	0.20, −0.14	1.000
13 y	8	0.03 (0.93)	−0.06	0.10	0.20, −0.06	1.000
14 y	6	0.01 (0.98)	−0.04	0.02	0.04, −0.10	1.000
15 y	5	0.00 (1.00)	−0.06	0.02	0.04, −0.16	1.000

CDVA = corrected distance visual acuity; pIOL = phakic intraocular lens; preop = preoperatively

^aMann-Whitney U test compared with 1-year postoperative with Bonferroni adjustment

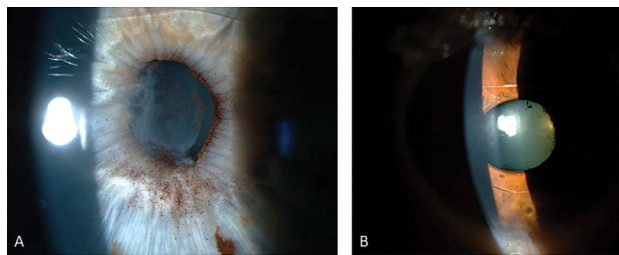


Figure 7. Photograph of a hyperopic eye with an Artisan iris-fixed phakic intraocular lens in situ and pigment dispersion. **A:** Severe pigment dispersion; note the pigment deposits, posterior synechiae, and the formation of a fibrin membrane over the iris and crystalline lens. **B:** Mild pigment dispersion; note the mild posterior synechiae and mild pigment deposits.

annual percentage of EC loss remained within a stable range with a mean annual rate of 1.6% decline in ECD, which is comparable with the annual EC loss of 1.8% with the ICL reported by Packer. To be able to compare the magnitude of EC loss, a detailed meta-analysis or comparison study between anterior and posterior chamber pIOLs with long-term follow up would be of great value for the future.²⁷ An ECD of below 1500 cells/mm² is considered an explantation criterion by the AFSSAPS (French Health Products and Safety Agency) and American Academy of Ophthalmology task force for recommendations on specular microscopy for pIOLs.^{28,29} It is believed that this is a safe ECD to perform cataract surgery without compromising corneal clarity. In this study population, 6 eyes (9.8%) had an ECD of below 1500 cells/mm² after a mean of 10.63 years. In 2 of these 6 eyes, explantation was

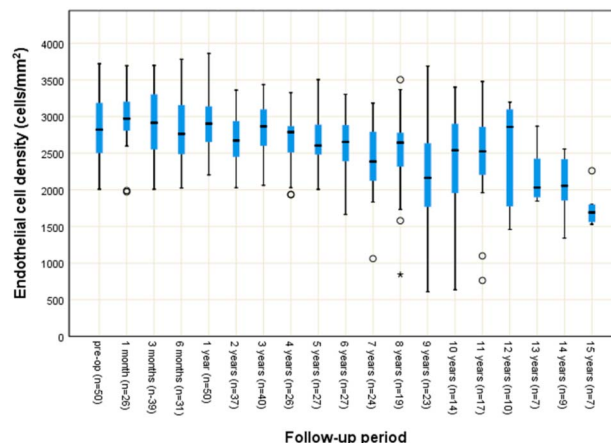


Figure 8. Box plots of all available endothelial cell count data over time in the study cohort of 61 hyperopic eyes with an Artisan iris-fixed phakic intraocular lens.

postponed after careful consideration of physician and patient. Corneal clarity is maintained in all 6 eyes with excellent CDVAs, although 3 eyes with EC densities between 500 and 800 cells/mm² are prone to corneal decompensation in the near future. Close monitoring of the corneal clarity and ECD is performed with an interval of 4 to 6 months and patients are explicitly reminded not to rub their eyes. A shallower preoperative ACD was found in these eyes compared with the group with EC densities above 1500 cells/mm². Moreover, evidence has been provided by previous articles that a shallow and crowded ACD is related to higher rates of EC loss.^{17,23,30-32}

Period	N	Mean preop ECD ± SD (cells/mm ²)	Mean postop ECD ± SD (cells/mm ²)	P value	Yearly rate of loss (%)
Preop	50	2818 ± 410	—	—	—
1 mo	22	2983 ± 397	2996 ± 442	1.000 ^a	—
3 mo	33	2823 ± 429	2873 ± 485	1.000 ^a	—
6 mo	27	2776 ± 407	2761 ± 467	1.000 ^a	—
1 y	40	2850 ± 392	2934 ± 412	.744 ^a	-3.98
2 y	29	2798 ± 346	2646 ± 383	.114 ^a	2.73
3 y	32	2953 ± 341	2843 ± 373	.482 ^a	1.24
4 y	19	2772 ± 407	2595 ± 397	.214 ^a	1.59
5 y	22	2917 ± 404	2692 ± 368	.172 ^a	1.54
6 y	20	2817 ± 334	2583 ± 416	.014 ^a	1.39
7 y	18	2823 ± 323	2397 ± 512	.005 ^a	2.16
8 y	13	2873 ± 470	2405 ± 742	.130 ^a	2.04
9 y	19	2863 ± 439	2108 ± 763	.000 ^a	2.93
10 y	13	2824 ± 467	2329 ± 768	.108 ^a	1.75
11 y	15	2976 ± 466	2441 ± 730	.004 ^a	1.63
12 y	9	2940 ± 487	2471 ± 742	1.000 ^b	1.33
13 y	7	2858 ± 221	2199 ± 393	.420 ^b	1.77
14 y	8	2900 ± 393	2090 ± 438	.176 ^b	2.00
15 y	6	2904 ± 158	1752 ± 267	.416 ^b	2.64

% = annual percentage loss from preoperative (a positive number indicates a decline); ACD = anterior chamber depth including corneal pachymetry; ECD = endothelial cell density; pIOL = phakic intraocular lens; preop = preoperative
^aPaired t test with Bonferroni adjustment
^bWilcoxon signed-rank test with Bonferroni adjustment

Table 8. Difference in ACD, ECD, and CCT in Hyperopic Eyes Implanted With an iris-fixated pIOL Lens With ECDs Below and Above 1500 cells/mm² at the Last Individual Follow-Up.

Data	Eyes with ECD <1500 cells/mm ²	Eyes with ECD >1500 cells/mm ²	P value ^a
N	5	45	.327
Median preop ECD (range)	2606 (2226, 3188)	2826 (2009, 3121)	
25th percentile, 75th percentile	2318, 2875	2505, 3191	
N	6	55	.044
Median preop ACD (range) (mm)	3.09 (2.97, 3.21)	3.33 (2.70, 3.91)	
25th percentile, 75th percentile	3.05, 3.20	3.10, 3.49	
N	5	38	.016
Median postop ACD (range) (mm)	2.78 (2.66, 2.90)	3.10 (2.57, 3.56)	
25th percentile, 75th percentile	2.69, 2.80	2.89, 3.36	
N	5	36	.139
Median postop CCT (range) (μm)	535 (527, 572)	569 (459, 644)	
25th percentile, 75th percentile	529, 562	544, 590	

ACD = anterior chamber depth including corneal pachymetry; CCT = central corneal thickness; ECD = endothelial cell density

^aMann-Whitney *U* test, a *P* value <0.05 was considered statistically significant.

Reliability of the evaluation of the corneal endothelium is a recurrent topic for discussion. Accurate and reliable EC analysis is not easy to perform. Reasons for imprecise EC measurements are known to be (1) the accuracy of operator–software interaction, (2) software precision, (3) specular reflection limitations leading to the generation of a low-quality image, (4) versatility for acquiring endothelial mosaic images, and (5) sampling processes.³³ Moreover, with long follow-up, change in equipment and analyzing technicians is inevitable. This poses a threat and weakness for long-term (retrospective) studies. Measurements acquired with different CSMs are prone to interchangeability problems. We discovered an interchangeability problem with the CSMs, the Topcon SP-2000P and SP-3000P, manufactured by the same company (Topcon Medical Systems). The interchangeability concern in this case was caused by software imprecision and erroneous calibration and led to a difference in ECD of up to 500 cells/mm². To increase the reliability of the EC measurements, we have incorporated a method we have described in detail elsewhere.¹¹ Using this method, we were able to (retrospectively) calculate a correction factor for ECD measurements performed by different specular microscopes, improving the reliability of the ECD measures for the purpose of longitudinal comparison. In future prospective trials, great attention should be given on evaluation of the corneal endothelium. EC mapping would ideally be integrated in the study protocol, enabling evaluation of EC loss in relation to the proximity of the pIOL to the corneal endothelium.

In this study population, 16.4% of the IF-pIOLs were explanted after a mean of 8.13 ± 5.11 years. With a predicted 72% of pIOLs still in situ after 15 years, we report a slightly better survival of the IF-pIOL than that reported in the study by Jonker et al.¹⁷ EC loss was the main reason for IF-pIOL explantation (6.6%) and was comparable with the incidence reported by Jonker et al., who also reported EC loss to be the main reason for explantation of IF-pIOLs in hyperopic eyes.¹⁷ Posterior synechiae formation with or without active signs of inflammation, however, was the

most encountered complication. We observed posterior synechiae formation in 18% of the eyes. Previous articles reported from 6% up to 15% pigment dispersion and synechiae formation.^{8,34} Noteworthy is that the study by Saxena et al. (15%) partly consists of the same eyes reported in this article. A high rate of pigment dispersion in 15 (68.2%) of 22 hyperopic eyes was described in a long-term ICL study by Kocova et al.¹⁹ Although a selection bias might be present in their study, the incidence of pigment dispersion in hyperopic eyes was significantly higher than that in myopic eyes, and they concluded that hyperopic eyes seem to be more prone to pigment dispersion because of their crowded anatomical ratios. A distinction should be made between immediate postoperative uveitis-like inflammatory reactions responsible for posterior synechiae formation and pigment deposits.³⁴ The immediate postoperative inflammatory uveitis-like reaction can usually be treated topically with steroids and

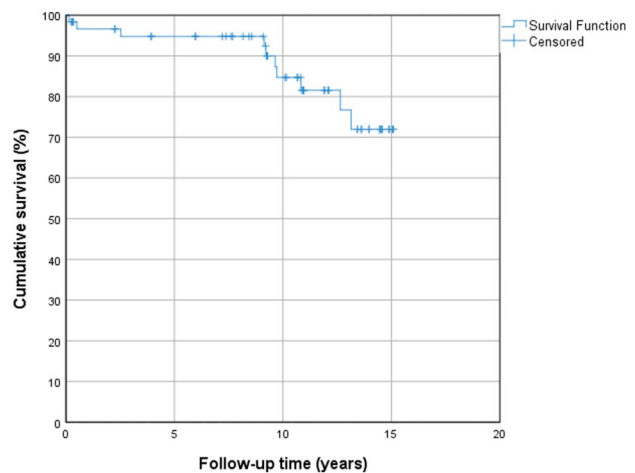


Figure 9. Kaplan-Meier curve showing the explantation/survival curve of the Artisan IF-pIOL in a cohort of 61 hyperopic eyes. Within the first 5 years, 3 IF-pIOLs were explanted due to inflammatory reactions or pigment dispersion. In the 5 years thereafter, 1 IF-pIOL was explanted due to cataract formation, and 2 due to excessive EC loss. After 10 years, 2 IF-pIOLs were explanted due to excessive EC loss and 2 IF-pIOLs due to cataract. pIOL = phakic intraocular lens

mydriasis.³⁵ In cases of pigment dispersion after IF-pIOL implantation without active inflammatory signs, the only medical solution is to explant the IF-pIOL in seriously affected cases. In 2 eyes, an early postoperative active inflammatory reaction preceded and accompanied posterior synechiae formation. In the 9 other eyes (14.8%), synechiae formation developed in a quiet eye with no other signs of active inflammation. We found a mean time to synechiae formation of 7.38 ± 5.48 years after implantation. This silent formation of posterior synechiae is probably caused by abnormal pressure on the iris through being sandwiched between the crystalline lens and the IF-pIOL. Slowly progressive pigment dispersion might be due to progressive shallowing of the ACD because of age-related crystalline lens thickening, which in turn might be accompanied by a slow but progressive convex bowing of the iris, leading to abnormal iris compression between the posterior pIOL and anterior pole of the crystalline lens and a concomitant increase in stress on the enclavation sites. Messina et al. additionally hypothesized that enclavating the full thickness of the iris, including the iris pigment epithelium, might predispose eyes to pigment dispersion.³⁶ The slightly less concave shape of the hyperopic IF-pIOL might also play a role. We believe that the high incidence of pigment dispersion in the hyperopic IF-pIOL population is multifactorial. First, we found evidence that the preoperative ACD in eyes that developed synechiae was significantly shallower than eyes that did not develop synechiae. Additional statistical analysis revealed that 12.2% of the eyes with an ACD more than 3.0 mm measured from the *epithelium* developed synechiae, in contrast to 0% in eyes with an ACD of more than 3.0 mm measured from the *endothelium* (Appendices 1 and 2, available at <http://links.lww.com/JRS/A284> and <http://links.lww.com/JRS/A285>). We, therefore, recommend a slight adjustment in eligibility criteria where the minimum ACD should be measured from the corneal endothelium instead of the currently proposed safety guidelines in which the ACD is measured from the corneal epithelium. Second, iris configuration and/or a high crystalline lens rise might have contributed to the incidence of synechiae formation in this study because 4 eyes were recorded to have a subjective convex iris configuration, and in 5 of 11 eyes with posterior synechiae formation, the IF-pIOL was implanted before 1998, before iris configuration became a safety criterion.³⁴ Unfortunately, we were not able to retrospectively determine the crystalline lens rise in this study population because preoperative measurements of ACD were mostly performed with A-scan biometry. Further studies are needed to evaluate to what extent each of these previous and possible other, still unknown, factors contribute to pigment dispersion. It should be considered that selection bias and variations in examination protocols, material, and technicians because of a long follow-up period might have influenced the results of the outcome variables. Patients who forget regular follow-up visits might have fewer complaints, resulting in overestimating complication rates in this study. Still, in the preoperative informed consent of eligible patients, the risk for pigment dispersion, EC loss, and cataract formation should be included. Because lifelong yearly follow-up visits are a

mandatory safety requirement, patients and physicians should make an agreement on how to meet this obligation.

In conclusion, the visual and refractive results after IF-pIOL implantation to correct hyperopia were good and stable for 15 years. EC loss was the main reason for IF-pIOL explantation, which underlines the need for mandatory lifelong monitoring of EC counts. An estimated annual EC loss of 58 cells/mm² was found in this study, indicating a careful assessment of the minimum required age-dependent ECD preimplantation. Care should be taken when considering implanting and monitoring an IF-pIOL in a hyperopic eye because pigment dispersion might present an additional problem in hyperopic eyes seldom seen in myopic eyes. The mechanism behind this remains unclear. Until we have a better understanding of the mechanism behind the development of pigment dispersion with an IF-pIOL in place, we recommend an ACD more than 3.0 mm measured from the corneal endothelium and to closely evaluate and monitor the anterior chamber dimensions with modern anterior chamber imaging techniques, in addition to a proper and careful enclavation technique.

REFERENCES

- Alshamrani AA, Alharbi SS. Phakic intraocular lens implantation for the correction of hyperopia. *J Cataract Refract Surg* 2019;45:1503–1511
- Alio JL, Mulet ME, Shalaby AM. Artisan phakic iris claw intraocular lens for high primary and secondary hyperopia. *J Refract Surg* 2002;18:697–707
- Güell JL, Morral M, Gris O, Gaytan J, Sisquella M, Manero F. Five-year follow-up of 399 phakic Artisan-Verisyse implantation for myopia, hyperopia, and/or astigmatism. *Ophthalmology* 2008;115:1002–1012
- Muñoz G, Alió JL, Montés-Micó R, Albarrán-Diego C, Belda JI. Artisan iris-claw phakic intraocular lens followed by laser in situ keratomileusis for high hyperopia. *J Cataract Refract Surg* 2005;31:308–317
- Pop M, Payette Y. Refractive lens exchange versus iris-claw Artisan phakic intraocular lens for hyperopia. *J Refract Surg* 2004;20:20–24
- Dick HB, Alió J, Bianchetti M, Budo C, Christiaens BJ, El-Danasoury MA, Güell JL, Krumeich J, Landesz M, Loureiro F, Luyten GP, Marinho A, Rahhal MS, Schwenn O, Spirig R, Thomann U, Venter J. Toric phakic intraocular lens: European multicenter study. *Ophthalmology* 2003;110:150–162
- Alio JL, Mulet ME, Gutierrez R, Galal A. Artisan toric phakic intraocular lens for correction of astigmatism. *J Refract Surg* 2005;21:324–331
- Saxena R, Landesz M, Noordzij B, Luyten GP. Three-year follow-up of the Artisan phakic intraocular lens for hypermetropia. *Ophthalmology* 2003;110:1391–1395
- Qasem Q, Kirwan C, O'Keefe M. 5-year prospective follow-up of Artisan phakic intraocular lenses for the correction of myopia, hyperopia and astigmatism. *Ophthalmologica* 2010;224:283–290
- Fechner PU, Singh D, Wulff K. Iris-claw lens in phakic eyes to correct hyperopia: preliminary study. *J Cataract Refract Surg* 1998;24:48–56
- van Rijn GA, Wijnen CJF, van Dooren BT, Cheng YY, Beenakker JM, Luyten GP. Improved interchangeability with different corneal specular microscopes for quantitative endothelial cell analysis. *Clin Ophthalmol* 2020;14:61–70
- Van der Heijde GL. Some optical aspects of implantation of an IOL in a myopic eye. *Eur J Implant Refractive Surg* 1989;1:245–248
- Tahzib NG, Nuijts RM, Wu WY, Budo CJ. Long-term study of Artisan phakic intraocular lens implantation for the correction of moderate to high myopia: ten-year follow-up results. *Ophthalmology* 2007;114:1133–1142
- Stulting RD, John ME, Maloney RK, Assil KK, Arrowsmith PN, Thompson VM. Three-year results of Artisan/Verisyse phakic intraocular lens implantation. Results of the United States Food and Drug Administration clinical trial. *Ophthalmology* 2008;115:464–472.e461
- Budo C, Hessloeh JC, Izak M, Luyten GP, Menezo JL, Sener BA, Tassignon MJ, Termote H, Worst JG. Multicenter study of the Artisan phakic intraocular lens. *J Cataract Refract Surg* 2000;26:1163–1171
- Silva RA, Jain A, Manche EE. Prospective long-term evaluation of the efficacy, safety, and stability of the phakic intraocular lens for high myopia. *Arch Ophthalmol* 2008;126:775–781

17. Jonker SMR, Van Averbeke AAC, Berendschot TTJM, Saelens IEY, Nuijts RMMA. Risk factors for explantation of iris-fixated phakic intraocular lenses. *J Cataract Refract Surg* 2019;45:1092–1098
18. Pesando PM, Ghiringhelli MP, Di Meglio G, Fanton G. Posterior chamber phakic intraocular lens (ICL) for hyperopia: ten-year follow-up. *J Cataract Refract Surg* 2007;33:1579–1584
19. Kocova H, Vikova E, Michalcova L, Rybarova N, Motyka O. Incidence of cataract following implantation of a posterior-chamber phakic lens ICL (Implantable Collamer Lens)-long-term results. *Cesk Slov Oftalmol* 2017;73:87–93
20. Chen LJ, Chang YJ, Kuo JC, Rajagopal R, Azar DT. Metaanalysis of cataract development after phakic intraocular lens surgery. *J Cataract Refract Surg* 2008;34:1181–1200
21. Wong TY, Klein BE, Klein R, Tomany SC, Lee KE. Refractive errors and incident cataracts: the beaver dam eye study. *Invest Ophthalmol Vis Sci* 2001;42:1449–1454
22. van Rijn GA, Gaurisankar ZS, Ilgenfritz AP, Lima JEE, Haasnoot GW, Beenakker JM, Cheng YYY, Luyten GPM. Middle- and long-term results after iris-fixated phakic intraocular lens implantation in myopic and hyperopic patients: a meta-analysis. *J Cataract Refract Surg* 2020;46:125–137
23. Jonker SMR, Berendschot TTJM, Ronden AE, Saelens IEY, Bauer NJC, Nuijts RMMA. Long-term endothelial cell loss in patients with artisan myopia and artisan toric phakic intraocular lenses: 5- and 10-year results. *Ophthalmology* 2018;125:486–494
24. Chebli S, Rabilloud M, Burillon C, Kocaba V. Corneal endothelial tolerance after iris-fixated phakic intraocular lens implantation: a model to predict endothelial cell survival. *Cornea* 2018;37:591–595
25. Choi BJ, Lee JK, Lee JS. Ten-year long-term endothelial cell changes after iris-fixed phakic intraocular lens implantation in Korean patients. *J Clin Exp Ophthalmol* 2014;5:1–5
26. Edelhauser HF, Sanders DR, Azar R, Lamielle H; Group ICLIToMS. Corneal endothelial assessment after ICL implantation. *J Cataract Refract Surg* 2004;30:576–583
27. Packer M. The Implantable Collamer Lens with a central port: review of the literature. *Clin Ophthalmol* 2018;12:2427–2438
28. MacRae S, Holladay JT, Hilmantel G, Calogero D, Masket S, Stark W, Glasser A, Rorer E, Tarver ME, Nguyen T, Eydelman M. Special report: American Academy of Ophthalmology task force recommendations for specular microscopy for phakic intraocular lenses. *Ophthalmology* 2017;124:141–142
29. Bernard PFM. Presbyopic Intraocular Lenses Newlife/Vivarte Presbyopic; Observational Study of Tolerance of Newlife Implant. 2006. Available at: <http://ansm.sante.fr/S-informer/Informations-de-securiteRetraits-de-lots-et-de-produits/Lentilles-intra-oculaires-NEW>. Accessed October 26, 2020
30. Saxena R, Boekhoorn SS, Mulder PG, Noordzij B, van Rijn G, Luyten GP. Long-term follow-up of endothelial cell change after artisan phakic intraocular lens implantation. *Ophthalmology* 2008;115:608–613.e601
31. Shajari M, Scheffel M, Koss MJ, Kohnen T. Dependency of endothelial cell loss on anterior chamber depth within first 4 years after implantation of iris-supported phakic intraocular lenses to treat high myopia. *J Cataract Refract Surg* 2016;42:1562–1569
32. Doors M, Cals DW, Berendschot TT, de Brabander J, Hendrikse F, Webers CA, Nuijts RM. Influence of anterior chamber morphometrics on endothelial cell changes after phakic intraocular lens implantation. *J Cataract Refract Surg* 2008;34:2110–2118
33. Abib FC, Holzchuh R, Schaefer A, Schaefer T, Godois R. The endothelial sample size analysis in corneal specular microscopy clinical examinations. *Cornea* 2012;31:546–550
34. Baikoff G, Bourgeon G, Jodai HJ, Fontaine A, Lellis FV, Trinquet L. Pigment dispersion and Artisan phakic intraocular lenses: crystalline lens rise as a safety criterion. *J Cataract Refract Surg* 2005;31:674–680
35. Sridhar MS, Majji AB, Vaddavalli PK. Severe inflammation following iris fixated anterior chamber phakic intraocular lens for myopia. *Eye (Lond)* 2006;20:1094–1095
36. Messina M, Elalfy M, Fares U, Ghaz N, Mavi B, Dua H. Creeping posterior synechiae following hyperopic iris-fixated phakic implants. *Int Ophthalmol* 2016;36:901–905

Disclosures: *None of the authors has a financial or proprietary interest in any material or method mentioned.*

First author:

Gwyneth A. van Rijn, MD

Department of Ophthalmology, Leiden University Medical Center, Leiden, the Netherlands

This is an open-access article distributed under the terms of the Creative Commons Attribution-NonCommercial-NoDerivatives License 4.0 (CC BY-NC-ND), which permits downloading and sharing the work provided it is properly cited. The work cannot be changed in any way or used commercially without permission from the journal.