



Universiteit
Leiden
The Netherlands

Prenatal exome sequencing: a useful tool for the fetal neurologist

Koning, M.A. de; Hoffer, M.J.V.; Nibbeling, E.A.R.; Bijlsma, E.K.; Toirkens, M.J.P.; Adama-Scheltema, P.N.; ... ; Peeters-Scholte, C.M.P.C.D.



Citation

Koning, M. A. de, Hoffer, M. J. V., Nibbeling, E. A. R., Bijlsma, E. K., Toirkens, M. J. P., Adama-Scheltema, P. N., ... Peeters-Scholte, C. M. P. C. D. (2021). Prenatal exome sequencing: a useful tool for the fetal neurologist. *Clinical Genetics*, 101(1), 65-77.
doi:10.1111/cge.14070

Version: Publisher's Version
License: [Creative Commons CC BY-NC 4.0 license](#)
Downloaded from: <https://hdl.handle.net/1887/3249467>

Note: To cite this publication please use the final published version (if applicable).

Prenatal exome sequencing: A useful tool for the fetal neurologist

Maayke A. de Koning¹  | Mariëtte J. V. Hoffer¹ | Esther A. R. Nibbeling¹ |
 Emilia K. Bijlsma¹ | Menno J. P. Toirkens² | Phebe N. Adama-Scheltema³ |
 E. Joanne Verweij³ | Marieke B. Veenhof³ | Gijs W. E. Santen¹ |
 Cacha M. P. C. D. Peeters-Scholte⁴ 

¹Department of Clinical Genetics, Leiden University Medical Centre, Leiden, The Netherlands

²Department of Radiology, Leiden University Medical Centre, Leiden, The Netherlands

³Department of Obstetrics, Leiden University Medical Centre, Leiden, The Netherlands

⁴Department of Neurology, Leiden University Medical Centre, Leiden, The Netherlands

Correspondence

Cacha M. P. C. D. Peeters-Scholte, K5-Q, LUMC, Albinusdreef 2, 2333 ZA Leiden, The Netherlands.
 Email: c.m.p.c.d.peeters-scholte@lumc.nl

Abstract

Prenatal exome sequencing (pES) is a promising tool for diagnosing genetic disorders when structural anomalies are detected on prenatal ultrasound. The aim of this study was to investigate the diagnostic yield and clinical impact of pES as an additional modality for fetal neurologists who counsel parents in case of congenital anomalies of the central nervous system (CNS). We assessed 20 pregnancies of 19 couples who were consecutively referred to the fetal neurologist for CNS anomalies. pES had a diagnostic yield of 53% (10/19) with most diagnosed pregnancies having agenesis or hypoplasia of the corpus callosum (7/10). Overall clinical impact was 63% (12/19), of which the pES result aided parental decision making in 55% of cases (6/11), guided perinatal management in 75% of cases (3/4), and was helpful in approving a late termination of pregnancy request in 75% of cases (3/4). Our data suggest that pES had a high diagnostic yield when CNS anomalies are present, although this study is limited by its small sample size. Moreover, pES had substantial clinical impact, which warrants implementation of pES in the routine care of the fetal neurologist in close collaboration with gynecologists and clinical geneticists.

KEYWORDS

CNS malformation, counseling, exome sequencing, fetal neurology, prenatal

1 | INTRODUCTION

Over the past decade, the implementation and accuracy of prenatal screening programs including first and second trimester ultrasonography (US) have significantly increased.^{1,2} Therefore, more congenital malformations are detected early in pregnancy, with higher precision. Counseling of parents remains nonetheless a challenge, because

prognosis is mostly based on imaging results, often without knowing the etiology of the detected anomalies.

Central nervous system (CNS) anomalies comprise a substantial part of all birth defects and occur in 0.26%–0.31% of all births.^{3,4} The etiology of CNS anomalies is associated with many different factors including genetic aberrations^{5,6} and can lead to an uncertain prognosis. Knowledge about prognosis is invaluable for parents who are in many countries pressured by a legal time limit regarding their decision for continuation or termination of the pregnancy. At present, standard

Gijs W. E. Santen and Cacha M. P. C. D. Peeters-Scholte are joint last authors.

This is an open access article under the terms of the Creative Commons Attribution-NonCommercial License, which permits use, distribution and reproduction in any medium, provided the original work is properly cited and is not used for commercial purposes.

© 2021 The Authors. *Clinical Genetics* published by John Wiley & Sons Ltd.

genetic diagnostic tools include quantitative fluorescent-polymerase chain reaction for aneuploidy screening and Chromosomal microarray analysis (CMA) for detecting copy number variants.⁷

Next generation sequencing, such as whole exome sequencing (WES) and whole genome sequencing, is emerging as a valuable tool to diagnose prenatal monogenetic disorders. By sequencing all coding parts of the DNA, WES can detect single nucleotide variants, copy number variants and small deletions or insertions. Prenatal exome sequencing (pES) is restricted by the limited prenatal phenotypic information which makes gene variant interpretation difficult. A large cohort study published in 2019 by Lord et al. demonstrated a diagnostic yield of 8.5% when pES was performed in fetuses with a variety of structural anomalies.⁸ This study reported different rates of diagnostic yield per phenotypic class, with a yield of less than 4% in fetuses with isolated brain malformations. Up to date, only very small cohort studies report on the diagnostic yield of pES in fetuses with CNS malformations, but they show a promising rate of 45%–75%.^{9,10} None however reports on actual implementation of pES for decision making during pregnancy in fetal clinical care specifically for pregnancies with neurological congenital anomalies.

In a previous pilot study, we have demonstrated the feasibility of pES in clinical care due to short turnaround-times (TAT).¹¹ Moreover, we were first to describe a significant clinical impact of pES in pregnancies with a variety of detected structural anomalies. A recent publication by Deden et al.¹² had similar results showing that pES can have a substantial effect on parental decision during and after pregnancy when implemented in routine fetal care. In this report we describe our experiences of pES on diagnostic yield and clinical impact from the viewpoint of the fetal neurologist, detailing the first 21 consecutive referrals of fetuses with CNS malformations.

2 | MATERIALS AND METHODS

2.1 | Patient cohort and data collection

This single cohort study was performed in patients referred to the fetal neurologist at the Leiden University Medical Centre (LUMC) from March 2017 up to September 2020. Data were collected retrospectively from patient files. The medical science board approved the protocol, the Medical Ethics Committee issued a waiver of approval and written consent was obtained from parents for the US and MRI images.

Parents of fetuses with CNS malformations, either isolated or in combination with other structural anomalies as detected by prenatal US, were counseled by the ultrasound specialist (PAS), gynecologist (MV/JV), fetal neurologist (CPS), and clinical geneticist (GS/EKB). Fetal MRI was assessed by the neuroradiologist (MT). Parents were offered prenatal genetic testing when a genetic cause was suspected based on clinical experience or literature. Fetal DNA was acquired through amniocentesis in all cases. Patients that were eligible for pES were divided into three groups;

Group A: parental decision making

pES could aid parents when deciding on continuation or termination of pregnancy. In the Netherlands, legal limit for TOP is below 24 + 0 weeks of gestation. In case parents considered TOP, the upper limit of gestational age (GA) had to be 22 + 0 weeks in order to obtain a timely result.

Group B: to guide perinatal management

Group C: to support requests for late termination of pregnancy (LTOP)

LTOP can be performed in the Netherlands in a strictly regulated setting. There should be no doubt regarding the prognosis and the diagnosis, and medical treatment following birth is considered futile.¹³

Pregnancies were also grouped according to the main phenotypic feature which was found on the initial prenatal US (hypoplasia or agenesis of the corpus callosum [H/ACC], pontocerebellar hypoplasia, ventriculomegaly, migration defects, holoprosencephaly, microcephaly) and fetuses were divided into two groups based on whether the US showed isolated CNS malformations or a combination of CNS malformations with malformations outside the CNS.

Results of CMA were awaited before pES initiation if time permitted. When a result of CMA could not be obtained before 22 + 0 weeks of gestation and parents considered TOP, pES was initiated simultaneously. Cases 1, 2, 5, 8, 12, 16, 17, and 19 were also included in our previous study.¹¹ We adhered to our previously formulated definition of clinical impact,¹¹ being;

- The pES result significantly influenced the decision on TOP, or
- The pES result changed intended prenatal or perinatal management, or
- The pES result supported the request for LTOP.

2.2 | Exome sequencing

Details on laboratory procedures and bioinformatics can be found in the Supporting Information SM1.¹¹ Trio samples of the fetus and both parents were used for sequencing to shorten TAT and facilitate variant interpretation. First, the DDG2P gene panel (www.ebi.ac.uk/gene2phenotype) was analyzed, which is one of the most comprehensive publicly available gene panels focused on postnatal setting and developed by the European Bioinformatics Institute, followed by a full exome analysis if no pathogenic variant was found in the panel.

TAT was defined as days between request of pES until final diagnostic report. Variants were classified according to the American College of Medical Genetics and Genomics (ACMG) guidelines.¹⁴ Variants classified as uncertain significance (class 3 out of 5) and likely pathogenic or pathogenic (class 4 out of 5 and class 5 out of 5 respectively) were submitted to the DECIPHER database. Variants of unknown significance (VUS) were discussed between laboratory specialists and clinical specialists and only reported to the patient if considered

potentially relevant. Incidental findings, which are (likely) pathogenic variants in disease genes not related to the fetal phenotype, were discussed between clinical and laboratory specialists and relayed to the parents depending on their consent. No variants are classified as secondary findings in the Netherlands, because no genes are deliberately analyzed in contradiction to the ACMG SF v3.0 list for reporting of secondary findings.¹⁵

3 | RESULTS

In the studied period, pES was performed in 21 consecutive pregnancies referred to the fetal neurologist for counseling. One patient had decided on TOP prior to initiation of pES and was excluded from this study, because the pES result was not reported during her pregnancy and could therefore not have had any clinical impact in the index pregnancy.

All remaining cases are described in Table 1 including classification criteria met by variants according to the ACMG guidelines. One patient was pregnant twice during the study period and congenital CNS malformations were detected in both pregnancies (cases 6_A and 6_B). As these cases are subsequent pregnancies of the same consanguineous couple and both showed significant clinical overlap, they will be regarded as one case in the analysis because of a strong possibility of a similar recessive genetic diagnosis. In case 7, CMA yielded a diagnosis, while pES was already initiated. We have included this case in the analysis as parents had not yet decided on the pregnancy at the time of pES initiation.

3.1 | Overall diagnostic yield and clinical impact

A pathogenic or likely pathogenic gene variant was found in 10 out of 19 sequenced fetuses, establishing a diagnostic yield of 53%. Clinical impact was present in 12 of 19 (63%) cases (see Table 1 and Figure 1D). Quotes from patient notes to illustrate clinical impact can be read in the Supporting Information SM2.

3.2 | Diagnostic yield and clinical impact based on prenatal ultrasound

The main feature on the initial prenatal US was H/ACC in 10 out of 19 (53%) fetuses (cases 1-6B, 10, 11, 13, and 18 in Table 1), while three cases had ventriculomegaly (case 8, 9, and 14), two pontocerebellar hypoplasia (cases 12 and 16), two migration defects (cases 15 and 17), one holoprosencephaly (case 7), and one microcephaly (case 19). The main phenotypic feature was an isolated finding only in cases 14 and 19.

When the main feature was H/ACC, a genetic diagnosis was made in seven out of 10 cases (70%), no isolated H/ACC was present. The diagnostic yield when other anomalies were present on the prenatal US was three out of nine cases (33%). Clinical impact

for these groups was 70% (7/10) and 56% (5/9) respectively (Figure 2A).

In the group with isolated CNS malformations (1, 4, 7, 10, 11, 14, 15, and 19), pES yielded a diagnosis in two out of eight (25%) fetuses, while eight out of 11 (73%) fetuses were diagnosed in the group with a combination of malformations. Clinical impact was 75% (6/8) in the group with isolated CNS malformations and 55% (6/11) when other malformations were present (Figure 2B).

3.3 | Diagnostic yield and clinical impact in

3.3.1 | Group A: parental decision making

pES was performed in 12 pregnancies to possibly aid the parental decision making regarding continuation of the pregnancy. Median GA at time of identification of structural anomalies was 19 + 5 weeks and median GA at time of pES result was 22 + 4 weeks. Five of these 11 cases (45%) received a definitive diagnosis, but we also detected two incidental findings and one VUS. pES had clinical impact in six cases (6/11, 55%) (Figure 1A).

In case 1, prenatal US identified a Blake's pouch cyst and hypoplasia of the corpus callosum (Figure 3A,C-D). Compound heterozygous likely pathogenic variants in *KIAA0586* (OMIM 610178) were detected by pES and the diagnosis Joubert syndrome type 23 (OMIM 616490) was made. Retrospectively, subtle hints of a molar tooth sign could be discerned (Figure 3B), although without the genetic findings this would not have been reported. Upon this diagnosis, parents opted for TOP. In case 2, the main phenotypic feature was ACC and a likely pathogenic de novo variant in *ZEB2* (OMIM 605802) was detected by pES, confirming Mowat-Wilson syndrome (OMIM 235730), which made parents decide on TOP.

Case 3 was diagnosed with Greig cephalopolysyndactyly syndrome (OMIM 175700) because of a likely pathogenic de novo variant in *GLI3* (OMIM 165240). Also a de novo variant in *EPHB4* (OMIM 600011) with unknown pathogenicity (ACMG class 3 out of 5) was detected. As variants in adjacent nucleotides in *EPHB4* are reported as pathogenic causing capillary malformation-arteriovenous malformations type 2 (OMIM 618196), the variant was considered to be close to ACMG class 4, and therefore we chose to report this variant as an incidental finding. The phenotypic features of this fetus fitted the diagnosis of Greig syndrome, but could not be related to the variant in *EPHB4* because no arteriovenous malformations (AVM) were detected on US. Parents were most worried about the severity of cognitive impairment, and although Greig syndrome has a relatively good prognosis regarding cognitive impairment, they eventually opted for TOP due to the uncertainty of the variant in *EPHB4* and the possibility of cerebral and spinal AVM with severe consequences.

In case 4, the main phenotypic feature was ACC and pES detected a likely pathogenic de novo variant in *OFD1* (OMIM 300170) causing X-linked dominant orofaciocaudal syndrome I (OMIM 311200), which made parents opt for TOP.

TABLE 1 Case description

Case	Consanguinity	GA at US	GA at pES result	TAT (days)	Prenatal phenotype (main phenotypic feature in bold)	pES result	Variant classification ACMG criteria ¹⁴	Inheritance	Diagnosis	Clinical impact	Pregnancy outcome
Group A: pES to aid parental decision making											
1	No	18 + 6	21 + 5	10	Hypoplasia corpus callosum , Blake's pouch cyst,	KIAA0586 c.863_864del p. (Gln288Argfs*7) (mat) KIAA0586 c.428del p. (Arg143Lysfs*4) (pat)	Likely pathogenic PV51, PM2, PM3, PP5 Likely pathogenic PV51, PM3, PP5	AR (compound heterozygous)	Joubert syndrome type 23	+	TOP <24 weeks GA
2	No	20 + 0	21 + 3	8	ACC , NT 6 mm in first trimester, hypospadias	ZEB2 c.786dup: p. (His263Thrfs*17) (dn)	Likely pathogenic PV51, PS2, PM2	AD (dn)	Mowat-Wilson syndrome	+	TOP <24 weeks GA
3	No	20 + 2	21 + 0	10	Hypoplasia corpus callosum , postaxial polydactyly feet, ventriculomegaly, absent septum pellucidum, mild hypertelorism	GLI3 c.4198dup p. (Asp1400Glyfs*12) (dn) EPHB4 c.2362G>A p. (Ala788Thr) (dn)	Likely pathogenic PV51, PS2, PM2 Incidental finding (VUS) PS2, PM1, PM2, PP3	AD (dn) AD (dn)	Greig cephalopolysyndactyly syndrome Capillary malformation-arteriovenous malformation type 2	+	Ventriculomegaly normalized at GA 23 weeks TOP <24 weeks GA
4	No	20 + 5	23 + 1	11	ACC , vermis hypoplasia, Blake's pouch cyst	OFD1 c.710dup p. (Tyr238Valfs*2) (dn)	Likely pathogenic PV51, PS2, PM2, PP5	XD (dn)	X-linked dominant orofaciodigital syndrome type 1	+	TOP <24 weeks GA
5	No	22 + 0	23 + 3	7	Hypoplasia corpus callosum , cerebellar hypoplasia, enlarged cisterna magna, delayed cerebral gyration pattern, SUA, urinary tract duplication with dilatation	ACTG1 c.212T>C p. (Ile71Thr) (dn)	Likely pathogenic PS2, PM2, PP2, PP3	AD (dn)	Baraitser-Winter syndrome	-	TOP <24 weeks GA
6 A	Yes	19 + 5	22 + 3	8	ACC , fissura centralis arachnoid cyst, unilateral pyelectasis, hygroma colli, tetralogy of Fallot, micrognathia, hypoplastic and low ears, abnormal shape of skull	SLC12A6 c.1012C>T p. (Arg338Cys)	VUS PM1, PM2, PM3 (supporting: homozygous, PP3, BP1)	AR (biparental)		-	TOP <24 weeks GA
6 B		13 + 1	23 + 2	32	ACC , hygroma colli; interhemispheric cyst, abnormal shape of skull, hypertelorism	MYBPC3 c.1805C>T p. (Thr602Ile)	Incidental finding (likely pathogenic) PM1, PM2, PP3, PP5	AD (inherited)	Hypertrophic cardiomyopathy	-	TOP <24 weeks GA

TABLE 1 (Continued)

Case	Consanguinity	GA at US	GA at pES result	TAT (days)	Prenatal phenotype (main phenotypic feature in bold)	pES result	Variant classification ACMG criteria ¹⁴	Inheritance	Diagnosis	Clinical impact	Pregnancy outcome
7	No	19 + 5	23 + 2	11	Lobar holoprosencephaly with coloboma, fused anterior horns, absent septum pellucidum, paired anterior cerebral artery and hypoplasia posterior corpus callosum	No pathogenic variant				-	TOP <24 weeks GA due to CMA result of 47,XY,+der(X)dup(X)(q21.32q28)t(X:11)(q28;q23.3)
8	No	19 + 4	21 + 4	13	Severe IUGR, ventriculomegaly, SUA, echogenic focus in left ventricle in monochorionic twin	No pathogenic variant				-	IUFD at 21 weeks GA
9	No	19 + 4	22 + 4	9	Ventriculomegaly, postaxial polydactyly both feet and left hand, synophris, short philtrum	No pathogenic variant				-	Ventriculomegaly normalized at GA 23 weeks TOP <24 weeks GA
10	No	19 + 2	22 + 2	9	Hypoplasia corpus callosum, absent cavum septum pellucidum	No pathogenic variant				+	US normalized at GA 23 weeks Live birth at GA 40 + 1 weeks. Normal development at age 5 months
11	No	21 + 1	23 + 0	13	ACC, colpocephaly, ventriculomegaly	No pathogenic variant				+	Live birth at GA 41 + 1 weeks. Normal development at age 2 weeks
Group B: pES to guide prenatal or perinatal management											
12	Yes	24 + 4	33 + 4	10	Hypoplastic cerebellum, microcephaly, mega cisterna magna, rocker bottom feet, IUGR, clenched feet and overlapping fingers	ERCC5 c.880G>A; p. (Gly294Ser)	Likely pathogenic PM2, PM3 (supporting; homozygous), PP2, PP3	AR (biparental)	COFS syndrome	+	IUFD at GA 35 weeks
13	No	24 + 0	42 + 2	107	ACC, colpocephaly, cardiomegaly, tricuspid insufficiency	EPG5 c.5631del; p. (Ser1879Alafs*12) (pat)	Likely pathogenic PV51, PM2, PM3 (supporting)	AR (biparental)	Vici syndrome	-	IUFD at GA 37 weeks

(Continues)

TABLE 1 (Continued)

Case	Consanguinity	GA at US	GA at pES result	TAT (days)	Prenatal phenotype (main phenotypic feature in bold)	pES result	Variant classification ACMG criteria ¹⁴	Inheritance	Diagnosis	Clinical impact	Pregnancy outcome
14	No	29 + 4	33 + 3	15	Severe ventriculomegaly due to aqueductal stenosis after intraventricular hemorrhage	FBXL5 nonsense c.403C>T p.(Gln135*) (dn)	VUS in gene of unknown significance PS2, PM2	AD (dn)		+	Live birth at GA 38 + 3 weeks. Severe psychomotor disability with facial dysmorphic features at age 14 months.
15	Yes	31 + 5	36 + 3	23	Possible delayed cerebral gyration , enlarged cavum septum pellucidum and vergae complex	No pathogenic variant				+	Live birth at GA 39 + 0 weeks. Normal development at age 1 month. Postpartum MRI cerebrum showed no abnormalities.
Group C: pES for late termination of pregnancy request											
16	No	29 + 0	31 + 3	19	Pontocerebellar hypoplasia , progressive microcephaly, arthrogryposis	Partial ATAD3A and ATAD3B deletion	Likely pathogenic	AR (biparental)	Pontocerebellar hypoplasia, and respiratory insufficiency syndrome	+	LTOP at GA 33 weeks
17	No	31 + 6	33 + 3	8	Polymicrogyria , bilateral subependymal cysts and unilateral occipital cysts, IUGR, cardiomegaly with grade 1 tricuspid insufficiency	ECHS1 c.389T>A: p.(Val130Asp) (mat) ECHS1 c.817A>G: p.(Lys273Glu) (pat)	Pathogenic PM1, PM2, PM3, PP2, PP3, PP5 Pathogenic PM1, PM2, PM3, PP2, PP5	AR (compound heterozygous)	Mitochondrial short-chain enoyl-CoA hydratase 1 deficiency	+	LTOP at GA 33 weeks
18	Yes	30 + 3	32 + 3	8	ACC , anterior horn cysts, bilateral pes equinovarus	AMPD2 c.693+1G>C p.(?)	Likely pathogenic PVS1, PM2, PM3 (supporting: homozygous), PP3	AR (biparental)	Pontocerebellar hypoplasia type 9	+	LTOP at GA 33 weeks
19	No	32 + 4	34 + 1	16	Severe microcephaly (<p3)	No pathogenic variant				-	LTOP at GA 34 weeks abroad

Abbreviations: (L)TOP, (late) termination of pregnancy; ACC, agenesis of the corpus callosum; AD, autosomal dominant; AR, autosomal recessive; BP, benign supporting; CMA, chromosomal microarray analysis; COFS, cerebro-oculo-facio-skeletal; dn, de novo; GA, gestational age; IUGR, intrauterine growth restriction; mat, maternal; NT, nuchal translucency; pat, paternal; pES, prenatal exome sequencing; PM, pathogenic moderate; PP, pathogenic supporting; PVS, pathogenic very strong; SUA, single umbilical artery; TAT, turnaround time; US, ultrasound; VUS, variant of unknown significance.

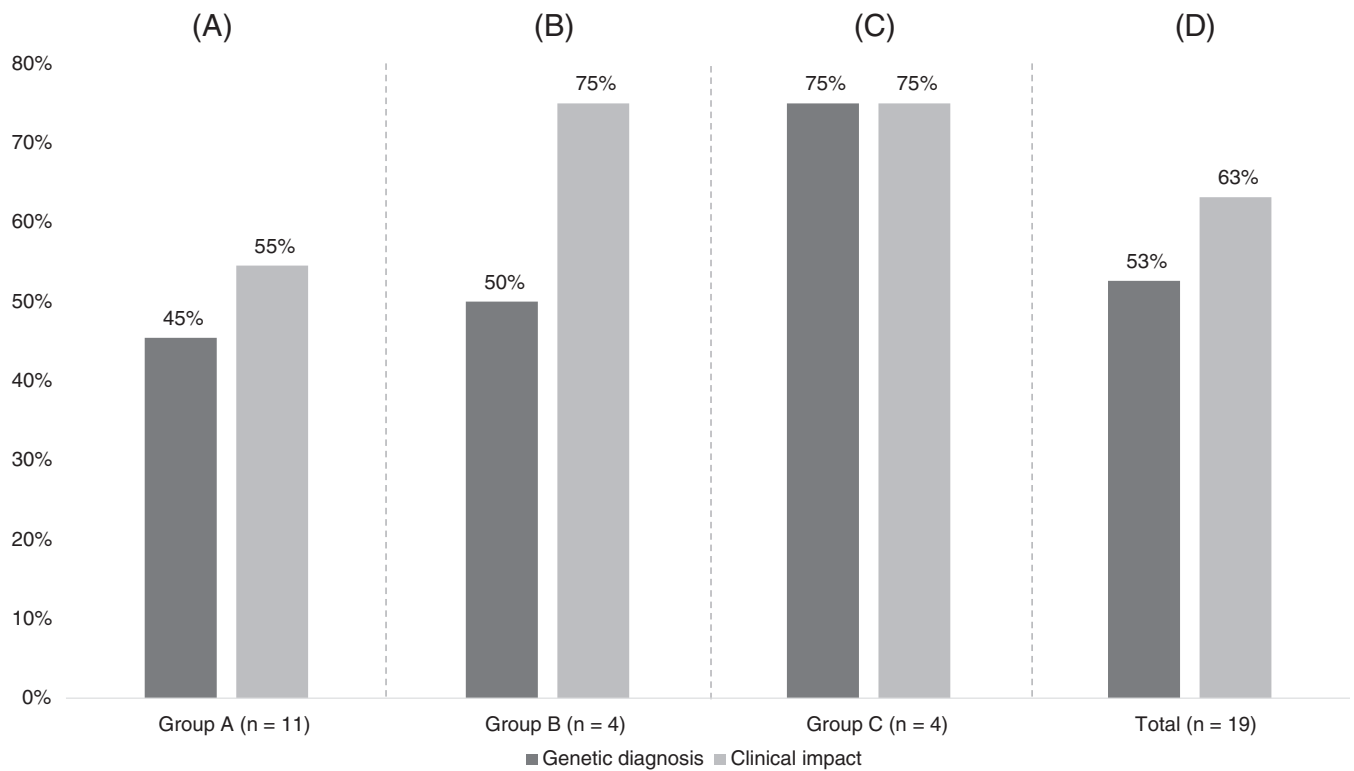


FIGURE 1 Diagnostic yield and clinical impact of prenatal exome sequencing (pES). A. In Group A: pES for parental decision making; B. In Group B: pES for guiding perinatal management; C. In Group C: pES for LTOP; D. In the total cohort

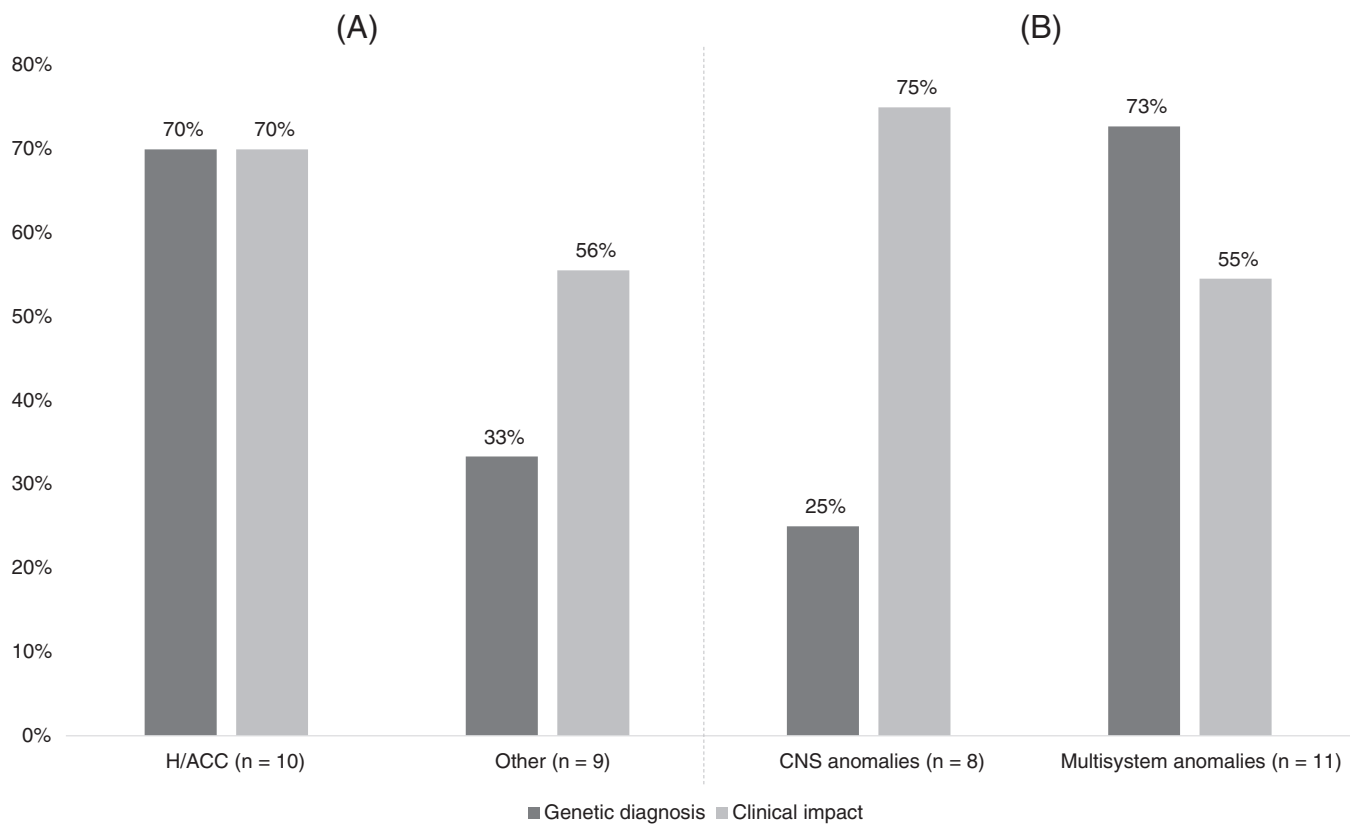


FIGURE 2 Diagnostic yield and clinical impact based on prenatal ultrasound. A. In fetuses with agenesis of the corpus callosum (ACC) as the main phenotypic feature versus other main phenotypic features; B. In fetuses with isolated central nervous system (CNS) anomalies versus multisystem anomalies

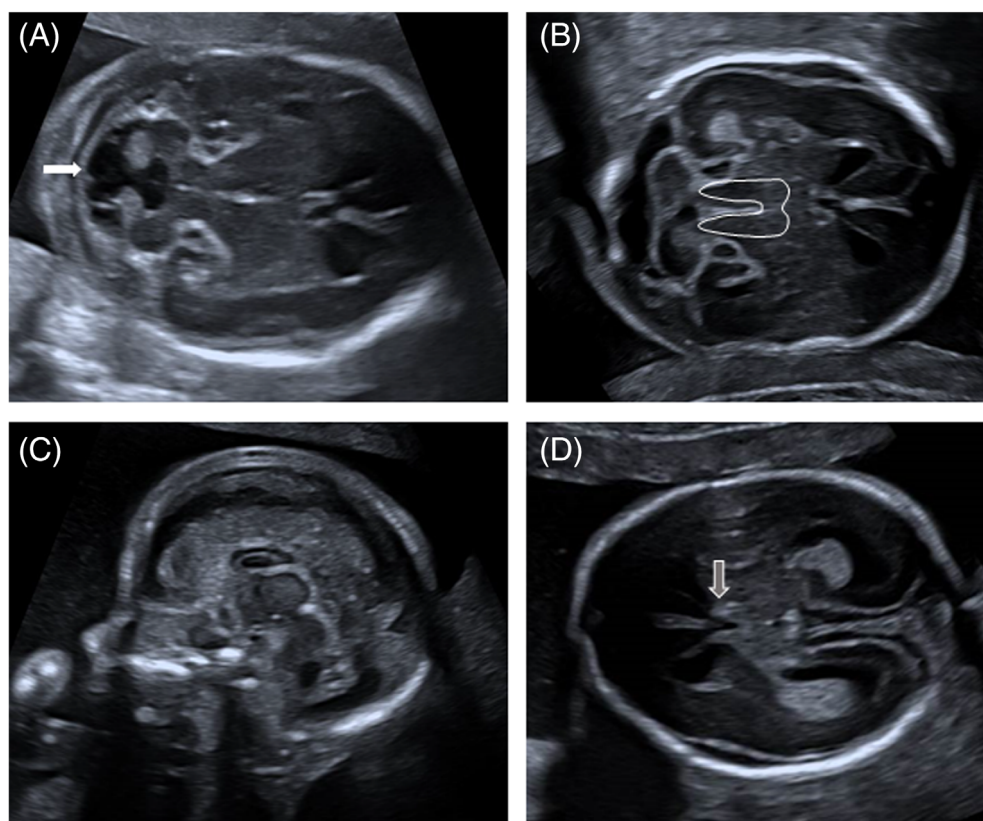


FIGURE 3 Joubert syndrome type 23 (case 1). Neurosonography at 18 + 6 weeks of gestation, showing. (A) Blake pouch cyst (white arrow; axial view); (B) Impression of molar tooth sign (axial view); (C) Small corpus callosum (sagittal view); (D) Small cavum septum pellucidum (gray arrow; axial view) [Colour figure can be viewed at wileyonlinelibrary.com]

To summarize, clinical impact was evident in all of the above cases in which pES provided a diagnosis, as parents would not have opted for TOP in the absence of a syndromic diagnosis.

In case 5, we reasoned that pES did not have clinical impact although the diagnosis of Baraitser–Winter syndrome (OMIM 614583) was made due to a likely pathogenic *de novo* variant in *ACTG1* (OMIM 1102560). Cerebral gyration was delayed in case 5 and parents chose for TOP, mainly based on the US that was made several days before the legal limit of TOP, showing stunted development of cerebral gyration.

Cases 6_A and 6_B were subsequent pregnancies of a consanguineous couple showing both ACC as a main phenotypic feature and other similarities in detected US anomalies with the main difference being a tetralogy of Fallot only present in case 6_A. A homozygous VUS in the gene *SLCA12A6* (OMIM 604878) was reported in case 6_A, but it was not considered to be the likely cause of the phenotype by the geneticist, as its high frequency in GnomAD. GnomAD also contains one person with this variant in homozygous form at the age of 65–70, which is unlikely in this disease. Despite this pES result, parents chose TOP because of their concern for the need of pediatric surgery due to the tetralogy of Fallot. As the second pregnancy was also affected, an MRI of both parents was made to rule out autosomal dominant ACC, but showed normal corpora callosa. In case 6_B, an inherited heterozygous likely pathogenic variant was detected in *MYBPC3* (OMIM 600958), associated with hypertrophic cardiomyopathy, which was reported due to the hygroma colli. However, in this pregnancy no cardiac defects were detected and therefore this mutation was not considered to explain the neurological phenotype and

was reported as an incidental finding. Parents opted again for termination, also because they were counseled about the high chance of a genetic diagnosis that pES was not yet able to detect.

In case 7, pES was initiated at 21 + 5 weeks of gestation simultaneously with CMA in order to obtain a result of both tests before the upper limit of GA for TOP. pES did not yield a diagnosis, but CMA detected a terminal duplication of chromosome 11 and a complex copy number pattern of the X-chromosome. With conventional G-banding analysis, the karyotype established was 47,XY,+der(X)dup(X)(q21.32q28)t(X;11)(q28;q23.3) with the following ISCN nomenclature of the CMA result:

arr[GRCh37] 11q23.3q25(116587952_134938470)x3 dn,Xp22.33(168566_2693624)x3 dn,Xp22.33q21.32(2865195_92344669)x2 dn,Xq21.32q28(92568557_153624154)x3 dn.

The duplication of 11q23 was classified as pathogenic and was not detected by the non-invasive prenatal test in spite of the 18 Mb size, because the duplication occurred in a highly variable region. This duplication was thought to be causative of the prenatal phenotype; duplication of 11q23 is associated with neurological malformations and subsequent severe intellectual disability. Parents opted for TOP because of this prognosis in combination with the severe anomalies as detected by US. pES did not find any additional variants and therefore did not have clinical impact.

No diagnoses were made in the remaining four pregnancies. In case 8, the results of pES were only available after intrauterine fetal demise (IUFD) of the fetus and therefore pES did not have any clinical impact. In case 9, parents still opted for TOP in the absence of a genetic diagnosis due to the severity of detected prenatal malformations, hence pES did not have clinical impact in this case either.

In cases 10 and 11, parents felt strengthened in their decision for continuation of the pregnancy in the absence of a definitive diagnosis (see quotes in SM2).

3.3.2 | Group B: to guide perinatal management

When parents did not consider TOP, but a genetic diagnosis could warrant a change of perinatal management, parents were still offered pES. Over the course of this study period, pES was performed to possibly guide perinatal management in four pregnancies. A diagnosis was made in two cases (50%) and pES had clinical impact in three cases (75%) (Figure 1B).

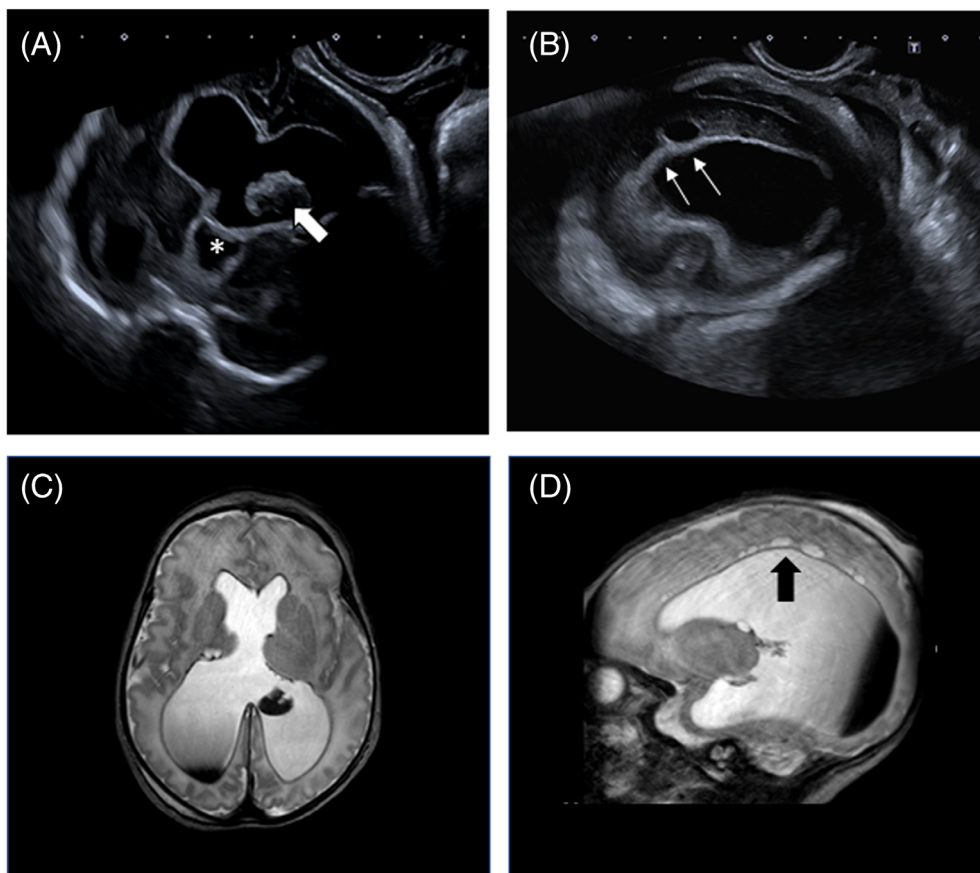
In case 12, the main phenotypic feature was a hypoplastic cerebellum and the diagnosis of cerebro-oculo-facio-skeletal (OMIM 616570) syndrome was made because of a biparental likely pathogenic variant in *ERCC5* (OMIM 133530). This diagnosis implied a poor prognosis with a high possibility of pediatric demise, therefore clinicians and parents agreed to limit lifesaving peri- and postnatal care. However, this pregnancy ended in IUFD at 35 weeks of gestation. We reasoned that pES would have had clinical impact in this case. A diagnosis was also made in case 13 in which the fetus had a main phenotypic feature of ACC and pES detected likely pathogenic compound heterozygous mutations in *EPG5* (OMIM 615068) establishing the diagnosis of Vici syndrome (OMIM 242840). However, the results

of pES were available after IUFD and therefore pES could not have had any clinical impact, similarly as in case 8.

In case 14, a large intraventricular bleeding was present, leading to severe ventriculomegaly with cyst formation (Figure 4A,B). No causative variant was identified but pES detected a VUS in a gene which has not been linked to disease. A de novo truncating variant in the *FBXL5* gene (OMIM 605655) was reported, which is highly expressed in the cerebellum and is responsible for iron homeostasis. Heterozygous knock-out mice do not show specific congenital malformations, but homozygous knock-out mice are not viable.¹⁶ After careful consideration by our multidisciplinary team of laboratory and clinical specialists, the variant was disclosed to parents, as the *FBXL5* gene (OMIM 605655) is highly expressed in the CNS and is of importance for embryogenesis. However in the absence of a reported human phenotype, it was subsequently not considered to be causal. Without a definitive diagnosis and clear prognosis, parents and clinicians agreed to optimize care after birth. The child was born alive at GA 38 + 3 weeks with several dysmorphic features. Due to the posthemorrhagic ventricular dilatation with cyst formation (Figure 4C, D) a ventriculoperitoneal drain was given. At age 14 months severe visual impairment and severe motor retardation was present.

No pathogenic variant was detected in case 15, so it was decided to optimize postnatal care. The pregnancy resulted in live birth at GA 39 + 0 weeks and the child shows a normal development at age 1 month with no dysmorphic features. During pregnancy, a possible

FIGURE 4 Prenatal hydrocephalus with large intraventricular hemorrhage (case 14). Neurosonography at 30 + 4 weeks of gestation, showing (A) Severe biventricular and third ventricular dilatation (*) with a large intraventricular hemorrhage at the left side (white arrow; coronal view); (B) Cystic development in the right parieto-occipital cortex (white small arrows, sagittal view); (C) T2-weighted MRI at day of birth at 38 + 3 weeks of gestation showing post-hemorrhagic ventricular dilatation with disrupted cavum septum pellucidum (transverse view) and; (D) Periventricular cystic transformation in the right hemisphere (black arrow, sagittal view) [Colour figure can be viewed at wileyonlinelibrary.com]



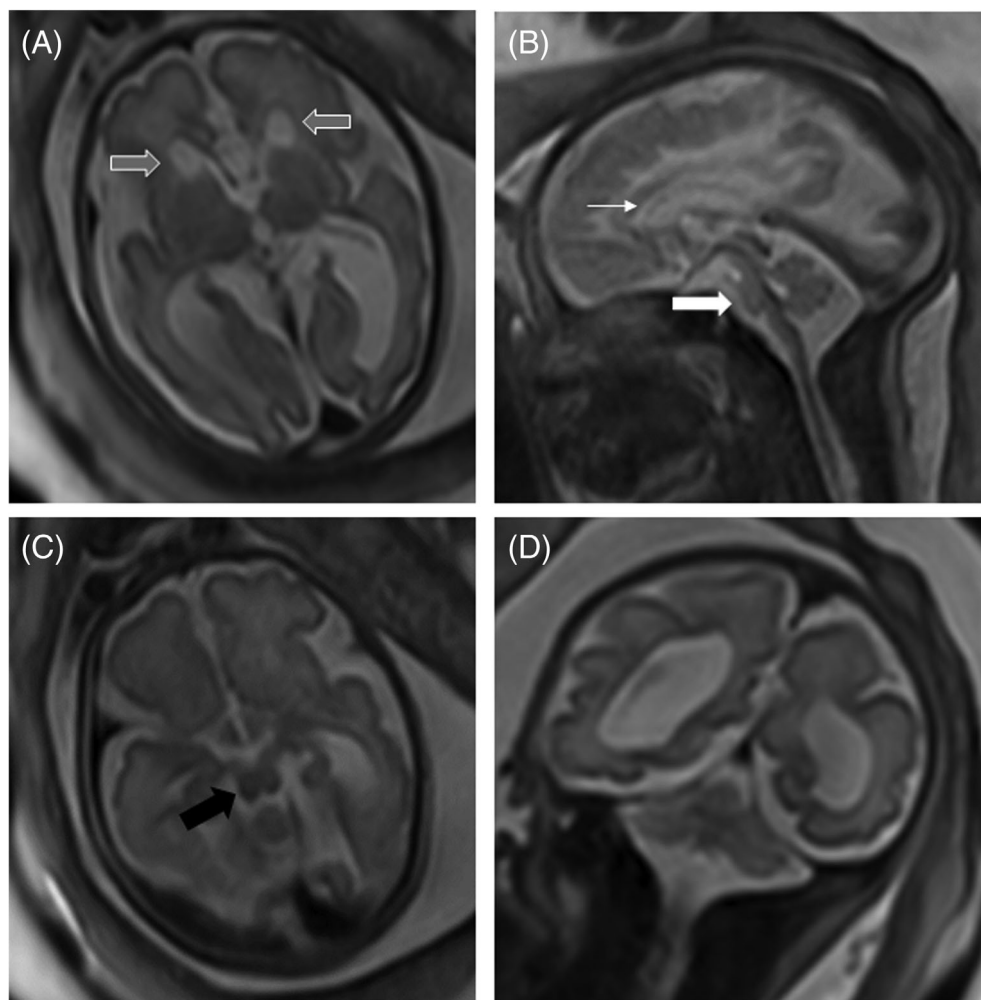


FIGURE 5 Orofaciodigital syndrome type 1 (case 18). T2-weighted fetal MRI at 31 + 2 weeks of gestation, showing (A) Colpocephaly and prefrontal cysts (gray arrows, axial view); (B) Near complete absence of the corpus callosum (small white arrow) with pontine hypoplasia (large white arrow, sagittal view); (C) Midbrain “figure 8”-sign (black arrow, axial view)²⁰; (D) Colpocephaly and dragonfly appearance of the cerebellum (transverse cerebellar diameter 32 mm [$p < 1$]; coronal view)

delay in cerebral gyration was seen, but MRI confirmed that this was normalized after birth.

3.3.3 | Group C: late termination of pregnancy requests

pES was performed to possibly approve a request for LTOP in four pregnancies. LTOP was approved in three cases in our cohort, all due to diagnoses with very severe prognoses (Figure 1C). Termination was performed at a mean gestational age of 33 weeks which was ~2 weeks after first identification of fetal malformations.

In case 16, pontocerebellar hypoplasia was the main phenotypic feature and the diagnosis of pontocerebellar hypoplasia, hypotonia and respiratory insufficiency syndrome (OMIM 618810) was made as pES detected likely pathogenic biparental partial deletions of the *ATAD3A* (OMIM 612316) and *ATAD3B* (OMIM 612317) genes. This syndrome is associated with severe respiratory insufficiency and almost certain neonatal demise. This case was reported before.¹⁷

In case 17, the diagnosis of mitochondrial short-chain enoyl-CoA hydratase 1 deficiency (OMIM 616277) was made due to compound heterozygous pathogenic variants in *ECHS1* (OMIM 602292). This fetus showed polymicrogyria as main phenotypic feature and LTOP

was approved because this syndrome is associated with neurodegeneration causing severely impaired psychomotor development and possible pediatric demise.

Case 18 showed ACC and anterior horn cysts (Figure 5A–D) and bilateral pes equinovarus on prenatal US. pES detected a likely pathogenic variant in *AMPD2* (OMIM 102771) and the diagnosis of pontocerebellar hypoplasia type 9 (OMIM 615809) was made, of which the prognosis was severe enough to approve the LTOP request.

In case 19, pES was initiated due to severe fetal microcephaly (head circumference $p \ll 3$). As pES did not yield a diagnosis, parents went abroad to have an LTOP because the request was not approved in the Netherlands even though the prognosis was thought to be severe.

4 | DISCUSSION

4.1 | Diagnostic yield

In this study, we showed that pES detected a pathogenic or likely pathogenic variant in 10 out of 19 sequenced fetuses with CNS malformations on prenatal US, thus establishing a diagnostic yield of 53%. Most pathogenic or likely pathogenic mutations were inherited in an autosomal recessive way (60%). This diagnostic yield might be biased

due to our small sample size, as it is higher than in previous studies containing fetuses with a variety of malformations on prenatal US (8.5–19.4%^{8,18,19}) and in our previous study, excluding the neurological cases that were included in this report (17%¹¹). Our diagnostic yield is comparable with previous publications investigating pES in a selected cohort of fetuses with CNS malformations.^{9,10} In the study of Tan et al.,⁹ pES established a diagnosis in five out of 11 fetuses (45%) and 80% of these diagnoses were autosomal recessive disorders. Reches et al.¹⁰ showed that pES could detect a diagnosis in five out of seven cases (71%) and 80% of these diagnoses were inherited in a recessive way. In the studies of Lord et al.⁸ and Deden et al.,¹² which both included a variety of congenital anomalies, also a separate diagnostic yield for fetuses with intracerebral congenital anomalies was provided. Lord et al. reported a diagnostic yield of 3% (2/69)⁸ and Deden et al. of 17% (3/18)¹² specifically for this group. The significant difference in diagnostic yield between these studies, might not only be due to sample size but also due to ascertainment criteria. Tan et al.⁹ and Reches et al.¹⁰ both included pregnancies with a higher a priori chance of syndromic diagnosis, for example, due to previously affected pregnancies or parental consanguinity, while Lord et al. included all pregnancies with one or more US anomaly without previous genetic review. Although Deden et al. reported a lower diagnostic yield, they still considered performing pES in fetuses with intracerebral structural anomalies as beneficial.

Our cohort was too small to draw definite conclusions about specific CNS malformations but a relatively high diagnostic yield was found in cases with H/ACC as main phenotypic feature (7/10, 70%) compared with other CNS abnormalities (Figure 2A). Lord et al.⁸ showed in the PAGE study that a combination of several congenital anomalies in different organ systems is significantly associated with a higher diagnostic yield in comparison with isolated anomalies. Our study has similar results (Figure 2B) and further substantiates the hypothesis that the presence of complex multisystem malformations is frequently explained by a genetic alteration.

Two incidental findings were reported over the course of this study period. In case 3, a variant of unknown clinical significance (class 3 out of 5 according to ACMG guidelines) in *EPHB4* (OMIM 600011) was reported as an incidental finding, as variants in adjacent nucleotides are pathogenic and associated with AVM. Parents let this variant weigh in on their decision and opted for TOP due to the diagnosis of Greig cephalopolysyndactyly syndrome in combination with the uncertain causality of this variant. The incidental finding in *MYBPC3* (OMIM 600958) in case 6_B was likely pathogenic but causality could not be proven, as no phenotypic features associated with this variant were detected on US. Parents chose TOP due to the high possibility of a genetic origin that could not be detected yet by pES, as they were consanguineous and as their first pregnancy was affected in a similar way. In total, two variants of unknown significance were detected. In case 6_A, the VUS was classified as likely benign (class 2 out of 5 according to ACMG guidelines) based on data from GnomAD. The nonsense variant in the candidate gene *FBXL5* (OMIM 605655) of case 14 had an unknown pathogenicity and parents did not terminate

the pregnancy. However, as the child shows a severely abnormal development with several facial dysmorphisms and cerebral visual impairment at age 14 months, it could be speculated that this variant might be causative, although presently we do no longer report such uncertain variants in genes of unknown significance.

Variant interpretation in a prenatal setting is very challenging due to difficulties with incomplete phenotyping. Quality of prenatal US has significantly increased over the years, but characteristics such as intellectual disability are impossible to assess prenatally solely based on imaging. On top of that, rapid diagnosis with short TAT of pES is of utmost importance for implementation in routine fetal care to optimize clinical impact, but this time pressure is challenging for multidisciplinary interpretation of gene variants. A rapid procedure is not always necessary for cases in which pES can influence perinatal management due to the initiation of pES early in the pregnancy. Therefore case 13 had quite a long TAT and the results were eventually available after IUPD. Prenatal variant interpretation is also difficult because of neurologic embryogenesis; not only are certain CNS malformation problematic to detect by prenatal US, but neurological structures are still developing when US examinations take place. In our cohort, the CNS malformation of cases 9, 10 and 15 normalized later on in pregnancy or were not present anymore at postnatal follow-up.

4.2 | Clinical impact

Overall, pES had clinical impact in 63% (12/19) of cases, which is comparable with the findings of Deden et al. (68% or 25/37 fetuses with a variety of anomalies).¹² When parents chose pES to support their decision making regarding termination or continuation of the pregnancy (group A), pES had impact in 55% (6/11), to guide perinatal management (group B) in 75% (3/4) of cases and to approve an LTOP request in another 75% (3/4) of cases. Clinical impact of pES in case of detection of a genetic syndrome is evident. However especially in the first group (A), a negative pES result was also of great impact as can be read in the S12, as parents felt strengthened in their decision for continuation of the pregnancy.

The benefit of rapid TAT is illustrated by all these cases in which clinical impact was evident. Because a rapid diagnosis was made, parents and clinicians had time to decide what course of action was best to take *during* the pregnancy. In countries where TOP is limited to a legal upper gestational age, which is 24 weeks of gestation in the Netherlands, a timely and clear prognosis can be of utmost importance. Apart from the need for a rapid diagnosis during a pregnancy, pES also gives useful insights for counseling about recurrence risk in subsequent pregnancies. In our cohort, we had six diagnoses that were inherited in a recessive way and therefore parents had a recurrence risk of 25%, a confirmation of our previous finding¹¹ that genetic disease detected during pregnancy is more often recessive. These couples were offered diagnostic testing in the first trimester, or optional intensive US follow-up in the next pregnancy.

5 | CONCLUSION

pES is a very promising and additional tool for fetal neurologists to adequately counsel parents of fetuses with CNS anomalies. We showed that pES had a diagnostic yield of 53% (10/19) when initiated in pregnancies with CNS malformations, which is substantially higher compared to an unselected cohort of fetuses with a variety of congenital anomalies. In this study, we illustrated that pES has a significant impact on pregnancy outcome.

Optimization of multidisciplinary interpretation of variants with unknown causality is a requirement for the best implementation of pES in routine care. Additionally, more research with larger cohorts is needed to assess cases with CNS anomalies that would most benefit from pES. The challenge for the future is to successfully incorporate genomic testing in routine care, with imaging performed side by side, to further improve adequate parental counseling.

ACKNOWLEDGMENTS

We would like to thank the clinical geneticists Y. Hilhorst-Hofstee, N. S. den Hollander, A. van Haeringen, and S. Koene for counseling the included patients in this research. For performing laboratory procedures of the included patients, we thank T. T. Koopmann, J. Knijnenburg, T. van Dijk, and C. A. L. Ruivenkamp. No funding was received for this research.

CONFLICT OF INTEREST

C. M. P. C. D. Peeters-Scholte is founder and consultant at Neurophyxia BV. She holds several patents and stocks of Neurophyxia BV. None of this work has a relationship with the current manuscript.


PEER REVIEW

The peer review history for this article is available at <https://publons.com/publon/10.1111/cge.14070>.

DATA AVAILABILITY STATEMENT

The authors confirm that the data supporting the findings of this study are available within the article and its supplementary material.

ORCID

Maayke A. de Koning  <https://orcid.org/0000-0003-0557-7530>

Cacha M. P. C. D. Peeters-Scholte  <https://orcid.org/0000-0002-3982-6868>

REFERENCES

- Lara Spalldi B, Milan S, Asim K, Selma P, Ghalia G. Diagnosis of fetal syndromes by three- and four-dimensional ultrasound: is there any improvement? *J Perinat Med*. 2017;45(6):651-665. doi:10.1515/jpm-2016-0416
- Boyd P, Rounding C, Chamberlain P, Wellesley D, Kurinczuk J. The evolution of prenatal screening and diagnosis and its impact on an unselected population over an 18-year period. *BJOG*. 2012;119(9):1131-1140. doi:10.1111/j.1471-0528.2012.03373.x
- Onkar D, Onkar P, Mitra K. Evaluation of fetal central nervous system anomalies by ultrasound and its anatomical co-relation. *J Clin Diagn Res*. 2014;8(6):Ac05-7. doi:10.7860/jcdr/2014/8052.4437
- EUROCAT. European Surveillance of Congenital Anomalies (EUROCAT), cases and prevalence (per 10. 000 births) for all full member registries from 2011 to 2018, prevalence tables. Last updated September 29, 2020.
- Van den Veyver IB. Prenatally diagnosed developmental abnormalities of the central nervous system and genetic syndromes: a practical review. *Prenat Diagn*. 2019;39(9):666-678. doi:10.1002/pd.5520
- Huang J, Wah IY, Pooh RK, Choy KW. Molecular genetics in fetal neurology. *Semin Fetal Neonatal Med*. 2012;17(6):341-346. doi:10.1016/j.siny.2012.07.007
- Song T, Xu Y, Li Y, et al. Detection of submicroscopic chromosomal aberrations by chromosomal microarray analysis for the prenatal diagnosis of central nervous system abnormalities. *J Clin Lab Anal*. 2020;34:e23434. doi:10.1002/jcla.23434
- Lord J, McMullan DJ, Eberhardt RY, et al. Prenatal exome sequencing analysis in fetal structural anomalies detected by ultrasonography (PAGE): a cohort study. *Lancet*. 2019;393(10173):747-757. doi:10.1016/s0140-6736(18)31940-8
- Tan H, Xie Y, Chen F, et al. Novel and recurrent variants identified in fetuses with central nervous system abnormalities by trios-medical exome sequencing. *Clin Chim Acta*. 2020;510:599-604. doi:10.1016/j.cca.2020.08.018
- Reches A, Hirsch L, Simchoni S, et al. Whole-exome sequencing in fetuses with central nervous system abnormalities. *J Perinatol*. 2018;38(10):1301-1308. doi:10.1038/s41372-018-0199-3
- de Koning MA, Haak MC, Adama van Scheltema PN, et al. From diagnostic yield to clinical impact: a pilot study on the implementation of prenatal exome sequencing in routine care. *Genet Med*. 2019;21(10):2303-2310. doi:10.1038/s41436-019-0499-9
- Deden C, Neveling K, Zafeiropoulou D, et al. Rapid whole exome sequencing in pregnancies to identify the underlying genetic cause in fetuses with congenital anomalies detected by ultrasound imaging. *Prenat Diagn*. 2020;40(8):972-983. doi:10.1002/pd.5717
- Minister van Veiligheid en Justitie MvV, Welzijn en Sport. Regeling van de Minister van Veiligheid en Justitie en de Minister van Volksgezondheid, Welzijn en Sport van 11 december 2015, kenmerk 885614-145412-PG, houdende instelling van een commissie voor de beoordeling van gemelde gevallen van late zwangerschapsafbreking en levensbeëindiging bij pasgeborenen (Regeling beoordelingscommissie late zwangerschapsafbreking en levensbeëindiging bij pasgeborenen). Staatscourant - officiële uitgave van het Koninkrijk der Nederlanden sinds 1814. 26-01-2016; 2016 (3145). <https://wetten.overheid.nl/BWBR0037570/2018-08-01>
- Richards S, Aziz N, Bale S, et al. Standards and guidelines for the interpretation of sequence variants: a joint consensus recommendation of the American College of Medical Genetics and Genomics and the Association for Molecular Pathology. *Genet Med*. 2015;17(5):405-424. doi:10.1038/gim.2015.30
- Miller DT, Lee K, Chung WK, et al. ACMG SF v3.0 list for reporting of secondary findings in clinical exome and genome sequencing: a policy statement of the American College of Medical Genetics and Genomics (ACMG). *Genet Med*. 2021;23:1381-1390. doi:10.1038/s41436-021-01172-3
- Ruiz JC, Walker SD, Anderson SA, Eisenstein RS, Bruick RK. F-box and leucine-rich repeat protein 5 (FBXL5) is required for maintenance of cellular and systemic iron homeostasis. *J Biol Chem*. 2013;288(1):552-560. doi:10.1074/jbc.M112.426171
- Peeters-Scholte C, Adama van Scheltema PN, Klumper F, et al. Genotype-phenotype correlation in ATAD3A deletions: not just of scientific relevance. *Brain*. 2017;140(11):e66. doi:10.1093/brain/awx239

18. Petrovski S, Aggarwal V, Giordano JL, et al. Whole-exome sequencing in the evaluation of fetal structural anomalies: a prospective cohort study. *Lancet*. 2019;393(10173):758-767. doi:10.1016/s0140-6736(18)32042-7
19. Diderich KEM, Romijn K, Joosten M, et al. The potential diagnostic yield of whole exome sequencing in pregnancies complicated by fetal ultrasound anomalies. *Acta Obstet Gynecol Scand*. 2021;100:1106-1115. doi:10.1111/aogs.14053
20. Scola E, Ganau M, Robinson R, et al. Neuroradiological findings in three cases of pontocerebellar hypoplasia type 9 due to AMPD2 mutation: typical MRI appearances and pearls for differential diagnosis. *Quant Imaging Med Surg*. 2019;9(12):1966-1972. doi:10.21037/qims.2019.08.12

SUPPORTING INFORMATION

Additional supporting information may be found in the online version of the article at the publisher's website.

How to cite this article: de Koning MA, Hoffer MJV, Nibbeling EAR, et al. Prenatal exome sequencing: A useful tool for the fetal neurologist. *Clinical Genetics*. 2022;101(1):65-77. doi:10.1111/cge.14070