



Universiteit
Leiden
The Netherlands

Pulmonary ductal coarctation: an entity associated with congenital heart defects involving the right ventricle outflow tract

Vliet, R. van; Kroft, L.J.M.; Hazekamp, M.G.; Roest, A.A.W.; Palen, R.L.F. van der

Citation

Vliet, R. van, Kroft, L. J. M., Hazekamp, M. G., Roest, A. A. W., & Palen, R. L. F. van der. (2021). Pulmonary ductal coarctation: an entity associated with congenital heart defects involving the right ventricle outflow tract. *Journal Of Cardiac Surgery*, 36(12), 4754-4755. doi:10.1111/jocs.16067

Version: Publisher's Version

License: [Creative Commons CC BY-NC 4.0 license](#)

Downloaded from: <https://hdl.handle.net/1887/3238109>

Note: To cite this publication please use the final published version (if applicable).

Pulmonary ductal coarctation: An entity associated with congenital heart defects involving the right ventricle outflow tract

Relin van Vliet MD¹ | Lucia J. M. Kroft PhD² | Mark G. Hazekamp PhD³ |
Arno A. W. Roest PhD¹ | Roel L. F. van der Palen PhD¹ 

¹Division of Pediatric Cardiology, Department of Pediatrics, Leiden University Medical Center, Leiden, The Netherlands

²Department of Radiology, Leiden University Medical Center, Leiden, The Netherlands

³Department of Cardiothoracic Surgery, Leiden University Medical Center, Leiden, The Netherlands

Correspondence

Roel L. F. van der Palen, MD, PhD, Division of Pediatric Cardiology, Department of Pediatrics, Leiden University Medical Center, Albinusdreef 2, Leiden 2333 ZA, The Netherlands.

Email: r.vanderpalen@lumc.nl

Abstract

We present a case of a prematurely born 2-month-old girl with a double outlet right ventricle with pulmonary atresia and a left pulmonary artery coarctation arising after ductal closure. The case highlights the importance of knowledge and identification of such an anomaly in patients with congenital heart malformations with severe pulmonary stenosis to atresia.

KEYWORDS

pulmonary atresia, pulmonary ductal coarctation, tetralogy of Fallot

A girl born at a gestational age of 31 weeks (1175 g) was prenatally diagnosed with double outlet right ventricle with pulmonary atresia (DORV-PA) of Fallot type, a ventricular septal defect, and persistent left superior caval vein draining into the coronary sinus. After birth, she was treated with prostaglandin to maintain ductal patency for pulmonary blood flow. At the age of 2 months, a modified Blalock–Taussig (BT) shunt was placed between the right subclavian artery and right pulmonary artery (RPA), after which the prostaglandin was discontinued. During the closure of the arterial duct, saturation decreased to 70%. Oxygen therapy was started to keep saturation levels above 75%. Echocardiographic examination showed a patent BT shunt, but a narrowing at the proximal left pulmonary artery (LPA) was suspected. A computed tomography angiography (CTA) confirmed the LPA coarctation (Figure 1A–C), characterized by a circumscriptive narrowing of the LPA lumen (1 mm) located at the ductal insertion into the LPA (2.5 mm) (Figure 1B,C). Moreover, the LPA was considerably smaller than the RPA (Figure 1B). A second BT

shunt was placed beyond the LPA coarctation as an intermediate step to corrective surgery. The patient clinically improved after this procedure with saturation up to 85%.

Coarctation of the LPA is a rare clinical entity that may occur in a few anatomically related congenital heart diseases involving severe narrowing of the right ventricular outflow tract, including pulmonary atresia, tetralogy of Fallot, and DORV-PA. The relationship between the arterial duct and the development of such unilateral pulmonary artery stenosis in these congenital heart diseases was first described by Elzenga et al.¹ In their morphologic study on the cardiac specimen with pulmonary atresia, an abnormal sideways arterial duct connection to the pulmonary artery was observed instead of being in direct continuity with the pulmonary trunk. In addition, histological examination revealed the presence and extension of ductal tissue into the pulmonary artery in about half of these specimens. If present, ductal tissue was located between the pulmonary trunk and the entry site of the duct in the pulmonary artery; and often a discrete obstructive

This is an open access article under the terms of the Creative Commons Attribution-NonCommercial License, which permits use, distribution and reproduction in any medium, provided the original work is properly cited and is not used for commercial purposes.

© 2021 The Authors. *Journal of Cardiac Surgery* published by Wiley Periodicals LLC

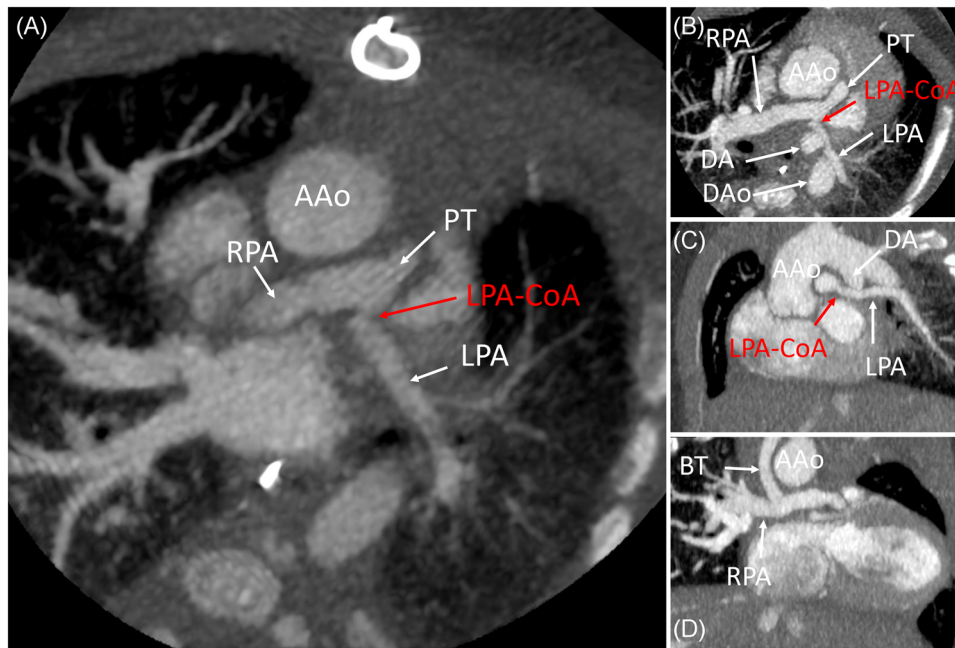


FIGURE 1 Pulmonary coarctation (red arrow) at the origin of the left pulmonary artery on 0.5 mm axial computed tomography image (A). 3 mm MIP in transversal (B), oblique coronal (C), and oblique sagittal (D) reconstructed images showing the PT with the LPA and RPA (B and C), and the Blalock–Taussig shunt anastomosis on the RPA (D). AAo, ascending aorta; BT, Blalock–Taussig shunt; DA, arterial duct; DAo, descending aorta; LPA, left pulmonary artery; LPA-CoA, pulmonary coarctation; PT, pulmonary trunk; RPA, right pulmonary artery

ridge into this pulmonary arterial segment, for the major part formed by ductal tissue, was noted.

These findings then clearly linked previously described clinical observations of cases with tetralogy of Fallot and LPA stenosis or absent LPA² and suggest constriction of (extended) ductal tissue during the closure of the arterial duct as a pathophysiological mechanism of proximal stenosis or even interruption of the LPA in such patients. Furthermore, recent investigations on embryonic development of this vascular region from the same research group confirmed that the lateral connection of the arterial duct to the proximal LPA is a cardiovascular developmental anomaly.³

Clinically, LPA coarctation will typically occur when prostaglandin administration is discontinued since most of these patients are treated with prostaglandin before palliative surgery. As echocardiography can be challenging, CTA can be of importance in diagnosis and surgical management. Ultimately, catheter intervention (stent implantation) or surgical correction (pulmonary artery reconstruction) is required to relieve branch pulmonary artery stenosis and to maintain central pulmonary artery continuity.

CONFLICT OF INTERESTS

The authors declare that there are no conflict of interests.

ETHICS STATEMENT

All procedures performed in studies involving human participants were in accordance with the 1964 Helsinki declaration and its later amendments or comparable ethical standards.

ORCID

Roel L. F. van der Palen  <https://orcid.org/0000-0003-3640-603X>

REFERENCES

1. Elzenga NJ, Gittenberger-de Groot AC. The ductus arteriosus and stenoses of the pulmonary arteries in pulmonary atresia. *Int J Cardiol.* 1986;11:195-208.
2. Presbitero P, Bull C, Haworth SG, De Leval MR. Absent or occult pulmonary artery. *Br Heart J.* 1984;52:178-185.
3. Gittenberger-de Groot AC, Peterson JC, Wisse LJ, et al. Pulmonary ductal coarctation and left pulmonary artery interruption; pathology and role of neural crest and second heart field during development. *PLoS One.* 2020;15(5):e0228478.

How to cite this article: van Vliet R, Kroft LJM, Hazekamp MG, Roest AA, van derPalen RLF. Pulmonary ductal coarctation: An entity associated with congenital heart defects involving the right ventricle outflow tract. *J Card Surg.* 2021;36:4754-4755. doi:10.1111/jocs.16067