



Universiteit
Leiden
The Netherlands

Preoperative brain MRI features and occurrence of postoperative delirium

Kant, I.M.J.; Bresser, J. de; Montfort, S.J. van; Mutsaerts, H.J.M.M.; Witkamp, T.D.; Buijsrogge, M.; ... ; Slooter, A.J.C.

Citation

Kant, I. M. J., Bresser, J. de, Montfort, S. J. van, Mutsaerts, H. J. M. M., Witkamp, T. D., Buijsrogge, M., ... Slooter, A. J. C. (2021). Preoperative brain MRI features and occurrence of postoperative delirium. *Journal Of Psychosomatic Research*, 140.
doi:10.1016/j.jpsychores.2020.110301

Version: Publisher's Version

License: [Creative Commons CC BY-NC-ND 4.0 license](https://creativecommons.org/licenses/by-nc-nd/4.0/)

Downloaded from: <https://hdl.handle.net/1887/3277324>

Note: To cite this publication please use the final published version (if applicable).



Preoperative brain MRI features and occurrence of postoperative delirium

Ilse M.J. Kant^{a,b}, Jeroen de Bresser^{c,*}, Simone J.T. van Montfort^a, Henri J.M.M. Mutsaerts^b, Theo D. Witkamp^b, Marc Buijsrogge^d, Claudia Spies^e, Jeroen Hendrikse^b, Arjen J.C. Slooter^a

^a Department of Intensive Care Medicine and UMC Utrecht Brain Center, UMC Utrecht, Utrecht University, Heidelberglaan 100, Utrecht, the Netherlands

^b Department of Radiology and UMC Utrecht Brain Center, UMC Utrecht, Utrecht University, Heidelberglaan 100, Utrecht, the Netherlands

^c Department of Radiology, Leiden University Medical Center, Leiden, the Netherlands

^d Department of Cardiothoracic Surgery, UMC Utrecht, Utrecht University, Heidelberglaan 100, Utrecht, the Netherlands

^e Department of Anesthesiology and Operative Intensive Care Medicine (CCM,CVK), Charité – Universitätsmedizin Berlin, Berlin, Germany

ARTICLE INFO

Keywords:

Delirium
MRI markers
Cortical infarcts
White matter hyperintensities

ABSTRACT

Objective: Delirium is a frequent complication after surgery with important negative outcomes for affected patients and society. However, it is still largely unknown why some patients have a predisposition for delirium and others not. To increase our understanding of the neural substrate of postoperative delirium, we studied the association between preoperative brain MRI features and the occurrence of delirium after major surgery.

Methods: A group of 413 patients without dementia (Mean 72 years, SD: 5) was included in a prospective observational two-center study design. The study was conducted at Charité Universitätsmedizin (Berlin, Germany) and the University Medical Center Utrecht (Utrecht, The Netherlands). We measured preoperative brain volumes (total brain, gray matter, white matter), white matter hyperintensity volume and shape, brain infarcts and cerebral perfusion, and used logistic regression analysis adjusted for age, sex, intracranial volume, study center and type of surgery.

Results: Postoperative delirium was present in a total of 70 patients (17%). Preoperative cortical brain infarcts increased the risk of postoperative delirium, although this did not reach statistical significance (OR (95%CI): 1.63 (0.84–3.18)). Furthermore, we found a trend for an association of a more complex shape of white matter hyperintensities with occurrence of postoperative delirium (OR (95%CI): 0.97 (0.95–1.00)). Preoperative brain volumes, white matter hyperintensity volume, and cerebral perfusion were not associated with occurrence of postoperative delirium.

Conclusion: Our study suggests that patients with preoperative cortical brain infarcts and those with a more complex white matter hyperintensity shape may have a predisposition for developing delirium after major surgery.

1. Introduction

Postoperative delirium is characterized by an acute change in attention and awareness after surgery [1]. Postoperative delirium is common in older patients with an incidence of 10–15% following major surgery, and is associated with a longer hospital stay, increased medical costs and impaired cognitive outcome [2,3]. Known predisposing risk factors for postoperative delirium include advanced age, preoperative cognitive deficits, functional impairment, and a history of delirium [2]. Precipitating factors for occurrence of a postoperative delirium include

major cardiovascular or orthopedic surgery, and complications of surgery. An increased understanding of the underlying pathophysiology could help to develop prevention and therapy strategies. Furthermore, it could result in improved identification of patients who are at risk for developing postoperative delirium. However, the underlying pathophysiology of delirium remains largely unknown.

To increase the understanding of the neural substrate of postoperative delirium, recent studies have focused on neuroimaging methods using brain magnetic resonance imaging (MRI) [4–14]. Previous studies showed that possible predisposing brain MRI markers of

* Corresponding author at: Department of Radiology, Leiden University Medical Center, Leiden, Albinusdreef 2, 2333 ZA, Leiden, the Netherlands.

E-mail addresses: i.kant-3@umcutrecht.nl (I.M.J. Kant), j.h.j.m.de.bresser@lumc.nl (J. de Bresser), s.j.t.vanmontfort-2@umcutrecht.nl (S.J.T. van Montfort), henkjanmutsaerts@gmail.com (H.J.M.M. Mutsaerts), claudia.spies@charite.de (C. Spies), j.hendrikse@umcutrecht.nl (J. Hendrikse), a.slooter-3@umcutrecht.nl (A.J.C. Slooter).

<https://doi.org/10.1016/j.jpsychores.2020.110301>

Received 19 March 2020; Received in revised form 18 October 2020; Accepted 12 November 2020

Available online 16 November 2020

0022-3999/© 2020 The Authors.

Published by Elsevier Inc.

This is an open access article under the CC BY-NC-ND license

(<http://creativecommons.org/licenses/by-nc-nd/4.0/>).

postoperative delirium could be a decreased global or regional brain volume [12–14], an increased white matter hyperintensity (WMH) volume [4,11,15] and multiple brain infarcts [8]. However, there is also conflicting evidence showing no relation with brain volumes [6,15], and no association with WMH volumes or hemodynamics [5,6,12]. An important issue to consider is that apart from the SAGES study [16], most of these previous studies were underpowered and/or lacked preoperative brain imaging. Moreover, these studies differed in clinical settings, characteristics of study participants and quality of study design [17]. No previous studies have distinguished between lacunar and cortical brain infarcts (i.e. distinguished infarcts due to cerebral small vessel disease or large vessel disease) [18], or assessed infarct volume as a measure for total infarct burden, or considered new advanced brain MRI features of cerebral small vessel disease such as WMH shape. Therefore, a large study that assesses multiple preoperative brain MRI features derived from advanced preoperative MRI methods is needed.

The aim of the present study was to assess whether preoperative brain MRI features are associated with occurrence of postoperative delirium in a large group of older patients without dementia undergoing major surgery. These brain MRI features include both commonly used and novel MRI brain features assessed with state-of-the-art techniques, including global brain volumes, WMH volume, WMH shape features, cerebral hemodynamics and cortical and lacunar infarcts.

2. Methods

2.1. Study design and participants

The Biomarkers for Postoperative Cognitive Decline (BioCog) study is a large observational two-center study at Charité Universitätsmedizin (Berlin, Germany) and the University Medical Center Utrecht (Utrecht, The Netherlands) that aims to detect biomarkers for postoperative delirium and postoperative cognitive dysfunction [19]. The study has been approved by medical ethics committees of both participating centers under ethical approval number EA2/092/14 (Berlin) and 14-469 (Utrecht). All study participants signed a written informed consent form and were (1) ≥ 65 years of age, (2) non-demented (minimal state exam (MMSE) score of ≥ 24), (3) able to undergo a brain MRI scan and cognitive tests, (4) scheduled for major elective surgery of at least 60 min.

2.2. Procedures

Patients who were scheduled for major surgery were invited to the hospital for a preoperative visit for a brain MRI scan, questionnaires and cognitive tests. Questionnaires were administered by trained researchers and included the MMSE, frailty questions and questions on medical history and vascular risk factors. The preoperative American Society of Anesthesiologists (ASA) score was scored by anesthesiologists (in training).

2.3. Delirium assessment

Postoperative delirium was defined according to the 5th edition of the Diagnostic and Statistical Manual of Mental Disorders (DSM-5) criteria [1]. Delirium assessment was performed by trained researchers who filled in the Confusion Assessment Method for the Intensive Care Unit (CAM-ICU) [20] and nursing Delirium Screening Scale (Nu-DESC) [21] twice daily (morning and afternoon) for seven days following surgery or discharge, whichever came first. An additional chart review in the same timeframe was performed by trained researchers [22]. Patients were considered delirious in case of ≥ 2 cumulative points on the Nu-DESC and/or a positive CAM-ICU score and/or patient chart review that showed descriptions of delirium (e.g., confused, agitated, drowsy, disorientated, delirious, receiving antipsychotic therapy).

Patients who had one or more delirious episodes in the seven days

following surgery were categorized as having postoperative delirium, whereas patients who had no delirious episodes were categorized as having no delirium.

2.4. Brain MRI scans

Participants were scanned on a 3 T Magnetom TrioTim (Siemens Healthcare, Erlangen, Germany) MRI scanner (Berlin) or a 3 T Achieva (Philips Healthcare, Best, The Netherlands) (Utrecht). The MRI scanning protocol was standardized and consisted of a 3-dimensional (3D) T1-weighted sequence (voxel size $1.0 \times 1.0 \times 1.0 \text{ mm}^3$; Berlin: repetition time [TR]/echo time [TE] 2500/4.77 ms; Utrecht: TR/TE 7.9/4.5 ms) a fluid-attenuated inversion recovery (FLAIR) sequence (Berlin: TR/TE/inversion time 4800/388/1800 ms; voxel size $0.49 \times 0.49 \times 1.00 \text{ mm}^3$; Utrecht: TR/TE/inversion time 4800/125/1650 ms; voxel size $1.11 \times 1.11 \times 0.56 \text{ mm}^3$), a 2D EPI pseudo-continuous arterial spin labeling (pCASL) sequence (Berlin: voxel size $3.0 \times 3.0 \times 7.0 \text{ mm}^3$; TR/TE 6000/14 ms, label duration 1650 ms, post labeling delay 1525–2275 ms, no background suppression; Utrecht: voxel size $3.0 \times 3.0 \times 7.0 \text{ mm}^3$; TR/TE 3919/17 ms, label duration 1650 ms, post labeling delay 1525–2225 ms, with background suppression) and a diffusion-weighted image (Berlin: n.a.; Utrecht: (voxel size = $0.96 \times 1.19 \times 4.00 \text{ mm}^3$; TR/TE 3294/68 ms) for visual inspection only.

2.5. MRI processing steps and analysis

For analysis of brain volumes and WMH volumes, a method was used that is robust for scanner differences [23], that was previously used in a BioCog substudy [24]. First, 3D FLAIR images were rigid-body registered to 3D T1-weighted images using statistical parametric mapping software (SPM) version 12 (SPM12; Wellcome Institute of Neurology, University College London, UK, <http://www.fil.ion.ucl.ac.uk/spm/doc/>) for Matlab (The MathWorks, Inc., Natick, Massachusetts, United States). WMH probability maps were calculated using an automated algorithm: the lesion prediction algorithm of the SPM12 lesion segmentation toolbox (LST, version 2.0.15, www.statistical-modeling.de/lst.html) for SPM12. The LST lesion filling method using the WMH probability maps was performed on the T1-weighted images. The filled T1-weighted images were segmented in gray matter, white matter and cerebrospinal fluid using the Computational Anatomy Toolbox 12 (CAT12), version r1155 [25], from which the tissue volumes were obtained. All segmented images were visually checked by a trained researcher (IK), supervised by a neuroradiologist with extensive experience in brain segmentation (JB). Scans with large artefact hindering accurate segmentation and other artefacts leading to oversegmentation or undersegmentation were excluded.

WMH shape features were determined by an in-house developed automated method [26]. This method has not been validated for between-scanner differences, and was therefore only performed on MRI FLAIR data from Utrecht. In short, the lateral ventricles were segmented and inflated. WMH within 10 mm from the lateral ventricles were considered periventricular, WMH over 10 mm from the ventricles as deep, and WMH that extended from periventricular to deep were considered confluent WMH. The WMH probability maps were thresholded at 10%, after which a convex hull was drawn around the volumes. Based on the convex hull, the convexity, solidity, concavity index, fractal dimension of periventricular/confluent WMH, and the fractal dimension and eccentricity of deep WMH were determined [26]. The brain volume and WMH shape features analyses were performed by a trained researcher (IK) under supervision by an experienced researcher in these areas (JB).

Cerebral perfusion was calculated using ExploreASL [27]. Intermediate ASL images were motion corrected and registered to the gray matter partial volume maps of the T1-weighted images. The CBF images were quantified with a single compartment model [28], after which the mean CBF of the total gray matter and of the deep white matter regions

of interest (ROI) was obtained. Additionally, the spatial coefficient of variation (spatial CoV) of these images was calculated in the total gray matter, as a proxy for cerebrovascular health [29]. The perfusion analyses and the quality assessment of the resulting CBF images were performed by a trained researcher (IK), supervised by an experienced ASL researcher (HM). Images were classified as 1) CBF contrast, 2) vascular contrast or 3) no contrast. Images of category 1 were included in both CBF and spatial CoV analyses, images of category 2 only in the spatial CoV analyses and images in category 3 were excluded from analysis. Presence and classification of brain infarcts was performed on the T1-weighted, FLAIR and DWI images by two experienced neuroradiologists (JB and TW) according to the international standards for reporting vascular changes on neuroimaging (STRIVE) criteria [18]. Manual segmentation of cortical infarcts >1.5 cm was performed by a trained researcher (IK) and supervised by a neuroradiologist (JB) (see Fig. 1).

2.6. Statistical analysis

Demographics of patients with and without a delirium were compared between both groups by an independent samples *t*-test for continuous, normally distributed data, a Mann-Whitney *U* test for continuous skewed data, and a chi-square for comparison of categorical data. The association of MRI features with postoperative delirium was studied with logistic regression analyses with adjustment for age, sex, study center and type of surgery (i.e. cardiothoracic, gastro-intestinal/abdominal, orthopedic or peripheral). Brain volumes, WMH volumes and cortical infarct volumes were additionally adjusted for intracranial volume.

3. Results

3.1. Patients

In total, 7568 patients were invited, 1033 persons gave informed consent, of whom 100 participants dropped out. Data was collected from a total of 933 patients, of whom 495 participants received a preoperative brain MRI scan. Of these participants a total of 31 participants were excluded due to previous or scheduled neurosurgery ($n = 17$), early quitting of the MRI scan due to claustrophobia ($n = 8$), brain tumors, cysts or old brain trauma ($n = 6$). For the current study we further excluded participants who had minor surgery ($n = 51$).

In total, 413 patients were therefore analyzed in the current study. Of these patients, 17% ($n = 70$) developed postoperative delirium during the first seven days after surgery. None of the diagnoses of delirium were based on chart review in the absence of a positive NuDESC or CAM-ICU. Patients who developed postoperative delirium were generally older, more often female, had a lower MMSE score and had a higher preoperative ASA score (Table 1). For demographics per study center see supplementary table A. Demographics of the total study cohort ($n = 933$) are shown in supplementary table B.

Table 1
Baseline demographics.

	Total (n = 413)	Delirium (n = 70)	No delirium (n = 343)	p-value
Age	72 ± 5	74 ± 4	72 ± 5	<0.001
Sex (F, %)	159 (39%)	35 (50%)	124 (36%)	0.03
MMSE	29 (28–30)	28 (27–30)	29 (28–30)	0.01
Frailty	55 (13%)	11 (16%)	44 (13%)	0.56
ASA score				0.02
I	25 (6%)	2 (3%)	23 (7%)	
II	250 (61%)	37 (53%)	213 (62%)	
III	137 (33%)	30 (43%)	107 (31%)	
Vascular risk factors				
Diabetes	91 (22%)	20 (29%)	71 (21%)	0.15
BMI	27 (24–29)	26 (23–29)	27 (24–29)	0.20
Hypertension	251 (62%)	45 (65%)	206 (61%)	0.59
Hyperlipidemia	145 (36%)	28 (41%)	117 (35%)	0.34
Current smoker	45 (11%)	6 (9%)	39 (12%)	0.15
History of TIA/CVA	13 (3%)	5 (7%)	8 (2%)	0.05
Type of surgery				0.01
Cardiac	40 (10%)	12 (17%)	28 (8%)	
Orthopedic	133 (32%)	17 (24%)	38 (11%)	
Gastro-intestinal/ abdominal	147 (36%)	31 (44%)	116 (34%)	
Peripheral*	93 (22%)	10 (14%)	83 (24%)	

Data represent n (percentage), mean ± SD or median (interquartile range). An independent samples T-test was performed on continuous data, and a Mann-Whitney U test for non-normal distributed data. A chi-square comparison of two groups was performed for categorical data.

MMSE: mini-mental state exam. ASA: classification of disease severity for the American Society of Anesthesiologists. BMI: body-mass index. TIA: transient ischemic attack. CVA: cerebrovascular accident.

* For a complete lists of types of surgery see supplementary material, table C.

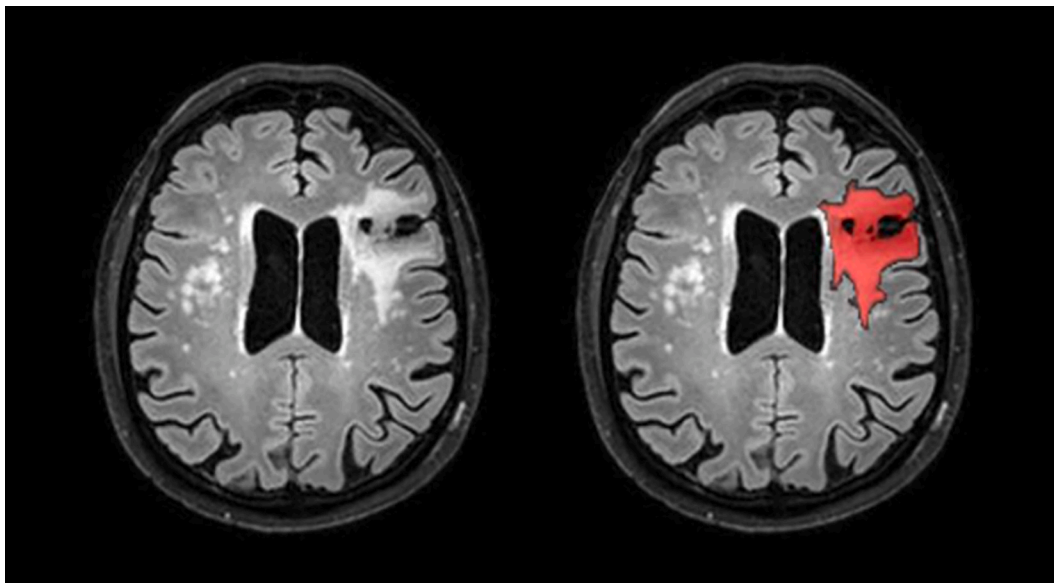


Fig. 1. Example of a FLAIR image with a manual segmentation of a large cortical brain infarct (left: original image; right: manual segmentation in red). (For interpretation of the references to colour in this figure legend, the reader is referred to the web version of this article.)

3.2. Brain volumes and WMH volume

A total of 387 participants was analyzed for brain volumes, and a total of 382 for WMH volumes. Total brain volume, gray matter volume and white matter volume were lower in the patients that developed postoperative delirium compared to the patients that did not develop postoperative delirium, however, this did not reach statistical significance (see Table 2). WMH volume was higher in the patients who developed delirium (see Table 2), however, this was also not a statistically significant association.

3.3. WMH shape features

WMH shape features were analyzed in 148 participants (Table 3). No statistically significant association was found between any WMH shape features and postoperative delirium. However, the convexity showed a non-significant trend of a lower convexity in the group with postoperative delirium (OR(95% CI): 0.95 (0.97–1.00), indicating a more complex shape of confluent and periventricular lesions.

3.4. Brain hemodynamics

A total of 245 participants had an ASL image of sufficient quality for perfusion analysis, and a total of 325 had an ASL image of sufficient quality for analysis of label distribution, for the indication of cerebrovascular health. There were no statistically significant associations between gray matter perfusion and in white matter perfusion and postoperative delirium. Furthermore, the spatial CoV showed no association with postoperative delirium (see Table 4).

3.5. Brain infarcts

Brain infarcts were analyzed for 413 participants. In total, 24% (n = 17) of the patients with postoperative delirium had cortical brain infarcts, compared to 16% (n = 54) of the patients without postoperative delirium (OR (95% CI): 1.63 (0.84–3.18), see Table 5). Furthermore, 10% (n = 7) of the patients with postoperative delirium showed large cortical brain infarcts (≥ 1.5 cm), compared to 4% (n = 14) of the patients without postoperative delirium. Preoperative cortical brain infarct volume was not associated with postoperative delirium. A subcortical infarct was present in six patients, who did not have postoperative delirium. Analyses on brain infarcts and postoperative delirium stratified for study site are presented in supplementary material, table D.

Table 2
Preoperative brain volumes in relation to postoperative delirium.

	Delirium	No delirium	OR (95% CI)
Brain volumes	n = 64	n = 323	
Total brain (% ICV)	71 ± 3	72 ± 3	1.00 (1.00–1.01)
Gray matter ^a (% ICV)	39 ± 2	39 ± 2	1.00 (0.99–1.01)
White matter ^a (% ICV)	32 ± 2	33 ± 2	1.00 (0.99–1.01)
White matter hyperintensities	n = 63	n = 319	
White matter hyperintensity volume (% ICV)	0.38 ± 0.60	0.31 ± 0.50	0.95 (0.75–1.21)

Brain volumes were presented as a percentage of the intracranial volume (ICV). All percentages were presented as the mean ± SD. White matter hyperintensity volumes were natural log transformed before the logistic regression analysis, volumes are shown as percentage of the ICV. Logistic regression analysis was performed, adjusted for age, sex, intracranial volume, study center and type of surgery. Odds ratio's are shown with a 95% confidence interval.

^a For gray and white matter analysis, patients with large cortical brain infarcts were excluded, due to segmentation errors, therefore a smaller group was analyzed (delirium: n = 57, no delirium: n = 306).

Table 3
Preoperative white matter hyperintensity shape features in relation to postoperative delirium.

	Delirium (n = 24)	No delirium (n = 124)	OR (95% CI)
Periventricular / confluent			
Solidity	0.33 ± 0.22	0.32 ± 0.19	1.01 (0.99–1.04)
Convexity	1.08 ± 0.20	1.17 ± 0.18	0.97 (0.95–1.00) ^a
Concavity index	1.16 ± 0.17	1.10 ± 0.11	1.03 (0.99–1.07)
Fractal dimension	1.64 ± 0.26	1.63 ± 0.23	0.99 (0.97–1.02)
Deep			
Fractal dimension	1.83 ± 0.19	1.82 ± 0.30	1.00 (0.99–1.02)
Eccentricity	0.59 ± 0.12	0.55 ± 0.12	1.03 (0.98–1.08)

All white matter hyperintensity shape features were multiplied by 100 before logistic regression analysis. All features were presented as the mean ± standard deviation. Logistic regression analysis was performed with adjustments for age, sex and type of surgery. Odds ratios are shown with a 95% confidence interval (95% CI).

^a p = 0.06.

Table 4
Preoperative perfusion in relation to postoperative delirium.

	Delirium (n = 41)	No delirium (n = 204)	OR (95% CI)
Gray matter perfusion	74.2 ± 21.7	74.7 ± 21.0	1.00 (0.98–1.02)
Deep white matter perfusion	29.3 ± 9.3	26.8 ± 8.9	1.02 (0.98–1.06)
Spatial CoV	0.62 ± 0.24	0.62 ± 0.27	0.72 (0.21–2.53)

Cerebral perfusion is presented as the mean ± SD (ml/100 g/min). Logistic regression analyses were performed, adjusted for age, sex, study center and type of surgery. Odds ratio's were shown with a 95% confidence interval (95% CI). Spatial CoV was calculated for a larger sample (delirium: n = 56, no delirium: n = 269).

Table 5
Preoperative brain infarcts in relation to postoperative delirium.

	Delirium (n = 70)	No delirium (n = 343)	OR (95% CI)
Presence of lacunar infarcts	13 (19%)	78 (23%)	0.60 (0.30–1.21)
Presence of cortical infarcts	17 (24%)	54 (16%)	1.63 (0.84–3.18)
Cortical infarct volume	1.61 ± 6.29	0.56 ± 5.52	1.03 (0.99–1.07)

Cortical brain infarct volumes were measured in patients with infarcts >1.5 cm and are shown as mean ± standard deviationD (ml). Logistic regression analyses were adjusted for age, sex, study center and type of surgery. Cortical infarct volume was additionally adjusted for intracranial volume.

4. Discussion

In summary, we found an association between preoperative cortical brain infarcts and occurrence of postoperative delirium, although this did not reach statistical significance. Furthermore, we detected a trend for an association of a more complex shape of WMH with occurrence of postoperative delirium. No associations were found between preoperative WMH volume, presence of lacunar infarcts, global brain volumes and postoperative delirium.

Previous studies on the association between preoperative global

brain volume and postoperative delirium have shown conflicting results. Some small studies showed an association between reduced preoperative brain volumes and postoperative delirium [9,30], however, most studies did not find this association [6,12–15]. Our findings are therefore in accordance with most previous studies. The total brain volume in patients with a delirium in our study was slightly lower than in patients without a delirium (Table 2), however, the effect size was very small, and comparable to previous negative findings in the SAGES study that had a similar design as the BioCog study [6].

WMH volume is a key imaging marker of cerebral small vessel disease. In previous studies on the relation between WMH and postoperative delirium, most studies showed an association [4,11,15] or trend [12] between WMH volume and postoperative delirium. However, the largest previous study (SAGES) has concluded that there was no significant association between WMH volume and postoperative delirium or delirium severity [6]. Our study is the largest study to date to assess this relation, and although WMH volume was higher in patients who developed postoperative delirium, this difference did not reach statistical significance. Based on our results the effect size of a possible association between WMH volume and occurrence of a postoperative delirium is probably smaller than previously expected.

WMH shape features are novel markers for cerebral small vessel disease, in which a more rough or complex shape of periventricular and confluent lesions, and a more elongated shape of deep lesions potentially represents a more severe manifestation of cerebral small vessel disease [26,31]. WMH shape features have shown the ability to distinguish patients with different diseases, showing that a more complex shape of lesions was related to a more severe disease type, such as type 2 diabetes mellitus and frailty [26,31]. Our study is the first to assess preoperative WMH shape features in relation to postoperative delirium. Although our study showed no significant between-group differences in these features, a trend was found for the association between a lower convexity of periventricular and confluent lesions and postoperative delirium. This finding indicates that periventricular and confluent WMH might be more complex in patients who will develop postoperative delirium. A lower convexity has previously shown to be related to frailty in a cross-sectional study from the same study cohort [32]. Future studies should be performed to elucidate the exact role of WMH shape in relation to adverse postoperative events.

Previous studies on cerebral hemodynamics have shown that during a delirium episode, cerebral perfusion was disrupted [33]. Furthermore, evaluation of cerebral hemodynamics has shown the ability to detect neurodegeneration such as Alzheimer's disease at an early stage [34]. As dementia is an important predisposing factor for delirium, altered hemodynamics might already be present before surgery in patients who are at risk for delirium. One retrospective study showed that cerebral blood flow abnormalities on CT scans in patients with cardiac surgery were related to postoperative adverse neurologic outcomes, of which only a small percentage (1.5%) was postoperative delirium. Only one previous study (SAGES) reported on the relationship between preoperative perfusion as measured with arterial spin labeling (ASL) MRI and postoperative delirium, and showed no association [5]. The lack of associations in our larger cohort are in line with this previous study. These findings may indicate that impaired cerebral perfusion may not predispose elderly for postoperative delirium, or that any relationship between cerebral hemodynamics and POD is more complex.

Brain infarcts can be divided into lacunar, subcortical and cortical brain infarcts. These infarcts reflect different disease processes, as lacunar brain infarcts are regarded as a feature of cerebral small vessel disease, whereas cortical brain infarcts are a feature of large vessel disease. Previous studies on the relation between cerebral infarcts and postoperative delirium have not distinguished between lacunar and cortical infarcts [8,35]. These studies have shown an association between multiple brain infarcts and postoperative delirium in patients after cardiac surgery [8,35]. We did not find an association between lacunar infarcts and postoperative delirium. However, we did detect an

association between cortical infarcts and delirium, although this did not reach statistical significance. Our findings contribute to previous findings by indicating that the previously observed association could be driven by the presence of cortical brain infarcts. Possibly, patients with large vessel disease are more at risk for perioperative events resulting in postoperative delirium, such as perioperative micro-embolism due to a higher preoperative cardiovascular burden [10,35,36]. Another explanation may be that patients with larger cortical brain infarcts have a lower brain reserve. A lower brain reserve could increase the vulnerability for precipitating risk factors for delirium in the perioperative period.

Strengths of our study are that it is the largest prospective study on preoperative brain volumes, perfusion and infarcts in relation to postoperative delirium to date, with state-of-the-art imaging and analysis techniques. This is the first study on WMH shape analysis and delirium. These WMH shape markers were not analyzed in the total study group, because these were not validated for between-center applications. Furthermore, our study included a heterogeneous group of patients who were scheduled for different types of major surgery from two study centers, increasing the generalizability of our results.

Limitations of our study may be the extensive work up study protocol for all participants, possibly introducing a selection of patients who were less vulnerable compared to patients who declined participation. This could have underestimated the observed associations between preoperative MRI features and postoperative delirium. Another limitation could be that we had to exclude patients with head motion artefacts, especially for the perfusion MRI. This reduced our power to detect between group differences, and possibly led to exclusion of vulnerable patients who were not able to lie still in the MRI scanner. However, there were no differences in the frequency of delirium in the group included in our perfusion analysis compared to the excluded group. A limitation could be that for some of the brain MRI feature not all scans could be used, which could have underestimated the found results for some of these features. Another limitation could be that we used two different types of MRI scanners, introducing a potential between center difference. However, we used an image analysis pipeline that is robust for center differences, and adjusted for study center in all analyses. Unfortunately, we did not collect data whether participants with cortical infarcts were symptomatic from their lesions. Further, due to the relatively small number of patients with cortical infarcts in combination with the large variation in lesion location, we had insufficient statistical power to perform analyses on the effect of lesion location.

In conclusion, we have shown that structural brain MRI features may only be minor predisposing factors for postoperative delirium, which is in contrast to a number of previous studies. Our study suggests that only patients with preoperative cortical brain infarcts and patients with a more complex white matter hyperintensity shape may have a predisposition for developing delirium after major surgery.

Funding

The research leading to these results has received funding from the European Union Funded Seventh Framework Research program (FP7 2007e2013) under grant agreement no. 602461/HEALTH-F2- 2014-60246, BioCog (Biomarker Development for Postoperative Cognitive Impairment in the Elderly), www.biocog.eu. The sponsor had no role in study design, collection, analysis and interpretation of data, writing of the report, and the decision to submit the article for publication.

Data statement

The datasets generated and analyzed during the current study are not publicly available as this is a substudy of a still ongoing consortium study, but may be available from the corresponding author on reasonable request. This research was conducted on behalf of the BioCog Consortium, clinicaltrials.gov identifier: NCT02265263, ethical

approval number EA2/092/14 (Berlin), 14-469 (Utrecht).

This research was conducted in the University Medical Center Utrecht (Utrecht, the Netherlands), Department of Intensive Care Medicine and at Charité Universitätsmedizin (Berlin, Germany).

Declaration of Competing Interest

The authors have no competing interests to report.

Appendix A. Supplementary data

Supplementary data to this article can be found online at <https://doi.org/10.1016/j.jpsychores.2020.110301>.

References

- [1] American Psychiatric Association, *Diagnostic and Statistical Manual of Mental Disorders*, 5th ed., 2013. Washington, DC.
- [2] S.K. Inouye, R.G.J. Westendorp, J.S. Saczynski, Delirium in elderly people, *Lancet* 383 (9920) (2014) 911–922, [https://doi.org/10.1016/S0140-6736\(13\)60688-1](https://doi.org/10.1016/S0140-6736(13)60688-1).
- [3] J. Sprung, R.O. Roberts, T.N. Weingarten, et al., Postoperative delirium in elderly patients is associated with subsequent cognitive impairment, *Br. J. Anaesth.* 119 (2) (2017) 316–323, <https://doi.org/10.1093/bja/aex130>.
- [4] Y. Hatano, J. Narumoto, K. Shibata, et al., White-matter hyperintensities predict delirium after cardiac surgery, *Am. J. Geriatr. Psychiatry* 21 (10) (2013) 938–945, <https://doi.org/10.1016/j.jagp.2013.01.061>.
- [5] T.T. Hsieh, W. Dai, M. Cavallari, et al., Cerebral blood flow MRI in the nondemented elderly is not predictive of post-operative delirium but is correlated with cognitive performance, *J. Cereb. Blood Flow Metab.* 37 (4) (2017) 1386–1397, <https://doi.org/10.1177/0271678X16656014>.
- [6] M. Cavallari, T.T. Hsieh, C.R.G. Guttmann, et al., Brain atrophy and white matter hyperintensities are not significantly associated with incidence and severity of postoperative delirium in older persons without dementia, *Neurobiol. Aging* (2015), <https://doi.org/10.1016/j.neurobiolaging.2015.02.024>.
- [7] M. Cavallari, W. Dai, C.R.G. Guttmann, et al., Longitudinal diffusion changes following postoperative delirium in older people without dementia, *Neurology* 89 (10) (2017) 1020–1027, <https://doi.org/10.1212/WNL.0000000000004329>.
- [8] S. Otomo, K. Maekawa, T. Goto, T. Baba, A. Yoshitake, Pre-existing cerebral infarcts as a risk factor for delirium after coronary artery bypass graft surgery, *Interact. Cardiovasc. Thorac. Surg.* 17 (5) (2013) 799–804, <https://doi.org/10.1093/icvts/ivt304>.
- [9] K. Maekawa, T. Baba, S. Otomo, S. Morishita, N. Tamura, Low pre-existing gray matter volume in the medial temporal lobe and white matter lesions are associated with postoperative cognitive dysfunction after cardiac surgery, *PLoS One* 9 (1) (2014), <https://doi.org/10.1371/journal.pone.0087375>.
- [10] H. Omiya, K. Yoshitani, N. Yamada, et al., Preoperative brain magnetic resonance imaging and postoperative delirium after off-pump coronary artery bypass grafting: a prospective cohort study, *Can. J. Anesth.* 62 (6) (2015) 595–602, <https://doi.org/10.1007/s12630-015-0327-x>.
- [11] C.C. Price, J.J. Tanner, I. Schmalfuss, et al., A pilot study evaluating pre-surgery neuroanatomical biomarkers for postoperative cognitive decline after total knee arthroplasty in older adults, *Anesthesiology* 120 (3) (2014) 601–613, <https://doi.org/10.1016/j.biotechadv.2011.08.021>.
- [12] C.H. Brown, R. Faigle, L. Klinker, et al., The Association of brain MRI characteristics and postoperative delirium in cardiac surgery patients, *Clin. Ther.* (2015) 1–23, <https://doi.org/10.1016/j.clinthera.2015.10.021>.
- [13] A. Shioiri, A. Kurumaji, T. Takeuchi, K. Nemoto, H. Arai, T. Nishikawa, A decrease in the volume of gray matter as a risk factor for postoperative delirium revealed by an atlas-based method, *Am. J. Geriatr. Psychiatry* (2015) 1–5, <https://doi.org/10.1016/j.jagp.2015.09.002>.
- [14] A.M. Racine, T.G. Fong, T.G. Trivison, et al., Alzheimer's-related cortical atrophy is associated with postoperative delirium severity in persons without dementia, *Neurobiol. Aging* 59 (2017) 55–63, <https://doi.org/10.1016/j.neurobiolaging.2017.07.010>.
- [15] J.C. Root, K.O. Pryor, R. Downey, et al., Association of pre-operative brain pathology with post-operative delirium in a cohort of non-small cell lung cancer patients undergoing surgical resection, *Psychooncology* 22 (9) (2013) 2087–2094, <https://doi.org/10.1002/pon.3262>.
- [16] E.M. Schmitt, E.R. Marcantonio, D.C. Alsop, et al., novel risk markers and long-term outcomes of delirium: the successful aging after elective surgery (SAGES) study design and methods, *J. Am. Med. Dir. Assoc.* 13 (9) (2012) 818.e1–818.e10, <https://doi.org/10.1016/j.jamda.2012.08.004>.
- [17] I.M.J. Kant, J. de Bresser, S.J.T. van Montfort, A.J.C. Slooter, J. Hendrikse, MRI markers of neurodegenerative and neurovascular changes in relation to postoperative delirium and postoperative cognitive decline, *Am. J. Geriatr. Psychiatry* 25 (10) (2017) 1048–1061, <https://doi.org/10.1016/j.jagp.2017.06.016>.
- [18] J.M. Wardlaw, E.E. Smith, G.J. Biessels, et al., Neuroimaging standards for research into small vessel disease and its contribution to ageing and neurodegeneration, *Lancet Neurol.* 12 (8) (2013) 822–838, [https://doi.org/10.1016/S1474-4422\(13\)70124-8](https://doi.org/10.1016/S1474-4422(13)70124-8).
- [19] G. Winterer, G. Androsova, O. Bender, et al., Personalized risk prediction of postoperative cognitive impairment – rationale for the EU-funded BioCog project, *Eur Psychiatry*. 0 (0) (2018) 4–9, <https://doi.org/10.1016/J.EURPSY.2017.10.004>.
- [20] E.W. Ely, R. Margolin, J. Francis, et al., Evaluation of delirium in critically ill patients: validation of the Confusion Assessment Method for the Intensive Care Unit (CAM-ICU), *Crit. Care Med.* 29 (7) (2001).
- [21] J.D. Gaudreau, P. Gagnon, F. Harel, A. Tremblay, M.A. Roy, Fast, systematic, and continuous delirium assessment in hospitalized patients: the nursing delirium screening scale, *J. Pain Symptom Manag.* 29 (4) (2005) 368–375, <https://doi.org/10.1016/j.jpainsymman.2004.07.009>.
- [22] S.K. Inouye, A.L. Leo-summers, Y. Zhang, S.T. Bogardus, D.L. Leslie, J.V. Agostini, A chart-based method for identification of delirium: validation assessment method, *Chart* (2005) 312–318.
- [23] R. Heinen, W.H. Bouvy, A.M. Mendrik, M. Viergever, G.J. Biessels, J. de Bresser, Robustness of automated methods for brain volume measurements across different MRI field strengths, *PLoS One* 11 (10) (2016) 1–16, <https://doi.org/10.1371/journal.pone.0165719>.
- [24] I.M.J. Kant, J. de Bresser, S.J.T. van Montfort, et al., The association between brain volume, cortical brain infarcts, and physical frailty, *Neurobiol. Aging* 70 (2018) 247–253, <https://doi.org/10.1016/j.neurobiolaging.2018.06.032>.
- [25] P. Schmidt, C. Gaser, M. Arsic, et al., An automated tool for detection of FLAIR-hyperintense white-matter lesions in Multiple Sclerosis, *Neuroimage* 59 (4) (2012) 3774–3783, <https://doi.org/10.1016/j.neuroimage.2011.11.032>.
- [26] R. Ghaznawi, M.I. Geerlings, M.G. Jaarsma-coes, et al., The Association Between Lacunes and White Matter Hyperintensity Features on MRI: The SMART -MR Study, 2018, <https://doi.org/10.1177/0271678X18800463>.
- [27] H.J.M.M. Mutsaerts, J. Petr, D.L. Thomas, et al., Comparison of arterial spin labeling registration strategies in the multi-center GENetic frontotemporal dementia initiative (GENFI), *J. Magn. Reson. Imaging* 47 (1) (2018) 131–140, <https://doi.org/10.1002/jmri.25751>.
- [28] D.C. Alsop, J.A. Detre, X. Golay, et al., Recommended implementation of arterial spin-labeled perfusion MRI for clinical applications: a consensus of the ISMRM perfusion study group and the european consortium for ASL in dementia, *Magn. Reson. Med.* 116 (October 2013) (2014) 102–116, <https://doi.org/10.1002/mrm.25197>.
- [29] H.J. Mutsaerts, J. Petr, L. Václavů, et al., The spatial coefficient of variation in arterial spin labeling cerebral blood flow images, *J. Cereb. Blood Flow Metab.* (2017), <https://doi.org/10.1177/0271678X16683690>, 271678X16683690.
- [30] A. Shioiri, A. Kurumaji, T. Takeuchi, K. Nemoto, H. Arai, T. Nishikawa, A decrease in the volume of gray matter as a risk factor for postoperative delirium revealed by an atlas-based method, *Am. J. Geriatr. Psychiatry* (September 2015) 1–5, <https://doi.org/10.1016/j.jagp.2015.09.002>.
- [31] J. de Bresser, H.J. Kuijff, K. Zaanen, et al., White matter hyperintensity shape and location feature analysis on brain MRI; proof of principle study in patients with diabetes, *Sci. Rep.* 8 (1) (2018) 1–10, <https://doi.org/10.1038/s41598-018-20084-y>.
- [32] I.M.J. Kant, H.J.M.M. Mutsaerts, S.J.T. van Montfort, et al., The association between frailty and MRI features of cerebral small vessel disease, *Sci. Rep.* 9 (1) (2020), <https://doi.org/10.1038/s41598-019-47731-2>.
- [33] T.G. Fong, S.T. Bogardus, A. Daftary, et al., Cerebral perfusion changes in older delirious patients using 99mTc HMPAO SPECT, *J. Gerontol. A Biol. Sci. Med. Sci.* 61 (12) (2006) 1294–1299.
- [34] C.E. Wierenga, C.C. Hays, Z.Z. Zlatar, Cerebral blood flow measured by arterial spin labeling MRI as a preclinical marker of Alzheimer's disease, *J. Alzheimer Dis.* 42 (Suppl. 4) (2014) S411–S419, <https://doi.org/10.1126/science.1249098>.
- [35] A. Ito, T. Goto, K. Maekawa, T. Baba, Y. Mishima, K. Ushijima, Postoperative neurological complications and risk factors for pre-existing silent brain infarction in elderly patients undergoing coronary artery bypass grafting, *J. Anesth.* 26 (3) (2012) 405–411, <https://doi.org/10.1007/s00540-012-1327-4>.
- [36] T. Goto, K. Maekawa, Cerebral dysfunction after coronary artery bypass surgery, *J. Anesth.* 28 (2) (2014) 242–248, <https://doi.org/10.1007/s00540-013-1699-0>.