



Universiteit
Leiden
The Netherlands

NTRK fusions are extremely rare in bone tumours

Lam, S.W.; Bruijn, I.H.B.D.; Wezel, T. van; Cleven, A.H.G.; Hogendoorn, P.C.W.; Cleton-Jansen, A.M.; Bovee, J.V.M.G.

Citation

Lam, S. W., Bruijn, I. H. B. D., Wezel, T. van, Cleven, A. H. G., Hogendoorn, P. C. W., Cleton-Jansen, A. M., & Bovee, J. V. M. G. (2021). NTRK fusions are extremely rare in bone tumours. *Histopathology*, 79(5), 880-885. doi:10.1111/his.14432

Version: Publisher's Version

License: [Creative Commons CC BY-NC-ND 4.0 license](#)

Downloaded from: <https://hdl.handle.net/1887/3274146>

Note: To cite this publication please use the final published version (if applicable).

SHORT REPORT

NTRK fusions are extremely rare in bone tumours

Suk Wai Lam,  Inge H Briaire-de Bruijn,  Tom van Wezel,  Arjen H G Cleven, 
Pancras C W Hogendoorn,  Anne-Marie Cleton-Jansen  & Judith V M G Bovée 
Department of Pathology, Leiden University Medical Centre, Leiden, The Netherlands

Date of submission 24 May 2021
Accepted for publication 18 June 2021
Published online Article Accepted 20 June 2021

Lam S W, Briaire-de Bruijn I H, van Wezel T, Cleven A H G, Hogendoorn P C W, Cleton-Jansen A-M & Bovée J V M G

(2021) *Histopathology* 79, 880–885. <https://doi.org/10.1111/his.14432>

NTRK fusions are extremely rare in bone tumours

Aims: Because of the efficacy of tropomyosin receptor kinase (Trk) inhibitor therapy in tumours with rearrangements of the neurotrophic tyrosine kinase receptor genes (*NTRK* genes), there has been a surge in demand for *NTRK* fusion screening. To date, most studies involving mesenchymal tumours have focused on soft tissue tumours, and data on bone tumours are sparse. Hence, we aimed to explore the frequency of *NTRK* fusions in a large series of primary bone tumours.

Methods and results: Immunohistochemical expression of pan-Trk was successfully assessed in 354 primary bone tumours by the use of tissue microarrays. In a selection of positive cases, additional molecular analysis for *NTRK* fusions was performed with anchored multiplex polymerase chain reaction-based

targeted next-generation sequencing. Positivity was found in 19 cases (5%), which comprised Ewing sarcoma ($n = 6$, 33%), osteosarcoma ($n = 11$, 13%), and giant-cell tumour of bone ($n = 2$, 3%). In all except one case, cytoplasmic staining was observed. Weak staining was most often observed ($n = 13$), although five cases showed moderate staining and one case showed focal strong staining. Molecular analysis was successful in six cases, all of which were negative for *NTRK* fusions.

Conclusion: The likelihood of finding an *NTRK* fusion in bone tumours in clinical practice is extremely low. This may imply that, if more comprehensive large-scale molecular studies confirm this, routine predictive *NTRK* testing in bone tumour patients with advanced disease may be reconsidered.

Keywords: bone tumours, immunohistochemistry, *NTRK* fusion

Introduction

The tropomyosin receptor kinase (Trk) family consists of three transmembrane neurotrophin receptors, i.e. TrkA, TrkB, and TrkC, which are encoded by the neurotrophic tyrosine kinase receptor genes *NTRK1*, *NTRK2*, and *NTRK3*, respectively.¹ Oncogenic gene fusions involving these genes lead to constitutive

activation of Trk receptors and are targetable with small-molecule inhibitors. Larotrectinib showed significant and durable antitumour activity in patients with *NTRK* fusion-positive cancer, regardless of age or tumour type.^{2–4} This has led to specific interest in *NTRK* testing, especially since clinical trials have shifted away from site-of-origin and histology-dependent designs towards basket trials, in which targeted therapy is evaluated in different diseases that share molecular alterations.⁵

NTRK fusions have been found at high frequency and to be characteristic for several rare cancer types,

Address for correspondence: J V M G Bovée, MD, PhD, Department of Pathology, Leiden University Medical Centre, P.O. Box 9600, L1-Q, 2300RC Leiden, The Netherlands. e-mail: j.v.m.g.bovee@lumc.nl

including sarcomas (i.e. infantile fibrosarcoma, secretory breast carcinoma, and congenital mesoblastic nephroma). Moreover, there is an emerging group of mesenchymal tumours defined by *NTRK* fusions that show a wide morphological spectrum, a variable risk of malignancy, and a non-specific immunoprofile.⁶ This also includes CD34-positive fibrosarcoma of bone, in which *NTRK3* fusions were recently described in two cases.⁷ In this specific category, *NTRK* fusions are diagnostic and *NTRK* fusion detection should be performed.⁸

In addition, there is an increased demand for *NTRK* fusion testing as a predictive biomarker for potential treatment with Trk inhibitors, irrespective of the tumour type. More common cancers have a low but significant frequency of *NTRK* fusions,¹ and thus represent a sizeable at-risk patient population that is worth testing for *NTRK* fusions.⁵ For sarcoma patients with locally advanced and unresectable or metastatic disease, the World Sarcoma Network (WSN) advises *NTRK* fusion testing by the use of pan-Trk immunohistochemistry prescreening only for those sarcoma types known to harbour complex genomes (e.g. osteosarcoma). In sarcomas with recurrent gene fusions (e.g. Ewing sarcoma) or amplifications as driver alterations, *NTRK* fusion testing should be restricted to research,⁸ because *NTRK* fusions and other drivers are typically mutually exclusive.⁵

As the proposed screening system is mainly based on the current knowledge of *NTRK* fusions in soft tissue sarcoma,^{8,9} we aimed to explore the frequency of *NTRK* fusions in a large series of different bone tumours. According to WSN recommendations, we used immunohistochemistry as a first screening method, followed by molecular analysis with anchored multiplex polymerase chain reaction (AMP)-based targeted next-generation sequencing (NGS) for fusions in selected cases.

Materials and methods

CASE SELECTION

Tissue microarrays (TMAs) of previously published cohorts were used to screen for *NTRK* fusions, and included conventional chondrosarcoma ($n = 137$), dedifferentiated chondrosarcoma ($n = 36$), clear cell chondrosarcoma ($n = 20$), mesenchymal chondrosarcoma ($n = 19$), osteochondroma ($n = 9$), enchondroma ($n = 11$), osteosarcoma ($n = 123$), angiosarcoma ($n = 26$), Ewing sarcoma ($n = 20$), giant-cell tumour of bone ($n = 74$), and aneurysmal bone cyst ($n = 6$).^{10–15} Most TMAs contained at least three 1.5-mm-diameter

cores of each sample to compensate for intratumoral heterogeneity. Samples were handled according to the ethical guidelines described in the 'Code for Proper Secondary Use of Human Tissue in the Netherlands' in a coded (pseudonymised) manner, as approved by the Leiden University Medical Centre ethical board (B17.020, B17.036, and B20.064).

IMMUNOHISTOCHEMISTRY

Immunohistochemistry was performed as described previously.^{11,16} For titration of the antibody, several dilutions were used on both neural tissue and a molecularly proven *NTRK*-fusion positive tumour of the parotid gland. In our study, a dilution of 1:200 showed the best signal-to-noise ratio. All slides were manually stained in one session. Microwave antigen retrieval in Tris-EDTA (pH 9.0) was performed with deparaffinised sections preincubated with phosphate-buffered saline (PBS)/1% bovine serum albumin (BSA)/5% non-fat dry milk, and this was followed by overnight incubation with the pan-Trk antibody (Abcam, Cambridge, UK; clone ERP17341, rabbit, 1:200) in PBS/1% BSA/5% non-fat dry milk. Detection with the PowerVision Poly-HRP Detection System (ImmunoLogic, Duiven, The Netherlands) and visualisation with a DAB+ substrate chromogen system (Dako, Glostrup, Denmark) were then performed. Finally, slides were counterstained with haematoxylin, dehydrated, and mounted.

For *NTRK* expression, a previously published semi-quantitative scoring system was used.¹⁶ Immunoreactivity was scored according to the location (cytoplasmic or nuclear), the intensity (1, weak; 2, moderate; or 3, strong), and the percentage of positive cells (1+, 1–25%; 2+, 25–50%; 3+, 50–75%; and 4+, >75%). Positivity of any intensity in $\geq 1\%$ of cells was considered to be a positive result. All slides were scored by two independent observers (S.W.L. and J.V.G.M.B.).

FUSION ANALYSIS

For selected cases, additional molecular analysis for *NTRK* fusions was performed with AMP-based targeted NGS. RNA was isolated from frozen sections with TRizol reagent (Life Technologies, Carlsbad, CA, USA) according to the manufacturer's instructions. The cDNA library was prepared with the Archer FusionPlex comprehensive thyroid and lung panel (Archer, Boulder, CO, USA), which included primers for *NTRK1* (exons 1–14 and 16), *NTRK2* (exons 4–17), and *NTRK3* (exons 1–12 and 14–17), and this

was followed by sequencing with the Ion S5 system (Thermo Fisher Scientific, Waltham, Massachusetts, USA) Archer analysis software (version 6.2.3) was used to analyse the produced libraries for the presence of *NTRK* fusions.

Results

PAN-TRK IMMUNOHISTOCHEMISTRY

Immunohistochemistry was successful in 354 cases. In the remaining cases, TMA cores were lost during processing. Nineteen cases (5%) showed staining of any intensity in $\geq 1\%$ of the cells; these included Ewing sarcoma ($n = 6$, 33%), osteosarcoma ($n = 11$, 13%), and giant-cell tumour of bone ($n = 2$, 3%). In all except one case, cytoplasmic staining was observed. Most of the positive cases showed weak staining ($n = 13$), five showed moderate staining, and one showed strong staining (Figure 1). Staining in only 1–25% of cells was observed in 12 cases, staining in 25–50% of cells was observed in four cases, staining in 50–75% of cells was observed in two cases, and staining in $>75\%$ of cells was observed in

one case. The remaining 335 cases were negative (Table 1).

MOLECULAR ANALYSIS FOR *NTRK* FUSION

Molecular analysis was performed in cases with weak staining in $>25\%$ of cells and in all cases with moderate or strong staining; this was successful in six cases, which comprised two Ewing sarcomas, three osteosarcomas, and one giant-cell tumour of bone (Table 1). In three cases, suitable material for molecular analysis was absent. All quality criteria were met, the coverage of *NTRK1–NTRK3* was sufficient, and none of the cases showed an *NTRK* fusion. The relative RNA expression level of *NTRK1–NTRK3* was low. As *NTRK* fusions were absent in cases with moderate and strong staining, cases with weak staining in $<25\%$ of cells were not further analysed.

Discussion

This study provides a comprehensive immunohistochemical evaluation of pan-Trk expression as a

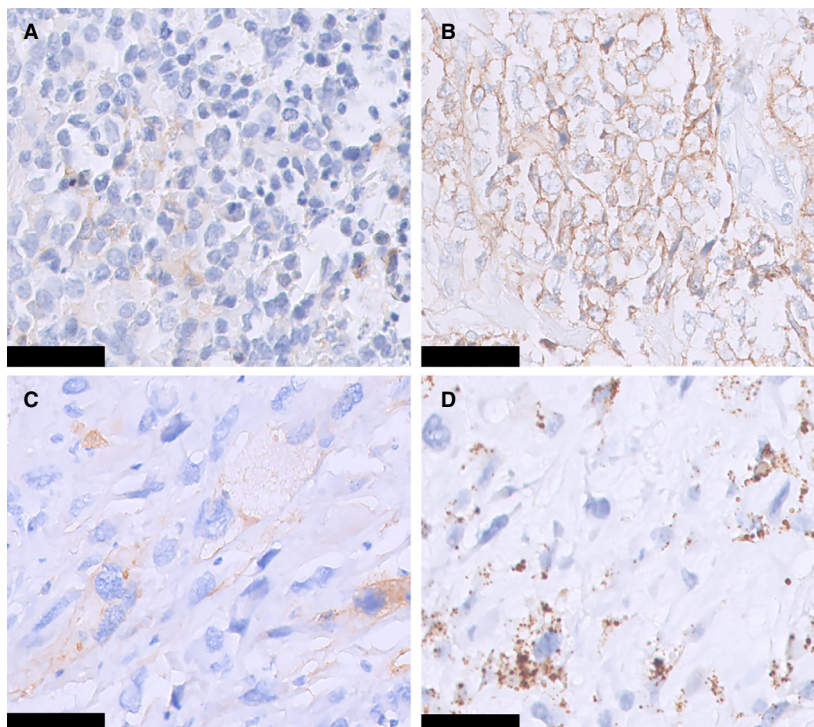


Figure 1. Immunohistochemical staining for pan-tropomyosin receptor kinase in bone tumours. Weak cytoplasmic staining (A) and moderate cytoplasmic staining (B) were seen in Ewing sarcoma. Moderate cytoplasmic staining (C) and strong cytoplasmic staining (D) were seen in osteosarcoma. Molecular analysis for neurotrophic tyrosine kinase receptor gene (*NTRK*) fusions was successful in the cases shown in (B) and (C), both of which were negative for *NTRK* fusions. Scale bar: 50 μm .

Table 1. Summary of immunohistochemical staining for pan-tropomyosin receptor kinase (Trk)

Tumour type	Total no. of cases	Positive, <i>n</i> (%) [*]	Location	Intensity	Score
Osteosarcoma	88	11 (13)			
		1	N	Weak	1+
		4	C	Weak	1+
		2 [†]	C	Weak	2+
		1 [†]	C	Moderate	1+
		2 [‡]	C	Moderate	2+
		1 [‡]	C	Strong	1+
Ewing sarcoma	18	6 (33)			
		3	C	Weak	1+
		1	C	Weak	3+
		1 [†]	C	Moderate	1+
		1 [†]	C	Moderate	4+
Giant cell tumour of bone	61	2 (3)			
		1	C	Weak	1+
		1 [†]	C	Weak	3+
Conventional chondrosarcoma	95	0			
Angiosarcoma	13	0			
Dedifferentiated chondrosarcoma	34	0			
Clear cell chondrosarcoma	16	0			
Mesenchymal chondrosarcoma	11	0			
Osteochondroma	7	0			
Enchondroma	6	0			
Aneurysmal bone cyst	5	0			

C, Cytoplasmic; N, Nuclear; 1+, 1–25%; 2+, 25–50%; 3+, 50–75%; 4+, >75%.

^{*}Pan-Trk positivity was defined as staining in ≥1% of cells of any intensity.

[†]Cases in which molecular analysis for neurotrophic tyrosine kinase receptor gene (*NTRK*) fusions was successful and gave a negative result.

[‡]Cases in which molecular analysis for *NTRK* fusions was unsuccessful.

surrogate marker for *NTRK* fusions in a large series of bone tumours, including osteogenic tumours, chondrogenic tumours, and Ewing sarcoma, which are the three most common bone sarcomas. Following WSN recommendations,⁸ we used pan-Trk immunohistochemistry as a screening method for *NTRK* fusions to explore the frequency of *NTRK* as a targetable therapeutic option in well-characterised bone tumours, and showed that *NTRK* fusions are almost non-existent.

NTRK fusions were not identified in 354 bone tumours after prescreening with immunohistochemistry,

which is in line with the low frequency in the literature, which contains only a handful of anecdotal cases.⁸ Besides one *NTRK*-fusion positive bone sarcoma that was found among a diverse set of paediatric malignancies (1.1%), the subtype of which was not further specified,¹⁷ two other *NTRK*-fusion positive bone sarcomas were described. These osteosarcoma patients and dedifferentiated chondrosarcoma patients were enrolled in a clinical trial and received larotrectinib.⁴ Interestingly, in another study of 113 osteosarcoma patients whose tumours were sequenced, three cases had an *NTRK* fusion, the chimaeric transcript of which appeared to be

non-functional and probably represented randomly occurring passenger alterations.¹⁸

Several caveats should be considered when pan-Trk immunohistochemistry is used as a first screening method for *NTRK* fusions, including variable staining patterns and intensities. Although the antibody appears to have 100% specificity in carcinomas of the colon, lung, and thyroid, the specificity in sarcomas is much lower. False-positive staining is especially frequent in tumours with smooth muscle and neural differentiation.^{5,19} In our study, positivity was observed in 5% of all cases, mostly in osteosarcoma and Ewing sarcoma, whereas *NTRK* fusions were absent in all sequenced tumours. Although positivity for pan-Trk in osteosarcoma has not been studied by others, false positivity in Ewing sarcoma has been previously described: pan-Trk expression was often present in tumours in the small blue round cell category, including desmoplastic small round cell tumours (100%), Ewing sarcoma (20–33%), and sarcomas with *BCOR* genetic abnormalities (60–100%).^{19,20} For the last of these categories of tumour, it was shown that pan-Trk expression was caused by *NTRK3* up-regulation.²⁰

Our cohort included a large proportion of sarcomas with complex genomes (osteosarcoma, high-grade chondrosarcoma, and dedifferentiated chondrosarcoma), for which the WSN recommends *NTRK* fusion testing with immunohistochemistry prescreening in patients with advanced disease. Our results indicate that the subgroup of sarcoma patients who may become eligible for *NTRK* inhibition is extremely small or even non-existent. However, it should be noted that not all bone tumour types were assessed for pan-Trk immunohistochemistry, so the frequency of *NTRK* fusions in these tumours remains unknown. Also, because the reported sensitivity of pan-Trk immunohistochemistry in sarcoma is 80%, the possibility of false negativity in our series cannot be completely ruled out, as molecular data on *NTRK* fusions in our cohort are not available.¹⁹ The false-negative rate may be even higher in tumours with *NTRK3* fusions.¹⁹ Another limitation of this study is that rare oncogenic activating splice variants of *NTRK1*, which have been described in neuroblastoma and acute myeloid leukaemia could potentially be missed, because the variant-calling pipeline used for *NTRK* fusion analysis is not able to pick these up.¹ Finally, the effect of decalcification on pan-Trk expression was not studied, so false-negative results due to decalcification cannot be ruled out completely. However, TMAs were shown to generate positive staining in previous studies,^{10,11,14,16,21,22}

and cases that were scored as pan-Trk-positive were also decalcified.

To conclude, the likelihood of finding *NTRK* fusions in bone tumours in clinical practice, even in tumours with complex genomes lacking driver alterations, such as osteosarcoma, is extremely low. This implies that, if more comprehensive large-scale molecular studies confirm this, routine predictive *NTRK* testing in bone tumour patients with advanced disease may be reconsidered.

Acknowledgements

L.G. Sand, D. Meijer, J. van Oosterwijk, D. van der Geest, S. Verbeke and Y. T. Sundara are acknowledged for contributing to the construction of TMAs.

Conflicts of interest

The authors state that they have no conflicts of interest.

Grant number and sources of support

Support was provided by Leiden University Medical Centre.

Author contributions

The study was designed, written and reviewed by S. W. Lam and J. V. M. G. Bovée. All authors contributed to data collection, data analysis, and interpretation. The manuscript was approved by all authors.

References

1. Cocco E, Scaltriti M, Drilon A. *NTRK* fusion-positive cancers and TRK inhibitor therapy. *Nat. Rev. Clin. Oncol.* 2018; **15**: 731–747.
2. Drilon A, Laetsch TW, Kummar S *et al.* Efficacy of larotrectinib in TRK fusion-positive cancers in adults and children. *N. Engl. J. Med.* 2018; **378**: 731–739.
3. Laetsch TW, DuBois SG, Mascarenhas L *et al.* Larotrectinib for paediatric solid tumours harbouring *NTRK* gene fusions: phase 1 results from a multicentre, open-label, phase 1/2 study. *Lancet Oncol.* 2018; **19**: 705–714.
4. Hong DS, DuBois SG, Kummar S *et al.* Larotrectinib in patients with TRK fusion-positive solid tumours: a pooled analysis of three phase 1/2 clinical trials. *Lancet Oncol.* 2020; **21**: 531–540.
5. Solomon JP, Benayed R, Hechtman JF, Ladanyi M. Identifying patients with *NTRK* fusion cancer. *Ann. Oncol.* 2019; **30**: vii16–viii22.
6. Antonescu CR. Emerging soft tissue tumors with kinase fusions: an overview of the recent literature with an emphasis

- on diagnostic criteria. *Genes Chromosomes Cancer* 2020; **59**: 437–444.
7. Yamazaki F, Nakatani F, Asano N *et al.* Novel NTRK3 fusions in fibrosarcomas of adults. *Am. J. Surg. Pathol.* 2019; **43**: 523–530.
 8. Demetri GD, Antonescu CR, Bjerkehagen B *et al.* Diagnosis and management of tropomyosin receptor kinase (TRK) fusion sarcomas: expert recommendations from the World Sarcoma Network. *Ann. Oncol.* 2020; **31**: 1506–1517.
 9. Siozopoulou V, Smits E, De Winne K, Marcq E, Pauwels P. NTRK fusions in sarcomas: diagnostic challenges and clinical aspects. *Diagnostics (Basel)* 2021; **11**: 478.
 10. Sand LG, Berghuis D, Szuhai K, Hogendoorn PC. Expression of CCL21 in Ewing sarcoma shows an inverse correlation with metastases and is a candidate target for immunotherapy. *Cancer Immunol. Immunother.* 2016; **65**: 995–1002.
 11. Cleven AH, Hocker S, Briaire-de Bruijn I, Szuhai K, Cleton-Jansen AM, Bovee JV. Mutation analysis of H3F3A and H3F3B as a diagnostic tool for giant cell tumor of bone and chondroblastoma. *Am. J. Surg. Pathol.* 2015; **39**: 1576–1583.
 12. Verbeke SLJ, Bertoni F, Bacchini P *et al.* Distinct histological features characterize primary angiosarcoma of bone. *Histopathology* 2011; **58**: 254–264.
 13. Buddingh EP, Kuijjer ML, Duim RAJ *et al.* Tumor-infiltrating macrophages are associated with metastasis suppression in high-grade osteosarcoma: a rationale for treatment with macrophage activating agents. *Clin. Cancer Res.* 2011; **17**: 2110–2119.
 14. Meijer D, Gelderblom H, Karperien M, Cleton-Jansen AM, Hogendoorn PC, Bovee JV. Expression of aromatase and estrogen receptor alpha in chondrosarcoma, but no beneficial effect of inhibiting estrogen signaling both in vitro and in vivo. *Clin. Sarcoma Res.* 2011; **1**: 5.
 15. Sundara YT, Kostine M, Cleven AH, Bovee JV, Schilham MW, Cleton-Jansen AM. Increased PD-L1 and T-cell infiltration in the presence of HLA class I expression in metastatic high-grade osteosarcoma: a rationale for T-cell-based immunotherapy. *Cancer Immunol. Immunother.* 2017; **66**: 119–128.
 16. Lam SW, Cleven AHG, Kroon HM, Briaire-de Bruijn IH, Szuhai K, Bovée J. Utility of FOS as diagnostic marker for osteoid osteoma and osteoblastoma. *Virchows Arch.* 2020; **476**: 455–463.
 17. Chmielecki J, Bailey M, He J *et al.* Genomic profiling of a large set of diverse pediatric cancers identifies known and novel mutations across tumor spectra. *Cancer Res.* 2017; **77**: 509–519.
 18. Ameline B, Saba KH, Kovac M *et al.* NTRK fusions in osteosarcoma are rare and non-functional events. *J. Pathol. Clin. Res.* 2020; **6**: 107–112.
 19. Solomon JP, Linkov I, Rosado A *et al.* NTRK fusion detection across multiple assays and 33,997 cases: diagnostic implications and pitfalls. *Mod. Pathol.* 2020; **33**: 38–46.
 20. Kao Y-C, Sung Y-S, Argani P *et al.* NTRK3 overexpression in undifferentiated sarcomas with YWHAE and BCOR genetic alterations. *Mod. Pathol.* 2020; **33**: 1341–1349.
 21. van Oosterwijk JG, Meijer D, van Ruler MA *et al.* Screening for potential targets for therapy in mesenchymal, clear cell, and dedifferentiated chondrosarcoma reveals Bcl-2 family members and TGFbeta as potential targets. *Am. J. Pathol.* 2013; **182**: 1347–1356.
 22. Verbeke SLJ, de Jong D, Bertoni F *et al.* Array CGH analysis identifies two distinct subgroups of primary angiosarcoma of bone. *Genes Chromosomes Cancer* 2015; **54**: 72–81.