



Universiteit  
Leiden  
The Netherlands

## **Neuroendocrine neoplasms of the middle ear: unpredictable tumor behavior and tendency for recurrence**

Lans, R.J.L. van der; Engel, M.S.D.; Rijken, J.A.; Hensen, E.F.; Bloemena, E.; Torn, M. van der; ... ; Smit, C.F.G.M.

### **Citation**

Lans, R. J. L. van der, Engel, M. S. D., Rijken, J. A., Hensen, E. F., Bloemena, E., Torn, M. van der, ... Smit, C. F. G. M. (2021). Neuroendocrine neoplasms of the middle ear: unpredictable tumor behavior and tendency for recurrence. *Head And Neck*, 43(6), 1848-1853. doi:10.1002/hed.26658


Version: Publisher's Version

License: [Creative Commons CC BY-NC 4.0 license](https://creativecommons.org/licenses/by-nc/4.0/)

Downloaded from: <https://hdl.handle.net/1887/3279819>

**Note:** To cite this publication please use the final published version (if applicable).

# Neuroendocrine neoplasms of the middle ear: Unpredictable tumor behavior and tendency for recurrence

Rik J. L. van der Lans MD<sup>1</sup> | Michelle S. D. Engel MD<sup>1</sup> |  
 Johannes A. Rijken PhD<sup>2</sup> | Erik F. Hensen PhD<sup>3</sup> | Elisabeth Bloemena PhD<sup>4</sup>  |  
 Marein van der Torn PhD<sup>5</sup> | Charles R. Leemans PhD<sup>1</sup> | Conrad F. G. M. Smit PhD<sup>1</sup>

<sup>1</sup>Department of Otolaryngology – Head and Neck Surgery, Amsterdam UMC, Vrije Universiteit Amsterdam, Amsterdam, The Netherlands

<sup>2</sup>Department of Head and Neck Surgical Oncology, University Medical Center Utrecht Cancer Center, Utrecht, The Netherlands

<sup>3</sup>Department of Otolaryngology – Head and Neck Surgery, Leiden University Medical Center, Leiden, The Netherlands

<sup>4</sup>Department of Pathology, Amsterdam UMC, Vrije Universiteit Amsterdam, Amsterdam, The Netherlands

<sup>5</sup>Department of Otolaryngology, Dijklander Hospital, Hoorn, The Netherlands

## Correspondence

Rik J. L. van der Lans, Department of Otolaryngology – Head and Neck Surgery, Amsterdam UMC, Vrije Universiteit Amsterdam, ZH 1 D 116, Postbus 7057, Amsterdam 1007 MB, The Netherlands. Email: r.vanderlans@amsterdamumc.nl

## Abstract

**Background:** Middle ear adenomatous neuroendocrine tumors (MEANTs) are rare temporal bone tumors. This study evaluates its clinical behavior and therapy outcome.

**Method:** Retrospective case review in a tertiary referral center evaluating histopathology, immunohistochemistry, treatment, and outcome.

**Results:** Nine patients were diagnosed with MEANT. One patient presented with locally invasive tumor and underwent extensive en-bloc tumor resection with adjuvant radiotherapy. Seven of eight patients with locally non-aggressive tumor confined to the tympanomastoid space underwent tumor resection. Two patients were disease-free, five presented recurrence, even after apparent successful surgery. All tumors showed neuroendocrine features. Histopathology and immunohistochemistry did not yield prognostic tumor characteristics.

**Conclusion:** MEANTs are rare tumors with uncertain biological behavior and subsequent unpredictable clinical course. The preferred treatment is complete surgical tumor resection. They have a high tendency for recurrence, irrespective of negative intermediary surgery. As of yet, there are no prognostic biomarkers, including histopathology and immunohistochemistry.

## KEYWORDS

adenoma, carcinoid, mastoid, middle ear, neuroendocrine tumor

## 1 | INTRODUCTION

Middle ear adenomatous neuroendocrine tumors (MEANTs) are rare epithelial-derived adenomatous tumors with neuroendocrine differentiation. Historically, reports of adenomatous tumors of the middle ear date as far back as 1898.<sup>1</sup> In 1976, Hyams et al and Derlacki et al both published on this subject.<sup>2,3</sup> In 1980, Murphy et al

reported on the histochemical and ultrastructural neuroendocrine features, further distinguishing MEANT from other neoplasms of the temporal bone and surrounding structures.<sup>4</sup> Its terminology is still equivocal and comprises (neuroendocrine/amphicrine) adenoma and carcinoid; however, all of these tumors share a common phenotype and immunohistochemical profile.<sup>5-7</sup> In the fourth edition of the WHO Classification of Tumors of

This is an open access article under the terms of the Creative Commons Attribution-NonCommercial License, which permits use, distribution and reproduction in any medium, provided the original work is properly cited and is not used for commercial purposes.

© 2021 The Authors. *Head & Neck* published by Wiley Periodicals LLC.

the Head and Neck, it is featured as *Middle ear adenoma* (ICD-O code: 8140/0). In contrast to other organ systems that may harbor neuroendocrine neoplasms (NENs), epithelial neuroendocrine progenitor cells are not identified in the middle ear. Here, embryologically enclosed pluripotent neural crest cells are the probable derivation.<sup>7</sup> MEANTs are usually indolent tumors restricted to the tympanic cavity, without infiltrative or otherwise aggressive behavior. However, since 1999 some studies have reported malignant behavior and metastasis, both in primary and recurrent tumors.<sup>8,9</sup> Whether this behavior represents separate histopathological entities or reflects a spectrum of disease is not entirely clear. Increasing evidence for the latter is published for NEN in other tracts.<sup>10</sup> As of yet, no reliable histopathological or immunohistochemical predictors of tumor behavior or clinical outcome have been identified.<sup>7</sup> The low incidence and unpredictable biological behavior are reflected in a lack of consensus on diagnostic strategies and follow-up protocols. Surgical resection is the treatment of choice, although the optimal extent remains subject to debate. In this study, we present a single-center experience with nine patients, illustrating the wide spectrum of tumor behavior and clinical course.

## 2 | MATERIALS AND METHODS

Ethics Statement: approval by the institutional Medical Ethics Committee was obtained.

In this retrospective single-center study, patients diagnosed with (neuroendocrine) adenoma, adenocarcinoma, or carcinoid of the temporal bone at Amsterdam UMC, location VUmc, were identified using the Otolaryngology-Head and Neck Surgery and Pathology departmental databases from the date of its inception in 1964 until 2019. Data extraction included patient demographics, presenting symptoms, used imaging modalities, histopathology, immunohistochemistry, treatment, and outcome. Available histopathological slides were retrieved and reviewed by a senior pathologist (EB). Histopathology and immunochemistry of primary and recurrent tumors and metastases were compared. Follow-up duration was defined as the period between histopathologic diagnosis and last outpatient clinic visit. IBM SPSS Statistics version 20.0 was used for data analysis.

## 3 | RESULTS

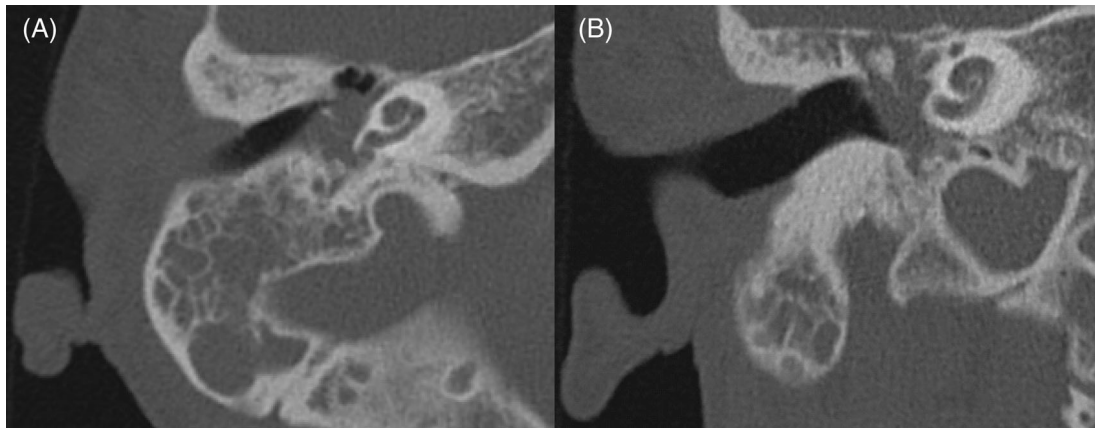
Nine patients with MEANT were identified, the first patient was diagnosed in 1986. All patients were referred after biopsy or (partial) tumor resection elsewhere.

**TABLE 1** Patient characteristics, presenting symptoms, used imaging modalities, follow-up, and outcome of nine patients with middle ear adenomatous neuroendocrine tumor

Sex	Male/female	3/6	
Age at onset	Mean	36	
	Range	24–60	
Presenting symptoms	Hearing loss	9	
	Tinnitus	3	
	Otalgia	2	
	Otorrea	2	
	Aural fullness	1	
	Vertigo	0	
	Facial nerve paresis	1	
Imaging	CT	9	
	MRI	7	
	SPECT	5	
	PET	3	
Follow-up (months)	Mean	155	
	Range	21–381	
Outcome	Malignant (1/9)	Metastatic disease 1/1	
	Benign (8/9)	Refused treatment	1/8
		Disease-free	2/8
		Local recurrence	5/8

Table 1 shows the patient characteristics, presenting symptoms, imaging modalities, follow-up and outcome. CT and/or MR imaging was used to evaluate the extent of disease. Figure 1 shows CT-scan images of a non-aggressive middle ear adenomatous tumor of the temporal bone (patient 8; T2bN0M0S0<sup>11</sup>). PET and SPECT scans were used to evaluate concurrent neuroendocrine neoplasms and metastasis at presentation. Median follow-up duration was 163 months (mean: 165; range: 33–381 months). In Table 2, we present the clinical course of the individual MEANT patients, including the surgical procedures and characteristics of the primary and recurrent tumors, alongside the TNMS-classification of the primary tumor as proposed by Marinelli et al.<sup>11</sup> The primary surgical procedure for resection comprised tympanotomy in four (44%) patients and canal wall up procedure in five (56%) patients.

One patient (1/9; patient 7) was seen with an infiltrative tumor and will be discussed later. Eight patients (8/9) presented with non-aggressive tumor. One patient (1/8; patient 4), with biopsy-proven local recurrence 13 years after incomplete resection elsewhere, refrained from further surgical treatment, but clinical follow-up has been continued. The other seven patients (7/8)



**FIGURE 1** CT images of the right temporal bone of a patient with non-aggressive middle ear adenomatous neuroendocrine tumor (patient 8). (A) Axial view with complete opacification of the mastoid process with intact septae, subtotal opacification of the mesotympanum, bulging intact tympanic membrane, and no bony erosion. (B) Coronal view with complete opacification of the mastoid process with intact septae, complete opacification of the tympanic cavity with intact scutum, intact ossicular chain, intact tympanic membrane, and no bony erosion

underwent additional surgical procedures in our center (Table 2).

Two patients (2/7) were disease-free at the end of the study period (patients 8 and 9; FU 96 and 177 months). Five patients (5/7) had one or more recurrences, of which patients 1 and 3 are most noteworthy. Patient 1 underwent diagnostic revision tympanotomy 10 months after the third procedure and appeared microscopically disease-free, including negative biopsies. However, recurrence manifested 15 months later. Ensuing revision procedures after 12 and 11 months, respectively, revealed residue again. Patient 3 appeared disease-free at the third and fourth procedures, including negative biopsies (FU 7 and 32 months). Even so, a recurrence manifested 142 months after the last procedure in which MEANT was found. Tympanomastoidectomy 16 months after microscopic re-excision showed recurrence again, which was resected. Both patients 1 and 3 will undergo protocolled surgery after 1 year.

In patient 6, concurrent cholesteatoma was removed during the fourth procedure, necessitating a canal wall down mastoidectomy. Resection of a small recurrence was performed 29 months later. After a long interval of 150 months with no signs of recurrence at the outpatient clinic, a small cystic lesion was resected from the mastoid cavity. This proved to be a small cholesterol granuloma; no recurrence of MEANT was encountered.

Patient 7 manifested with steroid-responsive facial nerve paresis. Diagnostic work-up revealed an infiltrative tumor, affecting the tympanomastoid segment of

the facial nerve and the midcranial fossa tegmen, without intracranial extension. Biopsy showed adenocarcinoma. Nuclear imaging was negative for metastasis and concurrent tumor. Extensive en-bloc tumor resection was performed, consisting of a subtotal temporal bone resection (STBR), including resection of the mandibular condyle and facial nerve trunk in the stylomastoid foramen, superficial parotidectomy, and selective neck dissection levels I-III. A hypoglossal-facial nerve interpositional-jump graft was used for facial nerve reconstruction and the residual cavity was obliterated with abdominal fat and temporalis muscle flap. Histopathology showed infiltrative tumor with positive resection margins at the infratemporal bone and midcranial fossa dura. Post-operative adjuvant radiotherapy consisted of 46Gy with an additional 20Gy-boost on the infratemporal region. After 6 years of follow-up, hepatic and bone metastasis occurred (T1-2 and L1, ilium, acetabulum, ischium). The metastases corresponded histopathologically with the preceding primary temporal bone tumor and showed neuroendocrine characteristics on immunohistochemistry. Additional immunohistochemical analysis now revealed the primary tumor to be neuroendocrine, expressing synaptophysin and chromogranin A. Long-acting release octreotide treatment (OCT-LAR) ensued and two large liver metastases were embolized. Progressive liver metastases and rising chromogranin-B levels indicated OCT-LAR refractory disease. The patient was referred for Peptide Radionuclide Receptor Therapy (PRRT), which outcome cannot yet be evaluated.

All tumors were synaptophysin and/or chromagranin A positive. No morphological or immunohistochemical differences were found between primary tumors, recurrences,

and metastases, except for the local infiltration of the primary tumor in patient 7. No significant difference in mitotic count and proliferation rate, as evaluated by Ki-67

**TABLE 2** Surgical procedure, characteristics of primary tumor, and recurrences and TNMS-classification<sup>a</sup> of nine patients with middle ear adenomatous neuroendocrine tumor

Patient no. Year of diagnosis	Interval (months)	Procedure	Tumor extent	Multifocal recurrence <sup>b</sup>	Structures involved	Concurrent pathology	T	N	M	S
1 2007	0	Ty	ME, EAC	n/a	TM, ChT		2c	0	0	0
	2	CWU, PT, PORP	ME	yes	I, S					
	106	CWU, PT	ME, EAC	no	TM, M, PORP, S					
	116	CWU, PT, PORP	c	c	c					
	131	eTy	ME	yes	S					
	143	CWU, PT	ME, MP, tuba	yes	TM, M					
	154	CWU, PT	ME	yes	n/a					
2 2004	0	biopsy EAC	ME, EAC	n/a	TM		2c	0	0	0
	5	rTy	ME	n/a	TM, M					
	166	rTy	ME, tuba	no	ChT, M, I, S					
	178	rTy	c	c	c					
3 2005	0	CWU	ME	n/a	M, I		2a	0	0	0
	3	CWU	ME	no	M, I, S					
	10	CWU	c	c	c					
	35	rTy, PORP	c	c	c					
	152	rTy	ME	no	S					
	168	CWU, PT	MP	yes	n/a					
4 2005	0	eTy	ME	n/a	M, I, S		2a	0	0	0
5 2017	0	eTy	ME	n/a	S		2a	0	0	0
	4	CWU, PT	ME	no	ChT, M, I, S					
	16	CWU, PT	ME	yes	n/a					
	31	CWU, PT	ME, MP	yes	n/a					
6 1986	0	CWU	N/A	n/a	n/a		2a	0	0	0
	2	eTy	ME	no	M, I, S					
	4	CWU	ME, MP	no	M, I, S					
	55	CWD	ME	no	M	Cholesteatoma				
	84	CWD	ME	no	S					
	234	CWD	c	c	c	Cholesterol granuloma				
7 2010	0	CWU	ME, MP	n/a	n/a		3	0	0	0
	1	See Results in main text for description								
8 2012	0	CWU	ME, MP	n/a	M, I, S		2b	0	0	0
	5	CWU, PT	c	c	c					
	18	Ty, PORP	c	c	c					

(Continues)

TABLE 2 (Continued)

Patient no.	Year of diagnosis	Interval (months)	Procedure	Tumor extent	Multifocal recurrence <sup>b</sup>	Structures involved	Concurrent pathology	T	N	M	S
9 2005	0		ME biopsy	ME	n/a	n/a		2b	0	0	0
	3		CWU, PT	ME, MP	n/a	TM, M, I, S					
	15		CWU, PT	c	c	c	Inclusion cholesteatoma				
	39		eTy, PORP	c	c	c					
	50		eTy, PORP	c	c	c					
	69		eTy	c	c	c					

<sup>a</sup>TNMS-classification for primary tumor as proposed by Marinelli et al<sup>11</sup>.

<sup>b</sup>Multifocal recurrence defined as non-continuous tumor in multiple locations.

<sup>c</sup>No recurrence.

Abbreviations: ChT, tympanic chorda; CWD, canal wall down procedure; CWU, canal wall up procedure; eTy, endaural tympanotomy; I, incus; M, malleus; ME, middle ear; MP, mastoid process; n/a, not applicable; PORP, partial ossicular replacement prosthesis; PT, posterior tympanotomy; rTy, retro-auricular tympanotomy; S, stapes; TM, tympanic membrane; Ty, tympanotomy.

and/or MIB-1 immunostaining, was found and tumor necrosis was not encountered (data not shown).

## 4 | DISCUSSION

Our single-center experience with nine MEANT patients illustrates an unpredictable tumor behavior, a high tendency for recurrence and lack of predictive histopathological/immunohistochemical biomarkers. Five (71%) out of seven patients treated for locally, non-aggressive MEANT developed a recurrence. Previous studies report recurrence rates between 13% and 22%. However, the follow-up duration in these reports was generally short, often not exceeding 24 months.<sup>5,9,12</sup> Since 1999, reports of aggressive local behavior and metastasis of MEANT have been published, both in primary and recurrent tumors. Concurrently, increased awareness of its potential for long-term recurrence arose, which can be up to 33 years due to its general indolent nature.<sup>7-9</sup> Therefore, the risk of recurrence has probably been underestimated previously.<sup>12</sup> In our study, multiple recurrences were found, even in patients who were apparently disease-free during (sequential) preceding surgery (patients 1 and 3). Aware of our studies' preliminary findings, three asymptomatic patients underwent a second look tympanotomy (2018–2019). All three had (microscopic) growth of residual disease (patients 1, 3, and 5 after 17, 16, and 12 months, respectively).

In general, NEN behaves notoriously unpredictably. Organ-specific grading schemes have aided in stratifying relative aggressiveness in other organ systems, where a dichotomous subdivision is made into NET and NEC (Neuro Endocrine Tumor and Carcinoma, respectively;

the former with site-specific grading). This subdivision is supported by clinical, epidemiological, and histological differences, as well as genetic evidence at specific anatomic sites.<sup>10</sup> An equivalent prediction model would be desirable for MEANT. However, the clinical parameters that have prognostic value in other NEN types are insufficiently investigated in MEANT or do not seem to predict the clinical outcome. Useful biomarkers for NEN in other organ systems, such as morphology and Ki-67, also do not seem to be associated with the clinical course or outcome in MEANT. As a result, there is currently no MEANT-specific grading system. In 2018, Marinelli et al proposed a TNMS-staging system describing tumor extension and dissemination (S for neuroendocrine secretion).<sup>11</sup> Its feasibility has yet to be evaluated.

Because of the high recurrence rate, unpredictable tumor behavior, and potential malignant transformation, complete initial surgical tumor resection is essential. For non-infiltrative MEANT confined to the tympanomastoid space, the surgical approach should enable complete tumor removal. Ossiculectomy may benefit outcome.<sup>12</sup> When affected by tumor, the chorda tympani should be included in the resection. More widespread or aggressive disease warrants more extensive surgical resection, with consequent morbidity; similar considerations apply for local recurrence. The value of radio-/chemotherapy, somatostatin analogues, and PRRT in MEANT is yet unascertained.<sup>9,11</sup> Current studies advocate long-term follow-up, irrespective of tumor characteristics at presentation, in order to facilitate early detection of recurrent disease.<sup>6-9,11,12</sup> This study, nor the literature, provides sufficient information to define specific follow-up protocols. The role and timing of both morphological and functional imaging have yet to be elucidated. We perform a

revision tympanomastoidectomy 1 year after primary tumor resection. If no recurrence is found, outpatient clinic follow-up with micro-otoscopy ensues, supported by CT or MRI. Tympanotomy is performed when recurrence is suspected. Prospective studies are needed to further clarify tumor behavior and optimize diagnostic, treatment, and follow-up strategies.

## 5 | CONCLUSION

Middle ear adenomatous neuroendocrine tumors are rare tumors with an elusive etiology, uncertain biological behavior, and subsequent unpredictable clinical course. The treatment of choice is complete surgical tumor resection. It has a high tendency for recurrence on the short term and long term, even after apparent successful surgery. Their malignant potential manifests in both primary aggressive local behavior with or without metastasis and malignant transformation in recurrent disease. There are no prognostic biomarkers as of yet, including histopathology and immunohistochemistry. Therefore, current studies advocate long-term follow-up.

### DATA AVAILABILITY STATEMENT

The data that support the findings of this study are available on request from the corresponding author. The data are not publicly available due to privacy or ethical restrictions.

### ORCID

Elisabeth Bloemena  <https://orcid.org/0000-0002-0221-9538>

### REFERENCES

- Treitel L. Über das Karzinom des Ohres. *Z Ohrenheilk.* 1898;33: 152-164.
- Hyams VJ, Michaels L. Benign adenomatous neoplasm (adenoma) of the middle ear. *Clin Otolaryngol.* 1976;1(1):17-26. <https://doi.org/10.1111/j.1365-2273.1976.tb00637.x>.
- Derlacki EL, Barney PL. Adenomatous tumors of the middle ear and mastoid. *Laryngoscope.* 1976;86(8):1123-1135. <https://doi.org/10.1288/00005537-197608000-00004>.
- Murphy GF, Pilch BZ, Dickersin GR, Goodman ML, Nadol JBJ. Carcinoid tumor of the middle ear. *Am J Clin Pathol.* 1980;73(6):816-823. <https://doi.org/10.1093/ajcp/73.6.816>.
- Torske KR, Thompson LDR. Adenoma versus carcinoid tumor of the middle ear: a study of 48 cases and review of the literature. *Mod Pathol.* 2002;15(5):543-555. <https://doi.org/10.1038/modpathol.3880561>.
- Agaimy A, Lell M, Schaller T, Mäarkl B, Hornung J. "Neuroendocrine" middle ear adenomas: consistent expression of the transcription factor ISL1 further supports their neuroendocrine derivation. *Histopathology.* 2015;66(2):182-191. <https://doi.org/10.1111/his.12447>.
- Bell D, El-Naggar A, Gidley P. Middle ear adenomatous neuroendocrine tumors: a 25-year experience at MD Anderson Cancer Center. *Virchows Arch.* 2017;471:667-672. <https://doi.org/10.1007/s00428-017-2155-6>.
- Mooney EE, Dodd LG, Oury TD, Burchette JL, Layfield LJ, Scher RL. Middle ear carcinoid: an indolent tumor with metastatic potential. *Head Neck.* 1999;21(1):72-77. [https://doi.org/10.1002/\(sici\)1097-0347\(199901\)21:1<72::aid-hed10>3.0.co;2-g](https://doi.org/10.1002/(sici)1097-0347(199901)21:1<72::aid-hed10>3.0.co;2-g).
- Ramsey MJ, Nadol JBJ, Pilch BZ, McKenna MJ. Carcinoid tumor of the middle ear: clinical features, recurrences, and metastases. *Laryngoscope.* 2005;115(9):1660-1666. <https://doi.org/10.1097/01.mlg.0000175069.13685.37>.
- Rindi G, Klimstra DS, Abedi-Ardekani B, et al. A common classification framework for neuroendocrine neoplasms: an International Agency for Research on Cancer (IARC) and World Health Organization (WHO) expert consensus proposal. *Mod Pathol.* 2017;31(12):1770-1786. <https://doi.org/10.1038/s41379-018-0110-y>.
- Marinelli JP, Cass SP, Mann SE, et al. Adenomatous neuroendocrine tumors of the middle ear. *Otol Neurotol.* 2018;39(8): e712-e721. <https://doi.org/10.1097/MAO.0000000000001905>.
- Saliba I, Evrard A-S. Middle ear glandular neoplasms: adenoma, carcinoma or adenoma with neuroendocrine differentiation: a case series. *Cases J.* 2009;2(3):6508. <https://doi.org/10.1186/1757-1626-2-6508>.

**How to cite this article:** van der Lans RJL, Engel MSD, Rijken JA, et al. Neuroendocrine neoplasms of the middle ear: Unpredictable tumor behavior and tendency for recurrence. *Head & Neck.* 2021;43:1848–1853. <https://doi.org/10.1002/hed.26658>