



**Universiteit  
Leiden**  
The Netherlands

**Neoadjuvant cytoreductive treatment with BRAF/MEK inhibition of prior unresectable regionally advanced melanoma to allow complete surgical resection, REDUCTOR: a prospective, single-arm, open-label phase II trial**

Blankenstein, S.A.; Rohaan, M.W.; Klop, W.M.C.; Hiel, B. van der; Wiel, B.A. van de; Lahaye, M.J.; ... ; Haanen, J.B.A.G.

**Citation**

Blankenstein, S. A., Rohaan, M. W., Klop, W. M. C., Hiel, B. van der, Wiel, B. A. van de, Lahaye, M. J., ... Haanen, J. B. A. G. (2021). Neoadjuvant cytoreductive treatment with BRAF/MEK inhibition of prior unresectable regionally advanced melanoma to allow complete surgical resection, REDUCTOR: a prospective, single-arm, open-label phase II trial. *Annals Of Surgery*, 274(2), 383-389. doi:10.1097/SLA.0000000000004893

Version: Publisher's Version  
License: [Creative Commons CC BY-NC-ND 4.0 license](https://creativecommons.org/licenses/by-nc-nd/4.0/)  
Downloaded from: <https://hdl.handle.net/1887/3276162>

**Note:** To cite this publication please use the final published version (if applicable).

# Neoadjuvant Cytoreductive Treatment With *BRAF/MEK* Inhibition of Prior Unresectable Regionally Advanced Melanoma to Allow Complete Surgical Resection, REDUCTOR

## *A Prospective, Single-arm, Open-label Phase II Trial*

Stéphanie A. Blankenstein, MD,\* Maartje W. Rohaan, MD,† Willem Martin C. Klop, MD, PhD,‡  
Bernies van der Hiel, MD,§ Bart A. van de Wiel, MD,¶ Max J. Lahaye, MD, PhD,|| Sandra Adriaansz, MS,†  
Karolina Sikorska, PhD,\*\* Harm van Tinteren, PhD,†† Aysegül Sari, BS,\*\*  
Lindsay G. Grijpink-Ongering, BS,\*\* Winan J. van Houdt, MD, PhD,\* Michel W. J. M. Wouters, MD, PhD,\*‡‡  
Christian U. Blank, MD, PhD,† Sofie Wilgenhof, MD, PhD,† Johannes V. van Thienen, MD, PhD,†  
Alexander C. J. van Akkooi, MD, PhD,\* and John B. A. G. Haanen, MD, PhD†✉

**Objective:** To evaluate the potency of short-term neoadjuvant cytoreductive therapy with dabrafenib plus trametinib (*BRAF* and *MEK* inhibitor) to allow for radical surgical resection in patients with unresectable locally advanced melanoma.

From the \*Department of Surgical Oncology, Netherlands Cancer Institute, Amsterdam, the Netherlands; †Department of Medical Oncology, Netherlands Cancer Institute, Amsterdam, the Netherlands; ‡Department of Head and Neck Surgery and Oncology, Netherlands Cancer Institute, Amsterdam, the Netherlands; §Department of Nuclear Medicine, Netherlands Cancer Institute, Amsterdam, the Netherlands; ¶Department of Pathology, Netherlands Cancer Institute, Amsterdam, the Netherlands; ||Department of Radiology, Netherlands Cancer Institute, Amsterdam, the Netherlands; \*\*Department of Biometrics, Netherlands Cancer Institute, Amsterdam, the Netherlands; ††Department of Biometrics, Princes Máxima Centrum, Utrecht, the Netherlands; and ‡‡Department of Biomedical Data Sciences, Leiden University Medical Center, Leiden, the Netherlands.

✉e-mail: j.haanen@nki.nl.

S.A.B. and M.W.R. contributed equally to this work.

This is an investigator-initiated study, funded by GlaxoSmithKline/Novartis.

**Author contributions:** SB and MR shared first authorship and contributed equally to this article. HvT, AvA, and JH made substantial contribution to the conception and design of the study. SB, MR, WK, BvdH, BvdW, ML, SA, AS, LG, WvH, MW, CB, SW, JvT, AvA, and JH contributed to data acquisition. Analysis and interpretation of the data were performed by SB, MR, BvdH, KS, HvT, AvA, and JH. All authors participated in writing the manuscript and/or critical revision of the manuscript. All authors gave final approval of the publishable version of the manuscript.

Through WvH, NKI has received compensation for advisory roles from Amgen, Belpharma, Sanofi. CB has received research funding from BMS, Novartis, and NanoString; has an advisory role for BMS, MSD, Roche, Novartis, GSK, AZ, Pfizer, Lilly, GenMab, Pierre Fabre, and Third Rock Ventures, is a stock owner of Uniti Cars, Neon Therapeutics, and Forty Seven, and is stockowner and co-founder of Immagine BV. Through JvT, the NKI has received compensation for advisory roles from Pfizer, MSD, BMS and has received compensation for travel expenses from Roche. Through AvA, NKI has received compensation for advisory roles from Amgen, BMS, Novartis, MSD-Merck, Merck-Pfizer, Sanofi, and 4SC, and NKI has received grants from Amgen, BMS, and Novartis. JH performed advisory roles from Achilles Therapeutics, Aimm, BioNTech US, BMS, Gadeta, Immunocore, Ipsen, MSD, Merck Serono, Molecular Partners, Neogene Therapeutics, Novartis, Pfizer, Roche/Genentech, Sanofi, Seattle Genetics, Third Rock Ventures, T-knife, and NKI has received grants from Amgen, BioNTech, BMS, MSD, Novartis. All the other authors report no conflicts of interest.

This is an open access article distributed under the terms of the Creative Commons Attribution-Non Commercial-No Derivatives License 4.0 (CCBY-NC-ND), where it is permissible to download and share the work provided it is properly cited. The work cannot be changed in any way or used commercially without permission from the journal.

Copyright © 2021 The Author(s). Published by Wolters Kluwer Health, Inc.

ISSN: 0003-4932/21/27402-0383

DOI: 10.1097/SLA.00000000000004893

**Summary Background Data:** Approximately 5% of stage III melanoma patients presents with unresectable locally advanced disease, making standard of care with resection followed by adjuvant systemic therapy impossible. Although neoadjuvant targeted therapy has shown promising results in resectable stage III melanoma, its potency to enable surgical resection in patients with primarily unresectable locally advanced stage III melanoma is still unclear.

**Methods:** In this prospective, single-arm, phase II trial, patients with unresectable *BRAF*-mutated locally advanced stage IIIC or oligometastatic stage IV melanoma were included. After 8 weeks of treatment with dabrafenib and trametinib, evaluation by positron emission tomography/computed tomography and physical examination were used to assess sufficient downsizing of the tumor to enable resection. The primary objective was the percentage of patients who achieved a radical (R0) resection.

**Results:** Between August 2014 and March 2019, 21 patients (20/21 stage IIIC American Joint Committee on Cancer staging manual 7th edition) were included. Planned inclusion of 25 patients was not reached due to slow accrual and changing treatment landscape. Despite this, the predefined endpoint was successfully met. In 18/21 (86%) patients a resection was performed, of which 17 were R0 resections. At a median follow-up of 50 months (interquartile range 37.7–57.1 months), median recurrence-free survival was 9.9 months (95% confidence interval 7.52-not reached) in patients undergoing surgery.

**Conclusions:** This prospective, single-arm, open-label phase II trial, shows neoadjuvant dabrafenib plus trametinib as a potent cytoreductive treatment, allowing radical resection of metastases in 17/21 (81%) patients with prior unresectable locally advanced melanoma.

**Keywords:** *BRAF* mutation, melanoma, neoadjuvant, surgery, unresectable (*Ann Surg* 2021;274:383–389)

Historically, the standard of care for macroscopic regional metastatic melanoma has been complete surgical resection of lymph node metastases. However, approximately 5% of patients presents with unresectable locally advanced disease with very bulky lymph node metastases or in-transit metastases, making a complete (R0) resection unfeasible. These patients are currently given the same treatment as patients with stage IV disease and subsequently have a similar prognosis.<sup>1</sup>

The systemic treatment of patients with unresectable stage III and IV melanoma has evolved drastically over the past decade with the development of both immune checkpoint inhibitors (ICIs) and targeted therapy. In metastatic melanoma, targeting the mitogen-activated protein kinase (MAPK)-pathway with *BRAF* plus *MEK* inhibitors (*BRAF/MEKi*) has proven to be successful in patients with

*BRAF*-mutated melanoma.<sup>2–5</sup> Compared to ICI, treatment with *BRAF/MEK*i shows higher response rates (up to 68% vs up to 59% with the combination ICI of nivolumab and ipilimumab), but most patients acquire resistance in due course (5-year progression-free survival (PFS) of 19% vs 36%).<sup>4–14</sup>

Indications for these systemic therapies are broadening, since treatment in the adjuvant setting has recently become the standard of care for patients with resectable stage III melanoma, who have a substantial risk of recurrence after resection.<sup>1,15,16</sup> Both adjuvant nivolumab or pembrolizumab, and adjuvant *BRAF/MEK*i were shown to improve the recurrence-free survival (RFS) in this patient population.<sup>17–19</sup> This treatment regimen is not feasible in patients with unresectable locally advanced melanoma, however, systemic therapy could possibly enable a complete resection when given in a neoadjuvant, cytoreductive setting. ICI and *BRAF/MEK*i have recently been demonstrated to downsize resectable stage III melanoma substantially, with very impressive major pathological responses, including complete remissions in only a very short period of time (6–12 weeks).<sup>20,21</sup> Yet no data are available for patients with primarily unresectable stage IIIC disease. For such patients with *BRAF* V600 mutated melanoma, the *BRAF/MEK*i combination may be suitable to enable enough downsizing to allow R0 resection, given the high response rate and short time to response.

Similar to unresectable stage IIIC melanoma, systemic therapy is the first choice of treatment in most stage IV melanoma patients. However, in patients with oligometastatic stage IV melanoma ( $\leq 3$  metastatic lesions), surgical resection could be a potential curative approach for a minority of patients.<sup>22,23</sup> Nowadays, these patients are also eligible for adjuvant systemic therapy with nivolumab.<sup>17</sup> Neoadjuvant treatment in these patients may also reduce the development of new metastatic lesions from undetected micrometastatic disease.<sup>1</sup>

The aim of this prospective, single arm, open-label phase II study is to evaluate the potency of short-term neoadjuvant cytoreductive therapy with dabrafenib plus trametinib (*BRAF* and *MEK* inhibitor, respectively) to allow for radical surgical resection in patients with unresectable and *BRAF*-mutated, locally advanced stage III or oligometastatic stage IV melanoma.

## PATIENTS AND METHODS

### Study Design and Population

This study was designed as a prospective, single-arm, phase II trial including 25 patients when at least four of the first 14 included patients would respond to the neoadjuvant treatment. The study was approved by the ethics committee of the Netherlands Cancer Institute (NKI, EudraCT number 2013-002616-28) and all participants provided written informed consent. The trial was conducted according to the principles of the Declaration of Helsinki and the Medical Research Involving Human Subjects Act (WMO). Patients were enrolled and treated at the Departments of Medical and Surgical Oncology at NKI (Amsterdam, The Netherlands).

Patients with unresectable *BRAF*-mutated stage IIIC melanoma or stage IV melanoma with  $\leq 3$  metastases, in which surgery alone was deemed not to be a feasible treatment option, were eligible for this trial. As official criteria for unresectability have not yet been defined, it is therefore considered as the result of a multisurgeon decision during multidisciplinary melanoma meetings. Reasons to designate metastases as “unresectable” were major nerve or vascular involvement (requiring vascular resection or reconstruction); requiring extensive skin or soft tissue resection with complex reconstructions; affected lymph nodes beyond the conventional margins of a complete lymphadenectomy; recurrence in a previously operated area (with possible difficulty in accessibility). Staging was performed according to the 7th edition of the melanoma American

Joint Committee on Cancer staging manual (AJCC 7th).<sup>24</sup> Pathologic confirmation of cutaneous melanoma harboring a *BRAF* V600E or -K mutation was required. Also, patients had to be treatment naïve for this disease stage and the intended operation should be considered to offer a chance of cure or substantial palliation. Other main inclusion criteria were: patients of  $\geq 18$  years of age; WHO performance status of 0 or 1; evaluable lesions on computed tomography (CT), magnetic resonance imaging, or positron emission tomography (PET)/CT; and adequate organ functions. Main exclusion criteria were presence of central nervous system metastases; major surgery, radiotherapy or systemic therapy in the four weeks before inclusion; pregnancy or lactation; known Human Immunodeficiency Virus (HIV), Hepatitis B or C infection; and cardiac abnormalities.

### Treatment and Procedures

All patients underwent 18F-Fluorodeoxyglucose (18F-FDG) PET/CT and magnetic resonance imaging of the brain as baseline measurements. Neoadjuvant treatment consisted of dabrafenib 150 mg twice daily and trametinib 2 mg once daily for a period of 8 weeks. Evaluation was performed with physical examination by the surgeon after 4 and 8 weeks and with PET/CT after 2 and 8 weeks of treatment. If the tumor had been downsized sufficiently (as defined by a multidisciplinary board) and no new lesions had occurred, the operation was performed within the next 2 to 3 weeks. In this period the dabrafenib and trametinib were continued. If the tumor was still deemed unresectable, treatment with *BRAF/MEK*i was continued until progressive disease or intolerable toxicity.

### Outcomes

The primary endpoint of this study was the percentage of patients for whom a radical (R0) resection was achieved, defined as tumor-free margins of the resection specimen, confirmed by an expert pathologist. The evaluation of tumor-free margins was considered an important issue, as patients may present with bulky matted node conglomerates. Pathologic responses were assessed using the consensus guidelines of the International Neoadjuvant Melanoma Consortium (INMC), using the percentage of tumor bed occupied by viable tumor cells.<sup>25</sup> Secondary endpoints were RFS, PFS, and overall survival (OS). RFS was calculated in patients undergoing a resection, defined as the time between surgery and time of first PD. In all patients, PFS was determined as the interval between the date of first administration of *BRAF/MEK*i and the time of PD or time of death due to any cause. The time of PD is defined as the date of radiological PD scored on imaging data according to Response Evaluation Criteria in Solid Tumors (RECIST) version 1.1.<sup>26</sup> OS is defined as the time between the date of first administration of *BRAF/MEK*i and date of death due to any cause. Patients not experiencing an event will be censored at the day of last contact. Metabolic response rates were evaluated on 18F-FDG PET/CT according to response criteria of the European Organization for Research and Treatment of Cancer (EORTC), and PET Response Criteria in Solid Tumors (PERCIST).<sup>27,28</sup> Radiologic response rates were evaluated on (low dose) CT following RECIST 1.1.

Additionally, adverse events (AE) were evaluated by the investigators during the study according to the National Cancer Institute's Terminology Criteria for Adverse Events version 4.03 (NCI-CTCAE v.4.03). New AEs were registered from the moment of signing informed consent until 30 days after the last study intervention and all existing AEs were followed-up until recovery or baseline levels. Only clinically significant laboratory abnormalities were reported (grade  $\geq 3$ ).

### Statistical Analyses

The hypothesis is that if downsizing by dabrafenib and trametinib treatment results in an R0 resection in 45% or more

patients, the treatment modality is considered effective (alternative hypothesis). An R0 resection in 20% or less patients is considered futile (null hypothesis). The sample size was calculated using the Simon optimal 2-stage method using an alpha of 0.1 and beta of 10% (power 90%).<sup>29</sup> The first stage would include 14 patients and the trial continued to the second stage, with 25 patients enrolled in total, if an R0 resection was achieved in at least four patients. Statistical analyses were performed using R version 3.5.1. Descriptive statistics were used to describe baseline patient and tumor characteristics; AE; responses; and recurrences. Survival endpoints (RFS, PFS, and OS) were analyzed using Kaplan-Meier estimates and medians were presented with 95% CI.

## RESULTS

### Patient and Treatment Characteristics

Between August 2014 and March 2019 a total of 21 patients were included in this study. After inclusion of the first 14 patients, sufficient downsizing of the tumor was seen in 10 patients and the trial proceeded. However, inclusion was ceased before reaching the predefined total of 25 patients due to slow accrual rate, changing treatment landscape in the running time of the trial and results that could not fail to meet the predefined endpoints anymore, as further elucidated in the discussion section. Baseline characteristics of the 21 included patients are summarized in Table 1. All but one patient (95%) had unresectable stage IIIC disease at the time of inclusion. A large proportion (43%) of the included patients had a melanoma of unknown primary (MUP).

All patients completed treatment with neoadjuvant *BRAF/MEK*i for eight weeks, although in six patients a short interruption was necessary due to toxicity (median four days (range 1–18 days).

### Clinical Responses

After eight weeks of treatment, two patients had experienced PD as detected on PET/CT, both of whom developed distant metastases during the neoadjuvant treatment period. In one of these patients, an axillary lymph node dissection (LND) was performed for palliative reasons and to obtain local control, as the initial lymph node metastases had responded and became resectable, despite the development of new distant lesions. Sufficient downsizing of the tumor was seen in the remaining 19 patients and all of these proceeded to surgery. Matted node conglomerates were not used as RECIST measurable target lesions due to the risk of inconsistency of the measurements. The mean baseline measurement of the largest nodal lesions was 8 cm (range 3.4–14.6 cm), with a mean reduction of 3.2 cm (range 0.1–8.3 cm) after 8 weeks of neoadjuvant treatment. Despite significant downsizing, in 1 patient, the tumor was still deemed unresectable during surgery due to encasement of the iliac artery and vein. Therefore, in 18/21 patients (86%) a complete macroscopic resection could be performed.

Table 2 shows radiologic and metabolic responses after eight weeks. According to RECIST, most patients (76.2%) had a partial response (PR) on CT and one patient had a radiologic complete response (CR). Metabolic responses according to EORTC and PERCIST were comparable in all patients but one, predominantly revealing a partial metabolic response (PMR, 61.9% PERCIST). This one patient with a different EORTC and PERCIST response showed stable disease (SD) according to PERCIST, but PMR when using EORTC. Four patients (19.0%) had a complete metabolic response (CMR).

### Surgical and Pathological Outcomes

Since the vast majority of patients in this trial had locally advanced stage III melanoma, surgery primarily consisted of a LND. In all patients, regardless of the radiologic response, a complete

TABLE 1. Baseline Characteristics

Characteristic	n	%
Age, yr		
Median	53	
Range	25–76	
Sex		
Female	10	48.0%
Male	11	52.0%
WHO performance status		
0	20	95.2%
1	1	4.8%
2	0	0.0%
3	0	0.0%
Disease stage (AJCC 7th edition)		
IIIC	20	95.2%
IV	1	4.8%
Location primary melanoma		
Extremity	7	33.3%
Trunk	5	23.8%
Head and neck	0	0.0%
Unknown primary	9	42.9%
Type		
Superficial spreading	5	23.8%
Nodular	3	14.3%
Acral lentiginous	2	9.5%
Lentigo maligna	0	0.0%
Desmoplastic	0	0.0%
Unknown primary	9	42.9%
Unknown	2	9.5%
Breslow thickness		
≤1.0 mm	0	0.0%
1.01–2.0 mm	6	28.6%
2.01–4.0 mm	2	9.5%
>4.0 mm	2	9.5%
Unknown primary	9	42.9%
Unknown	2	9.5%
Ulceration		
Yes	2	9.5%
No	10	47.6%
Unknown primary	9	42.9%
Site locoregional metastases		
Axillary LN	10	47.6%
Axillary and cervical LN	5	23.8%
Inguinal LN	0	0.0%
Iliac LN	3	14.3%
Inguinal and iliac LN	3	14.3%
<i>BRAF</i> -mutation		
V600E	20	95.2%
V600K	1	4.8%
LDH		
≤ULN	11	52.4%
>ULN	9	42.9%
Unknown	1	4.8%

AJCC indicates American Joint Committee on Cancer staging manual; LDH, lactatedehydrogenase; LN, lymph node; ULN, upper limit of normal.

lymphadenectomy of the affected nodal basin was performed and sometimes this was extended outside the normal borders of a lymphadenectomy. A median of 24 (IQR 16–37) lymph nodes was resected, with a median of 22 (IQR 18–41), 41 (IQR 29–56), and 14 (IQR 6–24) lymph nodes resected in the performed axillary, axillary plus cervical, and iliac (±inguinal) LND, respectively. In 13 (72%) patients an axillary LND was performed, in four patients this procedure was combined with a resection of either supraclavicular or cervical lymph nodes. Five (28%) patients underwent an extensive superficial (inguinal-femoral) and deep (iliac-obturator) groin LND. In the patient with stage IV disease at

**TABLE 2. Response and Surgery**

Response	N	%
<b>Radiologic response</b>		
Complete response	1	4.8%
Partial response	16	76.2%
Stable disease	1	4.8%
Progressive disease	2	9.5%
Missing*	1	4.8%
<b>Metabolic response EORTC criteria</b>		
Complete metabolic response	4	19.0%
Partial metabolic response	14	66.7%
Stable metabolic disease	0	0.0%
Progressive metabolic disease	2	9.5%
Missing*	1	4.8%
<b>Metabolic response PERCIST</b>		
Complete metabolic response	4	19.0%
Partial metabolic response	13	61.9%
Stable metabolic disease	1	4.8%
Progressive metabolic disease	2	9.5%
Missing*	1	4.8%
<b>Pathologic response</b>		
Pathologic complete response	6	28.6%
Pathologic near complete response	3	14.3%
Pathologic partial response	4	19.0%
Pathologic non response	5	23.8%
N.A.	3	14.3%
<b>Radical excision</b>		
R0	17	81.0%
R1	1	4.8%
R2	0	0.0%
N.A.	3	14.3%

\*In one patient lesions did not meet RECIST 1.1 criteria, additionally PERCIST and EORTC could not be assessed in this patient due to an incompatible FDG-PET at baseline. N.A.; not applicable; R0, radical resection; R1 tumor positive microscopic resection margins; R2, macroscopic residual tumor.

inclusion, an iliac LND was combined with resection of a spermatic cord metastasis and in a second procedure resection of a lung metastasis was performed.

Of the 18 patients undergoing a resection, the expert pathologist classified 17 as an R0 resection. In one patient the resection margin was not tumor-free and a re-excision was performed. In this

second specimen no vital melanoma cells could be found. Pathologic responses were evaluated in the 18 patients undergoing a per protocol resection: six patients had a pathologic CR (pCR); three a near pCR; 4 had a pathologic PR (pPR) and pathologic nonresponse (pNR) was seen in five patients. In the patient that underwent a palliative axillary LND despite development of distant metastases, a pPR was still seen in the resection specimen and tumor margins were free. However, due to the development of distant metastases during neoadjuvant treatment, this procedure is not classified as a per protocol resection nor an R0 resection. Neither radiologic response on CT nor metabolic response on PET could accurately predict pathologic response, which is shown in Table 3.

Per protocol, no adjuvant therapy was given, except for adjuvant radiotherapy in two patients. In one patient, this was advised in the multidisciplinary board after a R0 resection due to extracapsular extension in the resected lymph nodes. In the other patient, this was a combination of patient request and an attempt for optimal local control (this patient had been included in the trial with a recurrence in the axilla after a previous axillary LND). One patient traveled abroad to receive adjuvant systemic therapy (one year of PD-1 blockade), since this was not part of the study treatment nor standard and reimbursed care at that time in the Netherlands.

**Adverse Events**

Most patients experienced some form of toxicity during neoadjuvant systemic treatment with *BRAF/MEK*i: only two (10%) patients experienced no treatment-related AEs. In the majority of patients, the worst toxicity was grade 1 (11 patients, 52%), in four (19%) patients grade 2, and four (19%) patients experienced grade 3 toxicity. The most commonly reported AEs related to dabrafenib plus trametinib were fever (48%), chills (19%), fatigue (19%), nausea (19%), and myalgia (14%).

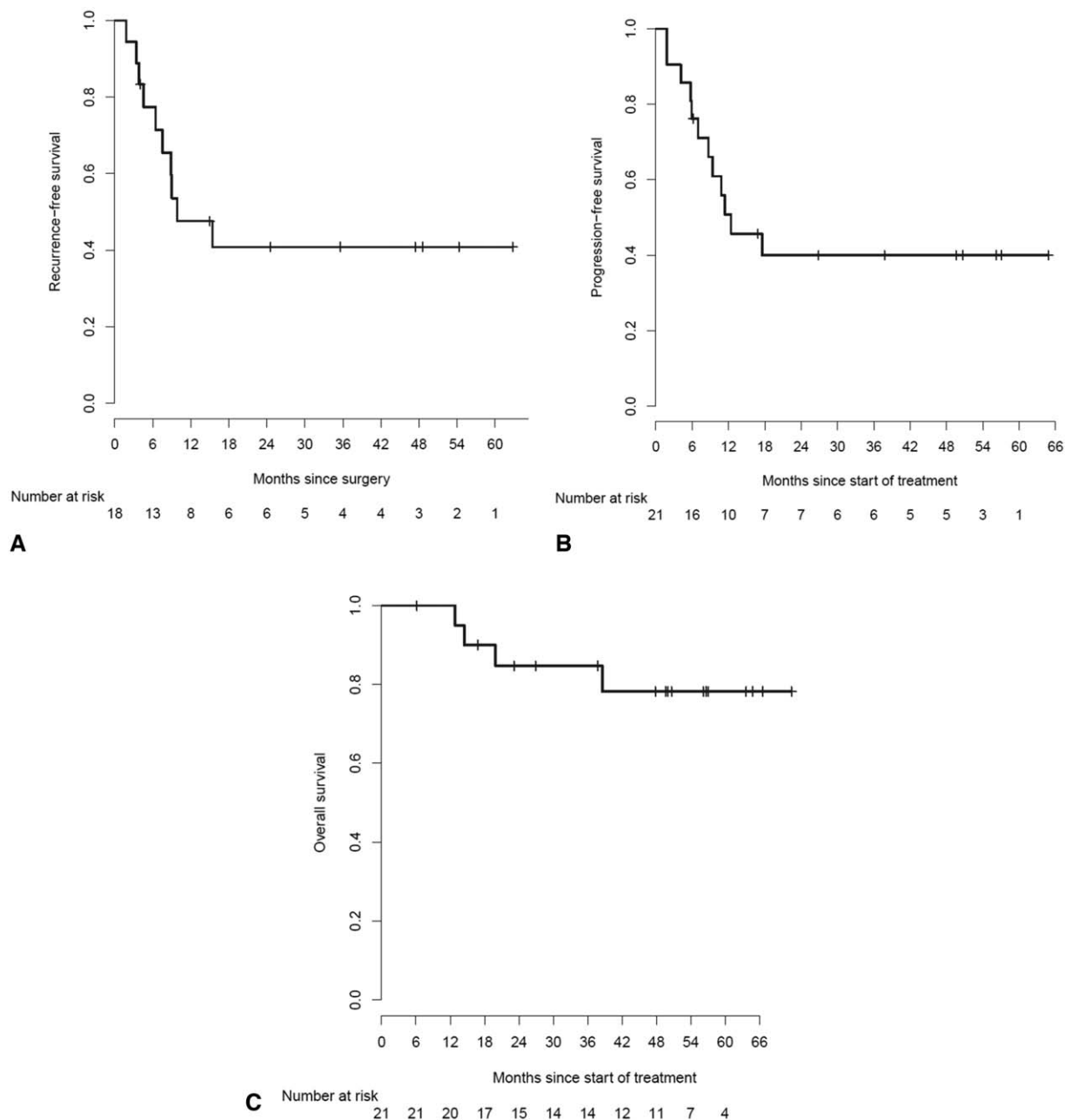
The majority of patients that underwent surgery (16/20, 80%) experienced a surgical complication, consisting mainly of the development of seroma (55%) and wound infections (30%). Three patients had grade 1 seroma, five patients grade 2, and three patients experienced grade 3 seroma for which elective radiologic or surgical intervention was indicated. Grade 2 wound infection was seen in two patients and four patients endured a grade 3 wound infection requiring intravenous antibiotics and hospital admittance. In six (30%) patients postoperative (lymph)edema was documented in the patient records.

**TABLE 3. Radiologic and Metabolic Versus Pathologic Response**

Pathology	pCR	pnCR	pPR	pNR	N.A.
<b>Imaging</b>					
<b>Radiologic response*</b>					
CR	0	0	0	1	0
PR	6	3	4	2	1
SD	0	0	0	1	0
PD	0	0	0	0	2
<b>Metabolic response EORTC criteria</b>					
CMR	1	0	0	3	0
PMR	5	3	4	1	1
SMD	0	0	0	0	0
PMD	0	0	0	0	2
<b>Metabolic response PERCIST</b>					
CMR	1	0	0	3	0
PMR	5	3	3	1	1
SMD	0	0	1	0	0
PMD	0	0	0	0	2

CMR indicates complete metabolic response; CR, complete response; nPCR, pathologic near complete response; pCR, pathologic complete response; PD, progressive disease; PMD, progressive metabolic disease; PMR, partial metabolic response; pNR, pathologic non response; pPR, pathologic partial response; PR, partial response; SD, stable disease; SMD, stable metabolic disease.

\*In one patient lesions did not meet RECIST 1.1 criteria, additionally PERCIST and EORTC could not be assessed in this patient due to an incompatible FDG-PET at baseline.



**FIGURE 1.** (A) Recurrence-free survival. (B) Progression-free survival. (C) Overall survival.

### Survival Outcomes

At a median follow-up of 50 months (IQR 37.7–57.1 months), the median RFS in the 18 patients undergoing surgery was 9.9 months (95% CI 7.52–not reached). Median PFS in all 21 patients was 12.4 months (95% CI 8.67 – not reached). The patient who had received adjuvant systemic therapy abroad, outside of the study protocol, was censored for PFS and RFS at time of commencement of adjuvant systemic treatment. Median OS was not reached. The 1-year OS was 100% and 2-year OS 85% (95% CI 70.0–100.0). RFS, PFS and OS are shown in Figure 1A–C, respectively.

### Recurrences

Recurrences were seen in half of the patients that underwent surgery (9/18). Most patients developed distant recurrences (6/9), versus three patients with locoregional recurrences as a first presentation of relapse. The three patients with locoregional recurrences were treated with surgery, but all developed distant metastases and were treated with systemic therapy at later time points. Of patients with a pCR, five (83%) did not relapse, but one (17%) did develop a recurrence. Four out of five patients with a pNR relapsed. All three patients that could not undergo a resection, due to either PD during study treatment or insufficient response, were treated with ICI, resulting in a CR in these patients.

## DISCUSSION

In this prospective, single-arm, open-label phase II trial, neoadjuvant treatment with dabrafenib and trametinib has shown to be a potent cytoreductive treatment, allowing radical resection of metastases in 17/21 (81%) patients with prior unresectable locally advanced melanoma. Encouraging RFS and OS are also seen in these patients, even compared to patients with resectable stage IIIB melanoma.<sup>30</sup>

Several trials have reported neoadjuvant treatment with either targeted therapy or ICI in stage III melanoma. Two studies reported treatment with neoadjuvant *BRAF/MEKi* in resectable *BRAF*-mutated stage III melanoma. Both Amaria et al<sup>31</sup> and Long et al<sup>20</sup> treated patients with neoadjuvant (8 and 12 weeks, respectively) and adjuvant (44 and 40 weeks, respectively) *BRAF/MEKi* for one year in total. Patients presented with a MUP in 14% (standard of care arm) and 29% (neoadjuvant arm) of cases in the trial by Amaria et al. The site of the primary melanoma was not described by Long et al. In our current trial, a relatively large proportion of patients (43%) presented with a MUP. This could be due to the fact that they were unaware of their melanoma and that patients were not seen in a standard follow-up program, resulting in later clinical presentation. In our current trial, the neoadjuvant treatment was given for a relatively short time compared to the trials by Amaria et al and Long et al. The cytoreductive effect of *BRAF/MEK* inhibitors usually occurs quickly after initiation of treatment, thus it was hypothesized that 8 weeks neoadjuvant treatment should suffice to achieve enough tumor downsizing to enable resection. A later response after this time was deemed unlikely. In the trial by Amaria et al, the RFS in patients that received this treatment was 19.7 months (95% CI 16.2-not reached), versus 2.9 months (95% CI 1.7-not reached, HR 0.016) in the standard of care arm of this trial. In the study by Long et al, the RFS was 23.3 months (95% CI 17.7–not reached). In both trials, high response rates could be observed, with 85% of patients achieving a radiological response scored per RECIST 1.1 and 58% of patients achieving a pCR in the trial by Amaria et al. In the trial by Long et al, 86% of patients achieved a radiological response before surgery and in all patients a pathological response was seen in the resection specimen (49% pCR, 51% noncomplete pathological response). The striking differences in (complete) response rates (RR) compared to the current trial can potentially be explained by the different patient populations included in these trials. These other two trials only included patients with resectable stage IIIB-C disease, whereas our current trial only included patients with unresectable disease, presently considered as stage IIIB disease following AJCC 8th edition. The differences in RFS may in turn be explained by the absence of adjuvant treatment after resection in our current trial, this in contrast to the trials by Amaria et al and Long et al.

Of the patients undergoing surgical resection, 17% presented with locoregional disease as site of first recurrence in our present trial. This is comparable to earlier reported locoregional recurrence rates in patients with resectable IIIB melanoma undergoing resection without (neo)adjuvant systemic therapy, as represented by placebo arms of recent adjuvant randomized trials.<sup>32–34</sup> However, the patients in our trial would not be able to undergo surgery, without cytoreductive treatment.

In our study, both radiologic and metabolic responses before surgery were not able to predict pathologic response. This was also shown by Eroglu et al in a retrospective study in a comparable patient population.<sup>35</sup> Of 9 patients with a (near) pCR, only one patient had shown a corresponding metabolic CR and no patients had a radiologic CR; the remainder of these pCR patients had shown a radiologic and metabolic PR. The poor performance of radiologic response as a predictor of pCR might be explained by fibrotic tissue visible as a

remaining lesion on CT, although no viable tumor cells are present. Tan et al described that FDG-PET may be superior to CT in showing a CR in metastatic melanoma patients treated with ICI.<sup>36</sup> However, in our cohort this distinction was not as clear. Both EORTC and PERCIST criteria were designed to measure response to chemotherapy, and perhaps this cannot be directly translated to treatment with targeted therapy.

Besides neoadjuvant targeted therapy, different schemes of neoadjuvant anti-PD-1 or the combination ICI with nivolumab and ipilimumab have been reported in patients with resectable palpable stage III melanoma as well, as described by Blank et al,<sup>37</sup> Rozeman et al,<sup>21</sup> Amaria et al,<sup>38</sup> and Huang et al.<sup>39</sup> In combination ICI studies, very high pathologic RR were seen of 73% to 80% and to date, pathologic response seemed predictive of RFS, as none of the patients who achieved a pathologic response relapsed in the OpA-CIN-neo study.<sup>21,37,38</sup>

As yet, no direct comparison between (neo)adjuvant targeted therapy and ICI has been performed in resectable stage III melanoma. Although response rates are high in the neoadjuvant setting for ICI, it is uncertain whether this can be translated to the population of patients with unresectable stage III melanoma. Both *BRAF/MEKi* and ipilimumab/nivolumab have shown rapid responses and high objective RR in stage IV melanoma.<sup>4,11</sup> In our current trial we have shown that 18/21 patients had a radiological and metabolic response after only 8 weeks of dabrafenib/trametinib treatment and radical resection could be achieved in 17/21 patients. The majority of patients did not develop distant metastases during this treatment period, despite being at very high risk for metastatic disease and with a median follow-up of 50 months, 43% was still disease-free. Whether similar or better results could be obtained for unresectable stage III disease with short-term neoadjuvant ICI is currently unknown.

Due to the rapid developments in the systemic treatment of stage IV melanoma and the oftentimes quickly progressive nature of stage IV disease, only one patient with stage IV disease was included in this study. Currently, the standard of care in these patients is first-line systemic treatment with PD-1 blockade or combined ipilimumab/nivolumab and surgery is only considered in select cases of residual disease or oligoprogression.<sup>1</sup>

This single arm, open-label phase II trial is, to our knowledge, the first prospective trial treating unresectable locally advanced melanoma patients with neoadjuvant cytoreductive targeted therapy, of which the results look very promising. A limitation of this trial, however, is the small patient cohort. This is partly due to the specific patient population, as most patients have either limited locoregional disease only or bulky locoregional metastases combined with multiple distant metastases. Also, during the course of this trial, *BRAF/MEKi* became available for unresectable stage III melanoma patients outside of clinical trials, reducing the number of referrals from other sites. Due to the slow accrual rate, the decision was made to cease the trial prematurely to retain its clinical relevance. An unplanned interim analysis of the, up until then, 21 included patients showed that predefined endpoints had already been exceeded. Moreover, since the neoadjuvant treatment with *BRAF/MEKi* was effective in most patients and adjuvant treatment had become standard of care in resected stage III melanoma during the course of this study, many patients inquired about the possibility of receiving adjuvant treatment after resection. Due to the combination of the slow accrual rate, results of the unplanned interim analysis and the changing treatment landscape with adjuvant systemic therapy as the new standard of care, the decision was made to cease inclusion and report the outcomes of this study.

Dabrafenib plus trametinib has shown to be a potent neoadjuvant cytoreductive treatment in this select population of *BRAF*-mutated unresectable locally advanced melanoma patients. Patients

with no recurrence remained disease-free for a prolonged period of time. However, when recurrences were seen, this usually occurred quickly after surgery. This may present a window of opportunity for adjuvant therapy with ICI, possibly in combination with *BRAF/MEKi*, in order to achieve improved and more durable RFS. Further clinical trials are needed to explore the additional benefit of such adjuvant therapy after previous neoadjuvant *BRAF/MEKi*.

## CONCLUSIONS

In this prospective single-arm, open-label phase II trial, neoadjuvant dabrafenib and trametinib have shown to be a potent cytoreductive treatment, allowing radical resection of metastases in 17/21 (81%) patients with prior unresectable locally advanced melanoma. If relapses occurred, this was usually quickly (within months) after surgery. This could present an opportunity for tailored adjuvant therapy.

## REFERENCES

1. Michielin O, van Akkooi ACJ, Ascierto PA, et al. Cutaneous melanoma: ESMO Clinical Practice Guidelines for diagnosis, treatment and follow-up. *Ann Oncol*. 2019;30:1884–1901.
2. Ascierto PA, McArthur GA, Dreno B, et al. Cobimetinib combined with vemurafenib in advanced BRAF(V600)-mutant melanoma (coBRIM): updated efficacy results from a randomised, double-blind, phase 3 trial. *Lancet Oncol*. 2016;17:1248–1260.
3. Long GV, Flaherty KT, Stroyakovskiy D, et al. Dabrafenib plus trametinib versus dabrafenib monotherapy in patients with metastatic BRAF V600E/K-mutant melanoma: long-term survival and safety analysis of a phase 3 study. *Ann Oncol*. 2017;28:1631–1639.
4. Robert C, Grob JJ, Stroyakovskiy D, et al. Five-year outcomes with dabrafenib plus trametinib in metastatic melanoma. *N Engl J Med*. 2019;381:626–636.
5. Dummer R, Ascierto PA, Gogas HJ, et al. Encorafenib plus binimetinib versus vemurafenib or encorafenib in patients with BRAF-mutant melanoma (COLUMBUS): a multicentre, open-label, randomised phase 3 trial. *Lancet Oncol*. 2018;19:603–615.
6. Hodi FS, O'Day SJ, McDermott DF, et al. Improved survival with ipilimumab in patients with metastatic melanoma. *N Engl J Med*. 2010;363:711–723.
7. Ascierto PA, Del Vecchio M, Robert C, et al. Ipilimumab 10 mg/kg versus ipilimumab 3 mg/kg in patients with unresectable or metastatic melanoma: a randomised, double-blind, multicentre, phase 3 trial. *Lancet Oncol*. 2017;18:611–622.
8. Ascierto PA, Long GV, Robert C, et al. Survival outcomes in patients with previously untreated BRAF wild-type advanced melanoma treated with nivolumab therapy: three-year follow-up of a randomized phase 3 trial. *JAMA Oncol*. 2019;5:187–194.
9. Larkin J, Minor D, D'Angelo S, et al. Overall survival in patients with advanced melanoma who received nivolumab versus investigator's choice chemotherapy in CheckMate 037: a randomized, controlled, open-label phase III trial. *J Clin Oncol*. 2018;36:383–390.
10. Weber JS, Gibney G, Sullivan RJ, et al. Sequential administration of nivolumab and ipilimumab with a planned switch in patients with advanced melanoma (CheckMate 064): an open-label, randomised, phase 2 trial. *Lancet Oncol*. 2016;17:943–955.
11. Larkin J, Chiarion-Sileni V, Gonzalez R, et al. Five-year survival with combined nivolumab and ipilimumab in advanced melanoma. *N Engl J Med*. 2019;381:1535–1546.
12. Hodi FS, Chesney J, Pavlick AC, et al. Combined nivolumab and ipilimumab versus ipilimumab alone in patients with advanced melanoma: 2-year overall survival outcomes in a multicentre, randomised, controlled, phase 2 trial. *Lancet Oncol*. 2016;17:1558–1568.
13. Robert C, Ribas A, Schachter J, et al. Pembrolizumab versus ipilimumab in advanced melanoma (KEYNOTE-006): post-hoc 5-year results from an open-label, multicentre, randomised, controlled, phase 3 study. *Lancet Oncol*. 2019;20:1239–1251.
14. Hamid O, Puzanov I, Dummer R, et al. Final analysis of a randomised trial comparing pembrolizumab versus investigator-choice chemotherapy for ipilimumab-refractory advanced melanoma. *Eur J Cancer*. 2017;86:37–45.
15. Schadendorf D, van Akkooi ACJ, Berking C, et al. Melanoma. *Lancet*. 2018;392:971–984.
16. Blankenstein SA, van Akkooi ACJ. Adjuvant systemic therapy in high-risk melanoma. *Melanoma Res*. 2019;29:358–364.
17. Weber J, Mandala M, Del Vecchio M, et al. Adjuvant nivolumab versus ipilimumab in resected stage III or IV melanoma. *N Engl J Med*. 2017;377:1824–1835.
18. Eggermont AMM, Blank CU, Mandala M, et al. Adjuvant pembrolizumab versus placebo in resected stage III melanoma. *N Engl J Med*. 2018;378:1789–1801.
19. Hauschild A, Dummer R, Schadendorf D, et al. Longer follow-up confirms relapse-free survival benefit with adjuvant dabrafenib plus trametinib in patients with resected BRAF V600-mutant stage III melanoma. *J Clin Oncol*. 2018;36:3441–3449.
20. Long GV, Saw RPM, Lo S, et al. Neoadjuvant dabrafenib combined with trametinib for resectable, stage IIIB-C, BRAF(V600) mutation-positive melanoma (NeoCombi): a single-arm, open-label, single-centre, phase 2 trial. *Lancet Oncol*. 2019;20:961–971.
21. Rozeman EA, Menzies AM, van Akkooi ACJ, et al. Identification of the optimal combination dosing schedule of neoadjuvant ipilimumab plus nivolumab in macroscopic stage III melanoma (OpACIN-neo): a multicentre, phase 2, randomised, controlled trial. *Lancet Oncol*. 2019;20:948–960.
22. Sosman JA, Moon J, Tuthill RJ, et al. A phase 2 trial of complete resection for stage IV melanoma: results of Southwest Oncology Group Clinical Trial S9430. *Cancer*. 2011;117:4740–4746.
23. Howard JH, Thompson JF, Mozzillo N, et al. Metastectomy for distant metastatic melanoma: analysis of data from the first Multicenter Selective Lymphadenectomy Trial (MSLT-I). *Ann Surg Oncol*. 2012;19:2547–2555.
24. Balch CM, Gershenwald JE, Soong SJ, et al. Final version of 2009 AJCC melanoma staging and classification. *J Clin Oncol*. 2009;27:6199–6206.
25. Tetzlaff MT, Messina JL, Stein JE, et al. Pathological assessment of resection specimens after neoadjuvant therapy for metastatic melanoma. *Ann Oncol*. 2018;29:1861–1868.
26. Eisenhauer EA, Therasse P, Bogaerts J, et al. New response evaluation criteria in solid tumours: revised RECIST guideline (version 1.1). *Eur J Cancer*. 2009;45:228–247.
27. Young H, Baum R, Cremerius U, et al. Measurement of clinical and subclinical tumour response using [18F]-fluorodeoxyglucose and positron emission tomography: review and 1999 EORTC recommendations. European Organization for Research and Treatment of Cancer (EORTC) PET Study Group. *Eur J Cancer*. 1999;35:1773–1782.
28. Wahl RL, Jacene H, Kasamon Y, et al. From RECIST to PERCIST: evolving considerations for PET response criteria in solid tumors. *J Nucl Med*. 2009;50(Suppl 1):122s–150s.
29. Simon R. Optimal two-stage designs for phase II clinical trials. *Control Clin Trials*. 1989;10:1–10.
30. Gershenwald JE, Scolyer RA, Hess KR, et al. Melanoma staging: evidence-based changes in the American Joint Committee on Cancer Eighth Edition Cancer Staging Manual. *CA Cancer J Clin*. 2017;67:472–492.
31. Amaria RN, Prieto PA, Tetzlaff MT, et al. Neoadjuvant plus adjuvant dabrafenib and trametinib versus standard of care in patients with high-risk, surgically resectable melanoma: a single-centre, open-label, randomised, phase 2 trial. *Lancet Oncol*. 2018;19:181–193.
32. Dummer R, Hauschild A, Santinami M, et al. Five-year analysis of adjuvant dabrafenib plus trametinib in stage III melanoma. *N Engl J Med*. 2020;383:1139–1148.
33. Maio M, Lewis K, Demidov L, et al. Adjuvant vemurafenib in resected, BRAF(V600) mutation-positive melanoma (BRIM8): a randomised, double-blind, placebo-controlled, multicentre, phase 3 trial. *Lancet Oncol*. 2018;19:510–520.
34. Eggermont AMM, Blank CU, Mandala M, et al. Longer follow-up confirms recurrence-free survival benefit of adjuvant pembrolizumab in high-risk stage III melanoma: updated results from the EORTC 1325-MG/KEYNOTE-054 trial. *J Clin Oncol*. 2020;38:3925–3936.
35. Eroglu Z, Eatrdes J, Naqvi SMH, et al. Neoadjuvant BRAF-targeted therapy in regionally advanced and oligometastatic melanoma. *Pigment Cell Melanoma Res*. 2020;33:86–95.
36. Tan AC, Emmett L, Lo S, et al. Utility of 1-year FDG-PET (PET) to determine outcomes from anti-PD-1 (PD1) based therapy in patients (pts) with metastatic melanoma (MM). *J Clin Oncol*. 2018;36(15\_suppl):9517–19517.
37. Blank CU, Rozeman EA, Fanchi LF, et al. Neoadjuvant versus adjuvant ipilimumab plus nivolumab in macroscopic stage III melanoma. *Nat Med*. 2018;24:1655–1661.
38. Amaria RN, Reddy SM, Tawbi HA, et al. Neoadjuvant immune checkpoint blockade in high-risk resectable melanoma. *Nat Med*. 2018;24:1649–1654.
39. Huang AC, Orlowski RJ, Xu X, et al. A single dose of neoadjuvant PD-1 blockade predicts clinical outcomes in resectable melanoma. *Nat Med*. 2019;25:454–461.