Universiteit Leiden
The Netherlands

EACVI recommendations on cardiovascular imaging for the detection of embolic sources: endorsed by the Canadian Society of Echocardiography

Cohen, A.; Donal, E.; Delgado, V.; Pepi, M.; Tsang, T.; Gerber, B.; ... ; Popescu, B.A.

Citation

Cohen, A., Donal, E., Delgado, V., Pepi, M., Tsang, T., Gerber, B., … Popescu, B. A. (2021). EACVI recommendations on cardiovascular imaging for the detection of embolic sources: endorsed by the Canadian Society of Echocardiography. *European Heart Journal - Cardiovascular Imaging*, *22*(6), E24-E57. doi:10.1093/ehjci/jeab008

Version: Publisher's Version
License: Creative Commons CC BY 4.0 license
Downloaded from: https://hdl.handle.net/1887/3279755

Note: To cite this publication please use the final published version (if applicable).

ESC European Society of Cardiology

European Heart Journal - Cardiovascular Imaging (2021) **22**, e24–e57
doi:10.1093/ehjci/jeab008

EACVI DOCUMENT

EACVI recommendations on cardiovascular imaging for the detection of embolic sources: endorsed by the Canadian Society of Echocardiography

(Chair) Ariel Cohen[1,2]*, (Co-Chair) Erwan Donal[3], Victoria Delgado[4], Mauro Pepi[5], Teresa Tsang[6], Bernhard Gerber[7], Laurie Soulat-Dufour[1,2], Gilbert Habib[8], Patrizio Lancellotti[9,10], Arturo Evangelista[11], Bibiana Cujec[12], Nowell Fine[13], Maria Joao Andrade[14], Muriel Sprynger[15], Marc Dweck[16], Thor Edvardsen[17], and Bogdan A. Popescu[18]

Reviewers: This document was reviewed by members of the 2018–2020 EACVI Scientific Documents Committee: Philippe Bertrand, Maurizio Galderisi, Kristina H. Haugaa, Leyla Elif Sade, Ivan Stankovic; and by the chair of the 2018–2020 EACVI Scientific Documents Committee: Bernard Cosyns.

[1]Assistance Publique-Hôpitaux de Paris, Saint-Antoine and Tenon Hospitals, Department of Cardiology, and Sorbonne University, Paris, France,; [2]INSERM unit UMRS-ICAN 1166; Sorbonne-Université, Paris, France.; [3]University of Rennes, CHU Rennes, Inserm, LTSI - UMR 1099, F-35000 Rennes, France; [4]Department of Cardiology, Leiden University Medical Centre, Leiden, the Netherlands; [5]Centro Cardiologico Monzino, IRCCS, Via Parea 4, 20141, Milan, Italy; [6]Division of Cardiology,University of British Columbia,Vancouver, British Columbia,Canada; [7]Service de Cardiologie, Département Cardiovasculaire, Cliniques Universitaires St. Luc, Division CARD, Institut de Recherche Expérimental et Clinique (IREC), UCLouvainAv Hippocrate 10/2803, B-1200 Brussels, Belgium; [8]Aix Marseille Univ, IRD, MEPHI, IHU-Méditerranée Infection, APHM, La Timone Hospital, Cardiology Department, Marseille, France; [9]University of Liège Hospital, GIGA Cardiovascular Sciences, Department of Cardiology, CHU SartTilman, Liège, Belgium; [10]Gruppo Villa Maria Care and Research, Maria Cecilia Hospital, Cotignola, and Anthea Hospital, Bari, Italy; [11]Servei de Cardiologia. Hospital Universitari Vall d'Hebron-VHIR. CIBER-CV. P° Vall d'Hebron 119. 08035. Barcelona. Spain; [12]Division of Cardiology, University of Alberta, 2C2.50 Walter Mackenzie Health Sciences Center, 8440 112 St NW, Edmonton, Alberta, Canada T6G 2B7; [13]University of Calgary, Libin Cardiovascular Institute, South Health Campus, 4448 Front Street Southeast, Calgary, Alberta T3M 1M4, Canada; [14]Maria Joao Andrade Cardiology Department, Hospital de Santa Cruz-Centro Hospitalar Lisboa Ocidental, Av. Prof. Dr. Reinaldo dos Santos 2790-134 Carnaxide, Portugal; [15]Department of Cardiology-Angiology, University Hospital Liège, Liège, Belgium; [16]British Heart Foundation, Centre for Cardiovascular Science, Edinburgh and Edinburgh Imaging Facility QMRI, University of Edinburgh, United Kingdom; [17]Faculty of medicine, Oslo University, Oslo, Norway and Department of Cardiology, Oslo University Hospital, Rikshospitalet, Oslo, Norway; and [18]Cardiology Department, University of Medicine and Pharmacy 'Carol Davila', Emergency Institute for Cardiovascular Diseases 'Prof. Dr. C. C. Iliescu', Sos. Fundeni 258, sector 2, 022328 Bucharest, Romania

Received 18 December 2020; editorial decision 21 December 2020; accepted 7 January 2021; online publish-ahead-of-print 12 March 2021

Cardioaortic embolism to the brain accounts for approximately 15–30% of ischaemic strokes and is often referred to as 'cardioembolic stroke'. One-quarter of patients have more than one cardiac source of embolism and 15% have significant cerebrovascular atherosclerosis. After a careful work-up, up to 30% of ischaemic strokes remain 'cryptogenic', recently redefined as 'embolic strokes of undetermined source'. The diagnosis of cardioembolic stroke remains difficult because a potential cardiac source of embolism does not establish the stroke mechanism. The role of cardiac imaging—transthoracic echocardiography (TTE), transoesophageal echocardiography (TOE), cardiac computed tomography (CT), and magnetic resonance imaging (MRI)—in the diagnosis of potential cardiac sources of embolism, and for therapeutic guidance, is reviewed in these recommendations. Contrast TTE/TOE is highly accurate for detecting left atrial appendage thrombosis in patients with atrial fibrillation, valvular and prosthesis vegetations and thrombosis, aortic arch atheroma, patent foramen ovale, atrial septal defect, and intracardiac tumours. Both CT and MRI are highly accurate for detecting cavity thrombosis, intracardiac tumours, and valvular prosthesis thrombosis. Thus, CT and cardiac magnetic resonance should be considered in addition to TTE and TOE in the detection of a cardiac source of embolism. We propose a diagnostic algorithm where vascular imaging and contrast TTE/TOE are

* Corresponding author. Tel: +33 1 49 28 28 86; Fax: +33 1 49 28 28 84. E-mail: ariel.cohen@aphp.fr
Published on behalf of the European Society of Cardiology. All rights reserved. © The Author(s) 2021. For permissions, please email: journals.permissions@oup.com.

Downloaded from https://academic.oup.com/ehjcimaging/article/22/6/e24/6168685 by Universiteit Leiden / LUMC user on 22 June 2022

considered the first-line tool in the search for a cardiac source of embolism. CT and MRI are considered as alternative and complementary tools, and their indications are described on a case-by-case approach.

Keywords stroke • ischaemic stroke • embolic stroke • cryptogenic stroke • cardiovascular imaging • echocardiography • magnetic resonance imaging • computed tomography • guidelines

Table of contents

1. Introduction ... e26
The need to update the recommendations ... e27
2. Definitions ... e27
Cerebral infarction ... e27
Transient ischaemic attack ... e27
Cryptogenic stroke ... e27
Embolic strokes of undetermined source ... e27
3. Cardiovascular imaging tools ... e27
Transthoracic and transoesophageal echocardiography for work-up of cryptogenic stroke and stroke with a suspected cardioembolic cause ... e27
Computed tomography and magnetic resonance imaging for work-up of cryptogenic stroke and stroke with a suspected cardioembolic cause ... e28
Vascular imaging for work-up of cryptogenic stroke and stroke with a suspected cardioembolic cause ... e28
4. Cardiac sources of cerebral embolism ... e31
Major cardiac sources of cerebral embolism ... e31
Left atrial thrombus and risk factors ... e31
Left atrial thrombi ... e31
Rheumatic valve disease (mitral stenosis) ... e31
Atrial fibrillation ... e31
Atrial flutter ... e32
Left atrial/left atrial appendage spontaneous echocardiographic contrast ... e32
Left atrial appendage dysfunction ... e32
Multimodality imaging of left atrial appendage and association with ischaemic stroke ... e32
Two-dimensional transthoracic echocardiography ... e32
Transoesophageal echocardiography (2D initially and now, mainly 3D with all capabilities related to the 3D acquisition) ... e33
Cardiac computed tomography and cardiac magnetic resonance imaging ... e33
Atrial cardiomyopathy ... e35
Left ventricular thrombus and risk factors ... e35
Recent myocardial infarction ... e35
Acute phase of myocardial infarction ... e36
Cardiomyopathy ... e36
Dilated cardiomyopathy ... e36
Hypertrophic and restrictive cardiomyopathies ... e36
Other cardiomyopathies ... e38
Heart failure ... e38
Cardiac masses ... e38
Intracardiac tumours ... e38
Myxoma ... e39
Fibroelastomas ... e39
Valvular vegetations ... e40
Infective endocarditis ... e40
Marantic vegetations ... e40
Aortic arch atheromatous plaques ... e41
Prosthetic cardiac valves (e.g. mechanical, biological, clips) ... e42
Minor or undetermined cardiac sources of cerebral embolism e44
Atrial septal abnormalities ... e44
Atrial septal aneurysm ... e44
Patent foramen ovale ... e44
Mechanisms of paradoxical embolism ... e45
Right atrial thrombi: thrombi 'in transit' (paradoxical embolism) ... e45
Left atrial septal pouch ... e46
Valvular abnormalities ... e46
Mitral valve prolapse ... e46
Mitral annulus calcification ... e47
Aortic valve calcification and stenosis ... e47
Giant Lambl's excrescences and strands ... e47
5. Flow chart ... e48
6. Conclusions ... e48
7. Acknowledgements ... e50
8. References ... e50

List of tables

Table 1 Grading of internal carotid artery stenoses with NASCET and ECST[42] ... e29
Table 2 Combined criteria for grading ICA stenosis (according to von Reutern *et al.*[43]) ... e30
Table 3 Clinical and imaging features associated with increased risk of ischaemic stroke in patients with asymptomatic ICA stenosis[4] ... e30
Table 4 Major and minor/unclear sources of ischaemic stroke ... e31

List of figures

Figure 1 Schematic drawings of patterns of brain infarctions signalling different stroke mechanisms.[16] ... e28
Figure 2 Carotid bifurcation with an echolucent ICA stenosis. The aliasing shown by colour Doppler is a direct sign of severe ICA stenosis. ICA, internal carotid artery. ... e28
Figure 3 NASCET and ECST methods: A, B, and D are measured with colour Doppler, B-flow, or eFlow; C is the normal lumen diameter before development of the stenosis.[42] ECST, European Carotid Surgery Trialists; NASCET, North American Symptomatic Carotid Endarterectomy Trial NASCET. ... e29
Figure 4 Area-reduction method for measuring internal carotid artery stenoses. ... e29
Figure 5 2D TOE: pulsed Doppler in the LAA during (left) sinus rhythm and (right) AF. ... e33

Downloaded from https://academic.oup.com/ehjcimaging/article/22/6/e24/6168685 by Universiteit Leiden / LUMC user on 22 June 2022

Figure 6 Multimodality imaging of LAA thrombi: (*A*) 2D TTE parasternal short-axis view depicting LAA thrombus in a patient with mitral stenosis; (*B*) TOE illustration of the different grades of LA SEC. e34
Figure 7 Multimodality evaluation of LVT. e37
Figure 8 Multimodality evaluation of cardiac masses. e39
Figure 9 Multimodality evaluation of infective endocarditis. e40
Figure 10 Multimodality evaluation of aortic arch atheromatous plaque: TOE (left) and CTA and angio MRI (right). e43
Figure 11 Multimodality evaluation of atrial septal abnormalities: 2D TOE (left) e46
Figure 12 Mitral annular calcifications on 2D TTE (short-axis view). e47
Figure 13 Diagnostic algorithm: proposal for a diagnostic approach based on the current evidence e49

Recommendations

- Recommendations for cardiovascular imaging tools e30
- Recommendations on imaging techniques to evaluate LA/LAA anatomy, geometry, and function in AF e35
- Recommendations for identification and evaluation of LVT . . e38
- Recommendations for evaluation of cardiac masses e39
- Recommendations for evaluation of valvular vegetations e41
- Recommendations for evaluation of aortic arch atheromatous plaques e43
- Recommendations for evaluation for prosthetic heart valves . e44
- Recommendations for evaluation of atrial septal anomalies (ASA, PFO) e45
- Recommendations for evaluation for PFO and paradoxical embolism e46
- Recommendations for evaluation and treatment of minor and putative sources of ischaemic stroke e47

Abbreviations and acronyms

2D, two-dimensional
3D, three-dimensional
AF, atrial fibrillation
ASA, atrial septal aneurysm
CEA, carotid endarterectomy
CHA_2DS_2-VASc, Congestive heart failure, Hypertension, Age ≥75 years, Diabetes mellitus, prior Stroke, TIA, or thromboembolism, Vascular disease, Age 65–74 years, Sex category (female)
$CHADS_2$, Congestive heart failure, Hypertension, Age ≥75 years, Diabetes mellitus, prior Stroke, TIA, or thromboembolism
CI, confidence interval
CMR, cardiac magnetic resonance
CT, computed tomography
CTA, computed tomography angiography
DCM, dilated cardiomyopathy
EACVI, European Association of Cardiovascular Imaging
EAE, European Association of Echocardiography
ECST, European Carotid Surgery Trialists
EDV, end-diastolic velocity
ESUS, embolic strokes of undetermined source
HCM, hypertrophic cardiomyopathy
HR, hazard ratio
ICA, internal carotid artery
LA, left atrial or left atrium
LAA, left atrial appendage; LAAT
left atrial appendage thrombus/thrombi
LASP, left atrial septal pouch
LAT, left atrial thrombus
LV, left ventricular or left ventricle
LVEF, left ventricular ejection fraction
LVSD, left ventricular systolic dysfunction
LVT, left ventricular thrombus
MESA, Multi-Ethnic Study of Atherosclerosis
MI, myocardial infarction
MR, magnetic resonance
MRI, magnetic resonance imaging
NASCET, North American Symptomatic Carotid Endarterectomy Trial
NBTE, non-bacterial thrombotic endocarditis
PET, positron-emission tomography
PFO, patent foramen ovale
PSV, peak systolic velocity
RA, right atrial or right atrium
RR, risk ratio
SEC, spontaneous echocardiographic contrast
SSFP, steady-state free precession
TIA, transient ischaemic attack
TOAST, Trial of ORG 10172 in Acute Stroke Treatment
TOE, transoesophageal echocardiography
TTE, transthoracic echocardiography

Introduction

Ischaemic stroke is a major cause of disability and mortality worldwide.[1–4] Cardioaortic embolism to the brain accounts for approximately 15–30% of ischaemic strokes and is often referred to as 'cardioembolic stroke'.[5,6] Cardioembolic stroke is generally severe and prone to early and long-term recurrences.[7] Identifying potential cardiac sources of embolism is a key objective, because treatment may vary according to the cardiac condition diagnosed.[8] Unfortunately, and often despite comprehensive evaluation of the underlying cause, up to 30% of ischaemic strokes remain 'cryptogenic' (i.e. without an established cause).[5,9] Consequently, a new entity has recently been defined: embolic strokes of undetermined source (ESUS).[10]

The diagnosis of cardioembolic stroke is often difficult because the presence of a potential cardiac source of embolism alone does not establish the stroke mechanism. The clinical significance of minor or uncertain sources of cardiac risk remains controversial,[11] as reported in the Canadian guidelines.[12] Furthermore, approximately 25% of patients have more than one cardiac source of embolism and 15% have significant cerebrovascular atherosclerosis.[13] Combined, these clinical factors emphasize the role of cardiac imaging—transthoracic echocardiography (TTE) and transoesophageal echocardiography (TOE) as the first-line, and cardiac computed tomography (CT) and magnetic resonance imaging (MRI) in addition—in the evaluation of

Downloaded from https://academic.oup.com/ehjcimaging/article/22/6/e24/6168685 by Universiteit Leiden / LUMC user on 22 June 2022

patients with stroke, in the diagnosis of potential cardiac sources of embolism, and for therapeutic guidance.[14,15]

Recommendations for classifying cardiac conditions that predispose to cerebral embolism have been made previously,[16] but we strongly believe that the subject should be revisited based on new imaging capabilities and evidence.

The need to update the recommendations

Recommendations for the use of echocardiography in the diagnosis and management of cardiac sources of embolism were published in 2010 by the European Association of Echocardiography (EAE).[16] The EAE recommends the use of TTE and TOE when neurological symptoms potentially due to a suspected cardiac cause are present.[16] We believe that an update is needed for the following reasons:

(1) The probability of detecting potentially emboligenic cardiac disease depends on the diagnostic method used. Taking into account the advances in ultrasound investigation techniques [real-time three-dimensional (3D) echocardiography—both TTE and TOE] and the improved value of the other imaging modalities (CT and MRI), we think it worthwhile to introduce herein these non-echocardiographic techniques.
(2) 'New' potentially cardiac sources can be discussed [e.g. lef atrail septal pouch (LASP), atrial cardiomyopathy].[17]
(3) In the absence of evidence, clinical expertise recommends the use of a synthetic algorithmic approach to cardiac work-up of a patient with ischaemic stroke or transient ischaemic attack (TIA).
(4) Based on these recommendations, research projects could be conducted to confirm and improve the level of evidence for performing a diagnostic test or another investigation in the clinical context.
(5) The present recommendations do not deal with specific imaging aspects related to exploration of the vessels. We focus instead on cardiac and aortic arch sources of systemic emboli, most of which are cerebral.

Definitions

Cerebral infarction

Cerebral infarction is defined as brain, spinal cord, or retinal cell death attributable to ischaemia, based on neuroimaging, neuropathological evidence, and/or clinical evidence of permanent injury.[15]

Transient ischaemic attack

TIA is a transient episode of neurological dysfunction caused by focal brain, spinal cord, or retinal ischaemia, without acute infarction.[15]

Cryptogenic stroke

Cryptogenic ischaemic strokes are symptomatic cerebral infarcts for which no probable cause is identified after adequate diagnostic evaluation. More expansive definitions include strokes in patients who are incompletely evaluated and in those with more than one probable identified cause, defined according to the Trial of ORG 10172 in Acute Stroke Treatment (TOAST) criteria.[5,8] However, if the TOAST criteria clearly specify that cryptogenic stroke is one that is not attributable to known aetiologies, they do not indicate specific diagnostic modalities that must be negative to declare a cryptogenic stroke.

More recently, the notion of cryptogenic embolism was introduced in the Causative Classification of Stroke System.[18] In this classification, cryptogenic embolism refers to a stroke for which there is angiographic evidence of abrupt cut-off consistent with a blood clot within otherwise angiographically normal-looking intracranial arteries, or imaging evidence of complete recanalization of a previously occluded artery, or the presence of multiple acute infarctions that have occurred closely related in time without detectable abnormalities in relevant vessels.

Embolic strokes of undetermined source

ESUS are defined as non-lacunar brain infarcts without substantial proximal arterial stenosis or major cardioembolic sources, and account for 80–90% of cryptogenic ischaemic strokes.[10] ESUS are thought to be a therapeutically relevant entity, as antiplatelet therapy and stroke risk-factor reduction are not highly effective in preventing recurrent strokes. Criteria for the diagnosis of ESUS are described in Supplementary data online, *Table S1*.

ESUS account for approximately one in six ischaemic strokes. Patients with ischaemic stroke meeting the criteria for ESUS are relatively young compared to patients with other ischaemic stroke subtypes, and tend to have minor strokes consistent with small emboli. The retrospective methods used in the published studies limit confidence in predicting stroke recurrence rates, but indicate a substantial (>4% per year) rate of stroke recurrence during (mostly) antiplatelet therapy.[19,20]

Several clinical and imaging findings suggest an embolic stroke:

a. abrupt onset of stroke symptoms;
b. previous infarctions in various arterial distributions;
c. multiplicity in space (infarct in both the anterior and posterior circulation, or bilateral);
d. multiplicity in time (infarcts of different ages);
e. other signs of systemic thromboembolism (e.g. edge-shaped infarctions of kidney or spleen; Osler splits; blue toe syndrome); and
f. territorial distribution of the infarcts involving the cortex, or subcortical 'large lenticulostriate infarct'.

Illustrations of patterns of brain infarctions signalling different mechanisms of stroke are shown in *Figure 1*.[16]

Cardiovascular imaging tools

Transthoracic and transoesophageal echocardiography for work-up of cryptogenic stroke and stroke with a suspected cardioembolic cause

TOE is a semi-invasive examination with possible associated complications but is widely performed in patients with ischaemic stroke. TOE is consistently superior to TTE, particularly when the patient presents without clinical signs suggestive of heart disease, but its superiority appears dependent on the patient's age. Therefore, patient age and history, and the risks of recurrence and consequences of treatment must be considered when making a diagnosis of a cerebral or peripheral embolic event. When a cardioembolic cause is suspected, it is recommended to consider both TTE and TOE. TOE should be performed according to the clinical context, but emergent indications are limited (e.g. fever, prosthesis).[8]

Downloaded from https://academic.oup.com/ehjcimaging/article/22/6/e24/6168685 by Universiteit Leiden / LUMC user on 22 June 2022

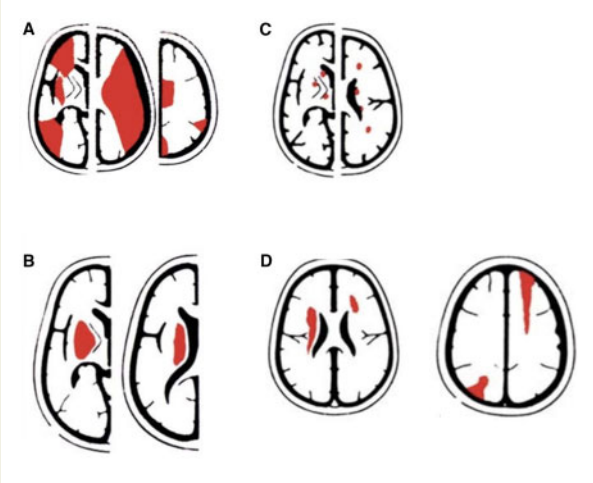

Figure 1 Schematic drawings of patterns of brain infarctions signalling different stroke mechanisms.[16] (*A*) Cardioembolic stroke is probable in cortical infarcts with territorial distribution; (*B*) the same holds true for large striatocapsular infarcts; (*C*) but not for lacunar infarctions, by definition located subcortically; and (*D*) low-flow infarct can be located subcortical (left panel) or cortical (right panel), but their distribution is interterritorial not territorial.

A 2006 study reported that more than one in eight patients of any age with normal TTE findings had a major cardiac risk factor revealed on TOE that warranted anticoagulation.[21] More than 30 cross-sectional studies have evaluated the yield of TTE or TOE, or both, in detecting cardiac sources of embolus in patients with stroke. In consecutive patients, the yield of echocardiography for the detection of intracardiac masses ranged from 0% to 21%.[12] Pooled data from these studies suggest an overall yield of 4% for TTE and 11% for TOE.

A systematic review and meta-analysis of 27 studies that aimed to assess TOE for cryptogenic stroke revealed that TOE-detected findings prompted the introduction of anticoagulant therapy in up to one-third of patients.[22] In a retrospective study that included 1458 patients hospitalized for stroke with a suspected cardioembolic cause, TOE changed the management in approximately 16% of patients, leading to the introduction of anticoagulation and antibiotics, closure and surgical closure of patent foramen ovale (PFO), and coil embolization.[14] In a meta-analysis of 12 studies, the pooled rate of reported anticoagulation therapy attributed to abnormal TOE findings among 3562 patients with acute ischaemic stroke was 8.7% [95% confidence interval (CI) 7.3–10.4]. The rates of initiation of anticoagulation therapy on the basis of TOE investigation did not differ ($P = 0.315$) among patients with cryptogenic stroke (6.9%, 95% CI 4.9–9.6), ESUS (8.1%, 95% CI 3.4–18.1), or ischaemic stroke (9.4%, 95% CI 7.5–11.8).[11]

Computed tomography and magnetic resonance imaging for work-up of cryptogenic stroke and stroke with a suspected cardioembolic cause

Both CT and MRI show potential for the detection of causes of cardioembolic stroke.[23] Indeed, both tests are highly accurate for detecting left atrial appendage (LAA) thrombosis (LAAT) in patients with atrial fibrillation (AF), with almost 100% sensitivity and specificity relative to TOE.[24–27] CT also allows the identification of valvular prosthesis thrombosis, aortic atheroma, PFO,[28,29] atrial septal defect,[30] and intracardiac tumours.[31] Cardiac magnetic resonance (CMR) is more sensitive and accurate than TTE for the detection of intraventricular thrombi after acute or chronic myocardial infarction (MI),[32] and allows the detection of left ventricular (LV) thrombi in patients with ESUS and a history of MI that may have been missed on TTE.[33]

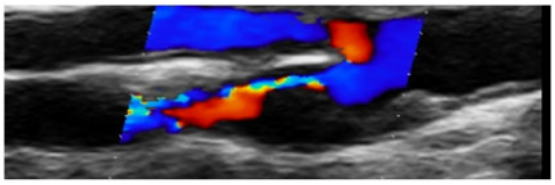

Figure 2 Carotid bifurcation with an echolucent ICA stenosis. The aliasing shown by colour Doppler is a direct sign of severe ICA stenosis. ICA, internal carotid artery.

Few studies have evaluated the sensitivity and accuracy of these techniques in stroke, and the published literature is conflicting (Supplementary data online, *Table S2*). In one study that included patients with cryptogenic stroke undergoing TTE or TOE, CMR reduced the percentage of patients classified as having cryptogenic stroke after echocardiography, from 27% to 20%.[34] However, in other research, CMR had limited additional value over TOE[35] and failed to identify all potential cardioembolic sources identified by TOE.[36] CT has 89% sensitivity and 100% specificity for identifying causes of cardioembolic strokes identified by TOE,[37] and has a similar predictive value as TOE for recurrence of ischaemic stroke.[38] Combined use of CT and TTE/TOE was more sensitive than TTE/TOE alone for detecting patients with at least one cardiac or aortic high-risk finding after acute stroke,[39] and in particular was able to identify more cerebral infarcts. In contrast, CT alone was less suitable for diagnosing small left atrial thrombi (LAT) or PFO than was TOE.

The main advantage of CT and MRI is that these tests are less invasive than TOE. The main limitation of cardiac CT is radiation exposure. However, when CT is already being performed in patients with acute stroke for evaluation of the aortic arch and carotid arteries, extension of the CT scan to the heart may be possible, allowing detection of high-risk cardiac and aortic sources of embolism with no increased incidence of contrast-induced nephropathy and only a minimal increase in radiation exposure.[40] Thus, CT and CMR should also be considered in addition of TTE and TOE in the detection of a cardiac source of embolism.

Vascular imaging for work-up of cryptogenic stroke and stroke with a suspected cardioembolic cause

Approximately 25% of ischaemic carotid territory strokes are caused by embolization from a ruptured plaque, or by an acute occlusion of the internal carotid artery (ICA) or middle cerebral artery. The main cause is atherosclerosis. Atherosclerotic stenoses are mostly located at carotid bifurcations. There are other less frequent locations: brachiocephalic trunk, common carotid arteries, intracranial arteries,

Downloaded from https://academic.oup.com/ehjcimaging/article/22/6/e24/6168685 by Universiteit Leiden / LUMC user on 22 June 2022

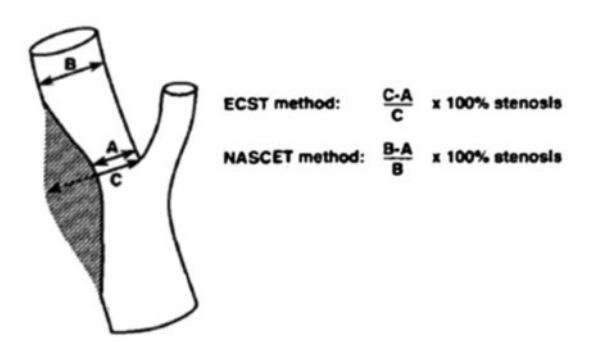

Figure 3 NASCET and ECST methods: A, B, are measured with colour Doppler, B-flow, or eFlow; C is the normal lumen diameter before development of the stenosis.[42] ECST, European Carotid Surgery Trialists; NASCET, North American Symptomatic Carotid Endarterectomy Trial NASCET.

vertebral arteries, and middle cerebral artery. Approximately 10–15% of all ischaemic strokes are related to a previously asymptomatic ICA stenosis >50%,[41] but ischaemic strokes can also be preceded by TIA or fugax amaurosis.

Duplex ultrasound is considered as the first-line imaging modality for carotid atherosclerosis. Unless they are too calcified, stenoses can be evaluated by direct two-dimensional (2D) echo measurements, colour Doppler (*Figure 2*), and optionally by Power Doppler, eFlow, or B-flow.

Several methods can be used for 2D measurements of ICA stenoses.[42] The standard method is the North American Symptomatic Carotid Endarterectomy Trial (NASCET) method, which is better related to haemodynamics and CT or magnetic resonance (MR) angiography. The European Carotid Surgery Trialists (ECST) method gives a better assessment of plaque burden (*Figure 3*).

The NASCET and ECST methods measure diameter reduction. Alone they are not sufficient to evaluate the degree of stenosis, especially for irregular or eccentric stenoses, and must be correlated with Doppler velocities (see below). The area-reduction method can also be used to measure ICA stenoses (*Figure 4*).

Of note, the ECST and area-reduction methods overestimate the severity of the stenosis compared with the standard method (NASCET) (*Table 1*). Their use must therefore be recorded in the patient's files.[42]

CT and MR angiography may also be required. Their advantage is the ability to give simultaneous imaging of the aortic arch, supra-aortic vessels, carotid bifurcation, distal ICA, intracranial arteries, and brain. Conversely, the main asset of duplex ultrasound is the haemodynamic data provided by Doppler. Stenosis assessment is based primarily on direct signs: ICA peak systolic velocity, ICA end-diastolic velocity, and carotid ratio (*Table 2*).

In the case of severe stenosis (>80%) or ICA occlusion, indirect signs can give additional information: altered intracranial blood flow (transcranial Doppler) and/or reduced or reverse flow in the ophthalmic artery.[42]

Catheter angiography is no longer needed apart from during endovascular procedures.

Carotid stenoses require the best medical treatment whether they are symptomatic or asymptomatic. In symptomatic patients, studies

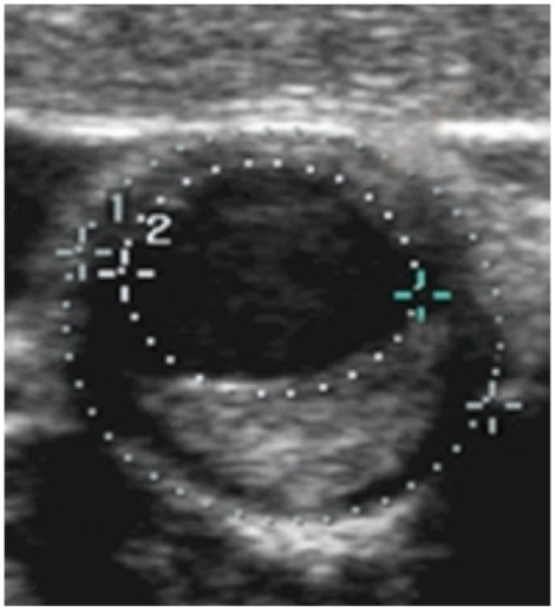

Figure 4 Area-reduction method for measuring internal carotid artery stenoses.

Table 1 Grading of internal carotid artery stenoses with NASCET and ECST[42]

NASCET	ECST
50%	75%
70%	85%
80%	90%

ECST, European Carotid Surgery Trialists; NASCET, North American Symptomatic Carotid Endarterectomy Trial.

show the maximum benefit of carotid endarterectomy (CEA) is in patients with NASCET 70–99% stenoses (number needed to treat = 6). The benefit was lower in patients with 50–69% NASCET stenoses (number needed to treat = 13), and no benefit was found in patients with NASCET 0–49% stenoses. Revascularization should preferably be done within 14 days of symptom onset.[44]

Optimal medical treatment has considerably reduced the risk of ischaemic stroke in patients with asymptomatic ICA stenoses, and currently, there is sufficient evidence for a more conservative approach in these individuals.[4] Nevertheless, predicting how dangerous an asymptomatic ICA stenosis is remains difficult. Some clinical and imaging features are associated with an increased risk of ischaemic stroke (*Table 3*). According to the European Society of Cardiology guidelines,[4] CEA should be considered in patients with asymptomatic 60–99% ICA stenoses, life expectancy >5 years, favourable anatomy, and ≥1 feature suggesting higher stroke risk on best medical treatment.

Ischaemic strokes can be caused, less frequently, by non-atherosclerotic lesions: arteritis (giant cell or Takayasu arteritis),

Downloaded from https://academic.oup.com/ehjcimaging/article/22/6/e24/6168685 by Universiteit Leiden / LUMC user on 22 June 2022

Table 2 Combined criteria for grading ICA stenosis (according to von Reutern et al.[43])

% stenosis	50%	60%	70%	80%	90%
PSV threshold	125 cm/s		230 cm/s		
PSV average	210 cm/s	240 cm/s	330 cm/s	370 cm/s	Variable
PSV post-stenotic			≥50 cm/s	<50 cm/s	<30 cm/s
EDV in the stenosis		<100 cm/s	>100 cm/s		
Carotid ratio[a]	≥2	≥2	>4	>4	

EDV, end-diastolic velocity; ICA, internal carotid artery; PSV, peak systolic velocity.
[a]ICA PSV divided by common carotid artery PSV.

Table 3 Clinical and imaging features associated with increased risk of ischaemic stroke in patients with asymptomatic ICA stenosis[4]

Clinical features	Contralateral TIA/stroke
Cerebral imaging	Ipsilateral silent infarction
Ultrasound	Stenosis progression (>20%)
	Stenosis characteristics: large plaque, echolucent plaque, juxta-luminal hypoechogenic area
	Vascularization of the plaque (contrast-enhanced echo)
	Impaired cerebral vascular reserve (transcranial Doppler)
	Spontaneous embolization in the ipsilateral middle cerebral artery on transcranial Doppler monitoring (high-intensity transient signals)
MRI	Intra-plaque haemorrhage
	Lipid-rich necrotizing core

ICA, internal carotid artery; MRI, magnetic resonance imaging; TIA, transient ischaemic attack.

Recommendations for cardiovascular imaging tools[45]

TTE, TOE, CMR

TTE should be performed systematically before TOE for evaluation of the cardiovascular source of embolus.

Contrast TTE, using intravenous injection of agitated saline, should be performed systematically at baseline and after provocative manoeuvres (Valsalva manoeuvre, coughing, both).

General indications in search of cardiac or aortic sources of embolism

Contrast TTE is the initial imaging modality of choice for evaluation of the cardiac and aortic sources of embolus.

Contrast TOE should be done in selected patients for evaluation of the cardiovascular sources of embolus if no identified source is found on TTE.

Contrast TOE should be performed according to the clinical context, but emergent indications are limited (e.g. fever, prosthesis).

Contrast TOE should be performed rapidly (ideally within 48 h) in case of ischaemic stroke, peripheral embolism, or previous heart valve replacement (percutaneous or surgical).

Contrast TOE is not indicated in ischaemic stroke patients with a previously identified source.

A comprehensive stroke CT protocol, including the intracranial and cervical arteries, aortic arch, cardiac chambers and walls, and coronary arteries, can be proposed in trained centres as an alternative initial imaging modality for evaluation of the cardiac and aortic sources of embolus.

CMR could be proposed in unselected patients with cryptogenic stroke who have a non-diagnostic cardiac evaluation including contrast TOE.

Vascular imaging

Doppler ultrasound (first-line), CTA, and/or MR angiography are recommended for evaluating carotid stenoses.

When carotid stenting is being considered, it is recommended that any Doppler ultrasound study be followed by either MR or CTA to evaluate the aortic arch, as well as the extra- and intracranial circulation.

When CEA is considered, it is recommended that Doppler ultrasound be corroborated by MR or CTA or repeat Doppler ultrasound performed by an expert.

CEA, carotid endarterectomy; CMR, cardiac magnetic resonance; CT, computed tomography; CTA, computed tomography angiography; MR, magnetic resonance; TOE, transoesophageal echocardiography; TTE, transthoracic echocardiography.

Downloaded from https://academic.oup.com/ehjcimaging/article/22/6/e24/6168685 by Universiteit Leiden / LUMC user on 22 June 2022

dissection (e.g. trauma, idiopathic, Marfan syndrome, fibromuscular dysplasia, Ehlers-Danlos syndrome, carotid bulb diaphragm).

Cardiac sources of cerebral embolism

Major cardiac sources of cerebral embolism

Major (as well as minor and unclear) sources of cerebral embolism are detailed in *Table 4*.

Table 4 Major and minor/unclear sources of ischaemic stroke

Major sources of stroke risk	Minor or unclear sources of stroke risk
Atrial fibrillation	Mitral valve prolapse
Recent myocardial infarction	Mitral annulus calcification
Previous myocardial infarction (LV aneurysm)	Spontaneous echo contrast
All cardiomyopathies including non-compaction and takotsubo cardiomyopathies	Calcified aortic stenosis
Cardiac masses (except calcifications)	Valvular strands
Intracardiac thrombus	Atrial septal aneurysm without PFO
Intracardiac tumours	
Fibroelastoma	
Marantic vegetations	PFO
Rheumatic valve disease (mitral stenosis)	
Aortic arch atheromatous plaques	Atrial septal pouch
Endocarditis	Giant Lambl's excrescences
Prosthetic valve (mechanical especially)	

LV, left ventricular; PFO, patent foramen ovale.

Left atrial thrombus and risk factors

Left atrial thrombi

LAT and particularly LAAT are the primary sources of cerebral embolism and are the most common sites for intracardiac thrombi. They are primarily, but not exclusively, seen in patients with AF and mitral stenosis.[46] AF is the most frequent dysrhythmia and is closely associated with advancing age. The stratification risk of thromboembolic events in AF is currently based on clinical risk scores, mainly $CHADS_2$[47] (Congestive heart failure, Hypertension, Age ≥75 years, Diabetes mellitus, prior Stroke, TIA, or thromboembolism) and CHA_2DS_2-VASc[48] [Congestive heart failure, Hypertension, Age ≥75 years, Diabetes mellitus, prior Stroke, TIA, or thromboembolism, Vascular disease, Age 65–74 years, Sex category (female)]. The risk of stroke for individuals in sinus rhythm increases along with left atrial (LA) dimensions.[49] LA/LAA thrombus is very infrequently detected in the presence of sinus rhythm.[46] LAT and LAAT are often associated with spontaneous echocardiographic contrast (SEC), defined as dynamic 'smoke-like' and slowly swirling echodensities in the left atrium (LA) and/or LAA. TOE is the gold standard for the diagnosis and exclusion of LAT and LAAT, and is a useful tool for embolic risk stratification in AF. TOE allows the identification of risk factors for thromboembolism such as LV ejection fraction (LVEF) <35%,[50] complex aortic plaques, SEC in the LA/LA appendage (LAA), and LAT/LAAT, LAA dysfunction as measured by emptying/filling velocities ≤20 cm/s on pulsed Doppler,[50] and dynamic evaluation of LA function by evaluation of LA global longitudinal strain.

Whereas TTE is recommended in all patients with AF to identify the underlying causes of AF, TOE as a semi-invasive tool is not systematically needed. In a meta-analysis by Romero *et al.*,[24] the mean sensitivity and specificity of cardiac CT was, respectively, 96% and 92% compared with TOE. In a further subanalysis of seven mostly prospective, single-centre studies in which delayed imaging CT was performed, sensitivity and specificity further increased to 100% and 99%, respectively.

In addition to its non-invasive character, CT also offers a superior visualization of the anatomy of the LAA.[51]

In a retrospective registry analysis of patients undergoing pulmonary vein isolation, all thrombi detected by TOE were also found with the use of delayed enhancement cardiac MRI.[27]

Rheumatic valve disease (mitral stenosis)

Rheumatic valve disease and mitral stenosis are still common in developing countries. Patients with rheumatic mitral stenosis are at increased risk for embolic events. Systemic embolization occurs in 10–20% of patients with mitral stenosis, with 75% of cases manifesting as cerebral embolism.[52–54] Various factors are related to an increased risk for embolization, including age, AF, and LA enlargement.[54–56] Embolic events can be the first clinical manifestation of the disease and do not appear to be related to the severity of mitral stenosis.[52]

Although AF appears to be a determining factor in the formation of left intra-atrial thrombosis and is a major potential source of peripheral arterial embolism in mitral stenosis, 8–20% of patients presenting with mitral stenosis and systemic embolism are in sinus rhythm.[57,58] In these patients, not only the size and shape of the LA but also the presence of SEC is significantly associated with a higher risk of clot formation.[58]

Oral anticoagulant therapy is mandatory when AF complicates mitral stenosis, regardless of its severity and CHA_2DS_2-VASc score. In patients with mitral stenosis and sinus rhythm, those with larger LA volume and the presence of SEC might also benefit from prophylactic anticoagulation. Non-vitamin K antagonist oral anticoagulants are not recommended in moderate-to-severe mitral stenosis due to the lack of data.[59]

Atrial fibrillation

The most common cardioembolic sources of ischaemic stroke are LAAT during AF; however, a thrombus can also rapidly appear just after reduction of the arrhythmia, during the stunning period, despite the absence of thrombus when the patient was in AF.[60]

AF affects 0.3–0.4% of adults,[61] and the prevalence rises with age to 10% in those >75 years.[62] Specific recommendations about the use of multimodality imaging in that field have been published by the European Association of Cardiovascular Imaging (EACVI).[60] The

Downloaded from https://academic.oup.com/ehjcimaging/article/22/6/e24/6168685 by Universiteit Leiden / LUMC user on 22 June 2022

incidence of ischaemic stroke in patients with AF reportedly ranged from 1% in low-risk patients to 15% in high-risk patients, and silent AF was detected in 26% of patients who had recently had a cryptogenic stroke.[61] The loss or reduction of LA and LAA contractility during AF causes a reduction of LAA emptying and an increase in blood stasis, which is favoured by the chicken-wing (cul-de-sac) shape and multilobate anatomical structure of the LAA.[60,63] The risk of thrombus formation can be conveniently estimated using the CHA_2DS_2-VASc score,[48] which accurately predicts the risk of ischaemic stroke but only takes clinical variables into consideration.[64,65] LA and LAA anatomical and functional factors can, however, significantly influence the risk of thrombosis. Recent studies that investigated LA reservoir function have demonstrated the value of this echocardiographic parameter for predicting the risk of ischaemic stroke.[66–70] Accordingly, echocardiography has been proposed as a tool in the management of patients with AF.[60] TOE can accurately identify LAT and LAAT, and provides fundamental information for the timing of cardioversion in patients who have been in AF for >48 h, allowing immediate cardioversion without the need for 3 weeks of anticoagulation once the presence of LAT/LAAT has been excluded.[60,71] In addition, TOE can detect dense SEC, LAA contractility, and LAA anatomy.[51,72] CT angiography (CTA) is a reasonable alternative to TOE when the primary aim is to exclude LAT and LAAT, and in patients in whom the risks associated with TOE outweigh the benefits (consider the delayed scan post-contrast).[51,60]

The recent literature strongly encourages the use of strain measurement of LA reservoir function.[66,73] Deformation of LA walls during LV systole is associated with thromboembolic risk.[70,74] The value is independent of LA volume and may be a target for further treatment strategies. The results from an ongoing large EACVI registry will probably provide input for future guidelines.[75]

Imaging techniques are not currently used to estimate the risk of AF, which can be silent and could be detected in patients who are assessed by devices.[76–78] Van Gelder *et al.*[79] demonstrated that subclinical AF lasting for >24 h is associated with an increased risk of ischaemic stroke or systemic embolism. In a study involving 1251 patients, 217 had SEC, 127 had LAT/LAAT, 241 had complex aortic plaque, and 746 had none of these.[80] The rates of ischaemic stroke/systemic embolism were not significantly different among patients with and without these echocardiographic findings when they are properly treated with a non-vitamin K antagonist oral anticoagulant.[80]

Atrial flutter

Atrial flutter is often associated with, or preceded by, AF; the annual thromboembolic risk for patients with atrial flutter ranges from 1% to 5%.[81] The primary and secondary prevention methods are the same as for AF.[82–85]

In a meta-analysis of 52 studies that assessed the relationship between atrial flutter and ischaemic stroke, Vadmann *et al.*[86] showed that observational studies reported an overall elevated stroke risk (risk ratio 1.40, 95% CI 1.35–1.46) and mortality risk [hazard ratio (HR) 1.9, 95% CI 1.2–3.1] over long-time follow-up compared with a control group. Moreover, this study confirmed that clinical thromboembolic events, LAT, and SEC are highly prevalent in patients with atrial flutter.[86]

Left atrial/left atrial appendage spontaneous echocardiographic contrast

SEC refers to smoke-like echoes that can be visualized on echocardiography when ultrasound is backscattered by red blood cell aggregates.[87] The severity of SEC is graded from 0 to 4 according to the Fatkin classification,[88] with the following criteria:

(1) Mild (minimal echogenicity located in the LAA or sparsely distributed in the main cavity of the LA; may be detectable only transiently during the cardiac cycle; imperceptible at operating gain settings for 2D echocardiography analysis);
(2) Mild to moderate (more dense swirling pattern than grade 1, but with similar distribution; detectable without increased gain settings);
(3) Moderate (dense swirling pattern in the LAA, generally associated with somewhat lesser intensity in the main cavity, may fluctuate in intensity but detectable constantly throughout the cardiac cycle); and
(4) Severe (intense echodensity and very slow swirling patterns in the LAA, usually with similar density in the main cavity).[89]

More recently, sludge (an early thrombotic stage) has been defined in echocardiography as a dynamic, viscid, layered echodensity without a discrete mass, visualized throughout the cardiac cycle.[90]

SEC has been associated with a higher rate of ischaemic stroke in patients with AF (Supplementary data online, *Table S3*). Furthermore, clinical outcomes in patients with ischaemic stroke and AF are poor in the presence of coexisting SEC.[91,92] TOE plays an important role in detecting and defining the degree of SEC in the LA cavity.[89,93,94] Sludge has been reported to be abolished with appropriate anticoagulation, in contrast to SEC. Sludge is an independent predictor of embolic events and all-cause death.[63,90,93]

Among patients with AF of different causes, greater than mild mitral regurgitation was much less associated with LA SEC than mild or lesser mitral regurgitation.[95]

Left atrial appendage dysfunction

Multimodality imaging of left atrial appendage and association with ischaemic stroke. The development of LA ablation procedures and LAA occlusion devices for the treatment of AF has increased the interest in LAA anatomy and function.[96–98] The LAA is an embryonic remnant of the primordial LA and is an important site of thrombus formation in AF. Anatomically, the LAA is divided into three regions: the ostium, the neck, and the lobar region. The LAA ostium is usually oval, but can be round, triangular, or water-droplet shaped.[99] A post-mortem study[100] reported that most people had two lobes (54%), followed by three lobes (23%), one lobe (20%), and four lobes (3%). In most cases, the tip of the LAA is directed antero-superiorly and the LAA extends between the anterior and lateral walls of the LA.[99] The LAA contains pectinate muscles, which have to be differentiated from thrombi. With its complex morphology and function, the LAA can be studied using TTE, 2D/3D TOE, CT, and MRI to improve understanding of its association with ischaemic stroke. A 3D modality is recommended to best assess the complex shape of this structure.

Two-dimensional transthoracic echocardiography. TTE imaging provides partial evaluation of the LAA. Unusually LAAT can be visualized using TTE. Some authors have reported a relationship between LAA dysfunction—measured by LAA wall velocity using TTE—and

Downloaded from https://academic.oup.com/ehjcimaging/article/22/6/e24/6168685 by Universiteit Leiden / LUMC user on 22 June 2022

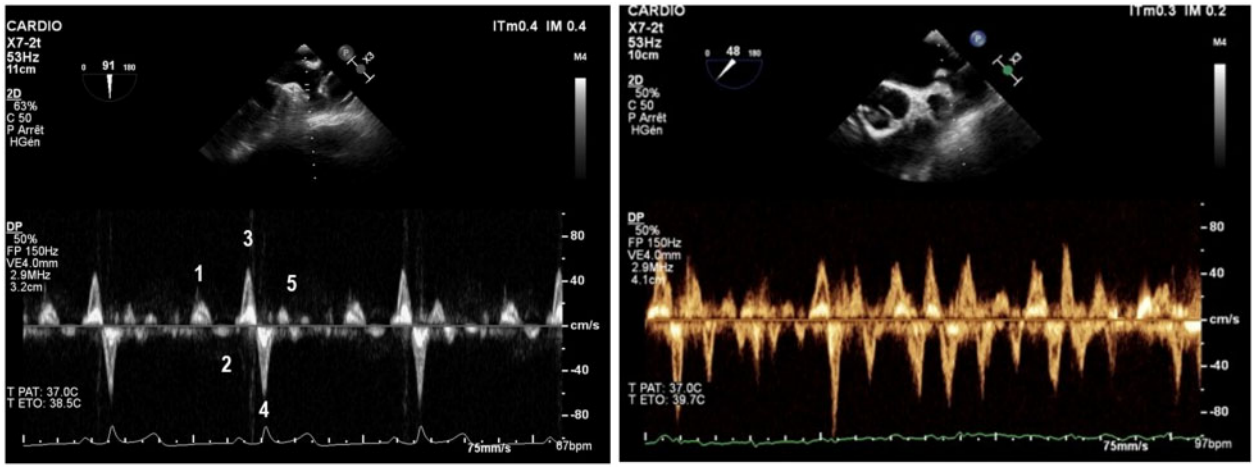

Figure 5 2D TOE: pulsed Doppler in the LAA during (left) sinus rhythm and (right) AF. (1) Early positive diastolic LAA emptying; (2) early negative diastolic LAA filling; (3) late positive diastolic LAA emptying (just after the P-wave on the electrocardiogram); (4) early negative systolic LAA filling; (5) systolic reflection waves. 2D, two-dimensional; AF, atrial fibrillation; LAA, left atrial appendage; TOE, transoesophageal echocardiography.

cerebrovascular events.[101] In addition to LAA evaluation, TTE imaging is essential for the evaluation of LAA risk of thrombus formation and cardioembolic events. LV dysfunction is an echocardiographic risk factor for LAAT, probably mediated by ventricular diastolic dysfunction and its effect on LA dynamics and pressure. Evaluation of diastolic function may improve stroke prediction in patients with non-valvular AF. *E*/*e*′ ratio and *e*′ velocity are associated with LAAT, independent of CHA_2DS_2-VASc score.[102] LA volume and mechanical dysfunction are closely associated with high risks of LAT and LAAT formation, and increased LA volume increases the risk of first ischaemic stroke.[103] LA global longitudinal strain—assessed using speckle-tracking TTE—discriminates the presence of LAT or LAAT on TOE in patients with acute ischaemic stroke.[74]

Transoesophageal echocardiography (2D initially and now, mainly 3D with all capabilities related to the 3D acquisition). TOE is a mandatory complement to TTE for the optimal evaluation of LAA anatomy and function. The LAA can be visualized using 2D TOE in the mid-oesophageal view by rotating the imaging sector from 0° to 180°. For LAAT detection—in comparison with surgical data—TOE has excellent sensitivity (92%) and specificity (98%).[104,105] Some years ago, before the dissemination of 3D TOE probes, some authors demonstrated that contrast injection could enhance visualization of the LAA and facilitate the exclusion of LAAT on TOE.[72,106]

One of the strengths of 2D TOE is the ability to perform Doppler evaluation of the emptying and filling velocities of the LAA (*Figure 5*). LAA blood-flow velocities are obtained using pulsed Doppler by positioning the sample volume at the proximal third of the LAA cavity after necessary gain and filter adjustments. LAA flow during sinus rhythm is divided into several phases.[107,108] After mitral valve opening, the following can be successively measured: early positive diastolic LAA emptying (the consequence of LV filling); early negative diastolic LAA filling (the consequence of LA filling); late positive diastolic LAA emptying (LAA contraction); early negative systolic LAA filling (LAA elastic recoil); and systolic reflection waves. In AF, no identifiable waves are individualized in the LAA, with a 'saw tooth' flow profile.

LAA dysfunction with alterations in LAA emptying and filling velocities <20 cm/s have been associated with an increased risk of thrombus formation within the LAA and a higher incidence of thromboembolic events in patients in normal sinus rhythm.[109,110]

3D TOE is superior to 2D TOE for anatomical evaluation of the LAA. 3D TOE has become 'a must'. 3D TOE allows visualization of the entire LAA and LAA orifice, their relation to the surrounding structures (mitral valve and left upper pulmonary vein), and evaluation of LAA volume, LAA ejection fraction, and LAA orifice area.[111–113] 3D TOE has to be considered to differentiate thrombi from artefacts or pectinate muscles within the LAA.[112,113]

In acute ischaemic stroke, LAA volume (analysed by real-time 3D TOE) is larger in patients with versus those without paroxysmal AF.[114] Multivariable analysis revealed $CHADS_2$ ($P = 0.002$), LVEF ($P = 0.01$), degree of LA SEC ($P = 0.02$), LA volume ($P = 0.02$), and number of LAA lobes ($P < 0.001$) to be independently associated with thrombus formation. Most patients with LAA thrombus (32/34, 94.4%) had ≥3 LAA lobes.[115]

Cardiac computed tomography and cardiac magnetic resonance imaging. In cardiac CT, differentiation between thrombi and blood stasis is possible with the analysis using delayed imaging.[116–119] In a meta-analysis of 753 patients with delayed imaging of the LAA, the mean weighted sensitivity and specificity for the detection of LAAT was 100% and 99%, respectively, and the positive predictive value and negative predictive were 92% and 100%, respectively.[24]

Using CT, a larger LAA orifice area is a significant risk factor for ischaemic stroke (adjusted odds ratio 6.16, 95% CI 2.67–14.18; $P < 0.001$).[120] Using MRI, ischaemic stroke risk has been reported to be highest in patients with an LAA volume >34 cm^3.[121] A retrospective study reported an association between LAA

Downloaded from https://academic.oup.com/ehjcimaging/article/22/6/e24/6168685 by Universiteit Leiden / LUMC user on 22 June 2022

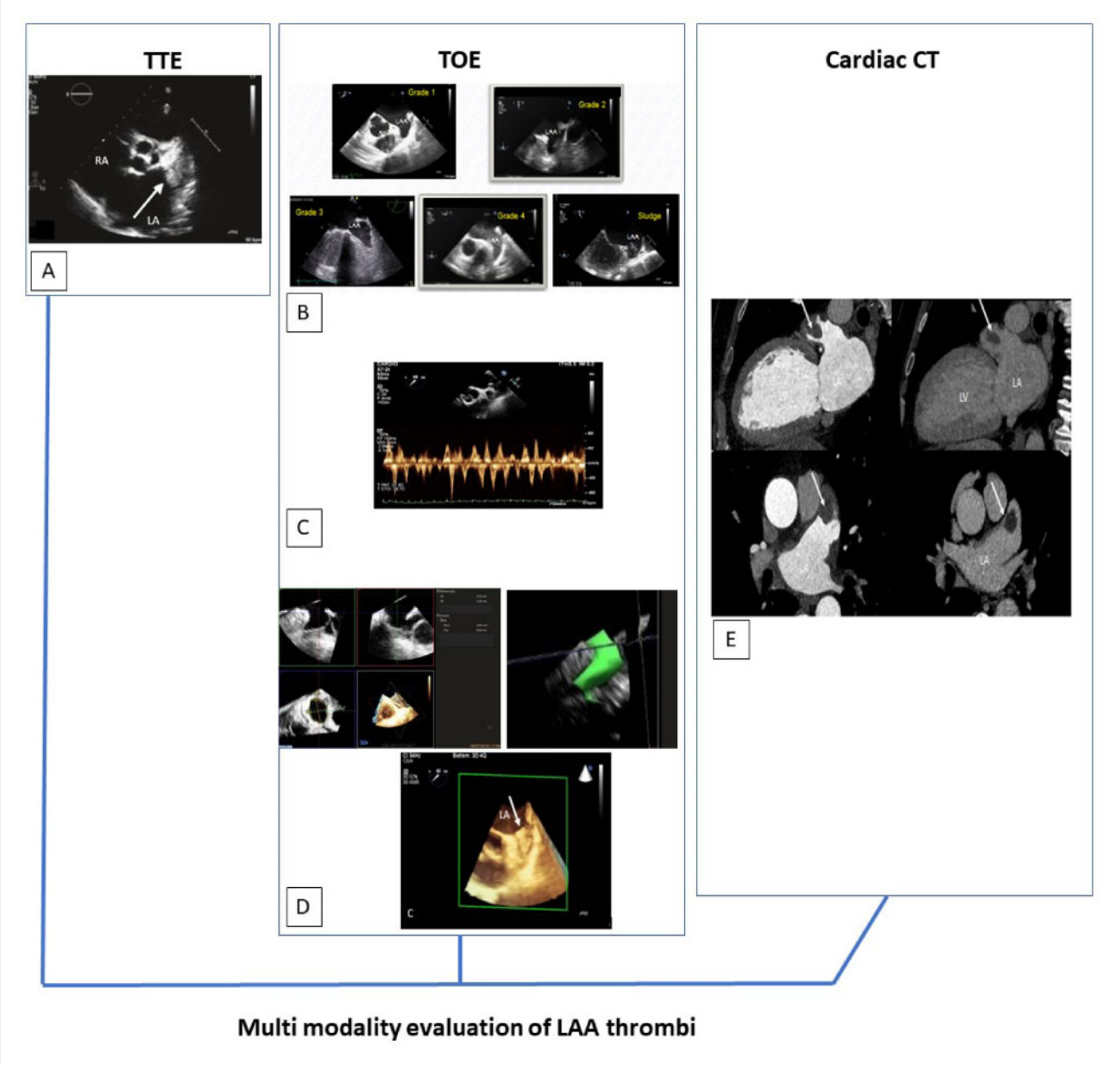

Figure 6 Multimodality imaging of LAA thrombi: (*A*) 2D TTE parasternal short-axis view depicting LAA thrombus in a patient with mitral stenosis; (*B*) TOE illustration of the different grades of LA SEC (see Supplementary data online, *Video S1A–D*); (*C*) 2D TOE: pulsed Doppler in the LAA during AF; (*D*) 3D TOE: analysis of the ostium of the LAA (upper left) and volume evaluation (upper right); example of LAA thrombus in a patient with mitral stenosis (bottom) (see Supplementary data online, *Video S2*); (*E*) Cardiac CT, arterial phase on the left and delayed phase on the right (90 s after iodine injection), two-chamber view on the top and axial view on the bottom, showing LAAT (courtesy of Gilles Soulat, MD, PhD). 2D, two-dimensional; 3D, three-dimensional; AF, atrial fibrillation; AO, aorta; CT, computed tomography; LA, left atrium; LAA, left atrial appendage; LAAT, left atrial appendage thrombus; LASEC, left atrial spontaneous echocardiographic contrast; RA; right atrium; SEC, spontaneous echocardiographic contrast; TOE, transoesophageal echocardiography; TTE, transthoracic echocardiography.

morphology and previous thromboembolic events, using CT and MRI.[122]

LAA morphology has been classified into four types: chicken wing, cauliflower, windsock, and cactus, based on cardiac CT. In a meta-analysis of eight studies, patients with chicken wing morphology were less likely to have an embolic event compared with the other LAA morphologies.[123] LAA morphology by CT is an independent determinant of LAA flow velocity by TOE, suggesting an association between LAA morphology (and number of lobes) and embolic events.[124] Delayed contrast CT has been shown to be almost as sensitive as TOE for detection of LAAT.[24–27]

Using MRI, extensive fibrosis of the LA is a significant predictor of TOE abnormalities (LAAT or SEC).[125]

Downloaded from https://academic.oup.com/ehjcimaging/article/22/6/e24/6168685 by Universiteit Leiden / LUMC user on 22 June 2022

Summary

Figure 6 summarizes the multimodality imaging of LAA thrombi and *Figure S1* the echocardiographic predictors of LAAT formation and ischaemic stroke. Supplementary data online, *Tables S4* and *S5* summarize studies that assessed the associations between: LAA anatomy/function and LAAT; diastolic function and LAAT; and LAA anatomy/function and LAA flow velocity (Supplementary data online, *Table S4*)[102,115,124]; and LAA anatomy/function and ischaemic stroke (Supplementary data online, *Table S5*).[101,109,120,122,123]

Recommendations on imaging techniques to evaluate LA/LAA anatomy, geometry, and function in AF

LA/LAA SEC and sludge should be reported when a TOE is performed. The degree of LA/LAA SEC is associated with the prognosis.

Repeated TOE is indicated to monitor resolution of LAT/LAAT after anticoagulation in the case of AF/atrial flutter cardioversion and/or ablation.

3D TOE (better than 2D) is recommended for the anatomical and functional evaluation of the LAA and evaluation of LAAT.

CT and MRI are recommended for a more complete assessment of LAA anatomy before/during procedures of ablation of atrial arrhythmias and percutaneous LAA closure. LAA geometry is better defined with CT scans.

CT may detect LAAT with similar sensitivity and specificity than TOE when a delayed imaging is used.

2D, two-dimensional; 3D, three-dimensional; AF, atrial fibrillation; CT, computed tomography; LA, left atrial; LAA, left atrial appendage; LAAT, left atrial appendage thrombi; LV, left ventricular; MRI, magnetic resonance imaging; SEC, spontaneous echocardiographic contrast; TOE, transoesophageal echocardiography; TTE, transthoracic echocardiography.

Atrial cardiomyopathy

Atrial cardiomyopathy is defined in the EACVI/European Heart Rhythm Association expert consensus document[60] as 'any complex of structural, architectural, contractile, or electrophysiological changes affecting the atria with the potential to produce clinically relevant manifestations'.[126] This term implies adverse consequences that can be independent of atrial arrhythmias.

The presence and type of cardiomyopathy are independent predictors of ischaemic stroke in patients with AF; however, atrial cardiomyopathy may be an independent determinant of stroke risk. In fact, frequent temporal discordance between AF episodes and stroke leads to the concept that an underlying atrial cardiomyopathy may cause thromboembolism even in the absence of AF.[127]

Atrial remodelling is caused by cardiovascular diseases or risk factors, including ageing-induced atrial remodelling, through fibrosis, leading to LA/LAA mechanical and endothelial dysfunction (LA strain), substrate for increased LA thrombogenicity though Virchow's triad, and thus increased risk of ischaemic stroke.[128] Recently, Habibi *et al.*[129] reported an inverse association between LA reservoir function [measured as total LA ejection fraction, using MRI in the Multi-Ethnic Study of Atherosclerosis (MESA) study] and the risk of cerebrovascular events. This association was independent of known cerebrovascular risk factors and AF.

The concept of a thrombogenic atrial cardiomyopathy remains speculative, but the assessment of atrial structure (LA volume), function (LA ejection fraction, LA strain), and fibrosis (cardiovascular MR) may help improve stroke risk stratification independently from the presence of AF.

Left ventricular thrombus and risk factors

Recent myocardial infarction

Ischaemic heart disease, notably acute anterior MI, is a major source of LV thrombus (LVT) formation. Here, the combination of blood stasis and an inflamed necrotic myocardium predispose to thrombus formation. Several other cardiac conditions are also associated with LVT formation, including dilated cardiomyopathy (DCM), stress-induced cardiomyopathy, and severe LV systolic dysfunction (LVSD) complicating valvular heart disease. The overall prevalence of LVT in the general population is low. In a retrospective review of >80 000 medical records, the incidence of LVT was 7 per 10 000 patients.[130] Of these cases, 80% were related to infarction while the rest were due to DCM and stress-induced cardiomyopathy.[130] LVTs have been reported in 4–39% of patients with anterior wall MIs.[131] The prevalence of LVT following an MI was 9.1% in recent study in which CMR was systematically used.[132]

LVTs appear as echo-dense masses within the LV cavity, adjacent to an abnormally contracting LV segment (akinetic and less frequently hypokinetic) or an aneurysmal myocardium. The LVT appears to have distinct margins between the LV wall and the LV cavity, a structural texture that is different from the LV myocardium, and a clear thrombus–blood interface. The LVT is visible throughout the entire cardiac cycle and in at least two modified views or transducer positions. The LVT shape is called 'protuberant' (intracavitary) when the borders mainly protrude into the LV cavity. It may be pedunculated or sessile. The LVT shape is termed 'mural' when the mass is flat and parallel to the contiguous endocardial surface (concave borders). The LVT is considered mobile when a segment of it moves independently of the adjacent endocardial motion.

Weinsaft *et al.*[133] reported a specificity for TTE as high as 100% for LVT detection. However, TTE has a lower sensitivity for detecting LVT (21–33%) compared with late gadolinium enhancement CMR. Sensitivity of TTE increases to 61% when contrast agents are used. TTE performance for LVT detection may vary according to the clinical indication of the echocardiograph.[133] When echocardiograms were performed for the well-defined clinical indication of LVT, TTE sensitivity increased from 26% to 60% and TTE positive predictive value increased from 21% to 75%.[134]

The diagnosis of LVT is facilitated by using a contrast echocardiogram, as the contrast fills the LV cavity and thus enhances the visibility of endocardial border delineation. LVT appears on contrast images as a dark linear or protruding structure, adjacent to akinetic (or hypokinetic) myocardium, and is surrounded by opacified blood (which appears bright) in the LV cavity. LVT identification is based on anatomical appearance.

Rates of sensitivity and specificity of 88% and 96%, respectively, for conventional echocardiography have been reported using contrast

Downloaded from https://academic.oup.com/ehjcimaging/article/22/6/e24/6168685 by Universiteit Leiden / LUMC user on 22 June 2022

echocardiography for the detection of LVT in a series of 392 patients with anterior MI.[135]

MRI has a higher sensitivity and specificity for the detection of LV thrombi compared with TTE and is considered the gold standard in this setting.[33] Delayed-enhancement cardiac MRI has been validated as a more sensitive method for detecting LVT compared with cine MRI. Indeed, in this sequence, the thrombus is characterized by the absence of contrast agent enhancement.[136] Nevertheless, TTE is most frequently used for the detection of LVT and may serve as an initial screening test. In a large study of 361 patients who had surgical or pathological validation, the sensitivity of cardiac MR was 88% and the specificity was 99%.[137]

On cardiac CT, LVT has a significantly lower attenuation in comparison with a normally perfused myocardial wall.[138] Currently, there are few validated data on the role of cardiac CT in the detection of LVT in comparison with TOE or MRI. *Figure 7* illustrates examples of LVT diagnosed using TTE and MRI.

Pathological evaluation may distinguish fresh thrombi (no organization), organizing thrombi, and laminated chronic organized thrombi. CMR characteristics enable distinction between acute and older thrombi. An acute thrombus shows high signal intensity on T1- and T2-weighted images, whereas an older thrombus has low signal intensity in both T1 and T2 sequences and occasionally shows evidence of calcification.[139] Embolic risk increases with more mobile thrombi and a greater number of thrombi. In a retrospective study, the overall rate of post-treatment thromboembolism in patients on anticoagulant treatment was about 17%.[130] However, this rate can vary from 0% to 33%.[140–147] Clinical or pathological endpoints at 6-month follow-up (TIA, cerebrovascular accident, or pathology-verified thrombus) seem to occur more frequently in patients with LVT detected by delayed-enhancement CMR than with TTE (16.7% vs. 7.7%).[134]

Certain LVT characteristics are known predictors of embolism, including LVT morphological variations over time in serial examinations, protruding shape, and mobility.[148]

Acute phase of myocardial infarction. Subsequent to the Olmsted County study,[149] a meta-analysis[150] reported a prevalence rate of 11.1 for ischaemic stroke per 1000 MIs in patients hospitalized for MI. At 1 month, the rate rose to 12.2 per 1000 and was 21.4 after 1 year.[150] Predictors of ischaemic stroke after MI include older age, diabetes, arterial hypertension, previous ischaemic stroke, anterior MI, previous MI, AF, heart failure, and race.

LVT is reported in 20% of cases when the coronary artery is not reperfused, and can reach 40% in anterior MI and 60% in the event of extensive MI involving the LV apex.[151] MI location and severity of LV dysfunction determine the embolic risk.[152] Thus, the rate of embolic events can reach 20% in patients with extensive anterior MI and LVT.[153]

Within 4 weeks of an acute MI, 1–2.5% of patients will present with ischaemic stroke, most often (in 50% of cases) within the first week.[154–156] The risk is particularly high (4–12%) when the Q-wave MI affects the anterior wall and apex of the LV.[157,158] These locations promote the formation of a left intraventricular thrombus, which generally arises in the 10 days following an MI. The risk of ischaemic stroke in patients presenting with an anterior MI and a left intraventricular thrombus is 12% in the month following the MI.[158] This risk seems to be higher if the thrombus is pedunculated and mobile. The risk of systemic embolism decreases markedly in the subsequent months in the absence of AF and heart failure, irrespective of the natural history of the LVT.[158] The incidence of embolism is high when the thrombus is forming (first 3 months), but then decreases.[159]

The presence of preclinical coronary artery disease in patients with stroke seems to be highly prevalent[160] and is a major cause of death during follow-up.[161]

Investigation of stroke patients for asymptomatic coronary artery disease (using coronary artery calcium score, CT coronary angiography, iodine coronary angiography), remains debatable.[162]

Cardiomyopathy

Cardiac thrombi are major sources of risk for embolism.[16] Blood stasis, myocardial wall damage, and hypercoagulability are the three main determinants of intracardiac thrombus formation.

Dilated cardiomyopathy. Dedicated recommendations have been published by the EACVI.[163] Irrespective of their cause, all DCM cases can be complicated by an LVT whose formation is promoted by the decrease in ventricular contractility,[164] dilatation of cardiac chambers,[165,166] and, in certain cases, the presence of endocardial lesions.[167] The incidence of LVT in DCM ranges from 11% to 44%.[167] AF increases this embolic risk.[168] In patients with non-ischaemic DCM, the risk of embolic events and ischaemic stroke is similar to that in patients with ischaemic cardiomyopathy.[164] The incidence of ischaemic stroke seems to be related to the degree of LVSD.[169]

Chagas disease is caused by the parasite *Trypanosoma cruzi*, and it is the most common cause of DCM in South America. Chagas cardiomyopathy has a particular high risk of thromboemboli. A risk score has been developed from a prospective study of 1043 patients with Chagas cardiomyopathy. The following risk factors are summed: age >48 years (1 point), ST-T changes on electrocardiogram (1 point), LV apical aneurysm (2 points), and any degree of LVSD (2 points). Patients with 4–5 points have an annual incidence of ischaemic stroke of 4.4% and no patient with a score of 0 had stroke.[6]

Hypertrophic and restrictive cardiomyopathies. Hypertrophic cardiomyopathy (HCM) is a genetically inherited condition with a large clinical spectrum and a wide variety of consequences, particularly the risk of sudden death, heart failure, and, to a lesser degree, ischaemic stroke.[170,171] The level of evidence in regard to the risk of cardiac emboli is weak. Maron *et al.*[172] compiled 900 patients in a registry, 51 of whom (prevalence rate 6%) presented with an ischaemic stroke or other vascular event during a mean follow-up of 7 ± 7 years. The registry also included 44 cases of cerebral infarction. The overall annual incidence was 0.8%, increasing to 1.9% for patients aged >60 years. Most events (72%) arose in patients aged >50 years, although 28% of the patients were <50 years. The onset of an ischaemic stroke or peripheral embolic event was independently associated with signs of congestive heart failure, increasing age, and AF (present in 88% of patients) at the time of the initial evaluation. The cumulative incidence of peripheral and cerebrovascular events in patients with AF was higher among those who were not receiving anticoagulant treatment vs. those taking vitamin K antagonists (31% vs. 18%; $P < 0.05$).[172] In addition, specific disease complications were more

Downloaded from https://academic.oup.com/ehjcimaging/article/22/6/e24/6168685 by Universiteit Leiden / LUMC user on 22 June 2022

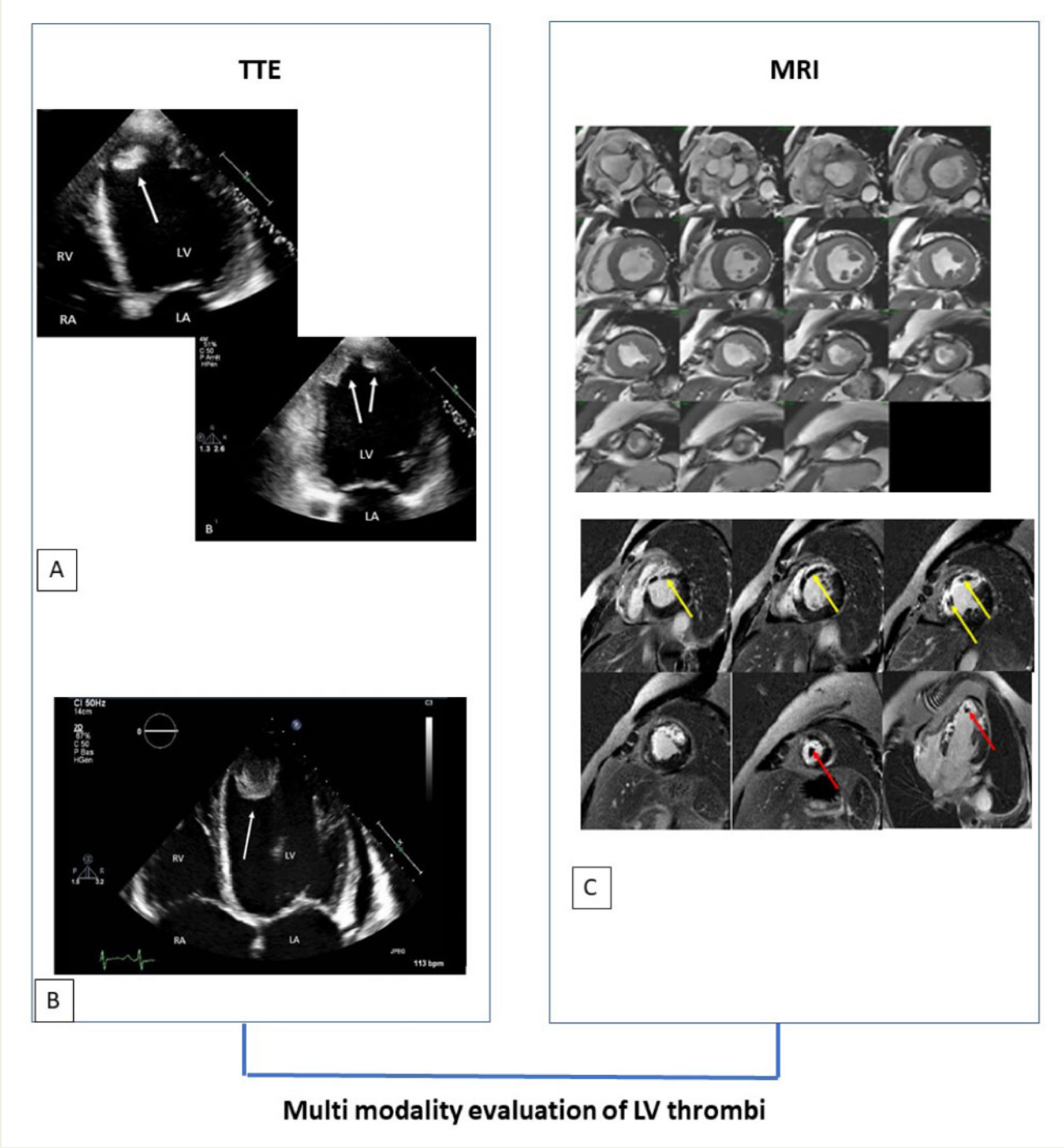

Figure 7 Multimodality evaluation of LVT. (*A*) 2D TTE four-chamber and two-chamber (*B*) of an apical LVT (arrow) in a patient with recent MI (see Supplementary data online, *Videos S3A* and *B*). (*B*) 2D TTE four-chamber. LVT (white arrow) in a patient with non-ischaemic cardiomyopathy. (*C*) Cardiac MRI: short-axis view with cine MRI on the left [SSFP sequence (balanced steady state free precession)] and late gadolinium enhancement on the right in a patient 48 h after ST-segment elevation MI involving the left anterior descending artery. Both no-reflow (yellow arrows) and LVT (red arrow) are present in the late gadolinium enhancement images (courtesy of Gilles Soulat, MD, PhD). 2D, two-dimensional; LA, left atrium; LVT, left ventricular thrombus; MI, myocardial infarction; MRI, magnetic resonance imaging; RA, right atrium; RV, right ventricle; SSFP, steady-state free precession; TTE, transthoracic echocardiography.

common in association with large or medium compared with small aneurysms, such as ischaemic stroke/LV apical thrombus (4 vs. 0).[173]

In a study that enrolled 593 patients with clinically diagnosed HCM (mean age at diagnosis 51.0 ± 15.6 years; mean follow-up 10.7 ± 7.5 years), 68 (11.5%) experienced ischaemic stroke and

Downloaded from https://academic.oup.com/ehjcimaging/article/22/6/e24/6168685 by Universiteit Leiden / LUMC user on 22 June 2022

embolic events.[174] Among the 431 patients without previously documented AF (39 with events and 392 without events), older age at diagnosis and LA dimension ≥48 mm were identified as independent determinants of an embolic event. The incidence of ischaemic stroke and embolic events was about 1.0% per year.[174] Rowin *et al.*[175] showed that there is evidence of apical aneurysm in 4.8% of all patients with HCM. Of these 4.8%, 14% had apical LVT, which was associated with thromboembolic events in non-anticoagulated patients. These findings emphasize the importance of CMR in HCM. Moreover, in HCM patients with cardioembolic events, a dedicated assessment for LV apical aneurysm is needed to guide management (including contrast TTE, and possibly adding CT/MRI). Multimodality imaging techniques are essential for the diagnosis, prognostic evaluation, and management of patients with restrictive cardiomyopathy.[176] In restrictive cardiomyopathy, patients with cardiac amyloidosis, and particularly those with AL (amyloid light-chain) type and AF, have a very high risk for thromboemboli. Amyloid infiltration of the atria and atrial mechanical dysfunction predispose to atrial thrombi. Intracardiac thrombi were present in 33% of explanted or autopsied hearts of patients with amyloid cardiomyopathy in a case series of 116 patients from the Mayo Clinic.[177] Of the 63 thrombi found in this autopsy study, only one was an LVT.[177] Embolic risk in restrictive cardiomyopathy is mediated by atrial dysfunction, and LVT is uncommon.

Other cardiomyopathies. Isolated LV non-compaction is characterized by trabeculations with deep intertrabecular recesses in which thrombi may form. A retrospective study of 144 patients with LV non-compaction found a prevalence of cardioembolic stroke of 10%. The majority of patients had either AF or LVSD.[178]

Takotsubo or stress cardiomyopathy is a transient form of regional LVSD, most commonly involving the mid and apical left ventricle. Ventricular thrombus was present in 1.3% patients with takotsubo cardiomyopathy in a registry of 1750 patients.[179]

Heart failure. Olsson *et al.*[180] reported on a study in 7599 patients divided on the basis of their baseline LVEF (≤40% or >40%) and monitored for a mean of 37.7 months. Patients with AF and low LVEF had the highest absolute risk of cardiovascular events. Patients with AF and low ejection fraction had the highest absolute risk of adverse cardiovascular outcomes (e.g. 45% with cardiovascular death or congestive heart failure hospitalization) relative to those with low ejection fraction and sinus rhythm (37% with an event), preserved ejection fraction, and AF (34% with an event), or preserved ejection fraction and sinus rhythm (21% with an event).[180] AF at baseline remained an independent predictor of all-cause death regardless of baseline ejection fraction: preserved ejection fraction HR 1.37 (95% CI 1.06–1.79) and low ejection fraction HR 1.22 (95% CI 1.04–1.43).

In a retrospective study, Doukky *et al.*[181] showed that diastolic function indices E/e' and e' were independently associated with LAAT in non-valvular AF.

Heart failure is associated with increased risks of ischaemic stroke and intracerebral haemorrhage at short- and long-term follow-up.[182] The associations persist in patients without AF or flutter, across age groups and sexes.[182] Di Tullio *et al.*[183] showed that among patients with systolic heart failure and sinus rhythm, LVEF of <15% more than doubled the risk of ischaemic stroke. In randomized clinical trials, the overall rate of ischaemic stroke in patients with heart failure with preserved ejection fraction and patients without AF (1.0% per year[184]) was similar to the rate reported in patients with heart failure with reduced ejection fraction without AF (CORONA study, 1.2% per year).[185] The CORONA study did not show that LVEF was an independent predictor of stroke risk; however, only patients with an LVEF ≤45% were included.[185]

Recommendations for identification and evaluation of LVT

TTE is recommended for the evaluation of patients with cardiac conditions who are at risk of LVT formation (e.g. MI, cardiomyopathy, severe LV systolic dysfunction, non-compaction and takotsubo cardiomyopathies).

TOE is not indicated when looking for LVT.

Contrast echocardiography and 3D echocardiography have to be considered to better characterize LVT. According to local facilities, CMR could be preferred for its sensitivity.

CMR has higher sensitivity for identification of LV thrombi and should be used when TTE is of suboptimal quality or when the TTE is negative in the setting of suspected apical thrombus.

Repeated TTE is indicated to monitor resolution of LVT after 4–6 weeks of anticoagulation.

3D, three-dimensional; CMR, cardiac magnetic resonance; LV, left ventricular; LVT, left ventricular thrombus; MI, myocardial infarction; MR, magnetic resonance; TOE, transoesophageal echocardiography; TTE, transthoracic echocardiography.

Cardiac masses

Intracardiac tumours

Primary benign cardiac tumours, a rare condition with a post-mortem incidence of 0.1–0.3%,[186] may affect the endocardium, myocardium, or epicardium. Three-quarters of primary cardiac tumours are benign. Atrial myxomas are the most prevalent type among benign tumours, whereas cardiac sarcomas are the most frequent type among malignant ones.[187]

The clinical presentation of cardiac tumours depends on the histological type, morphology, and intra-cardiac location. Four different clinical manifestations can be produced by a cardiac tumour: systemic (e.g. fever, fatigue, weight loss), embolic, cardiac, and metastatic. The evidence to build a strong recommendation is limited.

Myxoma. Cardiac myxomas are generally sporadic tumours of endocardial origin and are typically located in the LA opposite the fossa ovalis region. They can also be located atypically in other areas of the LA, in the right atrium (RA), or in the ventricles. Mean age at diagnosis is 50 years, with 90% of patients aged 30–60 years.[188] 'Carney syndrome' is present in 10% of cases and is characterized by multiple and recurrent familial myxomas affecting young patients, people with endocrine disorders or with a spotty skin pigmentation.[189]

The macroscopic appearance of a myxoma may be polypoid, often pedunculated or papillary, with villous extensions.[190] Microscopically, myxomas are formed by a myxoid substance. Intratumoural haemorrhage or calcifications are often present.

Downloaded from https://academic.oup.com/ehjcimaging/article/22/6/e24/6168685 by Universiteit Leiden / LUMC user on 22 June 2022

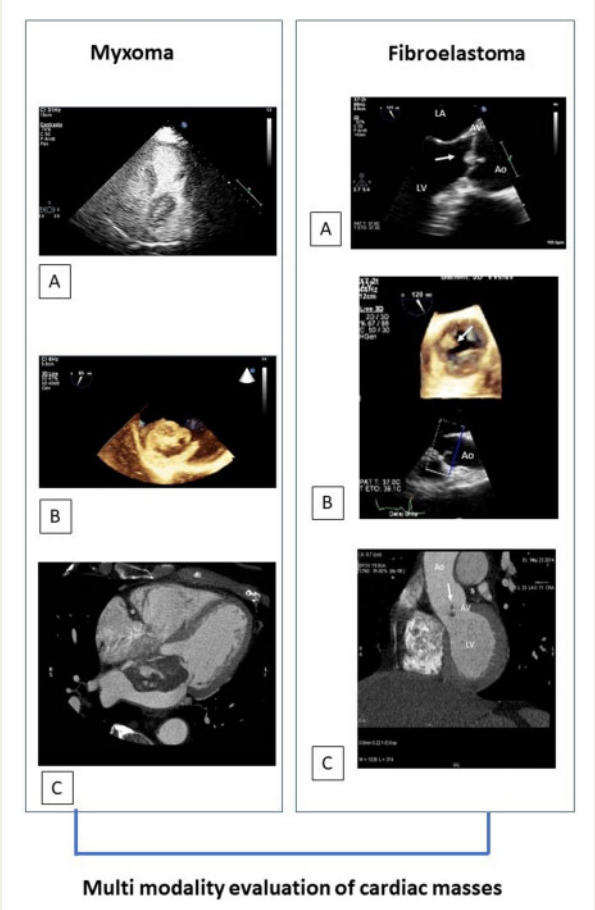

Figure 8 Multimodality evaluation of cardiac masses. Myxoma (left): same patient with LA myxoma: 2D TTE after (*A*) Sonovue perfusion; (*B*) 3D TOE; and (*C*) cardiac CT (see Supplementary data online, *Video S4A* and *B*, *Videos S5–S7*). Fibroelastoma (right): (*A*) 2D TOE 120°; (*B*) 3D TOE live 3D; and (*C*) cardiac CT: aortic fibroelastoma on the non-coronary cusp (white arrow) (see Supplementary data online, *Video S8A*and *B*) 3D. 2D, two-dimensional; 3D, three-dimensional; Ao, thoracic aorta; AV, aortic valve; CT, computed tomography; LA, left atrium; LAA, left atrial appendage; LV, left ventricle; MV, mitral valve.

The clinical manifestations of a cardiac myxoma are represented by systemic symptoms, secondary embolization, or intracardiac obstruction.[191] Myxoma embolization occurs in up to 75% of patients[192] and is associated with high morbidity and mortality. Owing to the tumour localization, systemic embolization (including cerebral arteries with ischaemic stroke and retinal arteries with secondary visual loss) is frequent. The risk factors for embolic events are irregular surface, atypical localization, and large tumour size.[193] Imaging can provide important information for diagnosis and management: localization, insertion, size, appearance, mobility, and features of embolic risk.

The main imaging modality for myxoma diagnosis is TTE, whereas TOE is often necessary for morphological details (e.g. localization of the attachment point). On cardiac CT, myxomas appear as isodense or slightly hypodense masses with weak enhancement after iodine contrast injection. Therefore, the differential diagnosis with a thrombus may be difficult.[194] On MRI, myxomas have a homogeneous hyperintense signal intensity on T2-weighted images, an isointense aspect on T1-weighted images, low signal on early gadolinium enhancement, and intense signal enhancement on late gadolinium enhancement, often with a hypointense core due to haemorrhage.[194] Gadolinium enhancement imaging is an important method for differentiating myxomas and thrombi.[195]

Fibroelastomas. Papillary fibroelastomas are papillary lesions of the endocardium, generally located on the surface of cardiac valves (80–90%), making them the most common valve tumour.[196,197] The aortic valve is most frequently affected.[198] Cardiac papillary fibroelastomas are benign tumours with an incidence of 0.002–0.33% in autopsy series, with incidence increasing with age.[199] Fibroelastomas represent almost 10% of intracardiac tumours.[200] The typical macroscopic description for a papillary fibroelastoma is a 'sea anemone' due to its round shape with digitations.[201] Microscopically, the tumour consists of connective tissue lined by endothelium.

The clinical manifestation of these tumours is very variable, from asymptomatic incidental discoveries during echocardiography to ischaemic stroke or even sudden cardiac death due to tumour embolization.[200] Tumour localization (aortic valve), mobility, and dimensions are predictors of arterial embolization.

Echocardiography is the first-line imaging modality. The echocardiographic appearance of a papillary fibroelastoma is a pedunculated free-moving mass with high-frequency oscillations during the cardiac cycle, with variable dimensions from a few millimetres to a few centimetres (rarely >3 cm), attached to the middle portion of the cardiac valves but without any valvular destruction (enclosure is exceptional and, although possible, regurgitation is minimal).[198,202] On cardiac MRI, the tumour might be not easily visualized due to its small size

Recommendations for evaluation of cardiac masses

The presence of a tumour may lead to a rapid surgical decision and this decision should not be delayed by performing a useless diagnostic examination. However, when making the decision on whether or not to operate, a multimodality approach is often requested. Cardiac CT and CMR are often considered in addition to echocardiographic exams. A PET scan may also be valuable when a metastasis or primary cardiac tumour is sought.

TOE (with 3D capabilities if possible) is recommended in addition to TTE in evaluating cardiac tumours (e.g. myxoma, papillary fibroelastoma).

Contrast echocardiography or 3D echocardiography is recommended to better characterize cardiac masses (atria > ventricles).

CT can be a helpful complementary tool to differentiate a myxoma from a thrombus in cases in which TTE/TOE is inconclusive.

CMR imaging is considered as the modality of choice for evaluating cardiac tumours.

3D, three-dimensional; CMR, cardiac magnetic resonance; CT, computed tomography; PET, positron emission tomography; TOE, transoesophageal echocardiography; TTE, transthoracic echocardiography.

Downloaded from https://academic.oup.com/ehjcimaging/article/22/6/e24/6168685 by Universiteit Leiden / LUMC user on 22 June 2022

and high mobility, but may be described as a hypointense mobile mass on cine images.[195]

The differential diagnosis of the tumour includes valvular calcifications, thrombi, vegetations (generally associated with valvular destructions), strands, and Lambl's excrescences (generally arising from the coaptation line). *Figure 8* illustrates the use of multimodality imaging in the diagnosis of cardiac masses.

Valvular vegetations

Infective endocarditis. Cerebral emboli are a frequent complication of infective endocarditis and are related to the migration of infected valvular vegetations in the cerebral arteries.[203] These emboli occur in 15–30% of patients with infective endocarditis, can arise at any time during the disease (before and during treatment), and are associated with a worse prognosis.[204–207]

Echocardiography plays a major role in the assessment of embolic risk in patients with infective endocarditis.[203,208] The 2015 European Society of Cardiology guidelines for the management of infective endocarditis recommend that both TTE and TOE are performed in patients with suspected or definite infective endocarditis.[204] In a meta-analysis of 16 observational studies, the diagnostic properties of TTE for detecting infective endocarditis findings was compared with those of TOE. For detecting vegetations, TTE had a sensitivity of 61% and a specificity of 94%, and thus had the potential to miss many vegetations detected on TOE.[209]

Several factors have been associated with an increased risk of cerebral embolism.[204,210,211] Among them, the size and mobility of the vegetations are the most potent independent predictors of a new embolic event[211,212] (Supplementary data online, *Table S6*). Patients with vegetations >10 mm are at higher risk of embolism and this risk is even greater in patients with very large (>15 mm) and mobile vegetations, especially in staphylococcal infective endocarditis.[208] An observational study[213] found that the risk of neurological complications was even higher in patients with very large (>30 mm) vegetations. In a study of 847 patients with infective endocarditis, the 6-month incidence of new embolism was 8.5%. Six factors (age, diabetes, AF, previous embolism, vegetation length, and *Staphylococcus aureus* infection) were associated with an increased embolic risk and were used to create an 'embolic risk calculator'.[211]

The risk of embolism is particularly high during the first days after the initiation of antibiotic therapy and decreases after 2 weeks,[207] although some risk persists indefinitely while vegetations remain present, particularly for very large vegetations.[213] For this reason, the benefit of surgery to prevent embolization will be greatest during the first week of antibiotic therapy, when the embolic rate is highest.[204]

In addition to echocardiography, other imaging techniques should be used for the assessment of patients with neurological complications of infective endocarditis (Figure 9). These include ^{18}F-fluorodeoxyglucose positron emission tomography (PET) CT, which is particularly useful for the diagnosis of prosthetic valve infective endocarditis,[204,214,215] and cerebral imaging, which is mandatory in patients with suspected or definite neurological complications of infective endocarditis. This may include CT scanning, with or without contrast, and/or MRI, depending on the neurological status of the patient.[204]

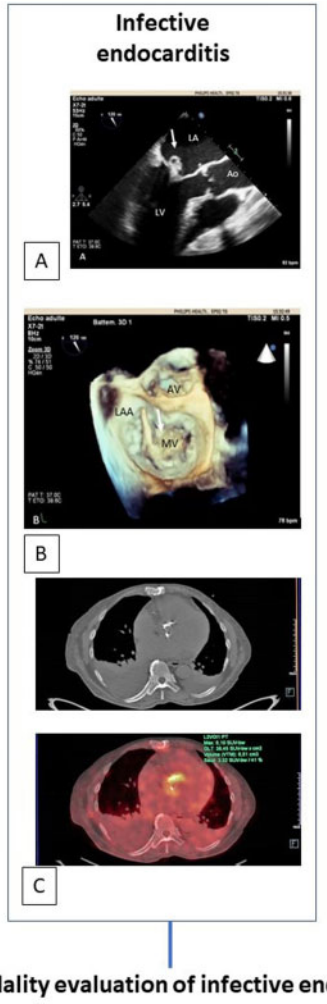

Figure 9 Multimodality evaluation of infective endocarditis. (*A*) 2D TOE 120° and (*B*) 3D TOE zoom 3D: mitral posterior valve vegetation in an active endocarditis (white arrow) complicated with ruptured chordae tendineae; (*C*) ^{18}F-FDG PET/CT images show infected prosthetic aortic valve (see Supplementary data online, *Video S9*). Ao, thoracic aorta; AV, aortic valve; CT, computed tomography; FDG, fluorodeoxyglucose; LA, left atrium; LAA, left atrial appendage; LV, left ventricle; MV, mitral valve; PET, positron emission tomography.

In a meta-analysis of 20 studies (including 496 patients) with prosthetic valve infective endocarditis, TTE, TOE, and multidetector CT plus TOE had a pooled sensitivity/specificity for vegetations of 29/100%, 82/95%, and 88/94%, respectively. Although multidetector CT data are limited, this review showed that multidetector CT in addition to TOE may improve sensitivity in detecting life-threatening periannular complications.[216]

Downloaded from https://academic.oup.com/ehjcimaging/article/22/6/e24/6168685 by Universiteit Leiden / LUMC user on 22 June 2022

Marantic vegetations. Non-bacterial thrombotic endocarditis

Non-bacterial thrombotic endocarditis (NBTE) is a form of non-infectious endocarditis that most commonly affects patients with advanced cancer (known as marantic endocarditis) and systemic lupus erythematosus (known as Libman–Sacks endocarditis), but also other chronic diseases.[217–219] In these conditions, endothelial damage and a hypercoagulable state concur to form sterile vegetations composed of bland fibrin–platelet thrombi. These lesions can affect both undamaged and damaged cardiac valves, as well as the chordae tendineae or the endocardium. They are classically found in mitral and aortic valves along valvular coaptation lines and are usually small, broad based, and irregularly shaped.[220] In comparison to the lesions in infective endocarditis, the weak inflammatory reaction at the site of attachment renders NBTE vegetations more friable and prone to systemic embolization, although they are less destructive and rarely cause a significant degree of valvular dysfunction.[221]

The typical clinical presentation of NBTE is systemic embolization. The incidence of cerebral ischaemia is higher in NBTE than in infective endocarditis (33% vs. 19%).[222,223] Patients with NBTE tend to have evidence of multiple, widely distributed brain infarcts on diffusion-weighted MRI, whereas single lesions or focal infarcts are more characteristic of infective endocarditis.[224]

The diagnosis of NBTE can be challenging and relies on strong clinical suspicion. Laboratory studies and imaging techniques play a decisive role in confirming a predisposing disease, establishing the presence of valvular vegetations using echocardiography, and ruling out infective endocarditis. TOE should be ordered when there is a high suspicion of NBTE. TOE has a higher sensitivity and specificity than TTE for the detection of NBTE; it should be considered either as a complement to a non-diagnostic TTE or as the initial test in patients with suspected cardioembolism, moderate or worse valve dysfunction, or superimposed infective endocarditis.[225,226]

Recommendations for evaluation of valvular vegetations

TTE is recommended as the first-line imaging modality in suspected infective endocarditis.

TOE is recommended in patients with a high clinical suspicion of infective endocarditis and a normal TTE, and when a prosthetic heart valve or an intracardiac device is present.

TOE should be considered in the majority patients with suspected infective endocarditis, even in cases with positive TTE findings.

Repeat TTE/TOE within 5–7 days is recommended in case of initially negative examination when clinical suspicion of infective endocarditis remains high.

Additional imaging techniques (cardiac CT, PET/CT) that allow the diagnosis of embolic events and cardiac involvement should be performed when TTE/TOE findings are negative or doubtful.

^{18}F-fluorodeoxyglucose PET/CT is predictive of major cardiac events in prosthetic valve endocarditis and new embolic events within the first year following infective endocarditis.

TOE is recommended in case of systemic lupus erythematosus with or without primary antiphospholipid antibody syndrome and ischaemic stroke/TIA or neurological manifestations plus focal lesions on cerebral MRI.

Continued

Continued

Recommendations for evaluation of valvular vegetations

TTE is indicated in patients with cancer (e.g. lymphoma, carcinoma of the gastrointestinal tract, and carcinoma of the lung) who have an ischaemic stroke or arterial embolism to document marantic vegetations.

TOE should be used in the characterization of valvular masses (differential diagnosis based on clinical and biological arguments).

CT, computed tomography; PET, positron emission tomography; MRI, magnetic resonance imaging; TIA, transient ischaemic attack; TOE, transoesophageal echocardiography TTE, transthoracic echocardiography.

When an early TOE examination is performed, the prognosis of NBTE is improved.[227] A prospective study that compared paired 3D TOE with 2D TOE in 29 patients with systemic lupus erythematosus and manifestations of cerebrovascular disease demonstrated that although 2D TOE has high diagnostic value for the detection of Libman–Sacks vegetations, 3D TOE provides clinically relevant additional information that complements 2D TOE for the detection, characterization, and clinical correlations of Libman–Sacks endocarditis.[228] Following embolization, small remnants (≤3 mm) on affected valves may result in false negative echocardiography results.[204]

Aortic arch atheromatous plaques

Imaging of the aorta is essential in the evaluation of ischaemic stroke and peripheral embolization. Atherosclerotic plaque is the most common source of embolism originating from the aorta (Supplementary data online, *Tables S7 and S8*).[229–234] In rare instances, embolism can arise from mobile thrombi[235,236] or aortic tumours.[237] Atherosclerotic plaques are a manifestation of general atherosclerosis and are associated with known atherosclerosis risk factors such as hypertension, diabetes mellitus, advanced age, hypercholesterolaemia, inflammation, and tobacco smoking.[238,239] Atherosclerotic plaques in the aorta may cause either thrombotic (thromboembolic) or atherosclerotic (cholesterol crystal) emboli.[240] Thromboemboli are usually large and commonly occlude medium-to-large arteries, causing ischaemic stroke, TIA, renal infarct, and peripheral thromboembolism. By contrast, cholesterol crystal emboli tend to occlude small arteries and arterioles and may cause 'blue-toe' syndrome, renal insufficiency, or mesenteric ischaemia. This atheroembolic syndrome can arise spontaneously,[241] after the aorta is instrumented during angiography or arterial catheterization,[242,243] or after heart surgery involving clamping of the aorta.[244] Finally, mobile thrombi of the aorta without diffuse atherosclerosis mostly located at the aortic arch have been reported since the introduction of TOE imaging for patients with cerebral or peripheral emboli. Clots floating in the aorta frequently become embedded in atherosclerotic plaque and carry a high embolic risk.[236]

The detection, characterization, and quantification of aortic plaques can be accomplished by TOE, CT, or MRI. Several classifications have been proposed to quantify severity of aortic atherosclerosis.

Downloaded from https://academic.oup.com/ehjcimaging/article/22/6/e24/6168685 by Universiteit Leiden / LUMC user on 22 June 2022

However, based on the results of most studies, atherosclerosis severity is considered mild when intimal thickening (focal or diffuse) is 2–3 mm (grade I), moderate when the atheroma is <4 mm (grade II), severe when the atheroma is ≥4 mm (grade III), and complex when any grade has associated mobile or ulcerated components (grade IV).[245,246]

TOE provides higher resolution images than TTE for diagnosing aortic atheroma. TOE characterizes the plaque by measuring plaque thickness, ulceration, calcification, and superimposed mobile thrombi, thereby determining the embolic potential of each plaque. Compared with 2D TOE, 3D TOE provides superior visualization of the number, morphology, volume, and spatial extent of aortic atheromas.[247] Assuming the intrinsic limitation of suprasternal TTE, this approach may be helpful for the preliminary screening of atherosclerotic plaques in the aortic arch. In one study, adequate transcutaneous image quality could be achieved in 84% of cases.[248] This approach may help to identify subjects at higher risk of subclinical cerebrovascular disease.[249] However, the low negative predictive value of TTE does not allow aortic plaques to be ruled out or a complex lesion to be correctly established.

The prevalence of aortic atheromas on TOE varies depending on the population studied. In a community study,[250] aortic atheromas were present in 51% of randomly selected residents aged ≥45 years, with a greater prevalence in the descending aorta. Complex atheromas were present in 7.6%. In patients with known significant carotid artery disease, the prevalence of aortic atheromas was 38%, and 92% in those with significant coronary artery disease.

Aortic plaques with a complex lesion are a risk factor for recurrent ischaemic stroke, silent brain infarction, and peripheral thromboembolic events in patients with ischaemic stroke[229,230] or TIA.[231] This association has been described for proximal aortic plaques, particularly in the aortic arch[232–234]; however, no clear association exists between the presence of descending aortic plaques and thromboembolic events. Complex and severe atheromas of the ascending aorta and aortic arch are associated with cerebral and peripheral embolic complications.[229,239] A meta-analysis[251] has identified an increased risk of cerebral infarction in patients with a plaque ≥4 mm in thickness, regardless of whether the two principal risk factors for cerebral infarction in older adults (i.e. carotid stenosis and AF) were also present. In addition to the presence of a plaque ≥4 mm, the risk of recurrent cerebral infarction is also higher in patients with ulcerated, uncalcified plaques, and plaques with mobile elements.[234,246] Attention has been drawn to some of the factors involved in aortic thrombosis,[252] such as hypercoagulability[253] and high homocysteine[238] or ultra-sensitive C-reactive protein levels, independently of other atherosclerotic risk factors.[254]

Few studies have focused specifically on the relationship between atheroma and peripheral artery embolism outside the cerebrovascular region.[255] However, TOE is indicated for the diagnosis of complex atheroma or the presence of a large mobile thrombus of the aorta, an infrequent cause of systemic emboli, which appears to be a complication of atherosclerosis, but is not always extensive or severe.

Multidetector CTA of the aorta can also be used to detect aortic atheromas. Its sensitivity, specificity, and overall accuracy for identifying a severe aortic atheroma are similar to those of TOE, the reference method.[256–258] Calcified plaque appears as a light, high-attenuation signal, whereas lipid-rich or fibrous plaque appears as hypo-attenuated dark signals within the vessel wall. In a retrospective study, CTA had a high negative predictive value for aortic arch disease atheromas; however, sensitivity for detecting grade 1–4 atheromas was 53%.[259] Benyounes *et al.*[260] observed that agreement between CTA and TOE is poor (61%) and that CTA lacks sensitivity but had high specificity (93%) for detecting aortic arch atheromas. Nevertheless, CTA has improved and can be reasonably considered in routine clinical practice.

MRI provides information on plaque characteristics.[261,262] However, MRI has limited utility for assessing mobile thrombi that are often superimposed on plaques. Moreover, its spatial resolution is inferior to that of CT. Compared with TOE, MRI overestimates plaque thickness and consequently classifies more patients as at high risk (≥4 mm plaque thickness).[263] 3D multicontrast MRI vessel wall imaging is capable of characterizing at-risk atherosclerotic plaques in the thoracic aorta.[264] A recent study[265] using a 3D multicontrast protocol was tailored to characterize aortic plaque. The CMR sequences showed high intra- and interobserver agreement regarding image quality grading of the 3D sequences and assessment of four-dimensional flow path lines. A high intra- and inter-rater agreement of plaque classification evaluation according to American Heart Association definitions.[266]

Figure 10 illustrates the use of multimodality imaging in the diagnosis of aortic arch atheromatous plaques.

Prosthetic cardiac valves (e.g. mechanical, biological, clips)

Intracardiac devices and prosthetic valves represent a major source of embolism. The presence of an intracardiac material in the setting of an embolic event raises a high level of suspicion of a cardioembolic source. A TOE is, in most cases, indicated within 48 h.

Two complications of prosthetic valve replacement must be suspected when an embolic event occurs in a patient with a valve: prosthetic valve infective endocarditis (see section Infective endocarditis) and prosthetic thrombosis. Prosthetic thrombosis is one of the most severe complications of mechanical heart valves, although it has been less frequently observed in other types of valve substitute. Particular attention should be taken to the bioprosthesis, and especially to transcatheter aortic valves.[267] Situations at risk include the early post-operative period, interruption of anticoagulant therapy, and pregnancy.[267–269] Both TTE and TOE must be performed in suspected prosthetic valve thrombosis as soon as possible:

- In severely obstructive thrombosis, TTE is the first-line examination and may provide evidence of an abnormal transprosthetic colour flow jet, an elevated Doppler transprosthetic gradient, and a reduced effective orifice area.
- A high transvalvular gradient is of great value for the diagnosis of prosthetic thrombosis, especially when comparison with a reference value is available.
- Although direct evidence of valve thrombus may be obtained by TTE, TOE is the method of choice to diagnose the main signs of prosthetic thrombosis (restricted leaflet or disc motion, abnormal central regurgitation, loss of physiological regurgitant jets in mechanical valves, and direct visualization of thrombus or pannus formation).
- Cinefluoroscopy may also be useful assess leaflet motion of mechanical prostheses.

Downloaded from https://academic.oup.com/ehjcimaging/article/22/6/e24/6168685 by Universiteit Leiden / LUMC user on 22 June 2022

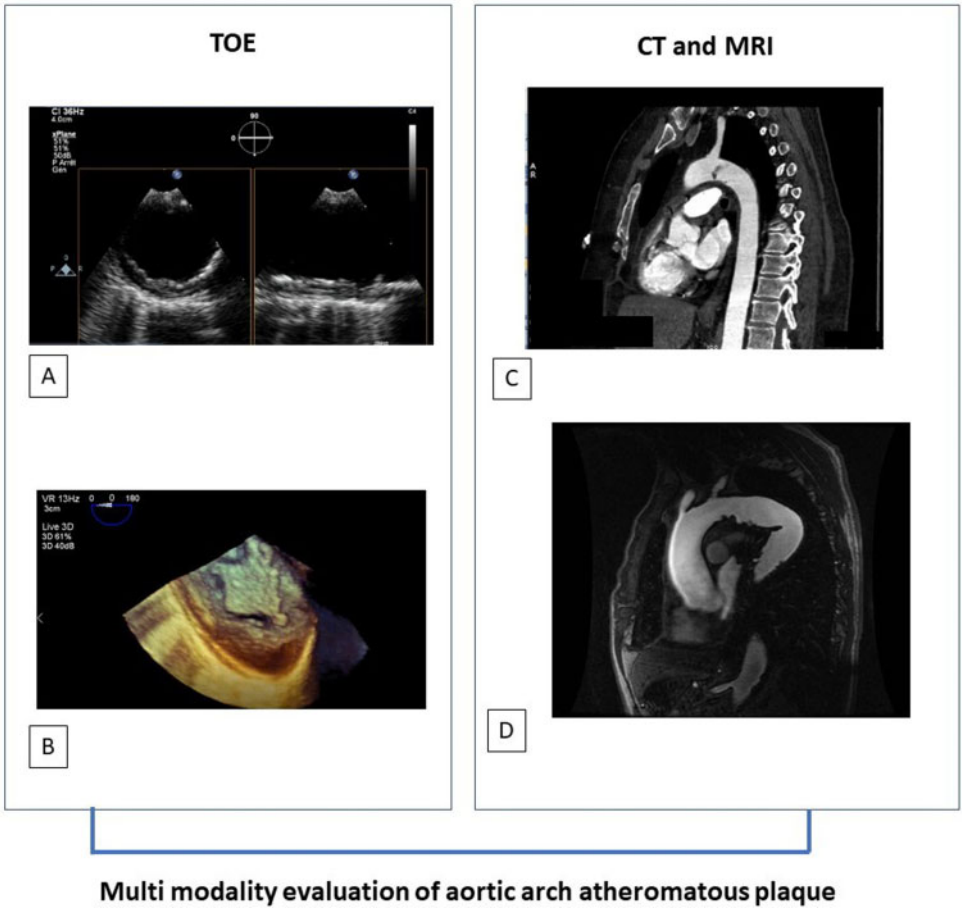

Figure 10 Multimodality evaluation of aortic arch atheromatous plaque: TOE (left) and CTA and angio MRI (right). (*A*) 3D TOE Xplane showing complex atheroma (≥4 mm in thickness and/or mobile components) of the ascending thoracic aorta with mobile components; (*B*) 3D live reconstruction of complex atheroma of the ascending thoracic aorta; (*C*) CTA and (*D*) angio MRI showing atherosclerotic arch plaques >4 mm (courtesy of Gilles Soulat, MD, PhD) (see Supplementary date online, *Videos S10* and *S11*).

Recommendations for evaluation of aortic arch atheromatous plaques
TOE is the reference echocardiographic method for the evaluation of thoracic aortic atherosclerosis location (descending, arch, ascending aorta) and severity (complex thoracic aortic plaques).[234]
TOE is the reference echocardiographic method for the description of complex thoracic aortic plaques (plaque thickness, ulceration, mobile elements suggesting thrombus).
TOE can characterize aortic plaques as a surrogate marker of ischaemic stroke risk, irrespective of AF or carotid stenosis.
TTE (suprasternal window when available) can be used to identify aortic arch atheromas.
CT is competitive with TOE in aortic plaque (ascending and arch thoracic aorta) characterization.
MRI can be proposed in aortic wall and atherosclerotic plaque characterization.

AF, atrial fibrillation; CT, computed tomography; MRI, magnetic resonance imaging; TOE, transoesophageal echocardiography; TTE, transthoracic echocardiography.

TOE is very helpful for assessing the extent of thrombus formation. Cardiac CT could be also considered. Recent evidence from expert teams demonstrates the great value of cardiac CT for identifying thrombi that are not easily seen on echocardiography.[270,271]

The risk of embolism and complications in prosthetic thrombosis is related to the size of the thrombus, with a large thrombus (≥0.8 cm^2) being a major risk factor for complications of thrombolytic treatment.[272] Thus, TOE may help in the choice between surgery and anticoagulant or thrombolytic therapy. TTE and TOE must also

Downloaded from https://academic.oup.com/ehjcimaging/article/22/6/e24/6168685 by Universiteit Leiden / LUMC user on 22 June 2022

be used for the follow-up of patients with prosthetic thrombosis after initiation of specific therapy.[273]

Diagnosis of partial prosthetic thrombosis is difficult, especially when obstruction is mild or absent. TTE is of limited value in this setting and TOE is the method of choice for the diagnosis of small prosthetic thrombosis. However, the diagnosis of prosthetic thrombosis, even with TOE, suffers from some limitations. First, small abnormal echoes around the prosthesis may also be observed in prosthetic endocarditis, and it may be difficult to differentiate thrombus formation from vegetation. Moreover, examination of aortic prostheses is often difficult when a mitral prosthesis is also present, owing to attenuation of the ultrasound beam. Cardiac CT should be considered after clear agreement about the setting required to get valuable results from the CT acquisitions.[270]

Recommendations for prosthetic heart valves

TTE must be performed within the 48 first hours in patients with a prosthetic valve and an embolic event.

TOE must be performed in patients with a prosthetic valve and an embolic event, even if the results of TTE are negative.

TOE plays an important role in guiding the therapeutic strategy in prosthetic thrombosis, the presence of a large thrombus favouring surgery. Cinefluoroscopy should not be forgotten in case of a mechanical prosthesis, and cardiac CT should be considered.

Repeated TTE/TOE is recommended for follow-up after thrombolytic therapy or anticoagulant therapy of a prosthetic valve thrombosis.

CT, computed tomography; TOE, transoesophageal echocardiography; TTE, transthoracic echocardiography.

Minor or undetermined cardiac sources of cerebral embolism

Atrial septal abnormalities

Atrial septal aneurysm

Atrial septal aneurysm (ASA) is defined as excursion of septal tissue (typically the fossa ovalis) >10 mm from the plane of the atrial septum into the RA or LA, or a combined total excursion right and left of 15 mm.[274] Excursion of the atrial septum can be documented by 2D imaging as well as by M-mode when the cursor can be aligned perpendicular to the plane of the interatrial septum. This can be done in the subcostal four-chamber views by TTE or in the bicaval views by TOE. The incidence of ASA in the general population, as estimated by TTE, is considered to be only 0.23%,[275] rising to 4.6% in TOE studies.[22] The link between ASA and PFO is well established, with approximately 60% of patients presenting with ASA plus PFO.[275] ASA has also been associated with multiple septal fenestrations, and this should be evaluated carefully by colour Doppler.[276–278] TOE is a more sensitive method than TTE for evaluating ASA. The presence and extent of an ASA is a factor in device selection for PFO closure. A relatively large device can be chosen to encompass and stabilize the atrial septum or a smaller and softer device for better conformation with the ASA.

The link between ASA and systemic embolism was initially described from isolated cases.[279] In one series,[280] the incidence of ASA was estimated to be 2.2% in the general population, significantly lower than the 7.2% incidence in patients undergoing TOE after an ischaemic stroke ($P = 0.002$). The embolic mechanisms proposed included a thrombus in the ASA, a paradoxical embolism from a venous thrombus through a PFO or coexisting paroxysmal AF.[281]

Patent foramen ovale

PFO is a flap-like opening between the septum primum and septum secundum at the fossa ovalis. During foetal life, the foramen ovale plays a physiological role, with the purpose of directing most oxygenated placental blood from the RA to the LA, avoiding the pulmonary bed. A PFO is the result of the failure of the septum primum and septum secundum to fuse postpartum. The reported prevalence of PFO in the general population is 25%, increasing to over 50% in patients with cryptogenic stroke.[275,282] Paradoxical embolism occurs when there is embolic transit from the systemic venous circulation to the systemic arterial circulation through a right-to-left shunt, such as a PFO or atrial septal defect. PFO refers to when right-to-left shunting of blood has been demonstrated by saline contrast injection without a true deficiency of the interatrial septum. Typically, the PFO is closed due to the gradient between the LA and RA, and no left-to-right shunting is seen. Under certain haemodynamic conditions, such as elevated right atrial (RA) pressure due to acute or chronic pulmonary hypertension, cough, or with a Valsalva manoeuvre, a right-to-left shunt can be seen.

The presence of PFO is presumed when agitated saline contrast is observed in the LA within three cardiac cycles after complete opacification of the RA.[283,284] Injections should be given at rest and with certain provocative manoeuvres such as cough and the Valsalva manoeuvre to increase RA pressure. Deviation of the interatrial septum to the LA side confirms elevated RA pressure. If agitated saline contrast is noted after five cardiac cycles, pulmonary arteriovenous malformations must be considered.[285,286] Elevated LA pressure from LV failure or mitral valvular disease can prevent right-to-left shunting, because higher RA pressure is required to overcome the elevated LA pressure. In a study comparing patients with or without left heart disease, the detection of PFO was 5% in patients with left heart disease and 29% in those without left heart disease.[287]

TTE, TOE, and transcranial Doppler are useful for the diagnosis of PFO[16,284] (Supplementary data online, *Table S9*). Transcranial Doppler records high-intensity transient signals, representing microbubbles passing through the middle cerebral artery. TTE is the primary method reported to characterize the presence of right-to-left shunting through a PFO and remains the most commonly used screening test due to its non-invasiveness and wide availability. The accuracy of TTE vs. TOE as the reference has been evaluated in a meta-analysis, which included 13 studies with 1436 patients.[288,289] The weighted mean sensitivity and specificity for TTE were 46% and 99%, respectively. Using different contrast agents, different

Downloaded from https://academic.oup.com/ehjcimaging/article/22/6/e24/6168685 by Universiteit Leiden / LUMC user on 22 June 2022

microbubble cut-offs for a positive TTE/TOE, and different cardiac cycle cut-offs for a positive TTE/TOE, did not affect the accuracy of TTE. In a population of patients with cryptogenic stroke, TOE had a sensitivity of 89% and a specificity of 91% for the diagnosis of PFO. The low negative likelihood ratio of TOE suggests that it is a proficient test of exclusion for PFO.[290]

In a systematic review of all prospective studies that assessed the accuracy of TOE for the detection of PFO using confirmation by autopsy, cardiac surgery, and/or catheterization as the reference, only four studies met the inclusion criteria.[290] Among 164 patients, TOE had a weighted sensitivity of 89% and a specificity of 91% to detect PFO.[290]

TTE is recommended first and should be performed as its sensitivity is important and it is easier to perform the Valsalva manoeuvres during a TTE. TOE is recommended in addition, but could be less sensitive according the condition of the examination.[290–293] Transcranial Doppler is a viable alternative to contrast TTE for screening, with higher sensitivity than TTE, but with the disadvantage of being unable to identify associated lesions, such as ASA, and failure to distinguish pulmonary from cardiac sources of shunting.[294]

A meta-analysis compared transcranial Doppler with TOE as the reference; both tests were performed with a contrast agent and a manoeuvre to provoke right-to-left shunt.[288] A total of 27 studies (29 comparisons) with 1968 patients (mean age 47.8 ± 5.7 years; 51% men) fulfilled the inclusion criteria. The weighted mean sensitivity and specificity for transcranial Doppler were 97% and 93%, respectively.[288]

A simultaneous study of TTE, TOE, and transcranial Doppler showed TTE to be more sensitive than TOE for the diagnosis of PFO.[295] TOE returned a false negative result in 10% of patients, and tended to underestimate the severity of right-to-left shunt. Transcranial Doppler performed simultaneously with TTE and with TOE showed that these false negatives were not due to the imaging technique used itself, because transcranial Doppler performed during TOE also yielded a similar number of false negatives, perhaps related to sedation and lower quality of the Valsalva manoeuvre.[295]

Cardiac CT has been evaluated in 152 patients after ischaemic stroke and showed a sensitivity of 73%, specificity of 98%, positive predictive value of 91%, and negative predictive value of 94.7% for the diagnosis of PFO. CT had a lower sensitivity than TOE in detecting PFO, because PFO requires a provocative manoeuvre diagnosis, which is impossible to do during CT.[29] CT may be of limited use for detecting cardioembolic sources in younger patients with stroke, as the incidence of PFO or ASA is higher in younger patients with stroke or those with cryptogenic stroke.[37]

Several studies have evaluated PFO as a predictive factor of recurrent ischaemic stroke in patients with cryptogenic stroke.[285,296–301] A strong association between PFO and ischaemic stroke has been observed in patients of all ages.[282,302] However, not all studies support the association between cryptogenic stroke and PFO.[299,302,303] Despite circumstantial evidence, prospective studies have failed to demonstrate causality between recurrent ischaemic stroke, presence of PFO or ASA, or right-to-left shunt size.[304–307] Similarly, controversy exists in the management of these patients. A meta-analysis has shown that among medically treated patients with ischaemic stroke/TIA, those with PFO did not have a higher risk of recurrent cerebrovascular ischaemia than those without PFO.[308] No relationship between the degree of right-to-left shunt and the risk of future cerebrovascular events was found when shunt size was dichotomized as small or moderate vs. large.[308] However, three recent studies have shown that among adults who had had a cryptogenic stroke, closure of a PFO with an ASA or large interatrial shunt was associated with a lower rate of recurrent ischaemic strokes than medical therapy alone during extended follow-up.[309–311] However, PFO closure was associated with higher rates of device complications and AF.[309–311]

Recommendations for evaluation of atrial septal anomalies (ASA, PFO)

In patients with cryptogenic stroke or TIA, PFO should be ruled out by contrast TTE and, if contrast TTE is negative, on contrast TOE.

ASA is defined as a >10 mm excursion from the plane of the atrial septum or a combined total excursion right and left ≥15 mm.

Contrast TOE is the reference method for defining a PFO. Contrast TTE has a lower sensitivity than other techniques, including transcranial Doppler. However, if contrast TOE is negative in the case of cryptogenic stroke, a second method should be performed (i.e. contrast TTE or transcranial Doppler).

At-risk PFO should be defined, based on the following: presence of an ASA, PFO size, length of the tunnel, number of bubbles crossing the interatrial septum (≥30 bubbles) (presence of Chiari network or Eustachian valve can be linked to a causal role of PFO).

3D contrast TOE may provide additional information in assessing interatrial septal anatomy and localization of the right-to-left shunt.

Contrast TOE should be systematically performed before the indication of a PFO closure and interpreted by the heart–brain team before any decision.

3D, three dimensional; ASA, atrial septal aneurysm; PFO, patent foramen ovale; TIA, transient ischaemic attack; TOE, transoesophageal echocardiography; TTE, transthoracic echocardiography.

No specific imaging pattern has been associated with a causal role of PFO in patients with ischaemic stroke.[312] ASA, PFO size, shunt severity, presence of Chiari network or Eustachian valve, and an atrial septal hypermobility can be linked to a causal role of PFO.[312–314]

Of note, in patients with endocardial leads (endocardial pacemaker and defibrillator), the presence of a PFO is associated with a greater than threefold increased risk of ischaemic stroke/TIA.[315]

Mechanisms of paradoxical embolism

Right atrial thrombi: thrombi 'in transit' (paradoxical embolism). RA thrombi are usually diagnosed in the setting of pulmonary embolism, and have been identified in 7–18% of patients with pulmonary embolism. RA thrombi are related to venous thromboembolic disease, as the RA represents a transit zone on the pathway between the legs and the pulmonary arteries.[316] TOE shows mobile and freely moving masses not attached to an intracardiac structure. When a systemic thromboembolic event occurs, a paradoxical embolism should be suspected.

Downloaded from https://academic.oup.com/ehjcimaging/article/22/6/e24/6168685 by Universiteit Leiden / LUMC user on 22 June 2022

Recommendation on the evaluation of PFO and paradoxical embolism

Contrast TTE should be performed or repeated in case of the occurrence of a TIA, ischaemic stroke, or peripheral embolism in patients with documented venous thrombosis and/or pulmonary embolism.

TIA, transient ischaemic attack; TTE, transthoracic echocardiography.

Another condition more linked to systemic thromboembolism is the thrombus straddling the PFO. It is diagnosed by TOE and appears as an oblong echodensity trapped in the foramen ovale, with two distal extensions. It is best visualized on a short-axis view of the heart. The thrombus is often described as long, mobile, and snake-shaped; sometimes it prolapses into the right ventricle and/or LV through the atrioventricular valves. This diagnosis of a thrombus straddling the PFO is rarely made by TTE; however, TTE may document the consequences of pulmonary embolism (dilated right cavities, paradoxical septum, and arterial pulmonary hypertension). TTE may also show serpentine thrombi in the LA and/or RA.[317]

In the setting of systemic embolism, the documentation of a thrombus straddling the PFO confirms a paradoxical embolism. The optimal choice of treatment remains challenged.[317]

Left atrial septal pouch. LASP is defined as incomplete fusion of the cranial segment of the overlap between the septum primum and septum secundum, resulting in a recess opening into the LA in the absence of an interatrial shunt at rest or with Valsalva manoeuvre release.[318] LASP may serve as a nidus for thrombus formation, particularly in the presence of low flow states, and therefore predisposes to thromboembolic events.[318] LASP is best identified using a standard bicaval view by TOE imaging, and 3D TOE may add incremental value for detecting and characterizing LASP morphology.[17] LASP generally cannot be identified using TTE, whereas they can be detected using either cardiac CT or MRI.[319] A previous autopsy study reported a prevalence of 39% among randomly selected patients with cardiovascular disease,[320] although subsequent studies have reported a lower prevalence with a suspected decline with increasing age.[321]

Published case reports have speculated on a causal relationship between LASP and ischaemic stroke,[319,322,323] and a number of retrospective studies have more closely examined this association. However, results to date have been discordant (Supplementary data online, *Table S10*).[318,324–326] A retrospective case–control study of 187 patients aged >50 years undergoing TOE after presenting with ischaemic stroke found no significant association between the presence of LASP and ischaemic stroke after comparison with 157 stroke-free controls.[318] A more recent study of 126 patients presenting with cryptogenic stroke undergoing TOE compared with 137 patients without stroke reported an association with LASP that was significant after adjustment for multiple other stroke risk factors.[321] A systematic review pooling data from 516 ischaemic stroke patients and 779 controls found no significant association.[326]

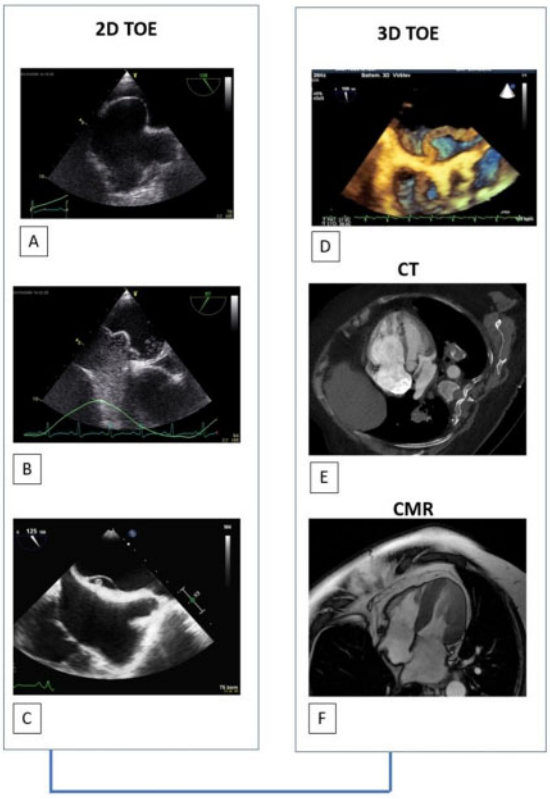

Figure 11 Multimodality evaluation of atrial septal abnormalities. 2D TOE (left panel): (*A*) ASA and (*B*) PFO in the same patient, diagnosed using contrast TOE (57°) during the Valsalva manoeuvre; (*C*) thrombus within an atrial septal pouch. 3D TOE (right panel): (*D*) entrapped thrombus through an ASA with a PFO; (*E*) entrapped thrombus through a PFO in patient with acute pulmonary embolism; (*F*) CMR: ASA on 2D SSFP imaging (Supplementary data online, *Videos S12–S14*). 2D, two-dimensional; 3D, three-dimensional; ASA, atrial septal aneurysm; CMR, cardiac magnetic resonance; CT, computed tomography; PFO, patent foramen ovale; SSFP: steady-state free precession; TOE, transoesophageal echocardiography; TTE, transthoracic echocardiography.

Figure 11 illustrates the use of multimodality imaging in the diagnosis of atrial septal abnormalities.

Valvular abnormalities

Mitral valve prolapse

Mitral valve prolapse arises as a result of myxomatous degeneration of the valve tissues and presents on 2D TOE as a hernia or protrusion measuring >2 mm in one or both of the LA mitral valve leaflets in systole, referred to as 'floppy valve syndrome' (morphological abnormality), and coaptation of the two mitral leaflets posterior to the mitral annulus mainly observed in the long-axis, parasternal longitudinal view.[327,328] The sensitivity and specificity of TOE for the detection of mitral valve prolapse are 87% and 97%, respectively.[329] Higher values, approaching 100%, have been obtained using TOE[330] and 3D echocardiography.[331]

Downloaded from https://academic.oup.com/ehjcimaging/article/22/6/e24/6168685 by Universiteit Leiden / LUMC user on 22 June 2022

Figure 12 Mitral annular calcifications on 2D TTE (short-axis view) (see Supplementary data online, *Video S15*). 2D, two-dimensional; TTE, transthoracic echocardiography.

A link between mitral valve prolapse and ischaemic stroke has been described in young subjects, predominantly those aged <45 years[332] or with a diffuse-form prolapse (mitral, aortic, and tricuspid) and valve thickening[333,334] but, as yet, the attributable risk of mitral valve prolapse to ischaemic strokes in young patients is very low (0.14–0.6/100 patient-years).[335]

The mechanism of stroke in mitral valve prolapse is not clearly understood. They may be caused either by platelet emboli forming on splits in the valve endothelium and subendothelium conjunctive tissue, or cruoric thrombi developing in the cul-de-sac formed by the posterior mitral valve and the LA wall. They are most likely related to the presence of other risk factors for embolism, primarily AF, which may be paroxysmal and asymptomatic. High-risk echocardiographic features in mitral valve prolapse are: ≥5 mm valve thickening, valvular dystrophy (redundancy), enlarged LA, ≥mild mitral regurgitation, and the presence of interatrial septal aneurysms.[336]

Mitral annulus calcification

Mitral annulus calcification is a very common (incidental finding) degenerative process (detected at echocardiography in approximately 14% of cases).[337] It mainly affects older people (>60 years), women, and patients with hypertension, diabetes, chronic renal dysfunction, or dysregulated mineral metabolism.[338–340] Patients presenting with mitral annulus calcification often have comorbidities such as endocarditis, arrhythmia, systemic emboli, and aortic valve calcification.[340] In advanced cases, it may cause significant obstruction of LV inflow and symptomatic mitral stenosis.

Mitral annulus calcification refers to a chronic inflammatory fibrous calcification of the mitral annulus (endothelial dysfunction, lipids, and calcium deposit in the fibrous ring of the mitral valve). No clear causal relationship between ischaemic stroke and mitral annulus calcification has been established because it is more a marker for generalized atherosclerosis.[338,339] However, occasionally, mobile plaques may be clearly identified at the level of the calcified annulus by echocardiography and, in those cases, the probability of a migration of calcified emboli or thrombotic debris is much higher. Certain ischaemic strokes may be related to an increased incidence of AF.[337]

Multimodality imaging with 2D, 3D, and Doppler echocardiography (*Figure 12*) and CTA can delineate the extent and location of mitral annulus calcification to help guide therapeutic strategies. Three semi-quantitative grades of severity can be identified: mild (focal, limited increase in echodensity of the mitral annulus), moderate (marked echodensity involving one-third to one-half of the ring circumference), or severe (marked echodensity involving more than half of the ring, or with intrusion into the LV inflow tract). Multislice CT can better quantify the severity of calcification. It is usually visualized on echocardiography as an echodense shelf-like structure with an irregular, lumpy appearance involving the mitral valve annulus, with associated acoustic shadowing. Using ^{18}F-sodium fluoride (calcification activity) and ^{18}F-fluorodeoxyglucose (inflammation activity) PET, mitral annulus calcification has recently been shown to be characterized by both calcification and inflammatory activity that increases proportionally to the baseline calcification burden (highest baseline CT calcium scores).[341]

Cardiac CT has been proposed in the evaluation of the extent and location of mitral annular calcification.[342]

Aortic valve calcification and stenosis

Calcific aortic valve disease with or without stenosis is a very common feature, especially among older adults. The clinical precursors of atherosclerosis are also risk factors for calcific aortic valve disease.[343] Spontaneous embolic complications observed in calcific aortic valve disease are rare and most often clinically silent, particularly owing to the small size of the thrombi, which preferentially migrate to the retinal artery.[344] Rarely, larger emboli have been associated with calcific aortic valve disease, mainly in procedural settings such as cardiac catheterization and percutaneous intervention or heart surgery.[345] TTE or TOE may rarely visualize small debris or mobile plaques at the level of the valve leaflets or annulus, further reinforcing the potential for an embolic event. Cardiac imaging techniques play a key role in the study of calcific aortic valve disease by confirming the diagnosis and estimating its severity. Calcium scoring CT offers the advantage of quantifying the calcium load at the valve level, which is associated with the severity of aortic valve stenosis (≥2000 Agatston units for men and ≥1200 Agatston units for women to distinguish severe from moderate aortic stenosis), and predicts poor prognosis and disease progression.[346,347]

Giant Lambl's excrescences and strands

Lambl's excrescences (or fibrous filaments or strands) are thin, elongated, mobile structures that arise opposite the contact surfaces of cardiac valve leaflets. They are more commonly described on the mitral valve (atrial surface), but are also described on the ventricular side of the aortic valve, and can also be found on prosthetic valves and, rarely, on native tricuspid and pulmonary valves.[348] Two case-

Recommendations for evaluation and treatment of minor and putative sources of ischaemic stroke

Isolated and uncomplicated mitral valve prolapse should not be considered as a potential cardiac source of embolism.

Continued

Downloaded from https://academic.oup.com/ehjcimaging/article/22/6/e24/6168685 by Universiteit Leiden / LUMC user on 22 June 2022

Continued

Recommendations for evaluation and treatment of minor and putative sources of ischaemic stroke

Mitral annulus and aortic valve calcifications should not be considered as potential cardiac sources of embolism because both are incidental and associated with other causes (e.g. aortic atheroma).

The significance of LASP for patients presenting with cryptogenic ischaemic stroke remains uncertain, and no recommendation can be made regarding the management of ischaemic stroke patients with LASP. Larger studies are needed to evaluate whether LASP is a risk factor for ischaemic stroke.

Lambl's excrescences are only weakly correlated with stroke risk. Their discovery during work-up for a cryptogenic stroke should not discourage the search for another possible cause. It has no effect on patient management.

LASP, left atrial septal pouch.

controlled studies[348,349] had discordant findings with respect to the association between valvular strands and ischaemic stroke, although both detected a relatively high prevalence in patients referred for exploration of cryptogenic stroke. Another case–control study[350] involving 284 patients referred for evaluation after an ischaemic stroke and 276 controls aged >60 years found a significantly increased stroke risk in patients presenting with mitral valve strands identified by TOE. These patients were monitored for a mean of 2.3 years and the risk of recurrent ischaemic stroke was not different in those with or without strands (6% vs. 4.2% per patient-year, respectively). The presence of mitral valve strands was not an independent predictor of risk for this outcome. A recent case-control study including 77 systemic lupus erythematosus cases and 26 age- and sex-matched controls found a similar frequency of Lambl's excrescences between the two groups and no association with incident ischaemic stroke.[351]

See Supplementary data online, *Videos S16*.

Flow chart

Vascular imaging and contrast TTE/TOE are considered the first-line tool in the search for a cardiac source of embolism (*Figure 13*). CT and MRI are considered as alternative tools, and their indications are described on a case-by-case approach:

- In the case of normal contrast TTE, cardiac rhythm (atrial tachyarrhythmia vs. sinus rhythm) should be taken into account.
  - In patients with AF, contrast TTE can detect the presence of thromboembolic risk markers (LA size, LA strain alteration, and LVEF <40%). The indication for contrast TOE cannot be part of a routine indication, except to answer a specific question or for inclusion in a research protocol. Without TTE-derived thromboembolic risk markers, contrast TOE indication is mandatory.
  - In the case of sinus rhythm (i.e. cryptogenic stroke), contrast TOE and a Holter electrocardiogram are mandatory.
- In the case of abnormal contrast TTE, a minor cardiac source of embolism has to be distinguished from a major cardiac source of embolism.
  - If a minor cardiac source of embolism is detected, contrast TOE might be indicated: (i) if another potential cardiac source of embolism (>20% of cases) is suspected; (ii) before percutaneous interatrial septum closure; and (iii) in the event of unequivocal results on contrast TTE.
    - In the case of negative contrast TOE, a transcranial Doppler is indicated. In case of a negative transcranial Doppler, a Holter monitoring should be considered.
  - If a major cardiac source of embolism is detected and is an unequivocal potential source of embolism, the indication of contrast TOE may be debatable. However, its input is indisputable for the detection of potential cardiac sources of small size (below the resolution of contrast TTE), such as atrial or LV thrombosis, atrial or LV tumour, or valvular vegetation.
    - When contrast TTE is equivocal, contrast TOE indication is mandatory.

Conclusions

Cardiac embolism accounts for an increasing proportion of ischaemic strokes, and the role of cardiac imaging (TTE with contrast, TOE with contrast, MRI, and CT) is increasing (Supplementary data online, *Tables S11* and *S12*). Echocardiography constitutes the primary choice for cardiac imaging after acute ischaemic stroke, with TTE and TOE providing complementary information. Cardiac CT and MRI are valuable alternatives in specific situations. AF remains the main cardiac source of embolism, although the role and imaging characteristics of LA/LAA dysfunction remain debatable (e.g. LAA geometry, LAA dysfunction, LA strain, LA/LAA SEC). Improved imaging of aortic atheromas (TOE > CT), ventricular thrombus (MRI > TTE), atrial thrombus (TOE or CT > MRI), valvular masses (3D TOE > MRI or CT) may lead to better aetiological work-up in patients with ischaemic stroke. Despite such a work-up, one-third of ischaemic strokes have an unclear cause, leading to the concept of ESUS, secondary to the so-called atrial cardiomyopathy. A thrombogenic atrial substrate (LA/LAA anomalies in cellular components, geometry, and/or function) can lead to atrial thromboembolism. LA strain, MRI (LA fibrosis), biomarkers and echo-markers, and rhythm anomalies can be further characterized. Atrial septal anomalies deserve careful examination to describe at-risk PFO and to discuss the indications of PFO closure in patients with cryptogenic stroke, after in-depth discussion and the ruling out of other possible causes, including occult AF (Holter or prolonged rhythm monitoring, insertable cardiac monitors). Patients with cryptogenic stroke constitute a heterogeneous group, leading to therapeutic implications based on the potential mechanism. The concept of ESUS deserves further refinement, because the results of the two studies on non-vitamin K antagonist oral anticoagulants are negative.[352,353]

Downloaded from https://academic.oup.com/ehjcimaging/article/22/6/e24/6168685 by Universiteit Leiden / LUMC user on 22 June 2022

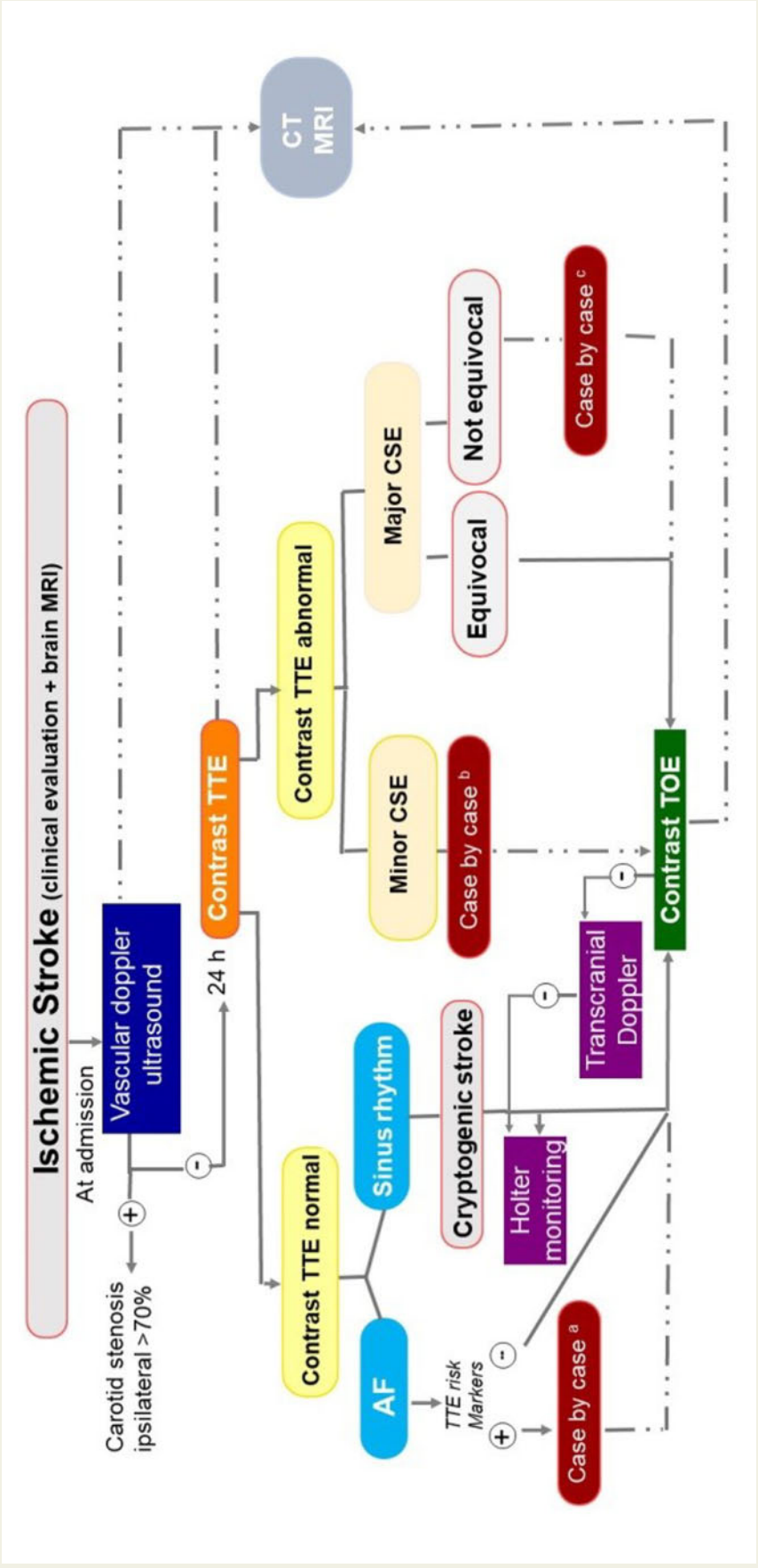

Figure 13 Diagnostic algorithm: proposal for a diagnostic approach based on the current evidence. [a]Contrast TOE could be useful to identify the presence of a LA/LAA thrombogenic status (LA/LAA thrombus, dense LA/LAA SEC or dysfunction). Biomarkers could be useful (e.g. D-dimers, B-type natriuretic peptide, troponin, von Willebrand factor, C-reactive protein, interleukin 6) to identify a subgroup of patients at higher thromboembolic risk. [b]Contrast TOE is mandatory in the search of other cardiac source of embolism, before percutaneous closure and in case of questionable contrast TOE. [c]Contrast TOE could be useful to identify small size or questionable abnormalities beyond the resolution of TTE, such as LA/LV thrombus, LA/LV tumours, left-sided vegetations. AF, atrial fibrillation (paroxysmal, persistent, permanent); CSE, cardiac source of embolism; CT, computed tomography; LA, left atrial; LAA, left atrial appendage; LV, left ventricular; MRI, magnetic resonance imaging; SEC, spontaneous echocardiographic contrast; TOE, transoesophageal echocardiography; TTE, transthoracic echocardiography.

Downloaded from https://academic.oup.com/ehjcimaging/article/22/6/e24/6168685 by Universiteit Leiden / LUMC user on 22 June 2022

Supplementary data

Supplementary data are available at *European Heart Journal - Cardiovascular Imaging* online.

Conflict of interest: A.C.: research grants from RESICARD (research nurses) and the companies ARS, Bayer and Boehringer Ingelheim. Consultant and lecture fees from the companies AstraZeneca, Bayer Pharma, BMS-Pfizer Alliance, Boehringer Ingelheim, and Novartis, unrelated to the present work. E.D.: research facilities from General Electric Healthcare, consultant and lecture fees from BMS-Pfizer alliance, Novartis, AstraZeneca. B.A.P.: research grants and lecture fees from GE Healthcare and Hitachi-Aloka; Consultant and lecture fees from Bayer, Bracco, Krka, Novartis, Pfizer, unrelated to the present work. The other authors declare that they have no competing interests.

Acknowledgements

Editorial support was provided by Sophie Rushton-Smith and Jenny Lloyd (MedLink Healthcare Communications, London) and was funded by the authors.

References

1. Astrom M, Adolfsson R, Asplund K. Major depression in stroke patients. A 3-year longitudinal study. *Stroke* 1993;**24**:976–82.
2. Pohjasvaara T, Erkinjuntti T, Vataja R, Kaste M. Correlates of dependent living 3 months after ischemic stroke. *Cerebrovasc Dis* 1998;**8**:259–66.
3. Pohjasvaara T, Leppävuori A, Siira I, Vataja R, Kaste M, Erkinjuntti T *et al.* Frequency and clinical determinants of poststroke depression. *Stroke* 1998;**29**:2311–7.
4. Hankey GJ. Stroke. *Lancet* 2017;**389**:641–54.
5. Adams HP, Bendixen BH, Kappelle LJ, Biller J, Love BB, Gordon DL *et al.* Classification of subtype of acute ischemic stroke. Definitions for use in a multicenter clinical trial. TOAST. Trial of Org 10172 in Acute Stroke Treatment. *Stroke* 1993;**24**:35–41.
6. Kamel H, Healey JS. Cardioembolic stroke. *Circ Res* 2017;**120**:514–26.
7. Li L, Yiin GS, Geraghty OC, Schulz UG, Kuker W, Mehta Z *et al.* Incidence, outcome, risk factors, and long-term prognosis of cryptogenic transient ischaemic attack and ischaemic stroke: a population-based study. *Lancet Neurol* 2015;**14**:903–13.
8. Saver JL. Cryptogenic stroke. *N Engl J Med* 2016;**374**:2065–74.
9. Yaghi S, Bernstein RA, Passman R, Okin PM, Furie KL. Cryptogenic stroke: research and practice. *Circ Res* 2017;**120**:527–40.
10. Hart RG, Diener H-C, Coutts SB, Easton JD, Granger CB, O'Donnell MJ *et al.* Embolic strokes of undetermined source: the case for a new clinical construct. *Lancet Neurol* 2014;**13**:429–38.
11. Katsanos AH, Giannopoulos S, Frogoudaki A, Vrettou AR, Ikonomidis I, Paraskevaidis I *et al.* The diagnostic yield of transesophageal echocardiography in patients with cryptogenic cerebral ischaemia: a meta-analysis. *Eur J Neurol* 2016;**23**:569–79.
12. Kapral MK, Silver FL. Canadian Task Force on Preventive Health Care. Preventive health care, 1999 update: 2. Echocardiography for the detection of a cardiac source of embolus in patients with stroke. *CMAJ* 1999;**161**:989–96.
13. Bogousslavsky J, Cachin C, Regli F, Despland P-A, Melle GV, Kappenberger L *et al.* Cardiac sources of embolism and cerebral infarction—clinical consequences and vascular concomitants: the Lausanne Stroke Registry. *Neurology* 1991;**41**:855–9.
14. Khariton Y, House JA, Comer L, Coggins TR, Magalski A, Skolnick DG *et al.* Impact of transesophageal echocardiography on management in patients with suspected cardioembolic stroke. *Am J Cardiol* 2014;**114**:1912–6.
15. Kernan WN, Ovbiagele B, Black HR, Bravata DM, Chimowitz MI, Ezekowitz MD *et al.* Guidelines for the prevention of stroke in patients with stroke and transient ischemic attack: a guideline for healthcare professionals from the American Heart Association/American Stroke Association. *Stroke* 2014;**45**:2160–236.
16. Pepi M, Evangelista A, Nihoyannopoulos P, Flachskampf FA, Athanassopoulos G, Colonna P *et al.*; on behalf of the European Association of Echocardiography. Recommendations for echocardiography use in the diagnosis and management of cardiac sources of embolism: European Association of Echocardiography (EAE) (a registered branch of the ESC). *Eur J Echocardiogr* 2010;**11**:461–76.
17. Elsayed M, Hsiung MC, Meggo-Quiroz LD, Elguindy M, Uygur B, Tandon R *et al.* Incremental value of live/real time three-dimensional over two-dimensional transesophageal echocardiography in the assessment of atrial septal pouch. *Echocardiography* 2015;**32**:1858–67.
18. Arsava EM, Ballabio E, Benner T, Cole JW, Delgado-Martinez MP, Dichgans M *et al.*; On behalf of the International Stroke Genetics Consortium. The Causative Classification of Stroke system: an international reliability and optimization study. *Neurology* 2010;**75**:1277–84.
19. Hart RG, Catanese L, Perera KS, Ntaios G, Connolly SJ. Embolic stroke of undetermined source: a systematic review and clinical update. *Stroke* 2017;**48**:867–72.
20. Ueno Y, Yamashiro K, Tanaka R, Kuroki T, Hira K, Kurita N *et al.* Emerging risk factors for recurrent vascular events in patients with embolic stroke of undetermined source. *Stroke* 2016;**47**:2714–21.
21. de Bruijn SFTM, Agema WRP, Lammers GJ, van der Wall EE, Wolterbeek R, Holman ER *et al.* Transesophageal echocardiography is superior to transthoracic echocardiography in management of patients of any age with transient ischemic attack or stroke. *Stroke* 2006;**37**:2531–4.
22. McGrath ER, Paikin JS, Motlagh B, Salehian O, Kapral MK, O'Donnell MJ *et al.* Transesophageal echocardiography in patients with cryptogenic ischemic stroke: a systematic review. *Am Heart J* 2014;**168**:706–12.
23. Pagán RJ, Parikh PP, Mergo PJ, Gerber TC, Mankad R, Freeman WD *et al.* Emerging role of cardiovascular CT and MRI in the evaluation of stroke. *AJR Am J Roentgenol* 2015;**204**:269–80.
24. Romero J, Husain SA, Kelesidis I, Sanz J, Medina HM, Garcia MJ *et al.* Detection of left atrial appendage thrombus by cardiac computed tomography in patients with atrial fibrillation: a meta-analysis. *Circ Cardiovasc Imaging* 2013;**6**:185–94.
25. Zou H, Zhang Y, Tong J, Liu Z. Multidetector computed tomography for detecting left atrial/left atrial appendage thrombus: a meta-analysis. *Intern Med J* 2015;**45**:1044–53.
26. Chen J, Zhang H, Zhu D, Wang Y, Byanju S, Liao M *et al.* Cardiac MRI for detecting left atrial/left atrial appendage thrombus in patients with atrial fibrillation: meta-analysis and systematic review. *Herz* 2019;**44**:390–7.
27. Kitkungvan D, Nabi F, Ghosn MG, Dave AS, Quinones M, Zoghbi WA *et al.* Detection of LA and LAA thrombus by CMR in patients referred for pulmonary vein isolation. *JACC Cardiovasc Imaging* 2016;**9**:809–18.
28. Revel M-P, Faivre J-B, Letourneau T, Henon H, Leys D, Delannoy-Deken V *et al.* Patent foramen ovale: detection with nongated multidetector CT. *Radiology* 2008;**249**:338–45.
29. Kim YJ, Hur J, Shim C-Y, Lee H-J, Ha J-W, Choe KO *et al.* Patent foramen ovale: diagnosis with multidetector CT—comparison with transesophageal echocardiography. *Radiology* 2009;**250**:61–7.
30. Rajiah P, Kanne JP. Cardiac MRI: part 1, cardiovascular shunts. *AJR Am J Roentgenol* 2011;**197**:W603–20.
31. Motwani M, Kidambi A, Herzog BA, Uddin A, Greenwood JP, Plein S *et al.* MR imaging of cardiac tumors and masses: a review of methods and clinical applications. *Radiology* 2013;**268**:26–43.
32. Roifman I, Connelly KA, Wright GA, Wijeysundera HC. Echocardiography vs. cardiac magnetic resonance imaging for the diagnosis of left ventricular thrombus: a systematic review. *Can J Cardiol* 2015;**31**:785–91.
33. Takasugi J, Yamagami H, Noguchi T, Morita Y, Tanaka T, Okuno Y *et al.* Detection of left ventricular thrombus by cardiac magnetic resonance in embolic stroke of undetermined source. *Stroke* 2017;**48**:2434–40.
34. Baher A, Mowla A, Kodali S, Polsani VR, Nabi F, Nagueh SF *et al.* Cardiac MRI improves identification of etiology of acute ischemic stroke. *Cerebrovasc Dis* 2014;**37**:277–84.
35. Liberman AL, Kalani RE, Aw-Zoretic J, Sondag M, Daruwalla VJ, Mitter SS *et al.* Cardiac magnetic resonance imaging has limited additional yield in cryptogenic stroke evaluation after transesophageal echocardiography. *Int J Stroke* 2017;**12**:946–52.
36. Zahuranec DB, Mueller GC, Bach DS, Stojanovska J, Brown DL, Lisabeth LD *et al.* Pilot study of cardiac magnetic resonance imaging for detection of embolic source after ischemic stroke. *J Stroke Cerebrovasc Dis* 2012;**21**:794–800.
37. Hur J, Kim YJ, Lee H-J, Ha J-W, Heo JH, Choi E-Y *et al.* Cardiac computed tomographic angiography for detection of cardiac sources of embolism in stroke patients. *Stroke* 2009;**40**:2073–8.
38. Lee K, Hur J, Hong SR, Suh YJ, Im DJ, Kim YJ *et al.* Predictors of recurrent stroke in patients with ischemic stroke: comparison study between transesophageal echocardiography and cardiac CT. *Radiology* 2015;**276**:381–9.
39. Sipola P, Hedman M, Onatsu J, Turpeinen A, Halinen M, Jäkälä P *et al.* Computed tomography and echocardiography together reveal more high-risk findings than echocardiography alone in the diagnostics of stroke etiology. *Cerebrovasc Dis* 2013;**35**:521–30.
40. Yeo LLL, Holmin S, Andersson T, Lundström E, Gopinathan A, Lim EL *et al.* Nongated cardiac computed tomographic angiograms for detection of embolic sources in acute ischemic stroke. *Stroke* 2017;**48**:1256–61.

Downloaded from https://academic.oup.com/ehjcimaging/article/22/6/e24/6168685 by Universiteit Leiden / LUMC user on 22 June 2022

41. Naylor AR, Ricco JB, de Borst GJ *et al.* Editor's choice—management of atherosclerotic carotid and vertebral artery disease: 2017 clinical practice guidelines of the European Society for Vascular Surgery (ESVS). *Eur J Vasc Endovasc Surg* 2018;**55**:3–81.
42. Sprynger M, Rigo F, Moonen M, Aboyans V, Edvardsen T, de Alcantara ML *et al.*; EACVI Scientific Documents Committee. Focus on echovascular imaging assessment of arterial disease: complement to the ESC guidelines (PARTIM 1) in collaboration with the Working Group on Aorta and Peripheral Vascular Diseases. *Eur Heart J Cardiovasc Imaging* 2018;**19**:1195–221.
43. von Reutern G-M, Goertler M-W, Bornstein NM, Sette MD, Evans DH, Goertler M-W *et al.* Grading carotid stenosis using ultrasonic methods. *Stroke* 2012;**43**:916–21.
44. Aboyans V, Ricco J-B, Bartelink M-LEL, Björck M, Brodmann M, Cohnert T *et al.*; ESC Scientific Document Group. 2017 ESC guidelines on the diagnosis and treatment of peripheral arterial diseases, in collaboration with the European Society for Vascular Surgery (ESVS): document covering atherosclerotic disease of extracranial carotid and vertebral, mesenteric, renal, upper and lower extremity arteriesEndorsed by: the European Stroke Organization (ESO)The Task Force for the Diagnosis and Treatment of Peripheral Arterial Diseases of the European Society of Cardiology (ESC) and of the European Society for Vascular Surgery (ESVS). *Eur Heart J* 2018;**39**:763–816.
45. Yaghi S, Liberman AL, Atalay M, Song C, Furie KL, Kamel H *et al.* Cardiac magnetic resonance imaging: a new tool to identify cardioaortic sources in ischaemic stroke. *J Neurol Neurosurg Psychiatry* 2017;**88**:31–7.
46. Agmon Y, Khandheria BK, Gentile F, Seward JB. Clinical and echocardiographic characteristics of patients with left atrial thrombus and sinus rhythm: experience in 20 643 consecutive transesophageal echocardiographic examinations. *Circulation* 2002;**105**:27–31.
47. Gage BF, Waterman AD, Shannon W, Boechler M, Rich MW, Radford MJ *et al.* Validation of clinical classification schemes for predicting stroke: results from the National Registry of Atrial Fibrillation. *JAMA* 2001;**285**:2864–70.
48. Lip GYH, Nieuwlaat R, Pisters R, Lane DA, Crijns HJGM. Refining clinical risk stratification for predicting stroke and thromboembolism in atrial fibrillation using a novel risk factor-based approach: the euro heart survey on atrial fibrillation. *Chest* 2010;**137**:263–72.
49. Overvad TF, Nielsen PB, Larsen TB, Søgaard P. Left atrial size and risk of stroke in patients in sinus rhythm. A systematic review. *Thromb Haemost* 2016;**116**: 206–19.
50. The Stroke Prevention in Atrial Fibrillation Investigators. Predictors of thromboembolism in atrial fibrillation: II. Echocardiographic features of patients at risk. *Ann Intern Med* 1992;**116**:6–12.
51. Pathan F, Hecht H, Narula J, Marwick TH. Roles of transesophageal echocardiography and cardiac computed tomography for evaluation of left atrial thrombus and associated pathology: a review and critical analysis. *JACC Cardiovasc Imaging* 2018;**11**:616–27.
52. Coulshed N, Epstein EJ, McKendrick CS, Galloway RW, Walker E. Systemic embolism in mitral valve disease. *Br Heart J* 1970;**32**:26–34.
53. Selzer A, Cohn KE. Natural history of mitral stenosis: a review. *Circulation* 1972; **45**:878–90.
54. Negi PC, Sondhi S, Rana V, Rathoure S, Kumar R, Kolte N *et al.* Prevalence, risk determinants and consequences of atrial fibrillation in rheumatic heart disease: 6 years hospital based-Himachal Pradesh- Rheumatic Fever/Rheumatic Heart Disease (HP-RF/RHD) Registry. *Indian Heart J* 2018;**70**:S68–S73.
55. Chiang CW, Lo SK, Ko YS *et al.* Predictors of systemic embolism in patients with mitral stenosis. A prospective study. *Ann Intern Med* 1998;**128**:885–9.
56. Goswami KC, Yadav R, Rao MB, Bahl VK, Talwar KK, Manchanda SC *et al.* Clinical and echocardiographic predictors of left atrial clot and spontaneous echo contrast in patients with severe rheumatic mitral stenosis: a prospective study in 200 patients by transesophageal echocardiography. *Int J Cardiol* 2000; **73**:273–9.
57. Bernstein NE, Demopoulos LA, Tunick PA, Rosenzweig BP, Kronzon I. Correlates of spontaneous echo contrast in patients with mitral stenosis and normal sinus rhythm. *Am Heart J* 1994;**128**:287–92.
58. Nunes MCP, Handschumacher MD, Levine RA, Barbosa MM, Carvalho VT, Esteves WA *et al.* Role of LA shape in predicting embolic cerebrovascular events in mitral stenosis: mechanistic insights from 3D echocardiography. *JACC Cardiovasc Imaging* 2014;**7**:453–61.
59. Iung B, Leenhardt A, Extramiana F. Management of atrial fibrillation in patients with rheumatic mitral stenosis. *Heart* 2018;**104**:1062–8.
60. Donal E, Lip GYH, Galderisi M, Goette A, Shah D, Marwan M *et al.* EACVI/EHRA Expert Consensus Document on the role of multi-modality imaging for the evaluation of patients with atrial fibrillation. *Eur Heart J Cardiovasc Imaging* 2016;**17**:355–83.
61. Wolf PA, Abbott RD, Kannel WB. Atrial fibrillation as an independent risk factor for stroke: the Framingham Study. *Stroke* 1991;**22**:983–8.
62. Feinberg WM, Blackshear JL, Laupacis A *et al.* Prevalence, age distribution, and gender of patients with atrial fibrillation. Analysis and implications. *Arch Intern Med* 1995;**155**:469–73.
63. Donal E, Yamada H, Leclercq C, Herpin D. The left atrial appendage, a small, blind-ended structure: a review of its echocardiographic evaluation and its clinical role. *Chest* 2005;**128**:1853–62.
64. Lip GY. Stroke prevention in Atrial Fibrillation. *Eur Heart J* 2017;**38**:4–5.
65. Heidbuchel H, Verhamme P, Alings M, Antz M, Diener H-C, Hacke W *et al.*; ESC Scientific Document Group. Updated European Heart Rhythm Association practical guide on the use of non-vitamin-K antagonist anticoagulants in patients with non-valvular atrial fibrillation: executive summary. *Eur Heart J* 2017;**38**: 2137–49.
66. Leung M, van Rosendael PJ, Abou R, Ajmone Marsan N, Leung DY, Delgado V *et al.* Left atrial function to identify patients with atrial fibrillation at high risk of stroke: new insights from a large registry. *Eur Heart J* 2018;**39**:1416–25.
67. Leong DP, Joyce E, Debonnaire P, Katsanos S, Holman ER, Schalij MJ *et al.* Left atrial dysfunction in the pathogenesis of cryptogenic stroke: novel insights from speckle-tracking echocardiography. *J Am Soc Echocardiogr* 2017;**30**:71–9.e1.
68. Schaaf M, Andre P, Altman M, Maucort-Boulch D, Placide J, Chevalier P *et al.* Left atrial remodelling assessed by 2D and 3D echocardiography identifies paroxysmal atrial fibrillation. *Eur Heart J Cardiovasc Imaging* 2017;**18**:46–53.
69. Pagola J, González-Alujas T, Flores A, Muchada M, Rodriguez-Luna D, Seró L *et al.* Left atria strain is a surrogate marker for detection of atrial fibrillation in cryptogenic strokes. *Stroke* 2014;**45**:e164–6.
70. Obokata M, Negishi K, Kurosawa K, Tateno R, Tange S, Arai M *et al.* Left atrial strain provides incremental value for embolism risk stratification over CHA_2DS_2-VASc score and indicates prognostic impact in patients with atrial fibrillation. *J Am Soc Echocardiogr* 2014;**27**:709–16.e4.
71. Heidbuchel H, Verhamme P, Alings M, Antz M, Hacke W, Oldgren J *et al.* EHRA practical guide on the use of new oral anticoagulants in patients with non-valvular atrial fibrillation: executive summary. *Eur Heart J* 2013;**34**: 2094–106.
72. Beigel R, Wunderlich NC, Ho SY, Arsanjani R, Siegel RJ. The left atrial appendage: anatomy, function, and noninvasive evaluation. *JACC Cardiovasc Imaging* 2014;**7**:1251–65.
73. Hoit BD. Assessment of left atrial function by echocardiography: novel insights. *Curr Cardiol Rep* 2018;**20**:96.
74. Kim D, Shim CY, Hong G-R, Kim M-H, Seo J, Cho IJ *et al.* Clinical implications and determinants of left atrial mechanical dysfunction in patients with stroke. *Stroke* 2016;**47**:1444–51.
75. Galderisi M, Donal E, Magne J, Lo Iudice F, Agricola E, Sade LE *et al.* Rationale and design of the EACVI AFib Echo Europe Registry for assessing relationships of echocardiographic parameters with clinical thrombo-embolic and bleeding risk profile in non-valvular atrial fibrillation. *Eur Heart J Cardiovasc Imaging* 2018; **19**:245–52.
76. Healey JS. Stroke prevention in atrial fibrillation: what is real world, and what do real-world data reveal? *J Am Coll Cardiol* 2018;**72**:154–5.
77. Reiffel JA, Verma A, Kowey PR, Halperin JL, Gersh BJ, Wachter R *et al.*; for the REVEAL AF Investigators. Incidence of previously undiagnosed atrial fibrillation using insertable cardiac monitors in a high-risk population: the REVEAL AF study. *JAMA Cardiol* 2017;**2**:1120–7.
78. Mittal S, Rogers J, Sarkar S, Koehler J, Warman EN, Tomson TT *et al.* Real-world performance of an enhanced atrial fibrillation detection algorithm in an insertable cardiac monitor. *Heart Rhythm* 2016;**13**:1624–30.
79. Van Gelder IC, Healey JS, Crijns HJGM, Wang J, Hohnloser SH, Gold MR *et al.* Duration of device-detected subclinical atrial fibrillation and occurrence of stroke in ASSERT. *Eur Heart J* 2017;**38**:1339–44.
80. Vinereanu D, Lopes RD, Mulder H, Gersh BJ, Hanna M, de Barros e Silva PGM *et al.* Echocardiographic risk factors for stroke and outcomes in patients with atrial fibrillation anticoagulated with apixaban or warfarin. *Stroke* 2017;**48**: 3266–73.
81. Wood KA, Eisenberg SJ, Kalman JM, Drew BJ, Saxon LA, Lee RJ *et al.* Risk of thromboembolism in chronic atrial flutter. *Am J Cardiol* 1997;**79**:1043–7.
82. Singer DE, Albers GW, Dalen JE, Fang MC, Go AS, Halperin JL *et al.* Antithrombotic therapy in atrial fibrillation: American College of Chest Physicians Evidence-Based Clinical Practice Guidelines (8th Edition). *Chest* 2008; **133**:546S–92S.
83. January CT, Wann LS, Alpert JS, Calkins H, Cigarroa JE, Cleveland JC Jr *et al.* 2014 AHA/ACC/HRS guideline for the management of patients with atrial fibrillation: a report of the American College of Cardiology/American Heart Association Task Force on Practice Guidelines and the Heart Rhythm Society. *J Am Coll Cardiol* 2014;**64**:e1–76.
84. Kirchhof P, Benussi S, Kotecha D, Ahlsson A, Atar D, Casadei B *et al.* 2016 ESC Guidelines for the management of atrial fibrillation developed in collaboration with EACTS. *Eur Heart J* 2016;**37**:2893–962.

Downloaded from https://academic.oup.com/ehjcimaging/article/22/6/e24/6168685 by Universiteit Leiden / LUMC user on 22 June 2022

85. January CT, Wann LS, Calkins H, Chen LY, Cigarroa JE, Cleveland JC Jr *et al.* 2019 AHA/ACC/HRS focused update of the 2014 AHA/ACC/HRS guideline for the management of patients with atrial fibrillation: a report of the American College of Cardiology/American Heart Association Task Force on Clinical Practice Guidelines and the Heart Rhythm Society. *J Am Coll Cardiol* 2019;**74**: 104–32.
86. Vadmann H, Nielsen PB, Hjortshøj SP, Riahi S, Rasmussen LH, Lip GYH *et al.* Atrial flutter and thromboembolic risk: a systematic review. *Heart* 2015;**101**: 1446–55.
87. Daniel WG, Nellessen U, Schröder E, Nonnast-Daniel B, Bednarski P, Nikutta P *et al.* Left atrial spontaneous echo contrast in mitral valve disease: an indicator for an increased thromboembolic risk. *J Am Coll Cardiol* 1988;**11**:1204–11.
88. Fatkin D, Kuchar DL, Thorburn CW, Feneley MP. Transesophageal echocardiography before and during direct current cardioversion of atrial fibrillation: evidence for "atrial stunning" as a mechanism of thromboembolic complications. *J Am Coll Cardiol* 1994;**23**:307–16.
89. Fatkin D, Kelly RP, Feneley MP. Relations between left atrial appendage blood flow velocity, spontaneous echocardiographic contrast and thromboembolic risk *in vivo*. *J Am Coll Cardiol* 1994;**23**:961–9.
90. Lowe BS, Kusunose K, Motoki H, Varr B, Shrestha K, Whitman C *et al.* Prognostic significance of left atrial appendage "sludge" in patients with atrial fibrillation: a new transesophageal echocardiographic thromboembolic risk factor. *J Am Soc Echocardiogr* 2014;**27**:1176–83.
91. Yoo J, Song D, Baek J-H, Kim YD, Nam HS, Hong G-R *et al.* Poor outcome of stroke patients with atrial fibrillation in the presence of coexisting spontaneous echo contrast. *Stroke* 2016;**47**:1920–2.
92. Squara F, Bres M, Baudouy D, Schouver E-D, Moceri P, Ferrari E *et al.* Transesophageal echocardiography for the assessment of left atrial appendage thrombus: study of the additional value of systematic real time 3D imaging after regular 2D evaluation. *Echocardiography* 2018;**35**:474–80.
93. Leung DYC, Black IW, Cranney GB, Hopkins AP, Walsh WF. Prognostic implications of left atrial spontaneous echo contrast in nonvalvular atrial fibrillation. *J Am Coll Cardiol* 1994;**24**:755–62.
94. Soulat-Dufour L, Lang S, Etienney A, Ederhy S, Ancedy Y, Adavane S *et al.* Correlation between left atrial spontaneous echocardiographic contrast and 5-year stroke/death in patients with non-valvular atrial fibrillation. *Arch Cardiovasc Dis* 2020;**113**:525–33.
95. Hwang J-J, Shyu K-G, Hsu K-L, Chen J-J, Kuan P, Lien W-P *et al.* Significant mitral regurgitation is protective against left atrial spontaneous echo contrast formation, but not against systemic embolism. *Chest* 1994;**106**:8–12.
96. Sievert H, Lesh MD, Trepels T, Omran H, Bartorelli A, Della Bella P *et al.* Percutaneous left atrial appendage transcatheter occlusion to prevent stroke in high-risk patients with atrial fibrillation: early clinical experience. *Circulation* 2002;**105**:1887–9.
97. Ostermayer SH, Reisman M, Kramer PH, Matthews RV, Gray WA, Block PC *et al.* Percutaneous left atrial appendage transcatheter occlusion (PLAATO system) to prevent stroke in high-risk patients with non-rheumatic atrial fibrillation: results from the international multi-center feasibility trials. *J Am Coll Cardiol* 2005;**46**:9–14.
98. Fountain R, Holmes DR, Hodgson PK, Chandrasekaran K, Van Tassel R, Sick P *et al.* Potential applicability and utilization of left atrial appendage occlusion devices in patients with atrial fibrillation. *Am Heart J* 2006;**152**:720–3.
99. Cabrera JA, Saremi F, Sanchez-Quintana D. Left atrial appendage: anatomy and imaging landmarks pertinent to percutaneous transcatheter occlusion. *Heart* 2014;**100**:1636–50.
100. Veinot JP, Harrity PJ, Gentile F, Khandheria BK, Bailey KR, Eickholt JT *et al.* Anatomy of the normal left atrial appendage: a quantitative study of age-related changes in 500 autopsy hearts: implications for echocardiographic examination. *Circulation* 1997;**96**:3112–5.
101. Tamura H, Watanabe T, Nishiyama S, Sasaki S, Wanezaki M, Arimoto T *et al.* Prognostic value of low left atrial appendage wall velocity in patients with ischemic stroke and atrial fibrillation. *J Am Soc Echocardiogr* 2012;**25**:576–83.
102. Doukky R, Garcia-Sayan E, Patel M, Pant R, Wassouf M, Shah S *et al.* Impact of diastolic function parameters on the risk for left atrial appendage thrombus in patients with nonvalvular atrial fibrillation: a prospective study. *J Am Soc Echocardiogr* 2016;**29**:545–53.
103. Fatema K, Bailey KR, Petty GW, Meissner I, Osranek M, Alsaileek AA *et al.* Increased left atrial volume index: potent biomarker for first-ever ischemic stroke. *Mayo Clin Proc* 2008;**83**:1107–15.
104. Acar J, Cormier B, Grimberg D, Kawthekar G, Iung B, Scheuer B *et al.* Diagnosis of left atrial thrombi in mitral stenosis—usefulness of ultrasound techniques compared with other methods. *Eur Heart J* 1991;**12**:70–6.
105. Manning WJ, Weintraub RM, Waksmonski CA, Haering JM, Rooney PS, Maslow AD *et al.* Accuracy of transesophageal echocardiography for identifying left atrial thrombi. A prospective, intraoperative study. *Ann Intern Med* 1995;**123**: 817–22.
106. von der Recke G, Schmidt H, Illien S, Lüderitz B, Omran H. Use of transesophageal contrast echocardiography for excluding left atrial appendage thrombi in patients with atrial fibrillation before cardioversion. *J Am Soc Echocardiogr* 2002; **15**:1256–61.
107. Agmon Y, Khandheria BK, Gentile F, Seward JB. Echocardiographic assessment of the left atrial appendage. *J Am Coll Cardiol* 1999;**34**:1867–77.
108. Patti G, Pengo V, Marcucci R, Cirillo P, Renda G, Santilli F *et al.*; Working Group of Thrombosis of the Italian Society of Cardiology. The left atrial appendage: from embryology to prevention of thromboembolism. *Eur Heart J* 2017;**38**:877–87.
109. Kamp O, Verhorst PM, Welling RC, Visser CA. Importance of left atrial appendage flow as a predictor of thromboembolic events in patients with atrial fibrillation. *Eur Heart J* 1999;**20**:979–85.
110. Goldman ME, Pearce LA, Hart RG, Zabalgoitia M, Asinger RW, Safford R *et al.* Pathophysiologic correlates of thromboembolism in nonvalvular atrial fibrillation: I. Reduced flow velocity in the left atrial appendage (The Stroke Prevention in Atrial Fibrillation [SPAF-III] study). *J Am Soc Echocardiogr* 1999;**12**: 1080–7.
111. Shah SJ, Bardo DME, Sugeng L, Weinert L, Lodato JA, Knight BP *et al.* Real-time three-dimensional transesophageal echocardiography of the left atrial appendage: initial experience in the clinical setting. *J Am Soc Echocardiogr* 2008;**21**: 1362–8.
112. Nucifora G, Faletra FF, Regoli F, Pasotti E, Pedrazzini G, Moccetti T *et al.* Evaluation of the left atrial appendage with real-time 3-dimensional transesophageal echocardiography: implications for catheter-based left atrial appendage closure. *Circ Cardiovasc Imaging* 2011;**4**:514–23.
113. Nakajima H, Seo Y, Ishizu T, Yamamoto M, Machino T, Harimura Y *et al.* Analysis of the left atrial appendage by three-dimensional transesophageal echocardiography. *Am J Cardiol* 2010;**106**:885–92.
114. Tanaka K, Koga M, Sato K, Suzuki R, Minematsu K, Toyoda K *et al.* Three-dimensional analysis of the left atrial appendage for detecting paroxysmal atrial fibrillation in acute ischemic stroke. *Int J Stroke* 2014;**9**:1045–51.
115. Yamamoto M, Seo Y, Kawamatsu N, Sato K, Sugano A, Machino-Ohtsuka T *et al.* Complex left atrial appendage morphology and left atrial appendage thrombus formation in patients with atrial fibrillation. *Circ Cardiovasc Imaging* 2014;**7**:337–43.
116. Kim YY, Klein AL, Halliburton SS, Popovic ZB, Kuzmiak SA, Sola S *et al.* Left atrial appendage filling defects identified by multidetector computed tomography in patients undergoing radiofrequency pulmonary vein antral isolation: a comparison with transesophageal echocardiography. *Am Heart J* 2007;**154**: 1199–205.
117. Hur J, Kim YJ, Nam JE, Choe KO, Choi E-Y, Shim C-Y *et al.* Thrombus in the left atrial appendage in stroke patients: detection with cardiac CT angiography—a preliminary report. *Radiology* 2008;**249**:81–7.
118. Hur J, Kim YJ, Lee H-J, Ha J-W, Heo JH, Choi E-Y *et al.* Left atrial appendage thrombi in stroke patients: detection with two-phase cardiac CT angiography versus transesophageal echocardiography. *Radiology* 2009;**251**:683–90.
119. Kim SC, Chun EJ, Choi SI, Lee S-J, Chang H-J, Han M-K *et al.* Differentiation between spontaneous echocardiographic contrast and left atrial appendage thrombus in patients with suspected embolic stroke using two-phase multidetector computed tomography. *Am J Cardiol* 2010;**106**:1174–81.
120. Lee JM, Shim J, Uhm J-S, Kim YJ, Lee H-J, Pak H-N *et al.* Impact of increased orifice size and decreased flow velocity of left atrial appendage on stroke in nonvalvular atrial fibrillation. *Am J Cardiol* 2014;**113**:963–9.
121. Burrell LD, Horne BD, Anderson JL, Muhlestein JB, Whisenant BK. Usefulness of left atrial appendage volume as a predictor of embolic stroke in patients with atrial fibrillation. *Am J Cardiol* 2013;**112**:1148–52.
122. Di Biase L, Santangeli P, Anselmino M, Mohanty P, Salvetti I, Gili S *et al.* Does the left atrial appendage morphology correlate with the risk of stroke in patients with atrial fibrillation? Results from a multicenter study. *J Am Coll Cardiol* 2012;**60**:531–8.
123. Lupercio F, Carlos Ruiz J, Briceno DF, Romero J, Villablanca PA, Berardi C *et al.* Left atrial appendage morphology assessment for risk stratification of embolic stroke in patients with atrial fibrillation: a meta-analysis. *Heart Rhythm* 2016;**13**: 1402–9.
124. Fukushima K, Fukushima N, Kato K, Ejima K, Sato H, Fukushima K *et al.* Correlation between left atrial appendage morphology and flow velocity in patients with paroxysmal atrial fibrillation. *Eur Heart J Cardiovasc Imaging* 2016; **17**:59–66.
125. Akoum N, Fernandez G, Wilson B, Mcgann C, Kholmovski E, Marrouche N *et al.* Association of atrial fibrosis quantified using LGE-MRI with atrial appendage thrombus and spontaneous contrast on transesophageal echocardiography in patients with atrial fibrillation. *J Cardiovasc Electrophysiol* 2013;**24**:1104–9.
126. Goette A, Kalman JM, Aguinaga L, Akar J, Cabrera JA, Chen SA *et al.* EHRA/HRS/APHRS/SOLAECE expert consensus on atrial cardiomyopathies: definition, characterization, and clinical implication. *Heart Rhythm* 2017;**14**:e3–40.

Downloaded from https://academic.oup.com/ehjcimaging/article/22/6/e24/6168685 by Universiteit Leiden / LUMC user on 22 June 2022

127. Brambatti M, Connolly SJ, Gold MR, Morillo CA, Capucci A, Muto C *et al.* Temporal relationship between subclinical atrial fibrillation and embolic events. *Circulation* 2014;**129**:2094–9.
128. Guichard JB, Nattel S. Atrial cardiomyopathy: a useful notion in cardiac disease management or a passing fad? *J Am Coll Cardiol* 2017;**70**:756–65.
129. Habibi M, Zareian M, Ambale Venkatesh B, Samiei S, Imai M, Wu C *et al.* Left atrial mechanical function and incident ischemic cerebrovascular events independent of AF: insights from the MESA study. *JACC Cardiovasc Imaging* 2019;**12**: 2417–27.
130. Lee JM, Park JJ, Jung HW, Cho Y-S, Oh I-Y, Yoon C-H *et al.* Left ventricular thrombus and subsequent thromboembolism, comparison of anticoagulation, surgical removal, and antiplatelet agents. *JAT* 2013;**20**:73–93.
131. Habash F, Vallurupalli S. Challenges in management of left ventricular thrombus. *Ther Adv Cardiovasc Dis* 2017;**11**:203–13.
132. Bière L, Audonnet M, Clerfond G, Delagarde H, Willoteaux S, Prunier F *et al.* First pass perfusion imaging to improve the assessment of left ventricular thrombus following a myocardial infarction. *Eur J Radiol* 2016;**85**:1532–7.
133. Weinsaft JW, Kim RJ, Ross M, Krauser D, Manoushagian S, LaBounty TM *et al.* Contrast-enhanced anatomic imaging as compared to contrast-enhanced tissue characterization for detection of left ventricular thrombus. *JACC Cardiovasc Imaging* 2009;**2**:969–79.
134. Weinsaft JW, Kim HW, Crowley AL, Klem I, Shenoy C, Van Assche L *et al.* LV thrombus detection by routine echocardiography: insights into performance characteristics using delayed enhancement CMR. *JACC Cardiovasc Imaging* 2011; **4**:702–12.
135. Wada H, Yasu T, Sakakura K, Hayakawa Y, Ishida T, Kobayashi N *et al.* Contrast echocardiography for the diagnosis of left ventricular thrombus in anterior myocardial infarction. *Heart Vessels* 2014;**29**:308–12.
136. Weinsaft JW, Kim HW, Shah DJ, Klem I, Crowley AL, Brosnan R *et al.* Detection of left ventricular thrombus by delayed-enhancement cardiovascular magnetic resonance prevalence and markers in patients with systolic dysfunction. *J Am Coll Cardiol* 2008;**52**:148–57.
137. Srichai MB, Junor C, Rodriguez LL, Stillman AE, Grimm RA, Lieber ML *et al.* Clinical, imaging, and pathological characteristics of left ventricular thrombus: a comparison of contrast-enhanced magnetic resonance imaging, transthoracic echocardiography, and transesophageal echocardiography with surgical or pathological validation. *Am Heart J* 2006;**152**:75–84.
138. Bittencourt MS, Achenbach S, Marwan M, Seltmann M, Muschiol G, Ropers D *et al.* Left ventricular thrombus attenuation characterization in cardiac computed tomography angiography. *J Cardiovasc Comput Tomogr* 2012;**6**:121–6.
139. Paydarfar D, Krieger D, Dib N, Blair RH, Pastore JO, Stetz Jr JJ *et al. In vivo* magnetic resonance imaging and surgical histopathology of intracardiac masses: distinct features of subacute thrombi. *Cardiology* 2001;**95**:40–7.
140. Haugland JM, Asinger RW, Mikell FL, Elsperger J, Hodges M. Embolic potential of left ventricular thrombi detected by two-dimensional echocardiography. *Circulation* 1984;**70**:588–98.
141. Johannessen KA, Nordrehaug JE, von der Lippe G. Left ventricular thrombosis and cerebrovascular accident in acute myocardial infarction. *Br Heart J* 1984;**51**: 553–6.
142. Jugdutt BI, Sivaram CA, Wortman C, Trudell C, Penner P. Prospective two-dimensional echocardiographic evaluation of left ventricular thrombus and embolism after acute myocardial infarction. *J Am Coll Cardiol* 1989;**13**:554–64.
143. Keren A, Goldberg S, Gottlieb S, Klein J, Schuger C, Medina A *et al.* Natural history of left ventricular thrombi: their appearance and resolution in the posthospitalization period of acute myocardial infarction. *J Am Coll Cardiol* 1990;**15**: 790–800.
144. Nihoyannopoulos P, Smith GC, Maseri A, Foale RA. The natural history of left ventricular thrombus in myocardial infarction: a rationale in support of masterly inactivity. *J Am Coll Cardiol* 1989;**14**:903–11.
145. Stratton JR, Resnick AD. Increased embolic risk in patients with left ventricular thrombi. *Circulation* 1987;**75**:1004–11.
146. Visser CA, Kan G, Meltzer RS, Dunning AJ, Roelandt J. Embolic potential of left ventricular thrombus after myocardial infarction: a two-dimensional echocardiographic study of 119 patients. *J Am Coll Cardiol* 1985;**5**:1276–80.
147. Weinreich DJ, Burke JF, Pauletto FJ. Left ventricular mural thrombi complicating acute myocardial infarction. Long-term follow-up with serial echocardiography. *Ann Intern Med* 1984;**100**:789–94.
148. Domenicucci S, Chiarella F, Bellotti P, Bellone P, Lupi G, Vecchio C *et al.* Long-term prospective assessment of left ventricular thrombus in anterior wall acute myocardial infarction and implications for a rational approach to embolic risk. *Am J Cardiol* 1999;**83**:519–24.
149. Witt BJ, Brown RD, Jacobsen SJ, Weston SA, Yawn BP, Roger VL *et al.* A community-based study of stroke incidence after myocardial infarction. *Ann Intern Med* 2005;**143**:785–92.
150. Witt BJ, Ballman KV, Brown RD Jr, Meverden RA, Jacobsen SJ, Roger VL. The incidence of stroke after myocardial infarction: a meta-analysis. *Am J Med* 2006; **119**:354.e1–9.
151. Keeley EC, Hillis LD. Left ventricular mural thrombus after acute myocardial infarction. *Clin Cardiol* 1996;**19**:83–6.
152. Chiarella F, Santoro E, Domenicucci S, Maggioni A, Vecchio C. Predischarge two-dimensional echocardiographic evaluation of left ventricular thrombosis after acute myocardial infarction in the GISSI-3 study. *Am J Cardiol* 1998;**81**: 822–7.
153. Visser CA, Kan G, Meltzer RS, Lie KI, Durrer D. Long-term follow-up of left ventricular thrombus after acute myocardial infarction. A two-dimensional echocardiographic study in 96 patients. *Chest* 1984;**86**:532–6.
154. Mooe T, Eriksson P, Stegmayr B. Ischemic stroke after acute myocardial infarction. A population-based study. *Stroke* 1997;**28**:762–7.
155. Goodman SG, Menon V, Cannon CP, Steg G, Ohman EM, Harrington RA *et al.* Acute ST-segment elevation myocardial infarction: American College of Chest Physicians Evidence-Based Clinical Practice Guidelines (8th Edition). *Chest* 2008; **133**:708S–75S.
156. Harrington RA, Becker RC, Cannon CP, Gutterman D, Lincoff AM, Popma JJ *et al.* Antithrombotic therapy for non-ST-segment elevation acute coronary syndromes: american College of Chest Physicians Evidence-Based Clinical Practice Guidelines (8th Edition). *Chest* 2008;**133**:670S–707S.
157. Gueret P, Khalife K, Jobic Y, Fillipi E, Isaaz K, Tassan-Mangina S *et al.* Echocardiographic assessment of the incidence of mechanical complications during the early phase of myocardial infarction in the reperfusion era: a French multicentre prospective registry. *Arch Cardiovasc Dis* 2008;**101**:41–7.
158. Vaitkus PT, Barnathan ES. Embolic potential, prevention and management of mural thrombus complicating anterior myocardial infarction: a meta-analysis. *J Am Coll Cardiol* 1993;**22**:1004–9.
159. Lapeyre AC, Steele PM, Kazmier FJ, Chesebro JH, Vlietstra RE, Fuster V *et al.* Systemic embolism in chronic left ventricular aneurysm: incidence and the role of anticoagulation. *J Am Coll Cardiol* 1985;**6**:534–8.
160. Amarenco P, Lavallée PC, Labreuche J, Ducrocq G, Juliard J-M, Feldman L *et al.* Prevalence of coronary atherosclerosis in patients with cerebral infarction. *Stroke* 2011;**42**:22–9.
161. Hur J, Lee KH, Hong SR, Suh YJ, Hong YJ, Lee H-J *et al.* Prognostic value of coronary computed tomography angiography in stroke patients. *Atherosclerosis* 2015;**238**:271–7.
162. Adams RJ, Chimowitz MI, Alpert JS, Awad IA, Cerqueria MD, Fayad P *et al.* Coronary risk evaluation in patients with transient ischemic attack and ischemic stroke: a scientific statement for healthcare professionals from the Stroke Council and the Council on Clinical Cardiology of the American Heart Association/American Stroke Association. *Circulation* 2003;**108**:1278–90.
163. Donal E, Delgado V, Bucciarelli-Ducci C, Galli E, Haugaa KH, Charron P *et al.*; 2016–18 EACVI Scientific Documents Committee. Multimodality imaging in the diagnosis, risk stratification, and management of patients with dilated cardiomyopathies: an expert consensus document from the European Association of Cardiovascular Imaging. *Eur Heart J Cardiovasc Imaging* 2019;**20**:1075–93.
164. Loh E, Sutton MSJ, Wun C-CC, Rouleau JL, Flaker GC, Gottlieb SS *et al.* Ventricular dysfunction and the risk of stroke after myocardial infarction. *N Engl J Med* 1997;**336**:251–7.
165. Sharma ND, McCullough PA, Philbin EF, Weaver WD. Left ventricular thrombus and subsequent thromboembolism in patients with severe systolic dysfunction. *Chest* 2000;**117**:314–20.
166. Hays AG, Sacco RL, Rundek T, Sciacca RR, Jin Z, Liu R *et al.* Left ventricular systolic dysfunction and the risk of ischemic stroke in a multiethnic population. *Stroke* 2006;**37**:1715–9.
167. Bakalli A, Georgievska-Ismail L, Koçinaj D, Musliu N, Krasniqi A, Pllana E *et al.* Prevalence of left chamber cardiac thrombi in patients with dilated left ventricle at sinus rhythm: the role of transesophageal echocardiography. *J Clin Ultrasound* 2013;**41**:38–45.
168. Maisel WH, Stevenson LW. Atrial fibrillation in heart failure: epidemiology, pathophysiology, and rationale for therapy. *Am J Cardiol* 2003;**91**:2–8D.
169. Pfeffer MA, Braunwald E, Moyé LA, Basta L, Brown EJ, Cuddy TE *et al.* Effect of captopril on mortality and morbidity in patients with left ventricular dysfunction after myocardial infarction. Results of the survival and ventricular enlargement trial. The SAVE Investigators. *N Engl J Med* 1992;**327**:669–77.
170. Spirito P, Chiarella F, Carratino L, Berisso MZ, Bellotti P, Vecchio C *et al.* Clinical course and prognosis of hypertrophic cardiomyopathy in an outpatient population. *N Engl J Med* 1989;**320**:749–55.
171. Maron BJ. Hypertrophic cardiomyopathy: a systematic review. *Jama* 2002;**287**: 1308–20.
172. Maron BJ, Olivotto I, Bellone P, Conte MR, Cecchi F, Flygenring BP *et al.* Clinical profile of stroke in 900 patients with hypertrophic cardiomyopathy. *J Am Coll Cardiol* 2002;**39**:301–7.

Downloaded from https://academic.oup.com/ehjcimaging/article/22/6/e24/6168685 by Universiteit Leiden / LUMC user on 22 June 2022

173. Maron MS, Finley JJ, Bos JM, Hauser TH, Manning WJ, Haas TS *et al.* Prevalence, clinical significance, and natural history of left ventricular apical aneurysms in hypertrophic cardiomyopathy. *Circulation* 2008;**118**:1541–9.
174. Haruki S, Minami Y, Hagiwara N. Stroke and embolic events in hypertrophic cardiomyopathy: risk stratification in patients without atrial fibrillation. *Stroke* 2016;**47**:936–42.
175. Rowin EJ, Maron BJ, Haas TS, Garberich RF, Wang W, Link MS *et al.* Hypertrophic cardiomyopathy with left ventricular apical aneurysm: implications for risk stratification and management. *J Am Coll Cardiol* 2017;**69**:761–73.
176. Habib G, Bucciarelli-Ducci C, Caforio ALP, Cardim N, Charron P, Cosyns B *et al.*; EACVI Scientific Documents Committee. Multimodality Imaging in Restrictive Cardiomyopathies: an EACVI expert consensus document In collaboration with the "Working Group on myocardial and pericardial diseases" of the European Society of Cardiology Endorsed by The Indian Academy of Echocardiography. *Eur Heart J Cardiovasc Imaging* 2017;**18**:1090–121.
177. Feng DLi, Edwards WD, Oh JK, Chandrasekaran K, Grogan M, Martinez MW *et al.* Intracardiac thrombosis and embolism in patients with cardiac amyloidosis. *Circulation* 2007;**116**:2420–6.
178. Stöllberger C, Blazek G, Dobias C, Hanafin A, Wegner C, Finsterer J *et al.* Frequency of stroke and embolism in left ventricular hypertrabeculation/noncompaction. *Am J Cardiol* 2011;**108**:1021–3.
179. Templin C, Ghadri JR, Diekmann J, Napp LC, Bataiosu DR, Jaguszewski M *et al.* Clinical features and outcomes of takotsubo (stress) cardiomyopathy. *N Engl J Med* 2015;**373**:929–38.
180. Olsson LG, Swedberg K, Ducharme A, Granger CB, Michelson EL, McMurray JJV *et al.* Atrial fibrillation and risk of clinical events in chronic heart failure with and without left ventricular systolic dysfunction: results from the Candesartan in Heart failure-Assessment of Reduction in Mortality and morbidity (CHARM) program. *J Am Coll Cardiol* 2006;**47**:1997–2004.
181. Doukky R, Garcia-Sayan E, Gage H, Nagarajan V, Demopoulos A, Cena M *et al.* The value of diastolic function parameters in the prediction of left atrial appendage thrombus in patients with nonvalvular atrial fibrillation. *Cardiovasc Ultrasound* 2014;**12**:10.
182. Adelborg K, Szépligeti S, Sundbøll J, Horváth-Puhó E, Henderson VW, Ording A *et al.* Risk of stroke in patients with heart failure: a population-based 30-year cohort study. *Stroke* 2017;**48**:1161–8.
183. Di Tullio MR, Qian M, Thompson JLP, Labovitz AJ, Mann DL, Sacco RL *et al.* Left ventricular ejection fraction and risk of stroke and cardiac events in heart failure: data from the warfarin versus aspirin in reduced ejection fraction trial. *Stroke* 2016;**47**:2031–7.
184. Campbell RT, Jhund PS, Castagno D, Hawkins NM, Petrie MC, McMurray JJV *et al.* What have we learned about patients with heart failure and preserved ejection fraction from DIG-PEF, CHARM-preserved, and I-PRESERVE? *J Am Coll Cardiol* 2012;**60**:2349–56.
185. Abdul-Rahim AH, Perez A-C, Fulton RL, Jhund PS, Latini R, Tognoni G *et al.* Risk of stroke in chronic heart failure patients without atrial fibrillation: analysis of the Controlled Rosuvastatin in Multinational Trial Heart Failure (CORONA) and the Gruppo Italiano per lo Studio della Sopravvivenza nell'Insufficienza Cardiaca-Heart Failure (GISSI-HF) trials. *Circulation* 2015;**131**:1486–94; discussion 1494.
186. Roberts WC. Neoplasms involving the heart, their simulators, and adverse consequences of their therapy. *Proc (Bayl Univ Med Cent)* 2001;**14**:358–76.
187. Vander Salm TJ. Unusual primary tumors of the heart. *Semin Thorac Cardiovasc Surg* 2000;**12**:89–100.
188. Sarjeant JM, Butany J, Cusimano RJ. Cancer of the heart: epidemiology and management of primary tumors and metastases. *Am J Cardiovasc Drugs* 2003;**3**:407–21.
189. Butany J, Nair V, Naseemuddin A, Nair GM, Catton C, Yau T *et al.* Cardiac tumours: diagnosis and management. *Lancet Oncol* 2005;**6**:219–28.
190. Reynen K. Cardiac myxomas. *N Engl J Med* 1995;**333**:1610–7.
191. Maraj S, Pressman GS, Figueredo VM. Primary cardiac tumors. *Int J Cardiol* 2009;**133**:152–6.
192. Pinede L, Duhaut P, Loire R. Clinical presentation of left atrial cardiac myxoma. A series of 112 consecutive cases. *Medicine (Baltimore)* 2001;**80**:159–72.
193. Obrenovic-Kircanski B, Mikic A, Parapid B, Djukić P, Kanjuh V, Milić N *et al.* A 30-year-single-center experience in atrial myxomas: from presentation to treatment and prognosis. *Thorac Cardiovasc Surg* 2013;**61**:530–6.
194. Colin GC, Gerber BL, Amzulescu M, Bogaert J. Cardiac myxoma: a contemporary multimodality imaging review. *Int J Cardiovasc Imaging* 2018;**34**:1789–808.
195. Sparrow PJ, Kurian JB, Jones TR, Sivananthan MU. MR imaging of cardiac tumors. *Radiographics* 2005;**25**:1255–76.
196. Sydow K, Willems S, Reichenspurner H, Meinertz T. Papillary fibroelastomas of the heart. *Thorac Cardiovasc Surg* 2008;**56**:9–13.
197. Tamin SS, Maleszewski JJ, Scott CG, Khan SK, Edwards WD, Bruce CJ *et al.* Prognostic and bioepidemiologic implications of papillary fibroelastomas. *J Am Coll Cardiol* 2015;**65**:2420–9.
198. Gowda RM, Khan IA, Nair CK, Mehta NJ, Vasavada BC, Sacchi TJ *et al.* Cardiac papillary fibroelastoma: a comprehensive analysis of 725 cases. *Am Heart J* 2003;**146**:404–10.
199. Saad RS, Galvis CO, Bshara W *et al.* Pulmonary valve papillary fibroelastoma. A case report and review of the literature. *Arch Pathol Lab Med* 2001;**125**:933–4.
200. Dehnee AE, Brizendine S, Herrera CJ. Recurrent strokes in a young patient with papillary fibroelastoma: a case report and literature review. *Echocardiography* 2006;**23**:592–5.
201. Baba Y, Tsuboi Y, Sakiyama K, Nakajima M, Fjino Y, Meschia JF *et al.* Cardiac papillary fibroelastoma as a cause of recurrent ischemic strokes: the diagnostic value of serial transesophageal echocardiography. *Cerebrovasc Dis* 2002;**14**:256–9.
202. Klarich KW, Enriquez-Sarano M, Gura GM, Edwards WD, Tajik AJ, Seward JB *et al.* Papillary fibroelastoma: echocardiographic characteristics for diagnosis and pathologic correlation. *J Am Coll Cardiol* 1997;**30**:784–90.
203. Habib G. Embolic risk in subacute bacterial endocarditis: determinants and role of transesophageal echocardiography. *Curr Cardiol Rep* 2003;**5**:129–36.
204. Habib G, Lancellotti P, Antunes MJ, Bongiorni MG, Casalta JP, Del Zotti F *et al.* 2015 ESC Guidelines for the management of infective endocarditis: the Task Force for the Management of Infective Endocarditis of the European Society of Cardiology (ESC). Endorsed by: European Association for Cardio-Thoracic Surgery (EACTS), the European Association of Nuclear Medicine (EANM). *Eur Heart J* 2015;**36**:3075–128.
205. Thuny F, Disalvo G, Belliard O, Avierinos J-F, Pergola V, Rosenberg V *et al.* Risk of embolism and death in infective endocarditis: prognostic value of echocardiography: a prospective multicenter study. *Circulation* 2005;**112**:69–75.
206. Thuny F, Avierinos J-F, Tribouilloy C, Giorgi R, Casalta J-P, Milandre L *et al.* Impact of cerebrovascular complications on mortality and neurologic outcome during infective endocarditis: a prospective multicentre study. *Eur Heart J* 2007;**28**:1155–61.
207. Steckelberg JM, Murphy JG, Ballard D, Bailey K, Tajik AJ, Taliercio CP *et al.* Emboli in infective endocarditis: the prognostic value of echocardiography. *Ann Intern Med* 1991;**114**:635–40.
208. Habib G, Badano L, Tribouilloy C, Vilacosta I, Zamorano JL, Galderisi M *et al.* Recommendations for the practice of echocardiography in infective endocarditis. *Eur J Echocardiogr* 2010;**11**:202–19.
209. Bai AD, Steinberg M, Showler A, Burry L, Bhatia RS, Tomlinson GA *et al.* Diagnostic accuracy of transthoracic echocardiography for infective endocarditis findings using transesophageal echocardiography as the reference standard: a meta-analysis. *J Am Soc Echocardiogr* 2017;**30**:639–46.e8.
210. Di Salvo G, Habib G, Pergola V, Avierinos J-F, Philip E, Casalta J-P *et al.* Echocardiography predicts embolic events in infective endocarditis. *J Am Coll Cardiol* 2001;**37**:1069–76.
211. Hubert S, Thuny F, Resseguier N, Giorgi R, Tribouilloy C, Le Dolley Y *et al.* Prediction of symptomatic embolism in infective endocarditis: construction and validation of a risk calculator in a multicenter cohort. *J Am Coll Cardiol* 2013;**62**:1384–92.
212. Vilacosta I, Graupner C, SanRomán JA, Sarriá C, Ronderos R, Fernández C *et al.* Risk of embolization after institution of antibiotic therapy for infective endocarditis. *J Am Coll Cardiol* 2002;**39**:1489–95.
213. García-Cabrera E, Fernández-Hidalgo N, Almirante B, Ivanova-Georgieva R, Noureddine M, Plata A *et al.* Neurological complications of infective endocarditis: risk factors, outcome, and impact of cardiac surgery: a multicenter observational study. *Circulation* 2013;**127**:2272–84.
214. Bruun NE, Habib G, Thuny F, Sogaard P. Cardiac imaging in infectious endocarditis. *Eur Heart J* 2014;**35**:624–32.
215. Saby L, Laas O, Habib G, Cammilleri S, Mancini J, Tessonnier L *et al.* Positron emission tomography/computed tomography for diagnosis of prosthetic valve endocarditis: increased valvular 18F-fluorodeoxyglucose uptake as a novel major criterion. *J Am Coll Cardiol* 2013;**61**:2374–82.
216. Habets J, Tanis W, Reitsma JB, van den Brink RB, Mali WP, Chamuleau SA *et al.* Are novel non-invasive imaging techniques needed in patients with suspected prosthetic heart valve endocarditis? A systematic review and meta-analysis. *Eur Radiol* 2015;**25**:2125–33.
217. Liu J, Frishman WH. Nonbacterial thrombotic endocarditis: pathogenesis, diagnosis, and management. *Cardiol Rev* 2016;**24**:244–7.
218. Lee JL, Naguwa SM, Cheema GS, Gershwin ME. Revisiting Libman-Sacks endocarditis: a historical review and update. *Clinic Rev Allerg Immunol* 2009;**36**:126–30.
219. Edoute Y, Haim N, Rinkevich D, Brenner B, Reisner SA. Cardiac valvular vegetations in cancer patients: a prospective echocardiographic study of 200 patients. *Am J Med* 1997;**102**:252–8.
220. Deppisch LM, Fayemi AO. Non-bacterial thrombotic endocarditis: clinicopathologic correlations. *Am Heart J* 1976;**92**:723–9.

Downloaded from https://academic.oup.com/ehjcimaging/article/22/6/e24/6168685 by Universiteit Leiden / LUMC user on 22 June 2022

221. Reisner SA, Brenner B, Haim N, Edoute Y, Markiewicz W. Echocardiography in nonbacterial thrombotic endocarditis: from autopsy to clinical entity. *J Am Soc Echocardiogr* 2000;**13**:876–81.
222. Eiken PW, Edwards WD, Tazelaar HD, McBane RD, Zehr KJ. Surgical pathology of nonbacterial thrombotic endocarditis in 30 patients, 1985-2000. *Mayo Clin Proc* 2001;**76**:1204–12.
223. Hart RG, Foster JW, Luther MF, Kanter MC. Stroke in infective endocarditis. *Stroke* 1990;**21**:695–700.
224. Singhal AB, Topcuoglu MA, Buonanno FS. Acute ischemic stroke patterns in infective and nonbacterial thrombotic endocarditis: a diffusion-weighted magnetic resonance imaging study. *Stroke* 2002;**33**:1267–73.
225. Roldan CA, Qualls CR, Sopko KS, Sibbitt WL Jr. Transthoracic versus transesophageal echocardiography for detection of Libman-Sacks endocarditis: a randomized controlled study. *J Rheumatol* 2008;**35**:224–9.
226. Dutta T, Karas MG, Segal AZ, Kizer JR. Yield of transesophageal echocardiography for nonbacterial thrombotic endocarditis and other cardiac sources of embolism in cancer patients with cerebral ischemia. *Am J Cardiol* 2006;**97**: 894–8.
227. Zamorano J, de Isla LP, Moura L *et al.* Impact of echocardiography in the short- and long-term prognosis of patients with infective endocarditis and negative blood cultures. *J Heart Valve Dis* 2004;**13**:997–1004.
228. Roldan CA, Tolstrup K, Macias L, Qualls CR, Maynard D, Charlton G *et al.* Libman-Sacks endocarditis: detection, characterization, and clinical correlates by three-dimensional transesophageal echocardiography. *J Am Soc Echocardiogr* 2015;**28**:770–9.
229. Amarenco P, Duyckaerts C, Tzourio C, Hénin D, Bousser M-G, Hauw J-J *et al.* The prevalence of ulcerated plaques in the aortic arch in patients with stroke. *N Engl J Med* 1992;**326**:221–5.
230. Tunick PA, Culliford AT, Lamparello PJ, Kronzon I. Atheromatosis of the aortic arch as an occult source of multiple systemic emboli. *Ann Intern Med* 1991;**114**: 391–2.
231. Guidoux C, Mazighi M, Lavallée P, Labreuche J, Meseguer E, Cabrejo L *et al.* Aortic arch atheroma in transient ischemic attack patients. *Atherosclerosis* 2013; **231**:124–8.
232. Amarenco P, Cohen A, Tzourio C, Bertrand B, Hommel M, Besson G *et al.* Atherosclerotic disease of the aortic arch and the risk of ischemic stroke. *N Engl J Med* 1994;**331**:1474–9.
233. French Study of Aortic Plaques in Stroke Group, Amarenco P, Cohen A, Hommel M, Moulin T, Leys D, Bousser M-G. Atherosclerotic disease of the aortic arch as a risk factor for recurrent ischemic stroke. *N Engl J Med* 1996; **334**:1216–21.
234. Cohen A, Tzourio C, Bertrand B, Chauvel C, Bousser M-G, Amarenco P *et al.* Aortic plaque morphology and vascular events: a follow-up study in patients with ischemic stroke. FAPS Investigators. French Study of Aortic Plaques in Stroke. *Circulation* 1997;**96**:3838–41.
235. Avegliano G, Evangelista A, Elorz C, González-Alujas T, García del Castillo H, Soler-Soler J *et al.* Acute peripheral arterial ischemia and suspected aortic dissection: usefulness of transesophageal echocardiography in differential diagnosis with aortic thrombosis. *Am J Cardiol* 2002;**90**:674–7.
236. Laperche T, Laurian C, Roudaut R, Steg PG. Mobile thromboses of the aortic arch without aortic debris. A transesophageal echocardiographic finding associated with unexplained arterial embolism. The Filiale Echocardiographie de la Societe Francaise de Cardiologie. *Circulation* 1997;**96**:288–94.
237. Mecklai A, Rosenzweig B, Applebaum R, Axel L, Grossi E, Chan A *et al.* Intimal sarcoma in the aortic arch partially obstructing the aorta with metastasis to the brain. *Tex Heart Inst J* 2014;**41**:433–6.
238. Sen S, Oppenheimer SM, Lima J, Cohen B. Risk factors for progression of aortic atheroma in stroke and transient ischemic attack patients. *Stroke* 2002;**33**: 930–5.
239. Sen S, Wu K, McNamara R, Lima J, Piantadosi S, Oppenheimer SM *et al.* Distribution, severity and risk factors for aortic atherosclerosis in cerebral ischemia. *Cerebrovasc Dis* 2000;**10**:102–9.
240. Saric M, Kronzon I. Aortic atherosclerosis and embolic events. *Curr Cardiol Rep* 2012;**14**:342–9.
241. Ferrari E, Taillan B, Drai E, Morand P, Baudouy M. Investigation of the thoracic aorta in cholesterol embolism by transoesophageal echocardiography. *Heart* 1998;**79**:133–6.
242. Karalis DG, Chandrasekaran K, Victor MF, Ross JJ, Mintz GS. Recognition and embolic potential of intraaortic atherosclerotic debris. *J Am Coll Cardiol* 1991; **17**:73–8.
243. Lund C, Nes RB, Ugelstad TP, Due-Tønnessen P, Andersen R, Hol PK *et al.* Cerebral emboli during left heart catheterization may cause acute brain injury. *Eur Heart J* 2005;**26**:1269–75.
244. Mackensen GB, Ti LK, Phillips-Bute BG, Mathew JP, Newman MF, Grocott HP *et al.* Cerebral embolization during cardiac surgery: impact of aortic atheroma burden. *Br J Anaesth* 2003;**91**:656–61.
245. Tugcu A, Jin Z, Homma S, Elkind MSV, Rundek T, Yoshita M *et al.* Atherosclerotic plaques in the aortic arch and subclinical cerebrovascular disease. *Stroke* 2016;**47**:2813–9.
246. Di Tullio MR, Sacco RL, Gersony D, Nayak H, Weslow RG, Kargman DE *et al.* Aortic atheromas and acute ischemic stroke: a transesophageal echocardiographic study in an ethnically mixed population. *Neurology* 1996;**46**:1560–6.
247. Piazzese C, Tsang W, Sotaquira M, Kronzon I, Lang RM, Caiani EG *et al.* Semiautomated detection and quantification of aortic plaques from three-dimensional transesophageal echocardiography. *J Am Soc Echocardiogr* 2014;**27**: 758–66.
248. Schwammenthal E, Schwammenthal Y, Tanne D, Tenenbaum A, Garniek A, Motro M *et al.* Transcutaneous detection of aortic arch atheromas by suprasternal harmonic imaging. *J Am Coll Cardiol* 2002;**39**:1127–32.
249. Weinberger J, Azhar S, Danisi F, Hayes R, Goldman M. A new noninvasive technique for imaging atherosclerotic plaque in the aortic arch of stroke patients by transcutaneous real-time B-mode ultrasonography: an initial report. *Stroke* 1998;**29**:673–6.
250. Agmon Y, Khandheria BK, Meissner I, Schwartz GL, Petterson TM, O'Fallon WM *et al.* Relation of coronary artery disease and cerebrovascular disease with atherosclerosis of the thoracic aorta in the general population. *Am J Cardiol* 2002;**89**:262–7.
251. Macleod MR, Amarenco P, Davis SM, Donnan GA. Atheroma of the aortic arch: an important and poorly recognised factor in the aetiology of stroke. *Lancet Neurol* 2004;**3**:408–14.
252. Cohen A. Atherosclerosis of the thoracic aorta further characterization for higher risk of vascular events. *J Am Coll Cardiol* 2008;**52**:862–4.
253. Di Tullio MR, Homma S, Jin Z, Sacco RL. Aortic atherosclerosis, hypercoagulability, and stroke the APRIS (Aortic Plaque and Risk of Ischemic Stroke) study. *J Am Coll Cardiol* 2008;**52**:855–61.
254. Agmon Y, Khandheria BK, Meissner I, Petterson TM, O'Fallon WM, Wiebers DO *et al.* C-reactive protein and atherosclerosis of the thoracic aorta: a population-based transesophageal echocardiographic study. *Arch Intern Med* 2004;**164**:1781–7.
255. Vongpatanasin W, Brickner ME, Willett DWL, Grayburn PA. Usefulness of transesophageal echocardiography in determining the source of emboli in patients with acute limb ischemia. *Am J Cardiol* 1998;**81**:253–5.
256. Tenenbaum A, Garniek A, Shemesh J, Fisman EZ, Stroh CI, Itzchak Y *et al.* Dual-helical CT for detecting aortic atheromas as a source of stroke: comparison with transesophageal echocardiography. *Radiology* 1998;**208**:153–8.
257. Ibanez B, Badimon JJ, Garcia MJ. Diagnosis of atherosclerosis by imaging. *Am J Med* 2009;**122**:S15–25.
258. Kamdar AR, Meadows TA, Roselli EE, Gorodeski EZ, Curtin RJ, Sabik JF *et al.* Multidetector computed tomographic angiography in planning of reoperative cardiothoracic surgery. *Ann Thorac Surg* 2008;**85**:1239–45.
259. Barazangi N, Wintermark M, Lease K, Rao R, Smith W, Josephson SA *et al.* Comparison of computed tomography angiography and transesophageal echocardiography for evaluating aortic arch disease. *J Stroke Cerebrovasc Dis* 2011;**20**: 436–42.
260. Benyounes N, Lang S, Savatovsky J, Cohen A, Lacroix D, Devys J-M *et al.* Diagnostic performance of computed tomography angiography compared with transesophageal echocardiography for the detection and the analysis of aortic atheroma. *Int J Stroke* 2013;**8**:E22.
261. Fayad ZA, Fuster V, Fallon JT, Jayasundera T, Worthley SG, Helft G *et al.* Noninvasive in vivo human coronary artery lumen and wall imaging using black-blood magnetic resonance imaging. *Circulation* 2000;**102**:506–10.
262. Fayad ZA, Nahar T, Fallon JT, Goldman M, Aguinaldo JG, Badimon JJ *et al.* *In vivo* magnetic resonance evaluation of atherosclerotic plaques in the human thoracic aorta: a comparison with transesophageal echocardiography. *Circulation* 2000; **101**:2503–9.
263. Saam T, Hatsukami TS, Takaya N, Chu B, Underhill H, Kerwin WS *et al.* The vulnerable, or high-risk, atherosclerotic plaque: noninvasive MR imaging for characterization and assessment. *Radiology* 2007;**244**:64–77.
264. Zhou C, Qiao H, He L, Yuan C, Chen H, Zhang Q *et al.* Characterization of atherosclerotic disease in thoracic aorta: a 3D, multicontrast vessel wall imaging study. *Eur J Radiol* 2016;**85**:2030–5.
265. Wehrum T, Dragonu I, Strecker C, Schuchardt F, Hennemuth A, Drexl J *et al.* Aortic atheroma as a source of stroke—assessment of embolization risk using 3D CMR in stroke patients and controls. *J Cardiovasc Magn Reson* 2017;**19**:67.
266. Cai J-M, Hatsukami TS, Ferguson MS, Small R, Polissar NL, Yuan C *et al.* Classification of human carotid atherosclerotic lesions with in vivo multicontrast magnetic resonance imaging. *Circulation* 2002;**106**:1368–73.
267. Puri R, Auffret V, Rodes-Cabau J. Bioprosthetic valve thrombosis. *J Am Coll Cardiol* 2017;**69**:2193–211.
268. Roudaut R, Serri K, Lafitte S. Thrombosis of prosthetic heart valves: diagnosis and therapeutic considerations. *Heart* 2007;**93**:137–42.

Downloaded from https://academic.oup.com/ehjcimaging/article/22/6/e24/6168685 by Universiteit Leiden / LUMC user on 22 June 2022

269. Lim WY, Lloyd G, Bhattacharyya S. Mechanical and surgical bioprosthetic valve thrombosis. *Heart* 2017;**103**:1934–41.
270. Tanis W, Habets J, van den Brink RBA, Symersky P, Budde RPJ, Chamuleau SAJ *et al.* Differentiation of thrombus from pannus as the cause of acquired mechanical prosthetic heart valve obstruction by non-invasive imaging: a review of the literature. *Eur Heart J Cardiovasc Imaging* 2014;**15**:119–29.
271. Tarzia V, Bortolussi G, Rubino M, Gallo M, Bottio T, Gerosa G *et al.* Evaluation of prosthetic valve thrombosis by 64-row multi-detector computed tomography. *J Heart Valve Dis* 2015;**24**:210–3.
272. Tong AT, Roudaut R, Özkan M, Sagie A, Shahid MSA, Pontes SC *et al.* Transesophageal echocardiography improves risk assessment of thrombolysis of prosthetic valve thrombosis: results of the international PRO-TEE registry. *J Am Coll Cardiol* 2004;**43**:77–84.
273. Alpert JS. The thrombosed prosthetic valve: current recommendations based on evidence from the literature. *J Am Coll Cardiol* 2003;**41**:659–60.
274. MüGge A, Daniel WG, Angermann C, Spes C, Khandheria BK, Kronzon I *et al.* Atrial septal aneurysm in adult patients. A multicenter study using transthoracic and transesophageal echocardiography. *Circulation* 1995;**91**:2785–92.
275. Homma S, Sacco RL. Patent foramen ovale and stroke. *Circulation* 2005;**112**:1063–72.
276. Giannopoulos A, Gavras C, Sarioglou S, Agathagelou F, Kassapoglou I, Athanassiadou F *et al.* Atrial septal aneurysms in childhood: prevalence, classification, and concurrent abnormalities. *Cardiol Young* 2014;**24**:453–8.
277. Scaffa R, Spaziani C, Leporace M, Leonetti S, Di Roma M, Gaspardone A *et al.* Voluminous atrial septal aneurysm may mask a large double atrial septal defect. *Ann Thorac Surg* 2012;**93**:e41.
278. Krumsdorf U, Keppeler P, Horvath K, Zadan E, Schrader R, Sievert H *et al.* Catheter closure of atrial septal defects and patent foramen ovale in patients with an atrial septal aneurysm using different devices. *J Interv Cardiol* 2001;**14**:49–55.
279. Belkin RN, Hurwitz BJ, Kisslo J. Atrial septal aneurysm: association with cerebrovascular and peripheral embolic events. *Stroke* 1987;**18**:856–62.
280. Agmon Y, Khandheria BK, Meissner I, Gentile F, Whisnant JP, Sicks JRD *et al.* Frequency of atrial septal aneurysms in patients with cerebral ischemic events. *Circulation* 1999;**99**:1942–4.
281. Berthet K, Lavergne T, Cohen A, Guize L, Bousser M-G, Le Heuzey J-Y *et al.* Significant association of atrial vulnerability with atrial septal abnormalities in young patients with ischemic stroke of unknown cause. *Stroke* 2000;**31**:398–403.
282. Overell JR, Bone I, Lees KR. Interatrial septal abnormalities and stroke: a meta-analysis of case-control studies. *Neurology* 2000;**55**:1172–9.
283. Pinto FJ. When and how to diagnose patent foramen ovale. *Heart* 2005;**91**:438–40.
284. Di Tullio MR. Patent foramen ovale: echocardiographic detection and clinical relevance in stroke. *J Am Soc Echocardiogr* 2010;**23**:144–55; quiz 220.
285. Webster MWI, Smith HJ, Sharpe DN, Chancellor AM, Swift DL, Bass NM *et al.* Patent foramen ovale in young stroke patients. *Lancet* 1988;**332**:11–2.
286. Van Camp G, Schulze D, Cosyns B, Vandenbossche J-L. Relation between patent foramen ovale and unexplained stroke. *Am J Cardiol* 1993;**71**:596–8.
287. Siostrzonek P, Lang W, Zangeneh M, Gössinger H, Stümpflen A, Rosenmayr G *et al.* Significance of left-sided heart disease for the detection of patent foramen ovale by transesophageal contrast echocardiography. *J Am Coll Cardiol* 1992;**19**:1192–6.
288. Mojadidi MK, Roberts SC, Winoker JS, Romero J, Goodman-Meza D, Gevorgyan R *et al.* Accuracy of transcranial Doppler for the diagnosis of intracardiac right-to-left shunt: a bivariate meta-analysis of prospective studies. *JACC Cardiovasc Imaging* 2014;**7**:236–50.
289. Mojadidi MK, Winoker JS, Roberts SC, Msaouel P, Gevorgyan R, Zolty R *et al.* Two-dimensional echocardiography using second harmonic imaging for the diagnosis of intracardiac right-to-left shunt: a meta-analysis of prospective studies. *Int J Cardiovasc Imaging* 2014;**30**:911–23.
290. Mojadidi MK, Bogush N, Caceres JD, Msaouel P, Tobis JM. Diagnostic accuracy of transesophageal echocardiogram for the detection of patent foramen ovale: a meta-analysis. *Echocardiography* 2014;**31**:752–8.
291. Schneider B, Zienkiewicz T, Jansen V, Hofmann T, Noltenius H, Meinertz T *et al.* Diagnosis of patent foramen ovale by transesophageal echocardiography and correlation with autopsy findings. *Am J Cardiol* 1996;**77**:1202–9.
292. Daniels C, Weytjens C, Cosyns B, Schoors D, Desutter J, Paelinck B *et al.* Second harmonic transthoracic echocardiography: the new reference screening method for the detection of patent foramen ovale. *Eur J Echocardiogr* 2004;**5**:449–52.
293. Clarke NR, Timperley J, Kelion AD, Banning AP. Transthoracic echocardiography using second harmonic imaging with Valsalva manoeuvre for the detection of right to left shunts. *Eur J Echocardiogr* 2004;**5**:176–81.
294. Caputi L, Carriero MR, Falcone C, Parati E, Piotti P, Materazzo C *et al.* Transcranial Doppler and transesophageal echocardiography: comparison of both techniques and prospective clinical relevance of transcranial Doppler in patent foramen ovale detection. *J Stroke Cerebrovasc Dis* 2009;**18**:343–8.
295. Gonzalez-Alujas T, Evangelista A, Santamarina E *et al.* Diagnosis and quantification of patent foramen ovale. Which is the reference technique? Simultaneous study with transcranial Doppler, transthoracic and transesophageal echocardiography. *Rev Esp Cardiol* 2011;**64**:133–9.
296. Lechat PH, Mas JL, Lascault G, Loron PH, Theard M, Klimczac M *et al.* Prevalence of patent foramen ovale in patients with stroke. *N Engl J Med* 1988;**318**:1148–52.
297. de Belder MA, Tourikis L, Leech G, Camm AJ. Risk of patent foramen ovale for thromboembolic events in all age groups. *Am J Cardiol* 1992;**69**:1316–20.
298. Di Tullio M, Sacco RL, Gopal A, Mohr JP, Homma S. Patent foramen ovale as a risk factor for cryptogenic stroke. *Ann Intern Med* 1992;**117**:461–5.
299. Jones EF, Calafiore P, Donnan GA, Tonkin AM. Evidence that patent foramen ovale is not a risk factor for cerebral ischemia in the elderly. *Am J Cardiol* 1994;**74**:596–9.
300. Di Tullio MR, Sacco RL, Sciacca RR, Jin Z, Homma S. Patent foramen ovale and the risk of ischemic stroke in a multiethnic population. *J Am Coll Cardiol* 2007;**49**:797–802.
301. Petty GW, Khandheria BK, Meissner I, Whisnant JP, Rocca WA, Christianson TJH *et al.* Population-based study of the relationship between patent foramen ovale and cerebrovascular ischemic events. *Mayo Clin Proc* 2006;**81**:602–8.
302. Handke M, Harloff A, Olschewski M, Hetzel A, Geibel A. Patent foramen ovale and cryptogenic stroke in older patients. *N Engl J Med* 2007;**357**:2262–8.
303. Meissner I, Khandheria BK, Heit JA, Petty GW, Sheps SG, Schwartz GL *et al.* Patent foramen ovale: innocent or guilty? Evidence from a prospective population-based study. *J Am Coll Cardiol* 2006;**47**:440–5.
304. Homma S, Sacco RL, Di Tullio MR, Sciacca RR, Mohr JP. Effect of medical treatment in stroke patients with patent foramen ovale: patent foramen ovale in Cryptogenic Stroke Study. *Circulation* 2002;**105**:2625–31.
305. Messé SR, Silverman IE, Kizer JR, Homma S, Zahn C, Gronseth G *et al.* Practice parameter: recurrent stroke with patent foramen ovale and atrial septal aneurysm: report of the Quality Standards Subcommittee of the American Academy of Neurology. *Neurology* 2004;**62**:1042–50.
306. Bridges ND, Hellenbrand W, Latson L, Filiano J, Newburger JW, Lock JE *et al.* Transcatheter closure of patent foramen ovale after presumed paradoxical embolism. *Circulation* 1992;**86**:1902–8.
307. Serena J, Marti-Fàbregas J, Santamarina E, Rodríguez JJ, Perez-Ayuso M, Masjuan J *et al.* Recurrent stroke and massive right-to-left shunt: results from the prospective Spanish multicenter (CODICIA) study. *Stroke* 2008;**39**:3131–6.
308. Katsanos AH, Spence JD, Bogiatzi C, Parissis J, Giannopoulos S, Frogoudaki A *et al.* Recurrent stroke and patent foramen ovale: a systematic review and meta-analysis. *Stroke* 2014;**45**:3352–9.
309. Mas J-L, Derumeaux G, Guillon B, Massardier E, Hosseini H, Mechtouff L *et al.* Patent foramen ovale closure or anticoagulation vs. antiplatelets after stroke. *N Engl J Med* 2017;**377**:1011–21.
310. Saver JL, Carroll JD, Thaler DE, Smalling RW, MacDonald LA, Marks DS *et al.* Long-term outcomes of patent foramen ovale closure or medical therapy after stroke. *N Engl J Med* 2017;**377**:1022–32.
311. Søndergaard L, Kasner SE, Rhodes JF, Andersen G, Iversen HK, Nielsen-Kudsk JE *et al.* Patent foramen ovale closure or antiplatelet therapy for cryptogenic stroke. *N Engl J Med* 2017;**377**:1033–42.
312. Pristipino C, Sievert H, D'Ascenzo F, Louis Mas J, Meier B, Scacciatella P *et al.* European position paper on the management of patients with patent foramen ovale. General approach and left circulation thromboembolism. *Eur Heart J* 2019;**40**:3182–95.
313. Homma S, Sacco RL, Di Tullio MR, Sciacca RR, Mohr JP. Atrial anatomy in noncardioembolic stroke patients: effect of medical therapy. *J Am Coll Cardiol* 2003;**42**:1066–72.
314. Bayar N, Arslan Ş, Çağırcı G, Erkal Z, Üreyen ÇM, Çay S *et al.* Assessment of morphology of patent foramen ovale with transesophageal echocardiography in symptomatic and asymptomatic patients. *J Stroke Cerebrovasc Dis* 2015;**24**:1282–6.
315. DeSimone CV, Friedman PA, Noheria A, Patel NA, DeSimone DC, Bdeir S *et al.* Stroke or transient ischemic attack in patients with transvenous pacemaker or defibrillator and echocardiographically detected patent foramen ovale. *Circulation* 2013;**128**:1433–41.

Downloaded from https://academic.oup.com/ehjcimaging/article/22/6/e24/6168685 by Universiteit Leiden / LUMC user on 22 June 2022

316. Chartier L, Béra JME, Delomez M, Asseman P, Beregi J-P, Bauchart J-J *et al.* Free-floating thrombi in the right heart: diagnosis, management, and prognostic indexes in 38 consecutive patients. *Circulation* 1999;**99**:2779–83.
317. Fauveau E, Cohen A, Bonnet N, Gacem K, Lardoux H. Surgical or medical treatment for thrombus straddling the patent foramen ovale: impending paradoxical embolism? Report of four clinical cases and literature review. *Arch Cardiovasc Dis* 2008;**101**:637–44.
318. Tugcu A, Okajima K, Jin Z, Rundek T, Homma S, Sacco RL *et al.* Septal pouch in the left atrium and risk of ischemic stroke. *JACC Cardiovasc Imaging* 2010;**3**: 1276–83.
319. Gurudevan SV, Shah H, Tolstrup K, Siegel R, Krishnan SC. Septal thrombus in the left atrium: is the left atrial septal pouch the culprit? *JACC Cardiovasc Imaging* 2010;**3**:1284–6.
320. Krishnan SC, Salazar M. Septal pouch in the left atrium: a new anatomical entity with potential for embolic complications. *JACC Cardiovasc Interv* 2010;**3**:98–104.
321. Hołda MK, Krawczyk-Ożóg A, Koziej M, Sorysz D, Hołda J, Dudek D *et al.* Left-sided atrial septal pouch is a risk factor for cryptogenic stroke. *J Am Soc Echocardiogr* 2018;**31**:771–6.
322. Kuwaki H, Takeuchi M, Kaku K, Haruki N, Yoshitani H, Tamura M *et al.* Thrombus attached to the left atrial septal pouch assessed on 3-dimensional transesophageal echocardiography. *Circ J* 2011;**75**:2280–1.
323. Elsokkari I, Reyneke E, William M. Left atrial septal pouch causing an ischaemic stroke in association with aortic coarctation. *Eur J Echocardiogr* 2011;**12**:916.
324. Sun JP, Meng F, Yang XS, Lee AP, Chen M, Zhang BO *et al.* Prevalence of atrial septal pouch and risk of ischemic stroke. *Int J Cardiol* 2016;**214**:37–40.
325. Strachinaru M, Catez E, Jousten I, Pavel O, Janssen C, Morissens M *et al.* The left atrial septal pouch as a possible risk factor for stroke. *Echocardiography* 2016;**33**:1016–1023.
326. Strachinaru M, Castro-Rodriguez J, Verbeet T, Gazagnes M-D. The left atrial septal pouch as a risk factor for stroke: a systematic review. *Arch Cardiovasc Dis* 2017;**110**:250–258.
327. Gilon D, Buonanno FS, Joffe MM, Leavitt M, Marshall JE, Kistler JP *et al.* Lack of evidence of an association between mitral-valve prolapse and stroke in young patients. *N Engl J Med* 1999;**341**:8–13.
328. Freed LA, Levy D, Levine RA, Larson MG, Evans JC, Fuller DL *et al.* Prevalence and clinical outcome of mitral-valve prolapse. *N Engl J Med* 1999;**341**:1–7.
329. Alpert MA, Carney RJ, Flaker GC, Sanfelippo JF, Webel RR, Kelly DL *et al.* Sensitivity and specificity of two-dimensional echocardiographic signs of mitral valve prolapse. *Am J Cardiol* 1984;**54**:792–796.
330. Zamorano J, Erbel R, Mackowski T, Alfonso F, Meyer J. Usefulness of transesophageal echocardiography for diagnosis of mitral valve prolapse. *Am J Cardiol* 1992;**69**:419–422.
331. Hirata K, Pulerwitz T, Sciacca R, Otsuka R, Oe Y, Fujikura K *et al.* Clinical utility of new real time three-dimensional transthoracic echocardiography in assessment of mitral valve prolapse. *Echocardiography* 2008;**25**:482–488.
332. Barnett HJM, Boughner DR, Taylor DW, Cooper PE, Kostuk WJ, Nichol PM *et al.* Further evidence relating mitral-valve prolapse to cerebral ischemic events. *N Engl J Med* 1980;**302**:139–144.
333. Barletta GA, Gagliardi R, Benvenuti L, Fantini F. Cerebral ischemic attacks as a complication of aortic and mitral valve prolapse. *Stroke* 1985;**16**:219–223.
334. Avierinos J-F, Brown RD, Foley DA, Nkomo V, Petty GW, Scott C *et al.* Cerebral ischemic events after diagnosis of mitral valve prolapse: a community-based study of incidence and predictive factors. *Stroke* 2003;**34**:1339–1344.
335. Salem DN, O'Gara PT, Madias C, Pauker SG. Valvular and structural heart disease: American College of Chest Physicians Evidence-Based Clinical Practice Guidelines (8th Edition). *Chest* 2008;**133**:593S–629S.
336. Mastroroberto P, Chello M, Zofrea S, Zucco D, Borrello G, Marchese AR. Combined mitral valve prolapse and atrial septal aneurysm. A cause for embolic events. *J Cardiovasc Surg (Torino)* 1994;**35**:507–509.
337. Fox CS, Vasan RS, Parise H, Levy D, O'Donnell CJ, D'Agostino RB *et al.* Mitral annular calcification predicts cardiovascular morbidity and mortality: the Framingham Heart Study. *Circulation* 2003;**107**:1492–1496.
338. Savage DD, Garrison RJ, Castelli WP, McNamara PM, Anderson SJ, Kannel WB *et al.* Prevalence of submitral (anular) calcium and its correlates in a general population-based sample (the Framingham Study). *Am J Cardiol* 1983;**51**: 1375–1378.
339. Benjamin EJ, Plehn JF, D'Agostino RB, Belanger AJ, Comai K, Fuller DL *et al.* Mitral annular calcification and the risk of stroke in an elderly cohort. *N Engl J Med* 1992;**327**:374–379.
340. Boon A, Lodder J, Cheriex E, Kessels F. Mitral annulus calcification and carotid atherosclerotic disease. *Stroke* 1999;**30**:693–693.
341. Massera D, Trivieri MG, Andrews JPM, Sartori S, Abgral R, Chapman AR *et al.* Disease activity in mitral annular calcification. *Circ Cardiovasc Imaging* 2019;**12**: e008513.
342. Higgins J, Mayo J, Skarsgard P. Cardiac computed tomography facilitates operative planning in patients with mitral calcification. *Ann Thorac Surg* 2013;**95**:e9–11.
343. Agmon Y, Khandheria BK, Meissner I, Sicks JR, O'Fallon WM, Wiebers DO *et al.* Aortic valve sclerosis and aortic atherosclerosis: different manifestations of the same disease? Insights from a population-based study. *J Am Coll Cardiol* 2001;**38**:827–834.
344. Brockmeier LB, Adolph RJ, Gustin BW, Holmes JC, Sacks JG. Calcium emboli to the retinal artery in calcific aortic stenosis. *Am Heart J* 1981;**101**:32–37.
345. Fox CS, Parise H, Vasan RS, Levy D, O'Donnell CJ, D'Agostino RB *et al.* Mitral annular calcification is a predictor for incident atrial fibrillation. *Atherosclerosis* 2004;**173**:291–294.
346. Clavel M-A, Pibarot P, Messika-Zeitoun D, Capoulade R, Malouf J, Aggarwal SR *et al.* Impact of aortic valve calcification, as measured by MDCT, on survival in patients with aortic stenosis: results of an international registry study. *J Am Coll Cardiol* 2014;**64**:1202–13.
347. Baumgartner H, Falk V, Bax JJ, De Bonis M, Hamm C, Holm PJ *et al.*; ESC Scientific Document Group. 2017 ESC/EACTS Guidelines for the management of valvular heart disease. *Eur Heart J* 2017;**38**:2739–2791.
348. Roldan CA, Shively BK, Crawford MH. Valve excrescences: prevalence, evolution and risk for cardioembolism. *J Am Coll Cardiol* 1997;**30**:1308–1314.
349. Roberts JK, Omarali I, Di Tullio MR, Sciacca RR, Sacco RL, Homma S *et al.* Valvular strands and cerebral ischemia. Effect of demographics and strand characteristics. *Stroke* 1997;**28**:2185–2188.
350. Cohen A, Tzourio C, Chauvel C, Bertrand B, Crassard I, Bernard Y *et al.* Mitral valve strands and the risk of ischemic stroke in elderly patients. The French Study of Aortic Plaques in Stroke (FAPS) Investigators. *Stroke* 1997;**28**: 1574–1578.
351. Roldan CA, Schevchuck O, Tolstrup K, Roldan PC, Macias L, Qualls CR *et al.* Lambl's excrescences: association with cerebrovascular disease and pathogenesis. *Cerebrovasc Dis* 2015;**40**:18–27.
352. Hart RG, Sharma M, Mundl H, Kasner SE, Bangdiwala SI, Berkowitz SD *et al.* Rivaroxaban for stroke prevention after embolic stroke of undetermined source. *N Engl J Med* 2018;**378**:2191–2201.
353. Diener H-C, Sacco RL, Easton JD, Granger CB, Bernstein RA, Uchiyama S *et al.* Dabigatran for prevention of stroke after embolic stroke of undetermined source. *N Engl J Med* 2019;**380**:1906–1917.

Downloaded from https://academic.oup.com/ehjcimaging/article/22/6/e24/6168685 by Universiteit Leiden / LUMC user on 22 June 2022