



Universiteit  
Leiden  
The Netherlands

## **Fusion cardiac resynchronization therapy in an left ventricular assist device patient from two devices and crossing leads: a case report**

Egorova, A.D.; Erven, L. van; Beerers, S.L.M.A.; Tops, L.F.

### **Citation**

Egorova, A. D., Erven, L. van, Beerers, S. L. M. A., & Tops, L. F. (2021). Fusion cardiac resynchronization therapy in an left ventricular assist device patient from two devices and crossing leads: a case report. *European Heart Journal-Case Reports*, 5(9).  
doi:10.1093/ehjcr/ytab335

Version: Publisher's Version

License: [Creative Commons CC BY-NC 4.0 license](https://creativecommons.org/licenses/by-nc/4.0/)

Downloaded from: <https://hdl.handle.net/1887/3279744>

**Note:** To cite this publication please use the final published version (if applicable).

# Fusion cardiac resynchronization therapy in an left ventricular assist device patient from two devices and crossing leads: a case report

Anastasia D. Egorova \*, Lieselot van Erven, Saskia L.M.A. Beeres , and Laurens F. Tops 

Department of Cardiology, Leiden Heart-Lung Center, Leiden University Medical Center, Albinusdreef 2, 2333 ZA Leiden, the Netherlands

Received 11 February 2021; first decision 26 April 2021; accepted 5 August 2021; online publish-ahead-of-print 17 August 2021

## Background

Cardiac implanted electronic devices (CIED) have significantly improved the survival and quality of life in heart failure patients. Although implantable cardioverter-defibrillators (ICD) and cardiac resynchronization therapy (CRT) have a major role in patients with moderate to severe heart failure symptoms, the role of these devices in patients with a left ventricular assist device (LVAD) is not yet well defined. The burden of CIED-related procedures in patients with an LVAD is high. The price of lead malfunctions and pocket complications requires creative approaches to tackle CIED-related issues in this patient population.

## Case summary

Here, we describe the clinical course of a 67-year-old ventricular pacing dependent LVAD patient with an ICD indication based on recurrent monomorphic ventricular tachycardias and a CRT indication due to previous deterioration of (right-sided) heart failure in the absence of biventricular pacing. We were confronted with impending right ventricular lead failure and bilateral venous access problems due to chronic subclavian vein occlusion in a patient with a total of five transvenous leads, therapeutic anticoagulation, and pronounced thoracic collaterals. We sought for a creative solution to be able to deliver effective biventricular fusion pacing with the existing leads from two contralateral pulse generators resulting in biventricular fusion pacing. This provided the solution to deliver effective CRT.

## Discussion

This case illustrates the complexity of care and CIED-related decision-making in pacing dependent LVAD patients, in particularly those with an ICD and CRT indication.

## Keywords

Cardiac implantable electronic devices • Cardiac resynchronization therapy • Implantable cardioverter-defibrillator • Heart failure • Left ventricular assist device • Complications • Venous occlusion • Case report

## Learning points

- (1) The burden of cardiac implanted electronic devices (CIED)-related complications is high in left ventricular assist device (LVAD) patients. A multi-disciplinary approach is required to deliver adequate CIED-related decision making in pacing-dependent LVAD patients, in particular, those with a concomitant implantable cardioverter-defibrillator and cardiac resynchronization therapy indication.
- (2) Creative approaches such as fusion pacing from multiple CIED pulse generators can result in effective biventricular pacing.

\* Corresponding author. Tel: +31 71 526 2020; Email: [a.egorova@lumc.nl](mailto:a.egorova@lumc.nl)

Handling Editor: Reuben Casado Arroyo

Peer-reviewers: Josip Andelo Borovac; Alessia Gambaro; Nuria Farre; Lilit Baghdasaryan; Flemming Javier Olsen; Sherif Mohammad Abd ElSamad

Compliance Editor: Alexander Tindale

Supplementary Material Editor: Katharine Kott

© The Author(s) 2021. Published by Oxford University Press on behalf of the European Society of Cardiology.

This is an Open Access article distributed under the terms of the Creative Commons Attribution-NonCommercial License (<http://creativecommons.org/licenses/by-nc/4.0/>), which permits non-commercial re-use, distribution, and reproduction in any medium, provided the original work is properly cited. For commercial re-use, please contact [journals.permissions@oup.com](mailto:journals.permissions@oup.com)

## Introduction

Cardiac implantable electronic devices (CIEDs) have improved the survival and quality of life of heart failure patients over the past decades. This can be attributed to the anti-tachycardia therapies of implantable cardioverter-defibrillators (ICDs) and cardiac resynchronization therapy (CRT) targeting electromechanical dyssynchrony, reversing pathological left ventricular remodelling, and improving functional capacity.<sup>1,2</sup> The role of CIEDs in patients with advanced heart failure eligible for a left ventricular assist device (LVAD) has not been well characterized and these patients have lower CRT response rates and survival benefit than would be expected based on the landmark trials.<sup>1,3,4</sup> However, many of the patients undergoing an LVAD implantation already have a CIED and the burden of CIED-related complications in this patient group is particularly high.<sup>4</sup> Given the price of lead malfunctions and complicated course of pocket hematomas and infections, creative approaches may be required to tackle CIED-related issues in LVAD patients. Here, we describe the clinical course of a ventricular pacing dependent patient with advanced heart failure, who underwent an LVAD implantation and retained the indication for an ICD and for CRT during follow-up. We were confronted with impending right ventricular (RV) lead failure and bilateral venous access problems.

## Timeline

1995	Cardiac sarcoidosis
2005	DDD-implantable cardioverter-defibrillator (ICD) implantation (left pectoral, primary prevention)
2015	Cardiac resynchronization therapy-defibrillator (CRT-D) implantation (right pectoral, occluded left-sided subclavian system, chronic pacing indication) ICD therapy for recurrent ventricular tachycardias (VTs), paroxysmal atrial fibrillation, and flutters
2016, January–February	Not eligible for heart transplantation due to pulmonary hypertension left ventricular assist device (LVAD), implantation as destination therapy, tricuspid valve annuloplasty, left atrial appendage amputation, and cryoablation
2016, June–August	<i>Staphylococcus aureus</i> bacteraemia (chronic suppression therapy)
2018	Recurrent VTs, two re-ablations Intracranial haemorrhage
2018–19 May	Six consecutive episodes of LVAD pump thrombosis (thrombolysis) Not eligible for pump exchange Impending right ventricle lead failure and elective replacement indication CRT-D
2019 June	7th episode of LVAD pump thrombosis Fusion CRT-D from two pulse generators

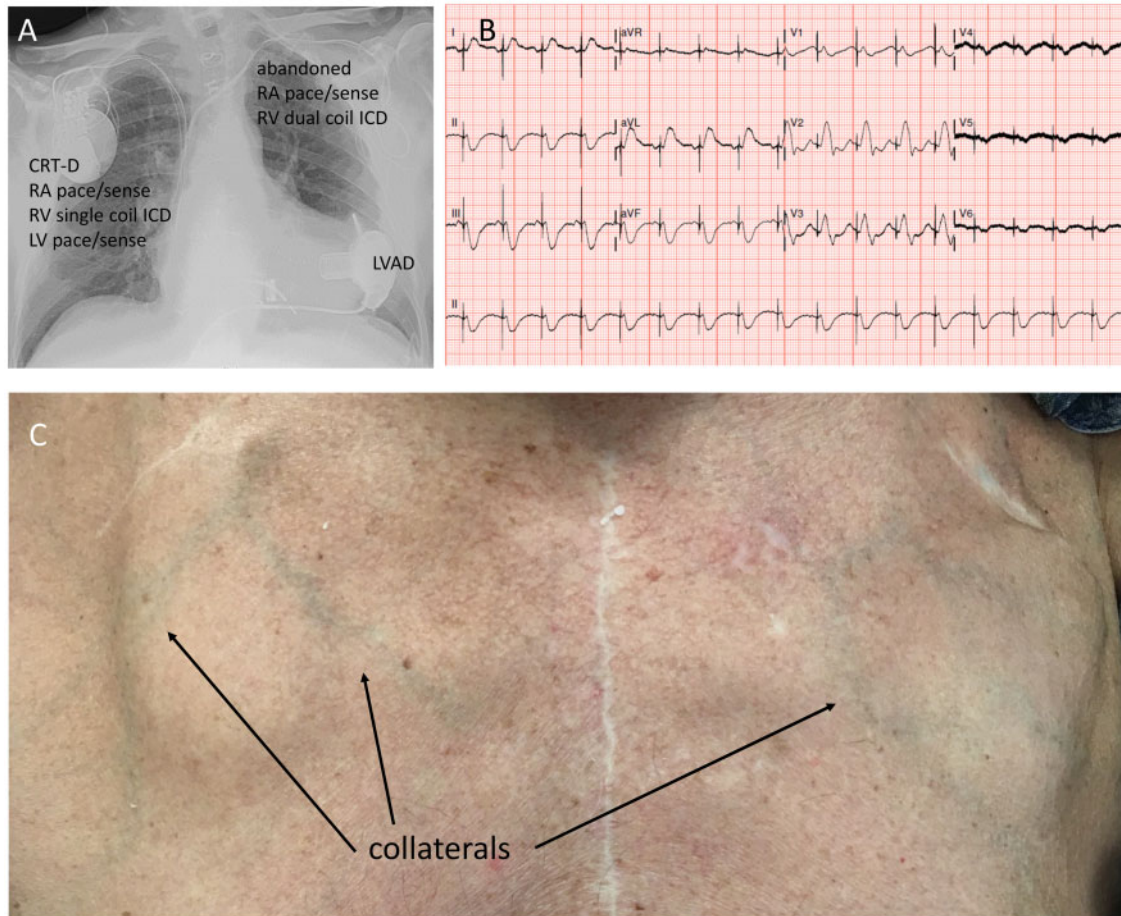
## Case presentation

A 67-year-old man with advanced heart failure due to cardiac sarcoidosis was referred to our centre. A two-chamber primary prevention ICD was implanted in the left pectoral position in 2005 in the referring hospital. In the following years, the patient developed a chronic pacing indication and an attempt to upgrade to a CRT-D system was not successful due to a venous occlusion of the left subclavian vein in 2015. The leads were capped and a new CRT-D system was implanted through the right cephalic and subclavian veins. The patient received ICD therapy for recurrent ventricular tachycardias (VTs) in 2015–16 and developed progressive heart failure [New York Heart Association (NYHA) III] despite optimal medical therapy and adequate CRT. He was deemed ineligible for a heart transplantation due to irreversible pulmonary hypertension.

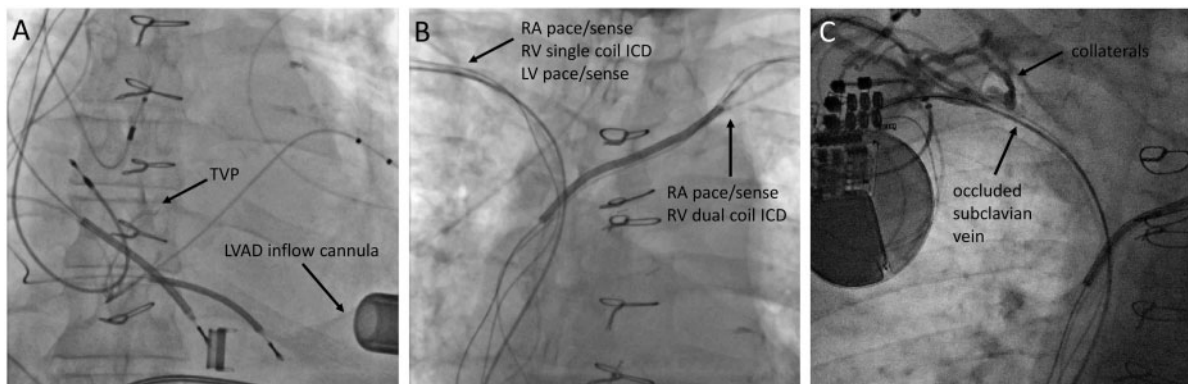
In 2016, an LVAD (HeartWare, Medtronic) as destination therapy was implanted in our tertiary referral centre and concomitant restrictive tricuspid valve annuloplasty, left atrial appendage amputation and VT cryoablation was performed. The initial recovery was uncomplicated and the patient's functional class improved to NYHA II, despite frequent episodes of VTs for which he received adequate ICD therapy and underwent two partially successful radio-frequency VT re-ablations. In 2016, he experienced a *Staphylococcus aureus* bacteraemia and chronic antibiotic suppressive therapy (flucloxacillin) was initiated. In 2018–19, the patient had an intracranial haemorrhage under therapeutic anticoagulation and seven episodes of pump thrombosis, all treated conservatively with thrombolysis. An LVAD pump exchange was considered to be of too high risk given the frailty and comorbidity of the patient.

In 2019, the patient was scheduled to undergo an elective pulse generator replacement of the CRT-D device due to low battery voltage and implantation of a new RV shock lead due to impending lead failure with high capture thresholds (4V/1.5 ms) and gradually decreasing impedance (<300 Ω). The pulse generator exchange was planned under an international normalized ratio (INR) of 2.5–3.5 and clopidogrel as any discontinuation of the anticoagulation would put the patient at risk of a recurrent pump thrombosis. The patient was fully pacing dependent and had no escape rhythm >30 beats/min. He required CRT as the previous trial of RV only pacing after LVAD implantation resulted in congestion and RV failure. [Figure 1](#) shows a chest X-ray of the patient and the implanted leads and hardware and an electrocardiogram (ECG) before the procedure. Note a total of five transvenous leads (a right atrial pacing, RV single-coil shock and a quadripolar left ventricular pacing lead through the right brachiocephalic vein and an abandoned right atrial pacing and a RV dual coil shock lead through the left brachiocephalic vein). Extensive thoracic collaterals were noted at the inspection ([Figure 1C](#)). Contrast venography revealed an occlusion of the right subclavian vein with an extensive collateral system ([Figure 2](#)).

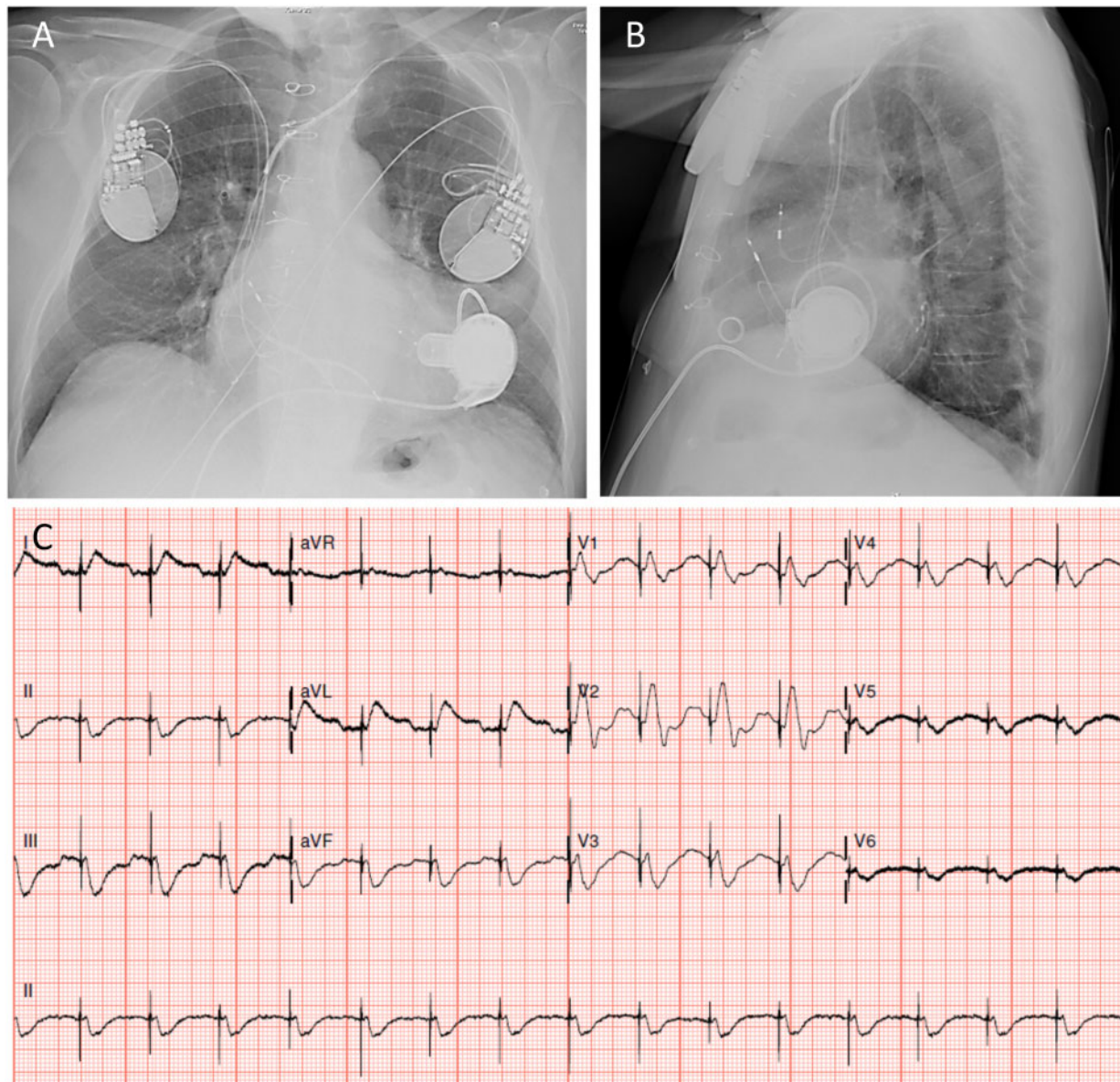
Considering the necessity for therapeutic anticoagulation and the pronounced venous collaterals, the risk of subcutaneous tunnelling of the left ventricular lead to the left-sided pocket was deemed too high. The team was reluctant to attempt a right-sided venoplasty of the subclavian system. Therefore, an alternative technical solution was sought. A new CRT-D pulse generator was implanted on the left side with a functional right atrial pacing and RV ICD lead (from 2005).



**Figure 1** (A) Postero-anterior chest X-ray image of the patient showing the abandoned/capped off dual chamber implantable cardioverter-defibrillator leads implanted from the left-sided transvenous access in 2005; a cardiac resynchronization therapy-defibrillator system implanted from the right-sided transvenous access in 2015; the left ventricular assist device in the left ventricular apex implanted in 2016. (B) Twelve-lead electrocardiogram with biventricular pacing from the right-sided cardiac resynchronization therapy-defibrillator system. (C) A photograph of the extensive thoracic collaterals.



**Figure 2** (A, B) Fluoroscopy images obtained during the pre-procedural evaluation in the catheterization laboratory illustrating the lead crowding of the superior venous system (five leads in the vena cava superior). (C) Contrast venography showing an occlusion of the right subclavian vein with an extensive collateral system, making it inaccessible for a simple new lead implantation.



**Figure 3** (A) Postero-anterior and (B) lateral chest X-ray imaging showing the final lead connections (functional right atrium and right ventricular pacing and tachytherapy from the left-sided pulse generator and functional left ventricular trigger pacing from the right-sided pulse generator). (C) Twelve-lead electrocardiogram with the resulting biventricular fusion pacing from the two pulse generators. Appreciate the morphological similarity to the initial biventricular capture electrocardiogram in [Figure 1B](#).

This would ensure stable RV pacing and tachytherapy options in case of recurrent VT. The LV port was capped to keep the option of LV lead tunnelling open for the future. The right-sided pulse generator was reprogrammed to LV trigger pacing/functionally LV only pacing mode. The right atrial and ventricular outputs were programmed to sub-threshold values to ensure no capture and extend battery life. The patient hereby had fusion CRT delivered from the two devices. The lead and device connections and the ECG are shown in [Figure 3](#). The QRS-duration and configuration were comparable to the initial conventional biventricular capture ([Figure 1B](#)) and patient had no heart failure-related hospitalizations during the follow-up so far (March 2021).

In addition to regular outpatient clinic visits at our hospital, the patient and his next of kin were referred to a dedicated team for advanced care planning given the frailty and limited therapeutic options.

## Discussion

The need for CIED upgrades and revisions has increased significantly over the past years.<sup>5</sup> These procedures are technically more challenging than primo implants and carry a higher risk of complications. Venous patency poses a notorious obstacle to successful lead

revision procedures. In our patient, venous occlusion of the left subclavian vein in the presence of two device leads in 2015 was the reason to convert to a right-sided CRT implantation procedure in the referring centre. We were confronted with a right-sided venous occlusion in 2019, impeding an RV shock lead revision. The incidence of a venous stenosis of more than 75% is reported in up to 27% of patients with chronically implanted leads.<sup>6</sup> The patient described here had a complete occlusion of the bilateral venous access with an extensive collateral network supporting the venous effluence. Direct vein access (i.e. venotomy) or puncture more medial to the stenosis site was not feasible. Although percutaneous venoplasty with or without lead extraction can have good clinical success rates in selected patients, the patient described here was deemed to be a high-risk candidate for this given the general frailty, therapeutic anticoagulation during the procedure, extensive thoracic collaterals, and bilateral venous occlusion.

The number of chronically implanted leads is an independent predictor of venous obstruction and the cumulative lead diameter is significantly higher in patients with venous stenosis.<sup>6,7</sup> Antiplatelet and anticoagulant therapy are reported to play a preventive role in the early stages of the pathogenesis of venous stenosis.<sup>8</sup> Local periprocedural vessel wall trauma, inflammation, and patient-specific factors are also suspected to play a role in the development of venous stenosis. Identification of patients at risk of CIED-related venous obstruction is of importance as it may not only influence procedural planning and the anticoagulation regimen but may also alter the strategy of procedures altogether.

Left ventricular assist devices significantly improve the survival and quality of life in end-stage heart failure patients. Despite the technological advances, however, these patients are frequently faced with complications including pump thrombosis, VTs, driveline infections, neurologic events, and CIED-related issues.<sup>9</sup> The patient described here has unfortunately experienced all of the above-mentioned complications and is illustrative of the frailty of this patient group requiring well-orchestrated multidisciplinary care and timely involvement of an advanced care planning team. The effectiveness of ICDs in continuous-flow LVAD patients is still a matter of controversy.<sup>10</sup> Our patient did, however, have a vital indication for ventricular pacing and for tachytherapy. Data suggest that although many VTs will initially be well tolerated by LVAD patients, these tachyarrhythmias eventually lead to worsening of heart failure and haemodynamic collapse, probably in part due to the compromised RV function and reduced preload.<sup>10</sup> This was also the reason to pursue a relatively aggressive approach with regard to VTs in our patient [various ablation procedures and patient-tailored anti-tachycardia pacing (ATP) programming] with moderately reduced RV function. The effectiveness of CRT in LVAD patients is a matter of ongoing investigations. A recent multi-centre analysis demonstrated that turning CRT off after LVAD implantation does not have an adverse impact on survival, heart transplantation or arrhythmia, and tachytherapy burden.<sup>2,11</sup> Although this would support the decision to inactivate CRT in LVAD patients (with the additional benefit of extending CIED battery life and delaying pulse generator exchange procedures), large prospective randomized studies are required to confirm this. Previous clinical deterioration with right-sided heart failure during a CRT off period in our patient was the reason to actively pursue CRT. Although the

mechanism behind this is not entirely elucidated, the reduced systolic and diastolic RV function in the setting of infiltrative sarcoid disease and the previously established irreversible pulmonary hypertension may have contributed to the maladaptive RV myocardial remodelling in response to chronic pressure overload. These mechanisms have been previously described to contribute to intra- and interventricular dyssynchrony in the context of pulmonary hypertension and congenital heart disease.<sup>12,13</sup> It is therefore plausible that alternations in the electromechanical coupling during the CRT off period reduce RV efficiency and result in right-sided congestion. Given the detrimental consequences of RV failure, the impact of CRT on RV function deserves further investigation.

Although CRT from two separate devices involving RV endocardial and (hybrid) left ventricular epicardial pacing has been reported previously and is of increasing interest in light of the new leadless pacing modalities,<sup>14</sup> the current case is, to the best of our knowledge, the first one involving entirely transvenous pacing from two separate CIEDs in an LVAD patient. During follow-up, one should be aware of the need for meticulous programming and fine-tuning to obtain the optimal biventricular pacing configuration—modern device algorithms try to automatically optimize the output and biventricular (multipolar) pacing configuration based on individual device programming and intracardiac electrocardiograms; and avoid the potential proarrhythmic effects of epicardial LV trigger pacing.<sup>15</sup>

This case illustrates the complexity of care and CIED-related decision-making in pacing-dependent LVAD patients, in particular, those with a concomitant ICD and CRT indication. We were confronted with impending RV lead failure and bilateral venous access problems in a patient with therapeutic anticoagulation and pronounced thoracic collaterals and managed to achieve a good solution to deliver effective biventricular pacing from two separate CIEDs.

## Lead author biography



Anastasia Dmitrievna Egorova (1987) is a cardiologist at the Leiden University Medical Center, the Netherlands. She obtained her Medical degree cum laude at the Leiden University and defended her PhD thesis on endothelial response to fluid hemodynamics in 2012. She completed her cardiology training in 2018, followed by fellowships in cardiac implantable electronic devices and adult congenital heart disease. Her academic interest focusses on cardiac device therapy in heart failure patients and optimization of heart failure treatment in adults with congenital heart disease.

## Supplementary material

Supplementary material is available at *European Heart Journal—Case Reports* online.

**Slide sets:** A fully edited slide set detailing these cases and suitable for local presentation is available online as [Supplementary data](#).

## Consent

All procedures performed involving the human participant were in accordance with the ethical standards of the institutional and/or national research committee and with the 1964 Helsinki declaration and its later amendments or comparable ethical standards. The authors confirm that written consent for submission and publication of this case report including images and associated text has been obtained from the patient in line with COPE guidelines.

**Conflict of interest:** L.F.T. receives speaker fees and is a member of the Medtronic advisory board. The other authors declare that they have no competing interests.

**Funding:** The general funding of the Department of Cardiology of the Leiden University Medical Center.

## References

1. Brignole M, Auricchio A, Baron-Esquivias G, Bordachar P, Boriani G, Breithardt O, et al.; Document Reviewers. 2013 ESC Guidelines on cardiac pacing and cardiac resynchronization therapy. *Eur Heart J* 2013;**34**:2281–2329.
2. Choi AJ, Thomas SS, Singh JP. Cardiac resynchronization therapy and implantable cardioverter defibrillator therapy in advanced heart failure. *Heart Fail Clin* 2016;**12**:423–436.
3. Ponikowski P, Voors AA, Anker SD, Bueno H, Cleland JGF, Coats AJA et al. 2016 ESC Guidelines for the diagnosis and treatment of acute and chronic heart failure. *Eur Heart J* 2016;**37**:2129–2200.
4. Alvarez PA, Sperry BW, Pérez AL, Yaranov DM, Randhawa V, Luthman J et al. Implantable cardioverter defibrillators in patients with continuous flow left ventricular assist devices: utilization patterns, related procedures, and complications. *J Am Heart Assoc* 2019;**8**:e011813.
5. Valzania C, Torbica A, Tarricone R, Leyva F, Boriani G. Implant rates of cardiac implantable electrical devices in Europe: a systematic literature review. *Health Policy* 2016;**120**:1–15.
6. Morani G, Bolzan B, Valsecchi S, Morosato M, Ribichini FL. Chronic venous obstruction during cardiac device revision: incidence, predictors, and efficacy of percutaneous techniques to overcome the stenosis. *Heart Rhythm* 2020;**17**:258–264.
7. Abu-El-Hajja B, Bhavne PD, Campbell DN, Mazur A, Hodgson-Zingman DM, Cotarlan V et al. Venous stenosis after transvenous lead placement: a study of outcomes and risk factors in 212 consecutive patients. *J Am Heart Assoc* 2015;**4**:e001878.
8. van Rooden CJ, Molhoek SG, Rosendaal FR, Schaliij MJ, Meinders AE, Huisman MV. Incidence and risk factors of early venous thrombosis associated with permanent pacemaker leads. *J Cardiovasc Electrophysiol* 2004;**15**:1258–1262.
9. Rose EA, Gelijns AC, Moskowitz AJ, Heitjan DF, Stevenson LW, Dembitsky W, et al.; Randomized Evaluation of Mechanical Assistance for the Treatment of Congestive Heart Failure (REMATCH) Study Group. Long-term use of a left ventricular assist device for end-stage heart failure. *N Engl J Med* 2001;**345**:1435–1443.
10. Vakil K, Kazmirczak F, Sathnur N, Adabag S, Cantillon DJ, Kiehl EL et al. Implantable cardioverter-defibrillator use in patients with left ventricular assist devices. *JACC: Heart Fail* 2016;**4**:772–779.
11. Roukoz H, Bhan A, Ravichandran A, Ahmed MM, Bhat G, Cowger J et al. Continued versus suspended cardiac resynchronization therapy after left ventricular assist device implantation. *Sci Rep* 2020;**10**:2573.
12. Rasmussen JT, Thenappan T, Benditt DG, Weir EK, Pritzker MR. Is cardiac resynchronization therapy for right ventricular failure in pulmonary arterial hypertension of benefit? *Pulm Circ* 2014;**4**:552–559.
13. Janoušek J, Kovanda J, Ložek M, Tomek V, Gebauer R, Kubuš P et al. Cardiac resynchronization therapy for treatment of chronic subpulmonary right ventricular dysfunction in congenital heart disease. *Circ Arrhythm Electrophysiol* 2019;**12**:e007157.
14. Carabelli A, Jabeur M, Jacon P, Rinaldi CA, Leclercq C, Rovaris G et al. European experience with a first totally leadless cardiac resynchronization therapy pacemaker system. *Europace* 2020;**00**:1–8.
15. Shukla G, Chaudhry GM, Orlov M, Hoffmeister P, Haffajee C. Potential proarrhythmic effect of biventricular pacing: fact or myth? *Heart Rhythm* 2005;**2**:951–956.