



Universiteit
Leiden
The Netherlands

The role of myocardial innervation imaging in different clinical scenarios: an expert document of the European Association of Cardiovascular Imaging and Cardiovascular Committee of the European Association of Nuclear Medicine

Gimelli, A.; Liga, R.; Agostini, D.; Bengel, F.M.; Ernst, S.; Hyafil, F.; ... ; Slart, R.H.J.A.

Citation

Gimelli, A., Liga, R., Agostini, D., Bengel, F. M., Ernst, S., Hyafil, F., ... Slart, R. H. J. A. (2021). The role of myocardial innervation imaging in different clinical scenarios: an expert document of the European Association of Cardiovascular Imaging and Cardiovascular Committee of the European Association of Nuclear Medicine. *European Heart Journal - Cardiovascular Imaging*, 22(5), 480-490. doi:10.1093/ehjci/jeab007

Version: Publisher's Version
License: [Creative Commons CC BY 4.0 license](https://creativecommons.org/licenses/by/4.0/)
Downloaded from: <https://hdl.handle.net/1887/3279783>

Note: To cite this publication please use the final published version (if applicable).

The role of myocardial innervation imaging in different clinical scenarios: an expert document of the European Association of Cardiovascular Imaging and Cardiovascular Committee of the European Association of Nuclear Medicine

Alessia Gimelli ^{1*}, Riccardo Liga², Denis Agostini³, Frank M. Bengel⁴, Sabine Ernst⁵, Fabien Hyafil⁶, Antti Saraste^{7,8}, Arthur J.H.A. Scholte⁹, Hein J. Verberne¹⁰, Derk O. Verschure^{10,11}, and Riemer H.J.A. Slart^{12,13}

¹Department of Imaging, Fondazione Toscana/CNR Gabriele Monasterio1, via Moruzzi n.1, Pisa 56124, Italy; ²Cardiac-Thoracic-Vascular Department, Università di Pisa, Pisa, Italy; ³Department of Nuclear Medicine, University Hospital of Normandy, CHU Cote de Nacre, Caen, France; ⁴Department of Nuclear Medicine, Hannover Medical School (MHH), Hannover, Germany; ⁵Royal Brompton and Harefield NHS Foundation Trust, National Heart and Lung Institute, Imperial College, London, UK; ⁶Department of Nuclear Medicine, European Hospital Georges-Pompidou, DMU IMAGINA, Assistance Publique—Hôpitaux de Paris, University of Paris, Paris, France; ⁷Turku PET Centre, University of Turku, Turku, Finland; ⁸Heart Center, Turku University Hospital, Turku, Finland; ⁹Department of Cardiology, Leiden University Medical Center, Leiden, The Netherlands; ¹⁰Department of Radiology and Nuclear Medicine, Amsterdam UMC, University of Amsterdam, Amsterdam, The Netherlands; ¹¹Department of Cardiology, Zaans Medical Center, Zaandam, the Netherlands; ¹²Department of Nuclear Medicine and Molecular Imaging, Medical Imaging Centre, University Medical Center Groningen, Groningen, The Netherlands; and ¹³Faculty of Science and Technology, Biomedical Photonic Imaging, University of Twente, Enschede, The Netherlands

Received 14 December 2020; editorial decision 21 December 2020; accepted 8 January 2021; online publish-ahead-of-print 1 February 2021

Cardiac sympathetic activity plays a key role in supporting cardiac function in both health and disease conditions, and nuclear cardiac imaging has always represented the only way for the non-invasive evaluation of the functional integrity of cardiac sympathetic terminals, mainly through the use of radiopharmaceuticals that are analogues of norepinephrine and, in particular, with the use of ¹²³I-MIBG imaging. This technique demonstrates the presence of cardiac sympathetic dysfunction in different cardiac pathologies, linking the severity of sympathetic nervous system impairment to adverse patient's prognosis. This article will outline the state-of-the-art of cardiac ¹²³I-MIBG imaging and define the value and clinical applications in the different fields of cardiovascular diseases.

Keywords MIBG • cardiac innervation • molecular imaging • nuclear cardiology

Introduction

Cardiac sympathetic activity plays a key role in supporting cardiac function in both health and disease conditions, a mechanism operated by released norepinephrine (NE),^{1–3} the physiological neurotransmitter binding alpha- and beta-adrenoceptors and undergoing reuptake by presynaptic (uptake 1) and extra-neuronal transporters (uptake 2).⁴ While these mechanisms ensure an optimal NE turnover at a normal neuronal stimulation, they cannot compensate NE overflow at high and prolonged stimulation frequencies. This will lead to diffuse functional denervation due to post-synaptic receptor down-

regulation and enhanced NE spillover by pre-synaptic re-uptake mechanisms in patients with chronic heart failure (CHF) leads.^{3–6} On the other hand, in patients with ischaemic heart disease (IHD) discrete regions of anatomical myocardial denervation are present, typically exceeding the extent of myocardial fibrosis and representing ideal substrates for cardiac arrhythmogenicity.^{5,7} However, the evaluation of cardiac sympathetic activity has been classically precluded by the regionalization of sympathetic activity, but results obtained in other body regions are difficult to extrapolate to the heart.

Nuclear cardiac imaging has always represented the only way for the non-invasive evaluation of the functional integrity of cardiac

* Corresponding author. Tel: +39 050 3152153. E-mail: gimelli@ftgm.it

Published on behalf of the European Society of Cardiology. All rights reserved. © The Author(s) 2021. For permissions, please email: journals.permissions@oup.com.

sympathetic terminals, mainly through the use of radiopharmaceuticals that are analogues of NE.^{6–8} In this context, ¹²³I-mIBG (metaiodobenzilguanidine) imaging, a non-metabolized NE analogue undergoing reuptake by the uptake-1 mechanism, represents the reference for the non-invasive evaluation of cardiac adrenergic nervous function. This technique demonstrates the presence of cardiac sympathetic dysfunction in different cardiac pathologies, linking the severity of sympathetic nervous system (SNS) impairment to adverse patient's prognosis. While planar acquisitions have been classically used to evaluate global cardiac ¹²³I-mIBG uptake, the current imaging protocol should also include single-photon emission computed tomography (SPECT) imaging that is able to evaluate the regional distribution of the radiotracer. More recently, the introduction of dedicated cardiac cameras, equipped with solid-state Cadmium–Zinc–Telluride (CZT) detectors has offered the advantage of repeated studies due to its low radiation exposure, while evaluating at the same time the perfusion of the heart.^{9–11}

This article will outline the state-of-the-art of cardiac ¹²³I-mIBG imaging and define the value and clinical applications in the different fields of cardiovascular diseases.

General concepts of nuclear imaging in the assessment of cardiac sympathetic activity

Radionuclide imaging interrogates the handling of NE in presynaptic sympathetic nerve terminals. Positron emission tomography (PET) uses short-lived tracers, such as ¹¹C-carbon (¹¹C)-hydroxyephedrine, ¹¹C-epinephrine, S-[¹¹C]CGP 12177, or more recently longer living variants, such as ¹⁸F-fluoride (¹⁸F)-LMI1195 or ¹⁸F-hydroxyphenethylguanidine.^{12,13} It should be noted that the tracers differ in their affinity to the NE transporter, vesicular storage and metabolism, and in their flow-dependency, leading to distinct differences in their kinetics and specificity. Yet, PET can be used to quantify the integrity of presynaptic nerve terminals in CHF by absolute means. The most commonly used tracer, however, is the gamma-emitting agent ¹²³I-mIBG, which enables semi-quantitative planar scintigraphy and SPECT over a longer period of time.¹ Using ¹²³I-mIBG, several parameters can be derived from planar images (Figure): i.e. the early and late heart-to-mediastinum (H/M) ratio, derived 15 min and 4 h post-injection, both considered to be markers of NE uptake. Of note, the ¹²³I-mIBG washout (WO) may then be obtained as a potential marker of NE turnover/sympathetic tone (see formula).¹

$$WO = \left\{ \frac{(\text{early H/M} - \text{late H/M})}{(\text{early H/M})} \right\} \times 100$$

Despite the large number of studies on ¹²³I-mIBG assessed cardiac sympathetic activity in CHF, the lack of standardization in both acquisition and semi-quantitative analysis between different institutions may be a significant factor limiting wide scale clinical implementation. Hence, technical considerations are important for standardized imaging with ¹²³I-mIBG. This particularly includes the choice of collimator. In addition to the main photopeak of 159 keV, ¹²³I emits also high-energy photons. These high-energy photons may penetrate

collimator septa, degrade image quality and affect calculation of the H/M ratio. The use of a medium energy (ME) collimator limits septum penetration and is preferable to low energy (LE) collimators.² However, ME collimators are not widely available and therefore LE collimators are most often used. Collimator choice is one of the most important factors causing variation in myocardial ¹²³I-mIBG-derived parameters.² A part of this variation can be overcome by assessing a phantom based conversion coefficient for each gamma camera-collimator combination.^{3,4} This allows for conversion of various conditions to standardized H/M ratios, and thereby, cross-calibration enables a better comparison between institutions. Such an approach may be of critical importance for identifying appropriate thresholds to differentiate high- and low-risk CHF patients for future applications.

Pros and cons of myocardial innervation imaging: impact of recent technological innovations

Despite solid prognostic evidence in favour of their implementation in daily clinical routine, planar measures of cardiac sympathetic activity have remained somehow neglected, possibly due to the intrinsic rudimentariness of the technique and the ability to provide only a global evaluation of myocardial innervation.^{5–7}

As a matter of fact, regional differences in myocardial ¹²³I-mIBG uptake may characterize specific cardiac pathologies, such as IHD and left ventricular hypertrophy.^{7,14}

Increasing evidence is available on the possibility to compare, by the use of SPECT, cardiac sympathetic activity, and myocardial perfusion on a regional basis,⁸ deriving indexes of myocardial innervation that might be superior to the standard H/M ratio in predicting morbidity.¹⁵

Accordingly, SPECT-derived measures of cardiac innervation correlate with major indicators of myocardial (hypo)perfusion, contractile (dys)function, and volume overload, possibly predicting adverse cardiac events.^{9,16,17} Consequently, the tomographic evaluation of cardiac sympathetic activity might be of additional value for clinical stratification in selected subgroups of high-risk patients.

Nevertheless, the combined assessment of myocardial innervation and perfusion has never gained wide clinical application, possibly due to the high radiation exposure and long acquisition time of this integrated imaging protocol. The use of new solid-state cardiac cameras with CZT detectors, characterized by a higher photon sensitivity and spatial resolution than standard cameras, could overcome these limitations and allow the assessment of myocardial innervation and perfusion in a single imaging session and with a limited radiation exposure, possibly guiding clinical decision-making.^{9,10}

Recent data^{9,10} indicated that CZT-derived measures of myocardial innervation heterogeneity (i.e. ¹²³I-mIBG defect score and innervation/perfusion mismatch score) could better identify, if compared with the classical planar indexes, patients at higher cardiovascular risk.

Myocardial innervation imaging in patients with CHF

Patients with CHF present a condition of cardiac sympathetic hyperactivity coupled with impaired post-synaptic beta-adrenoceptor desensitization, impaired NE re-uptake and NE spillover.¹⁸ In the past decade, cardiac ¹²³I-mIBG scintigraphy has been shown to be useful in prognostication of patients with CHF. Initially, numerous single-centre and retrospective studies have demonstrated the prognostic value of cardiac ¹²³I-mIBG imaging in CHF patients.^{19–23} The ADMIRE-HF study was the first large multicentre, prospective study in CHF ($n = 961$), using a predefined late H/M ratio cut-off value of 1.6.⁵ The late H/M ratio was, independent of brain natriuretic peptide (BNP) and left ventricular ejection fraction (LVEF), a predictor of the composite endpoint and of each individual component of the composite endpoint: progression of CHF, lethal ventricular tachycardia (VT), and sudden cardiac death (SCD). A late H/M ratio >1.6 was associated with incidence of 1% cardiac death per year. In contrast, the annual cardiac mortality in those patients with a late H/M ratio <1.2 was almost 10 times higher (9.6%).

Those results were reproduced by pooled analyses of independent studies, confirming the long-term prognostic value of ¹²³I-mIBG imaging in patients with CHF.^{24,25} However, a number of limitations have prevented the implementation of planar ¹²³I-mIBG scintigraphy in daily clinical routine. First of all as a main reason, no real cut-off of H/M ratio actually exists (i.e. <1.6).²⁶ In fact, the H/M ratio shows a continuous association with patients risk, and the different cut-off values proposed so far have only shown a modest accuracy in risk discriminating.²⁵ Interestingly, in contrast to the linear correlation between late H/M ratio and prognosis, a 'bell shaped' curve was seen for the late H/M ratio in relation to appropriated implantable cardioverter defibrillator (ICD) therapy. Patients with intermediate late H/M ratio (range 1.40–2.10) were more likely to have appropriate ICD therapy compared to patients with low and high late H/M ratios. These findings are in line with previous findings of Agostini *et al.*¹⁹ showing arrhythmia in CHF patients with an intermediate late H/M ratio (1.46–2.17) only. This suggests that the presumption of a monotonic increase of arrhythmia with decreasing late H/M ratio may not be correct and suggests that CHF patients with severe increased impaired sympathetic activity probably die due to terminal HF rather than arrhythmia. Incorporating ¹²³I-mIBG scintigraphy into the assessment of CHF patients eligible for ICD implantation may result in a reduction in ICD implantation of 21%.²⁷ According to these suggestions, the number needed to screen to prevent one ICD implantation would be 5. Screening with ¹²³I-mIBG scintigraphy could reduce the costs per patient by 5500 and 13 431 US dollars over 2 and 10 years, respectively, with <1 day and 2 weeks of life lost over 2 and over 2 and 10 years, respectively.²⁷ However, to date no prospective evaluation of the prognostic impact of innervation parameters on clinical decision-making and patient management has been provided, with the recent ADMIRE-ICD (NCT02656329) study interrupted prematurely because of low recruitment rate.

SPECT ¹²³I-mIBG imaging has been proposed as a possible solution to some of these limitations, providing information on the regional heterogeneity of cardiac sympathetic activity that could improve the diagnostic abilities of planar measures in identifying patients at risk of

adverse cardiac events. In fact, it has been demonstrated that a higher ¹²³I-mIBG defect score on SPECT imaging is associated with a significantly worse prognosis, particularly regarding arrhythmic events.¹⁵

Accordingly, based on current evidence, ¹²³I-mIBG scintigraphy might be of value in the risk stratification of patients with CHF, possibly contributing in identifying patients at increased risk that could benefit from more aggressive therapeutic/invasive approaches,²⁸ particularly in the case of patients currently excluded from prophylactic ICD implantation (i.e. borderline EF impairment).²⁹ Moreover, the presence of a relatively preserved cardiac sympathetic tone might help to postpone ICD implantation in patients with otherwise borderline indication (i.e. non-ischaemic dilated cardiomyopathy with LVEF 25–35%), in whom the benefit of ICD is disputed.³⁰

Specific interest has been given to the evaluation of cardiac sympathetic activity in patients eligible for cardiac resynchronization therapy (CRT), showing that the degree of sympathetic impairment predicted the magnitude of LV reverse remodelling and that the presence of sympathetic reserve (increase of late H/M ratio short after CRT implantation) could individuate positive responders to CRT.^{31–33} However, whether multiparametric nuclear cardiac imaging, comprising the evaluation of perfusion, dyssynchrony (phase analysis), and innervation, may help to individuate responders to CRT is still a matter of investigation^{10,34} (Figure 1).

An additional field of interest could be the assessment of cardiac sympathetic reinnervation following heart transplantation. In fact, while cardiac denervation occurs immediately after a heart transplantation, due to axonal Wallerian degeneration of post-ganglionic sympathetic nerve fibres, the extent of reinnervation is variable and inhomogeneous.³⁵ Specifically, reinnervation usually appears first in the left ventricle followed by the sinus node region.^{36–38} Cardiac denervation explains the abnormally elevated heart rate of heart transplant recipients, as well as the compromised exercise capacity and altered blood pressure control. On the other hand, an incoherent reinnervation may increase the arrhythmic risk.³⁵ Nuclear cardiac imaging has been instrumental for clarifying the pathophysiology of cardiac denervation/reinnervation after transplantation and may be possibly used for advanced risk-stratification of such patients.³⁹

Myocardial innervation imaging as predictor of ventricular arrhythmias

The evaluation of the integrity of cardiac sympathetic with ¹²³I-mIBG scintigraphy has been long proposed as a valuable method for the stratification of patients at risk for ventricular arrhythmias (VA).⁵ However, despite the value of planar ¹²³I-mIBG assessed myocardial innervation for prediction of adverse outcome in CHF, no dedicated randomized study has shown that outcome in ¹²³I-mIBG-defined categories of patients at risk can be improved by a preventive intervention, greatly in limiting the implementation of this technique in daily clinical routine. Also, following technological improvements of nuclear cardiac imaging, the interest in ¹²³I-mIBG scintigraphy has been recently increasing, with reports showing its possible use in innovative clinical scenarios.⁴⁰ Specifically, the application of SPECT technology to ¹²³I-mIBG imaging has been instrumental in demonstrating the

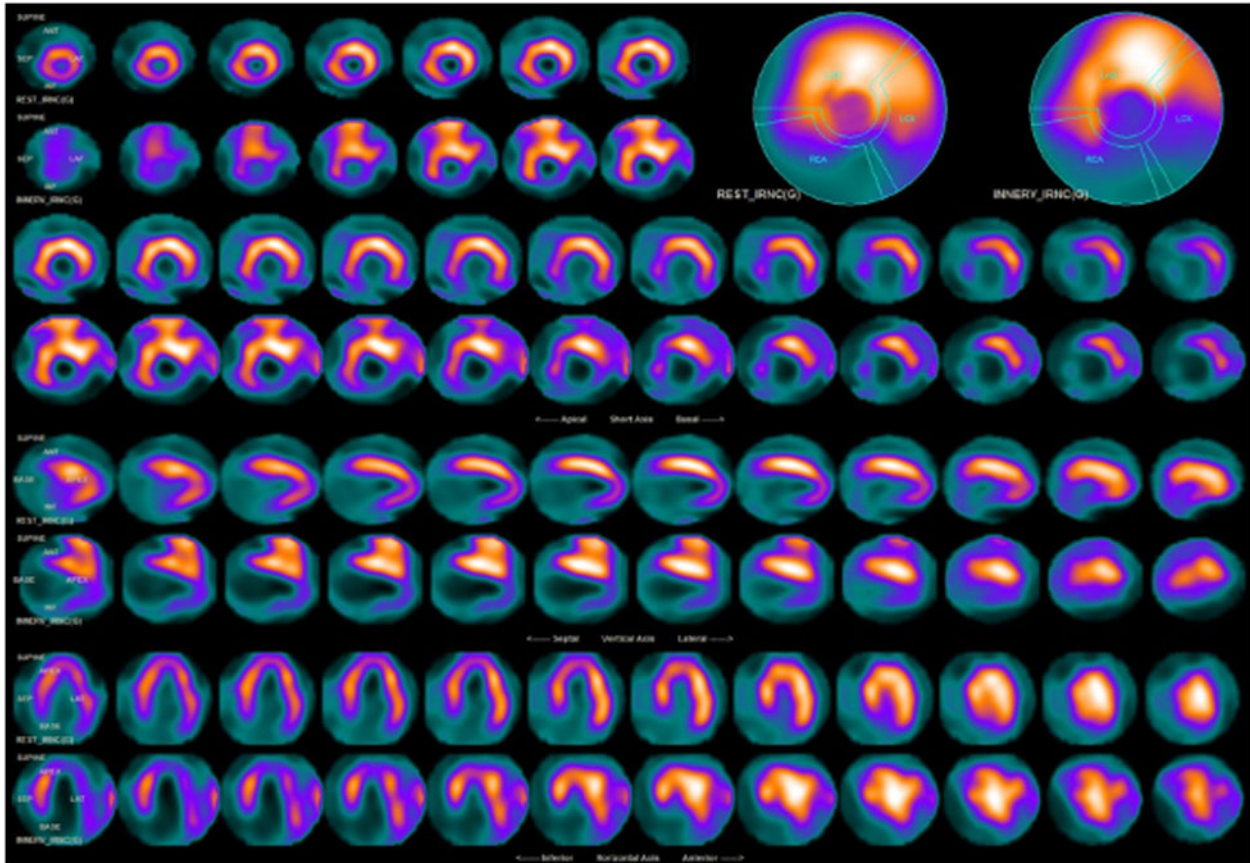


Figure 1 A patient with history of diabetes and recent onset of rest dyspnoea. Normal coronary anatomy. One episode of VT treated with DC shock. The scintigraphic perfusion images show a homogenous perfusion. The innervation images (lower rows) reveal an extensive area of denervation involving the basal to mid-ventricular lateral and the basal inferior walls with relevant innervation/perfusion mismatch. At EP study located the sites of origin of the arrhythmia at the level of the infero-lateral LV walls.

causal link between increased regional ^{123}I -mIBG heterogeneity and arrhythmic risk. It is now well accepted that patients with the highest arrhythmic risk, which could possibly benefit from an ICD implantation, are not necessarily those with a homogeneously depressed cardiac sympathetic activity (i.e. severely reduced H/M ratio), but rather patients showing a regionally jeopardized ^{123}I -mIBG uptake that may ultimately predispose to cardiac electrical instability.⁴¹ In addition to that, consistent evidence suggests that denervated regions having relatively preserved perfusion (the so-called innervation/perfusion mismatch phenomenon) can represent a specific marker of arrhythmic susceptibility, particularly in patients with IHD.¹⁶ Accordingly, the presence of areas of viable but denervated myocardium located nearby scarred regions has been identified as a likely source of VA and, as a consequence, an ideal site for targeted therapeutic intervention, such as endocavitary ablations⁴² (Figure 2).

Also, on PET, the presence of innervation/perfusion mismatch resulted the major predictor of VA, typically co-localizing at the level of the electrically unstable border-zone of a myocardial scar.⁴³ Current data may support myocardial innervation imaging for the stratification of patients at risk for VA, showing a causal role of innervation/perfusion mismatch in cardiac arrhythmogenicity. In this

setting, after initial validation hybrid PET/MR evaluation, combining the high-quality molecular imaging of PET with the insuperable tissue characterization of MR,^{44,45} has been shown to further increase the clinical value of molecular cardiac imaging, allowing a better characterization of patients at risk for VA^{46,47} possibly candidate to invasive procedures (i.e. cardiac ablations).

Myocardial innervation imaging in patients with atrial fibrillation

Atrial fibrillation (AF) occurs when structural and/or electrophysiological abnormalities alter atrial tissue to promote abnormal impulse formation and/or propagation. A focal source in the pulmonary veins (PVs) can trigger AF, and for this reason, pulmonary vein isolation (PVI) represents the cornerstone technique for treating patients with AF resistant to standard pharmacological therapies.⁴⁸ However, the success rate of the first AF ablation remains only $\approx 60\%$ at 1 year.⁴⁹

More recently, interest has turned to the role of left atrium (LA) innervation in the modulation of AF substrate. As a matter of fact, experimental and clinical studies have shown that the intrinsic cardiac

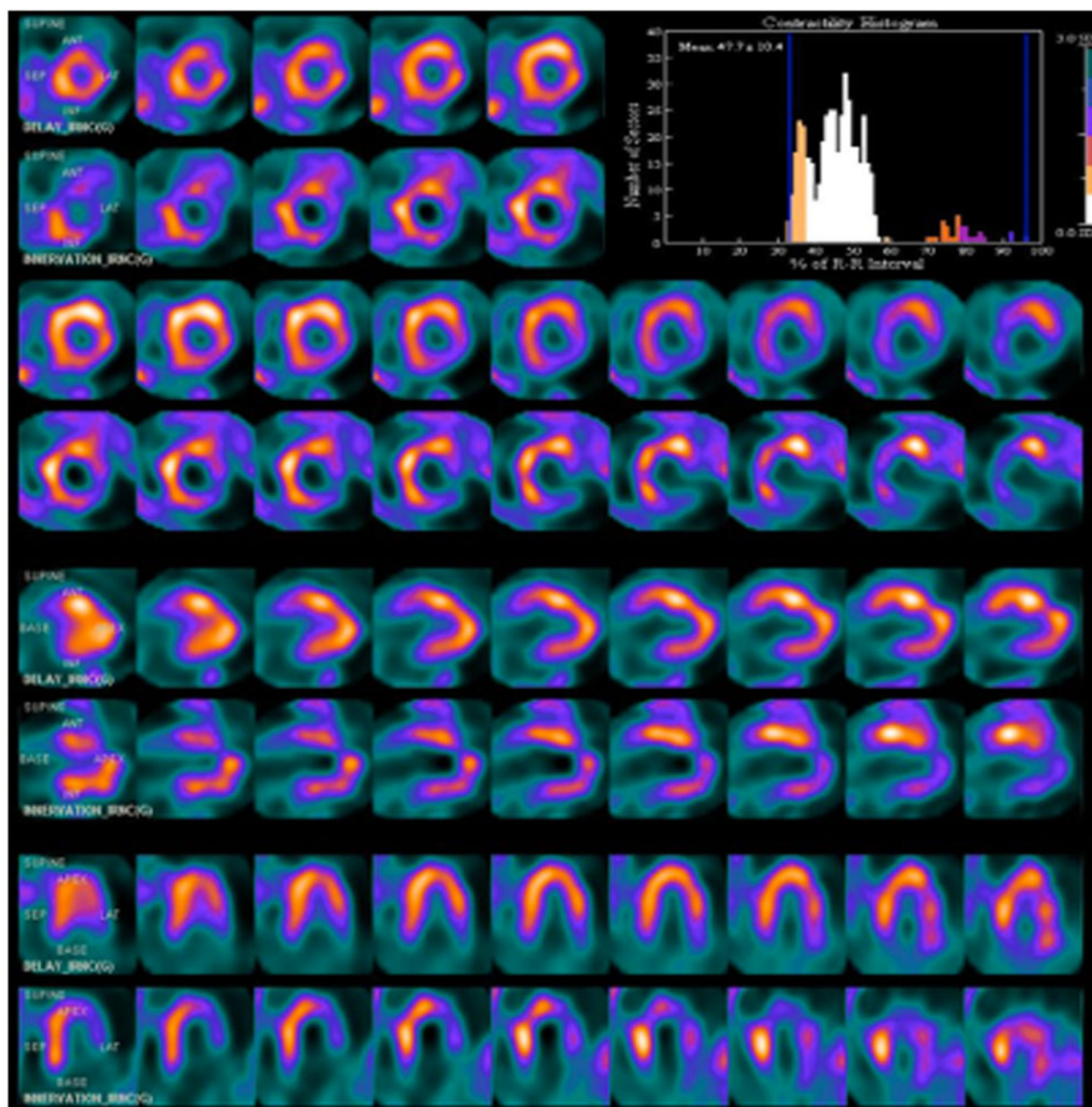


Figure 2 A patient with ischaemic heart disease and a previous myocardial infarction involving the circumflex coronary artery. ^{99m}Tc -Tetrofosmine perfusion images (upper rows) show a mainly inferior-to-inferolateral myocardial scar. ^{123}I -MIBG images (lower rows) show an evident area of sympathetic denervation at the level of the necrotic myocardium (innervation/perfusion match) and another ample region of impaired sympathetic tone at the level of the anterior, anteroseptal-to-apical LV segments despite a preserved perfusion (innervation/perfusion mismatch). Phase analysis demonstrates the presence of significant LVD with the regions of more delayed activation localized at the level of the mismatched myocardial regions. LVD: left ventricular dyssynchrony.

autonomic nervous system plays an important role in the initiation and maintenance of AF.

In fat pads on the atrial epicardium, large 'nests' of nerve cell bodies form the so-called ganglionated plexi (GP) containing both sympathetic and parasympathetic nerves. The GP can measure from 5 to 10 mm.⁵⁰ Catheter ablation of GPs as an add-on to PVI or even in isolation in patients with AF has been reported to improve clinical

outcomes by several investigators^{51,52} and the presence of residual GP activity after PVI might predict likelihood of recurrence.⁵³

The standard approach is to apply high-frequency stimulation (HFS) to the presumed GP areas to induce their typical vagal reaction (i.e. elicit AV block). As HFS has low specificity and sensitivity, is invasive and time consuming, better methods for localization of GPs are needed.

^{123}I -mIBG imaging has been performed to assess patients with AF, classically by imaging the indirect deleterious effect of AF on the firing activity of LV sympathetic nervous terminals, showing the ability to prognosticate patients with paroxysmal AF,^{54,55} predict the outcome of PVI,^{56,57} and evaluate the patterns of denervation/reinnervation after PVI.^{57,58} In patients with paroxysmal AF and without structural heart disease, cardiac autonomic nervous system abnormality defined as reduced late H/M ratio was a predictor of vascular events (i.e. myocardial infarction, stroke, or heart failure) during a mean follow-up of 4.5 years. Therefore, ^{123}I -mIBG imaging in this group of patients could support clinical risk stratification.⁵⁴ However, more data of multicentre studies are needed to implement this strategy for clinical purpose.

More recently, it has been proposed that the non-invasive evaluation of LA innervation might identify the GPs areas as discrete uptake areas (DUA) on the LA epicardial surface, potentially guiding catheter ablation procedures.

According to Stirrup *et al.*⁵⁹ reported an initial experience of left-atrial sympathetic innervation imaging with a solid-state SPECT. After feasibility assessment, they described methods for image acquisition and interpretation and thereafter present pilot data in patients with AF, with assessment of inter- and intraobserver variability, inter-study variability in sequential. Despite this pilot study comprised small numbers, it underlines that GP size and distribution are highly individual and a simple anatomical approach to GP ablation may not achieve complete results. The use of an individual GP localization by the use of might allow safer and more time-efficient GP ablation.

Myocardial innervation imaging in patients with amyloidosis

Cardiac amyloidosis (CA) is a form of restrictive cardiomyopathy commonly resulting from deposition of misfolded immunoglobulin light chain (AL) or transthyretin (ATTR) protein. ATTR has gained increasing attention in recent years and can be divided into a hereditary type (ATTRv) and a wild-type (ATTRwt). CA is an underestimated cause of heart failure and potential risk on arrhythmia, due to amyloid infiltration of the nerve conduction system and the myocardial tissue,^{60,61} most commonly in ATTR CA, particularly ATTRv.^{62,63} The prognosis in this progressive disease is poor, probably due to the development of arrhythmias. While AL CA patients less commonly manifest autonomic dysfunction, it may develop as a complication of AL amyloidosis treatment.⁶⁴

Early detection of myocardial innervation disturbances has become of major clinical interest, because its occurrence and severity limit the choice of treatment. ^{123}I -mIBG plays an important role in evaluation of myocardial innervation in CA.^{63,65–67} However, ^{123}I -mIBG scintigraphy is not able to discriminate between CA subtypes nor differentiate CA from other forms of cardiomyopathy.^{65,68} In TTR mutation carriers, cardiac sympathetic denervation evidenced by decreased ^{123}I -mIBG uptake is detected earlier than amyloid burden evidenced by bone scintigraphy.⁶⁹ These results raise the possibility of a diagnostic role for ^{123}I -mIBG scintigraphy at an early stage of cardiac involvement in TTR-mutated carriers, in addition to its well-established prognostic value.

An overview of the imaging acquisition parameters and reporting for ^{123}I -mIBG is available in recently published expert consensus document.⁷⁰ The potential role of PET for myocardial innervation in amyloidosis has not yet been identified. Prospective studies evaluating the diagnostic and prognostic value of ^{123}I -mIBG assessed myocardial innervation in CA should be undertaken. Current treatments are targeted at reducing the production of or stabilization of the precursor protein of amyloid deposits, thereby aim to stop or slow down further accumulation of amyloid.^{71,72} Molecular imaging, such as ^{123}I -mIBG, may be able to visualize regression of CA infiltration of the nerve conduction system under these new treatment regimens, but data are lacking at this moment.

Myocardial innervation imaging in diabetic patients

Diabetes mellitus (DM) is a worldwide healthcare problem that is largely the result of overweight and physical inactivity.⁷³ Long-term complications include microvascular- and macrovascular disease and also cardiac autonomic neuropathy (CAN), a complication that is proportional to the duration and magnitude of hyperglycaemia.⁷⁴ CAN results from injury of the autonomic nerve fibres innervating the heart and blood vessels, causing abnormalities in heart rate control and vascular dynamics. Major clinical manifestations of CAN are orthostatic hypotension, impaired heart rate control, and silent myocardial ischaemia, ultimately leading to increased arrhythmia susceptibility.^{75,76} CAN has been classically demonstrated non-invasively by assessing heart rate variability (HRV) and baroreflex sensitivity.⁷⁵ In particular, HRV can be tested simply by recording a Holter ECG registry, evaluating the sympatco-vagal balance at the sinoatrial level, and by measuring the difference in systolic blood pressure between supine and upright position. Despite its prognostic value, the evaluation of CAN by means of HRV is limited by its indirect nature and the fact that it evaluates predominantly parasympathetic function, mostly disregarding sympathetic contribution.⁷⁶

Since the 90's of the former century cardiac ^{123}I -mIBG scintigraphy has been used to assess diabetic CAN, generally diagnosing the presence of a reduced H/M ratio. It has been suggested that ^{123}I -mIBG scintigraphy may be more sensitive than HRV for the detection of CAN in patients with DM^{77,78} and a better predictor for major cardiac events, likely showing more precocious alterations of the autonomic tone.

As in the case of HRV, also the H/M ratio provides only a measure of global myocardial (dys)innervation, that may be 'paradoxically' preserved even in the presence of regional abnormalities. In this setting, SPECT imaging is able to look at regional innervation, demonstrating that the inferior wall and apex of the LV are more prone to show impaired ^{123}I -mIBG uptake,⁷⁶ a condition that might revert after sustained glycaemic control.⁷⁹

Accordingly, since ^{123}I -mIBG scintigraphy appears the most accurate technique for the detection of CAN, it might be used for the early risk stratification of DM patients, guiding intensive risk factors management even before the onset of micro- and macrovascular complications, and evaluating the effect of novel anti-diabetic drugs, such as SGLT2 inhibitors.⁸⁰

Myocardial innervation imaging in Takotsubo

Takotsubo cardiomyopathy (TTC) is a unique cardiac syndrome characterized by the presence of transient left ventricular wall motion abnormalities without a culprit coronary lesion.^{81–83} In all cases, a massive catecholamine release is observed.⁸⁴ The precise pathophysiological mechanism of TTC has not been completely elucidated. Emotional, psychological, or physical stress is frequently, but not always present prior to the onset of TTC and may thus trigger the onset of disease.⁸⁵ It has been suggested that epinephrine-mediated myocardial stunning in TTC is related to multiple coronary artery spasm and impaired coronary microcirculation. Furthermore, epinephrine seems to be an important factor in the pathophysiology. In the acute phase of TTC plasma epinephrine levels are more elevated compared with the acute phase of a myocardial infarction.⁸⁴

Recently, nuclear studies were conducted at different phases during the TTC time course.^{86,87} In the acute and subacute phases of TTC, similar defects of ¹²³I-mIBG and ¹⁸F-Fluorodeoxyglucose uptake, despite only slightly reduced perfusion, have been demonstrated in the dyskinetic LV segments. Subsequently, rapid normalization of myocardial perfusion, and delayed recovery of both LV glucose metabolism and sympathetic innervation, is observed. In a prospective study, late H/M ratio was compared in subacute and recovery phases of patients with TTC, showing a dysfunctional sympathetic activity in the early phase that resolved with recovery.⁸⁸ The observed decreased cardiac ¹²³I-mIBG uptake as expressed as H/M ratio could be due to inhibited ¹²³I-mIBG reuptake by high epinephrine levels in the synaptic cleft and/or down-regulation of the human NE transport. Moreover, in a study based on an animal model by Paur et al.⁸⁹ proposed the hypothesis that the apical ballooning in TTC is related to switching of epinephrine signalling. The data showed that there is an increasing gradient of from base to apex in rat and exposed to high levels of circulating epinephrine beta-2-receptors signalling switch from positively inotropic beta-1-mediated G_s stimulation (G_s) coupling to negative inotropic β₂-dependent G_i inhibition (G_i) coupling in the apex, resulting in apical ballooning.^{84,89} This hypothesis is based on the assumption that beta-2-receptors are more expressed in the apical region than the basal area, even if, it is unclear whether the human heart has a similar pattern of beta-2-receptors gradient.

Myocardial innervation imaging in neurodegenerative diseases

Increasing attention has been given recently on the use of myocardial innervation imaging in the clinical characterization and differential diagnosis of major neurodegenerative conditions. In particular, myocardial ¹²³I-mIBG uptake is reduced in patients with Lewy body diseases such as Parkinson disease (PD) and dementia with Lewy bodies,^{90,91} helping to differentiate these conditions to other types of parkinsonism.⁹² Specifically, in patients with PD, ¹²³I-mIBG scintigraphy may play a central role in the functional characterization of patients, since a relatively preserved ¹²³I-mIBG uptake identifies patients with a small motor burden and a reduced myocardial ¹²³I-

mIBG uptake is associated with a subsequent increased risk for the wearing-off phenomenon.⁹¹

Innovations in the field of myocardial innervation imaging: the role of quantification

PET imaging has sufficient spatiotemporal resolution and well-validated attenuation correction that allows for quantification of global and regional abnormalities in cardiac sympathetic activity based on tracer activity concentrations (Bq/mL) in the myocardium and blood pool in dynamic datasets.⁹³ Characterization of ¹¹C-*meta*-hydroxyephedrine ([¹¹C]-mHED) kinetics is usually performed with quantification of the tracer retention index that is defined as the ratio of the activity in the myocardium in the late uptake image of a 40- or 60-min dynamic scan to the integral of the image-derived arterial blood time-activity curve corrected for radiolabelled metabolites.⁹³ Quantification of volume of distribution in myocardial tissue based on compartment models can also be performed, but robustness of compartmental modelling may be impaired by rapid kinetics of [¹¹C]-mHED.^{1,2,93,94} In patients with stable heart failure and reduced ejection fraction, test-retest repeatability of global [¹¹C]-mHED retention index was 30% and regional defects (percentage of the left ventricle myocardium with reduced [¹¹C]-mHED uptake) 12%.^{2,94}

In addition to [¹¹C]-mHED, other ¹¹C labelled PET tracers, such as [¹¹C]-epinephrine and [¹¹C]-phenylephrine are available.^{3,93,95} These tracers show differences to [¹¹C]-mHED in their affinity to intraneuronal vesicular storage and metabolism. Combination of tracers and pharmacologic challenge may provide mechanistic information about differential effects of disease on anatomical nerve density as well as functional changes in cellular catecholamine uptake, storage, and metabolism.^{95,96}

A limitation of tracers labelled with ¹¹C is that due to short half-life an onsite cyclotron is required for production, which has limited their widespread use in the clinical setting. Tracers labelled with the positron emitter ¹⁸F have been introduced recently. [¹⁸F]-*meta*-fluorobenzylguanidine ([¹⁸F]-LMI1195) has similar kinetics to ¹²³I-mIBG and was well tolerated in a phase 1 clinical trial.^{97,98} Yet, approaches for absolute quantification for this tracer have not yet been widely established. Imaging properties of two other tracers, ¹⁸F-*meta*-hydroxyphenethylguanidine and 3-[¹⁸F]fluoro-*para*-hydroxyphenethylguanidine, have been studied in healthy volunteers.⁹⁹ Both tracers provided myocardial images of high quality and, owing to slower uptake kinetics when compared with ¹¹C labelled NE analogues, they offer the possibility for reproducible quantification of intraneuronal retention by Patlak kinetic analysis.

The introduction of cardiac dedicated SPECT devices equipped with cadmium-zinc-telluride (CZT) detectors has allowed evaluation of regional myocardial ¹²³I-mIBG kinetics in dynamic 3D datasets.^{100,101} Furthermore, improved spatial resolution of CZT SPECT scanners may facilitate evaluation of regional ¹²³I-mIBG uptake in combination with myocardial perfusion.^{9,16} Yet, this approach requires further validation and cross-comparison of clinical and prognostic value to the current standard of semi-quantitative heart-mediastinum ratios from planar scans.

Table 1 Impact of Planar and SPECT 123I-MIBG images in the evaluation of different clinical scenarios

Clinical scenarios for 123I-MIBG imaging	Planar imaging	SPECT
HF and severely depressed LV ejection fraction (<30–35%): advanced risk stratification	+++	+
Hypertrophic and infiltrative cardiomyopathies: evaluation of the arrhythmic risk	++	+/-
Ventricular arrhythmias candidate to trans-catheter ablation: identification of the ablation targets	-	++
Neurodegenerative disorders: differential diagnosis between Lewy body diseases (i.e. Parkinson disease) and parkinsonisms	++	-
Cardiac channelopathies: stratification of the arrhythmic risk	+	-
Atrial fibrillation before transcatheter ablation: identification of the autonomic ganglia	-	+
Heart transplantation: monitoring reinnervation	+/-	+/-
HF and borderline depressed LV ejection fraction (35–40%): indication for ICD implantation	+/-	-
Diabetes mellitus: long-term risk stratification	+/-	-

Future perspectives

The consistent improvement that has been taking place in nuclear cardiac imaging in the last years, comprising innovations in both software and hardware as well as the introduction of novel radiotracers, has allowed a gradual revival of cardiac sympathetic innervation imaging, with possible novel fields of applications.

Specifically, the combined evaluation of cardiac sympathetic innervation and perfusion in the same imaging session allows the assessment of cardiac innervation/perfusion mismatch, a parameter of increased prognostic relevance that has proven valuable for the characterization of patients with malignant ventricular arrhythmias candidate to ablation procedures.

In this setting, dedicated cardiac CZT cameras, with their increased sensitivity and resolution, have represented a quantum leap in conventional nuclear cardiology, allowing to couple a significant compression of imaging times together with the possibility to perform dynamic acquisitions, and hence the absolute quantification of data.

On the other hand, the recent introduction of 18-Fr-labelled PET radiotracers for sympathetic innervation imaging has the potential to increase the clinical application of this techniques, whose image quality and overall accuracy is still unsurpassed.

The possible field of application of cardiac sympathetic innervation imaging with either conventional nuclear imaging (planar scintigraphy and SPECT) or PET is reported in *Table 1*. As shown, while the use of cardiac innervation imaging has been classically limited to patient with HF and severely depressed EF, novel clinical scenarios have been recently added, comprising both the characterization of patients with malignant VAs, and the risk stratification of patients with innate or acquired cardiomyopathies, in whom the evaluation of cardiac sympathetic innervation may have both diagnostic (i.e. amyloidosis) and prognostic values.

Conclusions

The interpretation of myocardial innervation imaging requires the knowledge of different topics: neuronal biology, tracer kinetics, and the specific disease state. The possibility to help in understanding the pathophysiology of the different disease could add a new dimension

to myocardial innervation imaging and its appropriate use. Although cardiac ¹²³I-MIBG scintigraphy has been shown to be useful in prognostication of patients with CHF, limitations in tracer's availability and crude quantification methods has discouraged widespread clinical utility. However, the new CZT cameras for ¹²³I-MIBG on one hand and the new ¹⁸F-labelled PET tracers on the other, would take advantages of the improved spatial resolution, quantification capabilities, and potential wide distribution. Improving standardization and validation of myocardial innervation imaging is needed and will help to improve the quality of myocardial imaging and to facilitate appropriate use. Before this non-invasive imaging modality can become a part of clinical practice, larger prospective, and randomized control trials are required to confirm whether myocardial innervation imaging strategies can guide clinical management that can improve clinical outcomes, and constrain medical costs.

Liability statement

This Expert Document summarizes the views of the EACVI and the EANM. It reflects views for which the EACVI and the EANM cannot be held responsible. This position paper should be taken into context of good practice of nuclear medicine and do not substitute for national and international legal or regulatory provisions.

Conflict of interest: D.A.: Consultancy for Spectrum Dynamics. F.B.: Speaker honoraria by Pfizer, Alnylam, Abbott, and GE Healthcare, and Research grants by Siemens Healthineers. S.E.: Consultant for Biosense Webster, Stereotaxis Inc., and Spectrum Dynamics. Grants from Catheter Precision, Spectrum Dynamics, and Baylis Medical. A.S.: Speaker honoraria by Abbott, Amgen, Astra Zeneca, and Bayer and fees for consultancy from Amgen and Astra Zeneca. A.J.H.A.S.: Speaker honoraria by GE Healthcare.

Acknowledgements

This Expert Document was brought to the attention of the relevant EANM Committees and the National Societies of Nuclear Medicine, the EACVI, and the ESC CPG bodies. The comments and suggestions from the EANM Committees, EANM National Societies, the EACVI, and the ESC CPG bodies for their review and contribution are highly appreciated and have been considered for this Expert Document.

References

- Flotats A, Carrió I, Agostini D, Le Guludec D, Marcassa C, Schaffers M et al. Proposal for standardization of 123I-metaiodobenzylguanidine (MIBG) cardiac sympathetic imaging by the EANM Cardiovascular Committee and the European Council of Nuclear Cardiology. *Eur J Nucl Med Mol Imaging* 2010;**37**: 1802–12.
- Verberne HJ, Habraken JB, van Eck-Smit BL, Agostini D, Jacobson AF. Variations in ¹²³I-metaiodobenzylguanidine (MIBG) late heart mediastinal ratios in chronic heart failure: a need for standardisation and validation. *Eur J Nucl Med Mol Imaging* 2008;**35**:547–53.
- Nakajima K, Verschure DO, Okuda K, Verberne HJ. Standardization of (123)I-meta-iodobenzylguanidine myocardial sympathetic activity imaging: phantom calibration and clinical applications. *Clin Transl Imaging* 2017;**5**:255–63.
- Verschure DO, Poel E, Nakajima K, Okuda K, van Eck-Smit BLF, Somsen GA et al. A European myocardial (123)I-mIBG cross-calibration phantom study. *J Nucl Cardiol* 2018;**25**:1191–7.
- Jacobson AF, Senior R, Cerqueira MD, Wong ND, Thomas GS, Lopez VA et al. Myocardial iodine-123 meta-iodobenzylguanidine imaging and cardiac events in heart failure. Results of the prospective ADMIRE-HF (AdreView Myocardial Imaging for Risk Evaluation in Heart Failure) study. *J Am Coll Cardiol* 2010;**55**: 2212–21.
- Veltman CE, Boogers MJ, Meinardi JE, Al Younis I, Dibbets-Schneider P, Van der Wall EE et al. Reproducibility of planar (123)I-meta-iodobenzylguanidine (MIBG) myocardial scintigraphy in patients with heart failure. *Eur J Nucl Med Mol Imaging* 2012;**39**:1599–608.
- Marini C, Giorgetti A, Gimelli A, Kusch A, Sereni N, L'Abbate A et al. Extension of myocardial necrosis differently affects MIBG retention in heart failure caused by ischaemic heart disease or by dilated cardiomyopathy. *Eur J Nucl Med Mol Imaging* 2005;**32**:682–8.
- Bax JJ, Kraft O, Buxton AE, Fjeld JG, Paržek P, Agostini D et al. 123 I-mIBG scintigraphy to predict inducibility of ventricular arrhythmias on cardiac electrophysiology testing: a prospective multicenter pilot study. *Circ Cardiovasc Imaging* 2008;**1**:131–40.
- Gimelli A, Liga R, Giorgetti A, Genovesi D, Marzullo P. Assessment of myocardial adrenergic innervation with a solid-state dedicated cardiac cadmium-zinc-telluride camera: first clinical experience. *Eur Heart J Cardiovasc Imaging* 2014;**15**: 575–85.
- Gimelli A, Liga R, Genovesi D, Giorgetti A, Kusch A, Marzullo P. Association between left ventricular regional sympathetic denervation and mechanical dyssynchrony in phase analysis: a cardiac CZT study. *Eur J Nucl Med Mol Imaging* 2014;**41**:946–55.
- Gimelli A, Liga R, Avogliero F, Cocceani M, Marzullo P. Relationships between left ventricular sympathetic innervation and diastolic dysfunction: the role of myocardial innervation/perfusion mismatch. *J Nucl Cardiol* 2018;**25**:1101–9. doi: 10.1007/s12350-016-0753-3.
- Bravo PE, Lautamäki R, Carter D, Holt DP, Nekolla SG, Dannals RF et al. Mechanistic insights into sympathetic neuronal regeneration: multitracer molecular imaging of catecholamine handling after cardiac transplantation. *Circ Cardiovasc Imaging* 2015;**8**:e003507.
- Gaemperli O, Liga R, Spyrou N, Rosen SD, Foale R, Kooner JS et al. Myocardial beta-adrenoceptor down-regulation early after infarction is associated with long-term incidence of congestive heart failure. *Eur Heart J* 2010;**31**:1722–9.
- Liga R, Gimelli A, Marzullo P, Ambrosio G, Cameli M, Cerbai E et al; On Behalf of Società Italiana di Cardiologia, Sezione Regionale Tosco-Umbra. Myocardial (123)I-metaiodobenzylguanidine imaging in hypertension and left ventricular hypertrophy. *J Nucl Cardiol* 2018;**25**:461–70.
- Boogers MJ, Borleffs CJW, Henneman MM, van Bommel RJ, van Ramshorst J, Boersma E et al. Cardiac sympathetic denervation assessed with 123-iodine metaiodobenzylguanidine imaging predicts ventricular arrhythmias in implantable cardioverter-defibrillator patients. *J Am Coll Cardiol* 2010;**55**:2769–77.
- Gimelli A, Menichetti F, Soldati E, Liga R, Vannozzi A, Marzullo P et al. Relationships between cardiac innervation/perfusion imbalance and ventricular arrhythmias: impact on invasive electrophysiological parameters and ablation procedures. *Eur J Nucl Med Mol Imaging* 2016;**43**:2383–91.
- Gimelli A, Menichetti F, Soldati E et al. Correlation between ventricular arrhythmias and cardiac innervation: clinical impact on ablation procedure. *Eur Heart J* 2016;**37**:691.
- Florea VG, Cohn JN. The autonomic nervous system and heart failure. *Circ Res* 2014;**114**:1815–26.
- Agostini D, Verberne HJ, Burchert W, Knuuti J, Povinec P, Sambucetti G et al. I-123-mIBG myocardial imaging for assessment of risk for a major cardiac event in heart failure patients: insights from a retrospective European multicenter study. *Eur J Nucl Med Mol Imaging* 2008;**35**:535–46.
- Merlet P, Benvenuti C, Moysé D et al. Prognostic value of MIBG imaging in idiopathic dilated cardiomyopathy. *J Nucl Med* 1999;**40**:917–23.
- Nakata T, Miyamoto K, Doi A et al. Cardiac death prediction and impaired cardiac sympathetic innervation assessed by MIBG in patients with failing and non-failing hearts. *J Nucl Cardiol* 1998;**5**:579–90.
- Merlet P, Poullart F, Dubois-Randé JL, Delahaye N, Fumey R, Castaigne A et al. Sympathetic nerve alterations assessed with 123I-MIBG in the failing human heart. *J Nucl Med* 1999;**40**:224–31.
- Cohen-Solal A, Esanu Y, Logeart D, Pessione F, Dubois C, Dreyfus G et al. Cardiac metaiodobenzylguanidine uptake in patients with moderate chronic heart failure: relationship with peak oxygen uptake and prognosis. *J Am Coll Cardiol* 1999;**33**:759–66.
- Nakata T, Nakajima K, Yamashina S, Yamada T, Momose M, Kasama S et al. A pooled analysis of multicenter cohort studies of (123)I-mIBG imaging of sympathetic innervation for assessment of long-term prognosis in heart failure. *JACC Cardiovasc Imaging* 2013;**6**:772–84.
- Verschure DO, Veltman CE, Manrique A, Somsen GA, Koutelou M, Katsikis A et al. For what endpoint does myocardial 123I-MIBG scintigraphy have the greatest prognostic value in patients with chronic heart failure? Results of a pooled individual patient data meta-analysis. *Eur Heart J Cardiovasc Imaging* 2014;**15**:996–1003.
- Liga R, Scholte A. Neuro-cardiac imaging has a proven value in patient management: Con. *J Nucl Cardiol* 2017;**24**:1583–1587.
- O'Day K, Levy WC, Johnson M, Jacobson AF. Cost-effectiveness analysis of iodine-123 meta-iodobenzylguanidine imaging for screening heart failure patients eligible for an implantable cardioverter defibrillator in the USA. *Appl Health Econ Health Policy* 2016;**14**:361–73.
- Nakajima K, Nakata T, Yamada T, Yamashina S, Momose M, Kasama S et al. A prediction model for 5-year cardiac mortality in patients with chronic heart failure using (1)(2)(3). *Eur J Nucl Med Mol Imaging* 2014;**41**:1673–82.
- Kawasaki M, Yamada T, Morita T et al. Prognostic value of cardiac metaiodobenzylguanidine imaging and QRS duration in implantable cardioverter defibrillator patients with and without heart failure. *Int J Cardiol* 2019;**296**:164–171.
- Køber L, Thune JJ, Nielsen JC, Haarbø J, Videbæk L, Korup E et al. Defibrillator implantation in patients with nonischemic systolic heart failure. *N Engl J Med* 2016;**375**:1221–30.
- Moreira RI, Abreu A, Portugal G, Oliveira L, Oliveira M, Rodrigues I et al. Prognostic effect and modulation of cardiac sympathetic function in heart failure patients treated with cardiac resynchronization therapy. *J Nucl Cardiol* 2020;**27**: 283–290.
- Curcio A, Cascini GL, De Rosa S, Pasceri E, Veneziano C, Cipullo S et al. (123)I-mIBG imaging predicts functional improvement and clinical outcome in patients with heart failure and CRT implantation. *Int J Cardiol* 2016;**207**:107–9.
- Cha Y-M, Chareonthaitawee P, Dong Y-X, Kemp BJ, Oh JK, Miyazaki C et al. Cardiac sympathetic reserve and response to cardiac resynchronization therapy. *Circ Heart Fail* 2011;**4**:339–44.
- Gimelli A, Liga R, Menichetti F, Soldati E, Bongiorno MG, Marzullo P. Interactions between myocardial sympathetic denervation and left ventricular mechanical dyssynchrony: a CZT analysis. *J Nucl Cardiol* 2019;**26**:509–518.
- Awad M, Czer LS, Hou M et al. Early denervation and later reinnervation of the heart following cardiac transplantation: a review. *J Am Heart Assoc* 2016;**5**.
- Bengel FM, Ueberfuhr P, Ziegler SI, Nekolla S, Reichart B, Schwaiger M. Serial assessment of sympathetic reinnervation after orthotopic heart transplantation. A longitudinal study using PET and C-11 hydroxyephedrine. *Circulation* 1999;**99**: 1866–71.
- Bengel F, Ueberfuhr P, Karja J, Schreiber K, Nekolla S, Reichart B et al. Sympathetic reinnervation, exercise performance and effects of beta-adrenergic blockade in cardiac transplant recipients. *Eur Heart J* 2004;**25**:1726–33.
- Di Carli MF, Tobes MC, Mangner T, Levine AB, Muzik O, Chakraborty P et al. Effects of cardiac sympathetic innervation on coronary blood flow. *N Engl J Med* 1997;**336**:1208–15.
- Bengel FM, Ueberfuhr P, Hesse T, Schiepel N, Ziegler SI, Scholz S et al. Clinical determinants of ventricular sympathetic reinnervation after orthotopic heart transplantation. *Circulation* 2002;**106**:831–5.
- Klein T, Abdulghani M, Smith M, Huang R, Asoglu R, Remo BF et al. Three-dimensional 123I-meta-iodobenzylguanidine cardiac innervation maps to assess substrate and successful ablation sites for ventricular tachycardia: feasibility study for a novel paradigm of innervation imaging. *Circ Arrhythm Electrophysiol* 2015;**8**:583–91.
- Travin MI, Henzlva MJ, van Eck-Smit BLF, Jain D, Carrió I, Folks RD et al. Assessment of (123)I-mIBG and (99m)Tc-tetrafosmin single-photon emission computed tomographic images for the prediction of arrhythmic events in patients with ischemic heart failure: intermediate severity innervation defects are associated with higher arrhythmic risk. *J Nucl Cardiol* 2017;**24**:377–391.
- Abdulghani M, Duell J, Smith M, Chen W, Bentzen SM, Asoglu R et al. Global and regional myocardial innervation before and after ablation of drug-refractory ventricular tachycardia assessed with ¹²³I-MIBG. *J Nucl Med* 2015;**56**:525–585.

43. Sasano T, Abraham MR, Chang K-C, Ashikaga H, Mills KJ, Holt DP *et al*. Abnormal sympathetic innervation of viable myocardium and the substrate of ventricular tachycardia after myocardial infarction. *J Am Coll Cardiol* 2008;**51**: 2266–75.
44. Vontobel J, Liga R, Possner M, Clerc OF, Mikulic F, Veit-Haibach P *et al*. MR-based attenuation correction for cardiac FDG PET on a hybrid PET/MRI scanner: comparison with standard CT attenuation correction. *Eur J Nucl Med Mol Imaging* 2015;**42**:1574–80.
45. Nensa F, Bamberg F, Rischpler C, Menezes L, Poeppel TD, la Fougère C *et al*; on behalf of the European Society of Cardiovascular Radiology (ESCR). Hybrid cardiac imaging using PET/MRI: a joint position statement by the European Society of Cardiovascular Radiology (ESCR) and the European Association of Nuclear Medicine (EANM). *Eur Radiol* 2018;**28**:4086–4101.
46. Palmisano A, Vignale D, Peretto G *et al*. Hybrid FDG-PET/MR or FDG-PET/CT to detect disease activity in patients with persisting arrhythmias after myocarditis. *JACC Cardiovasc Imaging* 2021;**14**:288–92.
47. Wisenberg G, Thiessen JD, Pavlovsky W, Butler J, Wilk B, Prato FS. Same day comparison of PET/CT and PET/MR in patients with cardiac sarcoidosis. *J Nucl Cardiol* 2020;**27**:2118–129.
48. Wazni OM, Marrouche NF, Martin DO, Verma A, Bhargava M, Saliba W *et al*. Radiofrequency ablation vs antiarrhythmic drugs as first-line treatment of symptomatic atrial fibrillation: a randomized trial. *JAMA* 2005;**293**:2634–40.
49. Fink T, Schlüter M, Heeger C-H, Lemes C, Maurer T, Reissmann B *et al*. Stand-alone pulmonary vein isolation versus pulmonary vein isolation with additional substrate modification as index ablation procedures in patients with persistent and long-standing persistent atrial fibrillation: the randomized Alster-Lost-AF Trial (Ablation at St. Georg Hospital for Long-Standing Persistent Atrial Fibrillation). *Circ Arrhythm Electrophysiol* 2017;**10**:e005114.
50. Pauza DH, Skripka V, Pauziene N, Stropus R. Morphology, distribution, and variability of the epicardial neural ganglionated subplexuses in the human heart. *Anat Rec* 2000;**259**:353–82.
51. Po SS, Nakagawa H, Jackman WM. Localization of left atrial ganglionated plexi in patients with atrial fibrillation. *J Cardiovasc Electrophysiol* 2009;**20**:1186–9.
52. Pokushalov E, Romanov A, Artyomenko S, Turov A, Shirokova N, Katritsis DG. Left atrial ablation at the anatomic areas of ganglionated plexi for paroxysmal atrial fibrillation. *Pacing Clin Electrophysiol* 2010;**33**:1231–8.
53. Kurotobi T, Shimada Y, Kino N, Ito K, Tonomura D, Yano K *et al*. Features of intrinsic ganglionated plexi in both atria after extensive pulmonary isolation and their clinical significance after catheter ablation in patients with atrial fibrillation. *Heart Rhythm* 2015;**12**:470–476.
54. Akutsu Y, Kaneko K, Kodama Y, Li H-L, Suyama J, Shinozuka A *et al*. Significance of cardiac sympathetic nervous system abnormality for predicting vascular events in patients with idiopathic paroxysmal atrial fibrillation. *Eur J Nucl Med Mol Imaging* 2010;**37**:742–9.
55. Akutsu Y, Kaneko K, Kodama Y, Li H-L, Suyama J, Shinozuka A *et al*. Iodine-123 MIBG Imaging for Predicting the Development of Atrial Fibrillation. *JACC Cardiovasc Imaging* 2011;**4**:78–86.
56. Arimoto T, Tada H, Igarashi M, Sekiguchi Y, Sato A, Koyama T *et al*. High wash-out rate of iodine-123-metaiodobenzylguanidine imaging predicts the outcome of catheter ablation of atrial fibrillation. *J Cardiovasc Electrophysiol* 2011;**22**: 1297–304.
57. Wenning C, Lange PS, Schülke C, Vrachimis A, Mönnig G, Schober O *et al*. Pulmonary vein isolation in patients with paroxysmal atrial fibrillation is associated with regional cardiac sympathetic denervation. *EJNMMI Res* 2013;**3**:81.
58. Lemery R, Ben-Haim S, Wells G, Ruddy TD. I-123-Metaiodobenzylguanidine imaging in patients with atrial fibrillation undergoing cardiac mapping and ablation of autonomic ganglia. *Heart Rhythm* 2017;**14**:128–132.
59. Stirrup J, Gregg S, Baavour R, Roth N, Breault C, Agostini D *et al*. Hybrid solid-state SPECT/CT left atrial innervation imaging for identification of left atrial ganglionated plexi: technique and validation in patients with atrial fibrillation. *J Nucl Cardiol* 2019.
60. Maurer MS, Elliott P, Comenzo R, Semigran M, Rapezzi C. Addressing common questions encountered in the diagnosis and management of cardiac amyloidosis. *Circulation* 2017;**135**:1357–1377.
61. Goldstein DS. Cardiac Dysautonomia and Survival in Hereditary Transthyretin Amyloidosis. *JACC Cardiovasc Imaging* 2016;**9**:1442–1445.
62. Coutinho MCA, Cortez-Dias N, Cantinho G, Conceição I, Oliveira A, Bordalo e Sá A *et al*. Reduced myocardial 123-iodine metaiodobenzylguanidine uptake: a prognostic marker in familial amyloid polyneuropathy. *Circ Cardiovasc Imaging* 2013;**6**:627–36.
63. Delahaye N, Dinanian S, Slama MS, Mzabi H, Samuel D, Adams D *et al*. Cardiac sympathetic denervation in familial amyloid polyneuropathy assessed by iodine-123 metaiodobenzylguanidine scintigraphy and heart rate variability. *Eur J Nucl Med* 1999;**26**:416–24.
64. Dingli D, Tan TS, Kumar SK, Buadi FK, Dispenziers A, Hayman SR *et al*. Stem cell transplantation in patients with autonomic neuropathy due to primary (AL) amyloidosis. *Neurology* 2010;**74**:913–8.
65. Noordzij W, Glaudemans AWJM, van Rheenen RWJ, Hazenberg BPC, Tio RA, Dierckx RAJO *et al*. I-Labelled metaiodobenzylguanidine for the evaluation of cardiac sympathetic denervation in early stage amyloidosis. *Eur J Nucl Med Mol Imaging* 2012;**39**:1609–17.
66. Nakata T, Shimamoto K, Yonekura S, Kobayashi N, Sugiyama T, Imai K *et al*. Cardiac sympathetic denervation in transthyretin-related familial amyloidotic polyneuropathy: detection with iodine-123-MIBG. *J Nucl Med* 1995;**36**:1040–2.
67. Tanaka M, Hongo M, Kinoshita O, Takabayashi Y, Fujii T, Yazaki Y *et al*. Iodine-123 metaiodobenzylguanidine scintigraphic assessment of myocardial sympathetic innervation in patients with familial amyloid polyneuropathy. *J Am Coll Cardiol* 1997;**29**:168–74.
68. Jonker DL, Hazenberg BPC, Nienhuis HLA, Slart R, Glaudemans A, Noordzij W. Imaging cardiac innervation in hereditary transthyretin (ATTRm) amyloidosis: a marker for neuropathy or cardiomyopathy in case of heart failure? *J Nucl Cardiol* 2020;**27**:1774–84.
69. Piekarski E, Chequer R, Algalarrondo V, Eliahou L, Mahida B, Vigne J *et al*. Cardiac denervation evidenced by MIBG occurs earlier than amyloid deposits detection by diphosphonate scintigraphy in TTR mutation carriers. *Eur J Nucl Med Mol Imaging* 2018;**45**:1108–1118.
70. Dorbala S, Ando Y, Bokhari S, Dispenziers A, Falk RH, Ferrari VA, *et al*. ASNC/AHA/ASE/EANM/HFSA/ISA/SCMR/SNMMI expert consensus recommendations for multimodality imaging in cardiac amyloidosis: part 2 of 2-Diagnostic criteria and appropriate utilization. *J Nucl Cardiol* 2019.
71. Slart R, Glaudemans A, Noordzij W, Bijzet J, Hazenberg BPC, Nienhuis HLA. Time for new imaging and therapeutic approaches in cardiac amyloidosis. *Eur J Nucl Med Mol Imaging* 2019;**46**:1402–1406.
72. Zhang KW, Stockert-Goldstein KE, Lenihan DJ. Emerging therapeutics for the treatment of light chain and transthyretin amyloidosis. *JACC Basic Transl Sci* 2019;**4**:438–448.
73. <https://www.who.int/news-room/fact-sheets/detail/diabetes>.
74. Dal Canto E, Ceriello A, Rydén L, Ferrini F, Hansen TB, Schnell O *et al*. Diabetes as a cardiovascular risk factor: an overview of global trends of macro and micro vascular complications. *Eur J Prev Cardiol* 2019;**26**:25–32.
75. Vinik AI, Ziegler D. Diabetic cardiovascular autonomic neuropathy. *Circulation* 2007;**115**:387–97.
76. Gerritsen J, Dekker JM, TenVoorde BJ, Kostense PJ, Heine RJ, Bouter LM *et al*. Impaired autonomic function is associated with increased mortality, especially in subjects with diabetes, hypertension, or a history of cardiovascular disease: the Hoorn Study. *Diabetes Care* 2001;**24**:1793–8.
77. Scholte AJHA, Schuijff JD, Delgado V, Kok JA, Bus MTJ, Maan AC *et al*. Cardiac autonomic neuropathy in patients with diabetes and no symptoms of coronary artery disease: comparison of 123I-metaiodobenzylguanidine myocardial scintigraphy and heart rate variability. *Eur J Nucl Med Mol Imaging* 2010;**37**:1698–705.
78. Langer A, Freeman MR, Josse RG, Armstrong PW. Metaiodobenzylguanidine imaging in diabetes mellitus: assessment of cardiac sympathetic denervation and its relation to autonomic dysfunction and silent myocardial ischemia. *J Am Coll Cardiol* 1995;**25**:610–8.
79. Mba CM, Nganou-Gnindjio C-N, Azabji-Kenfack M, Mfeukeu-Kuate L, Dehayem MY, Mbanya JC *et al*. Short term optimization of glycaemic control using insulin improves sympatho-vagal tone activities in patients with type 2 diabetes. *Diabetes Res Clin Pract* 2019;**157**:107875.
80. Sano M. A new class of drugs for heart failure: SGLT2 inhibitors reduce sympathetic overactivity. *J Cardiol* 2018;**71**:471–476.
81. Bossone E, Savarese G, Ferrara F, Citro R, Mosca S, Musella F *et al*. Takotsubo cardiomyopathy: overview. *Heart Fail Clin* 2013;**9**:249–66.
82. Prasad A, Lerman A, Rihal CS. Apical ballooning syndrome (Tako-Tsubo or stress cardiomyopathy): a mimic of acute myocardial infarction. *Am Heart J* 2008;**155**:408–17.
83. Pilgrim TM, Wyss TR. Takotsubo cardiomyopathy or transient left ventricular apical ballooning syndrome: a systematic review. *Int J Cardiol* 2008;**124**:283–92.
84. Wittstein IS, Thiemann DR, Lima JAC, Baughman KL, Schulman SP, Gerstenblith G *et al*. Neurohumoral features of myocardial stunning due to sudden emotional stress. *N Engl J Med* 2005;**352**:539–48.
85. Sharkey SW, Windenburg DC, Lesser JR, Maron MS, Hauser RG, Lesser JN *et al*. Natural history and expansive clinical profile of stress (tako-tsubo) cardiomyopathy. *J Am Coll Cardiol* 2010;**55**:333–41.
86. Yoshida T, Hibino T, Kako N, Murai S, Oguri M, Kato K *et al*. A pathophysiological study of tako-tsubo cardiomyopathy with F-18 fluorodeoxyglucose positron emission tomography. *Eur Heart J* 2007;**28**:2598–604.
87. Cimarelli S, Sauer F, Morel O, Ohlmann P, Constantinesco A, Imperiale A. Transient left ventricular dysfunction syndrome: patho-physiological bases through nuclear medicine imaging. *Int J Cardiol* 2010;**144**:212–8.

88. Christensen TE, Bang LE, Holmvang L, Skovgaard DC, Oturai DB, Søholm H et al. I-MIBG scintigraphy in the subacute state of Takotsubo cardiomyopathy. *JACC Cardiovasc Imaging* 2016;**9**:982–90.
89. Paur H, Wright PT, Sikkell MB, Tranter MH, Mansfield C, O’Gara P et al. High levels of circulating epinephrine trigger apical cardiodepression in a beta2-adrenergic receptor/Gi-dependent manner: a new model of Takotsubo cardiomyopathy. *Circulation* 2012;**126**:697–706.
90. Lebasnier A, Lamotte G, Manrique A, Peyronnet D, Bouvard G, Defer G et al. Potential diagnostic value of regional myocardial adrenergic imaging using (123)I-MIBG SPECT to identify patients with Lewy body diseases. *Eur J Nucl Med Mol Imaging* 2015;**42**:1043–51.
91. Lee JE, Kim JS, Ryu DW, Oh YS, Yoo IR, Lee KS. Cardiac sympathetic denervation can predict the wearing-off phenomenon in patients with Parkinson disease. *J Nucl Med* 2018;**59**:1728–33.
92. De Rosa A, Pellegrino T, Pappatà S, Pellicchia MT, Peluso S, Saccà F et al. Myocardial (123)I-metaiodobenzylguanidine scintigraphy in patients with homozygous and heterozygous parkin mutations. *J Nucl Cardiol* 2017;**24**:103–107.
93. Thackeray JT, Bengel FM. Assessment of cardiac autonomic neuronal function using PET imaging. *J Nucl Cardiol* 2013;**20**:150–65.
94. Wu KY, Zelt JGE, Wang T, Dinulescu V, Miner R, Lapierre C et al. Reliable quantification of myocardial sympathetic innervation and regional denervation using [(11)C]meta-hydroxyephedrine PET. *Eur J Nucl Med Mol Imaging* 2020;**47**:1722–1735.
95. Zelt JGE, deKemp RA, Rotstein BH, Nair GM, Narula J, Ahmadi A et al. Nuclear imaging of the cardiac sympathetic nervous system: a disease-specific interpretation in heart failure. *JACC Cardiovasc Imaging* 2019;**13**:1036–105.
96. Lautamaki R, Sasano T, Higuchi T, Nekolla SG, Lardo AC, Holt DP et al. Multiparametric molecular imaging provides mechanistic insights into sympathetic innervation impairment in the viable infarct border zone. *J Nucl Med* 2015;**56**:457–63.
97. Yu M, Bozek J, Lamoy M, Guaraldi M, Silva P, Kagan M et al. Evaluation of LMI1195, a novel ¹⁸F-labeled cardiac neuronal PET imaging agent, in cells and animal models. *Circ Cardiovasc Imaging* 2011;**4**:435–43.
98. Sinusas AJ, Lazewatsky J, Brunetti J, Heller G, Srivastava A, Liu Y-H et al. Biodistribution and radiation dosimetry of LMI1195: first-in-human study of a novel 18F-labeled tracer for imaging myocardial innervation. *J Nucl Med* 2014;**55**:1445–51.
99. Raffel DM, Jung Y-W, Koeppel RA, Jang KS, Gu G, Scott PJH et al. First-in-human studies of [(18)F] fluorohydroxyphenethylguanidines. *Circ Cardiovasc Imaging* 2018;**11**:e007965.
100. Tinti E, Positano V, Giorgetti A, Marzullo P. Feasibility of [(123)I]-metaiodobenzylguanidine dynamic 3-D kinetic analysis in vivo using a CZT ultrafast camera: preliminary results. *Eur J Nucl Med Mol Imaging* 2014;**41**:167–73.
101. Giorgetti A, Burchielli S, Positano V, Kovalski G, Quaranta A, Genovesi D et al. Dynamic 3D analysis of myocardial sympathetic innervation: an experimental study using 123I-MIBG and a CZT camera. *J Nucl Med* 2015;**56**:464–9.