



Universiteit
Leiden
The Netherlands

Repair of traumatic avulsion of the right bronchus in children using extracorporeal membrane oxygenation support

Ricciardi, G.; Putman, L.M.; Hazekamp, M.G.

Citation

Ricciardi, G., Putman, L. M., & Hazekamp, M. G. (2021). Repair of traumatic avulsion of the right bronchus in children using extracorporeal membrane oxygenation support. *Interactive Cardiovascular And Thoracic Surgery*, 32(5), 834-836. doi:10.1093/icvts/ivaa327

Version: Not Applicable (or Unknown)

License: [Leiden University Non-exclusive license](#)

Downloaded from: <https://hdl.handle.net/1887/3277406>

Note: To cite this publication please use the final published version (if applicable).

Cite this article as: Ricciardi G, Putman LM, Hazekamp MG. Repair of traumatic avulsion of the right bronchus in children using extracorporeal membrane oxygenation support. *Interact CardioVasc Thorac Surg* 2021;32:834–6.

Repair of traumatic avulsion of the right bronchus in children using extracorporeal membrane oxygenation support

Gabriella Ricciardi *, Léon M. Putman and Mark G. Hazekamp

Department of Cardiothoracic Surgery, Leiden University Medical Center, Leiden, Netherlands

* Corresponding author. Department of Cardiothoracic Surgery, Leiden University Medical Center, Kinderhartcentrum D6-26, Albinusdreef 2, 2333 ZA Leiden, Netherlands. Tel: +393470970161, E-mail: g.ricciardi@lumc.nl, gabriella.ricciardi90@gmail.com (G. Ricciardi).

Received 26 October 2020; received in revised form 19 November 2020; accepted 28 November 2020

Abstract

Traumatic avulsion of the right main bronchus in children is usually caused by blunt trauma or traffic accidents. Primary repair by suturing is the preferred treatment. Lesions are life threatening and urgent or emergency surgical repair is indicated. We report our experience with 2 cases of traumatic avulsion of right bronchus in children successfully suture repaired with the use of extracorporeal membrane oxygenation.

Keywords: Trauma • Extracorporeal membrane oxygenation • Bronchial avulsion

INTRODUCTION

Traumatic tracheobronchial injuries (TBI) may occur anywhere between cricoid cartilage and carina and be accompanied by collateral damage to lungs and chest wall.

Lungs are mobile in the chest cavity but fixed at the hilum. Therefore, a sudden deceleration of the body can lead to avulsion of a (usually right) main bronchus (RMB) from the carina.

TBI are rare and only a few studies [1], even less in paediatric population, have addressed them. While some injuries may be immediately fatal due to total airway obstruction or tension pneumothorax, less severe lesions can evolve into delayed airway obstructions. Thus, prompt diagnosis and management is key to optimize outcomes.

Commonest indications for acute repair include ongoing risk of airway obstruction, massive air leak and (tension) pneumothorax, progressive emphysema of subcutaneous tissues or deeper in neck and mediastinum. Direct suturing of the avulsed bronchus back to the trachea is the preferred technique; lung resection should be avoided.

Extracorporeal membrane oxygenation (ECMO) has been described as a bridge therapy to maintain respiratory function while waiting for a complete diagnosis [2]. It can be used to stabilize patients when more urgent (e.g. neuro- or abdominal) surgery is indicated before airway repair, and it greatly facilitates bronchus repair. Furthermore, ECMO can be adopted without or with only a low dose of heparin [3], which is advantageous in multi-traumatized patients.

MATERIALS AND METHODS

We describe the management of 2 patients with RMB traumatic avulsion following traffic accidents.

Patient 1 was a 16-year-old, multi-traumatized boy with fractures of ribs (including the first one), vertebrae, scapula, clavicle and maxillofacial structures, mild epidural haematoma, bilateral pneumothorax and pneumomediastinum. CT scan showed in addition a lack of continuity between trachea and RMB (Fig. 1, upper part) and bilateral lung contusions.

Patient 2 was a 10-year-old boy with fractures of ribs (including the first one) and elbow, bilateral pneumothorax and pneumomediastinum. A priapism raised suspicion of medullar trauma, which was excluded by CT scan. Thoracic CT scan showed the avulsion of the RMB from the trachea (Fig. 1, lower part).

In both cases, pneumothorax and pneumomediastinum were drained and major fractures were stabilized first.

Urgent surgical repair of TBI was performed on veno-arterial (VA)-ECMO support.

In patient 1, ECMO was started after cannulation of right femoral vessels under local anaesthesia and before endotracheal intubation, which was expected to be high risk because of severe maxillofacial fractures. No heparin was given. Once on ECMO, the patient could be safely intubated. Subsequent bronchoscopy showed complete avulsion of RMB and a tear in the pars membranacea of left main bronchus (LMB).

After sternotomy and pericardial opening, the trachea was fully mobilized between superior vena cava, ascending aorta and right pulmonary artery. The arterial cannula was moved to the ascending aorta. A long distance was observed between trachea and RMB. Thus, division of the pulmonary ligamentum was performed via the right pleural space to enable a tension-free repair. A direct anastomosis of RMB to trachea and a direct closure of the LMB tear were performed, using 4/0 and 5/0 double polydioxanone (PDS) suture (Fig. 2).

In patient 2, ECMO cannulation was in ascending aorta and right atrium. A total of 100 UI/kg of heparin were added to the

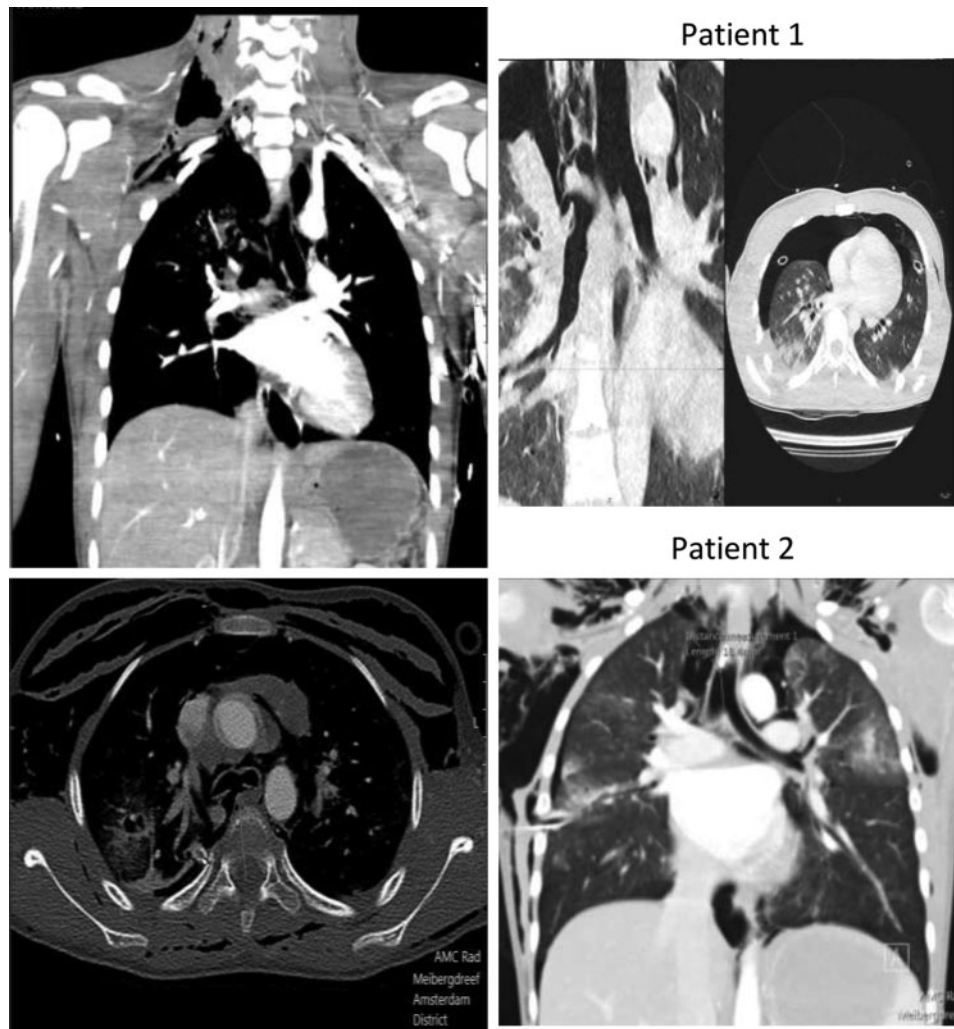

Figure 1: CT scan in the first patient, showing a lack of continuity between trachea and right main bronchus and bilateral lung contusions. CT scan in the second patient, showing an almost complete avulsion of the right main bronchus from the trachea.

ECMO circuit and antagonized by protamine afterwards. A posterior tear in LMB was directly sutured from the inside, after a careful inspection of both trachea and bronchi. RMB avulsion was repaired using a sliding technique because of the smaller size of airways.

Water test and post-repair bronchoscopy confirmed good results in both cases. A gentamycin-sponge was left under the pre-tracheal fascia to prevent late infections. ECMO was discontinued at the end of procedures.

RESULTS

CT scan performed 1 year and 1 month after surgery demonstrates the complete patency of trachea and bronchi.

DISCUSSION

Most of TBI produced by high-energy traumas present with total avulsion usually involving the RMB possibly because the LMB is protected in part by the aorta.

The presence of first rib fracture, according to other reports in literature [4], represents a marker of severe bronchial injuries.

Surgical repair is preferred over conservative management. Adequate exposure, sufficient airway length for reconstruction and preservation of tracheal blood supply and functional pulmonary tissue are paramount. The best exposure is in our opinion accomplished through median sternotomy to allow tension-free repair of trachea and both bronchi as well as access to both lungs.

Use of ECMO in this setting holds several advantages. Differently from Cardio-Pulmonary Bypass, it can be conducted without (patient 1) or only with a low (patient 2) heparin dose, limiting side effects on multi-traumatized patients, in which (full) heparinization is risky due to possible abdominal, lung, cerebral, spine and medullar bleeding (patient 2). We favour VA-ECMO over VV-ECMO because chest trauma with airway lesions right ventricular dysfunction may occur with high ventilator pressures [5], massive blood transfusion and use of catecholamines. VA-ECMO unloads right heart aiding in its support and recovery.

ECMO facilitates stabilization prior to surgery and can be started after the cannulation of femoral vessels under local anaesthesia when endotracheal intubation is expected to be difficult.

Conflict of interest: none declared.

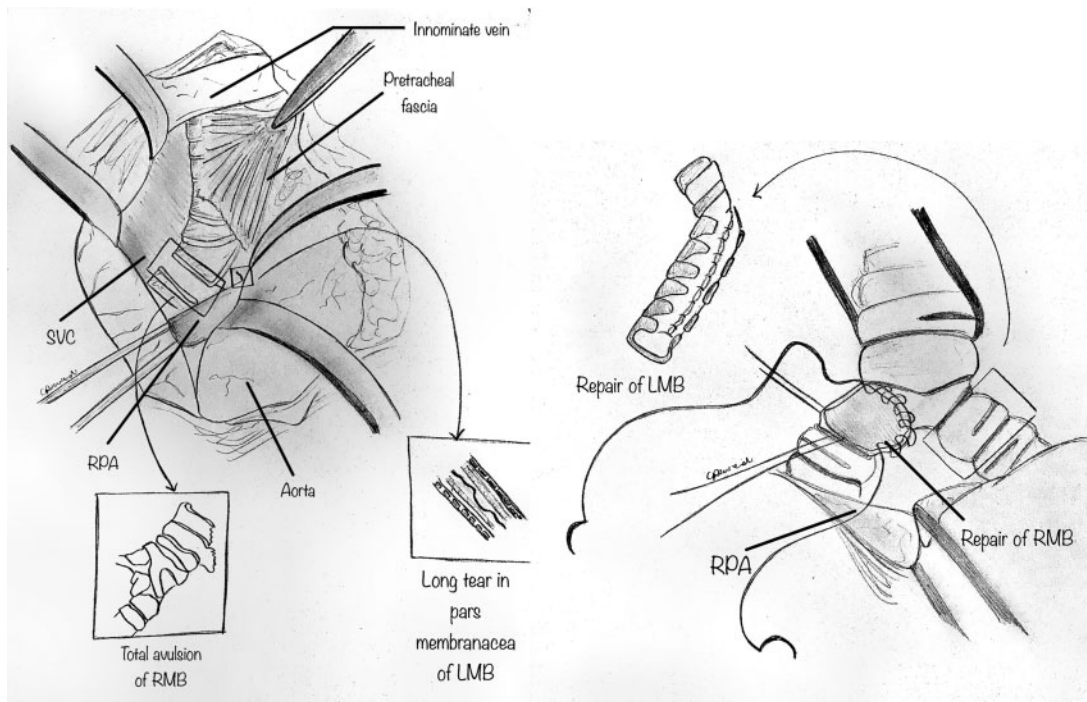


Figure 2: Personal drawings by one of the authors (G.R.).

Reviewer information

Interactive CardioVascular and Thoracic Surgery thanks Milton Saute and the other, anonymous reviewer(s) for their contribution to the peer review process of this article.

REFERENCES

- [1] Shemmeri E, Vallières E. Blunt tracheobronchial trauma. *Thorac Surg Clin* 2018;28:429-34.
- [2] Schmoekel N, O'Connor J, Scalea T. Nonoperative damage control: the use of extracorporeal membrane oxygenation in traumatic bronchial avulsion as a bridge to definitive operation. *Ann Thorac Surg* 2016;101:2384-6.
- [3] Oliver WC. Anticoagulation and coagulation management for ECMO. *Semin Cardiothorac Vasc Anesth* 2009;13:154-75.
- [4] Sammy IA, Chatha H, Lecky F, Bouamra O, Frago-Iñiguez M, Sattout A *et al.* Are first rib fractures a marker for other life-threatening injuries in patients with major trauma? A cohort study of patients on the UK Trauma Audit and Research Network database. *Emerg Med J* 2017;34:205-11.
- [5] Madershahian N, Wittwer T, Strauch J, Franke UF, Wippermann J, Kaluza M *et al.* Application of ECMO in multitrauma patients with ARDS as rescue therapy. *J Cardiac Surg* 2007;22:180-4.