



Universiteit
Leiden
The Netherlands

Three-dimensional-printed drill guides for occipitothoracic fusion in a pediatric patient with occipitocervical instability

Pijpker, P.A.J.; Kuijlen, J.M.A.; Kaptein, B.L.; Pondaag, W.

Citation

Pijpker, P. A. J., Kuijlen, J. M. A., Kaptein, B. L., & Pondaag, W. (2021). Three-dimensional-printed drill guides for occipitothoracic fusion in a pediatric patient with occipitocervical instability. *Operative Neurosurgery*, 21(1), 27-33. doi:10.1093/ons/opab060

Version: Publisher's Version

License: [Creative Commons CC BY-NC-ND 4.0 license](https://creativecommons.org/licenses/by-nc-nd/4.0/)

Downloaded from: <https://hdl.handle.net/1887/3213023>

Note: To cite this publication please use the final published version (if applicable).

Three-Dimensional-Printed Drill Guides for Occipitothoracic Fusion in a Pediatric Patient With Occipitocervical Instability

Peter A. J. Pijpker, MSc *

Jos M. A. Kuijlen, MD, PhD[‡]

Bart L. Kaptein, PhD[§]

Willem Pondaag, MD, PhD[¶]

*3D lab, University of Groningen, University Medical Center Groningen, Groningen, the Netherlands; [‡]Department of Neurosurgery, University of Groningen, University Medical Center Groningen, Groningen, the Netherlands; [§]Department of Orthopedics, Leiden University Medical Center, Leiden, the Netherlands; [¶]Department of Neurosurgery, Leiden University Medical Center, Leiden, the Netherlands

Correspondence:

Peter A. J. Pijpker, MSc,
Department of Neurosurgery,
University Medical Center Groningen,
University of Groningen,
PO Box 30001,
9700 RB Groningen, the Netherlands.
Email: p.a.j.pijpker@umcg.nl

Received, October 5, 2020.

Accepted, December 25, 2020.

Published Online, March 16, 2021.

© Congress of Neurological Surgeons
2021.

This is an Open Access article distributed under the terms of the Creative Commons Attribution-NonCommercial-NoDerivs licence (<http://creativecommons.org/licenses/by-nc-nd/4.0/>), which permits non-commercial reproduction and distribution of the work, in any medium, provided the original work is not altered or transformed in any way, and that the work is properly cited. For commercial re-use, please contact journals.permissions@oup.com

BACKGROUND: Pediatric occipitothoracic fusion can be challenging because of small size pedicles and thin occipital bone. Three-dimensional (3D) printing technology can help with accurate screw insertion but has not been described for occipital keel plate positioning so far.

OBJECTIVE: To describe the novel use of 3D technology to position occipital keel plates during pediatric occipitothoracic fixation.

METHODS: A young boy with segmental spinal dysgenesis presented with asymmetrical pyramidal paresis in all limbs. Developmental abnormalities of the cervical spine caused a thinned spinal cord, and because of progressive spinal cord compression, surgical intervention by means of occipitothoracic fixation was indicated at the age of 3 yr.

Because of the small-size pedicles and thin occipital bone, the pedicle screws and occipital plates were planned meticulously using 3D virtual surgical planning technology. The rods were virtually bent in order to properly align with the planned screws. By means of 3D-printed guides, the surgical plan was transferred to the operating theater. For the occipital bone, a novel guide concept was developed, aiming for screw positions at maximal bone thickness.

RESULTS: The postoperative course was uneventful, and radiographs showed good cervical alignment. After superimposing the virtual plan with the intraoperative acquired computed tomography, it was confirmed that the occipital plate positions matched the virtual plan and that pedicle screws were accurately inserted without signs of breach.

CONCLUSION: The use of 3D technology has greatly facilitated the performance of the occipitothoracic fixation and could, in the future, contribute to safer pediatric spinal fixation procedures.

KEY WORDS: 3D-printing, Virtual surgical planning, Guides, Occipitocervical fixation, Occipital keel screws, Pedicle screws

Operative Neurosurgery 21:27–33, 2021

DOI: 10.1093/ons/opab060

Nontraumatic occipitocervical instability in pediatric patients is a rare condition that has been observed in a variety of diseases such as rheumatoid arthritis, children with Down syndrome, and various syndromes with skeletal involvement.¹⁻³ Occipitocervical instability can present with neck or occipital pain, but in the majority of cases, radiological abnormalities remain asymptomatic. Although frequently asymptomatic,

early detection is critical because these abnormalities may eventually cause neurological compromise or even sudden death.⁴ The need for prophylactic surgery in children with asymptomatic instability is still debated, but early surgical intervention is indicated for patients with instability induced myelopathy.

The surgical approach aims for a solid fusion of the cervical spine towards the occiput, preventing (further) neurological deficit, giving stability, and leading to improved sagittal balance. Several surgical strategies have been implemented to achieve this goal, but immobilization using rigid screw-rod systems combined with bone graft has been shown to provide the

ABBREVIATIONS: SSD, segmental spinal dysgenesis; VSP, virtual surgical planning

best biomechanical stability and fusion rates.⁵⁻⁸ Although advances in surgical techniques led to safer and more effective fixation procedures, fixation can be particularly challenging in children given their small size pedicles and thin occipital bone.

For several years now, the popularity of virtual surgical planning (VSP) and three-dimensional (3D)-printed individualized drill guides is rising, and an increasing number of studies come available that describe their value for cervical spine surgery.⁹⁻¹¹ In contrast to computer-navigated surgery, guides provide tactile guidance and are less prone to realignment of vertebrae during surgical manipulation. Especially in the unstable pediatric spine, relative vertebral movements can be large, and secured immobile positioning of the computer navigation reference array may be challenging. In the current case, we describe the use of 3D technology to position pedicle screws and occipital screws in a young boy undergoing occipitothoracic fixation. To the best of our knowledge, this is the first report of this technique being used for the positioning of occipital plates and screws.

METHODS

Presentation

A young boy with segmental spinal dysgenesis (SSD) caused by a compound homozygous mutation in the *RIPPLY2*-gene was referred to the Leiden University Medical Center at the age of 9 mo. This genetic defect has been previously associated with spinal deformities.¹² From early infancy, he had an asymmetrical pyramidal paresis in all 4 limbs. During follow-up, some spontaneous improvement of the right-side arm-hand function occurred, but the left-side only showed limited improvement.

Radiographs of the cervical spine revealed developmental abnormalities of the cervical spine with a kyphosis at C3-C4. Computed tomography (CT)-imaging showed SSD of the upper cervical spine (Figure 1A). Magnetic resonance (MR) imaging revealed a severely thinned spinal cord at the level of kyphosis (Figure 1B). Initially, a conservative treatment was chosen with external immobilization because the neurological improvement did not necessitate intervention and because of his very young age and technical difficulties to perform spinal fusion surgery. A follow-up MR imaging revealed spinal cord edema and microbleeds, which is suggestive of continuous compression. Therefore, surgical intervention by means of occipitothoracic fixation (C0-T1-T2-T3-T4) was judged as necessary and was scheduled at the age of 3 yr. The underdeveloped spine provided little bone stock for the computer navigation reference array and the high mobility would require several times of computer navigation reregistration. It was therefore chosen to deploy a 3D-VSP strategy for this particular case.

Virtual Surgical Planning

The low dose CT scan (100 kV, 40 mAs, 0.5-mm slice thickness, hard-tissue kernel) was loaded into Mimics v22 (Materialise, Leuven, Belgium) in order to perform bone segmentation using thresholding techniques. The resulting mask was then split up into separate regions for each bone fragment and converted to 3D surface models. The models were imported in medical computer-aided design software,

3-matic v14 (Materialise, Leuven, Belgium). First, the optimal natural head position was simulated by virtual realignment of vertebral models based on the McGregor's skull-base line (Figure 2).¹³ After simulating various scenarios, it was concluded that insufficient bone stock hampers safe positioning of cervical screws, and therefore, thoracic pedicle screw trajectories were planned for the T1, T2, T3, and T4 vertebrae. Based on the defined trajectories, pedicle drill guides were tailored to the patients' anatomy according to our previously presented design blueprints and adjusted to the available drilling equipment (Figure 3).¹¹ Then, Occipital Plate Rods (Vertex Max, Medtronic, Dublin, Ireland) were CT scanned in order to obtain a 3D model needed for 3D planning. The occipital bone thickness was visualized using a colored heatmap and the plate was virtually positioned, aiming for screw regions with maximum bone thickness (Figure 4A and 4B). Based on these optimal screw positions, a drill guide was designed to fit on the occipital bone surface. Because of the relatively flat nature of the occipital bone and the lack of distinct bony references, 2 protruding rims on the guides' caudal edge were designed, finding support on the occipitalized atlas and the edge of the foramen magnum (Figure 4C). Lastly, the rods were virtually bent in order to properly align with the previously planned thoracic pedicle screw heads (Figure 4D). The guides, plates, and bone models were 3D printed in polyamide (Oceanz, Ede, the Netherlands) in accordance with ISO 13485 standards and sterilized for intraoperative use by autoclave steam sterilization.

All procedures performed were in accordance with the ethical standards of the institutional and/or national research committee and with the 1964 Helsinki declaration and its later amendments or comparable ethical standards. Informed consent was obtained for fixation surgery by means of 3D VSP and for the publication of the case report.

RESULTS

Surgery

The surgical procedure was performed with the patient in prone position and the head fixed in a Mayfield skull clamp. Using intraoperative lateral radiographs, the head was carefully aligned in neutral position, to obtain a clinically optimal position and attempt that the curvature of spine during surgery would match with the virtually planned curvature. During surgery the spine was exposed subperiosteally from the occiput to the fourth thoracic vertebrae. The 3D-printed pedicle guides were equipped with SS316L drill sleeves and positioned on the thoracic vertebra with a precision fit (Figure 5A). The trajectories were drilled at high speed (\varnothing 2.2 mm) using a 3D-printed stop that ensured the drill to stop at the predefined depth. The trajectories' integrity was checked using a ball-tip probe and after tapping, polyaxial (\varnothing 3.5 mm) screws were inserted. Then, the occipital guide was positioned and reported to find a good fit by visual and tactile feedback (Figure 5B). The entry points were marked through the guide using a round burr, and the trajectories were drilled using a hand-drill. Subsequently, the virtual bent 3D-printed plate rods were fitted (Figure 5C) and served as a template for bending of the final titanium plate rods. A slight discordance between the planned and intraoperative sagittal profile required additional template manipulation and unfortunately caused one of the templates to break. Therefore, final titanium

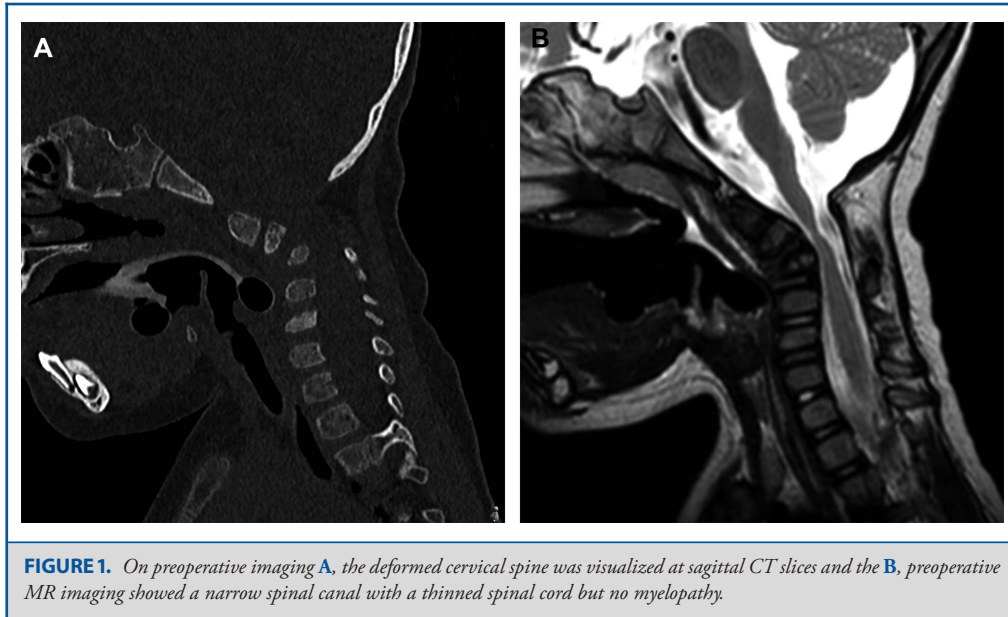


FIGURE 1. On preoperative imaging **A**, the deformed cervical spine was visualized at sagittal CT slices and the **B**, preoperative MR imaging showed a narrow spinal canal with a thinned spinal cord but no myelopathy.

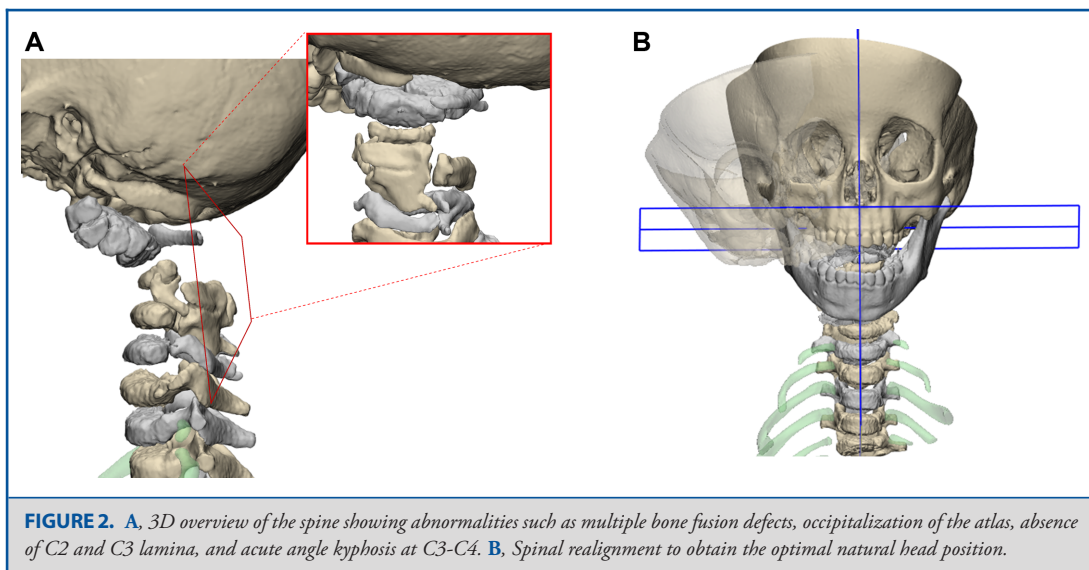


FIGURE 2. **A**, 3D overview of the spine showing abnormalities such as multiple bone fusion defects, occipitalization of the atlas, absence of C2 and C3 lamina, and acute angle kyphosis at C3-C4. **B**, Spinal realignment to obtain the optimal natural head position.

rod contouring had to be done partly freehand. Screw positions were confirmed using intraoperative CT. After confirmation, the plates were screwed, connected to the rods, and finally tightened. Finally, a donor femoral head was crafted and positioned tight to the posterior surface of the occiput and vertebrae using wires.⁸

The postoperative course was uneventful, and the boy was discharged after 7 d without neurological deterioration. The early postoperative radiographs showed good cervical alignment and adequate screw positions. After superimposing the virtual plan with the intraoperative acquired CT, it was confirmed that excellent accuracy was achieved for both the occipital plate and

the pedicle screws. The sagittal profile, however, showed more extension in comparison to what was planned, clinically occipitocervical alignment seemed balanced, and the boy had a forward horizontal gaze. A follow-up after 8 mo showed a stable construct, it was considered too early to perform a CT scan to assess bony fusion (Figure 6).

DISCUSSION

Traditionally, the surgical treatment of atlantoaxial and occipitocervical instability in pediatric patients was associated

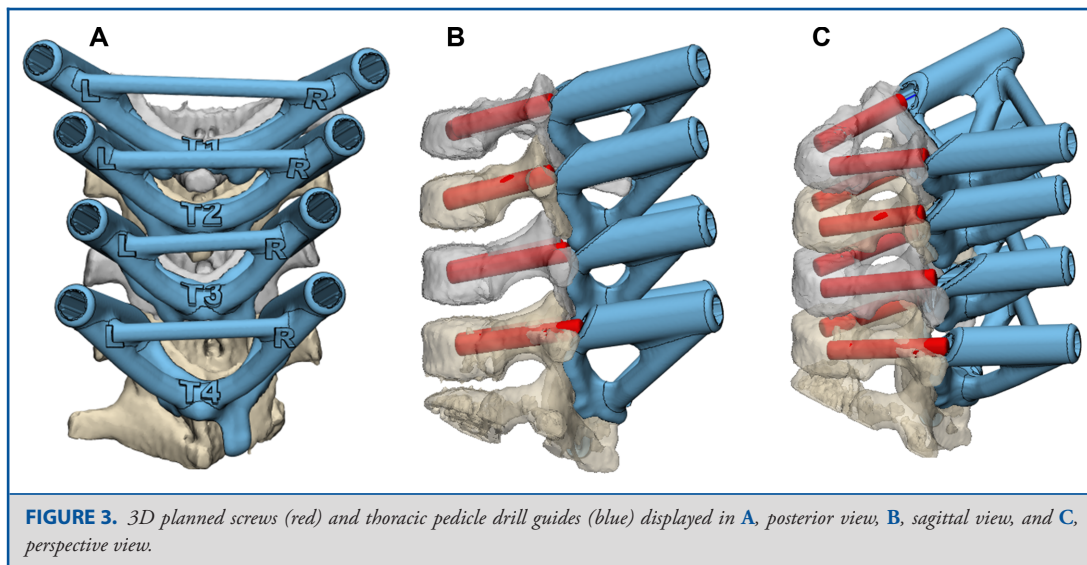


FIGURE 3. 3D planned screws (red) and thoracic pedicle drill guides (blue) displayed in **A**, posterior view, **B**, sagittal view, and **C**, perspective view.

with low fusion rates and risk of complications.¹⁴ Technical advances in fixation hardware and image guidance for screw placement have increased fusion rates substantially.¹⁵ In this report, we described the next step in guidance of occipital screws for the pediatric patient using 3D VSP technology.

The use of 3D printing in medicine is emerging, and the technology is set to transform the way complex surgeries are planned and executed. 3D VSP technology can basically be subdivided into 3 distinct categories. First, medical image data can be converted to dimensionally accurate virtual 3D models. The virtual environment allows surgical planning, simulation, and training for complex procedures.¹⁶ The next step, as described in this report, includes the manufacturing of patient specific surgical guides to actually translate the VSP to the surgical theater. Lastly, the third category includes the manufacturing of patient specific implants, which contrary to guides, remain inside the body.^{17,18}

For the case described in this report, the use of 3D-printed drill guides was successful, showing plate positions that match the VSP and screws positioned in the thickest regions of the occipital bone. In the thoracic region, all screws were inserted within the pedicle without any signs of breach. A new 3D VSP strategy was developed for guiding occipital keel screws and used in combination with earlier reported pedicle drill guides.

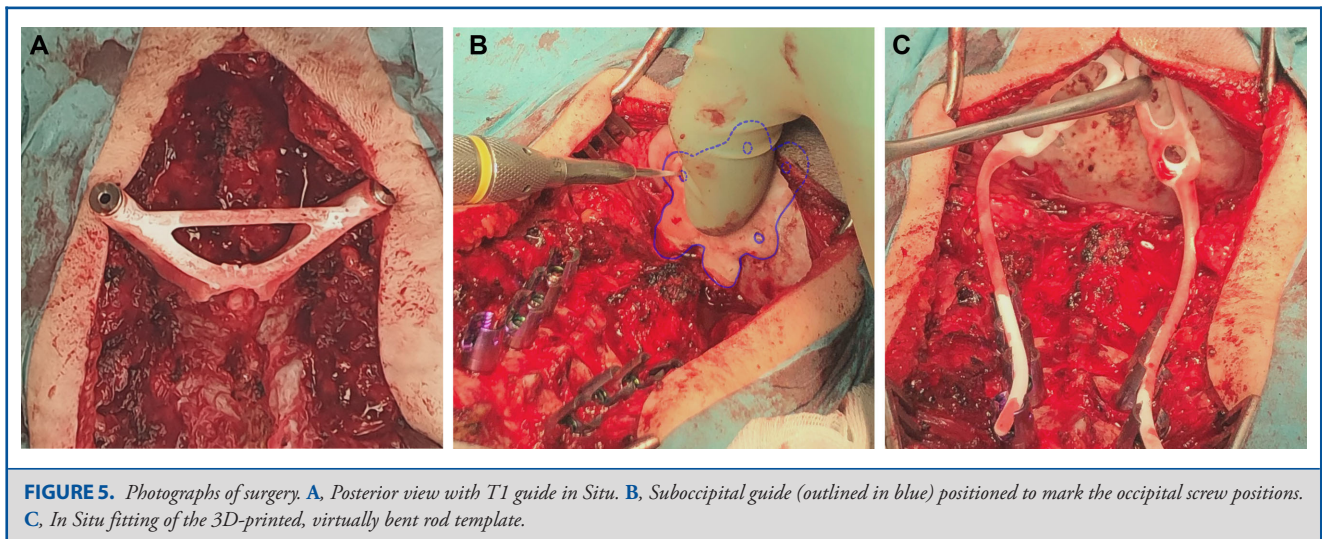
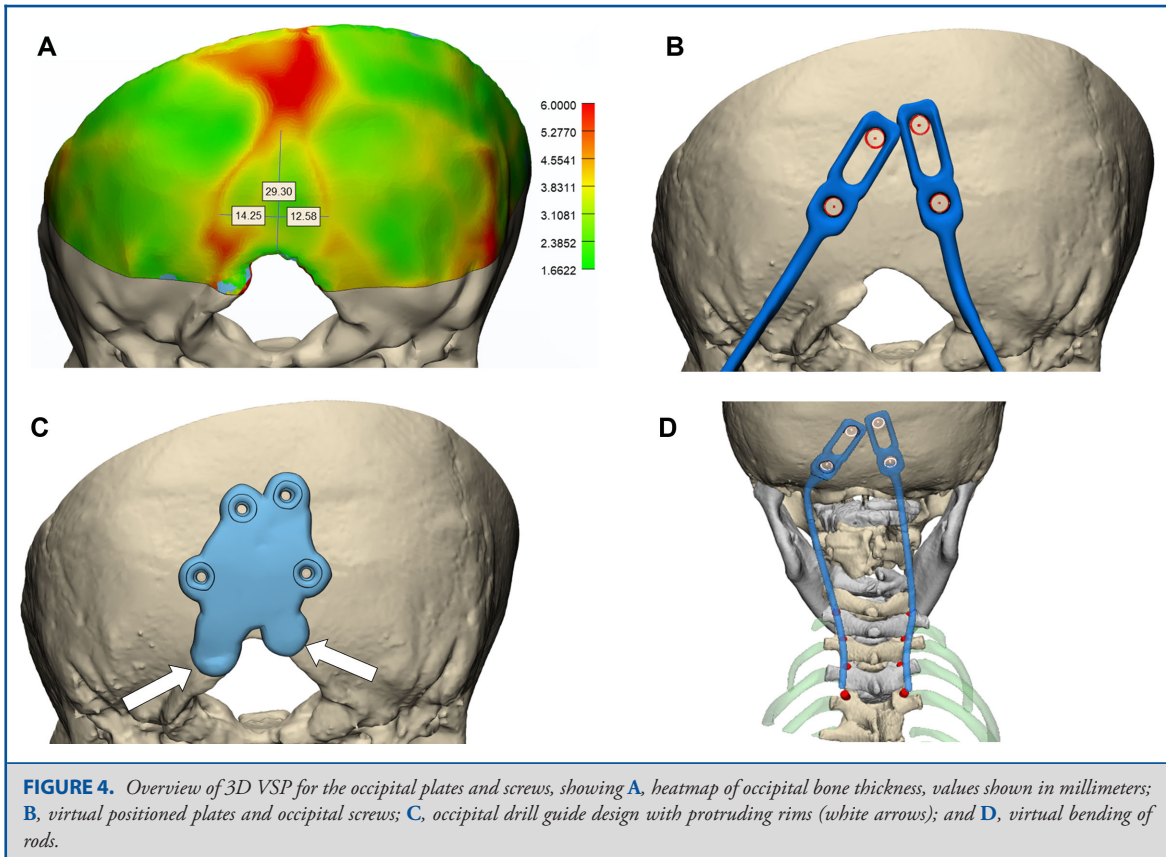
One drawback of current described workflow is the labor-intensive preoperative phase, which requires a 3D-planning facility, appropriate Conformité Européenne-marked software, and qualified technical personnel. On the other hand, senior surgeons reported that the extensive preplanning saved a considerable amount of intraoperative time because of the preplanned screw sizes, properly aligned screws, and not having to configure

computer navigation. This particular case roughly required half a day of work for an experienced technical medical physician, who was responsible for virtual planning and the design of the guides. The 3D-printed parts were produced externally according to medical device ISO 13485 standards for a total cost of 150 USD. These estimates however hugely depend on experience and might also in future change with the increasingly widespread availability of medical 3D-printing facilities.

In the current described workflow, intraoperative rod plate bending imposed some problems. Because virtual bending of the rod was unrestricted, this might have resulted in unrealistic planned curvatures (Figure 5B, left plate). In addition, the 3D-printed rod template was not rigid enough to be able to be used as a reliable guide during surgery.

A possible solution to overcome the issue regarding intraoperative rod contouring could be to add limitations to the virtual rod bending in order to create a more realistic plan for the rods' shape. Also, preoperative bending followed by sterilization might reduce the intraoperative time required for rod positioning. An alternative and more expensive solution would be to acquire patient specific rods by use of metal milling or 3D printing. Sunderland et al¹⁹ described a technique for intraoperative creation of skull implants with the aid of 3D-printed molds that could compress a stock implant into a predefined shape. A similar concept might be applicable for contouring of rods.

The present article reports the novel use of VSP for positioning of occipital plates, but because of the rarity of cases, it was limited to describing the technical aspects and use of this new method for 1 particular case. Hence, future studies should explore this technique for different variations of occipital plates and perform comprehensive accuracy studies relating the findings to the clinical outcomes.



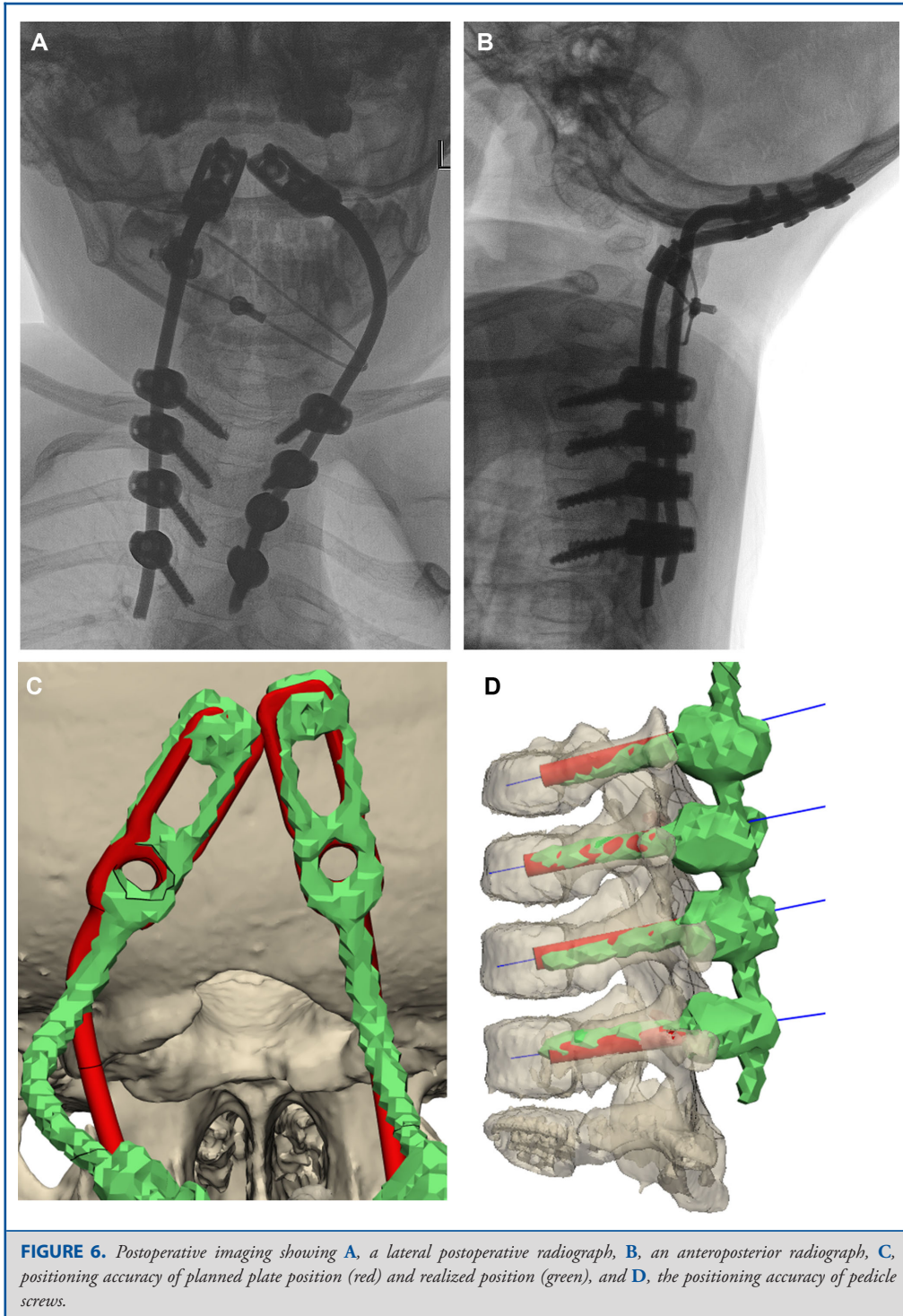
CONCLUSION

The novel use of 3D VSP for occipital screws in addition to the use of earlier reported pedicle drill guides have greatly facilitated the performance of the occipitothoracic fixation for this case and

could, in the future, contribute to safer pediatric spinal fixation procedures.

Funding

This study did not receive any funding or financial support.



Disclosures

The authors have no personal, financial, or institutional interest in any of the drugs, materials, or devices described in this article.

REFERENCES

1. Nguyen HV, Ludwig SC, Silber J, et al. Rheumatoid arthritis of the cervical spine. *Spine J*. 2004;4(3):329-334.
2. Song D, Maher CO. Spinal disorders associated with skeletal dysplasias and syndromes. *Neurosurg Clin N Am*. 2007;18(3):499-514.
3. Tredwell SJ, Newman DE, Lockitch G. Instability of the upper cervical spine in Down syndrome. *J Pediatr Orthop*. 1990;10(5):602-606.
4. Wolfs JFC, Kloppenburg M, Fehlings MG, van Tulder MW, Boers M, Peul WC. Neurologic outcome of surgical and conservative treatment of rheumatoid cervical spine subluxation: a systematic review. *Arthritis Rheum*. 2009;61(12):1743-1752.
5. Finn MA, Fassett DR, McCall TD, Clark R, Dailey AT, Brodke DS. The cervical end of an occipitocervical fusion: a biomechanical evaluation of 3 constructs. *J Neurosurg Spine*. 2008;9(3):296-300.
6. Winegar CD, Lawrence JP, Friel BC, et al. A systematic review of occipital cervical fusion: techniques and outcomes: a review. *J Neurosurg Spine*. 2010;13(1):5-16.
7. Hurlbert RJ, Crawford NR, Choi WG, Dickman CA. A biomechanical evaluation of occipitocervical instrumentation: screw compared with wire fixation. *J Neurosurg Spine*. 1999;90(1):84-90.
8. Groen JL, Peul WC, Pondaag W. Fusion rates support wired allograft combined with instrumented craniocervical fixation in the paediatric population. *Acta Neurochir (Wien)*. 2020;162(5):985-991.
9. Pu X, Yin M, Ma J, et al. Design and application of a novel patient-specific three-dimensional printed drill navigational guiding in atlantoaxial pedicle screw placement. *World Neurosurg*. 2018;114:e1-e10.
10. Sugawara T, Kaneyama S, Higashiyama N, et al. Prospective multicenter study of a multistep screw insertion technique using patient-specific screw guide templates for the cervical and thoracic spine. *Spine (Phila Pa 1976)*. 2018;43(23):1685-1694.
11. Pijpker PAJ, Kraeima J, Witjes MJH, et al. Accuracy assessment of pedicle and lateral mass screw insertion assisted by customized 3D-Printed drill guides: a human cadaver study. *Oper Neurosurg*. 2019;16(1):94-102.
12. McInerney-Leo AM, Sparrow DB, Harris JE, et al. Compound heterozygous mutations in RIPPLY2 associated with vertebral segmentation defects. *Hum Mol Genet*. 2015;24(5):1234-1242.
13. Cronin CG, Lohan DG, Mhuirheartigh JN, Meehan CP, Murphy J, Roche C. CT evaluation of Chamberlain's, McGregor's, and McRae's skull-base lines. *Clin Radiol*. 2009;64(1):64-69.
14. Reintjes SL, Amankwah EK, Rodriguez LF, Carey CC, Tuite GF. Allograft versus autograft for pediatric posterior cervical and occipito-cervical fusion: a systematic review of factors affecting fusion rates. *J Neurosurg Pediatr*. 2016;17(2):187-202.
15. Hwang SW, Gressot L V, Rangel-Castilla L, et al. Outcomes of instrumented fusion in the pediatric cervical spine. *J Neurosurg Spine*. 2012;17(5):397-409.
16. Gao F, Wang Q, Liu C, Xiong B, Luo T. Individualized 3D printed model-assisted posterior screw fixation for the treatment of craniovertebral junction abnormality: a retrospective study. *J Neurosurg Spine*. 2017;27(1):29-34.
17. Willemsen K, Nizak R, Noordmans HJ, Castelein RM, Weinans H, Kruyt MC. Challenges in the design and regulatory approval of 3D-printed surgical implants: a two-case series. *Lancet Digit Heal*. 2019;1(4):e163-e171.
18. Mobbs RJ, Parr WCH, Choy WJ, McEvoy A, Walsh WR, Phan K. Anterior lumbar interbody fusion using a personalized approach: is custom the future of implants for anterior lumbar interbody fusion surgery? [published online ahead of print: January 8, 2019]. *World Neurosurg*. doi:10.1016/j.wneu.2018.12.144.
19. Sunderland IRP, Edwards G, Mainprize J, Antonyshyn O. A technique for intraoperative creation of patient-specific titanium mesh implants. *Plast Surg*. 2015;23(2):95-99.

COMMENT

The authors have adopted 3D printing templates to guide screw trajectory and rod bending in a complex occipitocervical case. The authors report a very successful outcome with this new technology, albeit labor intensive with planning. The increasing access and decreasing costs of 3D printing overlap well with the complex and often unique anatomic variants encountered in the pediatric OC junction. Whether 3D printing or intraoperative navigation for screw trajectory is better remains to be seen, but cost and access may favor 3D printing.

Steven Hwang
Boston, Massachusetts, USA